

# Equine Herpesvirus 9 (EHV-9) Induced Encephalitis in Nonhuman Primates

Tokuma Yanai, Atsushi Kodama, Hiroki Sakai, Hideto Fukushi,  
Takeshi Kuraishi, Seisaku Hattori and Chieko Kai  
*The University of Tokyo, Gifu University  
Japan*

## 1. Introduction

Equine Herpesvirus 9 (EHV-9) is a new member of the equine herpesviruses which was isolated from Thomson's gazelles (*Gazella thomsoni*) that died of fulminant encephalitis in a Japanese zoo (Fukushi et al., 1997; Yanai et al., 1998). Previously, experimental infections of EHV-9 were conducted in various species of animals other than primates to clarify the infectivity and virulence of this virus and to assess the emerging aspects of EHV-9 in zoo and domestic animal populations. EHV-9 caused fatal infections with fulminant encephalitis characterized by neuronal degeneration and necrosis as well as intra-nuclear inclusion bodies in rodents (Fukushi et al., 1997; Fukushi et al., 2000), goats (Taniguchi et al., 2000), pigs (Narita et al., 2000, 2001), dogs (Yanai et al., 2003a) and cats (Yanai et al., 2003b). Based on several experimental studies of EHV-9 involving various domestic animals such as dogs and cats often found in close proximity to humans, there were grave concerns that EHV-9 could be transmitted to humans through contact with affected animals or zebras through certain routes. In order to assess the risk of EHV-9 to humans, we tried to determine the infectivity of EHV-9 in non-human primates, including common marmosets (*Callithrix jacchus*) and cynomolgus macaques (*Macaca fascicularis*), which have strong similarities to humans, using the nasal route.

## 2. Marmosets

One female and four male common marmosets, aged 2 to 4 years old and weighing 285-368g, were used for this assessment (Kodama et al., 2007). Four of the marmosets were inoculated intranasally with 1ml of EHV-9 virus solution containing  $10^6$  plaque-forming units. The other was inoculated with 1 ml of MEM as a negative control. The inoculated animals were humanely euthanatized on Days 3, 4 and 5 following inoculation, respectively, at a point when they were in poor condition or dying from a neuronal disorder. The virus was recovered and identified by polymerase chain reaction (PCR) with the primers targeting the EHV-9 specific region of the EHV-9 gene. The PCR primers used for amplification were 5'-CTGGGTATAGATTGTCGCCTC-3' and 5'-CCCAGAAAGTATTACACGCGAT-3'. The neutralization test was done using the 50% plaque reduction method with the MDBK cell monolayer.

All four of the inoculated animals exhibited various neurological signs and finally collapsed. From the second day post-inoculation (dpi), all four inoculated marmosets began to exhibit signs of anorexia and depression. A decrease in body weight was noted from 3 dpi. At 3 dpi, rectal temperatures in each of the treated animals were approximately 2 to 3 degrees lower than those in the non-treated control animal, although the animals recovered from the hypothermia the following day. From 3 to 5 dpi, the inoculated animals showed varying degrees of neurological signs consisting of salivation (Fig. 1), star gazing, convulsions and finally coma. At 4 and 5 dpi the animals refused food, became severely depressed, and collapsed. One animal was euthanized based on schedule, but two animals were euthanized at 3 dpi due to poor condition, and the last one was euthanized at 5 dpi. The control animal was euthanized at 6 dpi.



Fig. 1. Marked salivation with a large amount of foamy saliva at 4 dpi.

At necropsy, no significant abnormalities were observed in the external or visceral organs in any of the inoculated animals.

Histologically, the affected animals had severe encephalitis characterized by neuronal degeneration and necrosis with intra-nuclear inclusions, which extended from the olfactory bulb to the rhinencephalon and piriform lobe. The nuclei of affected degenerating neuronal cells exhibited severe degrees of chromatolysis or karyorrhexis, eventually resulting in neuronal loss and cellular debris (Fig. 2). The degenerating neuronal cells had frequent intra-nuclear inclusion bodies which were equivalent to herpesvirus in morphology, appearing as full-inclusion or Cowdry type A inclusions (Figs. 2 and 3). The inclusion bodies were particularly frequent in the olfactory bulb, piriform lobe and amygdaloid body in the affected animals. Cerebrum lesions were observed in all layers of the olfactory bulb, the piriform lobe (Fig. 4) and a part of the temporal lobe in an animal euthanized at 3 dpi.

The lesions then spread to the basal ganglia, except for the globus pallidus, and the limbic lobe, including the hippocampus and cingulate gyrus, basal forebrain and temporal lobe in the animals (Fig. 5). The animal euthanized at 5 dpi had widely distributed lesions in the cerebrum. No abnormalities were observed in the cerebellum or spinal cord. Immunohistochemistry to EHV-9 antibody revealed positive reactions in the nucleus, intranuclear inclusions and the cytoplasm in degenerating neuronal cells, and occasionally in normal-appearing neuronal cells in the marginal zone or surroundings of affected areas in the brain (Fig. 6). Prominent inclusion bodies appearing as the full-inclusion type had the most intensely positive reaction around the nuclear membrane.

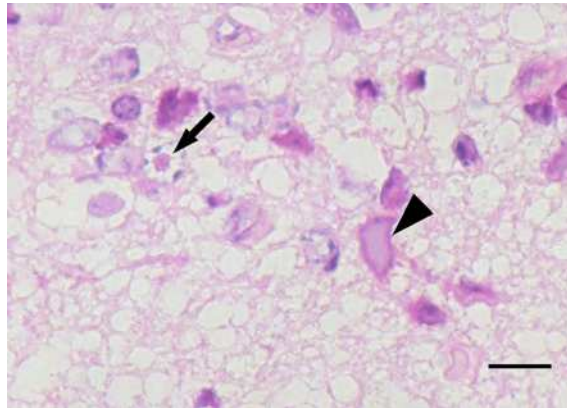


Fig. 2. Olfactory bulb; Neuronal necrosis with intra-nuclear inclusion bodies, appearing as Cowdry type A (arrow) or full-inclusion (arrow head) inclusions. HE. Bar=3.5 $\mu$ m.

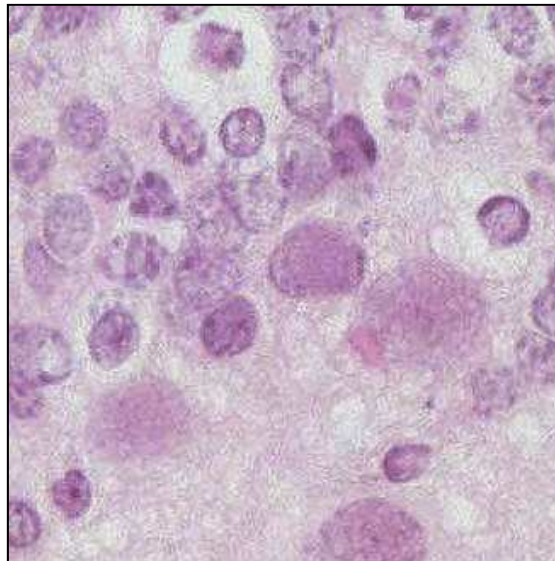


Fig. 3. Olfactory bulb; Frequent intra-nuclear inclusions. HE.

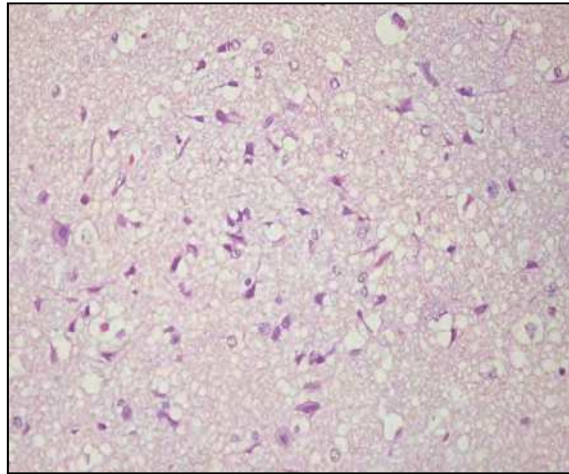


Fig. 4. Piriform lobe; Neuronal degeneration and necrosis with intra-nuclear inclusions.

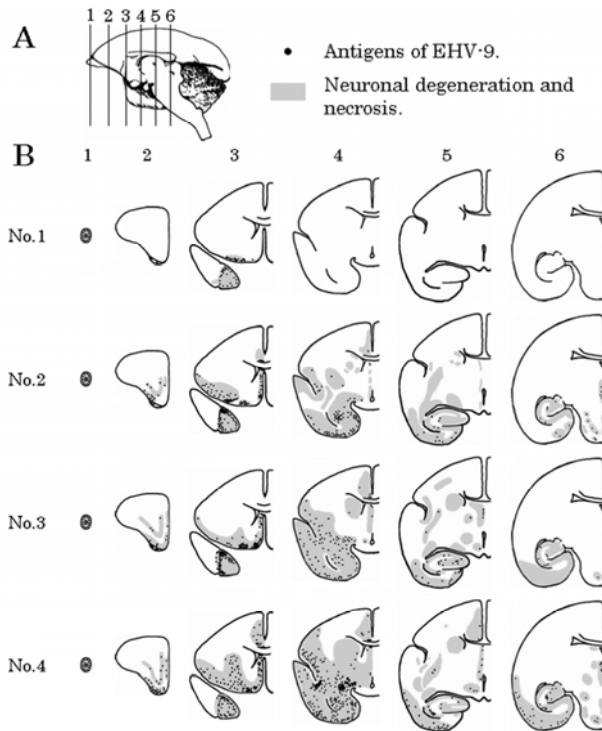


Fig. 5. Time-course extension of EHV-9 induced encephalitis in the brain.

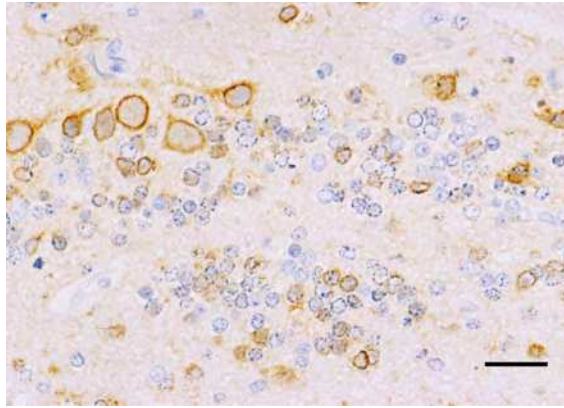


Fig. 6. Olfactory bulb. Most neuronal cells in all layers of the glomerular, mitral and granule layers are frequently positive to EHV-9 antigen. ABC method. Bar=5.7 $\mu$ m. Immunostaining for EHV-9 antigen. Frequent positive reactions.

In the nasal cavities of all of the animals inoculated with EHV-9, there was severe necrotizing rhinitis characterized by severe necrosis of the olfactory epithelium and olfactory glands in the olfactory area (Fig. 7). The marmosets that had been inoculated exhibited more severe desquamation of the olfactory epithelium, as well as degeneration and necrosis at 3 dpi. In addition, occasional olfactory Schwann cells were degenerative or necrotic. Frequent intra-neuronal inclusion bodies were seen in the degenerating epithelial cells in both the olfactory epithelium and olfactory glandular epithelium (Fig. 8). In the respiratory area, slight focal necrosis and ablation were occasionally observed in the mucosa. Immunohistochemically, there were frequent positive reactions in both intra-nuclear inclusion bodies and the cytoplasm of degenerating cells in the olfactory epithelium and olfactory glandular epithelium in all animals inoculated with EHV-9 (Figs. 9, 10). Occasional degenerating mucosal epithelium in the respiratory area and degenerating Schwann cells also had positive reactions.

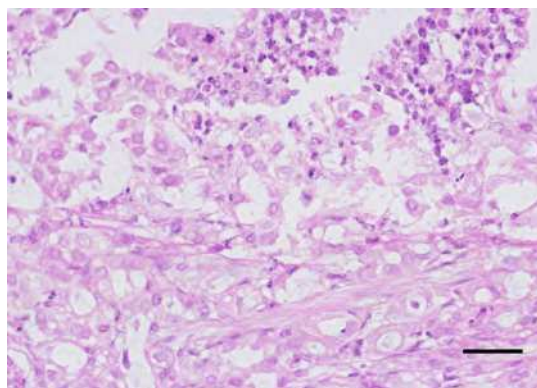


Fig. 7. Olfactory area in the nasal cavity; The degenerating epithelium and olfactory glandular epithelium with frequent intranuclear inclusions. HE. Bar = 8.6  $\mu$  m

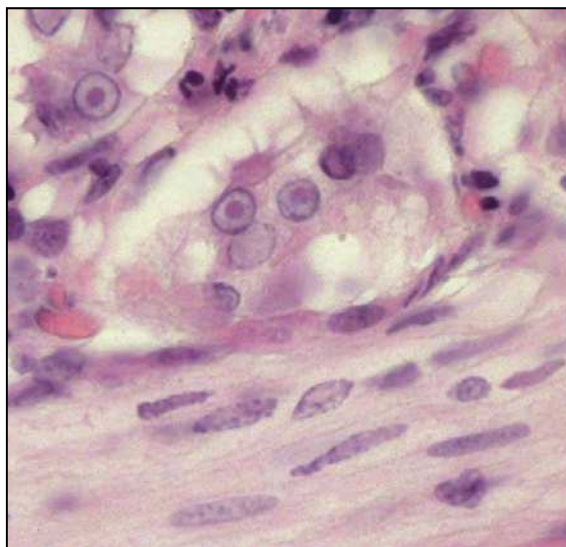


Fig. 8. Olfactory area in the nasal cavity; Frequent intra-neuronal inclusion bodies are seen epithelium and olfactory glandular epithelium. HE.

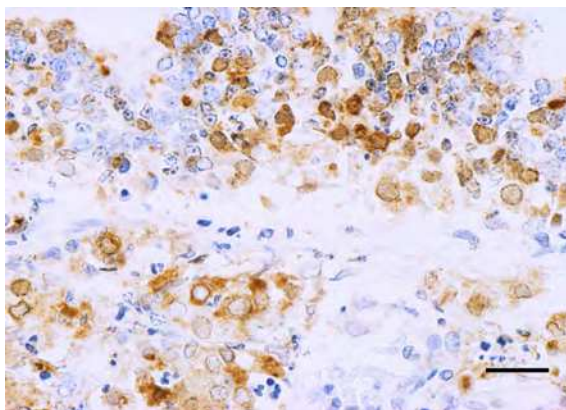


Fig. 9. Olfactory area in the nasal cavity; Positive reaction is seen in the degenerating epithelial cells in both the olfactory epithelium and olfactory glandular epithelium. Immunohistochemical stain for EHV-9. ABC method. Bar=8.6 $\mu$ m.

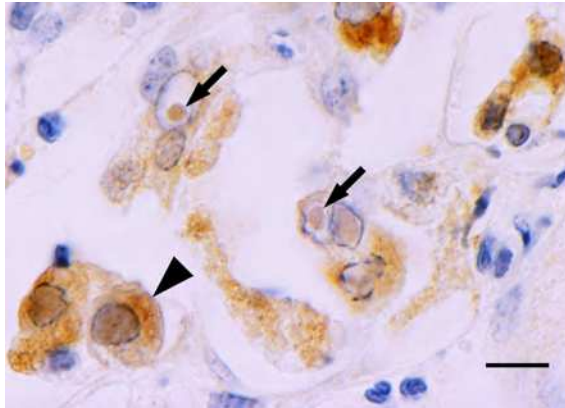


Fig. 10. Olfactory area in the nasal cavity; Positive reaction is seen at the intra-nuclear inclusion bodies (arrows), nucleus and cytoplasm (arrow head) in the degenerating olfactory glandular epithelial cells. Immunohistochemical stain for EHV-9. ABC method. Bar=3.3 $\mu$ m.

EHV-9 was recovered from the olfactory bulb and frontal lobe in all inoculated marmosets. In addition, EHV-9 was isolated from the lung in one marmoset and from the salivary gland and mandible lymph node in one marmoset. The recovered virus was confirmed to be EHV-9 by the PCR method. The EHV-9 virus was not neutralized by 4-times dilution serum in the neutralization test. No virus was isolated from other organs or blood.

EHV-9 demonstrated ready infectivity and rapid progression of the disease in marmosets, which indicates the possibility of EHV-9 infectivity in primates, including humans, as in other domestic animals and rodents. Nasal inoculation of EHV-9 resulted in varying degrees of encephalitis in a wide variety of animals, including rodents, domestic ruminants and companion animals. As with other novel herpesvirus infections such as pseudorabies virus infection in dogs (Yanai et al., 2003a) and B virus infection in humans (Adam and Graham, 1994), EHV-9 could possibly be more virulent in unusual hosts than in the natural host. The pathogenicity of EHV-9 to humans is currently unknown; however, we may be able to assess the virulence of EHV-9 in humans to a certain extent by using nonhuman primates as a model because nonhuman primates have many infectious diseases in common with humans. It was estimated that EHV-9 could possibly be pathogenic to humans if nonhuman primates were infected with it. We used common marmosets for the experimental infection of EHV-9 because they are commonly used for experiments and because they are known to be susceptible to some herpesviruses. Generally, nonhuman primates are highly susceptible to cross-species infectivity by human alpha-herpesvirus, including herpes simplex virus (HSV). In new world monkeys, HSV causes outbreaks characterized by severe ulcerative gingivostomatitis and encephalitis, and these outbreaks are quick to occur in zoo-housed marmosets, with marmosets being thought to be highly susceptible to HSV (Matz-Rensing et al., 2003). On the other hand, simian herpes virus, Herpesvirus B (Cercopithecine herpesvirus 1), has been implicated as the cause of approximately 40 cases of meningoencephalitis affecting persons in direct or indirect contact with laboratory macaques (Weigler, 1992).

In marmosets, as in other animals, EHV-9 shows strong neurotropism and causes selective neuronal necrosis. The distribution of lesions and the virus are most similar to those in cats

(Yanai et al., 2003b). As the most severely affected area was the olfactory bulb, the virus inoculated into the nasal cavity gained access to the olfactory bulb and then progressed along the rhinencephalon over time. In our study, all of the marmosets inoculated intranasally had severe rhinitis with intranuclear inclusions, and EHV-9 antigen was detected in the olfactory epithelium and glands. From these findings, the EHV-9 inoculated into the nasal cavity presumably multiplied in the olfactory mucosa, and then intruded into the nerve sheath connected to the olfactory bulb, going through the foramina in the cribriform plate of the ethmoid bone. As the olfactory epithelium is usually covered by secretory cells produced in the olfactory glands, the question remains of how the virus infected the epithelial and glandular cells. The inclusion body formation in the glandular epithelium indicated that a large amount of EHV-9 virus had multiplied in the olfactory glands and shed into the nasal cavity. This suggests that, once EHV-9 has infected the nasal mucosa, the marmoset sheds a large enough quantity of virus for transmission to another animal when contact occurs. In addition, a smaller amount of the virus may cause rhinitis with viral propagation once the virus intrudes into the nasal cavity. However, in the present study, it was not clear how the nerve axons were affected by the EHV-9 in the olfactory mucosa, or how the virus in the nerve sheath migrated to the olfactory bulb.

The study demonstrated that marmosets can be infected by a larger dose of EHV-9 by the intranasal route. It suggests the possibility that EHV-9 might be transmitted to other primates, including macaques, great apes and humans. EHV-9 might also be easily transmitted via the nasal route to immuno-compromised animals and patients such as AIDS patients. A recent study showed that Burchell's zebras (*Equus burchelli*) in Tanzania had a high seroprevalence to EHV-9 or to viruses serologically similar to EHV-9 (Borcher et al., 2005), which suggested that EHV-9 is present in zebras permanently residing in East Africa. Also, there has been some possibility of an outbreak of EHV-9 infection as an emerging infection in immuno-compromised animals and patients.

### 3. Cynomolgus macaques

One male and four female cynomolgus macaques were obtained from a commercial breeder (Kodama et al., 2011). All of the animals were free from pathogens such as salmonella and *Mycobacterium spp.* and passed the viral antibody tests for B virus and measles virus. The animals were divided into two groups consisting of Nos. 1 and 2 in one group and Nos. 3 and 4 in the other, and the two groups were inoculated intranasally with 1 ml of EHV-9 virus solution containing  $10^3$  and  $10^6$  plaque-forming units, respectively. The virus fluid was prepared by propagating the fifth passage of the original stock, which is in Madin-Darby bovine kidney (MDCK) cells, in fetal horse kidney cells. The infectivity of the inoculums was confirmed by virus plaque assay with MDCK cells. As a control, cynomolgus monkey No. 5 was inoculated with 1 ml of minimal essential medium. Animals Nos. 1 and 3 were euthanized in accordance with animal welfare regulations on 6 dpi. The other animals were euthanized on 10 dpi.

In contrast with the control animal, the inoculated animals began avoiding light starting from 4 dpi. Blood studies showed no hematological abnormalities in any of the animals.

At necropsy, no significant abnormalities were observed in any organs from any of the animals.

Histopathologically, no significant pathological changes were observed in any of the organs from any of the animals. Immunohistochemistry revealed no positive reactions in any of the



organs or tissues, including the nasal cavities or brains of the animals. In the amplification of the gene for gB (ORF33) using specific primers for EHV-9 by PCR, no bands were detected in any of the samples from the right olfactory bulb, right cerebrum or right cerebellum, the blood samples, or the nasal swabs. It was demonstrated that the nasal swabs had no infectivity. The EHV-9 virus was not neutralized by the serum from any of the animals in the neutralization test.

The results in this study suggest that EHV-9 may be non-pathogenic for adult cynomolgus monkeys. The etiology for the clinical symptom was not apparent because there were no histopathological changes. However, the symptom may have been a response to the EHV-9 inoculation.

Although lethal encephalitis was induced via the nasal, oral, intraperitoneal and ocular routes of EHV-9 inoculation in hamsters (El-Habashi et al., 2010), the intranasal route may be the most probable one. In addition, EHV-9 replicated in the olfactory epithelium and olfactory glandular epithelium in common marmosets (Kodama et al., 2007). Based on those results, successful infection to the olfactory epithelium might be among the essential factors for following EHV-9 induced encephalitis. The proportion of surface area covered by the olfactory epithelium in macaques may be considerably smaller than that in rodents and dogs (Herkema, 1991). Thus, there may be constitutional barriers to the entrance of the EHV-9 into the olfactory epithelium. However, because it has been suggested that the relative amount of the olfactory epithelium in common marmosets is much closer to that of macaques than that of rats, the constitutional distinction may not be associated with EHV-9 infection induced via the intranasal route (Wako et al., 1999).


#### **4. Conclusion: EHV-9 can induce encephalitis in primates, including humans**

In assessments of infectivity of EHV-9 in nonhuman primates, there were different results between new world and old world monkeys. While EHV-9 caused fulminant encephalitis, no infectivity was seen in cynomolgus macaques. It is still uncertain whether macaques have barriers to invasion of EHV-9 at the entrance, and this could apply to humans as well. Thus, it has not been determined that EHV-9 can cross the species barrier between new world and old world monkeys and humans. It is also uncertain whether EHV-9 can infect immune-compromised patients like AIDS patients, infants or elderly people. Ocular transmission of viruses to the CNS has been suspected in many viral diseases such as Cercopithecine herpes virus 1 (B-virus) in humans (CDC, 1999). Fatal infection by B-virus in humans via ocular exposure from biological fluid from macaque monkeys has been reported (CDC, 1999). Further studies using nonhuman primates may be needed to assess the risk to infants from the ocular route of infection.

#### **5. References**

- [1] Adams JH, Graham DI: Virus and other infections. *In: An Introduction to Neuropathology*, second edition, pp. 103-132. Churchill Livingstone, Edinburgh, 1994
- [2] Borchers K, Wiik H, Frolich K, Ludwig H, East ML: Antibodies against equine herpesviruses and equine arteritis virus in Burchell's zebras (*Equus burchelli*) from the Serengeti ecosystem. *J Wildl Dis* 41: 80-86, 2005

- [3] CDC (1999): Hazard ID 5- Cercopithecine herpesvirus 1 (B Virus) infection resulting from ocular exposure. National Institute for Occupational Safety and Health (NIOSH), Publication, 99-100.
- [4] El-Habashi N, Murakami M, EL-Nahass E, Hibi D, Sakai H, Fukushi H, Sasseville V, Yanai T: Study on the infectivity of equine herpesvirus 9 (EHV-9) by different routes of inoculation in hamsters. *Vet Pathol* 47: 1-7, 2010
- [5] Fukushi H, Tomita T, Taniguchi A, Ochiai Y, Kirisawa R, Matsumura T, Yanai T, Masegi T, Yamaguchi T, Hirai K: Gazelle herpesvirus 1: a new neurotropic herpesvirus immunologically related to equine herpesvirus 1. *Virology* 227: 34-44, 1997
- [6] Fukushi H, Taniguchi A, Yasuda K, Yanai T, Masegi T, Yamaguchi T, Hirai K: A hamster model of equine herpesvirus 9 induced encephalitis. *J Neurovirol* 6: 314-319, 2000
- [7] Herkema JR: Comparative aspects of nasal airway anatomy; relevance to inhalation toxicology. *Toxicol Pathol* 19: 321-336, 1991
- [8] Kodama A, Yanai T, Yomemaru K, Sakai H, Masegi T, Yamada S, Fukushi H, Kuraishi T, Hattori S, Kai C: Acute neuropathogenicity with experimental infection of equine herpesvirus 9 in common marmosets (*Callithrix jacchus*). *J Med Primatol* 36 : 335 – 342, 2007
- [9] Kodama A, Yanai T, Kubo M, El-Habashi N, Kasem S, Sakai H, Masegi T, Fukushi H, Kuraishi T, Hattori S, Kai C: Cynomolgus monkeys (*Macaca fascicularis*) may not become infected with equine herpesvirus 9. *J Med Primatol* 40: 18 – 20, 2011
- [10] Matz-Rensing K, Jentsch KD, Rensing S, Langenhuyzen S, Verschoor E, Niphuis H, Kaup FJ: Fatal Herpes simplex infection in a group of common marmosets (*Callithrix jacchus*). *Vet Pathol* 40: 405-411, 2003
- [11] Narita M, Uchimura A, Kimura K, Tanimura N, Yanai T, Masegi T, Fukushi H, Hirai K: Brain lesions and transmission of experimental equine herpesvirus type 9 in pigs. *Vet Pathol* 37: 476-479, 2000
- [12] Narita M, Uchimura A, Kawanabe M, Fukushi H, Hirai K: Invasion and spread of equine herpesvirus 9 in the olfactory pathway of pigs after intranasal inoculation. *J Comp Pathol* 124: 265-272, 2001
- [13] Taniguchi A, Fukushi H, Yanai T, Masegi T, Yamaguchi T, Hirai K: Equine herpesvirus 9 induced lethal encephalomyelitis in experimentally infected goats. *Arch Virol* 145: 2619-2627, 2000
- [14] Wako K, Hiratsuka H, Katsuta O, Tsuchitani M: Anatomical structure and surface epithelial distribution in the nasal cavity of the common cotton-eared marmoset (*Callithrix jacchus*). *Exp Animal* 48:31-36, 1999
- [15] Weigler BJ: Biology of B virus in macaque and human hosts: a review. *Clin Infect Dis* 14: 555-567, 1992
- [16] Yanai T, Sakai T, Fukushi H, Hirai K, Narita M, Sakai H, Masegi T: Neuropathological study of gazelle herpesvirus 1 (equine herpesvirus 9) infection in Thomson's gazelles (*Gazella thomsoni*). *J Comp Pathol* 119: 159-168, 1998
- [17] Yanai T, Fujishima N, Fukushi H, Hirata A, Sakai H, Masegi T: Experimental infection of equine herpesvirus 9 in dogs. *Vet Pathol* 40: 263-267, 2003a
- [18] Yanai T, Tujioka S, Sakai H, Fukushi H, Hirai K, Masegi T: Experimental infection with equine herpesvirus 9 (EHV-9) in cats. *J Comp Pathol* 128: 113-118, 2003b



## **Non-Flavivirus Encephalitis**

Edited by Dr. Sergey Tkachev

ISBN 978-953-307-720-8

Hard cover, 360 pages

**Publisher** InTech

**Published online** 16, November, 2011

**Published in print edition** November, 2011

This book covers the different aspects of non-flavivirus encephalitis of different etiology. The first section of the book considers general problems of epidemiology such as study of zoonotic and animal vectors of encephalitis causative agents and methods and approaches for encephalitis zoonoses investigations. The members of different virus species are known to be the causative agents of encephalitis, so the second section of the book is devoted to these viral pathogens, their epidemiology, pathology, diagnostics and molecular mechanisms of encephalitis development by such viruses as HIV/SIV, herpes simplex virus type 1 and equine herpesvirus 9, measles virus, coronaviruses, alphaviruses and rabies virus. The next section of the book concerns the study of protozoan pathogens such as toxoplasma and amoebae. The last section of the book is devoted to multicellular pathogen as human *Filaria Loa Loa* - a filarial worm restricted to the West Africa.

### **How to reference**

In order to correctly reference this scholarly work, feel free to copy and paste the following:

Tokuma Yanai, Atsushi Kodama, Hiroki Sakai, Hideto Fukushi, Takeshi Kuraishi, Seisaku Hattori and Chieko Kai (2011). Equine Herpesvirus 9 (EHV-9) Induced Encephalitis in Nonhuman Primates, Non-Flavivirus Encephalitis, Dr. Sergey Tkachev (Ed.), ISBN: 978-953-307-720-8, InTech, Available from: <http://www.intechopen.com/books/non-flavivirus-encephalitis/equine-herpesvirus-9-ehv-9-induced-encephalitis-in-nonhuman-primates>

**INTECH**  
open science | open minds

### **InTech Europe**

University Campus STeP Ri  
Slavka Krautzeka 83/A  
51000 Rijeka, Croatia  
Phone: +385 (51) 770 447  
Fax: +385 (51) 686 166  
[www.intechopen.com](http://www.intechopen.com)

### **InTech China**

Unit 405, Office Block, Hotel Equatorial Shanghai  
No.65, Yan An Road (West), Shanghai, 200040, China  
中国上海市延安西路65号上海国际贵都大饭店办公楼405单元  
Phone: +86-21-62489820  
Fax: +86-21-62489821

© 2011 The Author(s). Licensee IntechOpen. This is an open access article distributed under the terms of the [Creative Commons Attribution 3.0 License](#), which permits unrestricted use, distribution, and reproduction in any medium, provided the original work is properly cited.