

# Exacerbation of Viral Myocarditis by Tobacco Smoke: The Catecholamine Hypothesis

Nicolas Hanabergh and James P. Morgan

*Steward Carney Hospital, Dorchester, Steward St. Elizabeth's Medical Center, Boston  
and Tufts University School of Medicine, Boston,  
United States of America*

## 1. Introduction

### 1.1 Tobacco smoke exposure and cardiovascular disease

More than 1 in every 10 cardiovascular deaths in the world during the year 2000 were attributable to smoking, demonstrating that it is an important preventable cause of cardiovascular mortality (Ezzati et al., 2005). It has been clearly established that exposure to environmental tobacco smoke increases the risk of cardiovascular disease among persons who have never smoked (Steenland, 1992). The cardiovascular effects of secondhand smoke are nearly as large as those confronting the principal smoker (Barnoya & Glantz, 2005). Non-smokers living with smokers have about a 25% increase in risk of death from heart disease and are more likely to suffer a stroke. Exposure to secondhand smoke may increase the risk of heart disease by non-smokers as much as 60% (Whincup et al., 2004). In 2004, Ong & Glantz estimated that only about 69% of U.S. indoor workers were covered by a smoke-free workplace policy. Making all workplaces smoke free as been accomplished for the commercial aircraft industry (Repace, 2004) would in one year prevent about 1500 myocardial infarctions and 350 strokes, and result in nearly 49 million dollars in savings in direct medical costs. These estimates are supported by reports of reduced incidence of admissions for myocardial infarction associated with smoking bans (Sargent et al., 2004).

The cardiovascular effects of tobacco smoke exposure have been summarized in several excellent reviews (for example, see Barnoya and Glantz, 2005). Among the strongest pathophysiological correlates of tobacco smoking are accelerated endothelial dysfunction (Puranik & Celermajer, 2003) and acute clinical events, the latter being largely thrombotic (Ambrose & Barus, 2004). Recent studies indicate that increased oxidative stress is a potential mechanism for initiating cardiovascular dysfunction (Yang et al., 2004; Talukder et al, 2011). Tobacco smoke has also been demonstrated to increase inflammatory markers in patients exposed to secondhand smoke, including homocysteine, C-reactive protein, fibrinogen, and oxidized LDL cholesterol, (Panagiotakos et al., 2004) suggesting that an increased inflammatory response may contribute to accelerated atherosclerosis. Clearly, the incidence of ischemic coronary and peripheral vascular disease is increased in patients exposed to tobacco smoke, either as smokers or through exposure to secondhand tobacco smoke (Ambrose & Barus, 2004; Benowitz, 2003; Law & Wald, 2003; Burns, 2003; Leone et al., 2004). The cardiovascular effects of tobacco smoke exposure are summarized in Table I.

## **MECHANISMS OF CARDIAC AND VASCULAR INJURY FROM TOBACCO SMOKE EXPOSURE**

**Initiates inflammatory response**  
**Enhanced platelet activation and thrombosis**  
**Increased oxidative stress**  
**Increased insulin resistance**  
**Endothelial cell dysfunction**  
**Accelerates atherosclerosis**

Table 1. Cardiovascular effects of tobacco smoke exposure.

### **1.2 Tobacco smoke exposure and heart failure**

National hospital discharge surveys estimate that 4.8 million Americans have heart failure, which has become an increasingly frequent reason for inpatient admission (Ho et al., 1993). One recent study estimated that among individuals aged 55 and older almost 1 in 3 will develop heart failure during their remaining lifespan. Heart failure is a fatal disease, with only 35% surviving 5 years after diagnosis (Bleumink et al., 2004). Coronary disease and diabetes mellitus along with hypertension are the leading causes of heart failure in the United States and it is therefore not surprising that tobacco smoke exposure has been identified as an independent risk factor for developing heart failure (Kannel et al., 1994; He et al., 2001). However, in at least 5% of patients, the cause of heart failure is initially unknown (Baldasseroni et al., 2002) and it has been estimated that myocarditis or inflammation of the heart muscle, may account for some 9% of these cases (Felker et al., 2000). Although estimates vary, these figures indicate that hundreds of thousands of Americans and millions of patients worldwide with heart failure may have myocarditis as a primary or exacerbating cause. The true incidence of myocarditis from any cause among the general population is unknown and most patients do not develop clinical manifestations of heart failure (Olinde & O'Connell, 1994). However, the Myocarditis Treatment Trial in which endomyocardial biopsy was performed in over 2,200 patients with unexplained heart failure of less than two years duration indicated a prevalence of 10%, implicating myocarditis as a potential cause of heart failure in hundreds of thousands of patients (Mason et al., 1995). Since only around 5% of patients systemically infected with a cardiotropic virus (Coxsackie  $\beta$ ) may develop cardiac involvement, it is important to determine what factors may increase the risk of cardiac involvement (Grist & Bell, 1969; Gerzen et al., 1972; Rodeheffer & Gersh, 1996).

### **1.3 Catecholamines exacerbate myocarditis**

Evidence from several different sources indicates that catecholamines may exacerbate viral myocarditis in animals and patients. A variety of sympathomimetic agents have been reported to induce or exacerbate myocarditis (Table 2). It is also important to note that nicotine has

been shown to increase catecholamine levels in the blood (Wong et al, 2007). The most direct evidence arises from carefully controlled studies of murine myocarditis indicating that hypercatecholaminergic states, secondary to pheochromocytoma and during infusion with sympathomimetic drugs, can cause or significantly exacerbate myocarditis (Cho et al., 1987; Van Vliet et al., 1966; Bindoli et al., 1992; Kammermeier & Grobecker, 1995; Davila et al., 1995; Prichard et al., 1991; Brown & O'Connell, 1995; Siltanen et al., 1982; Haft, 1974; Noda, 1970; Morin & Cote, 1972; Seta et al., 1997; Nash & Carter, 1967; Karch, 1987; Krentz et al., 2001; Rezkalla et al., 1988). Reports of a prospective study by Karch (Karch, 1987) showed significantly elevated levels of epinephrine and norepinephrine in a group of patients who presented with cardiac symptoms immediately after using cocaine. Moreover, sympatholytic agents and states may ameliorate the manifestations of myocarditis and decrease mortality, although this effect is controversial (Rezkalla et al., 1988; Anandasabapathy & Frishman, 1998; Mehes et al., 1966; Dunn & Vickers, 1994). We have shown a beneficial effect of beta blockade, ameliorating cocaine and catecholamine exacerbation of myocarditis in a murine model (Wang et al., 2005). It is provocative to consider that many of the interventions shown to ameliorate viral myocarditic pathogenicity, including calcium channel blockers, act predominantly to attenuate sympathomimetic effects on the heart (Dong et al., 1992; Hiraoka et al., 1996; Lowenstein et al., 1996; Wang et al., 1997; Keaney et al., 1996). Additional evidence includes the observation that, among commonly abused substances in the general population (alcohol, nicotine, caffeine, marijuana, and cocaine), cocaine has been most strongly associated with an increased incidence of myocarditis, suggesting that its unique sympathomimetic properties, not shared with these other agents, may be the causative factor. Moreover, in the clinical area, it has been accepted clinical practice for many years to restrict the activities of patients with myocarditis, primarily based on animal studies and circumstantial clinical evidence in man that exercise exacerbates the disease (Abelmann, 1966; Cabinian et al., 1990; Gatmaitan et al., 1970; Friman et al., 1983; Kiel et al., 1989; Tilles et al., 1964; Elson & Abelmann, 1965; Hosenpud et al., 1987). In addition to directly increasing the work of the heart, normal exercise is associated with a marked increase in circulating catecholamine levels (Cabinian et al., 1990; Gatmaitan et al., 1970; Friman et al., 1983; Kiel et al., 1989). While the cardiac effects of sympathomimetic drugs and interventions using sympatholytic agents require additional testing in animal models of myocarditis and in man, the available evidence points to catecholaminergic effects in the development of myocarditis.

#### **1.4 Adrenergic activation by cigarette smoke**

It has been estimated that there are over 4,000 chemical constituents in cigarette smoke. Of these, about 400 have been measured or estimated in mainstream or sidestream smoke; of the 400, a significant amount of toxicology data exists for less than 100 (Fowles & Bates, 2000). Nicotine is the most comprehensively studied constituent of cigarette smoke, and has been shown to act primarily on nicotinic acetylcholine receptors in autonomic ganglia and in the brain (Benowitz, 2008; Mobascher & Winterer, 2008). This results in activation of the sympathetic nervous system, increasing the release of epinephrine (EPI) and norepinephrine (NE) from adrenergic nerve endings and the adrenal medulla, both systemically and into the local milieu of adrenergically innervated organs, including the heart (Haass & Kübler, 1997; Adamopoulos, et al., 2008; Shinozaki et al., 2008). Cigarette smoke also contains monoamine oxidase inhibitors (Cooper & Magwere, 2008; Fowles & Bates, 2000; Herraiz et al., 2005). Cigarette smoke has been shown to increase norepinephrine and epinephrine levels with

## SYMPATHOMIMETIC AGENTS WITH THE POTENTIAL TO CAUSE MYOCARDITIS

<b>Catecholamines</b>	<b>(Wang et al, 2005)</b>
<b>Ephedrine</b>	<b>(Naik &amp; Freudemberger, 2004)</b>
<b>Cocaine</b>	<b>(Wang et al, 2002a)</b>
<b>Amphetamine</b>	<b>(Smith et al, 1976)</b>
<b>Terbutaline</b>	<b>(Sykes et al, 1991)</b>
<b>Clozapine</b>	<b>(Wang et al, 2008)</b>
<b>Methylxanthines</b>	<b>(Nino et al, 1987)</b>

Table 2. Sympathomimetic agents that may initiate or exacerbate myocarditis.

associated increases in heart rate, blood pressure and coronary vasoconstriction (Haass & Kübler, 1997, Adamopoulos et al., 2008, Shinozaki et al., 2008). Nicotine may also potentiate catecholamine actions, perhaps via effects on nitric oxide synthesis or release (Haass & Kübler, 1997). The adrenergic actions of nicotine can be attenuated or blocked by administration of beta-adrenergic antagonists, although it has been proposed that the drug may act by additional mechanisms to activate the beta-adrenergic pathway (Haas & Kübler, 1997; Sofuoglu et al., 2006; Marano et al., 1999, Wang et al., 2005).

## 2. Experimental evidence

### 2.1 Overview

Our previous studies indicated that catecholamines exacerbate the severity of viral myocarditis in a murine model (Soodini & Morgan, 2001; Wang & Morgan, 2003; Wang et al., 2002a, 2002b, 2005). We performed studies with a variety of agents known to enhance the adrenergic tone, all of which exacerbated myocarditis in our viral model; in contrast, treatment with propranolol ameliorated the severity of myocarditis. Tobacco smoke has also been demonstrated to increase adrenergic activation in animals and patients, in part due to its content of nicotine (Cavarra et al., 2001; Pomerleau, 1992; Su, 1982) which in turn may exacerbate the severity of viral myocarditis in a murine model through adrenergically mediated mechanisms (Bae et al., 2010). As a more generalized hypothesis, exposure to tobacco smoke may be an important and as yet underappreciated cause of heart failure in patients receiving treatments with pro-inflammatory drugs (i.e. clozapine) or who are exposed to pathogens (i.e. viruses) or physical factors (i.e. radiotherapy) that can produce a level of myocarditis susceptible to exacerbation.

Sympathomimetic agents have the potential to produce toxic effects on the heart through a variety of mechanisms that are summarized in Figure 1. Note the overlap with mechanisms

attributed to tobacco smoke exposure in Table 1, most notably with regard to myocarditis, their effects on inflammation, immune function, and factors associated with cardiac and vascular dysfunction. Although multiple factors undoubtedly contribute to the exacerbation of myocarditis we have observed with tobacco smoke exposure, it is reasonable to propose that catecholamine-related effects play a central role.

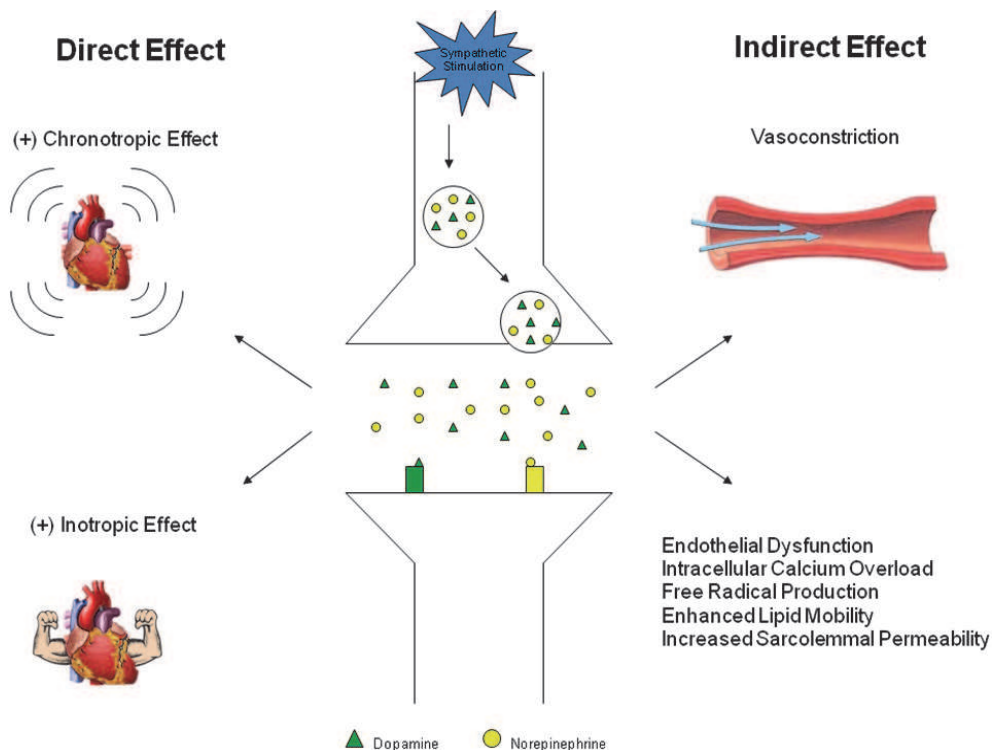


Fig. 1. Direct and indirect effects of catecholamines and related sympathomimetic agents on the heart.

## 2.2 Propranolol ameliorates and epinephrine exacerbates progression of acute and chronic viral myocarditis

Recent studies point to important interactions between proinflammatory cytokines and neurohumoral mediators in heart failure. We investigated the influence of the  $\beta$ -adrenergic system on cytokines and neurohumoral factors and the sequelae of viral myocarditis (Wang et al., 2005). In an experimental model with virus-infected BALB/c mice, we studied the acute and chronic effects of epinephrine and propranolol on myocardial morphology, cytokine gene expression, and survival. BALB/c mice were inoculated with the encephalomyocarditis virus (EMCV) or sham inoculated with saline and followed for 30 days. Epinephrine increased the severity of inflammatory cell infiltration and myocardial necrosis induced by EMCV-inoculated mice. Survival rate after 30 days was reduced to 40% in epinephrine-treated EMCV-inoculated mice compared with 70% in untreated EMCV-inoculated mice ( $P < 0.05$ ). Treatment with the  $\beta$ -blocker propranolol significantly decreased

mortality, myocardial necrosis and infiltration of inflammatory cells in EMCV-inoculated mice. Propranolol also suppressed gene expression of the cytokines TNF- $\alpha$ , IL-6 and IL-10 involved in inflammation. A single dose of epinephrine 120 days after EMCV inoculation caused death in 70% of infected mice; propranolol significantly reduced the incidence of death to 33%. These results indicate that acute and chronic stages of viral myocarditis are modulated by the  $\beta$ -adrenergic system and its interactions with proinflammatory factors.

### **2.3 Cocaine enhances myocarditis induced by encephalomyocarditis virus in murine models**

This study (Wang et al., 2002a) was designed to investigate whether cocaine can exacerbate viral myocarditis and increase its incidence. Clinical evidence suggests that cocaine abuse increases the incidence of myocarditis. However, it had not been directly demonstrated that cocaine exposure enhances murine myocarditis. BALB/c mice were divided into eight groups saline control, encephalomyocarditis virus (EMCV), 10 mg/kg cocaine (Coc-10), 30 mg/kg cocaine (Coc-30), 50 mg/kg cocaine (Coc-30), EMCV+Coc-50. After inoculation with EMCV, the mice were daily treated with either cocaine or saline for 90 days. Mice were euthanized at different days after EMCV inoculation. Mortality was recorded and myocarditis severity was evaluated. The mortality of the myocarditis mice treated with cocaine increased significantly from 22% (EMCV) to 25.7% (Coc-10+EMCV), 41.4% (Coc-30+EMCV) and 51.4% (Coc-50+EMCV) ( $P < 0.05$ ) respectively. The incidence and severity of inflammatory cell infiltration and myocardial lesions was higher in infected mice exposed to cocaine. Cocaine administered only before infection did not exacerbate myocarditis. Norepinephrine assay showed that cocaine exposure significantly increased myocardial norepinephrine concentration, but this increase was partially inhibited in infected animals. Adrenalectomy abolished the effect of cocaine on mortality. Furthermore, propranolol, a  $\beta$ -blocker, significantly decreased the enhancing effects of cocaine on myocarditis mice. In conclusion, cocaine increases the severity and mortality of viral myocarditis in mice. Increased catecholamines may be a major factor in this effect.

A variety of viruses have been reported as causative agents of myocarditis in man, including Coxsackie, echo and influenza viruses, cytomegalovirus, poliomyelitis virus, Epstein Barr virus, herpes simplex virus, adenovirus and several others (Rodeheffer & Gersh, 2001; Ensley et al., 1995; Abelmann, 1966). Our laboratory has demonstrated that cocaine can exacerbate viral myocarditis in a murine model (Wang et al., 2002a). Possible mechanisms of such an interaction include, (a) cocaine-induced damage to the endothelial/endocardial cells in the extracellular matrix or to the myocytes themselves, thereby reducing structural and immunological barriers to cellular penetration of the virus and increasing the myocardial and vascular permeability and infectivity of viral particles. Evidence supporting "possibility (a)" includes reports suggesting that cocaine can damage the endothelial lining of cells after even a single exposure, thereby accelerating atherosclerosis in animal models (Egashira et al., 1991; Bacharach et al., 1992). Cocaine has also been reported to increase natural killer cell activity (Van Dyke et al., 1986). Both lymphocytic and eosinophilic myocarditis have been reported in cocaine abusers (Virmani et al., 1988; Tazelaar et al., 1987) and heart failure is a common finding (Weiner et al., 1986; Duell, 1987). Alternatively, "possibility (b)", cocaine may exacerbate viral myocarditis by permitting enhanced viral replication of the viral agent once it has penetrated the cell membrane. Such an effect may occur through a direct or catecholamine-mediated alteration in the cellular milieu that in turn could alter viral transcription and replication. Enhanced viral replication could occur through a change in

cellular pH, shift in osmolarity, or likely depletion of high-energy stores necessary for protective proteolytic enzyme activity. Of course, it is likely that the effects of cocaine on the animal or a patient with myocarditis are complex and involve several mechanisms or conditioning factors, including drug diluents with intrinsic pharmacological activity or sensitizing effects (Ensing, 1985; Wolf and Blum, 1983). However, the observation that exacerbation of myocarditis seems to occur with cocaine but not other commonly abused drugs without prominent cardiac effects, including heroin and phencyclidine, suggests that cocaine may have a unique combination of properties that make its use in patients exposed or infected with viral pathogens likely to enhance development of myocarditis and its sequelae. Our data indicate that the unique ability of cocaine to increase local release and circulating levels of catecholamines is the primary factor responsible for exacerbation of myocarditis (Ensing, 1985).

#### **2.4 Clozapine-induced myocarditis: role of catecholamines in a murine model**

Clozapine, an atypical neuroleptic agent, is very effective in the treatment of resistant schizophrenia. However, cardiotoxicity of clozapine, particularly in young patients, has raised concerns about its safety and smoking may have a significant effect on serum concentrations of clozapine (Seppala et al., 1999). A particularly high incidence of myocarditis has been reported among patients treated with atypical neuroleptic drugs, including clozapine and risperidone. Clozapine has been shown to markedly increase circulating levels of catecholamines (Coulter et al., 2001; Elman et al., 2002). Increased catecholamines have been postulated to trigger an inflammatory response resulting in myocarditis, dilated cardiomyopathy, and death, although this has not yet been thoroughly studied. Here (Wang et al., 2008), we used the mouse to study whether clozapine administration could cause adverse myocarditis associated with an increase in catecholamines. Male BALB/c mice, age ~6 weeks, were administered 5, 10 or 25 mg/kg clozapine daily for 7 and 14 days; one group was administered 25 mg/kg clozapine plus 2 mg/kg propranolol for 14 days. Saline-treated mice served as controls. Heart sections were stained with hematoxylin and eosin for histopathological examination. Plasma catecholamines were measured with HPLC. Myocardial TNF- $\alpha$  concentrations were determined by ELISA. Histopathologic examination of clozapine-treated mice showed a significant dose-related increase in myocardial inflammation that correlated with plasma catecholamine levels and release of TNF- $\alpha$ . Propranolol significantly attenuated these effects. A hypercatecholaminergic state induced by clozapine could explain the occurrence of myocarditis in some patients. Our data suggest that  $\beta$ -adrenergic blocking agents may be effective in reducing the incidence and severity of clozapine-induced myocarditis.

### **3. Tobacco smoke**

#### **3.1 Exacerbation of viral myocarditis by tobacco smoke as a cause of heart failure**

In this study (Bae et al. 2010), we determined whether exposure to tobacco smoke will exacerbate the severity of viral myocarditis in mice. Viral myocarditis was generated in 4-week old male BALB/c mice by i.p. injection of encephalomyocarditis virus (EMCV). Mice were exposed to cigarette smoke for 90 minutes/day 5x/week. Four groups were studied: 1) Control (C, no smoke and no virus), 2) Smoke (S) only, and 3) Virus only (V), and 4) Pre-exposure to smoke for 1 week prior to virus injection (S+V). We observed an over 2-fold

increase in mortality among mice that were pre-exposed to smoke compared to the virus alone. Tobacco smoke alone did not affect mortality. There was a significant increase in virus load among hearts from mice exposed to S+V compared to V alone.

In this study, we also investigated the rate of apoptosis 5 days after i.p. injection of virus. Viral exposure alone significantly increased the number of apoptotic cells. The number of apoptotic cells was increased further by smoke exposure prior to viral injection. Viral injection increased the translocation of apoptosis-inducing factor from mitochondria, a hallmark of caspase-independent apoptosis activation. Exposure to tobacco smoke exacerbated these effects without changing the total expression of apoptosis-inducing factor suggesting activation of caspase-independent apoptotic pathways as well.

Apoptosis has been shown to play an important role in human and animal heart failure (Kang et al., 2000; Kang & Izumo, 2003). Other investigators have demonstrated EMCV-induced apoptosis in the hearts of mice and pigs (for example, see Mizutani et al., 1996 and Brewer et al., 2001). Activation of caspases may be a critical facilitator of viral infection in cardiomyocytes (DeBiasi et al., 2004, Kyoto et al., 2004). In fact, DeBiasi et al., have shown that inhibition of caspases effectively blocks virus-induced apoptosis *in vitro*, although caspase-independent factors also appeared to be involved. Apoptosis-inducing factor release from mitochondria is one important caspase-independent factor, and appears to play an important role in EMCV-infection related apoptosis, as shown in our study. These data were later to show that viral infection induced a significant increase in apoptosis, through caspase-independent apoptosis, and that preexposure to tobacco smoke exacerbated this effect.

Several studies have shown a relationship between myocyte apoptosis and increased sympathetic activity in patients with underlying heart disease, most commonly heart failure (Singh et al., 2001). Communal et al., 1998 showed that over-stimulation by norepinephrine produced apoptosis in ventricular myocytes of adult rats and blocking the beta-receptor decreased apoptosis. These data are consistent with our hypotheses that catecholamines are a major factor inducing inflammation and cell death in tobacco smoke exposed animals.

#### 4. Conclusions

Evidence from our laboratory and elsewhere (summarized above) indicates that both mainstream and secondhand tobacco smoke exposure can exacerbate viral myocarditis. Induction of a systemic inflammatory response appears to be a central initiating mechanism responsible for myocarditis, an effect that can be mediated by a cardiotropic viral infection itself and exacerbated by additional factors, most notably, catecholamines and other sympathomimetic agents, (Figure 2).

There appears to be an additive or synergistic effect of factors producing inflammation, which in turn can enhance viral load in the myocytes and exacerbate the extent and severity of myocarditis. Severe cardiac dysfunction and clinical heart failure may result. Our data suggest that disruption of gap junctions plays an important role in this regard (Figure 1). Moreover, to the extent that catecholamines are responsible, beta-adrenergic antagonists can attenuate the effect. Although the results presented in this review are consistent with a primary pathogenic role of catecholamines in the exacerbation of myocarditis by tobacco smoke, they do not exclude other factors that may operate through different mechanisms.



Additional animal and human studies will be necessary to further elucidate the several factors that may be involved. However, taken together, the available data indicate that tobacco smoke can exacerbate myocarditis which in turn may result in irreversible cardiac dysfunction and failure. Even in the absence of additional data, these results provide another example of the adverse effects of tobacco smoke and strengthen the argument for minimizing exposure to this agent in our environment.

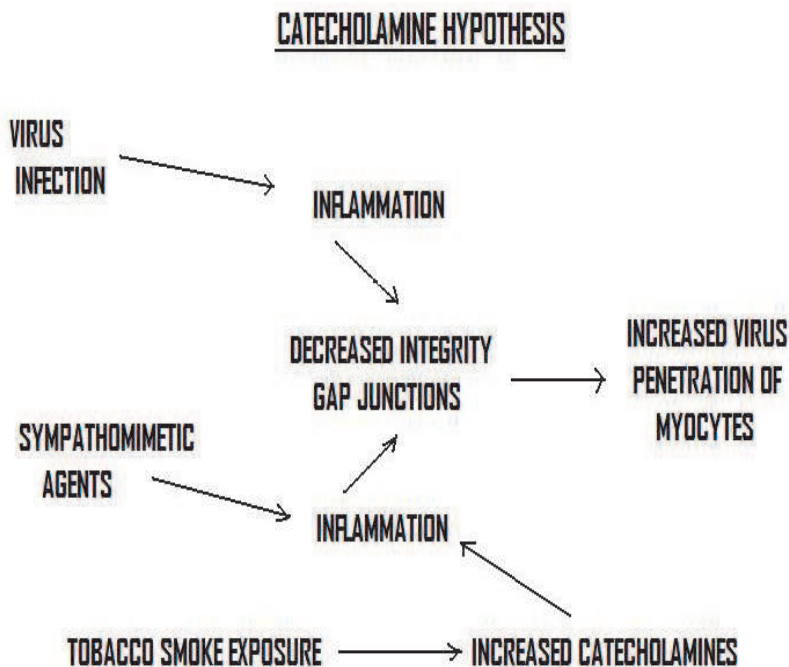


Fig. 2. Proposed primary mechanism for exacerbation of viral myocarditis by tobacco smoke exposure: the catecholamine hypothesis.

## 5. Acknowledgement

This manuscript is dedicated to the memory of Dr. Walter H. Abelmann (1921-2011) who made many contributions to our understanding of myocarditis in the laboratory and clinic. We acknowledge the generous support provided by the Flight Attendant Medical Research Institute (FAMRI) for tobacco smoke related studies in our laboratory. We also express our appreciation to Ms. Patricia Crilley for her expert assistance in manuscript preparation.

## 6. References

- Abelmann, W.H. Myocarditis. *N Engl J Med*, (1966), 275:944-945.
- Adamopoulos, D., van de Borne, P. & Argacha, J.F. New insights into the sympathetic, endothelial, and coronary effects of nicotine. *Clin Exp Pharmacol Physiol*, (2008), 35:458-63.

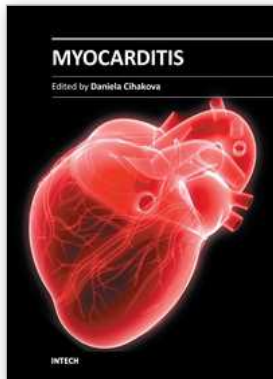
- Ambrose, J.A., & Barus, R.S. The pathophysiology of cigarette smoking and cardiovascular disease: an update. *J Am Coll Cardiol*, (2004), 43:1731-1737.
- Anandasabapathy, S., & Frishman, W.H. Innovative drug treatments for viral and autoimmune myocarditis. *J Clin Pharmacol*, (1998), 38:295-308.
- Bacharach, J.M., Colville, D.S., & Lie, J.T. Accelerated atherosclerosis, aneurismal disease, and aortitis possible pathogenetic association with cocaine abuse. *Int Angiol*, (1992), 11:83-86.
- Bae, S., Ke, Q., & Koh, Y.Y., et al. Exacerbation of acute viral myocarditis by tobacco smoke is associated with increased viral load and cardiac apoptosis. *Can J Physiol Pharmacol*, (2010), 88:568-575.
- Baldasseroni, S.A., Opasich, C. & Gorini M., et al.,. Left bundle-branch block is associated with increased 1-year sudden and total mortality rate in 5517 outpatients with congestive heart failure: a report from the Italian network on congestive heart failure. *Am Heart J*, (2002), 143:398-405.
- Barnoya J., & Glantz, S.A. Cardiovascular effects of secondhand smoke: nearly as large as smoking. *Circulation*, (2005), 111:2684-2698.
- Benowitz, N.L. Cigarette smoking and cardiovascular disease: pathophysiology and implications for treatment. *Prog Cardiovasc Dis*, (2003), 46:91-111.
- Benowitz, N.L. Pharmacology of nicotine: addiction, smoking-induced disease, and therapeutics. *Annu Rev Pharmacol Toxicol*, (2008), 49:57-71.
- Bindoli, A., Rigobello, M.P., & Deeb, D.J. Biochemical and toxicological properties of the oxidation products of catecholamines. *Free Radic Biol Med*, (1992), 13:391-405.
- Bleumink, G. S.; Knesch, A.M. & Sturkenbom, M.D., et al. Quantifying the heart failure epidemic: prevalence, incidence rate, lifetime risk and prognosis of heart failure in The Rotterdam Study. *Eur Heart J*, (2004), 25:1614-1619.
- Brewer, L.A., Lwamba, H.C., & Murtaugh, M.P., et al. Porcine encephalomyocarditis virus persists in pig myocardium and infects human myocardial cells. *J Virol*, (2001), 75(23), 11621-11629.
- Brown, C.A., & O'Connell, J.B. Myocarditis and idiopathic dilated cardiomyopathy. *Am J Med*, (1995), 99 : 309-314.
- Burns, D.M. Epidemiology of smoking-induced cardiovascular disease. *Prog Cardiovasc Dis*, (2003), 46 :11-29.
- Cabinian, A.E., Kiel, R., & Smith, F., et al. Modification of exercise-aggravated Coxsackie virus B3 murine myocarditis by T-lymphocyte suppression in an inbred model. *J Lab Clin Med*, (1990), 115, 454-462.
- Cavarra, E., Bartalesi, B. & Lucattelli, M., et al. Effects of cigarette smoke in mice with different levels of  $\alpha_1$  proteinase inhibitor and sensitivity to oxidants *Amer J Respir Crit Care Med*, (2001), 164:886-890.
- Cho, T., Tanimura, A., & Saito Y. Catecholamine-induced cardiopathy accompanied with pheochromocytoma. *Acta Pathol Jpn*, (1987), 37 :123-132.
- Communal, C., Singh, K., & Pimetel, D., et al. Norepinephrine stimulates apoptosis in adult rat ventricular myocytes by activation of the B-adrenergic pathway. *Circulation*, (1998), 98:1329-1334.
- Cooper, R.G. & Magwere, T. Nitric oxide-mediated pathogenesis during nicotine and alcohol consumption. *Indian J Physiol Pharmacol*, (2008), 52: 11-18.
- Coulter, D.M., Bare, A., & Meyboom, R.H.B., et al. Antipsychotic drugs and heart muscle disorder in international pharmacovigilance: data mining study. *BMJ*, (2001), 322:1207-1209.

- Davila, D.F., & Gottberg, C.F., & Torres, A., et al. Cardiac sympathetic-parasympathetic balance in rats with experimentally-induced acute chagasic myocarditis. *Rev Inst Med Trop Sao Paulo*, (1995), 37:155-159.
- DeBiasi, R.I., Robinson, B.A., & Sherry, B., et al. Caspase inhibition protects against reovirus-induced myocardial injury in vitro and in vivo. *J Virol*, (2004), 78:11040-11050.
- Dong, R., Liu, P., & Wee, L., et al. Verapamil ameliorates the clinical and pathological course of murine myocarditis. *J Clin Invest*, (1992), 90:2022-2030.
- Duell, F.B. Chronic cocaine abuse and dilated cardiomyopathy. *Am J Med*, (1987), 83:601 (Letter).
- Dunn, A.J., & Vickers, S.L. Neurochemical and neuroendocrine responses to Newcastle disease virus administration in mice. *Brain Res*, (1994), 645:103-112.
- Egashira, K., Pipers, F.S., & Morgan, J.P. Effects of cocaine on epicardial coronary artery reactivity in miniature swine after endothelial injury and high cholesterol feeding; In vivo and in vitro analysis. *J Clin Invest*, (1991), 88, 1307-1314.
- Elman, I., Goldstein, D.S., & Green, A.I., et al. Effects of risperidone on the peripheral noradrenergic system in patients with schizophrenia: a comparison with Clozapine and placebo. *Neuropsychopharmacology*, (2002), 27:293-300.
- Elson, S.H., & Abelmann, W.A. Effects of muscular activity upon the acute myocarditis of C3H mice infected with *Trypanosoma cruzi*. *Am H J*, 1965, 69:348-50.
- Ensing, J.G. Bazooka: cocaine-base and manganese carbonate. *J Anal Toxicol*, (1985), 9:45-46
- Ensley, R.D., Renlund, D.G., & Mason, J.W. Myocarditis. In: *Cardiovascular Medicine*, Edited by Willerson & Cohn, J.N., New York, NY, Churchill Livingstone, (1995), pp 894-923.
- Ezzati, M., Henley S.J., & Thun, M.J., et al. Role of smoking in global and regional cardiovascular mortality. *Circulation*, (2005), 112, 489-497.
- Felker, G.M., Thompson, R.E. & Hare, J.M., et al. Underlying causes and long-term survival in patients with initially unexplained cardiomyopathy. *N Engl J Med*, (2000), 342:1077-1084.
- Fowles, J.A., & Bates, M.A. The chemical constituents in cigarettes and cigarette smoke: priorities for harm reduction. *A report to the New Zealand Ministry of Health. Epidemiology and Toxicology Group, Kenepuru Science Center, Porirua, New Zealand*, (2000), pp 1-65.
- Friman, G., Larsson, E., & Rolf, C. Interaction between infection and exercise. *Annu Rev Physiol*, (1983), 45:139-53.
- Gatmaitan, B.G., Chason, J.L., & Lerner, A.M. Augmentation of the virulence of murine Coxsackie virus B-3 myocardiopathy by exercise. *J Exp Med*, (1970), 131:1121-1136.
- Gerzen, P., Branath, A., & Holmgren, B., et al. Acute myocarditis, a follow-up study. *Br Heart J*, (1972), 34:575-583.
- Grist, N.R. & Bell E.J. Coxsackie viruses and the heart. *Am Heart J*, (1969), 77:295-300.
- Haass, M., & Kübler, W. Nicotine and sympathetic neurotransmission. *Cardiovasc Drugs Ther*, (1997), 10: 657-665.
- Haft, J.L. Cardiovascular injury induced by sympathetic catecholamines. *Prog Cardiovas Dis*, (1974), 17:73-86.
- He, J., Ogden, L.G., & Bazzano, L.A., et al. Risk factors for congestive heart failure in US men and women, NHANES I epidemiologic follow-up study. *Arch Intern Med*, (2001), 161:996-1002.
- Herraiz, T., & Chaparro, C. Human monoamine oxidase is inhibited by tobacco smoke: beta-carboline alkaloids act as potent and reversible inhibitors. *Biochem Biophys Res Commun*, (2005), 326:378-386.
- Hiraoka, Y., Kishimoto, C., & Takada, H., et al. Nitric oxide and murine coxsackievirus B3 myocarditis: aggravation of myocarditis by inhibition of nitric oxide synthase. *J Am Coll Cardiol*, (1996), 28:1610-1615.

- Ho, K.K., Pinsky, J.L., & Kannel, W.B., et al. The epidemiology of heart failure: the Framingham study. *J Am Coll Cardiol*, (1993), 22:6A-13A.
- Hosenpud, J.D., Campbell, S.M., & Niles, N.R., et al. Exercise induced augmentation of cellular and humoral autoimmunity associated with increased cardiac dilation in experimental autoimmune myocarditis. *Cardiovas Res*, (1987), 21:217-22.
- Kammermeier, M., & Grobecker, H.F. Cardiotoxicity of catecholamines after application of L-DOPA in Wistar-Kyoto (WKY) and spontaneously hypertensive rats (SHR). *Hypertens Res*, (1995), 18 (Suppl 1):S165-168.
- Kang, P.M. & Izumo, S. Apoptosis in heart: basic mechanisms and implications in cardiovascular diseases. *Trends Mol Med*, (2003) 9:177-182.
- Kang, P.M., Haunstetter, A., & Aoki, H., et al. Morphological and molecular characterization of adult cardiomyocyte apoptosis during hypoxia and reoxygenation. *Circ Res*, (2000), 87: 118-125.
- Kannel, W.B., Ho K.K., & Thom, T. Changing epidemiological features of cardiac failure. *Br Heart J*, (1994), 72:S3-9.
- Karch, S.B. Serum catecholamines in cocaine intoxicated patients with cardiac symptoms. *Annals of Emer Med*, (1987), 16:481.
- Keaney, J.F., Hare, J.M., & Balligand, J.L., et al. Inhibition of nitric oxide synthase augments myocardial contractile responses to beta-adrenergic stimulation. *Am J Physiol*, (1996), 271:H2646-2652.
- Kiel, R.J., Smith, F.E., Khatib, R., et al. Coxsackie virus B3 myocarditis in C3HeJ mice: description of an inbred model of the effect of exercise on virulence. *Eur J Epidemiol*, (1989), 5:348-350.
- Krentz, A.J., Mikhail, S., & Cantrell, P., et al. Pseudopheochromocytoma syndrome associated with clozapine. *BMJ*, (2001), 322:1213.
- Kyotö, V., Saraste, A., & Saukko, P., et al. Apoptotic cardiomyocyte death in fatal myocarditis. *Am J Cardiol*, (2004), 94: 746-730.
- Law, M.R. & Wald, N.J. Environmental tobacco smoke and ischemic heart disease. *Prog. Cardiovasc Dis*, (2003), 46: 31-38.
- Leone, A., Giannini, D., & Bellotto, C., et al. Passive smoking and heart disease. *Curr Vasc Pharmacol*, (2004), 2:175-182.
- Lowenstein, C.J., Hill, S.L., & Lafonde-Walker, A., et al. Nitric oxide inhibits viral replication in murine myocarditis. *J Clin Invest*, (1996), 97:1837-1843.
- Mason, J.W., O'Connell, J.B. & Herskowitz, A., et al. A clinical trial of immunosuppressive therapy for myocarditis, *The Myocarditis Treatment Trial Investigators. N Engl J Med*, (1995), 333:269-265.
- Marano, G., Ramirez, A., & Mori, I., et al. Sympathectomy inhibits the vasoactive effects of nicotine in conscious rats. *Cardiovasc Res*, (1999), 42:201-205.
- Mehes, G., Rajkovits, K., & Papp, G. Effect of various types of sympatholytics on isoproterenol-induced myocardial lesions. *Acta Physiol Acad Sci Hung*, (1966), 29:75-85.
- Mizutani, M.; Hirasawa, K.; & Takeda, et al. Variation in serum creatinine phosphokinase activity as indicated in two-phase EMC-D virus induced myocarditis. *Exp Anim*, (1996), 45: 333-338.
- Mobascher, A. & Winterer, G. The molecular and cellular neurobiology of nicotine abuse in schizophrenia. *Pharmacopsychiatry*, (2008), 41 (Suppl 1): S51-59.
- Morin, Y., & Cote, G. Toxic agents and cardiomyopathies. *Cardiovasc Clinic*, 1972, 4:245-67.
- Naik, S.D., & Freudenberger, R.S. Ephedra-associated cardiomyopathy. *Ann Pharmacother*, (2004), 38, 400-3.

- Nash, C.B., & Carter, J.R. Hemorrhagic myocarditis and cardiovascular collapse induced by catecholamine infusion. *Arch Int Pharmacodyn Ther*, (1967), 166:172-180.
- Nino, A.F., Berman, M.M., & Gluck E.H., et al. Drug-induced left ventricular failure in patients with pulmonary disease. Endomyocardial biopsy demonstration of catecholamine myocarditis. *Chest*, (1987), 92:732-736.
- Noda, M., Kawano, O., & Uchida, O., et al. Myocarditis induced by sympathomimetic amines, 1. *Jpn Circ J*, (1970), 34 :7-12.
- Olinde, K.D., & O'Connell, J.B. Inflammatory heart disease: pathogenesis, clinical manifestations and treatment of myocarditis. *Annu Rev Med*, (1994), 45:481-490.
- Ong, M.K., & Glantz, S.A. Cardiovascular health and economic effects of smoke-free workplaces. *Am J Med*, (2004), 117:32-38.
- Panagiotakos, D.B., Pitsavos, C., & Chrysohoou, C., et al. Effect of exposure to secondhand smoke on markers of inflammation: the ATTICA study. *Am J Med*, (2004), 116:145-150.
- Pomerleau, O.F. Nicotine and the central nervous system: biobehavioral effects of cigarette smoking. *Am J Med*, (1992), 93:2s-7s.
- Prichard, B.N., Owens, C.W., & Smith, C.C., et al. Heart and catecholamines. *Acta Cardiol*, (1991), 46: 309-322.
- Puranik, R., & Celermajer, D.S. Smoking and endothelial function. *Prog Cardiovasc Dis*, (2003), 45:443-458.
- Repace, J. Flying the smoky skies: secondhand smoke exposure of flight attendants. *Tob Control*, (2004), 13:18-19.
- Rezkalla, S., Kloner, R.A., & Khatib, G., et al. Effect of metoprolol in acute coxsackievirus B3 murine myocarditis. *J Am Coll Cardiol*, (1988), 12:412-414.
- Rodeheffer, R.J., & Gersh, B.J. Cardiomyopathy and biopsy, A. Dilated cardiomyopathy and the myocarditides. In: *Mayo Clinic Practice of Cardiology*, Edited by Giuliani, E.R., Gersh, B.J., McGoon, M.D., Hayes, D.L. & Schaff, H.U., St. Louis, Mo, Mosby, (1996), pp. 636-671.
- Sargent, R.P., Shepard, R.M., & Glantz, S.A. Reduced incidence of admissions for myocardial infarction associated with public smoking ban: before and after study. *BMJ*, (2004), 328:977-980.
- Seppala, N.H., Leinonen, E.V.J., & Lehtonen, M.L., et al. Clozapine serum concentrations are lower in smoking than in non-smoking schizophrenic patients. *Therapeutic Drug Monitoring*, (1999), 85:244-246.
- Seta, Y., Kanda, T., & Yokoyama, T., et al. Effect of amrinone on murine viral myocarditis. *Res Commun Mol Pathol Pharmacol*, (1997), 95: 57-66.
- Shinozaki, N., Yuasa, T., & Takata, S. Cigarette smoking augments sympathetic nerve activity in patients with coronary heart disease. *Int Heart J*, (2008), 49:201-72.
- Siltanen, P., Penttila, O., & Merikallio, E., et al. Myocardial catecholamines and their biosynthetic enzymes in various human heart diseases. *Acta Med Scan (Suppl)*, (1982), 660:24-33.
- Singh, K., Xiao, L., & Remondino, A., et al. Adrenergic regulation of cardiac myocyte apoptosis. *J Cell Physiol*, (2001), 189: 257-265.
- Smith, H.J., Roche, A.H., & Janusch, M.M., et al. Cardiomyopathy associated with amphetamine administration. *Am Heart J*, (1976), 16:792-7.
- Sofuoglu, M., Mouratidis, M., & Yoo, S., et al. Adrenergic blocker carvedilol attenuates the cardiovascular and adverse effects of nicotine in abstinent smokers. *Behav Pharmacol*, (2006), 17:731-735.
- Soodini, G. & Morgan J.P. Can cocaine abuse exacerbate the cardiac toxicity of human immunodeficiency virus? *Clin Cardiol*, (2001), 24:177-181.
- Steenland, K. Passive smoking and the risk of heart disease. *JAMA*, (1992), 267:94-99.
- Su, C. Actions of nicotine and smoking on circulation. *Pharmacol Ther*, (1982), 17:129-141.

- Sykes, A.P., Lawson, N., & Finnegan, J.A., et al. Creatinine kinase activity in patients with brittle asthma treated with long term subcutaneous terbutaline. *Thorax*, (1991), 46:580-583.
- Talukder, M.A., Johnson, W.M., & Varadharaj, S., et al. Chronic cigarette smoking causes hypertension, increased oxidative stress, impaired NO bioavailability, endothelial dysfunction and cardiac remodeling in mice. *Am J Physiol Heart Circ Physiol*, (2011), 300:H388-96.
- Tazelaar, H.D., Karch, S.B., & Stephens, B.G., et al. Cocaine and the heart. *Human Path*, (1987), 18:195-199.
- Tilles, J.G., Elson, S.H., & Shaka, J.A., et al. Effects of exercise on coxsackie A9 myocarditis in adult mice. *Proc Soc Exp Bio Med*, (1964), 117:77-82.
- Van Dyke, G., Stesin, A., & Jones, R., et al. Cocaine increases natural killer cell activity. *J Clin Invest*, (1986), 77:1387-1390.
- Van Vliet, P.D., Burchel, H.B., & Titus, J.L. Focal myocarditis associated with pheochromocytoma. *N Engl J Med*, (1966), 274:1102-1108.
- Virmani, R., Robinowitz, M., & Smialek, J.E., et al. Cardiovascular effects of cocaine: an autopsy study of 40 patients. *Am Heart J*, (1988), 115:1068-1076.
- Wang, J.F. & Morgan, J.P. Cocaine-induced exacerbation of viral myocarditis. In: *Watson RR, ed. AIDS and Heart Disease*, New York: Marcel Dekker, Inc., (2003) pp 265-280.
- Wang, J.F., Min, J.Y., & Hampton, T.G., et al. Clozapine-induced myocarditis: role of catecholamines in a murine model. *Eur J Pharmacol*, (2008), 592:123-7.
- Wang, J.F., Zhang, J, & Min, J.Y., et al. Cocaine enhances myocarditis induced by encephalomyocarditis virus in murine model. *Am J Physiol Heart Circ Physiol*, (2002a), 282:H956-H963.
- Wang, J.F.; Yang, Y. & Wang G.K., et al. Embryonic stem cells attenuate viral myocarditis in a murine model. *Cell Transpl*, (2002b), 11:753-58.
- Wang, J.F., Meissner, A., & Malek, S., et al. Propranolol ameliorates and epinephrine exacerbates progression of acute and chronic viral myocarditis. *Am J Physiol Heart Circ Physiol*, (2005), 289: H1577-H1583.
- Wang, W.Z., Matsumori, A., & Yamada, T., et al. Beneficial effects of amlodipine in a murine model of congestive heart failure induced by viral myocarditis. A possible mechanism through inhibition of nitric oxide production. *Circulation*, (1997), 95:245-251.
- Weiner, R.S., Lockhart, J.T., & Schwartz, R.G. Dilated cardiomyopathy and cocaine abuse: report of two cases. *Am J Med*, (1986), 81:699-701.
- Whincup, P.H., Gilg, J.A., & Emberson, J.R., et al. Passive smoking and risk of coronary heart disease and stroke: prospective study with cotinine measurement. *BMJ*, (2004), 329: 200-205.
- Wolf, G.L., & Blum L. Cardiovascular toxicity and tissue proton tl response to manganese injection in the dog and rabbit. *AJR*, (1983), 141:193-197.
- Wong, H.P., Yu, L., & Lam, E.K., et al. Nicotine promotes colon tumor growth and angiogenesis through beta-adrenergic activation. *Toxicol Sci*, (2007), 97:279-87.
- Yang, Z., Knight, C.A., & Mamerow, M.M., et al. Prenatal environmental tobacco smoke exposure promotes adult atherogenesis and mitochondrial damage in apolipoprotein E -/- mice. *Circulation*, (2004), 110:3715-3720.



## **Myocarditis**

Edited by Dr. Daniela Cihakova

ISBN 978-953-307-289-0

Hard cover, 428 pages

**Publisher** InTech

**Published online** 19, October, 2011

**Published in print edition** October, 2011

Myocarditis, the inflammation of the heart muscle, could be in some cases serious and potentially fatal disease. This book is a comprehensive compilation of studies from leading international experts on various aspects of myocarditis. The first section of the book provides a clinical perspective on the disease. It contains comprehensive reviews of the causes of myocarditis, its classification, diagnosis, and treatment. It also includes reviews of Perimyocarditis; Chagas's™ chronic myocarditis, and myocarditis in HIV-positive patients. The second section of the book focuses on the pathogenesis of myocarditis, discussing pathways and mechanisms activated during viral infection and host immune response during myocarditis. The third, and final, section discusses new findings in the pathogenesis that may lead to new directions for clinical diagnosis, including use of new biomarkers, and new treatments of myocarditis.

### **How to reference**

In order to correctly reference this scholarly work, feel free to copy and paste the following:

Nicolas Hanabergh and James P. Morgan (2011). Exacerbation of Viral Myocarditis by Tobacco Smoke: The Catecholamine Hypothesis, Myocarditis, Dr. Daniela Cihakova (Ed.), ISBN: 978-953-307-289-0, InTech, Available from: <http://www.intechopen.com/books/myocarditis/exacerbation-of-viral-myocarditis-by-tobacco-smoke-the-catecholamine-hypothesis>

# **INTECH**

open science | open minds

### **InTech Europe**

University Campus STeP Ri  
Slavka Krautzeka 83/A  
51000 Rijeka, Croatia  
Phone: +385 (51) 770 447  
Fax: +385 (51) 686 166  
[www.intechopen.com](http://www.intechopen.com)

### **InTech China**

Unit 405, Office Block, Hotel Equatorial Shanghai  
No.65, Yan An Road (West), Shanghai, 200040, China  
中国上海市延安西路65号上海国际贵都大饭店办公楼405单元  
Phone: +86-21-62489820  
Fax: +86-21-62489821

© 2011 The Author(s). Licensee IntechOpen. This is an open access article distributed under the terms of the [Creative Commons Attribution 3.0 License](#), which permits unrestricted use, distribution, and reproduction in any medium, provided the original work is properly cited.