

## Perimyocarditis

Hesham R. Omar<sup>1</sup>, Hany Abdelmalak<sup>1</sup>, Engy Helal<sup>2</sup>,  
Yara Mikhaeil<sup>3</sup> and Ahmed Fathy<sup>4</sup>

<sup>1</sup>*Internal Medicine Department. Mercy Hospital and Medical Center, Chicago, Illinois,*

<sup>2</sup>*Emergency Department, Agouza Police Hospital, Cairo, Egypt*

<sup>3</sup>*Northwestern University, Feinberg School of Medicine.*

<sup>4</sup>*Cardiology Department. National Heart institute. Cairo, Egypt*

<sup>1,3</sup>USA

<sup>2,4</sup>Egypt

### 1. Introduction

Perimyocarditis is an acute inflammation of the pericardium and the underlying myocardium resulting in myocellular damage. It can simply be considered as acute pericarditis with elevated cardiac biomarkers. The coexistence of acute myocarditis and pericarditis is not uncommon since both are commonly caused by cardiotropic viruses. The 2 terms “perimyocarditis” and “myopericarditis” are used to describe the disease. While perimyocarditis implies predominant myocardial involvement and myopericarditis implies predominant pericardial involvement, both terms are used interchangeably without specific reference to the type of cardiac involvement. There is a wide spectrum of clinical presentations reflecting the extent of myocardial involvement ranging from asymptomatic cases with spontaneous recovery, to mild cases where symptoms are masked by the existing illness, to more severe cases complicated with heart failure necessitating inotropic support or even cardiac transplantation. Due to detrimental complications of acute myocarditis including left ventricular dysfunction and ventricular arrhythmias the diagnosis of myocarditis is more important and should be thoroughly looked for. Monitoring of the cardiac biomarkers is therefore mandatory in every patient presenting with clinical picture and electrocardiographic (EKG) evidence of acute pericarditis to exclude an underlying myocarditis. Acute pericarditis can present with ST segment elevation which can sometimes be focal rather than diffuse. In this scenario, chest pain associated with focal ST segment elevation and elevated cardiac biomarkers (if myocarditis co-existed) can mimic transmural myocardial infarction. Differentiation between both entities is of utmost importance to avert the un-necessary utilization of thrombolytic therapy which can be deleterious in perimyocarditis or to avoid missing a more serious diagnosis of ST segment elevation myocardial infarction (STEMI). After hospital discharge, patients should be followed for several weeks to exclude the development of heart failure or subclinical left ventricular dysfunction.

### 2. Etiology

Similar to myocarditis, perimyocarditis is most commonly of viral aetiology and less likely due to bacterial infection. Viral etiologies are predominately due to the coxsackie B virus,

however, other viruses have been incriminated including cytomegalovirus [1], parvovirus B 19 [2], Epstein-Barr virus [3], Rubella [4], influenza A virus [5] and during hepatitis A virus infection [6]. The most famous bacterial pathogens associated with perimyocarditis are *Borrelia burgderferi* [7] and *Campylobacter jejuni* [8]. Others include *Mycoplasma pneumonia* [9], *Chlamydia pneumonia*, [10], *Brucella* [11], *Rickettsia Helvetica* [12], *Yersinia enterocolitica* [13], rickettsial Q fever [14], *Shigella boydii* [15], *Shigella sonnei* [16], tuberculosis [17], following Streptococcal tonsillitis [18] and Meningococcal septicemia[19]. The protozoan *Toxoplasma gondii* has also been described as a cause [20]. Immunizations have also been linked with perimyocarditis. The Smallpox vaccine has received great attention especially after its reinstatement for military personnel in 2002 and the report of 50 cases of perimyocarditis [21, 22]. There are several reported cases of perimyocarditis that developed hours after Diphtheria-Tetanus-acellular Pertussis (DTaP) vaccination [23, 24]. Perimyocarditis has also been linked to the administration of certain drugs including meselazine used in the treatment of inflammatory bowel disease [25]. Table 1 represents a compilation of reported etiologies of perimyocarditis.

Etiology of perimyocarditis	
Viral pathogens	Coxsackie B virus Cytomegalovirus Parvovirus B19 Epstein barr virus Rubella Influenza A virus Hepatitis A virus
Bacterial pathogens	<i>Borrelia burgderferi</i> <i>Campylobacter jejuni</i> <i>Mycoplasma pneumonia</i> <i>Chlamydia pneumonia</i> <i>Brucella</i> <i>Rickettsia Helvetica</i> <i>Yersinia enterocolitica</i> Rickettsial q fever <i>shigella boydii</i> <i>Shigella sonnei</i> Tuberculosis Following streptococcal tonsiliitis Following meningococcal septicemia
Protozoa	<i>Toxoplasma gondii</i>
Immunizations	Smallpox vaccine Diphtheria-tetanus-acellular pertussis (DTaP) vaccination tetanus vaccination alone
Immunologic/Connective tissue disease	Sarcoidosis Rheumatoid arthritis Systemic lupus erythematosus Acute rheumatic fever
Drug induced	Meselazine Methydolpa Sulphonamide Cocaine

Table 1. Causes of perimyocarditis.

### 3. Clinical picture

Perimyocarditis has a wide spectrum of presentation with some cases being asymptomatic, some suffering from symptoms of the preceding viral illness and some presenting with acute heart failure and cardiogenic shock as in cases with fulminant myocarditis. 60% of the cases have constitutional symptoms including fever, arthralgia, malaise and chills. In 35% of the cases, there is chest pain which is usually mild, persistent, stitching, worsens with deep inspiration or coughing and radiates specifically to the trapezius ridge. Chest pain can sometimes be severe raising the suspicion of myocardial infarction which is always in the differential. Patients may also present with palpitations, syncope, Stokes-Adams attacks or sudden death due to arrhythmias including ventricular tachycardia and variable degrees of conduction abnormalities. Careful history taking is mandatory with specific reference to the patient's age, underlying medical problems including diabetes mellitus, hypertension, dyslipidemia, smoking history, positive family history of coronary artery disease and cocaine abuse that can place the patient at risk for myocardial ischemia. Clinical examination may be irrelevant with non-specific features as fever and tachycardia being the only positive clinical findings. Other clues in examination include a pericardial friction rub, however, only a minority of patients have pericardial rub on exam which tends to be transient and variable [26, 27]. A study of a cohort of patients with acute pericarditis confirmed poor sensitivity of a pericardial friction rub, which was found in only 35% of the cases [26]. Signs of decompensated heart failure (e.g. S3 gallop, elevated jugular venous pressure, lower limb edema and pulmonary congestion) can be detected in patients with fulminant myocarditis.

### 4. Cardiac biomarkers and other laboratory tests

Laboratory investigations in perimyocarditis can reveal elevated white blood cell count (WBC), erythrocyte sedimentation rate (ESR), C-reactive protein (CRP) and Brain natriuretic peptide (BNP) levels. Cardiac biomarkers are also elevated due to myocarditis. The incidence of elevated cardiac troponin I in patients with viral or idiopathic acute pericarditis has been reported to be 32.2%; of these patients 23.7% had a troponin I level at admission higher than those seen in myocardial infarction [28]. Elevated cardiac biomarkers in pericardial disease are not unusual and further complicate the diagnosis, raising suspicion for alternative diagnoses including myocardial infarction [29]. A study by Machdo et. al. concluded that perimyocarditis has a higher cardiac mortality than pericarditis [30]. This illustrates the importance of checking cardiac markers in all patients presenting with pericarditis. Studies also showed that elevated troponin is more common than elevated CKMB [31, 32]. The sole increase in troponin without other cardiac markers might represent a mild degree of myocardial injury.

### 5. Electrocardiography

Because the pericardium is electrically inert, EKG changes found in patients with acute pericarditis are suggestive of an underlying myocardial involvement. The typical EKG evolution is seen in up to 60 % of cases of acute pericarditis [26]. EKG may reveal sinus tachycardia, diffuse ST segment elevation that is concave upwards involving any lead except aVR and V1. In pericarditis, T wave inversion occurs only after the elevated ST segment returns to baseline. ST-segment elevation associated with pericarditis should not

result in the reciprocal depressions in aVL that accompany inferior MI, although this may not apply in some cases of localized pericarditis [33]. The most specific EKG finding for acute pericarditis is PR segment depression (PR segment elevation in aVR) which is considered an early EKG marker in the evolution of acute pericarditis. PR segment depression is due to subepicardial atrial injury and is present in more than 60 % of the patients. Acute pericarditis causes characteristic EKG changes that typically evolve through 4 stages as demonstrated in table 2.

<b>Stage 1</b>	Occurs during the first few days of pericardial inflammation and may last up to 2 weeks	<ul style="list-style-type: none"> <li>- Widespread concave upward ST segment elevation except in leads aVR and V1</li> <li>- Ratio of ST segment elevation to the T-wave amplitude in lead V5 or V6 is <math>\geq 0.25</math></li> <li>- PR segment depression</li> <li>- Absence of reciprocal ST changes</li> </ul>
<b>Stage 2</b>	Occurs hours to days after initial symptoms and may last from days to several weeks	<ul style="list-style-type: none"> <li>- ST segment returns to baseline</li> <li>- In the early phase, the J point returns to baseline while T waves are still upright and in the late phase T waves becomes flattened or even inverted</li> </ul>
<b>Stage 3</b>	Begins between the second and third week and may continue for several weeks	<ul style="list-style-type: none"> <li>- Diffuse T wave inversion</li> </ul>
<b>Stage 4</b>	May last from days up to 3 months	<ul style="list-style-type: none"> <li>- Resolution of T wave inversion and EKG returns back to baseline.</li> <li>- Rarely T wave inversions may persist indefinitely (chronic pericarditis).</li> </ul>

Table 2. The 4 Electrocardiographic stages of acute pericarditis.

Nevertheless, perimyocarditis can present with focal instead of diffuse ST segment elevation mimicking transmural myocardial infarction. This, in addition to the presence of chest pain and elevated cardiac biomarkers can make the differentiation of increasing difficulty. This is important because fatal complications can occur if thrombolytic therapy is administered for a patient with acute pericarditis, or if a diagnosis of transmural myocardial infarction is missed. Omar et al. demonstrated a similar scenario where an EKG of a patient presenting with chest pain revealed focal ST segment elevation (figure 1) and the cardiac biomarkers were elevated mimicking STEMI. [34] Careful history taking, EKG interpretation and urgent echocardiogram favored the diagnosis of acute perimyocarditis.

Previous studies have reported the use of thrombolytic therapy for what was later determined to be acute pericarditis [35, 36]. The utilization of urgent coronary angiography is not uncommon in patients with acute perimyocarditis. Salisbury and colleagues described the frequency of urgent coronary angiography in 238 patients with a final diagnosis of acute pericarditis to be 16.8 % [37].

## 6. Echocardiography

Echocardiography looking for pericardial effusion and regional wall motion abnormalities is mandatory to help in making the diagnosis and excluding other serious differentials. Imazio

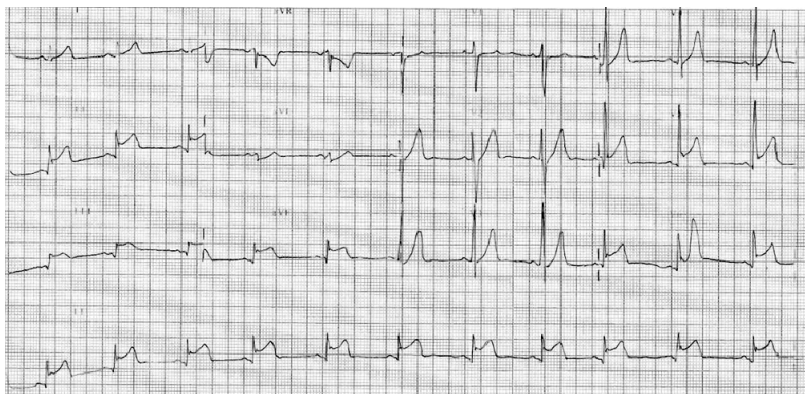


Fig. 1. Concave upward ST segment elevation in leads II, III, Avf, V5 and V6 in a patient with perimyocarditis. Notice the focal pattern of ST segment elevation (inferolateral leads) thereby mimicking transmural myocardial infarction. Adapted from Omar et. al. [34].

and colleagues found that pericardial effusions are present in approximately 60% of cases of acute pericarditis, with 80% being mild, 10% being moderate, and 10% being severe [26]. Pericardial effusion was present in 38.1% of patients in the ST segment elevation group and 73.5% of the patients in the non ST segment elevation and was explained by the tendency of the larger pericardial effusions to decrease voltage including the magnitude of ST segment elevation [26]. The presence of regional wall motion abnormalities favors an ischemic process rather than acute pericarditis. Another potential echocardiographic finding in perimyocarditis is transient myocardial thickening (figure 2 and 3) which is due to interstitial edema and its presence likely predicts a poor prognosis as it has been associated with a fulminant course [38]. In a series of 25 patients with acute myocarditis who underwent echocardiogram and endomyocardial biopsy, a significant decrease in myocardial thickness was observed between the acute and the convalescent phase. The reduction of the edema shown by the biopsy was also significant [39].

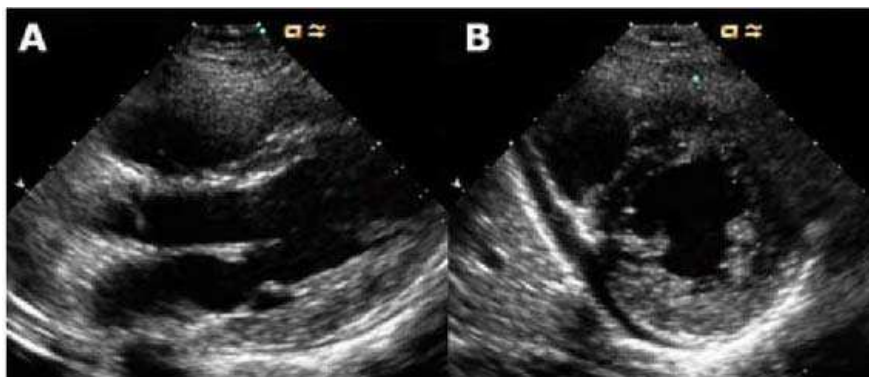


Fig. 2. Echocardiogram on admission. Parasternal long axis view (A) and short axis (B) in diastole. There is an asymmetrical thickening of the posterior wall involving the posterior papillary muscle, and slight pericardial effusion. Adapted from reference number 38 with permission.

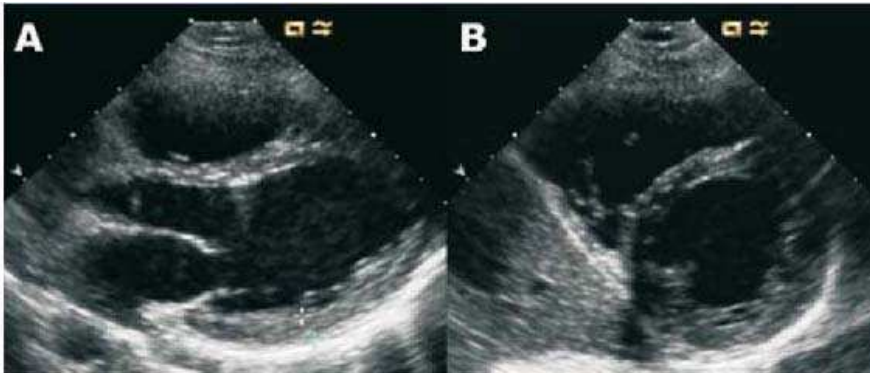


Fig. 3. Echocardiogram 5 days after admission. Parasternal long axis view (A) and short axis (B) in diastole. Normalization of the myocardial thickness in the posterior wall and posterior papillary and resolution of the pericardial effusion can be seen. Adapted from reference 38 with permission.

## 7. CT angiography

Another non-invasive diagnostic tool in patients presenting with chest pain, ST segment elevation and elevated cardiac biomarkers is the use of the 64-slice coronary CT angiography (CCTA) which is a reliable test that can be utilized in patients with low to intermediate pretest probability for coronary artery disease. Shturman et. al. used the 64-slice CCTA to rule out coronary artery disease in a case of perimyocarditis mimicking myocardial infarction [40]. This simple noninvasive test can avert the unnecessary need for coronary angiography or thrombolytic therapy for a presumed STEMI. Recently, Computed tomographic angiography (CTA) "triple rule out" protocol has been utilized in the emergency department for patients presenting with acute chest pain to differentiate between pulmonary embolism, aortic dissection and acute coronary syndrome. Compared with the usual radiation dose of a standard 64-slice CCTA, the effective radiation dose of a "triple rule-out" scan is often increased by 50% which should limit its unrestricted use. Takakuwa et. al. reported the successful use of the "triple rule-out" scan in diagnosing acute perimyocarditis (figure 4) and excluding other serious etiologies as acute coronary syndrome, aortic dissection and pulmonary embolism [41].

## 8. Cardiac magnetic resonance imaging

In perimyocarditis, gadolinium contrast MRI is useful to confirm the diagnosis by detecting an area of delayed contrast-enhancement, to evaluate the severity of inflammation in the acute stage as well as to determine the extent of fibrosis in the pericardium and myocardium [42]. The normal pericardium is observed as an area of low intensity on T1-weighted images and T2-weighted images [43]. In acute pericarditis, the inflamed pericardium is thickened and appears as an area of medium to high intensity with delayed contrast-enhancement recognized in the swollen pericardium which extends to the subepicardial myocardium affected by myocarditis [42]. The delayed enhancement in cardiac magnetic resonance (CMR) is explained by the leaking of the contrast media into the interstitial space due to

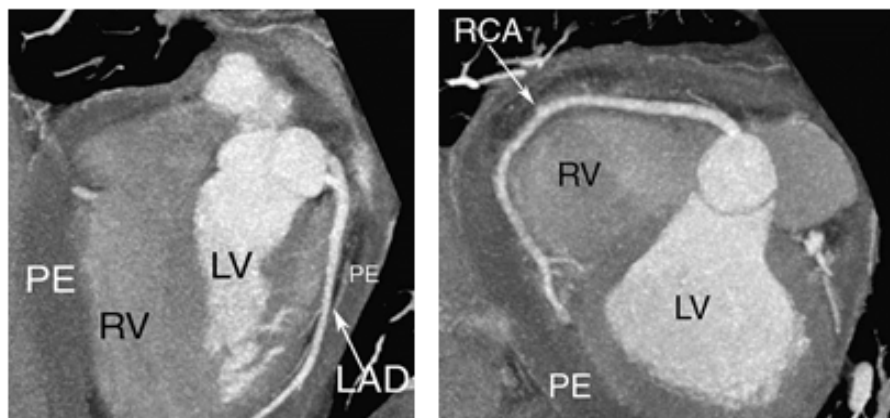


Fig. 4. Four chamber view (left). TRO study demonstrating mild-to-moderate pericardial effusion surrounding the heart. Left anterior oblique view (right) optimized to visualize the full length of the RCA. PE - pericardial effusion, RV - right ventricle, LV - left ventricle, LAD - left anterior descending coronary artery. Adapted with modification from reference number 41 with permission.

inflammation. As it stays out of the vessel, it cannot be washed away and is held for a longer time allowing it to be seen in the delayed enhancement images (figure 5) [44].

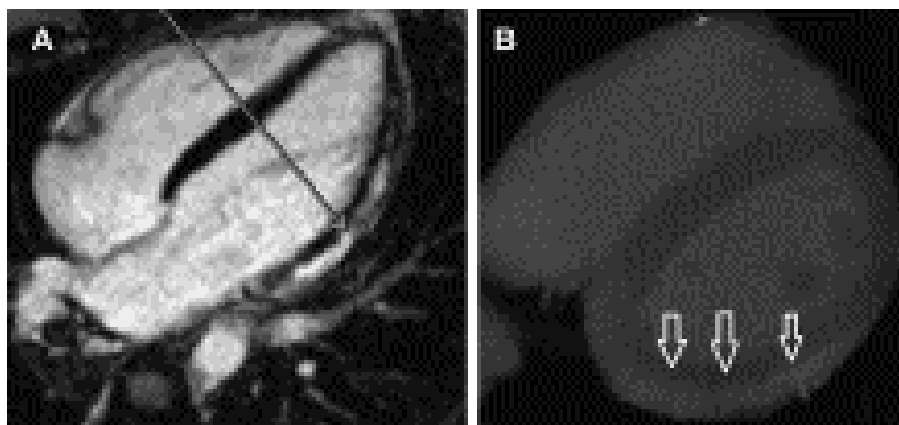


Fig. 5. Four chamber long-axis views. (A) Cardiac magnetic gadolinium delayed enhancement showing subepicardial hyperenhancement (arrow). (B) Cardiac CT delayed enhancement (arrows). Adapted from reference 44 with permission from Elsevier.

Cardiac magnetic resonance can also be a tool to differentiate between acute perimyocarditis and myocardial infarction. In acute myocarditis, myocardial late gadolinium enhancement is present in up to 88% of cases [45,46] which characteristically has patchy distribution not conforming to any particular coronary artery territory and is usually in the subepicardial and not the subendocardial layer [47] differentiating it from myocardial infarction.

## 9. Endomyocardial biopsy

Myocarditis may be focal or diffuse affecting any or all cardiac chambers. Although biopsy is the gold standard for the diagnosis, it is of limited utility especially in acute myocarditis, because of the patchy nature of active inflammation. In a series of over 2,000 patients with clinically suspected myocarditis, endomyocardial biopsy was only positive in 10% of the cases [48-50]. Given the potential risks of biopsy and the limited value it offers, its use should be limited to the patients with left ventricular dysfunction unresponsive to conventional therapy [51].

The various histologic patterns of myocarditis include either lymphocytic (including viral and autoimmune forms), eosinophilic (in which hypersensitivity myocarditis is the most common, followed by cases of hypereosinophilic syndrome), granulomatous (sarcoid and giant cell myocarditis), neutrophilic (bacterial, fungal, and early forms of viral myocarditis), and reperfusion type/contraction band necrosis (present in catecholamine-induced injury and reperfusion injury). Figure 6 represents the microscopic picture of acute perimyocarditis after diphtheria-tetanus vaccination.

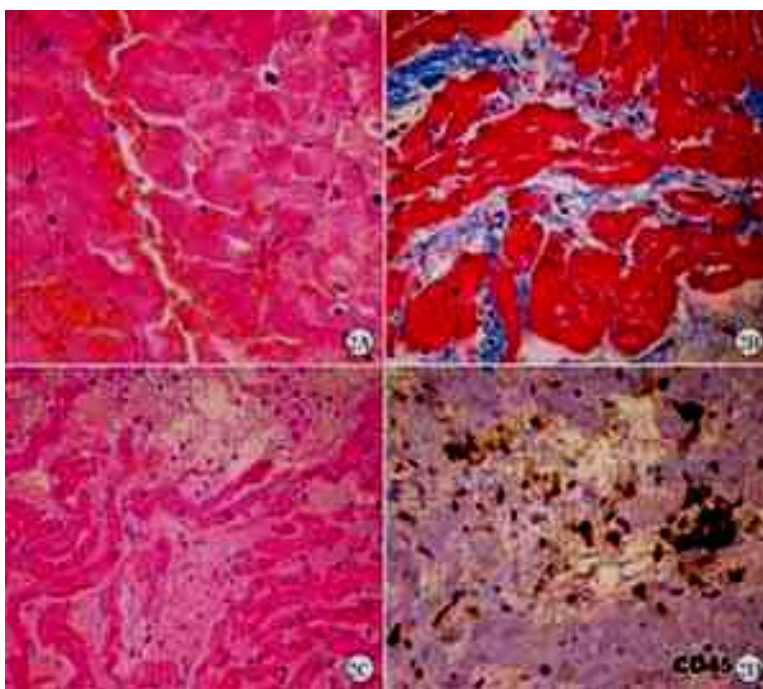


Fig. 6. Right ventricular endomyocardial biopsy. A . Haematoxylin-eosin, original magnification 200x: Diffuse interstitial oedema with scattered inflammatory cells. B. Immunohistochemical staining with anti-CD45 antibody, original magnification 400x: Lymphocyte inflammatory infiltrate associated with myocyte damage. C. Mallory triple stain, original magnification 200x: minimal interstitial fibrosis mixed with interstitial oedema. D. Haematoxylin-eosin, original magnification 200x: One focus of interstitial haemorrhage. Adapted from Journal of Chinese Clinical Medicine;2008,9;Vol.3, No.9. [24]



## 10. Management

As earlier described, perimyocarditis is a combination of both pericardial inflammation and myocardial damage. Treatment should therefore target both pathologies. Because myocarditis is a more serious diagnosis owing to the potential of serious ventricular arrhythmias and heart failure, the diagnosis of myocarditis is deemed more important. Acute pericarditis usually runs a smooth and benign course after empiric treatment with NSAID and routine hospitalization in most cases is not necessary. Perimyocarditis on the other hand has higher incidence of complications and is one of the indications for hospitalization. Checking the levels of cardiac biomarkers and echocardiography is therefore mandatory in any case of acute pericarditis. Imazio et. al. identified certain poor prognostic predictors that are more frequently associated with an increased risk of short term complications and therefore an indication for hospitalization [26]. Table 3 lists various indications for hospitalization of patients presenting with acute pericarditis

<b>Indications for Hospitalization of Patients with Acute Pericarditis</b>
1. Anticoagulation therapy
2. Body temperature greater than 100.4° F (38° C)
3. Echocardiographic findings of a large pericardial effusion
4. Findings of cardiac tamponade (i.e., hypotension and neck vein distention)
5. History of trauma and compromised immune system
6. Myopericarditis
7. Troponin I elevation

Table 3. Indications for Hospitalization of Patients with Acute Pericarditis. (adapted from reference 26)

There are certain scenarios when perimyocarditis present with focal EKG signs suggestive of STEMI. This can be challenging especially in developing countries where thrombolytic therapy is the mainstay of management of STEMI. In patients with acute pericarditis, thrombolytic therapy can be detrimental because of the risk of cardiac tamponade [52, 53]. Although the use of anticoagulants in patients with acute pericarditis is deemed unfavorable, in their study on 274 consecutive cases of idiopathic or viral acute pericarditis, Imazio and colleagues concluded that neither the use of heparin, anticoagulants nor glycoprotein IIb/IIIa inhibitors is associated with an increased risk of cardiac tamponade. [54] Risk factors for complications in that study included the lack of complete response to aspirin or NSAID (OR = 14.6, 95% CI 6.1 to 35.1; P = 0.001), or corticosteroid use (OR = 3.0, 95% CI 1.1 to 8.9; P = 0.048).

The mainstay of therapy for acute pericarditis is NSAID (class 1 recommendation in 2004 ESC guidelines). The goal of NSAID is to reduce pain and inflammation. Ibuprofen might be preferred because of its rare side effects, favorable impact on coronary artery blood flow and large dose range from 1200 to 1800 mg daily [55]. Aspirin can also be used in anti-inflammatory doses (up to 800 mg every 6 hours). Dose tapering is preferred to avoid recurrence. Gastric protection is mandatory and should be commenced in all patients. In perimyocarditis, NSAID should be used cautiously because in animal models they were shown to enhance the myocarditic process and may increase mortality [56-58]. Lower anti-inflammatory doses should therefore be considered whenever possible in perimyocarditis and its main use is to control symptoms. Failure to respond to NSAID within one week

(indicated by persistence of fever, new pericardial effusion, or continuing chest pain) indicates that a cause other than viral is responsible and should be searched for. Although colchicines can be used alone or in conjunction with NSAID in treatment and prevention of recurrent pericarditis, there is lack of data regarding its benefit in perimyocarditis [59].

The use of corticosteroids was found to be an independent risk factor for recurrence of acute pericarditis [60, 61] because of their ability to promote viral replication [62, 63]. Its use should therefore be restricted for those with autoimmune disease or in cases refractory to NSAID and colchicine and a specific cause has not been found. Despite the long list of pathogens, in most cases, a specific etiology for acute perimyocarditis can't be determined. In instances where an underlying treatable cause is confirmed, treatment of the target organism should be commenced. After hospital discharge, patient should be followed for several weeks to rule out the development of heart failure or subclinical left ventricular dysfunction. All patients should be advised to avoid strenuous exercise during the recovery phase (4-6 weeks) which can increase the risk of ventricular arrhythmias.

## 11. References

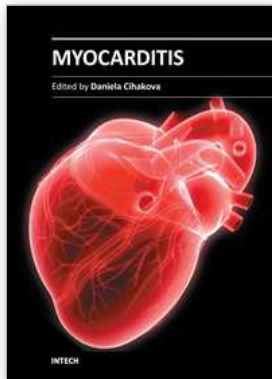
- [1] Maisch B, Schönian U, Crombach M, Wendl I, Bethge C, Herzum M, Klein HH: Cytomegalovirus-associated inflammatory heart muscle disease. *Scand J Infect Dis Suppl* 1993, 88:135-48.
- [2] Orth T, Herr W, Spahn T, Voigtländer T, Michel D, Mertens T, Mayet WJ, Dippold W, Meyer zum Büschenfelde KH: Human parvovirus B19 infection associated with severe acute perimyocarditis in a 34-year-old man. *Eur Heart J* 1997, 18(3):524-5.
- [3] Roubille F, Gahide G, Moore-Morris T, Granier M, Davy JM, Vernhet H, Piot C: Epstein Barr virus (EBV) and acute myopericarditis in an immunocompetent patient: first demonstrated case and discussion. *Intern Med* 2008, 47(7):627-9.
- [4] Harada T, Ohtaki E, Tobaru T, Kitahara K, Sumiyoshi T, Hosoda S: Rubella-associated perimyocarditis--a case report. *Angiology* 2002, 53(6):727-32.
- [5] Franzen D, Mertens T, Waidner T, Kruppenbächer J, Höpp HW, Hilger HH: Perimyocarditis in influenza A virus infection. *Klin Wochenschr* 1991, 69(9):404-8.
- [6] Bosson C, Lim DQ, Hadrami J, Chotard Y: Myopericarditis during hepatitis A. *Presse Med* 1996, 25(21):995-6.
- [7] Vasiljević Z, Vujisić B, Dmitrović R, Reljić B, Smiljanić J, Perunicic J, Nikitović S, Vukcević V, Stankov S: [Clinical picture of cardioborreliosis: from AV block to perimyocarditis. *Glas Srp Akad Nauka Med* 1993:213-8.
- [8] Turpie DF, Forbes KJ, Hannah A, Metcalfe MJ, McKenzie H, Small GR: Food-the way to a man's heart: A mini-case series of *Campylobacter* perimyocarditis. *Scand J Infect Dis* 2009, 24:1-4.
- [9] Pascual Velasco F, Rodríguez Pérez JC: Primary perimyocarditis caused by *Mycoplasma pneumoniae*. *An Med Interna* 1991, 8(7):360.
- [10] Gnarpe H, Gnarpe J, Gästrin B, Hallander H: Chlamydia pneumoniae and myocarditis. *Scand J Infect Dis Suppl* 1997, 104:50-2.
- [11] García de Lucas MD, Castillo Domínguez JC, Martínez González MS: [Brucella myopericarditis]. *Rev Esp Cardiol* 2004, 57(7):709.
- [12] Nilsson K, Lindquist O, Pålsson C: Association of *Rickettsia Helvetica* with chronic perimyocarditis in sudden cardiac death. *Lancet* 1999, 354(9185):1169-73.

- [13] Zöllner B, Sobottka I, Lippe G von der, Boyens M, Pokahr A, Grüter L, Laufs R: [Perimyocarditis caused by *Yersinia enterocolitica* serotype 0:3. *Dtsch Med Wochenschr* 1992, 117(47):1794-7.
- [14] Maisch B: Rickettsial perimyocarditis--a follow-up study. *Heart Vessels* 1986, 2(1):55-9.
- [15] Vieira NB, Rodriguez-Vera J, Grade MJ, Santos C: Traveler's myopericarditis. *Eur J Intern Med* 2008, 19(2):146-7.
- [16] Védrine L, Perez JP, Debien B, Petitjeans F, Bordier E, Pats B: Myopericarditis complicating severe *Shigella sonnei* infection. *Gastroenterol Clin Biol* 2003, 27(12):1176-7.
- [17] Roubille F, Gahide G, Granier M, Cornillet L, Vernhet-Kovacsik H, Moore-Morris T, Macia JC, Piot C: Likely tuberculous myocarditis mimicking an acute coronary syndrome. *Intern Med* 2008, 47(19):1699-701.
- [18] Putterman C, Caraco Y, Shalit M: Acute nonrheumatic perimyocarditis complicating streptococcal tonsillitis. *Cardiology* 1991, 78(2):156-60.
- [19] Sipilä R, Kiilavuori K: Meningococcus septicemia accompanied by perimyocarditis. *Duodecim* 1997, 113(17):1702.
- [20] Mroczek-Czernecka D, Rostoff P, Piwowska W: Acute toxoplasmic perimyocarditis in a 67-year-old HIV-negative woman, a case report. *Przegl Lek* 2006, 63(2):100-3.
- [21] Arness MK, Eckart RE, Love SS, Atwood JE, Wells TS, Engler RJ, Collins LC, Ludwig SL, Riddle JR, Grabenstein JD, Tornberg DN: Myopericarditis following smallpox vaccination. *Am J Epidemiol* 2004, 160(7):642-51.
- [22] Cassimatis DC, Atwood JE, Engler RM, Linz PE, Grabenstein JD, Vernalis MN: Smallpox vaccination and myopericarditis: a clinical review. *J Am Coll Cardiol* 2004, 43(9):1503-10.
- [23] Boccaro F, Benhaiem-Sigaux N, Cohen A. Acute myopericarditis after diphtheria, tetanus, and polio vaccination. *Chest*. 2001 Aug;120(2):671-2.
- [24] Taglieri N, Leone O, Ortolani P, Marzocchi A, Dallara G, Rosmini S, Baldazzi F, Rapezzi C, Branz. Acute myopericarditis after diphtheria-tetanus vaccination. *Journal of Chinese Clinical Medicine*;2008,9;Vol.3,No.9.
- [25] García-Morán S, Sáez-Royuela F, Pérez-Alvarez JC, Gento E, Téllez J: Myopericarditis and mitral insufficiency associated with ulcerative colitis treated with mesalazine. *Inflamm Bowel Dis* 2006, 12(4):334-5.
- [26] Imazio M, Demichelis B, Parrini I, et al. Day-hospital treatment of acute pericarditis: a management program for outpatient therapy. *J Am Coll Cardiol*. 2004;43(6):1042-1046.
- [27] Bonnefoy E, Godon P, Kirkorian G, Fatemi M, Chevalier P, Touboul P. Serum cardiac troponin I and ST-segment elevation in patients with acute pericarditis. *Eur Heart J*. 2000;21(10):832-836.
- [28] Imazio M, Demichelis B, Cecchi E, et al. Cardiac troponin I in acute pericarditis. *J Am Coll Cardiol*. 2003;42(12):2144-2148.
- [29] Smith KJ, Theal M, Mulji A .Pericarditis presenting and treated as an acute anteroseptal myocardial infarction. *Can J Cardiol*. 2001;17(7):815-817.
- [30] Machado S, Roubille F, Gahide G, Vernhet-Kovacsik H, Cornillet L, Cung TT, Sportouch-Dukhan C, Raczka F, Pasquié JL, Gervasoni R, Macia JC, Cransac F, Davy JM, Piot C, Leclercq F. Can troponin elevation predict worse prognosis in patients with acute pericarditis?

- [31] Smith SC, Ladenson JH, Mason JW, Jaffe AS. Elevations of cardiac troponin I associated with myocarditis. *Experimental and clinical Correlates. Circulation.* 1997 Jan 7;95(1):163-8.
- [32] Lauer B, Niederau C, Kühl U, Schannwell M, Pauschinger M, Strauer BE, Schultheiss HP. Cardiac troponin T in patients with clinically suspected myocarditis. *J Am Coll Cardiol.* 1997 Nov 1;30(5):1354-9.
- [33] Wang K, Asinger RW, Marriott HJ. ST-segment elevation in conditions other than acute myocardial infarction. *N Engl J Med.* 2003;349(22):2128-2135
- [34] Omar HR, Fathy A, Rashad R, Elghonemy M. Acute perimyocarditis mimicking transmural myocardial infarction. *Int Arch Med.* 2009 Dec 9;2(1):37.
- [35] Smith KJ, Theal M, Mulji A. Pericarditis presenting and treated as an acute anteroseptal myocardial infarction. *Can J Cardiol.* 2001;17(7):815-817.
- [36] Millaire A, de Groot P, Decouls E, Leroy O, Ducloux G. Outcome after thrombolytic therapy of nine cases of myopericarditis misdiagnosed as myocardial infarction. *Eur Heart J.* 1995;16(3):333-338.
- [37] Salisbury AC, Olalla-Gómez C, Rihal CS, Bell MR, Ting HH, Casaclang-Verzosa G, Oh JK. Frequency and predictors of urgent coronary angiography in patients with acute pericarditis. *Mayo Clin Proc.* 2009;84(1):11-5.
- [38] Fontenla Cerezuela A, Teijeiro Mestre R, Luaces Méndez M, Serrano Antolín JM. Transient myocardial thickening of the posterior wall in a patient with acute myopericarditis. *Rev Esp Cardiol.* 2010 Apr;63(4):497-8.
- [39] Hiramitsu S, Morimoto S, Kato S, Uemura A, Kubo N, Kimura K, et al. Transient ventricular wall thickening in acute myocarditis. A serial echocardiographic and histopathologic study. *Jpn Circ J.* 2001;65:863-6.
- [40] Shturman A, Chernihovski A, Goldfeld M, Furer A, Wishniak A, Roguin N. Usefulness of 64 multi-slice computed tomography in acute myopericarditis. *Isr Med Assoc J.* 2007 Apr;9(4):333-4.
- [41] Takakuwa KM, Ku BS, Halpern EJ. Myopericarditis diagnosed by a 64-slice coronary CT angiography "triple rule out" protocol. *Int J Emerg Med.* 2010 Aug 21;3(4):447-9.
- [42] Teraoka K, Hirano M, Yannbe M, Ohtaki Y, Ohkubo T, Abe K, Yamashina A. Delayed contrast enhancement in a patient with perimyocarditis on contrast-enhanced cardiac MRI: case report. *Int J Cardiovasc Imaging.* 2005 Apr-Jun;21(2-3):325-9.
- [43] Stark DD, Higgins CB, Lanzer P, et al. Magnetic resonance imaging of the pericardium: normal and pathologic findings. *Radiology* 1984; 150: 469-474
- [44] Ricardo Krieger Azzolini MDa, Fernando Arturo Effio Solis MDa, Paulo Cury Rezende MDa, Claudio Campi MD, PhDa, b, Henrique Lane Staniak MDa, Rodolfo Sharovsky MD, PhDa, Alexandre Volney Villa MD, Paulo Andrade Lotufo MD, PhDa and Márcio Sommer Bittencourt MDa Acute inferolateral ST-elevation myopericarditis diagnosed by delayed enhancement cardiac computed tomography. *Journal of Cardiology Cases.* Volume 3, Issue 2, April 2011, Pages e90-e93.
- [45] Mahrholdt H, Goedecke C, Wagner A, Meinhardt G, Athanasiadis A, Vogelsberg H, et al.: Cardiovascular magnetic resonance assessment of human myocarditis: a comparison to histology and molecular pathology. *Circulation* 2004, 109:1250-8.

- [46] Abdel-Aty H, Boye P, Zagrosek A, Wassmuth R, Kumar A, Messroghli D, et al.: Diagnostic performance of cardiovascular magnetic resonance in patients with suspected acute myocarditis: comparison of different approaches. *J Am Coll Cardiol* 2005, 45:1815-22.
- [47] Friedrich MG: Tissue characterization of acute myocardial infarction and myocarditis by cardiac magnetic resonance. *J Am Coll Cardiol Img* 2008, 1:652-62.
- [48] Aretz HT, Billingham ME, Edwards WD, et al. Myocarditis. A histopathologic definition and classification. *Am J Cardiovasc Pathol*. 1987;1:3-14
- [49] Davies MJ, Ward DE. How can myocarditis be diagnosed and should it be treated? *Br Heart J*. 1992;68:346-347
- [50] Mason JW, O'Connell JB, Herskowitz A, et al. A clinical trial of immunosuppressive therapy for myocarditis. The Myocarditis Treatment Trial Investigators. *N Engl J Med*. 1995;333:269-275
- [51] Cassimatis DC, Atwood JE, Engler RM, Linz PE, Grabenstein JD, Vernalis MN. Smallpox vaccination and myopericarditis: a clinical review. *J Am Coll Cardiol*. 2004 May 5;43(9):1503-10.
- [52] Blankenship JC, Almquist AK. Cardiovascular complications of thrombolytic therapy in patients with a mistaken diagnosis of acute myocardial infarction. *J Am Coll Cardiol*. 1989 Nov 15;14(6):1579-82.
- [53] Tilley WS, Harston WE. Inadvertent administration of streptokinase to patients with pericarditis. *Am J Med*. 1986 Sep;81(3):541-4.
- [54] Imazio M, Cecchi E, Demichelis B, Chinaglia A, Ierna S, Demarie D, Ghisio A, Pomari F, Belli R, Trincherio R. Myopericarditis versus viral or idiopathic acute pericarditis. *Heart*. 2008 Apr;94(4):498-501.
- [55] Maisch B, Seferović PM, Ristić AD, Erbel R, Rienmüller R, Adler Y, Tomkowski WZ, Thiene G, Yacoub MH; Task Force on the Diagnosis and Management of Pericardial Diseases of the European Society of Cardiology. Guidelines on the diagnosis and management of pericardial diseases executive summary; The Task force on the diagnosis and management of pericardial diseases of the European society of cardiology. *Eur Heart J*. 2004 Apr;25(7):587-610.
- [56] Costanzo-Nordin MR, Reap EA, O'Connell JB, et al. A nonsteroidal antiinflammatory drug exacerbates coxsackievirus B3 murine myocarditis. *J Am Coll Cardiol* 1985;6:1078-82.
- [57] Rezkalla S, Khatib G, Khatib R. Coxsackievirus B3 murine myocarditis. Deleterious effects of non-steroidal anti-inflammatory agents. *J Lab Clin Med* 1986;107:393-5.
- [58] Khatib R, Reyes MP, Smith F, et al. Enhancement of coxsackievirus B4 virulence by indomethacin. *J Lab Clin Med* 1990;116:116-20.
- [59] Imazio M, Trincherio R. Myopericarditis: Etiology, management, and prognosis. *Int J Cardiol*. 2008 Jun 23;127(1):17-26. Epub 2008 Jan 24.
- [60] Imazio M, Bobbio M, Cecchi E, Demarie D, Demichelis B, Pomari F, Moratti M, Gaschino G, Giammaria M, Ghisio A, Belli R, Trincherio R. Colchicine in addition to conventional therapy for acute pericarditis: results of the COLchicine for acute PERicarditis (COPE) trial. *Circulation*. 2005 Sep 27;112(13):2012-6.
- [61] Imazio M, Demichelis B, Parrini I, Cecchi E, Demarie D, Ghisio A, Belli R, Bobbio M, Trincherio R. Management, risk factors, and outcomes in recurrent pericarditis. *Am J Cardiol*. 2005 Sep 1;96(5):736-9.

- 
- [62] Soler-Soler J, Sagristà-Sauleda J, Permanyer-Miralda G. Relapsing pericarditis. *Heart*. 2004 Nov;90(11):1364-8.
- [63] Imazio M, Cecchi E, Demichelis B, Ierna S, Demarie D, Ghisio A, Pomari F, Coda L, Belli R, Trincherò R. . Indicators of poor prognosis of acute pericarditis. *Circulation*. 2007 May 29;115(21):2739-44.



## **Myocarditis**

Edited by Dr. Daniela Cihakova

ISBN 978-953-307-289-0

Hard cover, 428 pages

**Publisher** InTech

**Published online** 19, October, 2011

**Published in print edition** October, 2011

Myocarditis, the inflammation of the heart muscle, could be in some cases serious and potentially fatal disease. This book is a comprehensive compilation of studies from leading international experts on various aspects of myocarditis. The first section of the book provides a clinical perspective on the disease. It contains comprehensive reviews of the causes of myocarditis, its classification, diagnosis, and treatment. It also includes reviews of Perimyocarditis; Chagasâ€™ chronic myocarditis, and myocarditis in HIV-positive patients. The second section of the book focuses on the pathogenesis of myocarditis, discussing pathways and mechanisms activated during viral infection and host immune response during myocarditis. The third, and final, section discusses new findings in the pathogenesis that may lead to new directions for clinical diagnosis, including use of new biomarkers, and new treatments of myocarditis.

### **How to reference**

In order to correctly reference this scholarly work, feel free to copy and paste the following:

Hesham R. Omar, Hany Abdelmalak, Engy Helal and Ahmed Fathy (2011). Perimyocarditis, Myocarditis, Dr. Daniela Cihakova (Ed.), ISBN: 978-953-307-289-0, InTech, Available from:  
<http://www.intechopen.com/books/myocarditis/perimyocarditis>

**INTECH**  
open science | open minds

### **InTech Europe**

University Campus STeP Ri  
Slavka Krautzeka 83/A  
51000 Rijeka, Croatia  
Phone: +385 (51) 770 447  
Fax: +385 (51) 686 166  
[www.intechopen.com](http://www.intechopen.com)

### **InTech China**

Unit 405, Office Block, Hotel Equatorial Shanghai  
No.65, Yan An Road (West), Shanghai, 200040, China  
中国上海市延安西路65号上海国际贵都大饭店办公楼405单元  
Phone: +86-21-62489820  
Fax: +86-21-62489821

© 2011 The Author(s). Licensee IntechOpen. This is an open access article distributed under the terms of the [Creative Commons Attribution 3.0 License](#), which permits unrestricted use, distribution, and reproduction in any medium, provided the original work is properly cited.