

Hepatitis C Related Vasculitides

Reem H. A. Mohammed¹ and Hesham I El-Makhzangy²

¹*Department of Rheumatology and Rehabilitation,*

²*Department of Tropical Medicine, Faculty of Medicine, Cairo University Hospitals,
Egypt*

1. Introduction

Vasculitides comprise a heterogeneous group of autoimmune diseases sharing the common histopathologic feature of inflammation and fibrinoid necrosis of the blood vessel walls. Vasculitis features a wide variety of clinical manifestations depending on the localization and the size of the vessels involved, type of inflammatory infiltrate, and associated conditions making the diagnosis of specific forms of vasculitis difficult. The classification of the vasculitis remains a matter of controversy. Some classification systems have focused on the size of the vessels, while others have been based on histologic findings, yet an overlap of vessels of various sizes may occur, also the type of inflammatory infiltrate may change over time. Epidemiologic factors including; age, gender and ethnic background, patterns of organ affection, histopathologic and serologic features represent potential considerations while establishing the diagnosis and classification of vasculitis. The etiologic factors associated with the triggering of vascular endothelial injury and inflammations are quite variable with an unrecognized clear etiology in almost 50% of the cases. (Pipitone and Salvagni, 2006)

The interest in infection related vasculitides has been boosted for the last two decades by the development of new molecular techniques. Currently, a causal relationship between hepatitis C virus (HCV) and vasculitis has been established. (Falk and Hoffman, 2007) Chronic hepatitis C viremia has been known to provoke a plethora of autoimmune syndromes, as well as nonspecific rheumatologic manifestations referred to as extra-hepatic manifestations of HCV. Such extra-hepatic syndromes have been reported in as much as 40-90% of the chronic HCV infected patients, with a variable clinicopathological and serological spectrum that ranges between nonspecific serological abnormalities to manifest clinical disease with subsequent affection of multiple organs and systems. Established associations include; mixed cryoglobulinaemia (MC), complete or incomplete MC syndrome, porphyria cutanea tarda, significant associations include; autoimmune hepatitis, B cell non Hodgkin's lymphoma, monoclonal gammopathies, possible association include; chronic polyarthritis, sicca syndrome, lung fibrosis, polyarteritis nodosa, poly/dermatomyositis, thyroiditis/thyroid cancer, diabetes mellitus, lichen planus, mooren corneal ulcers. (Kattab et al., 2010, Mohammed et al., 2010)

2. Natural history and epidemiology of hepatitis C virus infection

Hepatitis C virus infection is a major worldwide public health problem. The estimated global worldwide reservoir is almost 200 million or 3% of the global population. Hepatitis C

virus is a retrovirus, member of the genus hepacivirus of the flaviviridae family enveloped with a 9.6 kb single-stranded RNA genome. Six different viral genotypes of HCV have been identified. The sero-prevalence of each of these genotypes varies according to geographic distribution; genotype 1 has a worldwide distribution, genotype 2 being more common in western Africa and genotype 3 in the northern Indian subcontinent, with a sero-prevalence rate of less than 1% in Western Europe and 2-3% in some Mediterranean areas. Regional geographic heterogeneity in the sero-prevalence rate can exist within the same country (in the USA, genotype 1 infection is significantly more prevalent in the northeastern, southeastern and middlewestern areas than in patients from the west and south). African-Americans are more likely to be infected with genotype 1 than Caucasians. Genotype 4 is predominant in the Middle East and Africa, genotype 4 is spreading in Western countries, especially among intravenous drug users. Genotype 5 is predominant in South Africa and genotype 6 in South-East Asia. Mixed cryoglobulinemia (MC), is considered the most highly associated and characteristic extrahepatic feature in HCV infection. (Mohammed et al., 2010) In HCV infected patients 30- 98% have cryoglobulinemia. Overt cryoglobulinaemic syndrome develops in 5-20% of patients. (Antonelli et al., 2009) The incidence of HCV infection in mixed cryoglobulinemia ranges from 40 to 90% and tests for viral genome concentrations in the cryoprecipitate might be as high as 1000 fold that of supernatant. (Ferri et al., 2002 a, Sansonno et al., 2007).

3. Mixed cryoglobulinemia

Mixed cryoglobulinemia (MC) is a chronic immune complex (IC) mediated systemic small vessel vasculitis, characterized by immune complex deposits (cryo-deposits) and frequent multiple organ involvement. A frequent synonym of this disease is "cryoglobulinemic vasculitis", a term that focuses on the typical histo-pathological alterations responsible for muco-cutaneous and visceral involvement. (Agnello, 1995) The term cryoglobulinemia refers to the presence of a single component (monoclonal) or more (polyclonal) immunoglobulins. These immunoglobulins typically precipitate at temperatures below 37°C giving rise to high molecular weight aggregates and re-dissolve on rewarming. Cryoglobulins are found in small quantities in normal serum and are present in variable concentrations in many pathological conditions, including myeloproliferative disorders, autoimmune disorders and several infectious diseases. They are classified on the basis of their Ig component into: Type I cryoglobulins (10-15% of cryoglobulins) is comprised simply of monoclonal immunoglobulins, typically IgM but less frequently IgG, IgA, or serum light chains. Individuals with Type I cryos typically have a paraproteinemia (e.g., myeloma, Waldenstrom's macroglobulinemia). Type II cryoglobulins (50-60% of cryoglobulins) occurs when a monoclonal Ig M recognizes and binds to polyclonal IgG's, accordingly, type II cryos are typically IgM-IgG complexes .Type III cryoglobulins (30-40% of cryoglobulins) are composed of polyclonal Ig M that binds to polyclonal IgG. Type II & III cryoglobulinemia are referred to as "Mixed Cryoglobulinemia", these are the types most commonly associated with hepatitis C. (Dammaco et al., 1997). The term essential cryoglobulinemia was used to describe cryoglobulinemia without identifiable underlying disease, currently it is clear that most of the patients with essential mixed cryoglobulinemia are chronically infected with HCV (Sansonno et al., 2007) **Table 1**

Cryoglobulins	Composition	Pathology	Clinical associations
Type I Cryoglobulins	Monoclonal Ig, (IgG, or IgM, or IgA) self-aggregation through Fc fragment of Ig	Histopathology of underlying disorder	Lympho-proliferative disorders: MM, WM, CLL, B-cell NHL
Type II MC	Monoclonal IgM (or IgG, or IgA) with RF activity (often cross-idiotypic WA-m RF) + Polyclonal Ig (mainly IgG)	-leukocytoclastic vasculitis. + - B lymphocyte expansion.	- Infections (mainly HCV, HBV, HIV) - Autoimmune/lympho-proliferative disorders. - Rarely, essential
Type III MC	Polyclonal mixed Ig (IgG, IgA, IgM) + RF activity of one polyclonal component (usually IgM)	-leukocytoclastic vasculitis. + -B-lymphocyte expansion with tissue infiltrates.	- Autoimmune disorders. - Infections (HCV, HBV, HIV) - Rarely 'essential'
Type II-III Variant of MC	Oligoclonal IgM RF or Mixture of poly/monoclonal IgM (often cross-idiotypic WA-mRF)	-leukocytoclastic vasculitis. + -B-lymphocyte expansion with tissue infiltrates	- Infections (mainly HCV) - Autoimmune/lympho-proliferative disorders - Rarely 'essential'

MM;multiple myeloma, WM; Waldenstrom macroglobulinemia, CLL; chronic lymphocytic leukemia, B-NHL; B cell Non-Hodgkin's Lymphoma

Table 1. Classification of Cryoglobulins. (Ferri, 2008)

3.1 Etio-pathogenesis of mixed cryoglobulinemia with HCV infection

Combined Viral and host-related factors contribute to the pathogenesis of HCV-related MC and lymphoproliferative disorder.

3.1.1 HCV infection of hepatocytes

The HCV life cycle starts with virion attachment to its specific receptor on hepatocytes. Several candidate molecules have been suggested to play a role in the receptor complex, including tetraspanin CD81, the scavenger receptor BI (SR-BI), the adhesion molecules DC-SIGN and L-SIGN, the low-density lipoprotein (LDL) receptor and recently, the tight junction components claudins (mainly CLDN-1, CLDN-6 and CLDN-9) have been identified as additional key factors for HCV infection. The HCV RNA genome serves as a template for viral replication and as a viral mRNA for viral production. In addition, the HCV enzymes- NS2-3 and NS3-4A proteases, NS3 helicase and NS5BRdRp—are essential for HCV replication, and are therefore potential future therapeutic targets. The activity of liver disease associated with cryoglobulinemic vasculitis is usually mild suggesting the existence of a state of immune tolerance between virus and host. At the same time the virus provokes a state of persistent high viremia necessary for circulating immune complex formation, essential for the activation of vasculitic inflammatory reaction. (Racanelli et al., 2001)

3.1.2 HCV and B lymphocytes

It is believed that HCV infects B lymphocytes (BL) in the same way it infects hepatocytes due to the shared expression of CD81 receptors. HCV induces lowering of lymphocyte activation threshold leading to chronic lymphocyte stimulation and widespread autoantibody production. (Ferri et al., 2000) The proposed etio-pathogenic mechanisms in HCV- mixed cryoglobulinemia, involves the following:

3.1.2.1-HCV-viral lymphotropism

The characteristic genome variability and viral lymphotropism of HCV cause prolonged and sustained antigen stimulation of B cell compartment, mainly exerted by E2 protein (highly variable region 1 HVR1) that allows distinguishing different, but strictly virus related genomic variants called quasispecies (Zignego and Brechot, 1999) and expresses B cell immunodominant epitopes involved in viral neutralization. Viral E2 region is able to directly interact with B-lymphocytes through tetraspanin CD 81 lowering the lymphocytes activation threshold (Pileri et al., 1998) with subsequent clonal expansion of the rheumatoid factor (RF) IgM/k producing lymphocytes (Agnello et al., 1992). The idiotypic similarities shared by mRFs from different patients with type II MC syndrome that correspond with a restricted set of rearranged immunoglobulin (Ig) genes that encode mRFs (IGHV1-69, IGHV3-23, and IGKV3-20 are associated with the WA CRI, IGHV3-7), suggesting that a specific antigen contributes to development of type II mixed cryoglobulinemia. Persistent and prolonged stimulation of B lymphocytes induces genetic modifications that play a key role in the evolution of lymphoproliferative disorders (LPD), passing from a physiologic polyclonal activation to a mono-oligo-clonal expansion characteristic of MC until the frank monoclonality of B cell lymphoma. In HCV related non-Hodgkin's Lymphomas malignant monoclonal B cells produce an Ig M with rheumatoid factor activity and highly homologous to anti-E2 antibodies. (De Vita et al., 2000)

3.1.2.2 Impaired apoptosis of B lymphocytes

HCV-dependent gene translocation leads to Bcl-2 recombination, activation of this anti-apoptotic protooncogene protects B lymphocyte from apoptosis triggering sustained B lymphocyte proliferation, autoantibody production, and oligoclonal monotypic lymphoproliferations with cells expressing oligo or monoclonal IgM sharing rheumatoid activity (mixed cryoglobulins). Recent studies highlighted the existence of an elevated frequency of proto-oncogene bcl-2 rearrangement [t(14;18) translocation] with altered bcl-2/bax ratio in subjects affected by chronic HCV infection. High levels of Bcl-2 protein expression have been detected in bone-marrow and liver infiltrates of HCV infected patients with cryoglobulinemia upon histopathological analysis. (Zignego et al., 2002, Giannini et al., 2008)

3.1.2.3 B- Lymphocyte somatic hypermutations (SHM)

Sequence analysis of rearranged Ig heavy chain genes within hepatic lymphoid infiltrates of patients with type II MC syndrome confirmed the presence of monoclonal or oligoclonal B-cell populations with sustained clonal somatic hypermutations (SHM) generating intra-clonal diversity in infiltrates. SHM enhances antibody affinity for a particular antigen by introducing nucleotide substitutions within the immunoglobulin variable (IgV) genes of germinal center (GC) B-cells. Genetic mutation arising from aberrant SHM has been proposed to contribute to B-cell NHL (e.g mutation in 5'-untranslated region of proto-

oncogenes like PIM-1, PAX-5, RhoH/TTF, and c-myc). The bcl-6 (B cell lymphoma-6) proto-oncogene is a transcriptional repressor gene that prevents the terminal differentiation of mature B cells to plasma cells and promotes proliferation of B lymphocytes. Bcl-6 is recently recognized as another target of SHM in GC B- cells in patients with HCV infection. In vitro studies suggest that genetic mutations in HCV infected cells arise from induction of error prone DNA polymerase activity by HCV infection. (De Vita et al., 2002, Machida et al., 2004)

3.1.3 Cytokines and soluble factors

Cytokines play a central role in the immune response to viral agents. Increased intrahepatic levels of interleukin (IL)-2, IL-6 and IL-8 were demonstrated by RT-PCR in cirrhotic patients. (Napoli et al., 1994) In vitro studies showed that HCV, through the action of its NS5A protein, induces expression of Toll like receptors 4 (TLR4), leading to enhanced IFN- β and IL-6 production and secretion. Members of the TNF-superfamily appear to play a relevant role in B cell expansion during chronic HCV infection. The two new members of the TNF-superfamily (B-lymphocyte stimulator-BLyS and APRIL- a proliferation inducing ligand) proved to play a crucial role in the control of humoral immunity. The binding of BLyS to its receptors (TACI and BLyS-R) induce strong B cells proliferation and extended survival via the strong activation of the antiapoptotic bcl-2 gene. Overexpression of BLyS in transgenic mice induced expansion and accumulation of mature B cells, high levels of serum IgG and IgM, and glomerulonephritis. BLyS, and its homologue APRIL, are now considered the main regulators of T-independent B-lymphocyte proliferation and autoimmunity. (Gross et al., 2000, Stein et al., 2002, Fabris et al., 2007, Sene et al., 2007)

3.1.4 HCV infection and T cell regulatory function (T reg)

The T-lymphocyte compartment was recently identified to acquire a distinct subset of lymphocytes with immune-regulatory properties named "regulatory T cells" (Treg). Treg. play a central role in modulating the immune response targeting infectious agents, in maintaining self-tolerance and lymphocyte homeostasis. (Sakaguchi, 2000) CD4+CD25+ T cells (T reg S) and "type 1 T regulatory cells" (Tr1) account for 5-10% of the CD4+ pool in normal subjects, they constitutively express CTLA-4 (CD152), and are anergic following in vitro TCR stimulation (partially reversed with high amounts of IL-2 and IL-15). The forkhead transcription factor Foxp3 is specifically expressed in CD4+CD25+ regulatory T cells and is required for their development and function. Several mutations within the Foxp3 gene alter CD4+CD25+ development, retroviral gene transfer of Foxp3 converts naive T cells toward a regulatory T cell phenotype similar to that of naturally occurring CD4+ regulatory T cells. "Type 1 T regulatory cells" (Tr1) are CD4+CD25-, which display a unique profile of cytokine production that is distinct from that of Th0, Th1 or Th2 cells and conversely to CD4+CD25+ they secrete high amounts of IL-10 and TGF-beta which in turn suppress naive and memory Th1 and Th2 responses, Such immune-dysregulation might contribute to chronic HCV viremia and cryoglobulin production. Patients with HCV-MC vasculitis were found to have a disturbed peripheral blood T cell repertoire, with a high frequency of T cell expansions. (Fontenot et al., 2003)

A role for C1q auto-antibodies has been reported in HCV infected patients. C1q receptor is overexpressed at sites of inflammation. C1q-R exacerbates inflammation by generating vasoactive peptides from the complement system and bradykinin from the contact system. HCV core protein interacts directly with the globular domain of C1q protein (gC1q-R).

Engagement of circulating HCV core protein with gC1q-R on the surface of B lymphocytes provides the virus with a direct means of affecting host immunity. Recently, there is also evidence of an important role of vascular cell adhesion molecule-1 (VCAM-1) a molecule exclusively involved in mononuclear cell recruitment, in the pathogenesis of severe forms of HCV-MC vasculitis. (Kittlesen et al., 2000, Kaplanski et al., 2005)

3.1.5 Paracrine/soluble factors

Other paracrine/soluble factors might be involved in the pathogenesis of HCV-related MC. The analysis of global protein pool (proteomic analysis) in sera and peripheral blood mononuclear cells (PBMC) samples represents a promising approach for identify new tumor markers, identification of post-translational modifications, protein-protein interactions, protein level expression, protein networks. (Leak et al., 2002) Figure 1

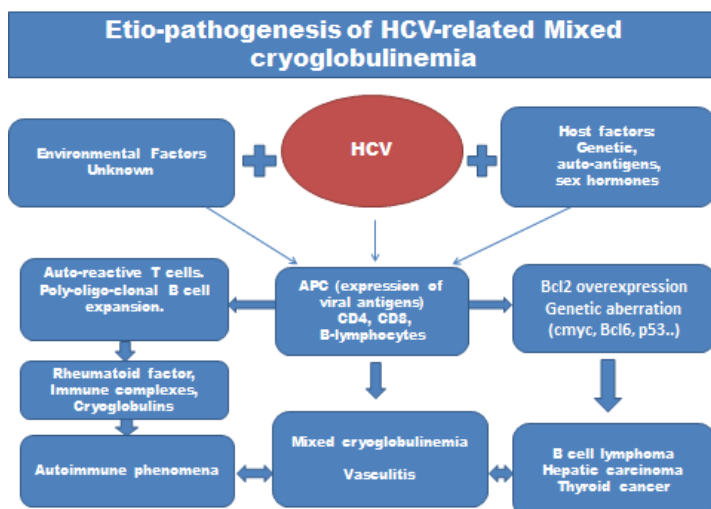


Fig. 1. Etiopathogenesis of HCV-Mixed Cryoglobulinemia

3.2 Mechanism of cryoglobulin production

The intrinsic mechanism by which HCV promotes cryoglobulin production remains unclear. It is postulated that upon initial antigenic stimulation, it is the interaction between HCV and lymphocytes that directly modulates B and T cell functions. Initial polyclonal activation and expansion of CD5 β cells (major source of IgM RF) occurs in type III mixed cryoglobulinemia. This is followed by the emergence of a single dominant clone of B lymphocytes with the production of monoclonal IgM RF. This clonal heterogeneity of IgM rheumatoid factor defines type II-type III variants which is considered a transitional stage in the switch between type III to type II MC. In HCV infection mixed cryoglobulins are predominantly type II cryoglobulins. (Sasso, 2000, Newkirk, 2002) Cryoglobulins interact with HCV forming immune complexes composed of HCV, anti-HCV polyclonal IgG and monoclonal IgM sharing Rheumatoid factor (RF) activity.

The presence of IgM RF in this megacomplex (cryoprecipitate complex) provides an obstacle to the incorporation of complement factor C3b into this complex. The incorporation of this C3b is

important as it allows binding of the immune complex to CR1 erythrocyte surface receptor required for immune complex neutralization. Thus this immune complex escapes neutralization by erythrocyte. HCV induces abnormalities in the biogenesis of lysosomal enzymes impairing the capacity of monocytes to digest engulfed immune complexes a phenomena described as “phagocyte blockade”. Failure of neutralization promotes the cryo-complex to circulate freely in an abundant form saturating the phagocyte ability to remove such immune complexes from the blood and creating a state of mixed cryoglobulinemia. This complex can easily deposit in tissues and promote inflammatory cascade. (Ferri et al., 2002 a, Sasso, 2000) The exact mechanisms leading to cryoprecipitation remain unclear. Different hypotheses have been proposed to explain this phenomenon, namely: (1) structural modification of the variable portions of Ig heavy (H) and light (L) chains; (2) a reduced concentration of sialic acid; (3) reduced amounts of galactose in the Fc portion of the IgG; and (4) the presence of N-linked glycosylation sites in the CH3 domain as a result of somatic Ig mutations during autoimmune responses. (5) Specific interactions between the IgM cryoprecipitable rheumatoid factor (RF) and the Fc portion of IgG, the corresponding autoantigen. (6) Occupancy of the Fc portion of IgG by IgM molecules is probably a major factor in the functional properties of immune complexes (ICs). They are large ICs known to be poor acceptors of C3 and C4, and deplete complement rather than fix it. Precipitation of these cryocomplex in the small blood vessels leads to cryoglobulinemic vasculitis. (Curry et al., 2003, Ferri, 2008, Saadoun et al., 2007)

3.3 Pathology in cryoglobulinemic vasculitis

The classic pathology in cryoglobulinemic vasculitis is leukocytoclastic vasculitis, a form of immune mediated small vessel vasculitis with immune complexes deposit in the walls of small blood vessels. This is associated with activation of the complement cascade and the production of C5a (a neutrophil polymorph chemotactant). The resultant polymorph influx is associated with release of lysosomal enzymes, including elastases and collagenases, resulting in blood vessel wall damage, fibrin deposition and the release of red blood cells into the perivenular connective tissue (palpable purpura). Thrombosis with epidermal ischemic damage is not uncommon. High levels of circulating immune complexes which correlated with vasculitic lesions can be detected. Immunoglobulins and complement were identified in vitro, by immunofluorescence or immune-peroxidase techniques, visualized ultra-structurally as clumps of electron-dense material, usually within the basement membrane between endothelial cells and pericytes of post-capillary venules. Examination of apparently uninvolved skin from patients with leukocytoclastic vasculitis sometimes shows immunoglobulin and complement within the walls of dermal blood vessels. The findings of immunofluorescence studies vary according to the age of the lesion. Immunoglobulins have been described in up to 81% of patients in early lesions, C3 and Ig M predominate, in fully developed lesions there is predominance of fibrinogen and Ig G and in late lesions fibrinogen and C3. (Stone, 2009)

4. Cryoglobulinemic vasculitis, the disease

HCV-related mixed cryoglobulinemia represents a form of small vessel vasculitis which manifests by a variety of autoimmune manifestations referred to as cryoglobulinemic syndrome. The cryoglobulinemic syndrome typically presents by Meltzer triad which is a

triad of purpura, weakness, arthralgia and/or arthritis, thereafter, a series of multisystem pathologies follow. Meltzer triad has been reported in 25-30% of patients with mixed cryoglobulinemia. Widespread vasculitis involving medium-small sized arteries, capillaries and venules with multiple organ involvement may develop in a small proportion of patients (Meltzer et al., 1996, Ferri et al., 2004, Ferri et al., 2006).

4.1 Frequency

4.1.1 United states

The prevalence of essential mixed cryoglobulinemia is reported as approximately 1:100,000. However, the exact prevalence of HCV related MC depends upon the geographic heterogeneity of HCV infection.

4.1.2 International

The prevalence of mixed cryoglobulinemia is related to the endemic presence and geographic heterogeneity of HCV infection. The disease is more common in Southern Europe than in Northern Europe or Northern America. The incidence of HCV infection in mixed cryoglobulinemia in the Mediterranean Basin is 90%. A growing incidence of HCV-related MC is observed especially in developing countries. HCV is endemic in some countries of the middleeast. Egypt has an exceptionally high prevalence of HCV infection estimated to be between 10% and 15% of its' 75 million population. The annual infection rate is more than 70, 000 new cases of which at least 35, 000 would have chronic hepatitis C, with viral genotype 4 the predominant genotype being isolated in up to 91% of HCV infected persons in Egypt. In a recent research conducted on 306 Egyptian patients with chronic HCV infection the prevalence of MC amongst other extrahepatic manifestation was 0.7%.

4.2 Predisposing factors

4.2.1 Race

Mixed cryoglobulinemia doesn't appear to have any specific racial predilection.

4.2.2 Age

Reported age range between 30-70 years (mean age reported 42-52 years).

4.2.3 Hormonal factors

The female-to-male ratio in mixed cryoglobulinemia is 3:1, female sex is considered one of the risk factors for developing extra-hepatic manifestations. Recent studies revealed an association between female gender and the presence of certain manifestations including fibromyalgia, cryoglobulinemic syndrome, autoimmune hemolytic anemia and arthritis. (Mohammed et al., 2010, Stefanova Petrova et al., 2007)

4.2.4 Genetic factors

HLA-B8 and DR3 may be considered risk factors for HCV-related MC in addition to cirrhosis. Recent data suggest that the HLA- phenotype B8 and DR3 are associated with increased risk of developing mixed cryoglobulinemia in HCV infected patients with the strongest association being with HLA-B8. Patients exhibiting the B8-DR3 phenotype may carry the C4A deletion, which might contribute to the low C4 levels measured in a proportion of MC patients in addition to complement consumption by the disease process

itself. Preliminary results on C4 allotyping in MC patients showed an increased frequency of C4AQ0 phenotype, thus suggesting a possible role of class III molecules in increasing the susceptibility to MC in HCV patients. (Ferri, 2008, Lenzi et al., 1998)

4.3 Criteria for the classification of mixed cryoglobulinemia

In 1989, the Italian group for the study of cryoglobulinemia has proposed preliminary criteria for the classification of MC. A revised version of these criteria including clinic-pathological and serological findings has been recently proposed, Criteria displayed in Table 2. (Ferri, 2008)

Criteria	Major	Minor
Serological	Mixed cryoglobulins Rheumatoid factor+ Low C4	Rheumatoid factor HCV + HBV +
Pathological	Leucocytoclastic vasculitis	Clonal B cell infiltrates (liver and/or bone marrow)
Clinical	Purpura	Chronic hepatitis Membrano-proliferative glomerulonephritis Peripheral neuropathy Skin ulcers

HCV+ or HBV+: markers of hepatitis C virus or hepatitis B virus infection (anti-HCV ±HCV RNA; HBV DNA or HBV surface antigen).

“Definite” mixed cryoglobulinaemia syndrome:

(a) Serum mixed cryoglobulins (±low C4) + purpura + leucocytoclastic vasculitis.

(b) Serum mixed cryoglobulins (±low C4) + 2 minor clinical symptoms + 2 minor serological/pathological findings.

“Incomplete” or “possible” mixed cryoglobulinaemia syndrome:

(a) Mixed cryoglobulins or low C4 + 1 minor clinical symptom + 1 minor serological ±pathological findings.

(b) Purpura and/or leucocytoclastic vasculitis + 1 minor clinical symptom + 1 minor serological ±pathological findings.

(c) Two minor clinical symptoms + 2 minor serological ± pathological findings.

“Essential” or “secondary” mixed cryoglobulinaemia:

Absence or presence of well known disorders (infectious, immunological, or neoplastic) at the time of the diagnosis.

Table 2. Classification Criteria for Mixed Cryoglobulinemia

4.4 Clinical picture of cryoglobulinemic vasculitis and related autoimmune syndromes

4.4.1 Skin involvement

Skin is the most commonly affected target organ in cryoglobulinemic vasculitis. The classical pattern in mixed cryoglobulinemia is cutaneous leukocytoclastic necrotizing vasculitis. (lee et al., 1998, Leon et al., 2002)

4.4.1.1 Purpura

The most commonly reported clinical feature of MC is palpable purpura. Palpable purpura manifests in as much as 70-90% of patients. Lesions are typically seen on the lower legs because of hydrostatics and blood vessel flow sludging, lesions might extend to the abdominal wall and less frequently to the trunk and upper limbs. The purpuric rash might acquire a petechial, papular, seldom necrotic aspect, and it can be compounded to erythematous maculae and dermal nodules. Lesions might be associated with other dermatological symptoms like upper malleolar ulcers as well as urticarial vasculitis. (Antonelli et al., 2009)

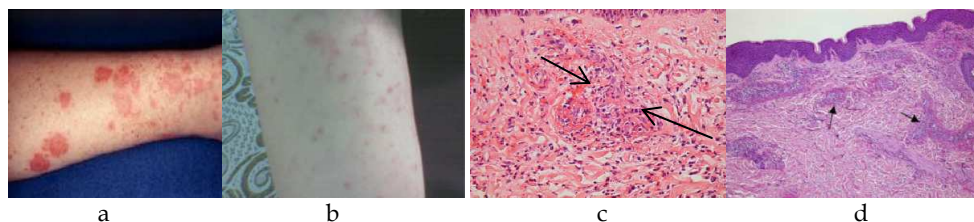


Fig. 2. a- Cutaneous leukocytoclastic vasculitis in mixed cryoglobulinemia patient, b- Palpable purpura with cutaneous leukocytoclastic vasculitis in a female patient with cryoglobulinemic syndrome. c- Nuclear dust associated with a perivascular neutrophilic infiltrate. d- Leukocytoclastic vasculitis (black arrows point to small blood vessels in the subcutaneous tissue with perivascular leukocytes).

Histopathological examination: Skin biopsy is optimally performed by 24-48 hours after the appearance of the lesion. Biopsies should be obtained from non-ulcerated site. Light microscopic examination reveals that the cellular infiltrate is composed of a combination of neutrophils and lymphocytes with a predominance of one cell type or another. Lymphocyte infiltrates are seen in specimens from either new (<12 hours) or old (>48 hours) lesions. The typical histopathologic features from cutaneous vasculitic lesions involve the disruption of blood vessels architecture by an inflammatory infiltrate in and around the vessel walls. Endothelial swelling and proliferation, leukocytoclasia (characteristic degranulation of neutrophils with the production of nuclear dust), might be accompanied by extravasation of erythrocytes. The severity of the histo-pathological changes in the cutaneous lesions of leukocytoclastic vasculitis does not predict extra-cutaneous involvement. Direct immunofluorescence (if sufficient lesions exist, separate biopsies are recommended for histology and DIF). DIF helps to differentiate pauci-immune and immune complex mediated vasculitis. In DIF frozen sections are incubated with fluorescein labeled anti human immunoglobulin (Ig) IgG, IgM, IgA and complement 3. The staining pattern of these immune-reactants provides insight into the diagnosis, the pathophysiology of the lesions and the autoantibody components of the immune complexes. (Stone, 2009, Antonelli et al., 2009)

Other cutaneous features of HCV-MC include; Ischemic necrosis (0-20%), Livedoid vasculitis (14%), cold-induced urticaria (10%), hyperkeratotic spicules in areas exposed to cold, scarring of tip of nose, pinnae, fingertips, and toes, raynaud's phenomenon, acrocyanosis which might evolve to digital ulceration might occur (Saadoun et al., 2007), and nail-fold capillary abnormalities. (Antonelli et al., 2009, Ferri, 2008)

4.4.2 Musculoskeletal involvement

Musculoskeletal complaints are present in as much as 70-80% of the cryoglobulinemic patients, with arthralgia in 40-80% of cases, frank arthritis occurs in less common < 10% of cases. Joint affection in MC is usually bilateral, symmetrical, non-deforming, affecting mainly large articulations, knees and hands, less commonly elbows and ankles with no radiographic evidences of joint destruction in HCV-MC related arthritis. RF activity is present in 70-80% of MC patients. Joint involvement can occur in the absence of RF seropositivity. (Lee et al., 1998, Mohammed et al., 2010) Antibodies to citrullinated C peptide (highly specific for rheumatoid arthritis) usually aren't significantly present. Myalgias, fibromyalgia, weakness and chronic fatigue are more frequent in cryoglobulin-positive than in cryoglobulin-negative HCV patients with recent evidences revealing higher prevalence of fibromyalgia and chronic fatigue syndrome with elevated fatigue score in HCV female patients. The elevated fatigue score is probably related to an increase in serum leptin levels which might interact with serotonin neurotransmission. Polymyositis is not uncommon. (Sene et al., 2006, Wener et al., 2004)

4.4.3 Neurological involvement

Neurological involvement in HCV-mixed cryoglobulinemia commonly presents by vasculitic peripheral neuropathy (subacute, chronic or acute on top of chronic). The pattern of affection ranges from pure sensory axonal neuropathy to mononeuritis multiplex. The most frequently described form is distal sensory or sensory motor polyneuropathy. Motor deficit is inconsistent, predominantly affecting the lower limbs appearing after sensory affection. The sensory involvement is usually bilateral commonly asymmetrical, with parasthesias and burning pain having characteristic nocturnal exacerbation. Polyneuropathies represent 40-70% of mixed cryoglobulinemic neuropathy, whereas mononeuritis multiplex represents 30-55% of cases. Nerve conduction studies show predominantly axonal neuropathy affecting mainly the sensory nerves. Nerve biopsies reveal axonal degeneration, differential fascicular loss of axons, signs of demyelination and small vessel vasculitis with mononuclear cell infiltrate in the perivascular area, HCV-RNA was found in epineural cells by reverse transcriptase polymerase chain reaction (RT-PCR). (Authier et al., 2003) Central nervous system involvement in patients with HCV-associated vasculitis is rare. (Dawson et al., 1999) Clinical presentations might be in the form of transient ischemic attacks, stroke, progressive reversible ischemic neurological deficits, lacunar infarcts, pseudotumor cerebri or encephalopathic syndrome. Magnetic resonance imaging studies are consistent with ischemic injury, with either small lesions of the periventricular white matter and the cerebral trunk or extensive supra and infra-tentorial white matter lesions diagnostic of cerebral vasculitis predominantly small sized vessel vasculitis. Neurocognitive impairment and Guillian-Barre syndrome can exist. (Casato et al., 2005, Heckmann et al., 1992)

4.4.4 Renal Involvement in HCV-mixed cryoglobulinemia syndrome:

Renal involvement in HCV-infected patients occurs in 10-60% of cases (**figure 6**). The most commonly reported form is cryoglobulinemic membranoproliferative glomerulonephritis. Less common forms of renal involvement include; non-cryoglobulinemic membranoproliferative glomerulonephritis, Ig A nephropathy, postinfectious glomerulonephritis, membranous nephropathy, thrombotic microangiopathies, focal and

segmental glomerulosclerosis, fibrillary or immunotactoid glomerulopathy. Cryoglobulinemia is present in almost 100% of patients with HCV- nephropathy. Renal involvement in HCV-MC is an immune complex mediated nephropathy (deposition in the glomerulus of immune-complexes made by the HCV antigen, anti-HCV Ig G antibodies, and a rheumatoid factor, which is an IgM kappa), usually in the form of type I membranoproliferative glomerulonephritis (MPGN). Such pattern of organ involvement severely affects the prognosis and survival of patients with HCV-mixed cryoglobulinemia. Renal disease in most cases, is a subsequent event to the cutaneous lesions (purpura), and might be associated with other extrahepatic manifestations like arthralgia and neuropathy. The commonest renal manifestation is asymptomatic proteinuria with microscopic hematuria, renal function is usually normal. In one quarter of patients there is nephritic syndrome, with macroscopic hematuria, proteinuria, hypertension, and increased serum creatinine. Hypertension develops in almost 80% of cases and often difficult to control. Occasionally, there is proteinuria in nephrotic range. The renal course of mixed cryoglobulinemia is variable; glomerular lesions usually have a more benign course than idiopathic membranoproliferative GN. Moderate renal insufficiency occurs in up to 50% of patients. Chronic renal failure develops years after the onset in approximately 10% of cases, oliguric or anuric renal failure develops in <5% of patients. There is hypo-complementemia in most of cases, but usually it is more marked for C4, with C3 slightly decreased or normal. (Garini et al., 2005, Kamar et al., 2006)

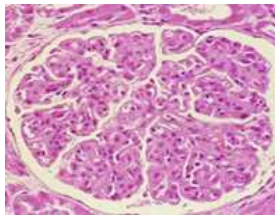


Fig. 3. Cryoglobulinemic glomerulonephritis with membranoproliferative and mesangial proliferative features. Strongly PAS-positive small cryoglobulin plugs are present within capillary loops. In the setting of subacute cryoglobulinemic glomerulonephritis, inflammatory cells can be present within the glomerulus. (periodic acid-Schiff stain original magnification x200)

Histopathological examination reveals glomerular hypercellularity predominantly by leukocytes and monocytes (different to idiopathic MPGN in which hypercellularity is mainly by mesangial and endothelial cells). Capillary walls show similar characteristics to those of idiopathic MPGN: double contours, "tram-tracking" aspect, duplication of the glomerular basement membrane and cells interposition in the subendothelial space (mainly monocytes). Usually there are nodular, eosinophilic, hyaline, homogeneous deposits occupying some glomerular capillary lumina: intraluminal thrombi; when present are highly suggestive of the disease. Crescents are not frequent. In few patients there is mesangial hypercellularity and sclerosis signifying chronicity with progressive organ damage. **Immunofluorescence:** There are parietal subendothelial deposits of IgG and IgM, usually accompanied by C3 and C4, with a variable intensity. Intraluminal thrombi are strongly positive for IgG and IgM demonstrating their origin in immune complexes. Staining for IgG and IgM may be present in mesangium, arterial walls, and arterioles. When

there is a monoclonal component (in type II cryoglobulinemia) the monoclonal origin can be demonstrated (usually kappa light chain). **Electron microscopy:** Glomerular lesions are very similar to those found in type I MPGN, but in cryoglobulinemia deposits are characteristically: organized, fibrillary or microtubular, with a distinctive substructure; there is a combination of curved cylinders arranged in pairs and annular structures in the subendothelial space. The cells that interpose in the subendothelial space (between the original GBM and the new synthesized membrane, or between GBM and endothelial cell) are in their majority monocytes (in idiopathic MPGN, mesangial cells occupy this space). (Garini et al., 2004)

4.4.5 Sicca syndrome

Symptomatic xerophthalmia and xerostomia occurs in 10-53% of HCV infected patients, the classical definite picture of Sjogren's syndrome is less commonly encountered in HCV-MC patients. In a recent study, serological screening of 1309 patients with Sjogren's syndrome for HCV seropositivity showed 156 patients (12%) to be seropositive for HCV. In HCV related sicca syndrome, xerostomia was found more abundant than xerophthalmia. (8) Sicca syndrome with HCV-MC represents a form of lymphocytic sialadenitis, the mechanism of damage to the salivary epithelial cells might be due to; either direct viral sialotropism (virus secreted in the saliva) or indirect immune mediated inflammatory process. Unlike patients with primary Sjogren's syndrome in patients with HCV-MC related Sjogren's syndrome, serological markers for MC are usually present including low complement 4, rheumatoid factor seropositivity and detectable mixed cryoglobulins. Salivary gland biopsy shows pericapillary and non-pericanalary lymphocytic infiltrate with lack of glandular canal damage. In patients with HCV related sialadenitis the prevalence of anti-SSA and anti-SSB antibodies were nearly 20%. (Doeffel- Hantz et al., 2005, Ramos-Casals et al., 2001)

4.4.6 Lung involvement

Pulmonary involvement is more common in cryoglobulinemic HCV-infected patients compared to non-cryoglobulinemic patients. Pulmonary involvement is mild and mostly in the form of interstitial lung disease. The disease is usually clinically inert, except for some patients who present with cough, moderate exertional dyspnea and a minimal decrease in pulmonary function tests. Pleural effusion and alveolitis with alveolar hemorrhage, hemoptysis, severe acute lung insult with acute respiratory distress might develop in HCV-MC. The condition is usually fatal and is mostly due to diffuse pulmonary vasculitis (autopsy disclosed pulmonary perivascular localization of IgG and IgM with immune complex materials containing IgM (kappa) and IgG occluding the pulmonary vessels in these patients (Ferri et al., 1997, Okutan et al., 2004, Suzuki et al., 2003).

4.4.7 Gastrointestinal tract involvement

Gastrointestinal involvement occurs in 2-22% of cases. Mesenteric vasculitis with abdominal pain, acute abdomen and even gastrointestinal bleeding might occur in HCV cryoglobulinemic vasculitis. Liver damage is common, over 50% of patients show signs of mild to moderate chronic hepatitis at diagnosis. Liver involvement is characterized by abnormally increased liver enzymes with or without echographic and/or histological features of chronic hepatitis, cirrhosis, or hepatocellular carcinoma. Late evolution into overt cirrhosis occurs in 25% of cases. Cryoglobulins are a prognostic indicator for increased risk

of cirrhosis in patients with chronic hepatitis C. Splenomegaly might coexist. (Kayali et al., 2003, Remoroza and Bonkovsky, 2003)

3.4.8 Cardiovascular involvement

Patterns of cardiovascular involvement in HCV-MC include: mitral valvular damage with mitral regurge, coronary vasculitis complicated by myocardial infarction, pericarditis, congestive heart failure and hypertrophic cardiomyopathy. Arterial thrombosis reported in 1%. (Antonelli et al., 2009)

4.4.9 Ocular

Retinopathy with cotton-wool spots, hemorrhages and arteriolar occlusion on fundus examination can occur in HCV patients with cryoglobulinemia, but rather a frequent complication of interferon therapy than HCV related small vessel vasculitis, uveitis is rare. Mooren's ulcer is a rapidly progressive, painful ulceration of the cornea that might occur. The diagnosis of Mooren's ulcer is a diagnosis of exclusion. (Remoroza and Bonkovsky, 2003)

4.4.10 Endocrine system

Some endocrinological disorders are significantly more frequent in HCV-MC patients compared to the general population. The most common endocrinal disorders are the thyroid disorders including; autoimmune thyroiditis, subclinical hypothyroidism, thyroid cancer with high prevalence of anti-thyroperoxidase antibody and antithyroglobulin antibody. Hyperthyroidism is less frequent, generally as reversible complication of interferon treatment. Type 2 diabetes is another frequent endocrinal disorder in cryoglobulin-positive than in cryoglobulin-negative patients. The raised prevalence of type 2 diabetes in HCV-patients with mixed cryoglobulinemia is attributed to an immune-mediated mechanism (127). Insulin resistance mediated by proinflammatory cytokines, rather than a deficit in insulin secretion, is probably the primary pathogenic mechanism involved in the development of type 2 diabetes in HCV infection. Erectile dysfunction is another disorder in male patients with HCV-MC attributable to hormonal and/or neuro-vascular alterations. (Antonelli et al., 2004 a&b, Ferri et al., 2002,b)

4.4.11 Hematological abnormalities

Anemia of chronic disease and thrombocytopenia are amongst the commonly reported hematological abnormalities in HCV-patients with cryoglobulinemia. The proposed pathological mechanisms in HCV related thrombocytopenia involved; platelet sequestration and destruction in the spleen, along with low thrombopoetin production and direct viral infection of the megakariocytes with immune mediated platelet destruction. (De Almeida et al., 2004, Doi et al., 2002, Giannini et al., 2002, Jiang et al., 2002). Autoimmune hemolytic anemia has been reported in female patients with cryoglobulinemic syndrome (8), Leukocytosis, an elevated erythrocyte sedimentation rate (ESR) and an elevated C-reactive protein level are common findings in most types of vasculitis. The auto-antibodies seen in patients with HCV infection resemble those seen in chronic viral infections - the autoantibody titers are low, frequently found during the clinical course of cryoglobulinemia, however, not essentially associated with typical autoimmune disease. Serological abnormalities in HCV-MC involve positive antinuclear antibodies (ANA), antismooth muscle antibodies (ASMA), anti-neutrophil cytoplasmic antibodies (ANCA), and anti-

cardiolipin autoantibodies. The prevalence of ANA and ASMA ranges from 4.4% to 41% and 7% to 66% respectively usually with low titre $\leq 1/160$. HCV core particles concentrated in the cryoprecipitate provoke an interaction between the cryoglobulins, endothelial cells and neutrophil granulocytes. A positive ANCA has been found in <5-10% of patients with HCV-associated mixed cryoglobulinemia with proteinase 3 and dihydrolipoamine dehydrogenase as the main anti-neutrophil cytoplasmic antigens in patients with HCV-MC. HCV patients with ANCA had a higher prevalence of skin involvement, anemia, abnormal liver function tests and elevated alpha feto-protein levels. Anti-cardiolipin antibodies occur in 3.3% to 22% of HCV patients, with higher frequency in patients with HCV-associated cryoglobulinemia yet insignificant being anti-b2-glicoprotein independent. (Cacoub et al., 1997, Lamprecht et al., 2003, Ordi-Ros et al., 2000, Yee et al., 2004, Wu et al., 2002)

4.4.12 Neoplastic disorders

Mixed cryoglobulinemia syndrome is considered as a pre-neoplastic syndrome that features a cross road between virus related autoimmune syndromes and virus associated malignancies (B cell lymphoma, hepatocellular carcinoma). B-cell lymphoma is the most frequent neoplastic manifestation complicating mixed cryoglobulinemia that presents late in the course of the disease. (Cacoub et al., 2000) Neoplasia is attributed to sustained peripheral B-lymphocyte expansion with significantly persistent lymphoid infiltrates that remain unmodified for years in the liver and bone marrow of MC patients. Such infiltrates are considered as "early lymphomas", and are given the nomenclature "monotypic lymphoproliferative disorder of undetermined significance (MLDUS)". Type II MC-related MLDUS has the highest incidence in the same geographic areas with high prevalence of HCV infection. The onset of malignant lymphoma is usually 5-10 years after disease diagnosis, with a reported incidence of less than 10% in some patients to as high as 40% in others. Overt lymphoid tumors develop in about 10% of cases. A sudden decrease or disappearance of serum cryoglobulins and RF with abnormally high levels of C4, are presenting symptoms of complicating B-cell malignancy. Other neoplastic manifestations, i.e. hepatocellular carcinoma or papillary thyroid cancer, are less frequently observed (Ferri et al., 2002, Matsuo et al., 2004, Quartuccio et al., 2007).

4.4.13 Other disease related features

Constitutional symptoms like fever, fatigue, anorexia, weight loss, amongst other immune mediated HCV related extra-hepatic manifestations including: Porphyria cutanea tarda, Lichen planus, pancreatitis, aplastic anaemia, systemic lupus erythematosus, CREST syndrome, and Waldenström's macroglobulinemia might exist. (Ferri et al., 2002 a, Ferri et al., 2000)

5. HCV and polyarteritis nodosa PAN (medium sized vessel vasculitis)

Despite that polyarteritis nodosa is more commonly reported in patients with hepatitis B viremia, yet medium sized vessels inflammation can occur in patients with chronic HCV infection featuring a polyarthritits nodosa pattern of vasculitis. PAN can occur in cryoglobulinemic as well as non cryoglobulinemic HCV patients. HCV related PAN displays a more severe and acute clinical presentation with more frequent fever and weight loss, severe hypertension, gastrointestinal tract involvement, severe acute sensory-motor

multifocal mononeuropathy, kidney and liver microaneurysms and elevated acute phase reactants levels. Cases of mesenteric vasculitis with stenosis and narrowing of the superior mesenteric vessels and reno-vascular micro-aneurysm with renal cortical infarcts have been described in HCV patients having purpuric eruptions, hypertension and abdominal pain. Such lesions resolved with antiviral therapy and prednisolone, supporting the possible etiopathogenic role of chronic HCV infection. Another case with vasculitic mucosal colonic ulceration with massive hematochezia, purpura, abdominal discomfort, pulmonary infiltrate and acute renal failure was described in a female patient with chronic HCV infection and negative for cryoglobulinemia, colonic biopsy showed evidence of fibrinoid necrotizing arteritis diagnosing a case of HCV related PAN with no evidence of leukocytoclastic vasculitis. (Costedoat-Chalumeau et al., 2002, Elias et al., 1998, Saadoun et al., 2010a)

6. Diagnosis of HCV- mixed cryoglobulinemia

6.1 Cryoglobulin detection

The detection of serum cryoglobulins is fundamental for the diagnosis of mixed cryoglobulinemia. (Ferri et al., 2002 a, Ferri et al., 2008) Due to their thermal instability, the measurement of cryoglobulin level in the blood should be performed immediately after sampling. For a correct evaluation of serum cryoglobulins it is necessary to avoid false-negative results due to Ig cold precipitation at room temperature, blood sampling, clotting, and serum separation by centrifugation is carried out at 37°C and the cryocrit determination and cryoglobulin characterization at 4°C (after 7 days). Cryocrit determinations (percentage of packed cryoglobulins referred to total serum after centrifugation at +4°C) should be done on blood samples without anticoagulation to avoid false-positive results due to cryofibrinogen. The analysis of cryoprecipitates is generally carried out by means of immunoelectrophoresis or immunofixation, other more sensitive methodologies include; immunoblotting or two-dimensional polyacrylamide gel electrophoresis. Type II MC shows a microheterogeneous composition. Type II-III mixed cryoglobulinemia represents an intermediate, evolutive state from type III to type II. The absence of detectable serum cryoglobulins despite the presence of the clinical syndrome is described to be a transient phenomenon due to the wide variability of the percentage of cryoprecipitable immune-complex during the natural history of the disease or, less frequently, to a switching from 'benign' B-cell lymphoproliferation to malignant lymphoma. The levels of serum cryoglobulins usually do not correlate with the severity and prognosis of the disease. (Ferri et al., 2002 a, Ferri et al., 2000)

6.2 Laboratory tests

Laboratory workup includes complete blood cell count with evidences of anemia of chronic disease, thrombocytopenia or autoimmune hemolytic anemia. Erythrocyte sedimentation rate is almost always elevated in all types of vasculitis, but a normal ESR does not rule out systemic vasculitis. Blood urea nitrogen, creatinine for renal involvement, proteinuria and hematuria on urinalysis, a fresh-spun urine sample should be evaluated for red blood cell casts or dysmorphic red cells to diagnose glomerulonephritis. Up to 40 % of patients with chronic hepatitis C have normal serum ALT levels, even when tested on multiple occasions. (Ferri, 2008, Ghany et al., 2009)

6.3 Serological tests

For the diagnosis of HCV, hepatitis C antibody testing is crucial, regarding the response to treatment quantitative assessment of viral load HCV-RT-PCR as well as the viral genotyping are important prognostic markers. Sustained negative results for HCV-RT-PCR with treatment signifies a sustained viral response. Rheumatoid factor and serum anti-cyclic citrullinated C peptide antibodies (markers for rheumatoid arthritis) are useful diagnostic tools in arthritis patients. Complement 3 (C3) and complement 4 (C4) and CH50 are usually consumed in patients with renal disease. Anti-neutrophil cytoplasmic antibodies (P-ANCA might be found in patients with small to medium sized vessel vasculitis). Anti SSA and anti-SSB (in up to 20%) and thyroid specific antibodies (up to 22.1%) are amongst associating serological abnormalities (Ghany et al., 2009, Ferri, 2008, Antonelli et al., 2009)

6.4 Imaging studies

Chest x ray and high resolution computerized tomography for diagnosis of pulmonary involvement, echocardiography and electrocardiogram (ECG) for cardiac disease, abdominal ultrasound for hepatic and renal disease. (Ferri, 2008)

6.5 Biopsy

Histopathological evidences of vasculitis remain the gold standard for the diagnosis of vasculitis. Biopsy from clinically involved sites (cutaneous lesions, nerve biopsy, renal biopsy) is a cornerstone in establishing the diagnosis. Bone marrow biopsy should be done to demonstrate polyclonal B cell proliferation and in suspected cases with lymphoproliferative disorders (Mukhtyar et al., 2009).

6.6 Differential diagnosis

A frequent clinico-pathological overlap exists between HCV-related cryoglobulinemic syndrome and some autoimmune diseases including; small and medium sized vessel vasculitides, infectious vasculitides (Bacterial vasculitis e.g., Neisserial, mycobacterial vasculitis e.g., Tuberculous, spirochetal vasculitis e.g., Syphilitic, rickettsial vasculitis e.g., Rocky Mountain Spotted Fever, fungal vasculitis e.g., Aspergillosis, viral vasculitis e.g., Herpes zoster, HIV), primary Sjogren's syndrome, secondary types of vasculitis (rheumatoid arthritis, systemic lupus erythematosus, seronegative arthritides), membranous glomerulonephritis, immune mediated thyroiditis, type II diabetes, autoimmune hepatitis, and myelo-proliferative disorders (lymphomas, leukemias and Plasma cell dyscrasias). (Ghany et al., 2009, Jennette et al., 1994)

7. Treatment of HCV related vasculitides

7.1 Treatment of HCV

Clinical improvement of HCV related vasculitides proved to correlate with virological response. Introducing anti-viral therapy namely interferon alpha with or without ribavirin remains the cornerstone in the management of HCV-MC. Antiviral therapy has been shown to reverse bone marrow monoclonal B-cell expansion in patients with HCV-MC. (Davis et al., 2002, Mukhtyar et al., 2009, NIDDK, 2010)

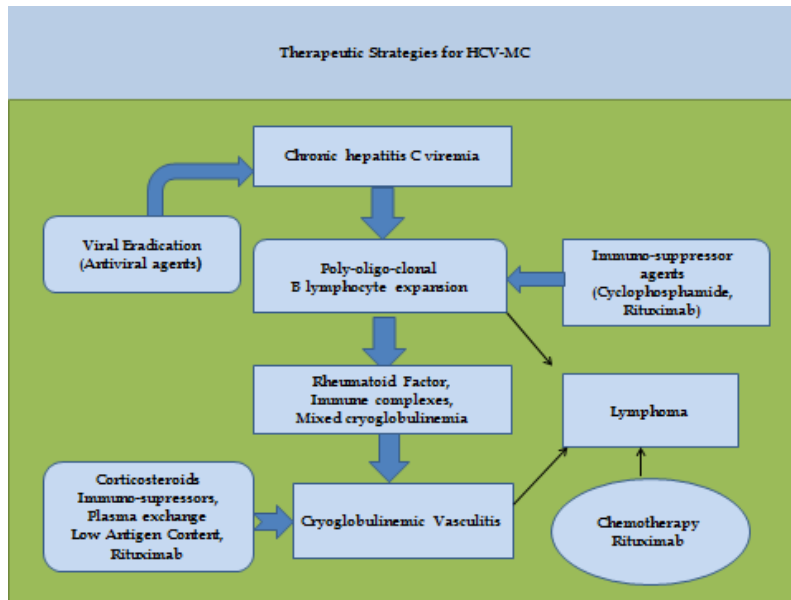


Fig. 4. Therapeutic strategies for hepatitis C mixed cryoglobulinemia.

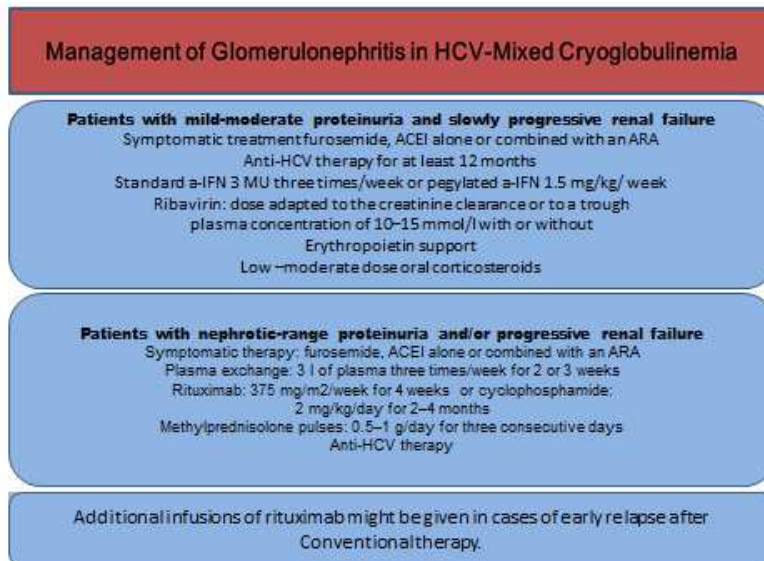


Fig. 5. Treatment of HCV cryoglobulinemic renal disease. The management of renal disease in HCV mixed cryoglobulinemia depends upon the severity of renal disease. The standard regimen is a combination of immunosuppressive drugs, antiviral agents in addition to symptomatic therapy. In refractory cases rituximab will be the drug of choice. (Alric et al., 2004, *Kidney International*, Guideline 5, 2008)

7.1.1 Interferon-alpha therapy

The standard initial therapy used to be recombinant interferon alfa-2b at a dose of 3×10^6 units administered subcutaneously 3 times per week for 6 weeks. Recombinant forms of alpha interferon are being currently replaced by pegylated interferon (peginterferon). Peginterferon is alpha interferon modified chemically by the addition of a large inert molecule of polyethylene glycol prolonging its half-life. Peg-Interferon being with better efficacy and easier administration replaced standard interferon both as monotherapy and as combination therapy for hepatitis C viremia. Peg-interferon is more active than standard interferon in inhibiting HCV and yields higher sustained response rates with equivalent side effects. Two forms of peg-interferon are available: peg-interferon alfa-2a and peg-interferon alfa-2b, roughly equivalent in efficacy and safety, with different dosing regimen. Peginterferon alfa-2a is given subcutaneously in a fixed dose of 180 micrograms (mcg) per week, while peginterferon alfa-2b is given subcutaneously weekly in a weight-based dose of 1.5 mcg per kilogram per week in the range of 75 to 150 mcg per week.

The goal of interferon treatment is suppression of active disease by achieving a sustained viral response (sustained decrease or negative HCV-RT PCR). **Table 4** Interferon alpha monotherapy is effective in purpuric skin lesions, thrombocytopenias, but less effective with neural or renal involvement. IFN-alpha monotherapy is associated with a relatively poor response and a high virologic relapse rate, detectable viremia with active liver disease can occur with normal alanine transferase. Higher initial doses and longer duration of therapy help to increase the interval before relapse and escalation of the dose might help to achieve response in some non-responders.

Peg-interferon therapy has bone marrow suppressive effects or cytopenias, therapy might be associated with immune mediated side effects including in about 2% of patients (particularly if high titers of antinuclear or antithyroid antibodies); peripheral sensory-motor neuropathy, nephropathy, retinopathy and micro-hemorrhages, thyroiditis, Sjogren's syndrome, rheumatoid like polyarthritis, psoriasis, fever, chills, headache, lethargy, somnolence, myalgia and fatigue, anorexia, hearing loss and tinnitus and serious CNS complications might occur during therapy. Rare side effects include; acute congestive heart failure, renal failure, vision loss, pulmonary fibrosis or pneumonitis, sepsis, acute myocardial infarction, stroke, suicide, and sepsis. Paradoxical worsening of hepatic disease provoking a form of autoimmune hepatitis that requires corticosteroid therapy is rare. Peginterferon therapy is contraindicated in severe depression or other neuropsychiatric syndromes, active substance or alcohol abuse, uncontrolled autoimmune disease (such as rheumatoid arthritis, lupus erythematosus, or psoriasis), bone marrow compromise, and inability to practice birth control measures. (Casato et al., 1997, Ferri et al., 1993, Iga et al., 2005, Lidove et al., 1999).

7.1.2 Ribavirin

Ribavirin is a broad spectrum antiviral nucleoside analog which acts through enhancement of host T-cell-mediated immunity against viral infection through switching the T-cell phenotype from type 2 to type 1, inhibition of the host enzyme inosine monophosphate dehydrogenase (IMPDH), direct inhibition of HCV, including NS5B-encoded RNAdependent RNA polymerase (RdRp) and being an RNA mutagen it drives a rapidly mutating RNA virus over the threshold to "error catastrophe". Ribavirin is an oral drug,

given twice a day in 200-mg capsules for a total daily dose based upon body weight (1,000 mg < 75 kg or 165 pounds and 1,200 mg for those >75 kg). Combination of ribavirin and interferon increases the sustained response rate by 2- to 3-fold with rapid improvements in serum ALT levels and disappearance of detectable HCV RNA in up to 70 percent of patients. The optimal therapeutic dose of ribavirin and the optimal duration varies depending upon viral genotype (genotype 1, rare genotypes 4, 5, 6 require the maximum therapeutic dose/body weight, and longer duration). Considering the variable responses to treatment, testing for HCV genotype is clinically useful before starting combination therapy. A response is considered "sustained" if HCV RNA remains undetectable for 6 months or more after stopping therapy. Some patients relapse by the end of treatment, the relapse rate is lower with combination therapy (55% sustained response with combination therapy for 48 weeks compared 35% with monotherapy)

Study	Patients (no)	TYPE OF STUDY	Treatment	Responses (%) (genotype unrelated)	Follow up
Calleja et al., 1999 (13)	13	Prospective	IFN 3 MU × 3 per week + Riba 1200 mg/day × 1 year	65	22% relapse rate
Zuckerman et al., 2000 (114)	9	Prospective	IFN 3 MU × 3 per week + Riba 15 mg/kg/day × 6 months.	100	NA
Donado et al., 1998 (28)	17	Prospective	IFN 6 MU × 3 per week × 3 months, 3 MU × 3 per week × 3 months + Riba 15 mg/kg/day × 6 months	85	55% relapse rate within 1 year
Mazzaro et al., 2003 (68)	27	Prospective	IFN 3 MU × 3 per week + Riba 1200 mg/day × 1 year	CR+PR: 85	70% early relapse; 22% long-term clinical and virological response

Table 5. Combined Treatment Interferon plus Ribavirin in HCV-related Cryoglobulinemia. CR = Complete remission; HCV = Hepatitis C virus; NA = Not applicable; PR = Partial remission; Riba = Ribavirin.

Ribavirin therapy causes anemia, fatigue and irritability, itching, skin rash, nasal stuffiness, sinusitis, and cough, red cell hemolysis to a variable degree in almost all patients. Patients with a pre-existing hemolysis or anemia (hemoglobin < 11 grams or hematocrit < 33 percent) should not receive ribavirin. Similarly, patients who have significant coronary or cerebral

vascular disease should not receive ribavirin, as the anemia caused by treatment can trigger significant ischemia. Fatal myocardial infarctions and strokes are amongst reported side effects during combination therapy with alpha interferon and ribavirin.

Ribavirin is excreted largely by the kidneys. Patients with renal disease can develop hemolysis that is severe and even life threatening. With serum creatinine above 2.0 mg per deciliter (dL) patients should not be treated with ribavirin. Ribavirin causes birth defects in animal studies and should not be used in women or men without contraception. Peg-interferon has direct antigrowth and anti-proliferative effects so it is contraindicated during pregnancy. Combination therapy should therefore be used with caution. Contraindications to ribavirin include marked anemia, renal dysfunction, and coronary artery or cerebrovascular disease, and inability to practice birth control. The newly emerging direct-acting antiviral (DAA) drugs are at the preclinical developmental stage and several are in clinical development. Initial clinical trials using some of these inhibitors, either alone or in combination with pegylated IFN-alpha and ribavirin, have yielded encouraging results. (Cacoub et al., 2002, Mazzaro et al., 2003, Pawlotsky, 2011) **Table 5.** Recently nucleotide polymorphism upstream of IL-28B gene has been found to be associated with response to PEG-IFN and ribavirin and spontaneous clearance of HCV infection in addition, genetic variants of inosine triphosphate (ITPA) have been correlated with protection against ribavirin induced hemolytic anemia (Fellay 2010)

7.2 Corticosteroids, standard Immunosuppression and plasma exchange therapy

The treatment of cryoglobulinemic vasculitis depends upon the severity of the acute manifestations and the extent of organ involvement. In asymptomatic MC monitoring without treatment is recommended. In patients with mild to moderate cryoglobulinemic symptoms (purpura, arthralgias, peripheral sensory neuropathy) first-line immunosuppression usually consists of low-dose corticosteroids. Patients with severe manifestations (cryoglobulinemic nephropathy, skin ulcers, sensory motor neuropathy, wide spread vasculitis) should promptly receive high-dose steroids and immunosuppressive therapy. Use of high dose intravenous corticosteroids might be useful for controlling life threatening organ involvement. Immunosuppressive drugs (e.g., Cyclophosphamide, Chlorambucil, and Azathioprine) can be used to suppress antibody and cryoglobulin production. The most effective and commonly used cytotoxic drug is Cyclophosphamide (750-1000mg intravenous pulse or orally at doses of 2 mg/kg per day). Recently; Mycophenolate Mofetil (1 g twice a day) is used as an alternative to Cyclophosphamide for the induction of remission in MC vasculitis. Mycophenolic Acid is more selective than Cyclophosphamide in inhibiting lymphocyte proliferation and functions, the drug was found to reduce viremia in HCV-infected renal or heart-transplant recipients due to its ability to inhibit inosine monophosphate dehydrogenase, the target enzyme inhibited by ribavirin. (Cacoub et al., 2005)

6.3 Plasma exchange

Plasma exchange therapy permits rapid control of life threatening symptoms of vasculitis by removal of circulating immune complexes with or without using high dose intravenous corticosteroids or immunosuppressive treatments, particularly in active cryoglobulinemic nephropathy. Oral cyclophosphamide (50-100 mg/day for 2-6 weeks) during the tapering of

aphaeretic sessions can reinforce the beneficial effect of plasma exchange; and prevent the rebound phenomenon that may be observed after the aphaeresis discontinuation. Plasma The use of INF- alpha after each plasma exchange session doesn't modify the viral response (Hausfaster et al., 2002, Khattab et al., 2010, Morra, 2010)

7.4 Biologic agents

7.4.1 Anti-CD20 therapy -Rituximab

Rituximab is a humanized anti- CD-20 monoclonal antibody that was primarily successfully employed for the treatment of B-cell lymphomas and other chronic lymphoproliferative diseases. The drug has proven efficacy in autoimmune disorders including vasculitis and refractory systemic lupus with nephritis. Recently, rituximab showed efficacy in cases of HCV-mixed cryoglobulinemia. The drug was successfully used in combination with antiviral agents as well as monotherapy in HCV cryoglobulinemic vasculitis. Rituximab combined with Peg-IFN- α /ribavirin delete both virus-dependent and -independent B-cell clones. Antiviral therapy alone decreased the memory B cells; whereas in association with rituximab, naive B cells are the main depleted population. This fact accounts for the delayed B-cell reconstitution after rituximab plus Peg-IFN- α /ribavirin and stresses the synergistic action of rituximab and antiviral therapy at the immunologic level. Rituximab shortens the therapeutic interval required for achieving a complete clinical reponse. Clonal expansion of marginal zone-like IgM+ CD27+ B cells (VH1-69 clonal B) has been recently observed in certain HCV-MC patients. Rituximab with Peg-IFN and ribavirin exerts a synergistic effect on polclonal B lymphocyte expansion. Rituximab plus Peg-IFN- α /ribavirin was more efficient to suppress both memory and VH1-69 clonal B cells compared with Peg-IFN- α /ribavirin alone. (Zaga et al., 2003, Sansonno et al., 2003, Roccatello et al., 2008) A standard therapeutic dose of 375 mg/m² weekly for 4 weeks is effective, well tolerated and induces a significant and rapid improvement of clinical signs (purpura, arthralgia, peripheral neuropathy) with a decline of cryocrit in most patients with mixed cryoglobulinemia even in cases resistant to IFN therapy.

Rituximab trials emphasized the benefit of the drug in inducing remission in cutaneous vasculitis, cryoglobulinemic nephropathy, cryoglobulinemic neuropathy and in underlying malignant lymphoproliferative disorder. Relapse of cryoglobulinemic vasculitis might occur. Complete clinical remission was associated with a significant reduction of RF activity and anti-HCV antibody titers. (Saadoun et al., 2008) An increase of viremia might be observed in responders, with insignificant variation of transaminases or deterioration of liver disease. Rituximab infusions proved effective on cryoglobulinemic vasculitis, with a Recent studies showed a relapse in 36.1% of patients within a few days to 19 months after the last rituximab infusion. Complete immunologic response was higher with the combination of rituximab plus Peg-IFN- α /ribavirin. Recently, rituximab treatment of a renal-transplant patient with de novo HCV-related type III cryoglobulinemic MPGN resulted in clearance of cryoglobulinemia, a decrease in proteinuria yet without a change in serum creatinine or HCV RNA. Rituximab, the drug can cause serum sickness, serum sickness like disease, neutropenia and increased risk of infections, pneumopathy, varicella zoster infection, erysipelas and as monotherapy increases HCV viremia. (Saadoun et al., 2010, Pereira et al., 2010) **Table 6**

Study	Patients (number with nephritis)	Rituximab dose	Other treatments	Remission overall (nephritis)	Remission purpura (neuropathy)	Side effects	HCV viral load	Relapse (number of cases)
Sansonno <i>et al.</i> 2003 (97)	20 (1)	375 mg/m ² weekly × 4 weeks	S (low doses)	16/20 (1/1)	12/14 (6/12)	Septic fever (1)	↑ responders = nonresponders	4/16 (>7 months)
Zaja <i>et al.</i> 2003 (110)	15 (2)	375 mg/m ² weekly × 4 weeks	S (<0.5 mg/kg/day)	13/14 (1/2)	12/12 (5/5)	Retinal thrombosis (1)	↑ 2/8 ↑ 1/8 = 5/8	6 (3–6 months)
Roccatello <i>et al.</i> ,2004 (87)	6 (5)	375 mg/m ² weekly × 4 weeks; 375 mg/m ² monthly × 2 months		5/5	4/4 (5/6)	Transient bradycardia (2)	4 unchanged	2 (>12 months)
Quartuccio <i>et al.</i> , 2006 (83)	5 (5)	375 mg/m ² weekly × 4 weeks	S (one case)	5/5 (5/5)	4/4 (1/2)	Transient neutropenia (1)	NR	3 (>5, >7 and >12 months)
Basse <i>et al.</i> 2005 (8)	7 (7) (post-kidney transplant)	375 mg/m ² weekly × 2–4 weeks	CNI, MMF and S	7/7		Lethal infection (2, fungal and HSV)	NR	NR
Visentini <i>et al.</i> 2007 (106)	6 (2)	250 mg/m ² weekly × 2 weeks	S	4/6 (1/2)	4/5 (2/2)	Lethal intestinal infarction	↓ 2/5 = 3/5	NR

Table 6. Rituximab treatment in Patients with HCV cryoglobulinemic vasculitis. CNI = Calcineurin inhibitor; HCV = Hepatitis C virus; HSV = Herpes simplex virus; MMF = Mycophenolate mofetil; NR = Not reported; S = Steroids. ↑: Increase; ↓: Decrease; =: No change.

7.5 Low antigen diet (LAC-diet)

LAC-diet is a particular dietetic treatment that can improve the clearance of circulating immune-complexes by restoring the activity of the reticulo-endothelial system, overloaded

by large amounts of circulating cryoglobulins. LAC-diet can be used for controlling mild disease manifestations. (Ferri et al., 1989, Morra, 2010)

7.6 Symptomatic therapy

Controlling blood pressure: diuretics, renin-angiotensin system blockade, the treatment of hyperlipidemia, are of proven benefit in prognosis of renal disease. Colchicine, an anti-inflammatory agent has been proposed for MC patients with mild to moderate levels of the disease. (Khatab et al., 2010)

7.7 Treatment of HCV-related vasculitis relapses

Clinical relapses are usually associated with relapsing HCV viremia (detectable HCV-RT-PCR). The use of combination therapy for in escalating doses for longer duration (18-24 months) effective in limiting relapses particularly in cases with renal involvement or peripheral neuropathy. A relapsing cryoglobulinemic vasculitis without HCV viral relapse might occur and in such conditions the possibility of an underlying malignant lymphoma (B cell Non-Hodgkin's Lymphoma) should be considered. Relapses can be successfully treated with a second trial of combination antiviral therapy with immunosuppression or anti CD-20 monoclonal antibody rituximab. (Fois et al., 2003, Saadoun et al., 2010) New direct acting antiviral drug combinations are under trial, the evolution of these drugs might expand the therapeutic benefit of combination therapy in HCV infection as well as extrahepatic disease. (Franciscus, 2011)

8. Prognosis

The prognosis of HCV-MC depends upon the extent and severity of organ involvement and the response to treatment (viral load and clinical manifestations). The overall prognosis is worse in persons with concomitant renal disease or lympho-proliferative disease (B cell non Hodgkin lymphoma or malignant lymphoma). Mean survival is approximately 50% at 10 years after diagnosis. Survival rates reported among patients with cryoglobulinemic renal involvement varies from greater than 60% at 5 years of follow-up, up to 30% at 7 years of follow-up. Infection, cardiovascular disease and hepatic failue are amongst causes of morbidity. (Morra, 2010, Saadoun et al., 2010)

9. Conclusion

Mixed cryoglobulinemia represents a form of leukocytoclastic vasculitis, which is considered to be a relatively rare disorder. Given its clinical polymorphism, a correct diagnosis might be delayed in addition the actual prevalence of disease is probably underestimated. Establishing the diagnosis of HCV-MC requires careful patient evaluation, biopsy from involved sites is the gold standard for diagnosing leukocytoclastic vasculitis. Owing to its' complex etio-pathogenesis and clinical polymorphism, the treatment of mixed cryoglobulinemia and cryoglobulinemic vasculitis remains challenging. The initial therapeutic step must target hepatitis C viremia being the chronic trigger for sustained immune-stimulation and autoantibody production. The second therapeutic target is to control downstream B cell clonal expansion thereby controlling the autoimmune manifestations related to cryoglobulinemia

(cryoglobulinemic vasculitis), and management of neoplastic complications. The prognosis of the disease depends largely upon the extent and severity of organ involvement and adequate therapeutic intervention.

10. References

- [1] Agnello, V., Chung, R. T. and Kaplan, L. M. (1992) A role for hepatitis C virus infection in type II cryoglobulinemia. *N Engl J Med*, 1992; 327, 1490-5.
- [2] Agnello V. (1995) The aetiology of mixed cryoglobulinaemia associated with hepatitis C virus infection. *Scand J Immunol* 1995;42:179-84.
- [3] Alric L, Plaisier E, Thebault S, et al. (2004) Influence of antiviral therapy in hepatitis C virus-associated cryoglobulinemic MPGN. *Am J Kidney Dis* 2004;43:617-23.
- [4] Antonelli A, Ferri C, Fallahi P, et al. (2004, a) Thyroid involvement in patients with overt HCV-related mixed cryoglobulinaemia. *QJM* 2004, 97:499-506.
- [5] Antonelli A, Ferri C, Fallahi P, et al. (2004, b): Type 2 diabetes in hepatitis C-related mixed cryoglobulinaemia patients. *Rheumatology (Oxford)* 2004, 43:238-40.
- [6] Antonelli A, Ferri C, Ferrari S M, et al., (2009). Serum levels of proinflammatory cytokines interleukin-1 β , interleukin-6, and tumor necrosis factor α in mixed cryoglobulinemia. *Arthritis & Rheumatism*. December, 2009, Volume 60, Issue 12, pages 3841-3847.
- [7] Authier FJ, Bassez G, Payan C et al. (2003) Detection of genomic viral RNA in nerve and muscle of patients with HCV neuropathy. *Neurology* 2003; 60:808-12.
- [8] Basse G, Ribes D, Kamar N et al. (2005) Rituximab therapy for de novo mixed cryoglobulinemia in renal-transplant patients. *Transplantation*. 2005; 80, 1560-1564.
- [9] Cacoub P, Musset L, Amoura Z, et al. (1997) Anticardiolipin, anti-beta2- glycoprotein I, and antinucleosome antibodies in hepatitis C virus infection and mixed cryoglobulinemia. *Multivirc Group. J Rheumatol* 1997; 24: 2139-2144.
- [10] Cacoub P, Renou C, Rosenthal E, et al. (2000) Extrahepatic manifestations associated with hepatitis C virus infection. A prospective multicenter study of 321 patients. The GERMIVIC. *Groupe d'Etude et de Recherche en Medecine Interne et Maladies Infectieuses sur le Virus de l'Hepatite C. Medicine (Baltimore)*. 2000; 79: 47-56.
- [11] Cacoub P, Lidove O, Maisonobe T, et al. (2002) Interferon alpha and ribavirin treatment in patients with hepatitis C virus-related systemic vasculitis. *Arthritis Rheum* 2002;46:3317-26.b
- [12] Cacoub P, Saadoun D, Limal N, et al., (2005). PEGylated interferon alfa-2b and ribavirin treatment in patients with hepatitis C virus-related systemic vasculitis. *Arthritis Rheum*, 2005; 52:911-5.
- [13] Calleja JL, Albillos A, Moreno-Otero R et al. (1999) Sustained response to interferon- α or to interferon- α plus ribavirin in hepatitis C virus-associated symptomatic mixed cryoglobulinaemia. *Aliment. Pharmacol. Ther.* 13, 1179-1186 (1999).
- [14] Casato M, Saadoun D, Marchetti A et al. (2005) Central nervous system involvement in hepatitis C virus cryoglobulinemia vasculitis: a multicenter case-control study

- using magnetic resonance imaging and neuropsychological tests. *J Rheumatol.*, 2005; 32:484–8.
- [15] Costedoat-Chalumeau N, Cacoub P, Maisonobe T, et al. (2002) Renal microaneurysms in three cases of hepatitis C virus-related vasculitis. *Rheumatology* (2002) 41 (6): 708-710.
- [16] Curry MP, Golden-Mason L, Doherty DG et al. (2003) Expansion of innate CD5pos B cells expressing high levels of CD81 in hepatitis C virus infected liver. *J Hepatol* 2003; 38:642–50.
- [17] Dammacco F, Sansonno D. (1997) Mixed cryoglobulinemia as a model of systemic vasculitis. *Clin Rev Allergy Immunol* 1997; 15:97–119.
- [18] Davis G L. (2002) HEPATITIS C THERAPY: The Liver in Health and Disease. AMERICAN LIVER FOUNDATION, 2002. Medline.
- [19] Dawson TM and Starkebaum G. (1999) Isolated central nervous system vasculitis associated with hepatitis C infection. *J Rheumatol* 1999; 26:2273–6.
- [20] De Almeida AJ, Campos-de-Magalhães M, de Melo Marçal OP, et al. (2004) Hepatitis C virus associated thrombocytopenia: a controlled prospective, virological study. *Ann Hematol* 2004; 83: 434-440.
- [21] De Vita S, De Re V, Gasparotto D et al., (2000). Oligoclonal non-neoplastic B cell expansion is the key feature of type II mixed cryoglobulinemia: clinical and molecular findings do not support a bone marrow pathologic diagnosis of indolent B cell lymphoma. *Arthritis Rheum* 2000;43:94–102. Pipitone N and Salvarani C. (2006) Systemic Vasculitis: State of the Art and Emerging Concepts. *Curr Opin Rheumatol.* 2006;18(1):1-2.
- [22] De Vita S, De Re V, Sansonno D, et al. (2002) Lack of HCV infection in malignant cells refutes the hypothesis of a direct transforming action of the virus in the pathogenesis of HCV-associated B-cell NHLs. *Tumori.* 2002; 88:400–406.
- [23] Doffoel-Hantz V, Loustaud-Ratti V, Ramos-Casals M, et al. (2005) Evolution of Sjogren's syndrome associated with hepatitis C virus when hepatitis C is treated with interferon or the association of interferon and ribavirin. *Rev Med Interne* 2005; 26:88-94.
- [24] Doi T, Homma H, Mezawa S, et al. (2002) Mechanisms for increment of platelet associated IgG and platelet surface IgG and their implications in immune thrombocytopenia associated with chronic viral liver disease. *Hepatol Res* 2002; 24: 23.
- [25] Donada C, Crucitti A, Donadon V, et al. (1998) Interferon and ribavirin combination therapy in patients with chronic hepatitis C and mixed cryoglobulinemia. *Blood* 92, 2983-2984 (1998).
- [26] Elias N; Sabo E; Naschitz JE; et al. (1998) Colonic ulcers in a patient with hepatitis C virus-associated polyarteritis nodosa. *J Clin Gastroenterol.* 1998; 26(3):212-5.
- [27] Falk R J and Hoffman G S. (2007) Controversies in Small Vessel Vasculitis - Comparing the Rheumatology and Nephrology Views. *Curr Opin Rheumatol.* 2007;19(1):1-9.
- [28] Fellay J, Thompson A J, Ge D, et al., 2010. ITPA gene variants protect against anemia in patients treated for chronic hepatitis C. *Nature*, 2020;464:405-8.

- [29] Fabris M, Quartuccio L, Sacco S, et al. (2007) B-Lymphocyte stimulator (BLyS) up-regulation in mixed cryoglobulinaemia syndrome and hepatitis-C virus infection. *Rheumatology (Oxford)*. 2007; 46:37-43.
- [30] Ferri C. (2008) Mixed Cryoglobulinemia. *Orphanet Journal of Rare Diseases* 2008, 3:25. Review.
- [31] Ferri C, Pietrogrande M, Cecchetti C, et al., (1989). Low-antigen-content diet in the treatment of mixed cryoglobulinemia patients. *Am J Med*, 1989. 87: 519-24.
- [32] Ferri C, La civita L, Fazzi P et al. (1997) Interstitial lung fibrosis and rheumatic disorders in patients with hepatitis C infection. *Br J Rheumatol* 1997; 36:360-5.
- [33] Ferri C, Pileri S, Zignego AL. (2000) Hepatitis C virus, B-cell disorders, and non-Hodgkin's lymphoma. In *Infectious causes of cancer: targets for intervention*. National Cancer Institute (NIH) Edited by: Goedert JJ. Totowa, NJ: The Humana Press Inc; 2000:349-368.
- [34] Ferri C, Zignego AL, Pileri SA. (2002, a) Cryoglobulins (review). *J Clin Pathol*. 2002, 55:4-13.
- [35] Ferri C, Bertozzi MA, Zignego AL (2002, b) Erectile dysfunction and hepatitis C virus infection. *JAMA* 2002, 288:698-9.
- [36] Ferri C, Sebastiani M, Giuggioli D, et al. (2004) Zignego AL: Mixed cryoglobulinemia: demographic, clinical, and serological features, and survival in 231 patients. *Sem Arthritis Rheum* 2004, 33:355-74.
- [37] Ferri C and Mascia MT: (2006) Cryoglobulinemic vasculitis: Review. *Curr Opin Rheumatol* 2006, 18:54-63.
- [38] Fois E, Guimard Y, Sene D, et al. (2003) Rechute des vascularites systémiques liées au virus de l'hépatite C, sans rechute virologique: se méfier du lymphome. *Rev Med Interne* 2003; 24:93s.
- [39] Fontenot, J. D., Gavin, M. A. & Rudensky, A. Y. (2003) Foxp3 programs the development and function of CD4+CD25+ regulatory T cells. *Nat Immunol*. 2003, 4, 330-6.
- [40] Franciscus A. (2011) Hepatitis C Treatments in Current Clinical Development. *Hepatitis C. Hepatitis C Advocate*, Medline update, 5th april, 2011.
- [41] Garini G, Allegri L, Vaglio A, et al. (2005) Hepatitis C virus-related cryoglobulinemia and glomerulonephritis: pathogenesis and therapeutic strategies. *Ann Ital Med Int*. 2005; 20:71-80.
- [42] Ghany MG, Strader DB, Thomas DL, et al. (2009) Diagnosis, management, and treatment of hepatitis C: an update. *Hepatology*. 2009;49:1335-1374.
- [43] Giannini E, Borro P, Botta F, et al. (2002) Serum thrombopoietin levels are linked to liver function in untreated patients with hepatitis C virus-related chronic hepatitis. *J Hepatol* 2002; 37: 572-577.
- [44] Gross JA, Johnston J, Mudri S, et al. (2000). TACI and BCMA are receptors for a TNF homologue implicated in B-cell autoimmune disease. *Nature*. 2000 Apr 27;404(6781):995-9.
- [45] Guideline 5: Diagnosis and management of kidney diseases associated with HCV infection *Kidney International* (2008) 73 (Suppl 109), S69-S77.

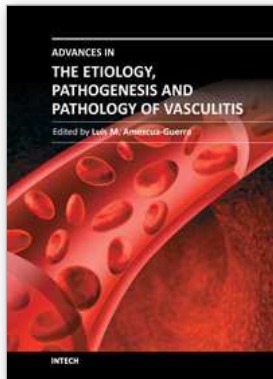
- [46] Hausfater P, Cacoub P, Assogba U, et al. (2002) Plasma exchange and interferon-alpha pharmacokinetics in patients with hepatitis C virus-associated systemic vasculitis. *Nephron*, 2002;91:627-3.
- [47] Heckmann JG, Kayser C, Heuss D, et al. (1992) Neurological manifestations of chronic hepatitis C. *J Neurol* 1999;246:486-91.
- [48] Iga D, Tomimatsu M, Endo H, et al. (2005) Improvement of thrombocytopenia with disappearance of HCV RNA in patients treated by interferon-alpha therapy: possible etiology of HCV-associated immune thrombocytopenia. *Eur J Haematol* 2005; 75: 417-423.
- [49] Jennette JC, Falk RJ, Andrassy K., et al (1994) Nomenclature of systemic vasculitides: The proposal of an international consensus conference. *Arthritis Rheum* 1994; 37:187-192.
- [50] Jiang XH, Xie YT, Tan DM. (2004) Study on the influencing factors of thrombocytopenia in viral hepatitis. *Zhonghua Ganzangbing Zazhi* 2004; 12: 734-736.
- [51] Kamar N, Rostaing L and Alric L. (2006) Treatment of hepatitis C-virus-related glomerulonephritis. *Kidney International* (2006) 69, 436-439.
- [52] Kaplanski G, Maisonneuve T, Marin V, et al. (2005) Vascular cell adhesion molecule-1 (VCAM-1) plays a central role in the pathogenesis of severe forms of vasculitis due to hepatitis C-associated mixed cryoglobulinemia. *J Hepatol* 2005, 42:334-340.
- [53] Kayali Z, Buckwold VE, Zimmermann B, et al. (2002) Hepatitis C, cryoglobulinemia, and cirrhosis: a metaanalysis. *Hepatology*. 2002; 36:978-985.
- [54] Khattab M, Eslam M, Allavian S M. (2010) Hepatitis C Virus as a Multifaceted Disease: A Simple and Updated Approach for Extrahepatic Manifestations of Hepatitis C Virus Infection. *Hepat Mon*. 2010; 10(4): 258-269.
- [55] Kittlesen, D. J., Chianese-Bullock K A, Yao Z Q, et al. (2000) Interaction between complement receptor gC1qR and hepatitis C virus core protein inhibits T-lymphocyte proliferation. *J. Clin. Invest.* 2000, 106:1239-1249.
- [56] Lamprecht P, Gutzeit O, Csernok E, et al. (2003) Prevalence of ANCA in mixed cryoglobulinemia and chronic hepatitis C virus infection. *Clin Exp Rheumatol* 2003; 21: S89-S94.
- [57] Leak LV, Petricoin EF 3rd, Jones M, et al. (2002) Proteomic technologies to study diseases of the lymphatic vascular system. *Ann N Y Acad Sci.* 2002, 979, 211-28; discussion 229-34.
- [58] Lee YH, Ji JD, Yeon JE, et al. (1998) Cryoglobulinaemia and rheumatic manifestations in patients with hepatitis C virus infection. *Ann Rheum Dis.* 1998;57:728-31.
- [59] Lenzi M, Frisoni M, Mantovani V, et al. (1998) Mixed Cryoglobulinemia Haplotype HLA-B8-DR3 Confers Susceptibility to Hepatitis C Virus-Related. *Blood*, 1998: 91: 2062-2066.
- [60] Leone N, Pellicano R, Ariata Maiocco I et al. (2002) Mixed cryoglobulinaemia and chronic hepatitis C virus infection: the rheumatic manifestations. *J Med Virol* 2002; 66:200-3.

- [61] Lidove O, Cacoub P, Hausfater P, et al. (1999) Cryoglobulinemia and hepatitis C: worsening of peripheral neuropathy after interferon alpha treatment. *Gastroenterol Clin Biol* 1999, 23:403-6.
- [62] Machida K, Cheng K T, Sung V M. et al. (2004) Hepatitis C virus induces a mutator phenotype: enhanced mutations of immunoglobulin and protooncogenes. *Proc Natl Acad Sci.*, 2004, 101, 4262-7.
- [63] Matsuo K, Kusano A, Sugumar A, et al. (2004) Effect of hepatitis C virus infection on the risk of non-Hodgkin's lymphoma: a meta-analysis of epidemiological studies. *Cancer Sci* 2004, 95:745-52.
- [64] Mazzaro C, Zorat F, Comar C et al. (2003) Interferon plus ribavirin in patients with hepatitis C virus positive mixed cryoglobulinemia resistant to interferon. *J. Rheumatol.* 30, 1775-1781 (2003).
- [65] Meltzer M, Franklin EC, Elias K, et al. (1996). Cryoglobulinemia--a clinical and laboratory study. II. Cryoglobulins with rheumatoid factor activity. *Am J Med.* Jun 1996; 40(6):837-56.
- [66] Mohammed R H A, ElMakhzangy H I, Gamal A, et al., (2010). Prevalence of rheumatologic manifestations of chronic hepatitis C virus infection among Egyptians. *Clin Rheumatol* (2010) 29:1373–1380.
- [67] Morra E. (2010) Cryoglobulinemia. American Society of Hematology, 2010. Medline.
- [68] Mukhtyar C, Guillevin L, Cid M C, et al. (2009) EULAR recommendations for the management of primary small and medium vessel vasculitis for the European Vasculitis Study Group. *Ann Rheum Dis.*, 2009; 68:310–317.
- [69] Napoli J, Bishop GA, McCaughan GW. (1994) Increased intrahepatic messenger RNA expression of interleukins 2, 6 and 8 in hepatic cirrhosis. *Gastroenterology.* 1994 Sep; 107(3):789-98.
- [70] National Digestive Diseases Information Clearing House. NIDDK, 2010 Chronic Hepatitis C: Current Disease Management. 2010, Medline.
- [71] Newkirk MM. (2002) Rheumatoid factors: host resistance or autoimmunity? *Clin Immunol* 2002; 104:1–32.
- [72] Okutan O, Kartaloglu Z, Ilvan A, et al. (2004) Evaluation of high-resolution computed tomography and pulmonary function tests in patients with chronic hepatitis C virus infection. *World J Gastroenterol* 2004;10(3):381-384.
- [73] Ordi-Ros J, Villarreal J, Monegal F, et al (2000) Anticardiolipin antibodies in patients with chronic hepatitis C virus infection: characterization in relation to antiphospholipid syndrome. *Clin Diagn Lab Immunol* 2000; 7:241-244.
- [74] Pawlotsky J-M. (2011) Hepatitis C Virus Drug Pipeline Overview and Clinical Trial Design. Chapter 7, in *Hepatitis C: Antiviral drugs discovery and development*. Edited by: Seng-Lai Tan and Yupeng He. April, 2011. Caister Academic Press.
- [75] Pereira P F, Lemos L B, Uehara S, et al. (2010) Long-term efficacy of rituximab in hepatitis C virus-associated cryoglobulinemia. *Rheumatol Int* (2010) 30:1515–1518.
- [76] Pileri P, Uematsu Y, Campagnoli S, et al., (1998). Binding of Hepatitis C virus to CD81. *Science.* 1998 Oct 30;282(5390):938-41.

- [77] Pipitone N and Salvarani C. (2006) Systemic Vasculitis: State of the Art and Emerging Concepts. *Curr Opin Rheumatol.* 2006;18(1):1-2.
- [78] Quartuccio L, Soardo G, Romano G, et al. (2006) Rituximab treatment for glomerulonephritis in HCV associated mixed cryoglobulinaemia: efficacy and safety in the absence of steroids. *Rheumatology (Oxford)*, 2006;45(7):45:842-846.
- [79] Racanelli V, Sansonno D, Piccoli C, et al., (2001). Molecular characterization of B cell clonal expansions in the liver of chronically hepatitis C virus-infected patients. *J Immunol.* 2001 Jul 1; 167(1):21-9.
- [80] Ramos-Casals M, García-Carrasco M, Cervera R, et al. (2001) Hepatitis c virus infection mimicking primary Sjogren's syndrome: a clinical and immunologic description of 35 cases. *Medicine (Baltimore)* 2001, 80:1-8.
- [81] Remoroza R and Bonkovsky H.(2003) Extrahepatic manifestations of chronic Hepatitis C. The HCV Advocate Medical Writer's circle, HCV support project; August, 2003. Medline.
- [82] Roccatello D, Baldovino S, Rossi D, et al. (2004) Longterm effects of anti-CD20 monoclonal antibody treatment of cryoglobulinaemic glomerulonephritis. *Nephrol Dial Transplant.* 2004;19(12):3054-3061.
- [83] Roccatello D, Baldovino S, Rossi D, et al., (2008). Rituximab as a therapeutic tool on severe mixed cryoglobulinemia. *Clin Rev Allergy Immunol.* 2008 Feb;34(1):111-7. Review.
- [84] Roncarolo MG, Bacchetta R, Bordignon C, et al. (2001) Type 1 regulatory T cells. *Immunol Rev.* 2001, 182, 68-79.
- [85] Saadoun D, Boyer O, Trebeden-Negre H, et al. (2004) Predominance of type 1 (Th1) cytokine production in the liver of patients with HCV-associated mixed cryoglobulinemia vasculitis. *J Hepatol.* 2004;41:1031-7.
- [86] Saadoun D, Bieche I, Maisonobe T et al. (2005) Involvement of chemokines and type 1 cytokines in the pathogenesis of hepatitis C virus-associated mixed cryoglobulinemia vasculitis neuropathy. *Arthritis Rheum* 2005; 52:2917-25.
- [87] Saadoun D, Landau D A, Calabrese L H et al. (2007) Hepatitis C-associated mixed cryoglobulinaemia: a crossroad between autoimmunity and lymphoproliferation. *Rheumatology* 2007; 46:1234-1242.
- [88] Saadoun D, Rosenzwajg M, Landau D, et al. (2008) Restoration of peripheral immune homeostasis after rituximab in mixed cryoglobulinemia vasculitis. *Blood.* 2008;111(11): 5334-5341.
- [89] Saadoun D, Terrier B, Semoun O, et al. (2010, a) HCV- associated polyarteritis nodosa. *Arthritis Care Res (Hoboken)*. Oct, 2010. [Epub ahead of print]
- [90] Saadoun D, Rigon M R, Sene D, et al. (2010) Rituximab plus Peg interferon-alpha/ribavirin compared with Peg interferon -alpha/ribavirin in hepatitis C related mixed cryoglobulinemia. *Blood*, 2010.116:326-334.
- [91] Sakaguchi, S. (2000) Regulatory T cells: key controllers of immunologic self-tolerance. *Cell.* 2000, 101, 455-8.

- [92] Sansonno D, De Re V, Lauletta G, et al. (2003) Monoclonal antibody treatment of mixed cryoglobulinemia resistant to interferon alpha with an anti-CD20. *Blood*. 2003; 101(10):3818-3826.
- [93] Sansonno D, Carbone A, De Re V and Dammacco F. (2007) Hepatitis C virus infection, cryoglobulinaemia, and beyond. *Rheumatology* 2007;46:572-578.
- [94] Sasso, E. H. (2000) The rheumatoid factor response in the etiology of mixed cryoglobulinemia associated with hepatitis virus infection. *Ann Med Interne*. 2000, 151, 30-40.
- [95] Sene D, Ghillani-Dalbin P, Limal N et al. (2006) Anti-cyclic citrullinated peptide antibodies in hepatitis C virus associated rheumatological manifestations and Sjogren's syndrome. *Ann Rheum Dis* 2006; 65:394-7.
- [96] Sene D, Limal N, Ghillani-Dalbin P, et al. (2007) Hepatitis C virus-associated B-cell proliferation—the role of serum B lymphocyte stimulator (BLyS/BAFF). *Rheumatology (Oxford)*. 2007; 46:65-69.
- [97] Stefanova-Petrova DV, Tzvetanska AH, Naumova EJ, et al. (2007) Chronic hepatitis C virus infection: prevalence of extrahepatic manifestations and its association with cryoglobulinemia in Bulgarian patients. *Viral hepatitis. World Journal of Gastroenterol*. 2007; 13(48):6518-6528.
- [98] Stein JV, López-Fraga M, Elustondo FA., et al. (2002) APRIL modulates B and T cell immunity. *J Clin Invest*. 2002; 109, 1587-98.
- [99] Stone J. (2009) Immune complex-mediated vasculitis. In Kelley's textbook of Rheumatology Eighth edition, Firestein G S, Budd R C, Harris E D, Mc Innes I B, Ruddy S and Sargent J S. 2009, p 1465-1473.
- [100] Suzuki R, Morita H, Komukai D, et al. (2003) Mixed Cryoglobulinemia Due to Chronic Hepatitis C with Severe Pulmonary Involvement. Case report, *Internal Medicine*. 2003; 42: 1210-1214.
- [101] Visentini M, Granata M, Veneziano ML et al. (2007) Efficacy of low-dose rituximab for mixed cryoglobulinemia. *Clin. Immunol*. 2007; 125, 30-33.
- [102] Wener MH, Hutchinson K, Morishima C, et al. (2004) Absence of antibodies to cyclic citrullinated peptide in sera of patients with hepatitis C virus infection and cryoglobulinemia. *Arthritis Rheum* 2004; 50:2305-8.
- [103] Wu YY, Hsu TC, Chen TY, et al. (2002) Proteinase 3 and dihydrolipoamide dehydrogenase (E3) are major autoantigens in hepatitis C virus (HCV) infection. *Clin Exp Immunol* 2002; 128: 347-352.
- [104] Yee LJ, Kelleher P, Goldin RD, et al. (2004) Antinuclear antibodies (ANA) in chronic hepatitis C virus infection: correlates of positivity and clinical relevance. *J Viral Hepat*. 2004; 11: 459-464.
- [105] Zaja F, De Vita S, Mazzaro C, et al. (2003,a) Efficacy and safety of rituximab in type II mixed cryoglobulinemia. *Blood*. 2003;101:3827-3834.
- [106] Zaja F, Vianelli N, Sperotto A, et al. (2003 b) Anti-CD20 therapy for chronic lymphocytic leukemia associated autoimmune diseases. *Leuk Lymphoma*. 2003;44(11):1951-1955.
- [107] Zignego A & Bréchet C. (1999) Extrahepatic manifestations of HCV infection: facts and controversies. *J. Hepatol*.1999; 31: 1152-1154.

- [108] Zignego AL, Ferri C, Giannelli F et al. Prevalence of bcl-2 rearrangement in patients with hepatitis C virus-related mixed cryoglobulinemia with or without B-cell lymphomas. *Ann Intern Med.* 2002; 137:571-580.
- [109] Zuckerman E, Keren D, Slobodin G et al. (2000) Treatment of refractory, symptomatic, hepatitis C virus related mixed cryoglobulinemia with ribavirin and interferon- α . *J. Rheumatol.* 27, 2172-2178 (2000).



Advances in the Etiology, Pathogenesis and Pathology of Vasculitis

Edited by Dr. Luis M Amezcua-Guerra

ISBN 978-953-307-651-5

Hard cover, 438 pages

Publisher InTech

Published online 17, October, 2011

Published in print edition October, 2011

This book represents the culmination of the efforts of a group of outstanding experts in vasculitis from all over the world, who have endeavored to devote their work to this book by keeping both the text and the accompanying figures and tables lucid and memorable. Here, you will find an amalgam between evidence-based medicine to one based on eminence, through an exciting combination of original contributions, structured reviews, overviews, state-of-the-art articles, and even the proposal of novel pathogenetic models of disease. The book contains contributions on the etiology and pathology of vasculitis, the potential role of endothelial cells and cytokines in vascular damage and repair as well as summaries of the latest information on several primary and secondary vasculitis syndromes. It also covers selected topics such as organ-specific vasculitic involvement and quality of life issues in vasculitis. The editor and each of the authors invite you to share this journey through one of the most exciting fields of the medicine, the world of Vasculitis.

How to reference

In order to correctly reference this scholarly work, feel free to copy and paste the following:

Reem H. A. Mohammed and Hesham I El-Makhzangy (2011). Hepatitis C Related Vasculitides, *Advances in the Etiology, Pathogenesis and Pathology of Vasculitis*, Dr. Luis M Amezcua-Guerra (Ed.), ISBN: 978-953-307-651-5, InTech, Available from: <http://www.intechopen.com/books/advances-in-the-etiology-pathogenesis-and-pathology-of-vasculitis/hepatitis-c-related-vasculitides>

INTECH

open science | open minds

InTech Europe

University Campus STeP Ri
Slavka Krautzeka 83/A
51000 Rijeka, Croatia
Phone: +385 (51) 770 447
Fax: +385 (51) 686 166
www.intechopen.com

InTech China

Unit 405, Office Block, Hotel Equatorial Shanghai
No.65, Yan An Road (West), Shanghai, 200040, China
中国上海市延安西路65号上海国际贵都大饭店办公楼405单元
Phone: +86-21-62489820
Fax: +86-21-62489821

© 2011 The Author(s). Licensee IntechOpen. This is an open access article distributed under the terms of the [Creative Commons Attribution 3.0 License](#), which permits unrestricted use, distribution, and reproduction in any medium, provided the original work is properly cited.