

Drug-Induced Vasculitis

Mislav Radić

*Department of Rheumatology and Clinical Immunology, University Hospital Split
Croatia*

1. Introduction

This chapter aims to draw attention to the features that distinguish drug-induced vasculitis from those of idiopathic autoimmune syndromes, first and foremost primary vasculitides. Development of a systemic drug-induced syndrome only develops in a minority of patients treated with a drug over a prolonged period of time, whereas cutaneous vasculitis occurs quite commonly. The most frequent symptoms at onset are arthralgia, myalgia and skin rash. Early withdrawal of the offending drug mostly leads to complete recovery while more advanced disease and late withdrawal of the drug may necessitate use of corticosteroid and/or immunosuppressive therapy. The recent discovery of anti-neutrophil cytoplasm antibodies (ANCA) in a large serological subset of drug-induced vasculitis caused by long-term antithyroid drug treatment has opened new avenues for differential diagnostics. Certain medications such as propylthiouracil can induce ANCA associated vasculitis. This chapter focuses on the data on causal drugs, possible pathogenesis, clinical description, diagnosis, treatment and prognosis of patients with drug-induced vasculitis. ANCA with specificity to more than one lysosomal antigen combined with presence of antibodies to histones and beta-2 glycoprotein 1 constitute a unique serological profile for drug-induced vasculitis.

The pathogenesis of drug-induced ANCA associated vasculitis might be multifactorial. The clinical manifestations are similar to those of primary ANCA associated vasculitis, but ANCA with multi-antigenicity may help to differentiate it from primary ANCA associated vasculitis. Rational use of laboratory marker profiles is likely to aid in distinguishing drug-induced from idiopathic syndromes. However, the use of ANCA and other autoantibodies as biomarkers of different phenotypes of drug-induced vasculitis is one of the focuses of this chapter.

To date, ANCA are important serological markers for certain small-vessel vasculitides, encompassing Wegener granulomatosis (WG), microscopic polyangiitis (MPA) and Churg-Strauss syndrome (CSS). By indirect immunofluorescence (IIF) technique, ANCAs are classified as a perinuclear pattern (P-ANCA) and a cytoplasmic pattern (C-ANCA). C-ANCA is caused almost exclusively by antibodies against proteinase 3 (PR3). In contrast, P-ANCA can be caused by antibodies reacting with a variety of different neutrophil granule constituents, including myeloperoxidase (MPO), lactoferrin, human leucocyte elastase (HLE) and others. Evidence is mounting that these specific antibodies are pathogenic in small-vessel vasculitis. However, the aetiology of ANCA associated vasculitis is largely unknown.

The diagnosis of drug-induced ANCA associated vasculitis is based on the temporal relationship between clinically evident vasculitis and administration of the offending drugs,

and excluding medical conditions that mimic vasculitis and other definable types of vasculitis. After the diagnosis of drug-induced ANCA associated vasculitis was made, the offending drugs should be withdrawn immediately, and appropriate immunosuppressive therapy should be administered only for patients with vital organ involvement. The duration of immunosuppressive therapy should be much shorter than that in primary ANCA associated vasculitis and long-term maintenance therapy might not be necessary. The prognosis of patients with drug-induced ANCA associated vasculitis is good as long as the offending drug is discontinued in time.

This chapter summarizes the causal drugs, possible pathogenesis, clinical description, diagnosis, treatment and prognosis of drug-induced ANCA associated vasculitis.

2. Drug-induced vasculitis

Drug-induced vasculitis usually attacks the skin and sometimes the subcutaneous part of the skin, but sometimes also the kidneys and the lungs. Clinical symptoms include arthralgias and myalgias but usually do not develop into overt arthritis or myositis, manifested as muscle weakness. End-stage kidney disease due to glomerular vasculitis may occur, but early removal of the offending drug most often leads to resolution of the glomerular inflammation. A few cases of drug-induced vasculitis presenting with a hemorrhagic syndrome due to lung capillaritis have been reported. Drug-induced vasculitis patients typically harbor ANCA directed to one or more neutrophil cytoplasm antigens, the most common antigens being the granule proteins MPO, HLE, cathepsin G, and lactoferrin. In one study from Boston (Choi, 2000), the levels of MPO-ANCA were found to be much higher in 30 patients with drug-induced MPO-ANCA vasculitis than those usually found in idiopathic vasculitides, and there was a strong association between presence of HLE-ANCA and lactoferrin-ANCA and exposure to the candidate drugs. A study from Denmark showed a strong association between heredity and development of drug-induced vasculitis during treatment with propylthiouracil in monozygotic triplets with Graves' disease. Two of these children that were treated with propylthiouracil got multispecific ANCA including HLE-ANCA, while the third triplet had no signs of drug-induced vasculitis and no ANCA during treatment with carbimazole.

To date, many studies have indicated that drug-induced vasculitis may be a complication of therapy with prior use of certain medications in some patients, and unreported and/or undiagnosed cases may be beyond our imagination. As shown in Table 1, the most often implicated drug in the published work is propylthiouracil, which may result from more frequent prescriptions in clinical practice. Clear evidence for an association with the development of drug-induced vasculitis has also been shown for the following drugs: hydralazine, anti-tumour necrosis factor- α (TNF- α) agents, sulfasalazine, D-penicillamine and minocycline, however, most of them were limited to case reports. Propylthiouracil is a common anti-thyroid drug widely used all over the world. In the published work, over a hundred cases of propylthiouracil-induced vasculitis have been reported. Further studies in pathogenesis, treatment and long-term outcomes of patients with propylthiouracil induced vasculitis provide useful information on understanding drug-induced vasculitis. It has been shown that propylthiouracil is implicated in 80-90% cases of vasculitis induced by anti-thyroid drugs, while cases related to others are less frequent such as methimazole, carbimazole and benzylthiouracil. The increasing use of so-called 'biologic' agents in medical practice has been accompanied by growing evidence on the toxicity profile of these

agents, including drug-induced vasculitis. Anti-TNF- α drugs, such as adalimumab, infliximab and etanercept, are now established therapy in the management of rheumatoid arthritis and several other chronic inflammatory diseases. Repeated treatment with these agents can lead to the development of autoantibodies, including antinuclear antibodies (ANA), anti-dsDNA and anti-cardiolipin antibodies, in up to 10% of patients. The autoantibody synthesis is associated with a greater cumulative dose of therapy. Although uncommon, some patients receiving anti-TNF- α agents were found to develop vasculitis. Minocycline, a semi-synthetic lipophilic tetracycline, is the favoured antibiotic for the treatment of acne and rheumatic diseases. The use of minocycline over the past decade has led to numerous reports on drug-induced lupus. Interestingly, the laboratory features of minocycline-induced lupus include positive ANA and frequently positive p-ANCA (>67% of cases). In Marzo-Ortega's study, 7% of the minocycline-treated patients at some point in the past became ANCA positive, however, only a few cases indicated the occurrence of drug-induced vasculitis. Because there seems to be a wide serological overlap between drug-induced lupus and drug-induced vasculitis, it may be difficult to discriminate between the two categories. Also, it might raise suspicion that some patients may actually contract drug-induced vasculitis rather than drug-induced lupus. In addition, there are a few published reports indicating the association between treatment with other drugs and the occurrence of vasculitis, including allopurinol, cephalexin, clozapine, levamisole, phenytoin and thioridazine. However, the causative relationship is much less certain. Leukotriene antagonists (LTA, such as montelukast and zafirlukast) have been implicated in the pathogenesis of CSS. Further studies showed that no significant association was observed between CSS and LTA after controlling for the use of other anti-asthma drugs. In a case-crossover study, it was suggested that the onset of CSS might be not associated with montelukast but a phenomenon possibly associated with a group of medications prescribed for long term control of severe asthma. Based on this evidence, the National Institutes of Health/US Food and Drug Administration panel concluded that no one class of LTA was associated with CSS and that LTA are safe. A possible clue to distinguish the patients with early CSS from those with idiopathic asthma is that the former patients tend to have severe upper airway disease, especially sinusitis, with radiographs showing paranasal abnormalities.

2.1 Epidemiology

There are no clear data on the prevalence of drug-induced vasculitis due to lack of prospective studies. Several cross-sectional studies reported that the prevalence of propylthiouracil induced vasculitis ranged from 20% to 64%. In some other study (Gao, 2004), ANCA was detected in 22.6% of patients treated with propylthiouracil, but only 6.5% patients had clinical evidence of drug-induced vasculitis. In Slot's study (Slot, 2005); ANCA and drug-induced vasculitis were present in 11% and 4% of patients treated with anti-thyroid drugs, respectively. However, in Choi's study (Choi, 2000), no patient in any of the active study drug groups (minocycline, for a 48-week trial; sulfasalazine, for a 37-week trial; penicillamine, for a 104-week trial) demonstrated ANCA seroconversion. Some researchers speculated that it might be due to a short observation period, and the prevalence of positive ANCA might be higher in patients with much long-standing therapy. Prospective, longitudinal studies with a larger cohort of patients are needed to establish the true prevalence of drug-induced vasculitis.

2.2 Pathogenesis

A variety of agents may produce a typical clinical picture together with a similar autoimmune profile, suggesting a common mechanism for drug-induced vasculitis. To date, the mechanism is far from fully understood and it might be multifactorial.

- Most drugs are low-molecular-weight substances, and require the formation of a complex to stimulate antibody formation and then to drive an immune response. One hypothesis (Jiang, 1994) proposed that activated neutrophils in the presence of hydrogen peroxidase released MPO from their granules, which converted the offending drugs such as prophythiouracil and hydralazine into cytotoxic products, then the drugs and their metabolites were immunogenic for T cells, which in turn activated B cells to produce ANCA.
- The offending drugs and their metabolites may accumulate within neutrophils, bind to MPO and modify its configuration, with subsequent intermolecular determinant spreading the autoimmune response to other autoantigens and turning neutrophil proteins (including elastase, lactoferrin and nuclear antigens) immunogenic.
- Some drugs like sulfasalazine could induce neutrophil apoptosis. Moreover, neutrophil apoptosis, in the absence of priming, is associated with translocation of ANCA antigens to the cell surface, which then induce the production of ANCA, and ANCA in turn is able to bind the membrane-bound antigens, causing a self-perpetuating constitutive activation by cross-linking PR3 or MPO and Fcγ receptors.

The oxidation activity of MPO could be inhibited by prophythiouracil and prophythiouracil-induced MPO-ANCA in a dose-dependent manner, which might also be involved in the pathogenesis of drug-induced vasculitis. The cytotoxic products of the offending drug, ANCA as well as cytotoxic neutral serine proteinases, degranulated from the activated neutrophils, could directly cause vascular damage. In other cases, the causal drugs (e.g. anti-TNF- α agents) may act as modulators of the normal immune system, rendering it permissive for self-directed responses. Rheumatoid arthritis is generally considered as a T-helper cell (Th) 1-mediated disease and TNF- α plays an important role in driving Th1-associated responses. Other forms of autoimmunity, for example, systemic lupus erythematosus and vasculitis (especially CSS and MPA), are characterized by a Th2 cytokine profile with prominent B-cell activation. Therefore, anti-TNF- α agents, administered in patients with rheumatoid arthritis, may shift the immune system from a Th1 to a Th2 profile thus upregulating antibody production. Alternatively, an increase in clinical or subclinical bacterial infections in the setting of TNF- α blockade might act as an immunostimulant and enable autoantibody production by inducing polyclonal B-cell activation. It is also speculated that drug-induced vasculitis might be genetic factors linked, because four out of six patients with minocycline-induced P-ANCA had human leucocyte antigen (HLA) DRB1*1104. The major histocompatibility complex (MHC) class II background may indicate that autoantibody production in these patients is driven by a genetically restricted T-cell response to epitopes from native or drug-modified MPO. Indeed, the ability of exogenous agents to induce vasculitis may be an opportunity, as a greater understanding of drug induced vasculitis is likely to provide insight into the nature of primary autoimmunity.

Several studies have demonstrated that the majority of patients with drug-induced ANCA were free from clinically evident vasculitis. These conditions provide a natural platform for the study of idiopathic autoimmune disease. The autoantibody response is pathogenic will depend on many factors including the characteristics of the autoantibodies such as epitope

specificity, avidity, subclass and idiotype. A series of studies on prophythiouracil-induced vasculitis has demonstrated the following.

Antibiotics

Cephotaxime
Minocycline
Anti-thyroid drugs
Benzylthiouracil
Carbimazole
Methimazole
Prophythiouracil

Anti-tumor necrosis factor- α agents

Adalimumab
Etanercept
Infliximab

Psychoactive agents

Clozapine
Thioridazine

Miscellaneous drugs

Allopurinol
D-Penicillamine
Hydralazine
Levamisole
Phenytoin
Sulfasalazine

Table 1. Medications associated with drug-induced vasculitis

- Almost all the patients with overt clinical vasculitis had MPO-ANCA or PR3-ANCA, which indicated that anti-MPO and anti-PR3 antibodies, just like those in primary ANCA associated vasculitis, might also be associated with the occurrence of clinically active vasculitis induced by drugs.
- A higher MPO-ANCA level, over a threshold, might be necessary to induce clinically evident vasculitis.
- Patients with prophythiouracil-induced vasculitis tended to have higher titres and higher avidity of MPO-ANCA than those with prophythiouracil induced anti-MPO antibodies but without clinical vasculitis.
- Most patients with prophythiouracil-induced ANCA but without clinical vasculitis had polyclonal MPO-ANCA recognizing both linear and conformational epitopes of the heavy chain of MPO; however, some patients with nephritis had MPO-ANCA

recognizing only the linear sites. They supposed that this clonality of MPO-ANCA might be a risk factor to induce clinical vasculitis.

- Anti-endothelial cell antibodies (AECA) are implicated in the pathogenesis of vascular injury. It was found that the majority (10/11) of patients with active prophythiouracil-induced vasculitis had serum AECA and their serum AECA disappeared quickly in remission; more importantly, patients with prophythiouracil induced ANCA but without clinical vasculitis did not have AECA. These findings indicated that AECA indeed might play an important role in the pathogenesis of drug-induced vasculitis.

The studies on immunological characteristics of drug induced ANCA might provide useful information on the pathogenetic role of ANCA in primary vasculitis. Some studies have shown that although serum ANCA in patients with primary ANCA associated vasculitis usually recognized only one target antigen, either MPO or PR3, antibodies against multiple ANCA antigens, especially the antigens other than MPO and PR3, might be the characteristic of drug-induced ANCA. Compared with immunological characteristics of anti-MPO antibodies in sera from patients with primary ANCA associated vasculitis, prophythiouracil-induced anti-MPO antibodies usually had a higher titre but lower avidity. MPO-ANCA from patients with prophythiouracil-induced ANCA associated vasculitis might recognize more restricted epitopes of MPO, although the epitopes were overlapping between the two groups. In a study of ANCA immunoglobulin (Ig)G subclass distribution, the anti-MPO IgG3 subclass, which has a potent complement-activation capacity and a firmly binding ability to Fc receptors on mononuclear cells, was not detectable in sera from patients with prophythiouracil-induced vasculitis. Furthermore, the levels of IgG4 subclass of MPO-ANCA decreased dramatically after cessation of prophythiouracil, in contrast to primary ANCA associated vasculitis, and this indicated that the production of prophythiouracil-induced MPO-ANCA might be a result of chronic antigen (prophythiouracil) stimulation. The above studies provide substantial evidence that the mechanisms of ANCA production might be different between prophythiouracil-induced vasculitis and primary ANCA associated vasculitis.

2.3 Clinical manifestations

The clinical manifestations of drug-induced vasculitis are similar to those of primary vasculitides, which range from less specific syndromes (fever, malaise, arthralgia, myalgia, weight loss) to single tissue or organ involvement and life-threatening vasculitis. Some researchers suggested that more severe specific organ involvement might develop in patients with non-specific systemic syndrome when the casual drug was not withdrawn in time. The clinical characteristics of drug-induced vasculitis are more likely in the category of MPA and isolated glomerulonephritis (GN) in the published work. Kidney is the most common involved organ and the renal features vary widely, including haematuria, proteinuria and elevated serum creatinine. Intra-alveolar hemorrhage is the most commonly reported pulmonary manifestation with consequent cough, dyspnea and haemoptysis. Some patients may only have lung involvement such as acute respiratory distress syndrome and interstitial pneumonia and without renal injury. Contrary to idiopathic vasculitides, drug-induced vasculitis usually has a milder course, and fewer patients have rapidly progressive GN in drug-induced vasculitis. Rare clinical manifestations were also described in case reports such as sensorineural hearing loss, pericarditis, pyoderma gangrenosum, central nervous system vasculitis presenting as cognitive symptoms and cerebral pachyleptomeningitis.

2.4 Laboratory and histopathology findings

There is no unique clinically pathological or laboratory marker for discrimination between drug-induced vasculitis and other vasculitides. The laboratory abnormalities could indicate organ involvement. Anemia is common in patients with drug-induced vasculitis. Urine abnormalities have consisted of haematuria and proteinuria in patients with kidney vasculitis. Accurate assessment of disease activity within the lungs may be difficult because disease activity correlates poorly with pulmonary symptoms. A plain chest radiograph is a tool to monitor disease activity and high-resolution computed tomography (CT) scanning of the chest offers a more sensitive imaging technique. Although acute-phase reactants such as erythrocyte sedimentation rate (ESR) or C-reactive protein (CRP) are usually elevated in patients with drug-induced vasculitis on diagnosis, they are neither sufficiently sensitive nor specific in making the diagnosis. In some studies, ESR, which was associated with the Birmingham Vasculitis Activity Score, might be a better indicator for disease activity than the titres of ANCA. Laboratory markers, including selected autoimmune serological findings such as ANA, anti-dsDNA and rheumatoid factor among others are commonly used for excluding other diseases or diagnosing other types of vasculitides.

Because detection of ANCA might serve as a warning of the possibility of drug-induced vasculitis, ANCA assays using combined IIF and antigen-specific enzyme-linked immunosorbent assays (ELISA) rather than relying on either test alone are recommended in all patients suspected of drug-induced vasculitis. Detection of IgG ANCA is a routine laboratory test, and the presence of high titre IgM MPO-ANCA has also been noted in some cases. Eighty to ninety percent of cases are positive for P-ANCA, and almost all the patients with drug-induced vasculitis had antibodies to MPO rather than PR3. It has been shown that autoantibodies against multiple ANCA antigens might be the characteristic of drug-induced ANCA. Merely ANCA directed to other specific target antigens such as lactoferrin and HLE among others (except MPO and PR3), were found in rare cases. ANCA was also detected in bronchoalveolar lavage fluid (BALF) from a patient with drug-induced interstitial pneumonia. Although ANCA is an important serological marker for certain small-vessel vasculitides, it might not be suitable for monitoring the disease activity of drug-induced vasculitis. After discontinuation of the offending drug, even after immunosuppressive therapy, serum ANCA may still remain positive in remission in the majority of patients with drug-induced vasculitis for up to 5 years, and an increasing of ANCA titres may also occur without overt clinical relapse. Some studies showed that although the levels of MPO-ANCA decreased slowly, other immunological characteristics of MPO-ANCA might change substantially. For example, the avidity of MPO-ANCA could decrease rapidly after withdrawal of medication, indicating that the avidity of anti-MPO antibodies might be a more sensitive serological biomarker to monitor disease activity.

Tissue biopsy is usually necessary to provide a definitive diagnosis of vasculitis and to exclude other diseases. Specimens may come from skin lesions, renal and lung biopsies. Skin lesions are characterized by leucocytoclasia and fibrinoid necrosis of the blood vessels. The renal biopsy is recommended in patients with kidney vasculitis in order to reveal the disease severity and to guide treatment. Typical pauci-immune necrotizing crescentic GN could be identified in patients with drug-induced vasculitis, but not necessarily. Interestingly, it was reported that three out of 14 and seven out of 10 patients with prophythiouracil-induced vasculitis had immune complex GN in renal biopsy. Bronchoscopic examination and bronchoalveolar lavage (BAL) can be useful in patients with

lung involvement. BAL typically shows neutrophilic alveolitis. Haemosiderin-laden macrophages may be found in BAL..

2.5 Risk for drug-induced vasculitis

In contrast to primary ANCA associated vasculitis, which occurs more often in the elderly, the demographic characteristics of patients with drug-induced vasculitis may reflect the features of the underlying diseases. For example, patients with drug-induced vasculitis are younger and predominantly female, which might merely be a reflection of the greater prevalence of thyroid disease in young women. Furthermore, a preponderance of reported cases are from countries in Europe and Asia where the medical community, in sharp contrast to that in the USA, preferentially manages hyperthyroid states with thionamides rather than with radioactive iodine. Long-standing therapy using the offending drug might be a risk factor for developing clinically evident vasculitis. *In vitro*, some studies confirmed that in contrast to short-term treatment with the parent drugs, long-term therapy, which allowed for more extensive generation of the reactive intermediates, resulted in sensitization of T cells to the intermediates. Because the risk of drug-induced lupus was increasing in patients receiving a higher cumulative dose of minocycline and hydralazine, similar results might exist in drug-induced vasculitis; however, there is no data on the cumulative threshold dose of the causal drugs in drug-induced vasculitis.

2.6 How to make a proper diagnosis

Because primary ANCA associated vasculitis is associated with high morbidity and mortality, as well as potentially life-threatening toxicity from immunosuppressive therapy, identification of potentially reversible causes of specific drugs is very important. Failure to recognize the offending drug can lead to fatal organ damage. However, the diagnosis of drug-induced vasculitis is complicated and difficult for several reasons, including: (a) physicians often do not recognize the syndrome as drug-induced (inappropriate diagnosis); (b) variable and often prolonged duration between the commencement of therapy and initial vasculitic symptoms; and (c) failure to evaluate appropriate laboratory and invasive tests. The awareness of drug-induced vasculitis by physicians is important in order to make prompt diagnosis and treatment and thus achieving favorable outcomes. It is essential that a comprehensive drug history should be obtained in patients with vasculitis. Clinicians should seek information on drug use for at least 6 months before presentation. The evaluation of pertinent laboratory data and prompt histological confirmation of the disease may aid in the diagnosis. Biopsies are strongly encouraged to confirm the presence of vasculitis³ and to determine the disease severity. Patients with drug-induced vasculitis should fulfilled the 1994 Chapel Hill Consensus Conference definition for ANCA associated vasculitis. We suggest that drug-induced vasculitis should be defined further by the following: (a) the signs and symptoms of vasculitis are temporally related to using the offending drug, and regressed with its discontinuation; (b) serum ANCA is positive, especially those with multi-antigenicity; and (c) medical conditions that mimic vasculitis are excluded, especially infections and malignancies, and other definable types of vasculitis. A low percentage of patients treated long term with a drug risk developing hypersensitivity reactions, some of which appear as vasculitis. There are laboratory markers that can help distinguish drug induced vasculitis from idiopathic autoimmune diseases, and thorough knowledge about such serological changes may help to differentiate drug-induced from idiopathic syndromes (summarized in Table 2).

	Drug-induced vasculitis	SLE	AAV
Antihistone abs.	Can be seen	Rare	Absent
AntidsDNA abs.	Absent	Common	Absent
ANCA	Common ^a	Rare	Common ^b
Antiphospholipid abs.	Common	Common	Rare
Immune complexes	Rare	Common	Absent

SLE, systemic lupus erythematosus; AAV, anti-neutrophil cytoplasmic antibodies-associated vasculitis.

^a Multispecific.

^b Single ANCA specificity.

Table 2. Laboratory marker differences between drug-induced vasculitis and idiopathic systemic lupus erythematosus and ANCA associated vasculitis

2.7 Treatment

There is no standard approach to the treatment of drug induced vasculitis. Because the pathogenesis is different between primary and drug-induced vasculitis, the cornerstone of treatment for primary ANCA associated vasculitis, including induction therapy and maintenance therapy with combined corticosteroid and cyclophosphamide, might not be suitable for patients with drug-induced vasculitis. Treatment should be based on individualized assessment in patients with drug-induced vasculitis. Because the offending drugs are involved in the pathogenesis, cessation of the casual drug immediately after diagnosis is essential and might be enough for those with limited to general systemic symptoms. In some case reports, organ involvement such as renal and pulmonary vasculitis could resolve only after discontinuation of the casual drug. However, in another case report, vasculitis worsened in the next 5 months after withdrawal of medication. Furthermore, in the published work it was reported that at least seven patients had died of prophythiouracil-induced vasculitis in spite of intensive immunosuppressive therapy. Therefore, treatment for patients with organ involvement should depend on the severity of clinical manifestations and histopathological lesions. For patients with severe and active organ involvement, intensive immunosuppressive therapy such as corticosteroid and/or immunosuppressive agents could improve organ function and prevent progression to severe, irreversible disease. As shown in Table 3, prednisone should be administered at 1 mg/kg per day for the first 4–8 weeks, followed by a gradual tapering within 6–12 months. Cyclophosphamide (0.6–1.0 g/ month i.v., or 1–2 mg/kg per day p.o.) or mycophenolate mofetil (1.5–2.0 g/day) could be administered for 6–12 months. In addition, patients with severe necrotizing crescentic GN and diffuse pulmonary alveolar hemorrhage should receive pulse methylprednisolone (7–15 mg/kg per day) for 3 days, and patients with life-threatening massive pulmonary hemorrhage may respond to plasmapheresis. It is well accepted that treatment for patients with primary ANCA associated vasculitis comprised both induction and maintenance therapy. However, for patients with drug-induced vasculitis, the duration of immunosuppressive therapy is still inconclusive. The duration of immunosuppressive therapy in patients with drug-induced vasculitis could be much shorter

than that in primary ANCA associated vasculitis and that as long as the offending drug was withdrawn, maintenance therapy might not be necessary. Although ANCA detection may provide a clue to the diagnosis of drug-induced vasculitis, positive seroconversion alone may not be a sufficient reason to discontinue the offending drug, because only a small proportion of the patients with positive ANCA will actually develop clinically evident vasculitis. Physicians should carefully monitor those with drug-induced ANCA but without clinical vasculitis. Resolution of most symptoms has generally occurred within 1–4 weeks except for severe organ involvement. Nonspecific symptoms may resolve dramatically only after cessation of the casual drug. However complete resolution of vasculitis occurred in most of the reported cases, some patients do have persistent laboratory abnormalities (elevated serum creatinine, proteinuria) throughout a long-term follow up. As we mentioned before, if necrotizing crescentic GN was present, the patients were at high risk of developing chronic renal failure.

Management of causal agents

Withdrawal

Avoid re-challenges

Consider avoiding similar drug classes

Individualized therapy

Non-specific symptoms

Withdrawal of causal agents alone

Organ involvement

Corticosteroid and/or immunosuppressive drugs

Severe organ involvement (e.g. necrotizing glomerulonephritis, focal segmental necrotizing glomerulonephritis, diffuse alveolar hemorrhage)

Methylprednisolone pulse therapy, followed by combined corticosteroid and immunosuppressive drugs

Massive pulmonary hemorrhage

Plasmapheresis

Special notes for patients with drug-induced vasculitis

A shorter course of immunosuppressive therapy

Long-term maintenance may not be necessary

Monitoring of serum ANCA

Surveillance for emergence of a chronic underlying vasculitis

AAV, anti-neutrophil cytoplasmic antibodies-associated vasculitis; ANCA, anti-neutrophil cytoplasmic antibodies.

Table 3. Treatment strategy for patients with drug-induced vasculitis

3. Conclusion

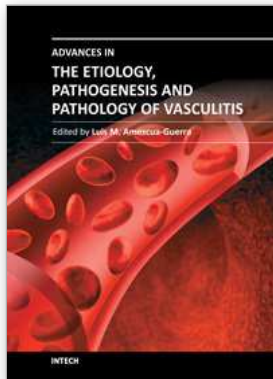
The clinician needs to be aware of this risk and quickly stop the offending drug therapy if signs of drug-induced vasculitis develop. In conclusion, patients undergoing treatments with the drugs able to induce vasculitis should be monitored closely during long-term therapy. ANCA is a useful tool to diagnose discontinued immediately after diagnosis. Appropriate immunosuppressive therapy should be administered only for patients with vital organ involvement in order to prevent progression to severe, irreversible disease. The duration of immunosuppressive therapy should be much shorter than that of primary ANCA associated vasculitis and long-term maintenance therapy might not be necessary. Identification of predisposing factors to drug-induced vasculitis may provide insight into the pathogenesis of primary vasculitis. Finally the recommendations for clinicians are:

- Avoid use of the drugs able to induce drug-induced vasculitis in the long term, and patients using long-term treatment with these drugs should be monitored carefully.
- Discontinue the offending drug immediately upon diagnosis of drug-induced vasculitis.
- Individualized immunosuppressive therapy should be initiated according to the severity of organ involvement.
- Adequate documentation of the potentially serious drug-induced reaction in patients' medical records is necessary to avoid re-challenge.

4. References

- Doyle, MK.; Cuellar, ML. (2003). Drug-induced vasculitis. *Expert Opin Drug Saf*, Vol.2, No.4, (July 2003), pp. 401-409, ISSN 1474-0338.
- Merkel, PA. (2001). Drug-induced vasculitis. *Rheum Dis Clin North Am*, Vol.27, No.4, (November 2001), pp. 849-862, ISSN 1558-3163.
- Choi, HK.; Slot, MC.; Pan, G.; Weissbach, CA.; Niles, JL.; Merkel, PA. (2000) Evaluation of antineutrophil cytoplasmic antibody seroconversion induced by minocycline, sulfasalazine, or penicillamine. *Arthritis Rheum*, Vol.43, No.2, (February 2000), pp. 2488-92, ISSN 0004-3591.
- Gao, Y.; Zhao, MH.; Guo, XH.; Xin, G.; Gao, Y.; Wang, HY. (2004) The prevalence and target antigens of anti-thyroid drugs induced antineutrophil cytoplasmic antibodies (ANCA) in Chinese patients with hyperthyroidism. *Endoc Res*, Vol.30, No.2, (May 2004), pp. 205-13, ISSN 1532-4206.
- Slot, MC.; Links, TP.; Stegeman, CA.; Tervaert, JW. (2005). Occurrence of antineutrophil cytoplasmic antibodies and associated vasculitis in patients with hyperthyroidism treated with anti-thyroid drugs: A long-term follow-up study. *Arthritis Rheum*, Vol.53, No.1, (February 2005), pp. 108-13, ISSN 0004-3591
- Jiang, X.; Khursigara, G.; Rubin, RL. (1994). Transformation of lupusinducing drugs to cytotoxic products by activated neutrophils. *Science*, Vol.266, No.5186, (November 1994), pp. 810-13, ISSN 1095-9203.

von Schmiedeberg, S.; Goebel, C.; Gleichmann, E.; Uetrecht J. (1995). Neutrophils and drug metabolism. *Science*, Vol.268, No.5210, (April 1995), pp. 585-6, ISSN 1095-9203.



Advances in the Etiology, Pathogenesis and Pathology of Vasculitis

Edited by Dr. Luis M Amezcua-Guerra

ISBN 978-953-307-651-5

Hard cover, 438 pages

Publisher InTech

Published online 17, October, 2011

Published in print edition October, 2011

This book represents the culmination of the efforts of a group of outstanding experts in vasculitis from all over the world, who have endeavored to devote their work to this book by keeping both the text and the accompanying figures and tables lucid and memorable. Here, you will find an amalgam between evidence-based medicine to one based on eminence, through an exciting combination of original contributions, structured reviews, overviews, state-of the-art articles, and even the proposal of novel pathogenetic models of disease. The book contains contributions on the etiology and pathology of vasculitis, the potential role of endothelial cells and cytokines in vascular damage and repair as well as summaries of the latest information on several primary and secondary vasculitis syndromes. It also covers selected topics such as organ-specific vasculitic involvement and quality of life issues in vasculitis. The editor and each of the authors invite you to share this journey through one of the most exciting fields of the medicine, the world of Vasculitis.

How to reference

In order to correctly reference this scholarly work, feel free to copy and paste the following:

Mislav Radić (2011). Drug-Induced Vasculitis, *Advances in the Etiology, Pathogenesis and Pathology of Vasculitis*, Dr. Luis M Amezcua-Guerra (Ed.), ISBN: 978-953-307-651-5, InTech, Available from: <http://www.intechopen.com/books/advances-in-the-etiology-pathogenesis-and-pathology-of-vasculitis/drug-induced-vasculitis>

INTECH
open science | open minds

InTech Europe

University Campus STeP Ri
Slavka Krautzeka 83/A
51000 Rijeka, Croatia
Phone: +385 (51) 770 447
Fax: +385 (51) 686 166
www.intechopen.com

InTech China

Unit 405, Office Block, Hotel Equatorial Shanghai
No.65, Yan An Road (West), Shanghai, 200040, China
中国上海市延安西路65号上海国际贵都大饭店办公楼405单元
Phone: +86-21-62489820
Fax: +86-21-62489821

© 2011 The Author(s). Licensee IntechOpen. This is an open access article distributed under the terms of the [Creative Commons Attribution 3.0 License](#), which permits unrestricted use, distribution, and reproduction in any medium, provided the original work is properly cited.