

# Tumour Angiogenesis in Rectal Cancer- Computer-Assisted Endosonographic and Immunohistochemical Methods for Assessment

Tankova Ludmila<sup>1</sup>, Daniel Kovatchki<sup>2</sup>, Georgi Stoilov<sup>3</sup>,  
Antonina Gegova<sup>4</sup> and Ivan Terziev<sup>5</sup>

<sup>1</sup>*Clinical Centre of Gastroenterology,*

*Clinic of Gastroenterology, University Hospital „Queen Joanna”, Sofia*

<sup>2</sup>*Golden Cross Private Clinic, Vienna*

<sup>3</sup>*Institute of Mechanics, Bulgarian Academy of Sciences, Sofia*

<sup>4</sup>*Department of Pathology, Medical Faculty, University „Kliment Ohridski”, Sofia*

<sup>5</sup>*Department of Pathology, University Hospital „Queen Joanna”, Sofia*

<sup>1,3,4,5</sup>*Bulgaria*

<sup>2</sup>*Austria*

## 1. Introduction

Angiogenesis is an essential process in tumour growth, invasion, metastasis and recurrence. The conventional way of quantifying angiogenesis requires a biopsy or tissue specimens applying specific immunohistochemical or molecular biological tests. The evaluation of the microvessel density is a gold standard in the assessment of the tumour neovascularisation. The determination of the vascular endothelial growth factor (VEGF) expression of the tumour sections is an alternative method of estimating the angiogenic activity of the tumour. Doppler ultrasound is an attractive modality for imaging angiogenesis in vivo which can be repeated without exposing the patient to any risk (Chen et al., 2002; Ogura et al., 2001; Yang et al., 2002). Because of its high sensitivity in measuring slow flows and the improved detailed information about the curved and irregular vessel ways, power Doppler is a suitable technique for depicting the vessels inside the tumour. Nevertheless, the evaluation of the tumour angiogenesis has not still become routine, which might be explained by the lack of an accurate method for angiogenesis assessment (Pietra et al., 2000).

## 2. Aim

Aim of the current study was to evaluate the rectal cancer angiogenesis with Doppler endosonography and immunohistochemistry and to compare the results with computer-assisted methods.

### 3. Material and methods

#### 3.1 Patients

One hundred ninety five patients (123 males, 72 females; mean age  $61.5 \pm 11$  years) with histologically proved rectal cancer were included in the study. The age of the patients ranged from 27 to 83 years. The patients were operated and staged according to the criteria of *World Health Organization* (WHO) for colon and rectum as follows: in stage I - 36 patients (18.5%), stage II - 53 (27.2%), stage III - 84 (43%), and stage IV - 22 patients (11.3%) (Hamilton et al., 2000). Immunohistochemical studies were performed in 110 rectal tumour samples. The distribution of the stages was as follows: Stage I - 20 patients (18.2%); Stage II - 29 patients (26.4%); Stage III - 47 patients (42.7%), Stage IV - 14 patients (12.7%). The patients were followed up for a mean period of  $30.4 \pm 17.6$  months (from 6 to 82 months) after the operation.

#### 3.2 Assessment of angiogenesis by Doppler endosonography

All patients were examined on Toshiba, Nemio SSA 550A, Japan apparatus with a biplane convex transversal and end-fire scanning probe PVM-740RT (5.0/7.5/10 MHz/144°) capable of pulse colour and power Doppler. Every patient was prepared by small enema two hours before endosonography. The examination was performed with the patient in left lateral position. The probe was inserted 12-15cm and then was pulled out to the tumour level. pulse colour (cut-off wall filter: 50-100Hz; pulse repetition frequency: 4kHz) and power Doppler were used to estimate tumour vascularisation. Power Doppler settings were set to detect low velocity flow without artefacts (frequency 5MHz, power Doppler gain 20 (range: 1-30); dynamic range: 20-40dB, pulse repetition frequency: 1kHz).

##### 3.2.1 Pulse colour and power Doppler

The semi quantitative assessment of angiogenesis was done by pulse colour Doppler, measuring the peak systolic velocity (PSV, cm/s) and the resistance index (RI) of the arterial flow in the tumour. The highest value for PSV was recorded, as well as the lowest value for RI. By using power Doppler endosonography tumour vascularisation was determined subjectively according to the following classification: poor vascularisation - absent or isolated colour signals; abundant vascularisation - abundance of chaotic vessels in the periphery and/or the central part of the tumour.

##### 3.2.2 Computer-assisted power Doppler examination

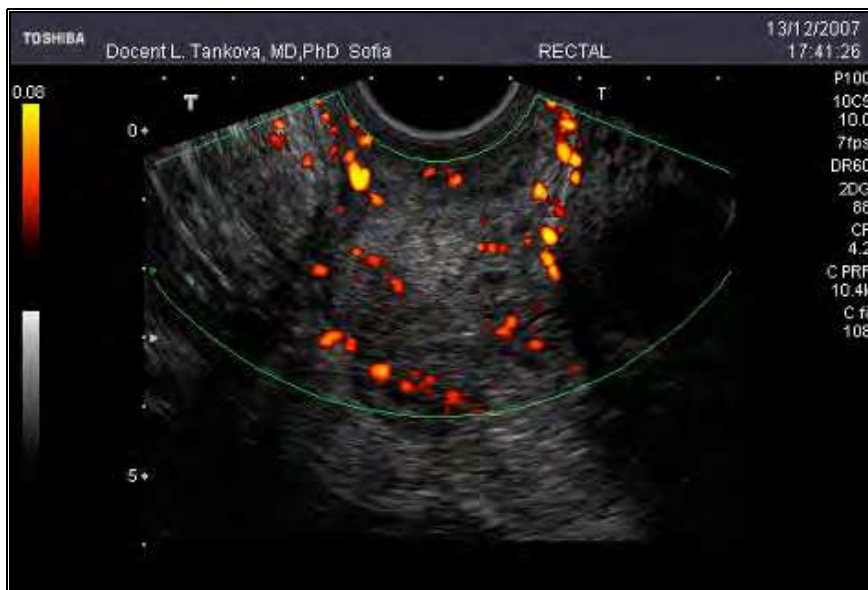The power Doppler was used for the digital tumour vascularisation assessment. The colour window was set to include the lesion and a small part of the surrounding normal tissues. Afterwards, three tumour slices with maximal colour signal numbers were chosen. The tumour image was traced with the pointer, followed by a computer-assisted calculation of the percentage ratio of the number of the coloured pixels within a delineated tumour section to the number of total pixels in that specific tumour section (Fig. 1.). The term Power Doppler Vascularisation Index (PDVI) was introduced, showing the mean of the three consecutive results.

#### 3.3 Assessment of angiogenesis by immunohistochemistry

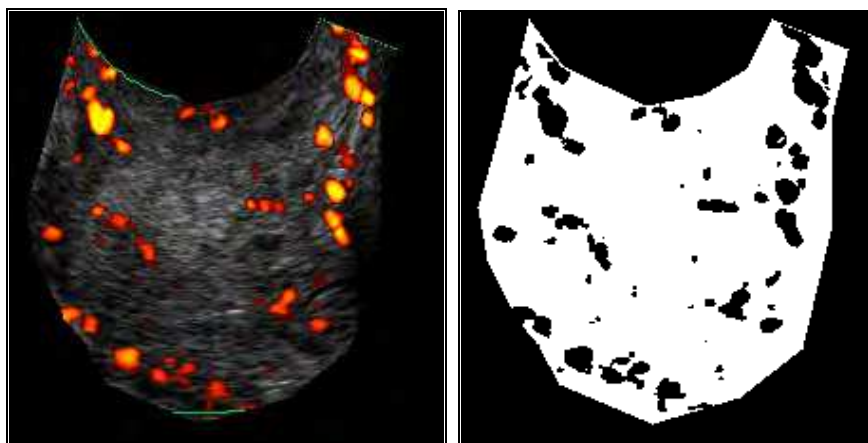
The histological assessment of the microvessel density (MVD) and the level of the VEGF expression in the tumour specimens were determined in 110 patients (71 males; 39 females;

mean age 62 years). The sections were taken from the point of greatest tumour penetration into the rectal wall.

The LSAB2 method (Labelled Streptavidin-Biotin2) was applied using streptavidin-biotin-peroxidase technique.



(a)



(b)

(c)

Fig. 1. (a) - Power Doppler image of tumour hypervascularisation. (b) and (c) - Determination of Power Doppler Vascularisation Index (PDVI) as the ratio of the colour pixels within a marked tumour section to the number of total pixels in that specific tumour section.

Four  $\mu\text{m}$ -thick sections of formalin-fixed, paraffin-embedded resection specimens were prepared. The sections were mounted on clean slides, previously coated with poly-L-lysine adhesive, then deparaffinized using xylol and rehydrated in graded alcohols. Antigen retrieval was done using target retrieval solution (citrate buffer, pH 6, DakoCytomation code S1700 for CD31 and code S2368 for VEGF) in a water bath at 95-98°C for 20min. Thereafter, the endogenous peroxidase was deactivated by soaking the slides in 3% hydrogen peroxidase for 5min to block endogenous peroxidase. Antibodies were purchased from DakoCytomation, Inc, Carpinteria, California: Mouse Monoclonal anti-CD31 antibody (code N1596, clone JC/70A, ready for use dilution 1:20), Monoclonal Mouse Anti-Human VEGF (code M7273, clone VG1, dilution 1:25). The binding reaction was detected by DAB (diaminobenzidine) Substrate Chromogen System. Finally, the sections were counterstained with haematoxylin and mounted using aqueous mounting medium. All immunostaining processes were carried based on the manufacturers' recommendations.

### 3.3.1 Determination of microvessel density

MVD was determined via the method proposed by Weidner et al. (Weidner et al., 1991).

The regions with the most intensive vascularisation (hot spots) were defined by scanning the entire tumour section at low magnification (x40 or x100) with a selection of three fields (Fig. 2.). These were the fields with highest density of the brown coloured CD31+ cells. The individual microvessels were counted at high magnification of x200 (20x objective, 10x eyepiece) or x250 (25x objective, 10x eyepiece). The pictures were realized with the optical microscope Nikon 800E or Leica DM1000, coupled to a colour video camera.

Each image corresponded to a microscope field with an area of  $0,29\text{mm}^2$ . The counting of the microvessels was done manually by calculating the average number for the three selected fields and dividing this number by 0.29, thus obtaining the number of microvessels per  $\text{mm}^2$ . Any brown-stained endothelial cell or endothelial cell cluster that was clearly separated from adjacent microvessels, tumour cells and connective elements was counted as one microvessel, independent of the presence of a vascular lumen or erythrocytes.

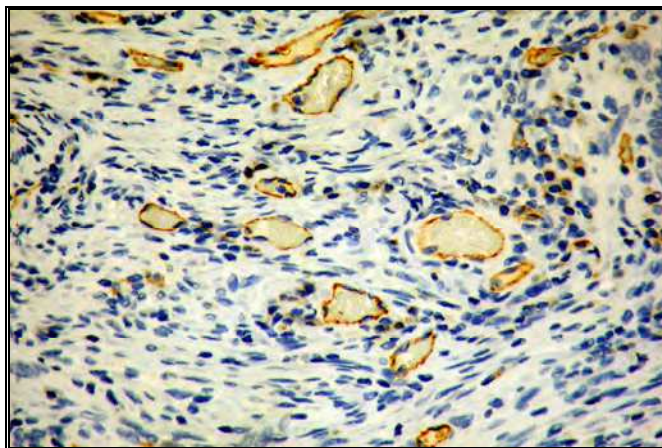


Fig. 2. CD31 immunostaining. Representative cases of „hot spot” of tumor specimens with high MVD (original magnification x 100)

### 3.3.2 Computer-assisted method for endothelial area assessment

Computer-assisted method for endothelial area determination was applied by imaging analysis software. The quality of the colouring varies since archive paraffin blocks were used for the immunohistochemical tests and the samples were prepared at different conditions. Because of that, several steps were needed to equalise the colour image quality before the automatic calculation of the coefficient of vascularisation (CV):

- Equalization of the image colour temperatures. Figure 3. shows two images, shot at different conditions with different spectral curves.

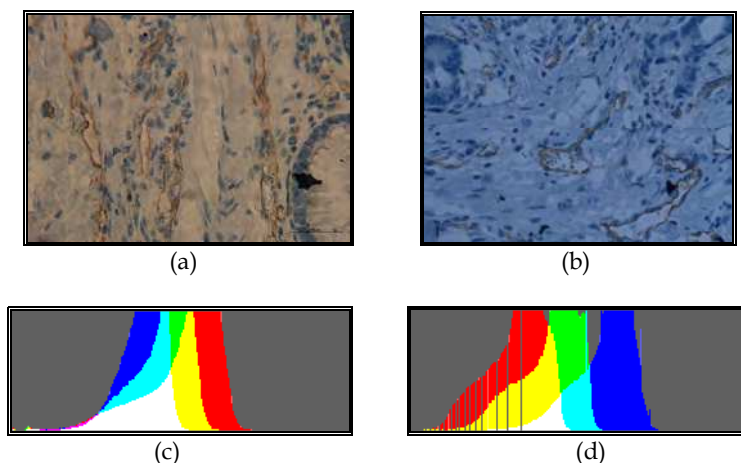


Fig. 3. (a) (b) - Images shot at different conditions. (c) (d) - Corresponding spectral curves

- After their colour temperatures have been equalized (Fig. 4.), the images had the same colours, but different contrast and brightness, depending on the optical characteristics of the microscope and the camera.




Fig. 4. (a)(b) - Equalized spectral curves. (c)(d) - Corresponding images

- The contrast was increased, so that the intensity histogram filled the whole usable dynamic range, yielding images with close colour properties and contrast (Fig. 5).

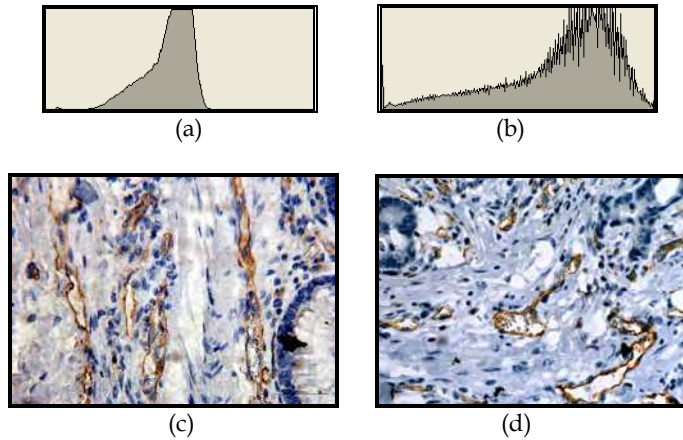


Fig. 5. (a) - Histogram of the contrast (b) - Histogram of the contrast with an extended dynamic range. (c) (d) - Equalized images

The brown marked endothelial cells were determined by imaging analysis software with high accuracy (Fig. 6.). In order to exclude non-endothelial structures a computer-assisted method was used, in which a qualified researcher-pathologist observed the marked areas before the final estimation. The endothelial area was measured automatically and the coefficient of vascularisation was calculated. The coefficient of vascularisation (CV) depicts the percentage of the endothelial area (CD31+ areas) in relation to the total image surface. The mean value of the coefficient from measurements in three areas was chosen.

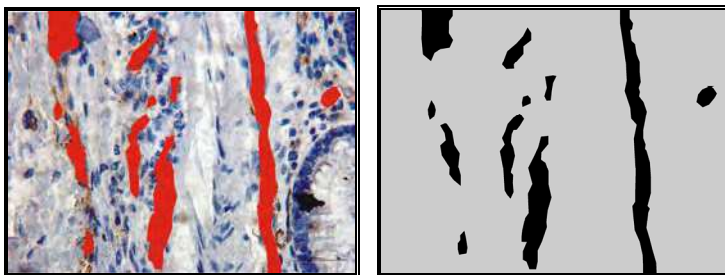


Fig. 6. Computer-assisted selection of the vessels and calculation of the coefficient of vascularisation.

- The data were entered automatically in a database for statistical processing.

### 3.3.3 Immunohistochemistry for VEGF

The VEGF immunoreactivity was estimated at magnification of x200 or x250. Only the clear brownish staining of the cytoplasm and/or the membrane of the tumour cells was counted as positive. The intensity value was given on a scale from 0 to 3 (0 - no staining, 1 - weak

staining in <25% of tumour cells, 2 - moderate cytoplasm staining in >25% of cells; 3 - strong cytoplasm staining). In order to facilitate the correlative analyses, values 0 and 1 were defined as negative staining, whereas values 2 and 3 were considered positive staining. Even if a small part of the tumour had a high staining intensity, the whole tumour was regarded as with high intensity.

### 3.4 Statistical methods

The data was entered and processed with the statistical package SPSS for Windows version 17. The degree of significance, for which the zero hypotheses was rejected, was chosen as  $p < 0.05$ . The following statistical methods were used: Descriptive analysis; Variation analysis; Student's t-test; Single factor dispersion analysis (ANOVA) - parametric method to test hypotheses for differences between several independent subsets; Mann-Whitney non-parametric test - to test hypotheses for differences between two independent subsets; Kaplan-Meier's method for survival curves estimation; Log Rank test - for estimating the influence of the tested factors on the survival; ROC (Receiver operating characteristic) curve analysis - to determine the cut-off of the quantitative variables.

The study was approved by Regional Ethic Committee in the University Hospital „Queen Joanna”, Sofia.

## 4. Results

### 4.1 Doppler endosonography

The average peak systolic velocity (PSV) of the tumour vessels was  $23.1 \pm 13.7$  cm/s (from 6 to 88.9 cm/s). The average resistance index (RI) was  $0.67 \pm 0.12$  (from 0.36 to 0.89). Cut-off values for PSV and RI were set based on a ROC analysis - 17.5 cm/s and 0.7, respectively. In 55 % (76/94) of the tumours, a high peak systolic velocity (above 17.5 cm/s) was observed (Fig. 7).

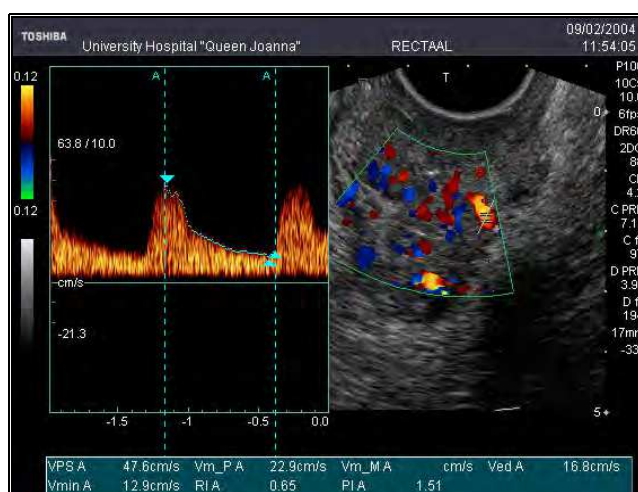


Fig. 7. Pulse colour Doppler endosonography of rectal cancer (high PSV - 47.6 cm/s and low RI - 0.65).

The power Doppler endosonographic evaluation determined poor vascularisation in 102 patients and abundant vascularisation in 93 patients (Fig. 8., Fig. 9.).

The mean PDVI measured in 195 patients was  $8.9 \pm 6.0\%$  (from 0 to 27.3%). According to ROC analysis the cut-off of PDVI was 8%. PDVI correlated with the tumour stage ( $p < 0.05$ ). The index value was higher in the advanced stages than in the initial ones.

The computer-assisted estimation of vascularisation, measured with a Power Doppler, correlated moderately inversely proportionally with the RI ( $r = -0.45$ ,  $p < 0.001$ ) and moderately proportionally with the peak systolic velocity of the blood flow in the tumour vessels ( $r = 0.39$ ,  $p < 0.001$ ).

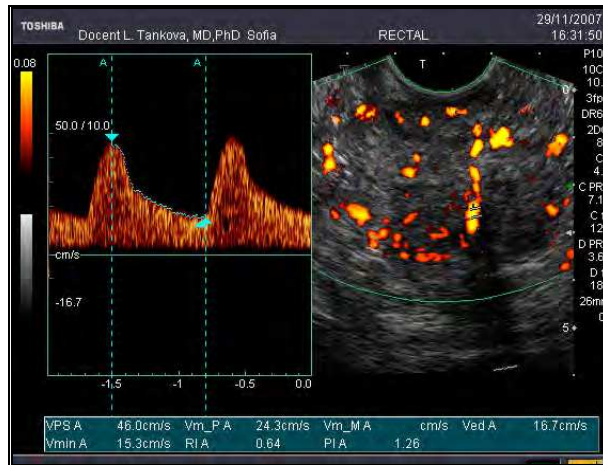

Fig. 8. Power Doppler endosonography of rectal cancer with high vascularisation - abundant chaotic vascularisation in the centre and periphery of the tumour (high PSV – 46 cm/s and low RI – 0.64)

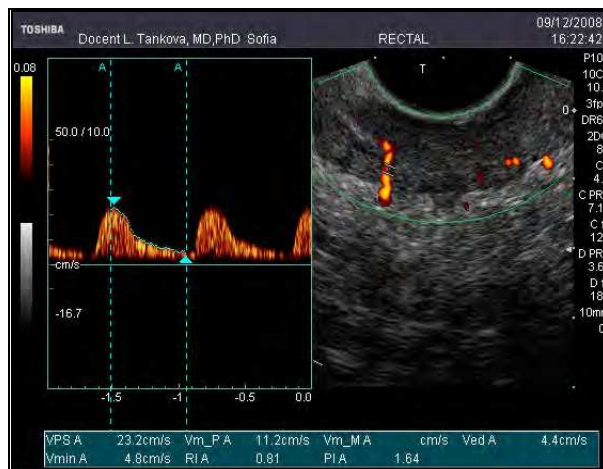


Fig. 9. Power Doppler endosonography of rectal cancer with poor vascularisation (high RI – 0.81)



## 4.2 Immunohistochemistry

### 4.2.1 Determination of the microvessel density and the coefficient of vascularisation

The average microvessel density per square millimetre in the examined 110 tumour samples was  $163 \pm 69$  microvessels/mm<sup>2</sup> (from 50 to 328). The agreement between the two observers was good. In cases of disagreement, a final score was determined by consensus. The cut-off values of MVD determined by the ROC curve allowed us to discriminate the hypervascularised tumours ( $\geq 160$ ) from the hypovascularised ones (MVD < 160).

No correlations were found between the microvessel density and the patient age, gender or tumour size. There was a significant correlation between the microvessel density and the histological differentiation of the tumour. The MVD values for the low differentiation subset were significantly higher than these for the high differentiation subset. MVD correlated significantly with the tumour stage (Table 1).

Stage	MVD		
	n	$\bar{X}$	SD
I	20	103.68 <sup>a</sup>	39.83
II	29	137.41 <sup>b</sup>	48.91
III	47	180.34 <sup>c</sup>	64.84
IV	14	236.07 <sup>d</sup>	66.22

\*different letters (a, b, c, d) show a significant difference ( $p < 0.05$ ).

Table 1. The correlation between microvessel density (MVD) and the rectal cancer stage

The digital assessment of the endothelial area by calculation of the coefficient vascularisation (CV) showed a mean CV of  $5.8 \pm 3.9\%$  (from 1.1 to 24.6%). According to the ROC curve analysis the hypervascularised group (CV  $\leq 3.25\%$ ) was discriminated from the hypovascularised tumours (CV  $> 3.25\%$ ) (Fig. 10.).

The coefficient of vascularisation was significantly higher in tumour stages III and IV compared to the stages I and II (Table 2).

There was a close correlation between microvessel density, calculated by the traditional method and the coefficient of vascularisation determined by the computer-assisted method ( $r=0.536$ ,  $p<0.001$ ). There was a linear correlation between PDVI calculated using power Doppler examination and MVD ( $r=0.41$ ,  $p<0.001$ ) as well as between PDVI and the coefficient of vascularisation determined by the immunohistochemical examination ( $r=0.31$ ,  $p<0.01$ ).

Positive VEGF tumour expression was estimated in 59 tumours (54%) (Fig. 11.). No significant interobserver variability has been noticed between two pathologists.

There was a statistically significant correlation with the MVD values. The MVD value was higher in the VEGF positive group than in the negative group ( $P < 0.05$ ). In tumour samples with positive VEGF expression the mean microvessel density was  $188/\text{mm}^2$  and in the cases of negative VEGF expression, the mean MVD was  $136/\text{mm}^2$  (Table 3.).

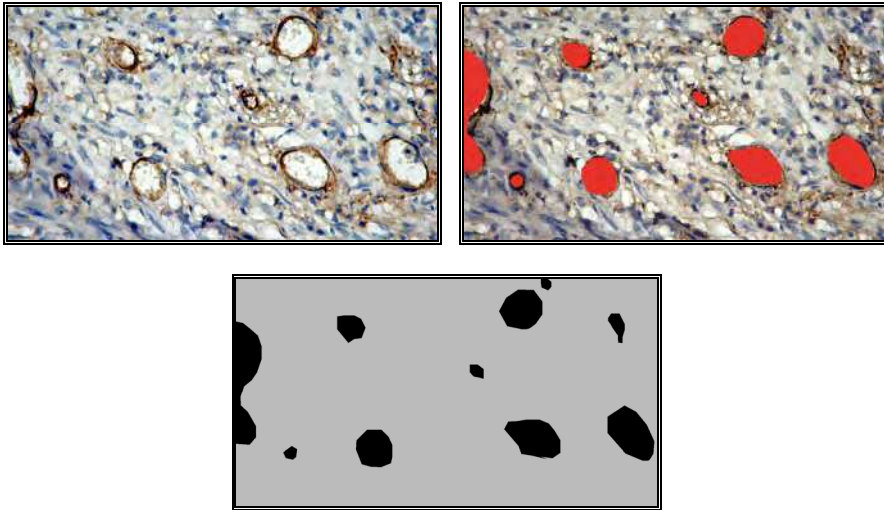


Fig. 10. Steps in the coefficient of vascularisation calculation. High coefficient of vascularisation - 9.2% (original magnification x100)

Stage	CV		
	n	$\bar{X}$ (%)	SD
I	20	3.59a	2.67
II	29	4.69a	4.33
III	47	6.56b	3.35
IV	14	8.30b	4.33

\*the different letters (a, b) show a significant difference ( $p < 0.05$ ); the same letters show no significant difference ( $p > 0.05$ ).

Table 2. The correlation between the coefficient of vascularisation and the rectal cancer stage

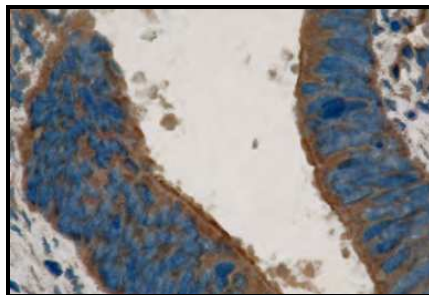


Fig. 11. VEGF expression showing a strong cytoplasmic immunostaining (original magnification x250).

VEGF	MVD		
	n	$\bar{X}$	SD
Negative expression	51	136.08a	66.53
Positive expression	59	187.92b	61.84

\* the different letters (a, b) show a significant difference ( $p < 0.05$ ).

Table 3. The correlation between VEGF and MVD

The conducted Kaplan-Meier analysis showed 21 months longer overall survival ( $p < 0.05$ ) of the patients with RI below 0.70 than those with higher values. As for the Power Doppler Vascularisation Index (PDVI), the overall survival of patients with PDVI lower than 8% was about 25 months longer than that of patients with PDVI above 8%, and the difference was significant. The survival curve showed a statistically significant relationship between microvessel density and the survival period. The overall survival of the patients with MVD tumours up to 160/mm<sup>2</sup> tended to be 36 months longer than that in the patients with elevated values of the microvessel density. The overall survival of patients with MVD above 160/mm<sup>2</sup> decreased very rapidly to circa 30 % within 30 months. A significantly better survival was observed in patients with MVD below 160/mm<sup>2</sup> (Fig. 12).

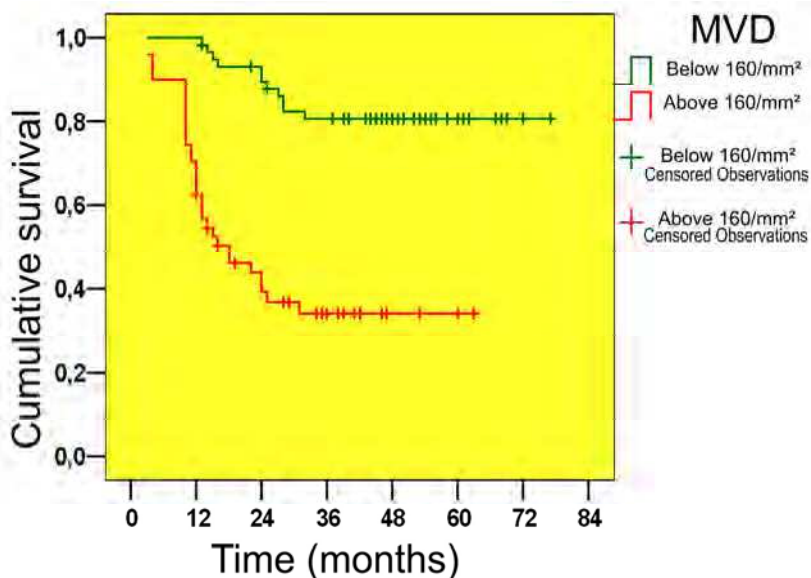


Fig. 12. Kaplan-Meier’s curve, based on the MVD

We could establish a statistically significant higher survival period (with about 33.5 months) for patients with negative VEGF than for positive patients. The overall survival of patients with CV above 3.25% decreased very rapidly to circa 45% within 30 months. A significantly better survival was observed in patients with CV below 3.25% (Fig. 13).

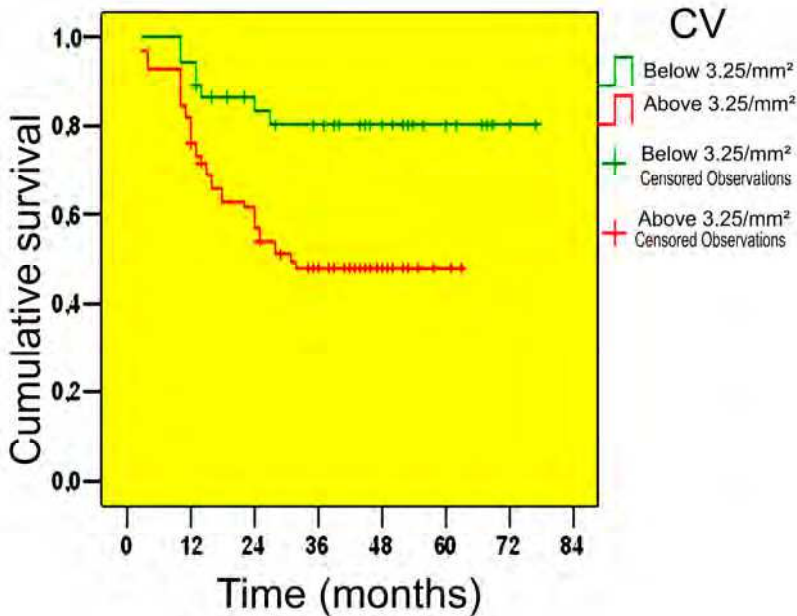


Fig. 13. Kaplan-Meier's curve, based on the CV.

## 5. Discussion

The determination of the microvessel density is a morphological “golden standard” for assessing the tumour neovascularisation.

Angiogenesis measured by microvessel density determination correlates with the tumour behaviour. There are a lot of reports showing that the higher microvessel density is associated with the metastases development, poor prognosis and life expectancy shortage in colorectal cancer patients (Choi et al., 1998; Engel et al., 1996; Frank et al., 1995; Galindo, 2000; Giatromanolaki et al., 2006 Koukourakis et al., 2005 Li et al., 2003; Rasheeda S. et al, 2009; Sternfeld et al., 1999, Takahashi et al., 1997; Takebayashi et al., 1996; Tanigawa et al., 1997; Tomisaki et al., 1996; Uribarrena et al., 2009; White et al., 2002). However, there are conflicting results regarding the prognostic value of tumour MVD (Abdala et al., 1999, Bossi et al., 1995; Ellis at al., 1998; Pietra et al., 2000; Tarta et al., 2002).

In the current study the microvessel counts are high (163/mm<sup>2</sup> on average), which confirms the assumption that the rectal carcinoma is strongly dependent on angiogenesis. Significant correlations between the microvessel density values, tumour differentiation and clinical stage are observed. MVD is significantly higher in more advanced tumour stages and may be used as a determinant of survival in patients with rectal cancers.

The high average values of microvessel densities in the present study probably are due to the dominance of advanced tumour stages in the clinical material (55% of the tumours were in Stages III and IV) and the use of CD31 as endothelial cell marker. CD31 marks the pre-existent mature vessels and neofomed vessels, the thrombocytes, plasmocytes and megakaryocytes.

There are considerable differences in microvessel counts of carcinoma tissue. The different results may be related to the lack of a standardized and an objective method of the tumour angiogenesis assessment (Vermeulen et al., 1995). The type of antibody used to label the endothelium is a possible cause for the large variation in microvessel counts among studies. Platelet endothelial cell adhesion molecule-1 (PECAM-1) also known as cluster of differentiation 31 (CD31) is a transmembrane glycoprotein involved in cell adhesion. Other commonly used antibodies to highlight tumour blood vessels are those against Factor VIII related antigen, CD34, CD105. Factor VIII related antigen is a part of the von Willebrand factor complex and plays a role in the coagulation cascade. Tissue slices stained with CD34 have been reported to give 1.8-fold higher microvessel counts than slices stained with factor VIII (Tomisaki et al., 1996). The criteria used for identification of microvessels (single endothelium or clusters of endothelium with or without lumen) may be another cause for the considerable differences.

The quantification of angiogenesis was made in the majority of studies with the classical "hot-spot" Weidner's method, which supposes the counting of positive microvessels with and without vascular lumen (Engel et al., 1996; Frank et al., 1995; Galindo, 2000; Pietra et al., 2000; Sternfeld et al., 1999; Takahashi et al., 1997; Takebayashi et al., 1996; Vermeulen et al., 1999).

Some authors use Chalkey count to minimize the subjectivity in the quantification of MVD (Li et al., 2003; White et al., 2002). The Chalkey count consists of applying a 25-point eyepiece graticule on several hot spots (usually 3) (Chalkey, 1943). The graticule is oriented to allow the maximum number of points to hit on or within the areas of stained microvessel profiles (Chalkey grid area: 0.196 mm<sup>2</sup>).

Other possibility to assess tumour angiogenesis is to determine the endothelial area which is defined as the percentage area occupied by the positive endothelial cells in the microscope field (Leme et al., 2006; Uribarrena et al., 2009). The measurement of endothelial area by the computerized method is particularly useful in the evaluation of tumors with high vessel density, in which the presence of microvessels very close to each other makes manual counting difficult and laborious. Since measurement of the endothelial area represents the total quantity of vascular endothelium on the histological thin section, there is no need to separately identify each vessel. Automated computerized image analysis for quantifying the MVD may reduce subjective bias during the counting process (Goddard et al., 2002; Poon et al., 2003; Sprindzuk et al., 2009). In a study of breast cancer, tumor microvessel density obtained by automated computerized image analysis, but not the MVD obtained by manual counting, is an independent prognostic factor (Acenero et al., 1998).

We believe that the computerized method is more accurate than conventional MVD determination because the latter counts the vessels, but does not take into account other information such as vessel size or lumen size. The computer-assisted method overcomes some of the disadvantages of traditional microvessel counting. The researcher variations are decreased, because the measurements are done partly by the computer. Another advantage of the computer-assisted method is the faster assessment of the tumour angiogenesis, which makes it suitable for wider application in clinical practice.

A potential drawback of the computerized measurement of tumour vascularisation is the inclusion of non-endothelial structures, unspecifically stained with anti-CD31. However, this can easily be corrected by the pathologist.

The evaluation of expression of angiogenic factors in tumour specimens provides an alternative to MVD in assessing tumour angiogenic activity. This method may potentially reduce the bias associated with the selection of hot spots for MVD evaluation, and may provide more functional information on the tumour angiogenic activity than MVD.

The vascular endothelial growth factor is one of the most important angiogenesis regulators and is intimately involved in the progressing and metastasising of the colorectal cancer. VEGF/VPF (now termed VEGF-A) was first identified in 1983 by Senger and colleagues in ascites fluid of tumours in rodents (Senger et al., 1983). VEGF is a heparin binding glycoprotein that occurs in at least four molecular isoforms as the result of alternative VEGF mRNA splicing.

Numerous studies have demonstrated that tumour over expression of VEGF correlates with high tumour MVD and with the tumor invasiveness in various common human cancers (Des Guetz et al., 2006; Jacobson, 2000; Kaio et al., 2003; Lee et al., 2000; Seo et al., 2000; White et al., 2002). In some studies, VEGF expression in the tumour has been shown as a prognostic factor independent of conventional prognostic factors (Cascinu et al., 2000; Ferroni et al., 2005).

Our results also show a statistically significant relation between the VEGF expression level and the overall survival of rectal cancer patients.

MVD provides direct assessment of angiogenesis and requires tumour tissue, mainly from resection specimens. This process is, however, limited by the inability to provide information about vascular functionality, particularly in response to treatment. Indirect methods of assessing angiogenesis include determination of serum angiogenic cytokines and circulating endothelial cells as well as imaging methods. Several commonly available imaging techniques are able to assess human tumours *in vivo* with respect to the functional status of the vasculature. Both CT and MRI have the advantage of good spatial resolution, which is often equal to that of corresponding morphological images. Ultrasound, Perfusion CT, also called functional multi-detector row CT (f-MDCT), Dynamic contrast-enhanced MRI (DCE-MRI) are currently the favoured techniques for evaluating tumours with respect to their functional microcirculation (Cosgrove, 2003; McDonald & Choyke 2003). The introduction of ultrasound contrast agents (gas-encapsulated microbubbles of less than 10  $\mu\text{m}$  in diameter) is a recent development in the imaging technology. Since microbubbles are confined to the vascular space, this makes them ideal for the perfusion imaging techniques. Microbubble-specific techniques allow imaging of vessels down to 50–100  $\mu\text{m}$  in diameter (Cosgrove, 2003; McDonald & Choyke 2003; Turkbey et al. 2009).

Endorectal sonography is proven to be the most exact method for rectal cancer staging, but less attention was paid to the pulse colour and power Doppler evaluation. The color Doppler signals seen within the tumour represent the larger vessels (approximately 100  $\mu\text{m}$  or more in diameter), possibly intratumoral arterioles, venules, and arteriole-venule shunts. The tumour vascularisation is usually chaotically distributed and heterogeneous. The microvessel numbers in a small part of the tumour is not enough to represent the global tumour angiogenesis, or to depict the functional properties of tumour blood supply. The colour Doppler allows visualization of the vessels via the colour coding. With the pulse Doppler one can assess the blood flow speed and the resistance of a particular vessel at a certain time point.

Several studies have suggested that color Doppler ultrasonography may provide a reliable preoperative quantitation of tumor angiogenesis and prognostic information in cancer patients (Ogura et al., 2001; Chen et al., 2002).

We hypothesized that the amount of detected supplying intratumoral arterioles and draining venules correlates positively with the degree of the microvascularisation in the tumour. Thus, the Power Doppler Vascularisation Index, by quantitatively depicting the larger supplying arterioles and draining venules, can reflect the extent of global neovascularisation of a tumour.

In the present study the patients with poor vascularisation, determined by the subjective Doppler assessment tend to live longer. Higher resistance index and lower peak systolic velocity (below 17.5 cm/sec) are favourable prognostic signs.

Our results show that the intensity of the intratumour angiogenesis, estimated with endorectal Doppler as well as with immunohistochemical methods, correlates to the tumour stage and tumour aggressiveness.

## 6. Conclusions

Endorectal pulse colour and power Doppler sonography is useful non-invasive method of preoperative in vivo evaluating the extent of angiogenesis.

In this study the determination of tumour angiogenic activity through endorectal Doppler evaluation, is well correlated with the conventional and computer-assisted immunohistochemical methods. The computer-assisted endosonographic Doppler and immunohistochemical based methods represent rapid, reliable and reproducible means for quantitative assessment of the tumour vascularisation.

## 7. References


- Abdalla, S. A.; Behzad, F.; Bsharah, S.; Kumar, S.; Amini, S. K.; O'dwyer, S. T. & Haboubi, N. Y. (1999). Prognostic relevance of microvessel density in colorectal tumours. *Oncol Rep*, Vol. 6, No. 4, pp. 839-842, ISSN 1021-335X.
- Acenero, M. J.; Gonzalez, J. F.; Gallego, M. G. & Ballesteros, P. A. (1998). Vascular enumeration as a significant prognosticator for invasive breast carcinoma. *J Clin Oncol*, Vol. 16, No. 5, pp. 1684-1688, ISSN 0732-183X.
- Bossi, P.; Viale, G.; Lee, A. K.; Alfano, R.; Coggi, G. & Bosari, S. (1995). Angiogenesis in colorectal tumors: Microvessel quantitation in adenomas and carcinomas with clinicopathological correlations. *Cancer Res*, Vol. 55, No. 21, pp. 5049-5053, ISSN 0008-5472.
- Cascinu, S.; Staccioli, M. P.; Gasparini, G.; Giordani, P.; Catalano, V.; Ghiselli, R.; Rossi, C.; Baldelli, A. M.; Graziano, F.; Saba, V.; Muretto, P. & Catalano, G. (2000). Expression of vascular endothelial growth factor can predict event-free survival in stage ii colon cancer. *Clin Cancer Res*, Vol. 6, No. 7, pp. 2803-2807, ISSN 1078-0432.
- Chalkley H. W. (1943). Method for the quantitative morphologic analysis of tissues. *J Natl Cancer Inst*, Vol. 4, pp. 47-53, ISSN 0027-8874.
- Chen, C. N.; Cheng, Y. M.; Lin, M. T.; Hsieh, F. J.; Lee, P. H. & Chang, K. J. (2002). Association of color doppler vascularity index and microvessel density with survival in patients with gastric cancer. *Ann Surg*, Vol. 235, No. 4, pp. 512-518, ISSN 0003-4932.
- Choi, H. J.; Hyun, M. S.; Jung, G. J.; Kim, S. S. & Hong, S. H. (1998). Tumor angiogenesis as a prognostic predictor in colorectal carcinoma with special reference to mode of metastasis and recurrence. *Oncology*, Vol. 55, No. 6, pp. 575-581, ISSN 0030-2414.

- Cosgrove, D. (2003). Angiogenesis imaging--ultrasound. *Br J Radiol*, Vol. 76 Spec No 1, pp. S43-49, ISSN 0007-1285.
- Des Guetz, G.; Uzzan, B.; Nicolas, P.; Cucherat, M.; Morere, J. F.; Benamouzig, R.; Breau, J. L. & Perret, G. Y. (2006). Microvessel density and vegf expression are prognostic factors in colorectal cancer. Meta-analysis of the literature. *Br J Cancer*, Vol. 94, No. 12, pp. 1823-1832, ISSN 0007-0920.
- Ellis, L. M.; Takahashi, Y.; Liu, W. & Shaheen, R. M. (2000). Vascular endothelial growth factor in human colon cancer: Biology and therapeutic implications. *Oncologist*, Vol. 5 Suppl 1, pp. 11-15, ISSN 1083-7159.
- Engel, C. J.; Bennett, S. T.; Chambers, A. F.; Doig, G. S.; Kerkvliet, N. & O'malley, F. P. (1996). Tumor angiogenesis predicts recurrence in invasive colorectal cancer when controlled for dukes staging. *Am J Surg Pathol*, Vol. 20, No. 10, pp. 1260-1265, ISSN 0147-5185.
- Ferroni, P.; Spila, A.; Martini, F.; D'alessandro, R.; Mariotti, S.; Del Monte, G.; Graziano, P.; Buonomo, O.; Guadagni, F. & Roselli, M. (2005). Prognostic value of vascular endothelial growth factor tumor tissue content of colorectal cancer. *Oncology*, Vol. 69, No. 2, pp. 145-153, ISSN 0030-2414.
- Frank, R. E.; Saclarides, T. J.; Leurgans, S.; Speziale, N. J.; Drab, E. A. & Rubin, D. B. (1995). Tumor angiogenesis as a predictor of recurrence and survival in patients with node-negative colon cancer. *Ann Surg*, Vol. 222, No. 6, pp. 695-699, ISSN 0003-4932.
- Galindo G. M.; Fernandez Acenero, M. J.; Sanz Ortega, J. & Aljama, A. (2000). Vascular enumeration as a prognosticator for colorectal carcinoma. *Eur J Cancer*, Vol. 36, No. 1, pp. 55-60, ISSN 0959-8049.
- Giatromanolaki, A.; Sivridis, E. & Koukourakis, M. I. (2006). Angiogenesis in colorectal cancer: Prognostic and therapeutic implications. *Am J Clin Oncol*, Vol. 29, No. 4, pp. 408-417, ISSN 1537-453X.
- Goddard, J. C.; Sutton, C. D.; Furness, P. N.; Kockelbergh, R. C. & O'byrne, K. J. (2002). A computer image analysis system for microvessel density measurement in solid tumours. *Angiogenesis*, Vol. 5, No. 1-2, pp. 15-20, ISSN 0969-6970.
- Hamilton, S.; Vogelstein, B.; Kudo, S.; Riboli, S.; Nakamura, D.; Hainaut, J.; Rubio, C.; Sobin, L.; Fogt, F.; Winawer, S.; Goldgar, D. & Jass J. (2000). Tumours of the colon and rectum. In: *World Health Organization Classification of Tumours: Pathology and genetics of tumours of the digestive system*, Hamilton, S. & Aaltonen, L. (eds), pp. 104-143, IARC Press, ISBN 92 832 2410 8 Lyon, France.
- Jacobsen, J.; Rasmuson, T.; Grankvist, K. & Ljungberg, B. (2000). Vascular endothelial growth factor as prognostic factor in renal cell carcinoma. *J Urol*, Vol. 163, No. 1, pp. 343-347, ISSN 0022-5347.
- Kaio, E.; Tanaka, S.; Kitadai, Y.; Sumii, M.; Yoshihara, M.; Haruma, K. & Chayama, K. (2003). Clinical significance of angiogenic factor expression at the deepest invasive site of advanced colorectal carcinoma. *Oncology*, Vol. 64, No. 1, pp. 61-73, ISSN 0030-2414.
- Koukourakis, M. I.; Giatromanolaki, A.; Sivridis, E.; Gatter, K. C. & Harris, A. L. (2005). Inclusion of vasculature-related variables in the dukes staging system of colon cancer. *Clin Cancer Res*, Vol. 11, No. 24 Pt 1, pp. 8653-8660, ISSN 1078-0432.
- Lee, J. C.; Chow, N. H.; Wang, S. T. & Huang, S. M. (2000). Prognostic value of vascular endothelial growth factor expression in colorectal cancer patients. *Eur J Cancer*, Vol. 36, No. 6, pp. 748-753, ISSN 0959-8049.



- Leme, M. B.; Waitzberg, A. F.; Artigiani Neto, R.; Linhares, M. M. & Matos, D. (2006). Assessment of angiogenesis expression and its relationship with prognosis of colorectal cancer by conventional and computer-assisted histopathological image analysis. *Acta Cir Bras*, Vol. 21, No. 6, pp. 392-397, ISSN 0102-8650.
- Li, C.; Gardy, R.; Seon, B. K.; Duff, S. E.; Abdalla, S.; Renehan, A.; O'dwyer, S. T.; Haboubi, N. & Kumar, S. (2003). Both high intratumoral microvessel density determined using cd105 antibody and elevated plasma levels of cd105 in colorectal cancer patients correlate with poor prognosis. *Br J Cancer*, Vol. 88, No. 9, pp. 1424-1431, ISSN 0007-0920.
- Mcdonald, D. M. & Choyke, P. L. (2003). Imaging of angiogenesis: From microscope to clinic. *Nat Med*, Vol. 9, No. 6, pp. 713-725, ISSN 1078-8956.
- Ogura, O.; Takebayashi, Y.; Sameshima, T.; Maeda, S.; Yamada, K.; Hata, K.; Akiba, S. & Aikou, T. (2001). Preoperative assessment of vascularity by color doppler ultrasonography in human rectal carcinoma. *Dis Colon Rectum*, Vol. 44, No. 4, pp. 538-546; ISSN 0012-3706.
- Pietra, N.; Sarli, L.; Caruana, P.; Cabras, A.; Costi, R.; Gobbi, S.; Bordi, C. & Peracchia, A. (2000). Is tumour angiogenesis a prognostic factor in patients with colorectal cancer and no involved nodes? *Eur J Surg*, Vol. 166, No. 7, pp. 552-556, ISSN 1102-4151.
- Poon, R. T.; Fan, S. T. & Wong, J. (2003). Clinical significance of angiogenesis in gastrointestinal cancers: A target for novel prognostic and therapeutic approaches. *Ann Surg*, Vol. 238, No. 1, pp. 9-28, ISSN 0003-4932.
- Rasheed, S.; Harris, A. L.; Tekkis, P. P.; Turley, H.; Silver, A.; Mcdonald, P. J.; Talbot, I. C.; Glynn-Jones, R.; Northover, J. M. & Guenther, T. (2009). Assessment of microvessel density and carbonic anhydrase-9 (ca-9) expression in rectal cancer. *Pathol Res Pract*, Vol. 205, No. 1, pp. 1-9, ISSN 0344-0338.
- Senger, D. R.; Galli, S. J.; Dvorak, A. M.; Perruzzi, C. A.; Harvey, V. S. & Dvorak, H. F. (1983). Tumor cells secrete a vascular permeability factor that promotes accumulation of ascites fluid. *Science*, Vol. 219, No. 4587, pp. 983-985, ISSN 0036-8075.
- Seo, Y.; Baba, H.; Fukuda, T.; Takashima, M. & Sugimachi, K. (2000). High expression of vascular endothelial growth factor is associated with liver metastasis and a poor prognosis for patients with ductal pancreatic adenocarcinoma. *Cancer*, Vol. 88, No. 10, pp. 2239-2245, ISSN 0008-543X.
- Sprindzuk, M.; Dmitruk, A.; Kovalev, V.; Bogush, A.; Tuzikov, A.; Liakhovski, V. & Fridman, M. (2009). Computer-aided Image Processing of Angiogenic Histological Samples in Ovarian Cancer. *J Clin Med Res*, Vol. 1, No. 5, pp. 249-261, ISSN 1918-3003.
- Sternfeld, T.; Foss, H. D.; Kruschewski, M. & Runkel, N. (1999). The prognostic significance of tumor vascularization in patients with localized colorectal cancer. *Int J Colorectal Dis*, Vol. 14, No. 6, pp. 272-276, ISSN 0179-1958.
- Takahashi, Y.; Tucker, S. L.; Kitadai, Y.; Koura, A. N.; Bucana, C. D.; Cleary, K. R. & Ellis, L. M. (1997). Vessel counts and expression of vascular endothelial growth factor as prognostic factors in node-negative colon cancer. *Arch Surg*, Vol. 132, No. 5, pp. 541-546, ISSN 0004-0010.
- Takebayashi, Y.; Aklyama, S.; Yamada, K.; Akiba, S. & Aikou, T. (1996). Angiogenesis as an unfavorable prognostic factor in human colorectal carcinoma. *Cancer*, Vol. 78, No. 2, pp. 226-231, ISSN 0008-543X.

- Tanigawa, N.; Amaya, H.; Matsumura, M.; Lu, C.; Kitaoka, A.; Matsuyama, K. & Muraoka, R. (1997). Tumor angiogenesis and mode of metastasis in patients with colorectal cancer. *Cancer Res*, Vol. 57, No. 6, pp. 1043-1046, ISSN 0008-5472.
- Tarta, C.; Teixeira, C. R.; Tanaka, S.; Haruma, K.; Chiele-Neto, C. & Da Silva, V. D. (2002). Angiogenesis in advanced colorectal adenocarcinoma with special reference to tumoral invasion. *Arq Gastroenterol*, Vol. 39, No. 1, pp. 32-38, ISSN 0004-2803.
- Tomisaki, S.; Ohno, S.; Ichiyoshi, Y.; Kuwano, H.; Maehara, Y. & Sugimachi, K. (1996). Microvessel quantification and its possible relation with liver metastasis in colorectal cancer. *Cancer*, Vol. 77, No. 8 Suppl, pp. 1722-1728, ISSN 0008-543X.
- Turkbey, B.; Kobayashi, H.; Ogawa, M.; Bernardo, M. & Choyke, P. L. (2009). Imaging of tumor angiogenesis: Functional or targeted? *AJR Am J Roentgenol*, Vol. 193, No. 2, pp. 304-313, ISSN 1546-3141.
- Uribarrena, A. R.; Ortego, J.; Fuentes, J.; Raventos, N.; Parra, P. & Uribarrena, E. R. (2009). Prognostic value of microvascular density in dukes a and b (t1-t4, n0, m0) colorectal carcinomas. *Gastroenterol Res Pract*, Vol. 2009, No. 2009, pp. 679830, ISSN 1687-630X.
- Vermeulen, P. B.; Gasparini, G.; Fox, S. B.; Toi, M.; Martin, L.; Mcculloch, P.; Pezzella, F.; Viale, G.; Weidner, N.; Harris, A. L. & Dirix, L. Y. (1996). Quantification of angiogenesis in solid human tumours: An international consensus on the methodology and criteria of evaluation. *Eur J Cancer*, Vol. 32A, No. 14, pp. 2474-2484, ISSN 0959-8049.
- Vermeulen, P. B.; Verhoeven, D.; Fierens, H.; Hubens, G.; Goovaerts, G.; Van Marck, E.; De Bruijn, E. A.; Van Oosterom, A. T. & Dirix, L. Y. (1995). Microvessel quantification in primary colorectal carcinoma: An immunohistochemical study. *Br J Cancer*, Vol. 71, No. 2, pp. 340-343, ISSN 0007-0920.
- Weidner, N.; Semple, J. P.; Welch, W. R. & Folkman, J. (1991). Tumor angiogenesis and metastasis-correlation in invasive breast carcinoma. *N Engl J Med*, Vol. 324, No. 1, pp. 1-8, ISSN 0028-4793.
- White, J. D.; Hewett, P. W.; Kosuge, D.; Mcculloch, T.; Enholm, B. C.; Carmichael, J. & Murray, J. C. (2002). Vascular endothelial growth factor-d expression is an independent prognostic marker for survival in colorectal carcinoma. *Cancer Res*, Vol. 62, No. 6, pp. 1669-1675, ISSN 0008-5472.
- Yang, W. T.; Tse, G. M.; Lam, P. K.; Metreweli, C. & Chang, J. (2002). Correlation between color power doppler sonographic measurement of breast tumor vasculature and immunohistochemical analysis of microvessel density for the quantitation of angiogenesis. *J Ultrasound Med*, Vol. 21, No. 11, pp. 1227-1235, ISSN 0278-4297



## **Rectal Cancer - A Multidisciplinary Approach to Management**

Edited by Dr. Giulio A. Santoro

ISBN 978-953-307-758-1

Hard cover, 410 pages

**Publisher** InTech

**Published online** 10, October, 2011

**Published in print edition** October, 2011

Dramatic improvements in medicine over the last few years have resulted in more reliable and accessible diagnostics and treatment of rectal cancer. Given the complex physiopathology of this tumor, the approach should not be limited to a single specialty but should involve a number of specialties (surgery, gastroenterology, radiology, biology, oncology, radiotherapy, nuclear medicine, physiotherapy) in an integrated fashion. The subtitle of this book "A Multidisciplinary Approach to Management" encompasses this concept. We have endeavored, with the help of an international group of contributors, to provide an up-to-date and authoritative account of the management of rectal tumor.

### **How to reference**

In order to correctly reference this scholarly work, feel free to copy and paste the following:

Tankova Ludmila, Daniel Kovatchki, Georgi Stoilov, Antonina Gegova and Ivan Terziev (2011). Tumour Angiogenesis in Rectal Cancer-Computer-Assisted Endosonographic and Immunohistochemical Methods for Assessment, Rectal Cancer - A Multidisciplinary Approach to Management, Dr. Giulio A. Santoro (Ed.), ISBN: 978-953-307-758-1, InTech, Available from: <http://www.intechopen.com/books/rectal-cancer-a-multidisciplinary-approach-to-management/tumour-angiogenesis-in-rectal-cancer-computer-assisted-endosonographic-and-immunohistochemical-metho>

# **INTECH**

open science | open minds

### **InTech Europe**

University Campus STeP Ri  
Slavka Krautzeka 83/A  
51000 Rijeka, Croatia  
Phone: +385 (51) 770 447  
Fax: +385 (51) 686 166  
[www.intechopen.com](http://www.intechopen.com)

### **InTech China**

Unit 405, Office Block, Hotel Equatorial Shanghai  
No.65, Yan An Road (West), Shanghai, 200040, China  
中国上海市延安西路65号上海国际贵都大饭店办公楼405单元  
Phone: +86-21-62489820  
Fax: +86-21-62489821

© 2011 The Author(s). Licensee IntechOpen. This is an open access article distributed under the terms of the [Creative Commons Attribution 3.0 License](#), which permits unrestricted use, distribution, and reproduction in any medium, provided the original work is properly cited.