

# Role of Liver Biopsy After Liver Transplantation

Marco Carbone and James Neuberger  
*Liver Unit, Queen Elizabeth Hospital,  
United Kingdom*

## 1. Introduction

Assessment of liver histology following orthotopic liver transplantation is an essential component of management in the transplant recipient. Most programs recommend liver biopsies when there are changes in the patient's status or biochemical tests. The use of protocol allograft biopsies, that is in asymptomatic recipients with normal or near-normal liver tests, is controversial. Considerations such as potential morbidity and mortality, cost, inconvenience, use of resources, and potential impact of unexplained histopathological findings should be weighed against potential individual and societal benefits. More than one insult can contribute to late posttransplantation dysfunction and immunosuppression can influence the histological findings and the severity of many disease such as recurrent viral hepatitis, autoimmune hepatitis (AIH), and rejection. Histological analysis can help to determine the main component of injury, but careful clinicopathological correlation is needed. Biopsy interpretation should include an assessment of adequacy of the sample, and more than 6 portal tracts are considered adequate, a systematic examination, and a correlation with clinical aspects such as the original disease, immunosuppression, liver tests, viral serology, immunology and radiologic findings. Many transplant units follow center-specific criteria; however, a wide use of the standardized criteria (Anonymous, 1997; Demetris 2000) would enable centers to compare and pool results, improve management, and better understand the pathophysiology of disease mechanisms.

## 2. Early post-transplant period

Of the many causes of graft dysfunction in the early posttransplantation period, acute allograft rejection, preservation or reperfusion injury, drug-induced liver injury, viral infection and bile duct injury are the most common, and a liver biopsy may be required for their specific diagnosis and optimal management. The histological changes of preservation/reperfusion injury are uncommonly severe and typically resolve during the immediate and early posttransplant period. Acute cellular rejection (ACR) normally occurs within the first month of transplantation and liver biopsy represents a valuable tool for its diagnosis and guiding treatment. Though the histological diagnosis is often straightforward, several clinical situations can pose diagnostic challenges, such as patients with co-existing viral hepatitis and other forms of tissue injury. In the early postoperative period, transplant recipients receive many drugs that are potentially hepatotoxic, such as antibiotics, analgesics, immunosuppressive agents and total parenteral nutrition. Although the histological features of drug-induced liver injury are rarely diagnostic, recognition of drug-

induced graft damage will allow prompt withdrawal. While bacterial and fungal infection are often systemic, many viral infections directly affect the graft and usually require histology to differentiate infection from rejection and, as the two often co-exist, the histological findings will usually guide the need for any change in immunosuppression. The two opportunistic viral infections most frequently observed in liver allograft biopsies are cytomegalovirus (CMV) and Epstein-Barr virus (EBV) (Hubscher, 2006). Other opportunistic viral infections that can involve the liver allograft include adenovirus (mainly in pediatric liver transplant recipients), herpes simplex virus, varicella zoster virus, and human herpesvirus 6 (Kusne, 2006; Ohashi 2008). Most complications of the biliary tree are diagnosed radiologically, therefore liver biopsy has a limited role in this setting. Several reports have clearly indicated that serum liver tests have poor sensitivity and specificity in the diagnosis of graft dysfunction. We have found that the extent of changes seen on liver histology, evaluated by protocol liver biopsy on the 7th postoperative day and assessed using the Banff criteria, has only a weak correlation with the liver tests. Furthermore, the change in the liver test is unreliable in predicting the histological severity of graft rejection (Neuberger et al., 1998). There is no evidence that patient outcome is improved with use of early protocol biopsies. A systematic review of 15 studies including 1566 liver transplant recipients showed that 32% of the patients had histologic acute cellular rejection (ACR) on protocol biopsy without associated biochemical graft dysfunction; without additional treatment, only 14% of these patients subsequently developed biochemical graft dysfunction. The authors, therefore, advised against the early protocol biopsy, after considering the small but definite risk associated with this procedure, and suggested that liver biopsy should be delayed until patients develop biochemical graft dysfunction, unexplained fever, or other surrogate markers of rejection or other early graft harmful event (Bartlett et al., 2002).

### 3. Late post-transplant period

Allograft biopsies in the late post-transplant period may be done on a protocol basis or as part of the diagnostic work-up of patients who are experiencing biochemical or clinical graft dysfunction, for monitoring recurrence of disease and response to therapy (e.g. recurrent hepatitis C infection). A wide spectrum of histological changes has been reported in the late posttransplant period. General classification is difficult as changes may reflect a variety of factors including the indications for liver transplant, the center's policy regarding protocol liver biopsies, the consequences of differing regimens of immunosuppression and differences in describing changes. Most of the main complications that occur during the early post-transplant period can also be seen in the later period. Changes seen in late post-transplant biopsies are often complex and may reflect more than one pathological process; histology may help to identify the dominant cause of graft damage in such cases.

Protocol liver biopsies are defined as those biopsies done according to agreed-on guidelines and not in response to changes in clinical status or biochemical tests. An informal survey of 35 transplant units located in North America, Europe, and Australasia, carried out in our unit in 2007, showed that whereas 65% of units undertake protocol biopsies for patients grafted for hepatitis C virus infection, only 25% do so for patients grafted for other indications (Mells, 2008). Furthermore, protocol biopsies are done less frequently than in the past. The lack of consensus regarding the use of protocol liver biopsies is due, in part, to the risks associated with the procedure, uncertainty about the usefulness of these biopsies in patients with normal liver function tests, costs. Part of the rationale for protocol biopsies was the need to understand

the range of histological findings in the 'normal' allograft and the histological and clinical correlations; it is believed that these changes are now understood (Table 1).

Pros	Cons
Liver tests are associated with poor sensitivity and specificity in the diagnosis of graft dysfunction and provide little information on the severity of graft damage	Risk of morbidity and mortality associated with the procedure
Protocol liver biopsies are able to detect the early stage of many diseases occurring late after transplant and allow a early treatment that may avoid or delay graft injury and graft loss	The information provided by protocol biopsies can be obtained by other means
Knowledge of the histological changes may improve the understanding of the post-transplant diseases that could improve post-transplant care	Histologic findings often do not influence management when liver tests are normal and the patient is well
	High costs
	Interpretation of the biopsy may be jeopardized by differences in interpretation between observers
	Sampling variability

Table 1. Pros and Cons of a Protocol Biopsy

Percutaneous liver biopsies carry a risk of morbidity and mortality, that is relatively low, however this risk needs to be outweighed by benefits. Early studies reported a rate of major complications, represented mostly by bleeding and infection, between 0.2% and 1.79%, with a mortality rate up to 0.2% (Bubak, 1991; Chezmar, 1991; Lang, 1999; Larson, 1997; Perez Roldan, 1995; Van Thiel, 1993). The main factors associated with morbidity and mortality after a liver biopsy in the immunocompetent patient, such as the presence of a gallbladder or an unsuspected abnormal vascular anatomy or dilated bile ducts, generally do not apply to a liver transplant recipient; therefore, a lower rate of complication may be anticipated in these patients. Whether the presence of a Roux-en-Y choledochojejunostomy is associated with an increased risk of septic complication compared with duct-to-duct anastomosis (Ben-Ari, 1996; Galati, 1994) is controversial; in our center, as with many other units, a single prophylactic dose of antibiotic is given before a percutaneous liver biopsy is performed in recipients with Roux loop biliary anastomosis. Liver biopsies are relatively expensive, with a cost estimated at USD\$1,032 in those without complications and USD\$2,745 with complications (Poynard, 2004), and where resources are limited, this represents an important argument against a controversial diagnostic tool. Furthermore, the reliability of liver histology in making a specific diagnosis; this should be evaluated in terms of differences in interpretation between observers, evidenced in the assessment of hepatitis C and rejection in allograft biopsies (Demetris, 1991; Netto, 2006), and in terms of sampling variability (Maharaj, 1986; Poniachik, 1996; Ratziu, 2005; Regev, 2002); although studies of sampling variability in liver allograft biopsies have not been reported; however this is likely to be similar to that in the native liver.

The justification for doing protocol biopsies is based on many arguments:

- Liver tests (LFTs) are associated with poor sensitivity and specificity in the diagnosis of graft dysfunction and provide little information on the severity of graft damage;

- graft function is better preserved if liver damage is diagnosed and treated early;
- knowledge of the histological changes in the allograft in different clinical situations may result in better understanding of the post-transplant diseases that could improve post-transplant care.

There is a poor correlation between liver tests and histological findings in the late post-transplant setting. Thus, Berenguer reported that 11 (11.5%) of 97 recipient who were found to have abnormal histology at 1-year protocol biopsy had normal liver tests (Berenguer, 2001). Similar findings were reported with a longer follow-up of 10 years. Duclos-Valee et al, who documented recurrent autoimmune hepatitis in 7 (41%) of 17 patients and reported that in 4 (23%) of these patients the histologic findings of disease recurrence on protocol allograft biopsies preceded biochemical abnormalities by 1 to 5 years (Duclos-Valla, 2003). Sebagh et al evaluated 10-year post-OLT protocol biopsies of 134 patients and calculated that the sensitivity and specificity of normal liver tests for the detection of histologic abnormalities was only 75% and 54%, respectively. More recently, Abraham et al. evaluated 165 protocol allograft biopsies taken from 100 liver transplant patients at the time of normal LFTs and normal clinical function and evidenced as a significant fraction of protocol allograft biopsies harbor histologic (27%) and clinically significant (11.5%) abnormalities, most commonly fatty liver disease, low-grade/low-stage recurrent hepatitis C and primary biliary cirrhosis, and central venulitis, including some cases with subsequent fibrosis progression (Abraham, 2008) (Table 2).

Study	Years post-LT	Sample size	Patients with abnormal histology [n(%)]	Patients with normal LFTs and abnormal histology [n(%)]	Histologic findings
Berenguer	1	231	97 (42%)	11 (11.5%)	-
Duclos-Vallée	10	17	7 (41%)	4 (57%)	Autoimmune hepatitis
Sebagh	10	143	115 (80%)	53 (46%)	PBC, viral, CH, AIH, CR, undetermined
Abraham*	3 to 8 months (21.8%) 1 year (31.5%) 2 to 3 years (32.7%) 4 to 5 years (13.9%)	165	44 (27%)	44 (27%)	Fatty liver disease, recurrent disease (PBC, hepatitis C, sarcoidosis), Ito cell hyperplasia, central venulitis, mild acute portal rejection

\* protocol allograft biopsies were taken at the time of normal LFTs.

Abbreviations: PBC, primary biliary cirrhosis; CH, chronic hepatitis; AIH, autoimmune hepatitis; CR, chronic rejection.

Table 2. Association between liver tests and histological findings

### 3.1 Hepatitis C

Another potential indication for protocol liver allograft biopsies is represented by recurrence of hepatitis C (rHCV), that is almost universal following liver transplantation (Everhart, 1999). In addition to confirming a diagnosis of rHCV (and excluding other causes of graft dysfunction), sequentially liver biopsies are used to assess the need for treatment, disease severity and progression. The majority of studies assessing the usefulness of long-term liver biopsies have been performed in centers with a low prevalence of viral infection, and this has led to an underestimation of the clinical importance of this tool. Histological abnormalities are often present in protocol biopsies from HCV-positive patients who are clinically well with apparently normal graft function (Berenguer, 2001; Sebah, 2003) and these changes may have implications for prognosis and treatment (Roche, 2010). The posttransplant course of hepatitis C is associated with a more rapid progression of fibrosis than in the native liver, with the development of cirrhosis after 5 years in 28% of cases (Samuel, 2006). Early recognition and intervention of recipients with rapidly evolving recurrent hepatitis C following orthotopic liver transplantation (OLT) is the only practical approach to improve outcome of these patients (Gane, 2008).

Histologic changes at 1 year, such as fibrosis stage of  $>2$  or an hepatitis activity index score  $>4$ , predict the subsequent course of recurrent hepatitis C and provide not only an early indication of which patients should receive antiviral treatment (Firpi, 2004) but are also used to monitor treatment responses (Bahra, 2007). Moreover, diagnosis of HCV-related graft cirrhosis before clinical decompensation may facilitate an early referral for liver retransplantation at a stage when the probabilities of a favorable outcome are greater. Combinations of laboratory test with or without clinical parameters, direct biochemical markers of hepatic extracellular matrix turnover, and more complex assays such as FibroTest, Fibrometer, and Hepascore, have been evaluated in the non-transplant setting for the assessment of progression of fibrosis (Lok, 2005; Leroy, 2004; Imbert-Bismut, 2001; Cales, 2005; Adams, 2005) and have also more recently been used in a similar manner in liver allograft recipients (Carrion, 2010; Cholongitas, 2010). Some authors have recently developed a model, the FibroTransplant score, based on the presence/absence of HCV infection, time since transplant, alpha 2-macroglobulin, AP, total protein, INR, and glucose -  $1/(1+EXP\{-20.5+(0.99 \times \text{presence of HCV infection})+(0.008 \times \text{time since LT}) + (0.096 \times \text{total protein}) + (6.36 \times \text{international normalized ratio [INR]}) \times (0.277 \times \text{glucose}) + (0.007 \times \text{alkaline phosphatase [AP]}) + (0.97 \times \text{alpha 2-macroglobulin})\})$  - which accurately distinguished patients with mild to moderate fibrosis from those with advanced fibrosis (Beckebaum, 2010). As fibrosis progresses, total protein decreases, whereas INR and the concentration of the protease inhibitor alpha 2-macroglobulin increase; moreover, elevated alkaline phosphatase, HCV infection and diabetes have been described as risk factors for progression to severe fibrosis (Berenguer, 2000; Syn, 2007). The optimal cutoff value for diagnosis of  $F>3$  was 0.55, with a specificity of 90.2%, a sensitivity of 61.8%, a positive predictive value (PPV) of 77.2% and a negative predictive value (NPV) of 81.4%. Recently, Berres et al have shown as early serum levels of chemokines CXCL10 (interferon-inducible protein 10) independently predict the progression of liver fibrosis after LT for HCV infection (Berres, 2011). The most promising tool for non-invasive assessment of fibrosis progression in recurrent hepatitis C is the transient elastography; this is a reproducible technique that assesses liver stiffness, has been validated in patients with chronic hepatitis C for the assessment of hepatic fibrosis and can identify patients with rapidly progressive hepatitis C in the first year following OLT, differentiating them from patients with slowly progressive hepatitis C (Carrion, 2010);

however liver stiffness measurement (LSM) seems to be less reliable in the intermediate stages of fibrosis (Beckebaum, 2010), as already reported in the non-transplant setting (Foucher, 2006; Ganne-Carrie, 2006). These noninvasive methods, however, should be interpreted with caution in the transplant population as there are other possible causes of graft fibrosis, there may be atypical features, some related to the effects of immunosuppression such as fibrosing cholestatic hepatitis (FCH), and there may be a combination of hepatitis C recurrence and graft rejection, that cannot be detected unless a liver biopsy is performed. It is likely that non invasive methods will lead to a changing role for liver biopsy in the assessment of allograft damage in HCV-positive patients. These are not expected to replace liver biopsy in the immediate future, however currently they represent an additional tool capable to reduce the frequencies of biopsies for monitoring fibrotic changes during follow-up in selected populations, such as patients under anticoagulative therapy, with coagulopathy, or those declining a biopsy.

Patients undergoing liver transplantation for reasons other than HCV have not a strict need to undergo protocol liver biopsies. However, abnormal histological findings among non-HCV+ve recipients with normal aminotransferase levels are not uncommon (Ayata, 2000; Mells, 2009; Pappo, 1995; Slapak, 1997); the histological assessment of the graft using protocol biopsies in this setting may be helpful in improving the management of these patients. The more important histologic abnormalities other than HCV recurrence that may be revealed by protocol liver allograft biopsies are reported below.

### 3.2 Chronic rejection

Chronic rejection (CR) is a rare condition that affects the liver graft with a prevalence of 1-2% but it can lead to graft loss within the first 12 months of transplantation (Hubscher, 2007; Sebagh, 2003). It is characterized by obliterative arteriopathy leading to loss of medium-sized arteries, ischemic cholangiopathy, and progressive loss of interlobular and septal bile ducts extent to more than 50% of portal tracts (Demetris, 1998). However, duct loss can be patchy in distribution and the assessment of bile duct numbers should be interpreted with caution, particularly in small biopsies with fewer than 10 portal tracts. Improvements in immunosuppression have resulted, not only in a reduced prevalence of graft failure from CR, but also in a different pattern of presentation. More cases now occur later (> 12 months post transplant) with a more insidious presentation and an indolent course, in some cases running for a period of several years without progressing to graft failure (Nakazawa, 2000; Sebagh, 2003). In the early stage of chronic rejection there is a loss of bile ducts in less than 50% of portal tracts; this is characterized by inflammatory and degenerative changes in bile ducts, which have an atrophic or 'dysplastic-like' appearance associated with features of replicative senescence (Demetris, 2000). Early-stage CR is associated with normal or slightly abnormal LFTs and so is detected only by using protocol biopsies; this may be reversible simply by altering immunosuppression (IMS) (Wiesner, 1999). However whether the early recognition of chronic rejection and a prompt change in IMS have some impact on graft survival is an open question.

### 3.3 Hepatitis B

Allograft histology is not as useful in patients transplanted for HBV cirrhosis, as with HCV because the virological and serological markers highly reliable for monitoring recurrent hepatitis B. However, protocol biopsies may be useful to detect other causes of late allograft

dysfunction in patients who received a liver transplant for HBV-related cirrhosis, like chronic hepatitis (CH) despite normal liver tests and negative virological markers (Targhetta, 2006).

### **3.4 Autoimmune hepatitis**

Autoimmune hepatitis (AIH) recurs in up to 30% to 40% of patients after liver transplantation (Ayata, 2000; Reich 2000; Vogel 2004;), and if untreated may lead to loss of the graft. Protocol biopsies allow early detection of AIH in the allograft because histologic changes may precede biochemical disturbance, even by several years (Duclos-Vallee, 2003) and therefore a prompt addition or increase in corticosteroid therapy may prevent significant injury to the allograft.

### **3.5 Cholestatic liver disease**

Primary biliary cirrhosis (PBC) and Primary sclerosing cholangitis (PSC) may recur after liver transplantation (Lerut, 1988; Neuberger, 1982), although the impact of recurrent disease on long-term survival is controversial. Unlike PSC, liver biopsy represent the gold standard for the diagnosis of recurrent PBC with the histological findings of granulomatous cholangitis or florid duct lesions, since LFTs and serum AMA after transplant are not reliable and it is also important to differentiate recurrent disease from other causes of bile-duct damage. Protocol biopsies may provide early signs of recurrence of primary disease, and a early use of ursodeoxycholic acid treatment may be beneficial in the long-term, although there are no strong evidences supporting this.

### **3.6 Chronic hepatitis**

A common histological finding in late allograft liver graft is an unspecified chronic hepatitis (CH), defined as a mononuclear portal and lobular infiltrate without features of acute or chronic rejection or any other identifiable causes of graft injury (Neuberger, 2005). CH is a common finding in late allograft biopsies, occurring in up to 30% to 70% of biopsies taken after 12 months and is poorly correlated with the clinical and serologic findings (Hubscher, 1990; Mells 2009). CH is clinically important because it may be associated with progressive fibrosis which may lead to graft cirrhosis (Evans, 2006). In most of the transplant recipients CH may be related to identifiable factors such as viral infections, recurrent autoimmune diseases, de novo autoimmune hepatitis, fatty liver disease and drug toxicity (Banff Working Group, 2006; Brunt, 1999; Haydon, 2002; Hubscher, 2001; Nakhleh, 2005; Pappo, 1995; Slapak, 1997). However, many patients with CH still do not have any clear cause of graft damage. Idiopathic CH may represent a late cellular rejection from suboptimal immunosuppression, as suggested by limited evidences (Evans, 2006; Syn, 2007); this may justify changes in the IMS and a closer follow-up of these patients.

### **3.7 Withdrawal of immunosuppression**

Protocol biopsy may be a useful tool to drive the reduction of immunosuppression after transplantation. Some of the major causes of late mortality, such as renal impairment, vascular disease, and some de novo malignancies, are clearly related to immunosuppression; the absence of significant inflammation or fibrosis in a late protocol biopsy may help to identify patients in whom immunosuppression can be safely reduced or even withdrawn completely in the hope of achieving "operational tolerance" , with a long-term benefits for the patient.

#### 4. Timing of protocol liver biopsy

In HCV recipients, fibrosis of the graft progresses since the first year after transplantation with a rate of 0.2-0.3 of fibrosis units (FU)/year; the progression seems not to be linear during a 10-year follow-up, and may be accelerated in the second half. Therefore, in order to monitor the aggressiveness of recurrent disease protocol liver biopsies should be performed in those transplanted for HCV-related cirrhosis since the first year from transplant and then annually.

For non-HCV-related transplants, the usual schedule in many centers that undertake protocol biopsies is a biopsy at 1, 2 or 3, 5, 10, and 15 years (Mells, 2008); however, there are no strong evidences supporting this and the right timing remains to be assessed.

#### 5. Conclusion

Protocol allograft liver biopsies represent a useful tool in HCV-recipients for detection and follow-up of HCV recurrence.

The usefulness of long-term protocol liver biopsies in non-HCV liver transplant recipients is controversial. They may be useful to detect the early stage of many diseases occurring late after transplant, such as chronic rejection or PBC recurrence, and so allow a early treatment that may avoid or delay graft injury and graft loss. They may also represent an important tool to optimize immunosuppression management and identify recipients that might be successfully weaned. Last but not least, protocol biopsies may offer a better understanding of the allograft structure and function. However, clear evidence that these are cost-effective and improve patient and graft outcomes is lacking. Further studies are required to devise optimal algorithms for the use of liver biopsy in the assessment of the long-term liver allograft.

#### 6. References

- Adams LA, Bulsara M, Rossi E, et al. (2005) Hepascore: An accurate validated predictor of liver fibrosis in chronic hepatitis C infection. *Clin Chem*, Vol. 51, (2005), pp.(1867).
- Anonymous. (1997). Banff schema for grading liver allograft rejection: an international consensus document. *Hepatology*, Vol. 25, (1997), pp. (658-663).
- Ayata G, Gordon FD, Lewis WD, et al. (2000).Liver transplantation for autoimmune hepatitis: A long-term pathologic study. *Hepatology*. Vol. 32, (2000), pp. (185-92).
- Bahra M, Neumann UP, Jacob D, Langrehr JM, Berg T, Neuhaus R, & Neuhaus P. (2007). Fibrosis progression in hepatitis C positive liver recipients after sustained virologic response to antiviral combination therapy (interferon-ribavirin therapy). *Transplantation*, Vol. 83, (2007), pp. (351-353).
- Bartlett AS, Ramadas R, Furness S, Gane E, & McCall JL. The natural history of acute histologic rejection without biochemical graft dysfunction in orthotopic liver transplantation: a systematic review. (2002). *Liver Transpl*. Vol. 8, No12, (Dec 2002), pp. (1147-53).
- Beckebaum S, Jacob S, Klein CG, Dechêne A, Varghese J, Baba HA, Sotiropoulos GC, Paul A, Gerken G, & Cicinnati VR. (2010). Assessment of allograft fibrosis by transient elastography and noninvasive biomarker scoring systems in liver transplant patients. *Transplantation*. Vol 27, No 89, (Apr 2010), pp. (983-93).

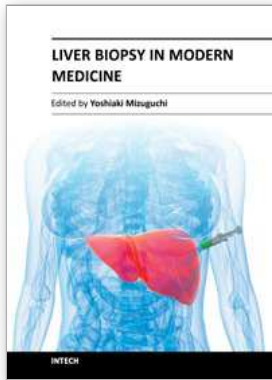


- Ben-Ari Z, Neville L, Rolles K, et al. (1996). Liver biopsy in liver transplantation: No additional risk of infections in patients with choledochojunostomy. *J Hepatol*, Vol 24, (1996), pp.(324).
- Berenguer M, Ferrell L, Watson J, et al. (2000) HCV-related fibrosis progression following liver transplantation: Increase in recent years. *J Hepatol*, Vol. 32, (2000), pp.(673).
- Berenguer M, Rayon JM, Prieto M, et al. (2001). Are posttransplantation protocol liver biopsies useful in the long term? *Liver Transpl*. Vol. 7, (2001), pp. (790-796).
- Berres ML, Trautwein C, Schmeding M, Eurich D, Tacke F, Bahra M, Neuhaus P, Neumann UP, & Wasmuth HE. (2011). Serum chemokine CXC ligand 10 (CXCL10) predicts fibrosis progression after liver transplantation for hepatitis C infection. *Hepatology*. Vol 53, No 2, (Feb 2011), pp. (596-603).
- Brunt EM, Janney CG, Di Bisceglie AM, Neuschwander- Tetri BA, & Bacon BR. (1999). Nonalcoholic steatohepatitis: a proposal for grading and staging of histological lesions. *Am J Gastroenterol*, Vol. 94, (1999), pp.(2467-2474).
- Brunt EM. (2001). Nonalcoholic steatohepatitis: definition and pathology. *Semin Liver Dis*, Vol. 21, (2001), pp. (3-16).
- Bubak ME, Porayko MK, Krom RA, et al. (1991). Complications of liver biopsy in liver transplant patients: Increased sepsis associated with choledochojunostomy. *Hepatology* Vol. 14, (1991), pp. (1063).
- Cales P, Oberti F, Michalak S, et al. (2005). A novel panel of blood markers to assess the degree of liver fibrosis. *Hepatology* ,Vol. 42 (2005), pp. (1373).
- Carrion JA, Fernandez-Varo G, Bruguera M, Garcia-Pagan JC, Garcia-Valdecasas JC, Perez-Del-Pulgar S, Fornis X, Jimenez W, & Navasa M. (2010). Serum fibrosis markers identify patients with mild and progressive hepatitis C recurrence after liver transplantation. *Gastroenterology*, Vol. 138, (2010), pp. (147-58).
- Carrion JA, Torres F, Crespo G, Miquel R, Garcia-Valdecasas JC, Navasa M, et al. (2010). Liver stiffness identifies two different patterns of fibrosis progression in patients with hepatitis C virus recurrence after liver transplantation. *Hepatology*, Vol 51, (2010), pp. (23-34).
- Chezmar JL, Keith LL, Nelson RC, et al. (1991). Liver transplant biopsies with a biopsy gun. *Radiology*, Vol. 179, (1991), pp. (447).
- Cholongitas E, Tsochatzis E, Goulis J, & Burroughs AK. (2010). Noninvasive tests for evaluation of fibrosis in HCV recurrence after liver transplantation: a systematic review. *Transpl Int*, Vol 23, (2010), pp. (861-70).
- Demetris AJ, Belle SH, Hart J, et al. (1991). Intraobserver and interobserver variation in the histopathological assessment of liver allograft rejection. The Liver Transplantation Database (LTD) Investigators. *Hepatology*, Vol. 14, (1991), pp. (751).
- Demetris AJ, Seaberg EC, Batts KP, et al. (1998). Chronic allograft rejection. *Am J Surg Pathol*, Vol. 22, (1998), pp. 28.
- Demetris A, Adams D, Bellamy C, et al. (2000). Update of the International Banff Schema for Liver Allograft Rejection: working recommendations for the histopathologic staging and reporting of chronic rejection. An International Panel. *Hepatology* Vol 31, (2000), pp.(792).
- Duclos-Vallee JC, Sebagh M, Rifai K, et al. (2003). A 10 year follow up study of patients transplanted for autoimmune hepatitis: histological recurrence precedes clinical and biochemical recurrence. *Gut*. Vol. 52, (2003), pp. (893-897).

- Evans HM, Kelly DA, McKiernan PJ, et al. (2006). Progressive histological damage in liver allografts following paediatric liver transplantation. *Hepatology*, Vol. 43, (2006), pp. (1109).
- Everhart JE, Wei Y, Eng H, et al. (1999). Recurrent and new hepatitis C virus infection after liver transplantation. *Hepatology*, Vol. 29, (1999), pp.(1220).
- Fabrega E, Castro B, Crespo J, et al. (2000). Different time course of circulating adhesion molecules and hyaluran during hepatic allograft rejection. *Transplantation*, Vol. 69, (2000), pp. (569).
- Firpi RJ, Abdelmalek MF, Soldevila-Pico C, et al. (2004). One-year protocol liver biopsy can stratify fibrosis progression in liver transplant recipients with recurrent hepatitis C infection. *Liver Transpl*, Vol. 10, (2004), pp. (1240).
- Foucher J, Chanteloup E, Vergniol J, et al. (2006). Diagnosis of cirrhosis by transient elastography (FibroScan): A prospective study. *Gut*, Vol. 55, (2006), pp. (403).
- Galati JS, Monsour HP, Donovan JP, et al. (1994). The nature of complications following liver biopsy in transplant patients with Roux-en-Y choledochojejunostomy. *Hepatology* Vol. 20, (1994), pp. (651).
- Gane EJ. (2008). The natural history of recurrent hepatitis C and what influences this. *Liver Transpl* Vol. 14, Suppl 2, (2008), pp. (36-44).
- Ganne-Carrie N, Ziol M, de Ledinghen V, et al. (2006). Accuracy of liver stiffness measurement for the diagnosis of cirrhosis in patients with chronic liver diseases. *Hepatology* Vol. 44, (2006), pp. (1511).
- Haydon G, Lalor PF, Hubscher SG, & Adams DH. (2002). Lymphocyte recruitment to the liver in alcoholic liver disease. *Alcohol*, Vol. 27, (2002), pp. (29-36).
- Hubscher SG. (1990). Chronic hepatitis in liver allografts. *Hepatology*, Vol. 12, (1990), pp. (1257).
- Hubscher SG. (2001). Recurrent autoimmune hepatitis after liver transplantation: diagnostic criteria, risk factors, and outcome. *Liver Transpl* Vol. 7, (2001), pp. (285-291).
- Hubscher SG. (2006). Recurrent and de-novo disease in the liver allograft. *Current Opinion in Organ Transplantation* Vol. 11, (2006), pp. (283-288).
- Hubscher SG, Portmann BC. (2007). Transplantation pathology. In: *MacSween's Pathology of the Liver*. 5th ed. Edinburgh: Churchill Livingstone, (2007), pp. (815-879).
- Imbert-Bismut F, Ratziu V, Pieroni L, et al. (2001). Biochemical markers of liver fibrosis in patients with hepatitis C virus infection: A prospective study. *Lancet*, Vol. 357, (2001), pp. (1069).
- Kusne S, & Blair JE. (2006). Viral and fungal infections after liver transplantation-part II. *Liver Transpl*, Vol. 12, No. 1, (2006), pp. (2-11).
- Lang M, Neumann UP, Muller AR, et al. (1999). Complications of percutaneous liver biopsy in patients after liver transplantation. *Z Gastroenterol* 1999, Vol. 37, (1999), pp. (205).
- Larson AM, Chan GC, Wartelle CF, et al. (1997). Infection complicating percutaneous liver biopsy in liver transplant recipients. *Hepatology*, Vol. 26, (1997), pp. (1406).
- Leroy V, Monier F, Bottari S, et al. (2004). Circulating matrix metalloproteinases 1, 2, 9 and their inhibitors TIMP-1 and TIMP-2 as serum markers of liver fibrosis in patients with chronic hepatitis C: Comparison with PIIINP and hyaluronic acid. *Am J Gastroenterol*, Vol. 99, (2004), pp. (271).
- Lerut J, Demetris AJ, Stieber AC, Marsh JW, Gordon RD, Esquivel CO, et al. (1988). Intrahepatic bile duct strictures after human orthotopic liver transplantation.

- Recurrence of primary sclerosing cholangitis or unusual presentation of allograft rejection? *Transpl Int*, Vol. 1, (1988), pp. (127-30).
- Lok AS, Ghany MG, Goodman ZD, et al. Predicting cirrhosis in patients with hepatitis C based on standard laboratory tests: Results of the HALT-C cohort. *Hepatology*, Vol. 42, (2005), 282.
- Maharaj B, Maharaj RJ, Leary WP, et al. (1986). Sampling variability and its influence on the diagnostic yield of percutaneous needle biopsy of the liver. *Lancet*, Vol. 1, (1986), pp. (523).
- Mells G, & Neuberger J. (2008). Protocol liver allograft biopsies. *Transplantation*. Vol. 85, No. 12, (Jun 2008) pp.(1686-92).
- Mells, Neuberger J. (2009). Late Protocol Liver Biopsies in the Liver Allograft: A Neglected Investigation?. *Liver Transplantation*, Vol15, (2009), pp. (931-938).
- Nakazawa Y, Jonsson JR, Walker NI, Kerlin P, Steadman C, Lynch SV, Strong RW, Clouston AD. (2000). Fibrous obliterative lesions of veins contribute to progressive fibrosis in chronic liver allograft rejection. *Hepatology*, Vol. 32, (2000), pp. (1240-1247).
- Nakhleh RE, Krishna M, Keaveny AP, Dickson RC, Rosser B, Nguyen JH, Steers JL. (2005). Review of 31 cases of morphologic hepatitis in liver transplant patients not related to disease recurrence. *Transplant Proc*, Vol 37, (2005), pp. (1240-1242).
- Netto GJ, Watkins DL, Williams JW, et al. (2006). The hepatitis C 3 trial group. interobserver agreement in hepatitis C grading and staging and in the Banff grading schema for acute cellular rejection: the "hepatitis C 3" multi-institutional trial experience. *Arch Pathol Lab Med*, Vol. 130, (2006), pp. (1157).
- Neuberger J, Portmann B, Macdougall BR, Calne RY, Williams R. (1982). Recurrence of primary biliary cirrhosis after liver transplantation. *N Engl J Med*, Vol. 306, (1982), pp. (1-4).
- Neuberger J., Wilson P., & Adams D. (1998) Protocol liver biopsies: the case in favour. *Transplant Proceeding*, Vol. 30, No. 4, ( Jun 1998), pp. (1497-9).
- Neuberger J. (2003). Recurrent primary biliary cirrhosis. *Liver Transpl* 2003;Vol. 9, (2003), pp. (539).
- Neuberger J. (2005). Chronic allograft dysfunction: diagnosis and management. Is it always progressive? *Liver Transpl* , Vol. 11, (2005), pp. (63).
- Ohashi M, Sugata K, Ihira M, et al. (2008). Human herpesvirus 6 infection in adult living related liver transplant recipients. *Liver Transpl*, Vol.14, No.1, (2008), pp. (100-109).
- Pappo O, Ramos H, Starzl TE, et al. (1995). Structural integrity and identification of causes of liver allograft dysfunction occurring more than 5 years after transplantation. *Am J Surg Pathol* , Vol. 19, (1995), pp. (192).
- Perez Roldan F, Banares R, Clemente G, et al. (1995). Severe complications of percutaneous hepatic biopsy in patients with orthotopic liver transplantation. *Gastroenterol Hepatol* 1995; Vol. 18, (1995), pp (410).
- Perkins JD, Nelson DL, Rakela J, et al. (1989). Soluble interleukin 2 receptor level in liver allograft recipients: an indicator of rejection. *Transplant Proc* 1989;Vol. 21, (1989), pp. (2275).
- Piccinino F, Sagnelli E, Pasquale G, et al. (1986). Complications following percutaneous liver biopsy. A multi-centre retrospective study on 67,276 biopsies. *J Hepatol* 1986; Vol. 2, (1986), pp. (165).

- Poniachik J, Bernstein DE, Reddy KR, et al. (1996). The role of laparoscopy in the diagnosis of cirrhosis. *Gastrointest Endosc*, Vol. 43, (1996), pp.(568).
- Poynard T, Imbert-Bismut F, Ratzu V (2004). "Serum markers of liver fibrosis". *Hepatology Reviews*, Vol 1, (2004), pp. (23-31).
- Ratzu V, Charlotte F, Heurtier A, et al. (2005). Sampling variability of liver biopsy in nonalcoholic fatty liver disease. *Gastroenterology*, Vol. 128, (2005), pp. (1898).
- Regev A, Berho M, Jeffers LJ, et al. (2002). Sampling error and intraobserver variation in liver biopsy in patients with chronic HCV infection. *Am J Gastroenterol*, Vol. 97, (2002), pp. (2614).
- Reich DJ, Fiel I, Guarrera JV, et al. (2000). Liver transplantation for autoimmune hepatitis. *Hepatology* 2000; Vol. 32, (2000), pp. (693).
- Roche B, Samuel D. (2010). Hepatitis C virus: up to the minute. *Liver Transpl*, Vol. 16, (2010), pp. (S26-S35).
- Samuel D, Fornis X, Berenguer M, Trautwein C, Burroughs A, Rizzetto M, et al. (2006). Report of the monothematic EASL conference on liver transplantation for viral hepatitis (Paris, France, January 12-14, 2006). *J Hepatol* Vol. 45, (2006), pp. (127-143).
- Sebagh M, Rifai K, Feray C, Yilmaz F, Falissard B, Roche B, Bismuth H, Samuel D, & Reynes M. (2003). All liver recipients benefit from the protocol 10-year liver biopsies. *Hepatology* Vol. 37, (2003), pp. (1293-1301).
- Slapak GI, Saxena R, Portmann B, Gane E, Devlin J, Calne R, Williams R. (1997). Graft and systemic disease in long-term survivors of liver transplantation. *Hepatology*, Vol 25, (1997), pp. (195-202).
- Syn W-K, Nightingale P, Gunson B, et al. (2007). Natural history of unexplained chronic hepatitis after liver transplantation. *Liver Transpl*, Vol. 13, (2007), pp. (984).
- Targhetta S, Villamil F, Inturri P, et al. (1997). Protocol liver biopsies in longterm management of patients transplanted for hepatitis B-related liver transplantation. *Hepatology*, Vol. 5, (1997), pp. (195-202).
- Trull AK, Facey SP, Rees GW, et al. (1994). Serum alpha-glutathione Stransferase—a sensitive marker of hepatocellular damage associated with acute liver allograft rejection. *Transplantation*, Vol. 58, (1994), pp. (1345).
- Van Thiel DH, Gavaler JS, Wright H, et al. (1993). Liver biopsy. Its safely and complications seen at a liver transplant center. *Transplantation*, Vol. 55, (1993), pp.(1087).
- Vogel A, Heinrich E, Bahr MJ, et al. (2004). Long-term outcome of liver transplantation for autoimmune hepatitis. *Clin Transplant*, Vol.18, (2004), pp. (62).
- Weisner RH, Batts KP, Krom RAF. Evolving concepts in the diagnosis, pathogenesis, and treatment of chronic hepatic allograft rejection. *Liver Transpl Surg*, Vol. 5, (1999), pp. (388).



## **Liver Biopsy in Modern Medicine**

Edited by Dr. Yoshiaki Mizuguchi

ISBN 978-953-307-883-0

Hard cover, 378 pages

**Publisher** InTech

**Published online** 10, October, 2011

**Published in print edition** October, 2011

Liver biopsy, first performed by Paul Ehrlich in 1883, remains an important diagnostic procedure for the management of hepatobiliary disorders and the candidate/donated organ for transplantation. The book "Liver biopsy in Modern Medicine" comprises 21 chapters covering the various aspects of the biopsy procedure in detail and provides an up-to-date insightful coverage to the recent advances in the management of the various disorders with liver biopsy. This book will keep up with cutting edge understanding of liver biopsy to many clinicians, physicians, scientists, pharmaceuticals, engineers and other experts in a wide variety of different disciplines.

### **How to reference**

In order to correctly reference this scholarly work, feel free to copy and paste the following:

Marco Carbone and James Neuberger (2011). Role of Liver Biopsy After Liver Transplantation, Liver Biopsy in Modern Medicine, Dr. Yoshiaki Mizuguchi (Ed.), ISBN: 978-953-307-883-0, InTech, Available from: <http://www.intechopen.com/books/liver-biopsy-in-modern-medicine/role-of-liver-biopsy-after-liver-transplantation>

# **INTECH**

open science | open minds

### **InTech Europe**

University Campus STeP Ri  
Slavka Krautzeka 83/A  
51000 Rijeka, Croatia  
Phone: +385 (51) 770 447  
Fax: +385 (51) 686 166  
[www.intechopen.com](http://www.intechopen.com)

### **InTech China**

Unit 405, Office Block, Hotel Equatorial Shanghai  
No.65, Yan An Road (West), Shanghai, 200040, China  
中国上海市延安西路65号上海国际贵都大饭店办公楼405单元  
Phone: +86-21-62489820  
Fax: +86-21-62489821

© 2011 The Author(s). Licensee IntechOpen. This is an open access article distributed under the terms of the [Creative Commons Attribution 3.0 License](#), which permits unrestricted use, distribution, and reproduction in any medium, provided the original work is properly cited.