

# Laparoscopic Varicocelectomy

Ali Shamsa

*Professor of Urology and Kidney Tx  
Mashhad University of Sciences  
Iran*

## 1. Introduction

Varicocele is dilatation of pampiniform plexus in the scrotum. It is one of the most common causes of male infertility. The aim of this chapter is the evaluation of the role of laparoscopy in varicocele treatment; however, because of high incidence of this disease we will discuss it in brief.

## 2. History

Celsus, in the first century, found that varicocele makes testicular atrophy. Abol-ghasem Khalaf Zahravi (Albucasis) mentioned this subject and added that my teacher (Celsus) suggested orchidectomy for testis atrophy due to varicocele through scrotal incision parallel to the penis (1).

Toullouch published a paper in 1952 about an infertile man with bilateral varicocele. He operated on him, and the patient became fertile. Then after two children he came in for vasectomy (2).

## 3. Vasculature

The main artery of the testes arises from the aorta. This artery communicates to the other arteries like cremaster and vasal arteries at the internal ring (3).

The main testicular vein has a high anastomotic condition which is called the internal spermatic vein. It has some communication with external pudendal, cremasteric and vasal veins (3).

The left internal spermatic vein drains to the left renal vein just opposite to the adrenal vein at a rectangular angle, but the right internal spermatic vein drains to the inferior vena cava, 4-5 cm below the renal vein (4).

## 4. Diagnosis

Physical exam is still the key to diagnosis of varicocele. However, in obese patients or during cold weather or for any other doubt, sonography, especially color Doppler sonography, is indicated. Our study showed that the standing position with and without Valsalva maneuver and looking for reflux to be the choice procedure for the diagnosis of varicocele (5).

## 5. Grading

Clinically, there are three grades for varicocele.

Grade I. The patient is standing and varicocele appears while the scrotum is palpated and Valsalva maneuver is done.

Grade II. Varicocele appears while the scrotum is palpated without Valsalva maneuver.

Grade III. Varicocele appears as a "bag of worms" while the patient stands, without Valsalva and palpation.

## 6. Incidence and laterality

Left sided varicocele is more common than the right side (85% vs. 11.2-25%, 6-7). The use of ultrasonography incidence of bilateral varicocele is more common than before. Our study on diagnosis of suspected varicocele with ultrasonography among 100 patients showed bilateral varicocele was 87%, left side 12%, and only right side 1% (5). Incidence of varicocele among young patients is 8-20%, but in infertile cases it is up to 40% (7-8).

The reason for high incidence of varicocele in the left side may be the longer left spermatic vein and its attachment to the left renal vein with a perpendicular angle just opposite the adrenal vein established behind the descending colon.

## 7. Etiology

Etiology of varicocele is not really known. The most acceptable theory is absence or insufficiency of internal spermatic vein valves and resulting venous reflux with its consequent results. But Shafik (1973) suggested that varicocele is the result of cremasteric weakness and made scrotal plication for its treatment (9).

Renogonadal bypass and nutcracker phenomenon is another theory for varicocele appearance.

## 8. Effect of varicocele on spermatogenesis

Now, most researchers believe that varicocele has some adverse effect on spermatogenesis. It is said that retrograde venous flow increase the scrotum temperature up to 2.5 deg. C. (10), and this increased temperature change stagnation of blood and decreases blood flow from the scrotum end to decrease oxygen and finally decrease maturation of sperm at the epididymis (7).

Retrograde of adrenal metabolites through left internal spermatic vein, which have serotonin, can decrease spermatogenesis as well. It is suggested that serotonin can increase prostaglandin production and affect spermatogenesis.

Recent study by Benof et al (11) showed increased cadmium, even in unilateral varicocele, can accumulate bilaterally and induce apoptosis, decreasing sperm concentration.

## 9. Symptoms and siepididymisgns

The most important symptom of varicocele is infertility. From 21 March 1990 until 20 March 2003 we operated on 1,711 patients. The operation was done because of infertility in 91.7%. Dull ache and heavy sensation (48%) were another symptom. We also found two additional symptoms: early ejaculation and spouse abortion.

In one study in the city of Kerman, Iran, the incidence of spontaneous abortion was 12% (12), but it was 59% ( $P < 0.05$ ) among 117 patients with varicocelectomy (from Sept. 1997). From September 1977 we asked about early ejaculation. 499 (58%) out of 862 varicocele patients had early ejaculation. The incidence of early ejaculation in our population was 27% ( $P = 0.000$ ) (13).

Three months postoperatively, 206 out of 499 patients that came for follow up 154 (75%) had improvement (6).

Recently we are conducting a research in our IVF Center (Montaserieh) on varicocele and DNA fragmentation on sperm of spouses with their wives' history of abortion. Varicocelectomy can decrease DNA fragmentation in most cases (not published data).

It is believed that varicocele can effect on hypothalamus - hypophyse axis (14). In this regard it decreases Sertoli cell and Leydig cell functions (15).

Sometimes we diagnosed high grade varicocele incidentally, without any symptoms and with children.

## 10. Treatment

### 10.1 Indication for treatment

Not all varicoceles need treatment. We have seen, as we mentioned earlier, that, varicoceles with no symptoms: i.e. infertility, pain, sperm abnormality and testicular atrophy, do not need intervention.

There are different treatments for a varicocele, including varicocelectomy, sclerotherapy and recently laparoscopy (16-17). Open varicocelectomy and sclerotherapy is beyond the scope of this chapter. So we will focus on laparoscopic varicocelectomy.

In 1991 Aaberge et al introduced laparoscopic varicocelectomy as the new and less invasive treatment for varicocele (18). In 1999 Piskun and Rajpal introduced laparoendoscopic single site (LEES) surgery for cholecystectomy (19). This newer technique is even less invasive than conventional laparoscopy, and it is safe and effective with a single 10 - 15mm incision. But it needs more cases and comparison with conventional laparoscopy (20). For this reason we describe the conventional laparoscopic varicocelectomy.

### 10.2 Technique

Patient in supine position and under general anesthesia received by nasogastric tube and urethral Foley catheter. A one-cm transverse incision is made immediately above the umbilicus, and then fascia is opened transversally. We prefer Hasson (open) rather Verese (Blind) technique. Before the insertion of a 10 mm trocar, we grasp the fascia with 0-nylon. After insertion of the trocar, the abdomen is filled with Co2 gas (# 15 mm Hg). At this time, a 10 mm telescope is inserted into the first trocar. Now we can see abdominal organs including the internal spermatic vein.

After that two 5mm trocars are inserted through the midclavicular line at both sides of the umbilicus. Grasping with one hand and using scissors in the other hand, two perpendicular incisions are made in the peritoneum overlying the left or right internal spermatic veins. By lifting the vascular mass, arterial and lymphatic component should be separated from the vein(s) (fig.1-3). Then veins are ligated by one or two clips (fig.4).

We do not recommend cauterizing or suturing or even cutting the veins, to save time.

When a 5 mm clip- applicator is not available, it is possible to change the 10 mm telescope to a 5 mm telescope and 10 mm clips applied.

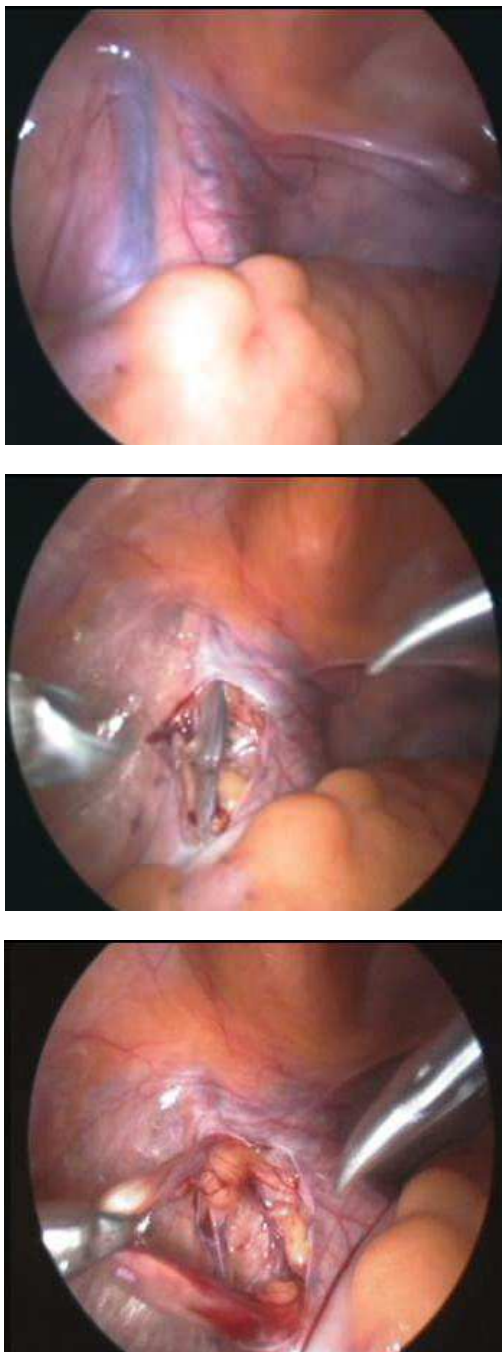


Fig. 1-3. Right int. spermatic vein

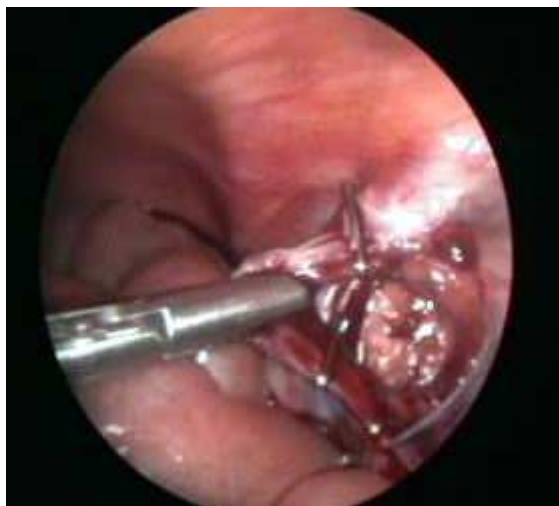

Fig. 4. Left int. spermatic vein after clipped applied

### 11. Our study

We conducted a randomized study comparing three different forms of varicocelectomy: Laparoscopy, open with general anesthesia and open with local anesthesia. We allocated 30 patients with bilateral varicoceles in each group. Our aim was to compare operative time, complications, and sperm analysis after surgery. SPSS Software was used for data analysis. P value <.05 considered significant (21).

### 12. Results

The mean operative times were  $3.0 \pm 5.5$ ,  $27.0 \pm 3.5$  and  $38.0 \pm 1.8$  minutes respectively ( $P = .02$ ).

### 13. Complications

Regarding complications, it occurred only in the laparoscopic group (subcutaneous emphysema (one case).

Post operative complications were summarized in table I.

Complication	Laparoscopy	Open With General Anesthesia	Open With Local Anesthesia
Hydrocele	1 (3.3)	0	0
Scrotal edema	4 (13.3)	3 (10.0)	0
Orchitis	1 (3.3)	1 (3.3)	0
Wound infection	0	3 (10.0)	0
Hematoma	0	0	1 (3.3)
Recurrence	2 (6.7)	0	0

\*Values in parentheses are percents.

Table 1. Varicocelectomy Complications With Different Surgical Methods\*

Sperm count after 3 months with analysis t test did not show any significant changes among the three groups, except slight improvement of sperm morphology in Group 3. It is also summarized in Table 2(21).

Varicocelectomy	Before Treatment	After Treatment	P
<b>Laparoscopy</b>			
Sperm count, $\times 10^6/\text{mL}$	58 $\pm$ 42	54 $\pm$ 33	.65
Sperm motility, %	73 $\pm$ 49	92 $\pm$ 100	.26
Sperm morphology, %	69 $\pm$ 52	74 $\pm$ 41	.31
<b>Open with general anesthesia</b>			
Sperm count, $\times 10^6/\text{mL}$	40 $\pm$ 25	34 $\pm$ 20	.26
Sperm motility, %	35 $\pm$ 20	35 $\pm$ 20	.91
Sperm morphology, %	31 $\pm$ 16	38 $\pm$ 18	.07
<b>Open with local anesthesia</b>			
Sperm count, $\times 10^6/\text{mL}$	51 $\pm$ 23	47 $\pm$ 25	.31
Sperm motility, %	55 $\pm$ 19	58 $\pm$ 19	.18
Sperm morphology, %	51 $\pm$ 27	57 $\pm$ 22	.045

Table 2. Semen Analysis Results With Different Varicocelectomy Methods

Our results showed the Complications, cost and also operative time, laparoscopy is not superior to other methods of varicocelectomy. It is similar to other studies (22).

We recommend laparoscopic approach for obese patients, recurrent (or persistent) varicocele, history of inguinal surgery and patients who had other diseases (renal cyst, inguinal hernia, non palpable testis, etc).

One important notice: Bilateral varicocele is certainly more common than other urologic diseases that need laparoscopy surgery. So for gaining experience and increasing the learning curve, conventional laparoscopic varicocelectomy or LEES has this potential value and are good options.

We do not advocate the laparoscopic approach for unilateral varicocele except when it is concomitant with other mentioned pathology.

## 14. Conclusion

Laparoscopic varicocelectomy is recommended for infertile men with bilateral varicoceles. It is preferred in obese patients, history of inguinal surgery and or other diseases (renal cyst, inguinal hernia, non palpable testis, etc).

LEES varicocelectomy is promising but needs either more experience or more patients.


## 15. References

- [1] Spink MS, Lewis GL. *Albucasis on surgery and instruments*. Great Britain. Oxford university press, 1927:438.
- [2] Tulloch WS. Varicocele in subfertility: Results of treatment. *Br Med J* 1955;4935(1):356-8.
- [3] Brooks J.D., *Anatomy of the Lower Urinary Tract and Male Genitalia*, in Wein A.J.(Eds) *Campbell-Walsh Urology*. Philadelphia, Saunders, 2007:38-77.
- [4] Redman J.F., *Anatomy of the Genitourinary System*, in Gillenwater J.Y., et.al.(Eds) *Adult and Pediatric Urology*. St.Louis. Mosby ,1996:3-61.

- [5] Oraei Abbasian F., comparison of two methods of varicocele diagnosis (upper and supine positions) with color Doppler ultrasonography, thesis for the degree of doctorate in medicine, supervised by Shamsa A., Nekuei C., Shakeri M.S. 2010, MUMS.
- [6] Shamsa A., Nademi M., Aqaei M., Nouraei Fard A., Molaei M., Complications and the effect of varicocelectomy on semen analysis, fertility, early ejaculation and spontaneous abortion Saudi J Kidney Dis Transplant. 2010;21: 6; 1100-1105.
- [7] Shamsa A. Varicocele in Iranian Textbook of Urology, (eds) Simforoosh N., Nouralizadeh A.; Tehran, Behine, 2007, vol 2: 1147-1153
- [8] Goldstein M. Surgical management of male infertility and other scrotal disorders. In: Walsh P, Wein A, Kavoussi L, Novick A, Partin A, Peters C. (eds). Campbell's Urology. 8th ed. Philadelphia. Saunders, 2002. 1532-83.
- [9] Shafik A. The cremasteric Muscle: Role in varicoelogenesis and in thermoregulatory function of the testicle. Invest Urol 1973;11 (2):92-7.
- [10] Marmar JL. Varicocele and male infertility: Part II the pathophysiology of varicoceles in the light of current molecular and genetic information. Hum Reprod Update 2001;7(5):461-72.
- [11] Benoff SH, Millan C, Hurley IR, Napolitano B, Marmar JL. Bilateral increased apoptosis and bilateral accumulation of cadmium in infertile men with left varicocele. Hum Reprod 2004;19(3):616-27.
- [12] Habibzadeh V. Incidence of spontaneous abortion in women referred to Kerman health centers. J Shahid Sadoughi Univ Med Sci Health Serv. 2001;3(8):88-92.
- [13] Hoseini S, Beigi D, Khoshabi K. Pervalece of early ejaculation among infertile men referred to Royan institute and society men. Articles abstract of Iran's 5th congress of Urology, Tehran. Iran university of medical sciences, p75,1381.
- [14] Comhair F., Vermeulen A., Hormonal Testicular Function in patients with Varicocele, in Jecht E.W., Zeitler E. (Eds): varicocele and male infertility. Berlin, Springer Verlag, 1982: 110-116.
- [15] Shamsa A review of 427 cases of Varicocele, Medical Journal of The Islamic Republic of Iran 1988;2(2): 115-118.
- [16] Hassan JM, Adams MC, Pope J Ct, Demarco RT, Brock JW, 3rd Hydrocele formation following laparoscopic varicocelectomy. J Urol. 2006;175:1076-9.
- [17] Misseri R, Gershbein AB, Horowitz M, Glassberg KI. The adolescent varicocele. II: the incidence of hydrocele and delayed recurrent varicocele after varicocelectomy in a long-term follow-up. BJU Int., 2001;87:494-8.
- [18] Aaberg RA, Vancaillie TG, Schuessler WW. Laparoscopic varicocele ligation: a new technique, Fertil Steril. 1991;56:776.
- [19] Piskun G, Rajpal S. Transumbilical laparoscopic cholecystectomy utilizes no incisions outside the umbilicus. J Laparoendosc Adv Surg Tech A. 1999;9:361-364.
- [20] Kawauchi A, Naitoh Y., Miki T. Laparoendoscopic single-site surgery for pediatric patients in urology; Current Opinion in Urology, 2011,21:303-308.
- [21] Shamsa A, Mohammadi L, Abolbashari M, Shakeri MT, Shamsa S. Comparison of open and laparoscopic varicocelectomies in terms of operative time, sperm parameters, and complications. Urol J. 2009 ;6(3):170-5.

- [22] Diegidio P, Jhaveri JK, Ghannam S, Pinkhasov R, Shabsigh R, Fisch H. Review of current varicoelectomy techniques and their outcomes. *BJU Int.* 2011 Mar 24. doi: 10.1111/j.1464-410X.2010.09959.x. [Epub ahead of print] [PubMed]





## **Advanced Laparoscopy**

Edited by Prof. Ali Shamsa

ISBN 978-953-307-674-4

Hard cover, 190 pages

**Publisher** InTech

**Published online** 30, September, 2011

**Published in print edition** September, 2011

The present book, published by InTech, has been written by a number of highly outstanding authors from all over the world. Every author provides information concerning treatment of different diseases based on his or her knowledge, experience and skills. The chapters are very useful and innovative. This book is not merely devoted to urology sciences. There are also clear results and conclusions on the treatment of many diseases, for example well-differentiated papillary mesothelioma. We should not forget nor neglect that laparoscopy is in use more extensively than before, and in the future new subjects such as use of laparoscopy in treatment of kidney cysts, simple nephrectomy, pyeloplasty, donor nephrectomy and even robotic laparoscopy will be researched further.

### **How to reference**

In order to correctly reference this scholarly work, feel free to copy and paste the following:

Ali Shamsa (2011). Laparoscopic Varicocelectomy, *Advanced Laparoscopy*, Prof. Ali Shamsa (Ed.), ISBN: 978-953-307-674-4, InTech, Available from: <http://www.intechopen.com/books/advanced-laparoscopy/laparoscopic-varicocelectomy>

# **INTECH**

open science | open minds

### **InTech Europe**

University Campus STeP Ri  
Slavka Krautzeka 83/A  
51000 Rijeka, Croatia  
Phone: +385 (51) 770 447  
Fax: +385 (51) 686 166  
[www.intechopen.com](http://www.intechopen.com)

### **InTech China**

Unit 405, Office Block, Hotel Equatorial Shanghai  
No.65, Yan An Road (West), Shanghai, 200040, China  
中国上海市延安西路65号上海国际贵都大饭店办公楼405单元  
Phone: +86-21-62489820  
Fax: +86-21-62489821

© 2011 The Author(s). Licensee IntechOpen. This chapter is distributed under the terms of the [Creative Commons Attribution-NonCommercial-ShareAlike-3.0 License](#), which permits use, distribution and reproduction for non-commercial purposes, provided the original is properly cited and derivative works building on this content are distributed under the same license.