

Laparoscopy in Children and Infants

Ngozi Joy Nwokoma¹ and Thomas Tsang²

¹Addenbrooke's Hospital, Cambridge

²Norfolk and Norwich University Hospital
United Kingdom

1. Introduction

The “*first do no harm*” ethics of medical care has its age-long influence manifested in the continual search for the least invasive method of administering treatment to the patient. The advancement of the minimally invasive surgery has therefore been a very welcome development in surgical specialities with paediatric surgery not left behind in this quest.

Laparoscopy is the visual inspection of the peritoneal cavity aided by a telescope and facilitated by the creation of a pneumoperitoneum. The earliest description of diagnostic laparoscopy was by Cortesi et al., (1976). However, diagnostic laparoscopy was originally introduced in 1910 by the Swedish physician - Hans Christian Jacobeus who published his results from diagnostic laparoscopy and thoracoscopic procedures (Badani et al., 2006). Therapeutic laparoscopy was made popular following the description of laparoscopic appendicectomy by a German gynaecologist - Kurt Semm in 1983 (Semm, 1983) and of laparoscopic cholecystectomy by the German surgeon - Erich Muhe in 1985 (Badani et al., 2006). Advancements in development of instrument components particularly illumination, optics, fiberoptic transmission, insufflation and video-apparatus have progressed alongside development of techniques for minimal access into the abdominal cavity. Development of paediatric laparoscopy was marked by Gans in his contribution to the development of paediatric instruments in 1970 (Tantoco et al., 2005).

Laparoscopy offers the surgeon the option of achieving high standard surgical treatment while keeping tissue trauma to a minimum. Since the early 20th century, laparoscopic approach to surgical treatment has gained increasing popularity. However, the paediatric surgical subspecialty has lagged behind adult surgery in exploring the advances offered by laparoscopy. This is largely because some common conditions in adults like cholelithiasis which opened the gateway to the explosion in the application of laparoscopic surgery are uncommon in the paediatric age group. In addition, the low volume of corresponding conditions in the paediatric population has made it unattractive to companies involved in manufacturing and developing the paediatric laparoscopic equipment. For example, laparoscopic cholecystectomy which is a relatively non-complex procedure developed faster in the adult population than in children because of the lower case volume in the latter. Higher case volume equates to higher demand which attracts investors. The converse being the case in the paediatric population has hindered enthusiasm among product developers.

Development of laparoscopy in the paediatric population has followed the same course as the development and modification of the laparoscopic apparatus to fit this patient group. Advances in paediatric anaesthetic monitoring and support equipment have also made a huge contribution

to this development. The result is an increasingly wider application to the use of laparoscopy in children. Jen and Shew (2010) observed an increase in the utilization of laparoscopy for the management of appendicitis in children from 18.6% in 1999 to 52.4% in 2006. Several diagnostic and therapeutic procedures have been demonstrated to be safely and efficiently undertaken with laparoscopy with several advantages over traditional methods of approach.

The development of 3mm instruments has pushed the boundaries of diagnostic, as well as therapeutic laparoscopy into the infant and neonatal population. In the investigation of the neonate with abdominal distension, free gas on plain abdominal radiograph in the absence of corresponding clinical or physiological signs of peritonism, laparoscopy has been used to evaluate the condition and arrive at more focused specific management decisions with improved outcome. In our experience an uncommon case of neonatal perforated appendicitis was diagnosed and treated at laparoscopy with quick recovery and discharge home within 48hours. Should the same neonate have had laparotomy for presumed bowel perforation from unknown cause with the consequent greater degree of bowel handling, resultant postoperative ileus and high doses of opiate, recovery would have been slower with longer duration of hospitalisation.

Many procedures can be performed safely in children through small incisions, for example the repair of inguinal hernia. This has contributed to the reluctance of paediatric surgeons to embrace the laparoscopic approach. However, better access, panoramic visual field, quick recovery and reduced complication rates still put laparoscopy ahead in these procedures.

2. Advantages of paediatric laparoscopy

There is growing evidence that laparoscopy has more advantages and benefits to offer children than was earlier presumed to be the case. These benefits have been widely reported (Table 1) and significantly outweigh any concerns regarding the technical difficulties (Table 2) which are largely overcome with increasing experience and further developments in the laparoscopic equipment.

Reduced wound size
Reduced wound trauma
Less wound infection
Less incisional hernia
Less wound dehiscence
Less wound pain
Early mobilisation
Less bleeding
Less heat loss from tissue
Wider field of vision
Less postoperative adhesions
Less postoperative ileus
Earlier return to usual activities
Earlier commencement of chemotherapy
Less respiratory complications
Less risk of thromboembolism
Reduction in nerve entrapment

Table 1. Advantages of laparoscopy

Loss of tactile sensation
Loss of spatial and depth orientation
Two-dimensional imaging
Difficulty with control of bleeding
Difficulty with extraction of resected tissue

Table 2. Technical difficulties of laparoscopy

Some of these benefits have been published in our publications (Rehman et al., 2010; Panteli et al., 2009; Nwokoma et al., 2009a, Nwokoma et al., 2009b). The age-long principles of safe surgery include adequate access, adequate target organ visualisation and minimal tissue trauma. In children, access can be quite a challenge because of the smaller height/width ratio of the abdomen particularly observed in those under 7 years of age. In many cases, however long the incision, gaining access to the target organ, or indeed to the four quadrants of the abdomen and pelvis, can be very difficult. Laparoscopy offers the paediatric surgeon the advantage of been able to visualise these areas while reducing the trauma usually consequent upon use of large abdominal wall incisions. In conventional or open surgery, access is also facilitated by the use of retractors. The purpose built retractors for the abdominal wall have meant the junior trainees can be spared the arduous task of holding retractors for prolonged periods of time. Despite these, quite often a trainee or two are required to further improve access by using less heavy retractors at different stages of an abdominal operation. In children, particularly infants, this challenge is heightened by the fact that the small size precludes access and space for more than one surgeon to be actively involved from any one side of the patient.

In the repair of paediatric inguinal hernia, laparoscopy offers significant advantage over conventional methods. There is a clear visualisation of the vas deferens and testicular vessels with reduction in the risk of injury to these structures. Following reduction of an incarcerated hernia when the cord tissues are oedematous and friable with higher risk of complications, laparoscopic approach offers a safer alternative with the added benefit of inspection of reduced structures. The senior author's experience of recurrence following laparoscopic repair of inguinal hernia is less than 1%. On the other hand, the reported overall recurrence rate in children following open hernia repair is 0.3 – 3.8% and up to 8.6% in neonates (Morecroft et al., 1993; Nagraj et al., 2006; Parkinson & Pierro, 2006). Laparoscopic approach to inguinal hernia repair also allows the assessment of the contralateral side and closure of any patent processus vaginalis. This is particularly important for infants in whom the rate of synchronous hernia discovered during laparoscopy is up to 40%. Though there is no clear evidence on how many of these will eventually manifest as clinical hernia, repair of a patent processus vaginalis discovered intra-operatively is highly recommended. This is due to the fact that documented risk of metachronous hernia is 10% in children under 2years and up to 68% in infants (Parkinson & Pierro, 2006). Some cases of hernia can present unusual challenges which are best tackled laparoscopically. Interestingly, Lee and Dubois (2000) noted a case of recurrent inguinal hernia following laparoscopic herniotomy to be due to a direct hernia. The laparoscopic approach facilitated appropriate diagnosis and treatment, avoiding the unnecessary exploration for a presumed recurrent patent processus vaginalis. In another case, we found a male infant with bilateral inguinal hernia to have rudimentary female internal sex organs; in such cases, laparoscopy is highly valuable. In addition, the senior author reported the first case of emergency laparoscopic repair of Amyand's hernia in an 8-week-old infant (Rehman et al., 2010).

For many years paediatric surgeons argued about the safety, efficiency and cost implications of laparoscopy. With the development of experience and equipment, the laparoscopic

approach has been demonstrated to be a safe, cost-effective and efficient way of managing increasingly complex procedures in children. We demonstrated that laparoscopic approach offered significant advantages with better outcomes than open approach in paediatric advanced appendicitis with less wound-related complications: 8.6% versus 17.6% (Nwokoma et al., 2009a). In a different study, we also demonstrated that the risk of developing post-operative adhesions was much less following laparoscopic procedures than open approach, with a rate of adhesions comparable to those who have never had any abdominal surgery; 10% versus 10-28% (Nwokoma et al., 2009b).

Trauma resulting from establishing access to the abdominal cavity contributes greatly to postoperative pain, delayed recovery, delayed discharge, respiratory complications and delayed return to usual activity. This is minimised by laparoscopy with corresponding advantages. The old assumption that neonates had impaired perception of pain and physiological response has been set aside in light of evidence to the contrary (Anand et al., 1985; Anand & Hickey, 1987; Anand & Aynsley-Green, 1988). As in older children neonatal post-operative pain is also minimised by laparoscopy while the children are spared the need for strong analgesia, risk of over sedation and respiratory depression to which younger infants are particularly susceptible.

3. Laparoscopic procedures in children

Some surgical procedures that have been safely and efficiently accomplished through laparoscopic approach in children are enumerated in anatomical and regional groups below.

3.1 Upper gastrointestinal tract

- Ladd's procedure for intestinal malrotation
- Pylomyotomy
- Fundoplication
- Reduction of intussusception
- Gastrostomy tube insertion
- Jejunostomy
- Heller myotomy
- Treatment of duodenal atresia
- Treatment of Jejunal atresia
- Intestinal duplication cyst
- Torsion of appendix epiploicae
- Adhesiolysis
- Mesenteric cyst resection
- Resection of Meckel's diverticulum
- Inflammatory bowel
- Repair of post-traumatic gastric perforation
- Repair of post-traumatic duodenal perforation

3.2 Lower gastrointestinal tract

- Appendectomy
- Antegrade continence enema
- Laparoscopy assisted endorectal pullthrough procedure

3.3 Abdominal wall defects

Egigastric hernia repair
Umbilical hernia repair
Inguinal hernia repair
Femoral hernia repair

3.4 Solid Intra-abdominal organs

Splenectomy
Deroofing of liver cyst
Laparoscopic Kasai portoenterostomy
Pancreatic biopsy
Liver biopsy
Abdominal cystic masses
Adrenal gland biopsy
Adrenal gland excision
Excision of intra-abdominal neuroblastoma
Excision of hepatoblastoma
Excision of intra-abdominal extralobar pulmonary sequestration
Partial pancreatectomy
Splenic cyst resection
Cholecystectomy
Cholecystotomy

3.5 Gynaecologic

Ovarian cystectomy
Ovarian detorsion
Oophorectomy
Diagnostic laparoscopy for chronic abdominal pain

3.6 Urology

Laparoscopy for impalpable testis
Fowler Stephen's stage 1 orchidopexy
Ligation of varicocele
Renal biopsy
Ureteral implanatation,
Mitrofanoff appendicovesicostomy,
Bladder augmentation
Pyeloplasty
Nephroureterectomy
Heminephrectomy
Placement of dialysis catheter

4. Physiological considerations

4.1 The cardiovascular system

Potentially, pneumoperitoneum could result in reduction in cardiac filling with resultant reduction in cardiac output by compression of the veins running across the abdominal

cavity. This may result in increase in systemic vascular resistance with reduction in blood flow to the renal vasculature. Gómez et al (2005) noted anuria in 88% of children less than 1 year-old during laparoscopic procedure and oliguria in 32% of those above 1 year of age. This was found to be completely reversible within 5 to 6 hours after the surgery with no significant associated reduction in renal blood flow or rise in serum creatinine and urea levels. For this reason, intra-operative urine output in children undergoing laparoscopic procedures is not a reliable indicator of intravascular volume or need for intravenous therapy until 5 hours after surgery.

With good cardiac reserve in the absence of underlying cardiac or coronary artery or vascular disease, children respond well to the stress of pneumoperitoneum on the circulatory system. Therefore problematic rise in heart rate and blood pressure changes in this population are rare. To keep these physiological changes to a minimum, the lowest intra-abdominal pressure required to carry out the procedure safely is recommended: between 5 - 8mmHg in the newborn, 10 - 12mmHg in infants and less than 15mmHg in older children. Flow rate for insufflation of carbon dioxide ranges from 1 to 5L/min.

The longer operating times associated with many laparoscopic procedures, means longer period of cardiovascular stress. The reverse Trendelenburg position of 10-15degrees often used to facilitate laparoscopy of the upper abdomen may also reduce venous return and preload with consequent reduction in cardiac output and tissue perfusion. Applying the minimal intra-abdominal pressure required for adequate access and visualisation of the target organ and operating field avoids the reduced cardiac output, impairment of distal limb perfusion, tissue hypoperfusion and resultant reperfusion injury.

4.2 Respiratory system

Pneumoperitoneum leads to diaphragmatic splinting and upward displacement into the thoracic cavity. This in turn leads to a reduction in compliance of the thoracic cage and lung tissue, reduction in the functional residual capacity and tidal volume as well as a rise in the peak pressure required to aerate the bronchoalveolar system. The carbon dioxide used for pneumoperitoneum is cheap, non-combustible, highly soluble with little risk of causing gas embolism. It diffuses easily into the general circulation and needs to be eliminated via the lungs. There are concerns about other gases which could be used for insufflation. Nitrous oxide may cause explosion while helium is linked with a higher risk of gas embolism and subcutaneous emphysema and argon may cause cardiac depression (Fingerhut et al., 2005). The pressure on ventilation from the pneumoperitoneum as stated above may make the respiratory system inefficient at this resulting in hypercarbia and respiratory acidosis. The Trendelenburg position often used to facilitate laparoscopy of the lower abdomen/pelvis further contributes to diaphragmatic elevation.

The elimination of carbon dioxide during and immediately after insufflation with carbon dioxide in children is age and size dependent with the younger and smaller children eliminating more carbon dioxide than older children. The reason for this is not clear but is thought to be because of the different characteristics of their peritoneal surface (McHoney et al, 2003). However, this did not result in any clinically evident effect on the cardiovascular or respiratory system. For this reason, more careful observation is recommended in smaller children during and immediately following laparoscopic procedures. Pacilli et al (2006) demonstrated that in children after 10 -12mins of laparoscopy, 10-20% of expired carbondioxide derived from absorption of exogenous carbon dioxide and continues to be eliminated for up to 30minutes after the end of insufflation. Minute ventilation needs to be

adjusted in order to avoid hypercarbia.. McHoney et al (2003) observed the elimination of carbon dioxide in children to be age-dependent.

The short trachea in children increases the risk of endobronchial intubation. The tip of the tracheal tube has been observed to have a tendency to be displaced caudally with the cranial displacement of lung tissue and carina during the establishment of pneumoperitoneum. This risk is greater when the head up Trendelenburg tilt is employed to facilitate laparoscopy of the upper aspect of the abdominal cavity (Böttcher-Haberzeth et al, 2007). Prior discussion with the anaesthetic team will enable appropriate choice of tube, depth of endotracheal tube placement and degree of neck extension required to prevent this complication.

5. Anatomic considerations

Safe and efficient laparoscopy relies heavily on good apparatus and expertise but also on appropriate placement of telescope and instruments. Infants have a relatively shorter and wider abdominal cavity than do older children. This anatomic variation usually exists up to the age of seven years. In addition, the abdominal wall thickness is often moderate and requires careful choice of placement of ports to allow as much space as possible for safe and effective laparoscopy. The urinary bladder is often an abdominal organ in infants and young children. It will need to be emptied by expression with gentle compression pressure on the lower abdomen or by use of a urethral catheter. To maximise the space, a nasogastric tube is often inserted and intermittently aspirated to decompress the stomach. Some surgeons give aperients to the children to empty intestinal contents 24 to 48hours before laparoscopic surgery to minimise interference with surgery and optimise the space within the abdominal cavity. The relatively higher body surface/ mass ratio in infants means they have a delicate fluid balance which is easily stressed and put under pressure by evaporation of body fluids from exposure of abdominal contents at laparotomy. This is minimized by the laparoscopic approach and modification of laparoscopic equipment is on-going to further limit any drying effect the gas and light may exert on abdominal viscera. As mentioned above, the short trachea in children, particularly in young infants, needs careful consideration during the entire length of the procedure especially where special positioning is required.

6. Anaesthetic considerations

Laparoscopic procedures commonly take longer to perform than their conventional open counterparts. This means prolonged neuromuscular blockade/paralysis. The intubation of the patient has to be skilfully administered to avoid intraluminal gaseous distension and the consequent impairment of visualisation. To minimise this, limited use of the bag and mask is recommended as well as immediate decompression of the stomach by use of a nasogastric tube. The positioning of the patient may require the patient being at the end of the bed and far from the anaesthetic machine. This will need long length apparatus and connectors to intravenous access lines to facilitate management of anaesthetic requirements intraoperatively. The endotracheal tube is preferable to the laryngeal mask or facial mask ventilation as it leads to less risk of distension of stomach and bowel which would limit view and make surgery more difficult. The orientation and length of tubing should allow appropriate patient positioning. Adequate patient relaxation through out the duration of surgery is required to allow lower pressures to be used for adequate pneumoperitoneum.

Communication between team members is crucial to enable the anaesthetist interpret haemodynamic changes appropriately.

7. Surgical planning

7.1 Preoperative assessment

This is crucial in all children in preparation for a laparoscopic procedure. This can be as a formal assessment in a dedicated preoperative assessment clinic led by experienced paediatric surgeons with easy access to paediatric anaesthetist and paediatrician or informally in the outpatients' clinic when the decision to undertake the procedure is made. The anaesthetic team would need to be informed if any potential cardiovascular/respiratory problems are anticipated. The child's suitability for laparoscopy by way of respiratory and cardiovascular status as well as suitability regarding skin condition at proposed site of access and situations which may make access to the abdominal cavity greatly limited. For example severe kyphoscoliosis may make laparoscopy quite challenging or impossible, and this needs to be addressed during the preoperative assessment.

7.2 Informed consent

Parents or carers with parental responsibility for the child need to be appropriately informed in the relevant aspects of the laparoscopic procedure. The indication for surgery as well as other treatment options, risks and complications – both general and specific to the child's condition and expected outcome need to be discussed. The possible risk of conversion to an open procedure needs to be discussed in most cases to deal with complications or to facilitate safe undertaking of the procedure.

7.3 Equipment

Availability of essential equipment should be checked before the day of surgery. In our institute, this is usually done by way of distributing the operating list to theatre coordinating department who would then arrange for the appropriate equipment to be available on the day. Some special apparatus may need to be ordered several weeks ahead. On the day of the surgery, every equipment required must be carefully checked by the surgeon with the support of the theatre staff. A set of equipment required for open approach for the procedure must also be available for use in the event of need for conversion.

7.4 Positioning

Careful positioning of the equipment and staff to achieve optimal access to the patient is crucial to successful laparoscopy. Examples are given in Figures 1 and 2. The position must allow adequate exposure of the patient and safe access to the operating field. The recommended alignment is to have the monitor, operating surgeon and the patient or target organ in a straight line.

It is preferable to have two monitors to serve the operating surgeon and his or her assistant separately; this is standard for most operating rooms today. The position of other staff members including the surgeon's assistant, scrub nurse and anaesthetist depends on where the operating surgeon is positioned. The position of the patient depends on the target organ for the procedure. Supine position can be applied to a good number of the procedures. A Trendelenburg position may be preferred for pelvic laparoscopy and a reverse Trendelenburg position for upper abdominal laparoscopy to visualise the diaphragm and its

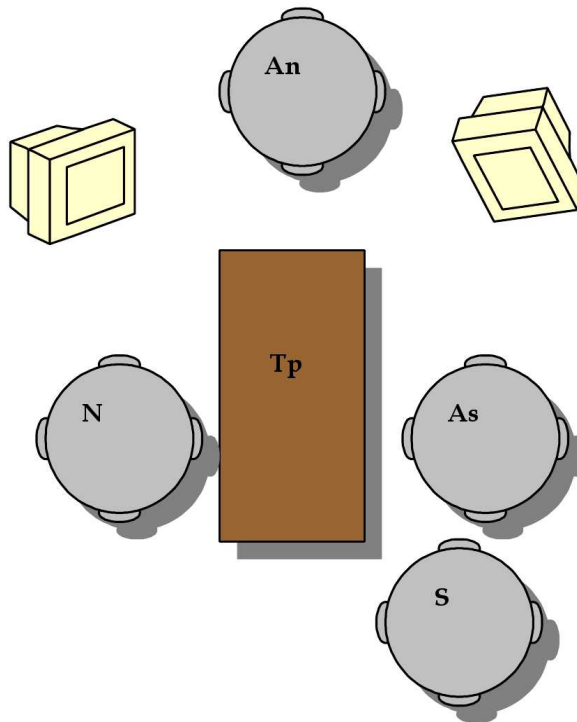


Fig. 1. Operative positioning for laparoscopic appendectomy. S: surgeon, As: surgeon's assistant, N: scrub nurse, An: anaesthetist, Tp: table with patient. Two monitors are shown on either side of the anaesthetist.

apertures or any hernia present, stomach and liver. A lateral tilt position may be required for splenic or renal and retroperitoneal organs. In all cases, appropriate care must be taken to avoid pressure area injury to the patient and the use of gel-filled flexible or rigid moulds or support apparatus needs to be considered. Adhesive material may be needed to further secure the patient in the desired position.

7.5 Port insertion

The open Hasson's technique for the insertion of the primary port is almost exclusively applied by most paediatric surgeons having been shown to be associated with fewer complications than the Veress' needle. The centre of the umbilicus is commonly used for this purpose. Particular care should be taken if there is a history of previous abdominal surgery. Secondary ports should be inserted under direct visual control with the camera. The 5mm port is often used in most cases; the 10mm port may be suitable for older children whose periumbilical region can accommodate this without excessive scarring. Secondary port size would vary according to nature of procedure. For repair of inguinal hernia, the instrument may be introduced directly through a 2-3mm opening in the skin. The depth of insertion of the port should be such as allows space for the instrument to be inserted and manoeuvred while allowing for the port to be anchored to the abdominal wall. Various methods are used

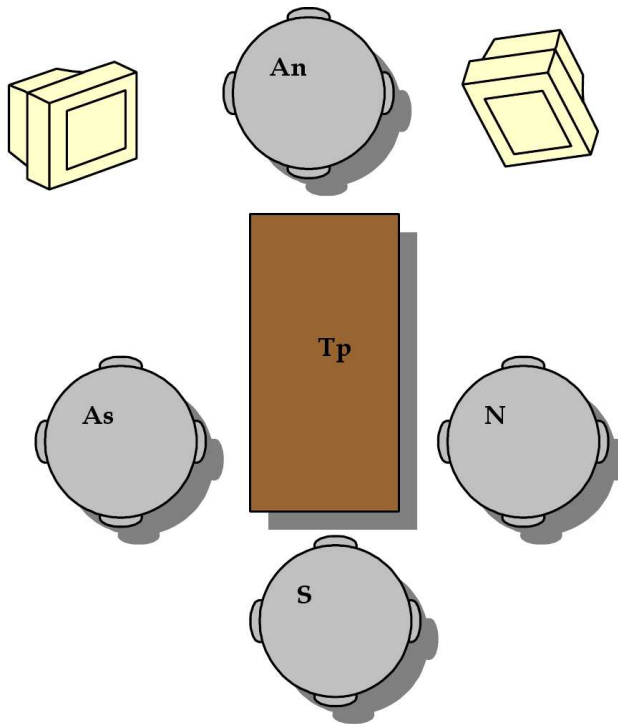


Fig. 2. Operative positioning for laparoscopic fundoplication. S: surgeon, As: surgeon's assistant, N: scrub nurse, An: anaesthetist, Tp: table with patient. Two monitors are shown on either side of the anaesthetist.

to secure the port to the abdominal wall. A common practice is to insert a purse string to the deep fascia at the point of port insertion and tie this to the sides of the port. Care should be taken to plan port insertion appropriately and keep the number of ports to the number required for safe laparoscopy. We demonstrated that the risk of port site adhesions though low, is further reduced by using less ports (Nwokoma et al., 2009b).

7.6 Closure

At the end of the procedure, all incisions of 5mm and above should be closed with standard sutures at deep fascia and skin level as these may still result in incisional hernia if not closed appropriately. Tissue glue or adhesive strips can be used to close incisions of less than 5mm size.

8. Contraindications

Experience in paediatric laparoscopy has advanced supported by advances in paediatric anaesthetic care as well as improvement and adaptability of instruments and equipment. This has led to a shift in classification of certain clinical conditions from *absolute* to *relative* contraindications to laparoscopy. The contraindications are listed in Table 3.

Patient unsuitable for open surgery
Uncontrolled bleeding or coagulation problems
Multiple previous abdominal surgery

Table 3. Contraindications to paediatric laparoscopy

Infants less than six months old respond to challenges to their circulatory system by compensatory increase in their heart rate, their relatively immature cardiac muscles being unable to increase contractility in such situations. Consequently, children in this age group need to be carefully selected when significant congenital cardiac disease is present. In the presence of coagulopathy or haemoglobinopathies, laparoscopic cholecystectomy and splenectomy have been carried out safely. In these cases, safety has not been compromised by the theoretical diminution in visibility caused by the absorption of light consequent upon blood in the operating field. Careful medical management of these conditions compliment surgical technique to make laparoscopic approach safe in these patients. The early mobilisation, smaller scars needing less opiate analgesics give added benefit in these situations. Children with respiratory difficulties also benefit from the benefits of smaller scar and less opiate analgesia, early mobilisation which leads to reduction of hospital stay, reduced risk of atelectasis or exacerbation of respiratory problems (Nagraj et al., 2006). Complication rate is higher in children who weigh less than 5kg. This was observed by Iwanaka et al (2004) following Nissen's fundoplication. The little intra-abdominal space in this group of patients limits surgeon's movement and efficiency, and may contribute to a higher complication rate. Several urologic procedures have been safely performed by laparoscopic approach in children. However, Lee DJ et al., advocate that ureteric reimplantation is contraindicated in children less than 4years of age, in the presence of concomitant ureterocele or megaureter requiring tapering.

9. Controversies

9.1 Laparoscopy and intra-abdominal tumours

Laparoscopy has contributed significantly to the management of paediatric abdominal tumours. Similar to other medical conditions, the usefulness of laparoscopy in paediatric oncology can be broadly viewed as diagnostic or therapeutic.

Diagnostic laparoscopy is a valuable tool for visualising and obtaining tissue for diagnosis from intra-abdominal masses. It offers the advantage of the biopsy being done under direct vision, being less invasive than open biopsy, less post-operative pain and fewer problems with adhesion of tissue to the abdominal wall. Unlike ultrasound-guided or CT-guided percutaneous biopsy which also requires a general anaesthetic, it offers the operator visual appreciation of the biopsy site and opportunity to control any resultant bleed. It also allows a deeper reach than the percutaneous approach. The risk of collateral tissue injury and inadequate sampling is also reduced. The extent of the tissue or mass lesion and its resectability can also be evaluated while planning of definitive surgery can be undertaken including best mode and site of access, if required at a later date. Its applicability relies on there being enough space and optimal site for introduction of camera and instruments with safe creation of pneumoperitoneum. For these reasons, large tumours may present a challenge and require careful evaluation and case selection. Peritoneal washings can also be

obtained at laparoscopy. Despite these advantages, many advocate that its use in diagnosis for malignancy be complimentary to and not a replacement for other non-invasive diagnostic tools (Conlon & Toomey, 2003).

The surgeon and oncologist continually face the challenge of obtaining adequate tissue for immunohistochemical, karyotyping and molecular analysis. Incorrect diagnosis leads to inappropriate management and therefore must be avoided as much as possible. Laparoscopy has been demonstrated to be safe in various childhood tumours such as neuroblastoma, rhabdomyosarcoma and liver tumours. The combination with ultrasonography adds information regarding the status of the tissue beneath the surface and increasing the diagnostic yield by 14% to 25%; core biopsies can be obtained and Doppler flow may add information about vessels and tumour-vessel interface (Conlon & Toomey, 2003).

The development of coagulative equipment such as the bipolar and harmonic scalpel, coagulative gels and tissue glue have contributed significantly to the reduction in risk of bleeding as well as the safe management of bleeding complications in laparoscopy. Concerns regarding tumour spillage and port site secondaries have limited the use of laparoscopy in oncology. Sandoval et al (2004) found tumour spillage in a therapeutic biopsy of a thoracic paraspinal Wilm's tumour and recommend open biopsy in these cases. They however found laparoscopic biopsy to have benefit in other intra-abdominal tumours.

Iwanaka et al (2003) reported port site recurrence to be rare in children. It is noteworthy that 64% of the patients in their report had neuroblastoma diagnosed following mass screening using levels of urinary Vanillylmandelic acid and homovanillic acid. Some have suggested that port-site recurrence is related to surgeon's inexperience (Bailey & Love, 2008) while others reported no difference in rate of port site or incisional recurrence in open or laparoscopic tumour surgery (Conlon & Toomey, 2003). Tumour rupture or spillage, implant and metastasis (including port site metastasis) were observed to be significantly higher in laparoscopic surgery than in open surgery following laparoscopy for gynaecological cancers and its use is limited to a clinically presumed benign diagnosis with normal levels of tumour markers (Medeiros LRF et al., 2010).

Iwanaka et al (2001) in their review of laparoscopic versus open adrenalectomy noted that there was reduced duration of hospital stay, time to post-operative feeding and commencement of chemotherapy in the laparoscopic group. Early post-operative high dose adjuvant chemotherapy has been found to reduce port site recurrence in abdominal neuroblastoma. Care should be taken with heat-operated instruments to avoid heat damage to tumour and surrounding organs. The transperitoneal approach is recommended as this offers the advantage of inspection of the contralateral adrenal gland and biopsy of regional para-aortic lymph nodes which is a requirement for the International Neuroblastoma Staging System to facilitate accurate staging of abdominal neuroblastoma (Iwanaka, 2008).

Laparoscopy was found to offer less blood loss, decreased time of postoperative feeding, decreased time to start chemotherapy, reduced hospital stay, better prognosis and quality of life to children (Iwanaka et al., 2007). Bax and van der Zee (2004) reported improved outcome from laparoscopy assisted interruption of the median sacral artery and dissection of the internal component of sacrococcygeal teratomas. Desai et al (2009) reported the ligation of median sacral artery in a premature neonate with a giant sacrococcygeal teratoma achieving minimal blood loss in the remaining part of the surgery.

9.2 Laparoscopy in trauma

Diagnostic laparoscopy is gaining increasing application in paediatric trauma in the stable patient with equivocal clinical parameters not requiring immediate laparotomy but not symptom-free. It has a sensitivity of 88% for liver and spleen injuries; 83% for diaphragm, 57% for pancreas and kidney and 25% for hollow viscus. It is not recommended in penetrating injuries because distension of the anterior abdominal wall by pneumoperitoneum risks disruption of injured tissues which may aggravate bleeding (O'Neill et al., 2003). Laparoscopy in paediatric trauma still has limited application and evidence available is mostly case reports. With a sensitivity of less than 50% for identification of perforation of hollow viscera and difficulty in interpreting haemodynamic changes, more evidence is required to clearly delineate its use in this patient group. It has been successfully used to evaluate abdominal trauma in children who are haemodynamically stable but with clinical suspicion of injury with normal imaging (Goldstein and Stylianou, 2005). Tytgat et al (2010) reported successful treatment of gastric and duodenal perforation following blunt abdominal trauma in children.

9.3 Sceptics

Opposers to the claim of the supremacy of the laparoscopic approach to open surgery cite the need for endotracheal general anaesthesia rather than regional block for procedures such as inguinal herniotomy as additional needless trauma, stress and cost (Raveenthiran V. 2010). This argument fails in the paediatric population where regional anaesthetic is of limited application as children do not tolerate this like the adults. Moreover, the pathology of hernia in adults is different from that in children this difference dictating different modes of treatment. In addition, concomitant contralateral inguinal hernia may not be apparent in children without laparoscopy. Raveenthiran (2010) argues that laparoscopy should not be a preferred option in children as they have nothing to benefit from early return home, having no loss of wages to account for. However, the cost of hospital admission and also early return to work for parents counters this stance. The psychologic trauma of separation from usual environment, siblings, play toys or equipment has been documented and may be enough to delay a child's recovery. Problems such as nocturnal enuresis and disrupted sleep patterns have been noted to be decreased with reduction in hospital stay (Brennan & Prabhu, 2003).

10. Complications of laparoscopy

The challenges facing the paediatric surgeons with regards to the use of laparoscopic approach for treatment in children are often peculiar to the particular condition in question and also to the age and size of the patient. The experience of the surgeon may also be a contributory factor. Complication rates are therefore variable; from 2% in elective procedures (Chen et al., 1996) to 17.4% in emergency procedures (Nwokoma et al., 2009a). Panteli et al, (2008) observed an overall complication rate of 6.9% among trainee paediatric surgeons. A list of possible complications is presented in Table 4.

Rigorous pursuit of haemostasis is essential for success in laparoscopic surgery as blood in the operating field significantly reduces visibility. Adequate control of blood vessels of target organ must be achieved to minimise risk of uncontrollable blood loss this often being the reason for conversion to an open approach. Vascular injury can affect the primary target organ or secondary intra-abdominal organs. This can have dire consequences for the devascularised organ. Vascular injury to the mesenteric vessels can result in bowel ischaemia and loss resulting in feeding problems commensurate with the length of bowel

Prolonged operative time
Visceral injury
Bladder injury
Bleeding
Shoulder tip pain
Vascular injury
Conversion to open procedure
Pneumothorax
Wound infection
Port site hernia
Renal impairment
Adhesive Intestinal obstruction
Intra-abdominal abscesses
Port site recurrence of malignancy
Gas embolism
Gastric volvulus

Table 4. Complications of laparoscopy

affected. Direct perforation of the bowel by instrumentation or diathermy heat injury is a well-documented complication. If noted at the time of surgery, repair can usually be achieved with minimal disruption to the procedure and without significant increase in morbidity. If missed, this can lead to delayed presentation with peritonitis or sepsis with possible bowel loss which may require the formation of a diverting stoma in emergency surgery. Shoulder tip pain is common following laparoscopy with a rate of 35% reported by Lejus et al., (1996).

Intra-abdominal abscess may complicate surgery particularly in the presence of peritoneal contamination or ischaemic tissues. Jen and Shew (2010) reported intra-abdominal abscess rate of 4.9% in perforated appendicitis versus 0.6% in non-perforated appendicitis. Due to the relatively new techniques of laparoscopic surgery as compared to conventional open approach surgical expertise is still developing in this area leading to increased operating time. Panteli et al., (2008) demonstrated an increased operating time for laparoscopic procedures among trainees which reduced with time and experience. This can be facilitated with the use of simulators for training surgeons. Many of the available simulators are easy to set up and can be modified to suit training needs. Jaffer et al., (2009) developed a low cost simulator to aid training in laparoscopic paediatric hernia repair. In addition, operating room staff may not be fully aware of alternative instruments which may be required intra-operatively to deal with challenges or conditions that were not apparent before the start of the procedure. Ure et al (2000) noted that problems with instruments and devices led to a mean time loss of 15.1 minutes in 15.6% of the laparoscopic procedures in their series.

The rate of conversion is related to the complexity of the procedure as indicated by target organ position in the abdominal cavity, adherence to neighbouring or surrounding structures, malignant tendency, inflammation, presence of pus or peritoneal soiling, presence of adhesions between the abdominal wall and intra-abdominal structures as well as surgeon's expertise. Hazzan et al (2001) reported a conversion rate of 7% in laparoscopic excision for benign adrenal neoplasm. In our report of laparoscopy for advanced appendicitis in children (Nwokoma et al., 2009a), we had a conversion rate of 0%.

Port site hernia is not common but is more likely with port site incisions of more than 5mm length. Chen et al, (1996) reported a port site hernia rate of 0.003%.

Gastric volvulus complicating inappropriate placement of gastrostomy tube is rare. Jen and Shew (2010) reported other uncommon complications as follows: cardiac 0.1%, respiratory 0.2 - 1%, renal 0.1-0.2% and intestinal obstruction 0.5 -2.0%. Gas embolism from carbon dioxide is very rare with reported incidences of between 0.0016% and 0.013% (Fingerhut et al., 2005).

11. Economic considerations

Macarulla E et al., (1997) found the laparoscopic approach to appendectomy to have an average cost of \$394 while the open approach had an average cost of \$508. The laparoscopic equipment and instruments are continually being modified. Many of them are single use. These factors contribute to their cost being above their open surgery equivalents, many of which are reusable after sterilisation. As already stated above, the advantage of reduced hospital stay makes for enough savings to cover the extra operative time and cost of equipment and instruments. This cost advantage is more evident when the duration of hospital stay for the open approach would normally be 4 days or more (Morris and Wood, 2000).

12. On-going developments

Single site laparoscopy was introduced in 1992 (Pelosi and Pelosi 1992). Since then it has continued to gain wide acceptance among paediatric surgeons. Limitations to its practical application include the relatively small size of periumbilical region or skin fold in children, the single incision multiport system still being between 15 - 20mm size. This potentially increases the risk of long unsightly scars, infection and incisional hernia. Also, the angle of instrumentation for the single port system limits movement, hindering dexterity which leads to prolonged operating time and higher risk of complications including collateral injury to tissues in and near the operating field. This problem is of course compounded by the smaller intra-abdominal cavity space in children. Further development of the single incision or single port system to suit the paediatric population is needed to extend its use and benefits to this patient group. Nevertheless, there are reports of some procedures that have been successfully performed using the single incision multi-port system and they include cholecystectomy, appendectomy, intussusception reduction, splenectomy, inguinal hernia repair, Nissen's fundoplication, insertion of gastrostomy tube, pyloromyotomy, ovarian detorsion, gastric sleeve resection and gastric band placement (Ponsky & Krpata, 2011).

The 3-dimensional imaging system is also getting increasingly available and will improve the spatial and depth perception of target organ. The use of heated humidified carbon dioxide for the creation of pneumoperitoneum is gaining increasing popularity but is not yet common practice. Some studies have demonstrated that it can lead to even less post-operative pain, hypothermia and analgesic requirement but no difference in length of hospital stay or less fogging rates. (Sajid et al., 2008). Peng et al., (2008) further observed that it caused less peritoneal damage and less post-operative adhesions. Further studies are needed to confirm these findings.

13. Conclusion

An increasingly wider range of surgical procedures are now being safely undertaken using the laparoscopic approach. In spite of the paucity of randomised clinical trials in the

paediatric population, many studies in this patient group have demonstrated a clear advantage of the laparoscopic approach over the open approach in different clinical situations. We believe that, 'What is worth doing, is worth doing well'. We advocate that as laparoscopy certainly gives an undeniable edge over the conventional approach to the treatment of several surgical conditions in children, it merits increased focus and advancement.

14. Acknowledgment

The authors would like to express their appreciation to their colleagues who have worked with them in various studies evaluating the clinical application of laparoscopy in children; some of the published work are included in the text.

15. References


- Anand, K.J.; Brown, M.J.; Causon, R.C.; Christofides, N.D.; Bloom, S.R. & Ainsley-Green, A. (1985). Can the human neonate mount an endocrine and metabolic response to surgery? *Journal of Pediatric Surgery*, Vol.20, No.1, (February 1985), pp. 41-48, ISSN 0022-3468
- Anand, K.J. & Hickey, P.R. (1987). Pain and its effects in the human neonate and fetus. *New England Journal of Medicine*, Vol.317, No.21, (November 1987), pp. 1321-1329, ISSN 0028-4793
- Anand, K.J. & Aynsley-Green, A. (1988). Measuring the severity of surgical stress in newborn infants. *Journal of Pediatric Surgery*, Vol.23, No.4, (April 1988), pp. 297-305, ISSN 0022-3468
- Badani, K.K.; Patel, H.R.H. & Hemal, A.K. (2006). Historical development of keyhole surgery, In: *Minimally Invasive Surgery: Looking through the keyhole*, H. Patel, J. Joseph, (Eds.), 2-3, MA Healthcare Ltd, ISBN 1-85642-296-8, London, United Kingdom
- Bailey and Love's Short Practice of Surgery, (2008). Twenty-fifth edition. N.S. Williams, C.J.K. Bulstrode, P.R. O'Connell, (Eds.), 247-249, Hodder Arnold, ISBN 9780340939321, London, United Kingdom
- Bax, N.M.A. & van der Zee, D.C. (1998). Trocar fixation during endoscopic surgery in infants and children. *Surgical Endoscopy*, Vol.12, No.2, pp. 181-182, 0930-2794
- Bax, N.M. & van der Zee, D.C. (2004). The laparoscopic approach to sacrococcygeal teratomas. *Surgical Endoscopy*, Vol.18, No.1, (January 2004), pp. 128-130, ISSN 0930-2794
- Böttcher-Habberzeth, S.; Dullenkoff, A.; Gitzelmann, A. & Weiss, M. (2007). Tracheal tube tip displacement during laparoscopy in children. *Anaesthesia*, Vol.62. No.2, (February 2007), pp. 131-134, ISSN 0003-2409
- Chen, M.K.; Schropp, K.P. & Lobe, T.E. (1996). Complications of minimal-access surgery in children. *Journal of Pediatric Surgery*, Vol.31, No.8, (August 1996). pp. 1161-1165, ISSN 0022-3468

- Conlon, K.C. & Toomey, D. (2007). Diagnostic Laparoscopy, In: *Mastery of Surgery, Volume 1*. Fifth edition, J.E. Fischer, K.I. Bland, (Eds.), 251-258, Wolters Kluwer/Lippincott Williams & Wilkins, ISBN 9780781771658, Philadelphia, USA
- Desai, A.P.; Wragg, R.; kulkarni, M. & Tsang, T. (2009). Sacrococcygeal teratoma: Excision aided by laparoscopic ligation of the median sacral artery in a premature neonate. *Journal of Indian Association of Pediatric Surgeons*, Vol.14, No.1, (January 2009), p. 39, ISSN 0971-9261
- Fingerhut, A.; Millat, B. & Borie, F. (2005). Prevention of complications in laparoscopic surgery, In: *Mastery of Endoscopic and Laparoscopic Surgery*, N.J. Soper, L.L. Swanström, W.S. Eubanks, (Eds.), 57-58, Lippincott Williams & Wilkins, ISBN 0-7817-4445-8, Philadelphia, USA
- Goldstein, A.M. & Stylianos, S. (2005). The role of minimal access surgery in pediatric trauma, In: *Pediatric Minimal Access Surgery*. Edited by J.C. Lange, C.T. Albanese, (Eds.), 81-88, Taylor and Francis Group, ISBN 0-8247-5447-6, Florida, USA
- Gómez, D.B.H.; Karanik, E.; Glüer, S.; Jesch, N.K.; Kübler, J.; Latta, K.; Sumpelmann, R. & Ure, B.M. (2005). Anuria during pneumoperitoneum in infants and children: a prospective study. *Journal of Pediatric Surgery*, Vol.40, No.9, (September 2005), pp. 1454-1458, ISSN 0022-3468
- Hazzan, D.; Shiloni, E.; Golijanin, D.; Jurim, O.; Gross, D. & Reissman, P. (2001). Laparoscopic versus open adrenalectomy for benign adrenal neoplasm. A comparative study. *Surgical Endoscopy*, Vol.15, No.11, (November 2001), pp. 1356-1358, ISSN 0930-2794
- Iwanaka, T.; Arai, M.; Ito, M.; Kawashima, H.; Yamamoto, K.; Hanada, R. & Imaizumi S. (2001). Surgical treatment for abdominal neuroblastoma in the laparoscopic era. *Surgical Endoscopy*, Vol.15, No.7, (July 2001), pp. 751-754, ISSN 0930-2794
- Iwanaka, T.; Arai, M.; Yamamoto, H.; Fukuzawa, M.; Kubota, A.; Kouchi, K.; Nio, M.; Satomi, A.; Sasaki, F.; Yoneda, A.; Ohhana, Y.; Takehara, H.; Morikawa, Y. & Miyano, T. (2003). No incidence of port-site recurrence after endosurgical procedure for pediatric malignancies. *Pediatric Surgery International*, Vol.19, No.3, (May 2003), pp. 200-203, ISSN 0179-0358
- Iwanaka, T.; Uchida, H.; Kawashima, H.; Nishi, A.; Kudou, S. & Satake, R. (2004). Complications of laparoscopic surgery in neonates and small children. *Journal of Pediatric Surgery*, Vol.39, No.12, (December 2004), pp. 1838-1841, ISSN 0022-3468
- Iwanaka, T.; Kawashima, H. & Uchida, H. (2007). The laparoscopic approach to neuroblastoma. *Seminars in Pediatric Surgery*, Vol.16, No.4, (November 2007), pp. 259-265, ISSN 1055-8586
- Iwanaka, T. (2008). Laparoscopic approach to abdominal neuroblastoma, In: *Endoscopic Surgery in Infants and Children*. Edited by N.M.A. Bax, K.E. Georgeson, S.S. Rothenberg, V. Jean-Stéphane, C.K. Yeung, (Eds.), 617-627, Springer, ISBN 978-3-540-00115-7, Berlin Heidelberg, Germany
- Jaffer, U.; Manoharan, S. & Tsang, T. (2009). Low cost laparoscopic paediatric inguinal hernia repair simulator. *Annals of the Royal college of Surgeons of England*, Vol.91, No.6, (September 2009), p. 515, ISSN 0035-8843

- Jen, H.C. & Shew, S.B. (2010). Laparoscopic versus open appendectomy in children: outcomes comparison based on a state wide analysis. *Journal of Surgical Research*, Vol.161, No.1, (June 2010), pp. 17-19, ISSN 0022-4804
- Lee, D.J.; Kim, P.H. & Koh, C.J. (2010). Current trends in pediatric minimally invasive urologic surgery. *Korean Journal of Urology*, Vol.51. No.2, (February 2010), pp. 80-87, ISSN 2005-6737
- Lee, S.L. & DuBois, J.J. (2000). Laparoscopic diagnosis and repair of pediatric femoral hernia. Initial experience of four cases. *Surgical Endoscopy*, Vol.14, No.12, (December 2000), pp. 1110-1113, ISSN 0930-2794
- Lejus, C.; Delile, L.; Plattner, V.; Guillou, S.; Héroudy, Y. & Souron, R. (1996). Randomised, single-blinded trial of laparoscopic versus open appendectomy in children: effects on post-operative analgesia. *Anesthesiology*, Vol.84, No.4, (April 1996), pp. 801-806, ISSN 0003-3022
- Macarulla, E.; Vallet, J.; Abad, J.M.; Hussein, H.; Fernandez, E. & Nieto, B. (1997). Laparoscopic versus open appendectomy: a prospective randomized trial. *Surgical Laparoscopy & Endoscopy*, Vol.7, No.4, (August 1997), pp. 335-339, 1051-7200
- McHoney, M.; Corizia, L.; Eaton, S.; Kiely, E.M.; Drake, D.P.; Tan, H.L.; Spitz, L. & Pierro A. (2003). Carbon dioxide elimination during laparoscopy in children is age dependent. *Journal of Pediatric Surgery*, Vol.38, No.1, (January 2003), pp. 105-110, 0022-3468
- Medeiros, L.R.F.; Rosa, D.D.; Bozzetti, M.C.; Mines, R.; Edelweiss, M.I.; Stein, A.T.; Zelmanowicz, A.; Ethur, A.B. & Zanini, R.R. (2010). Laparoscopy versus laparotomy for FIGO (International Federation of Gynaecology and Obstetrics) Stage 1 ovarian cancer (Review), The Cochrane Collaboration, The Cochrane Library 2010 (on line), Issue 12, ISSN 1469-493X
- Meehan, J.J. & Georgeson, K.E. (1997). Laparoscopic fundoplication yields low postoperative complications in neurologically impaired children. *Pediatric Endosurgery & Innovative Techniques*, Vol.1, No.1, (January 1997), pp. 11-14, ISSN 1092-6410
- Morecroft, J.A.; Stringer, M.D.; Higgins, M.; Holmes, S.J. & Capps, S.N. (1993). Follow up after inguinal herniotomy or surgery for hydrocele in boys. *British Journal of Surgery*, Vol.80, No.12, (December 1993), pp. 1613-1614, ISSN 0007-1323
- Morris, P.J. & Wood W.C. (2000). Endoscopic surgery, In: *Oxford Textbook of Surgery*, Second edition. Volume 1. p. 603, Oxford University Press Inc. ISBN 0-19-262884-4, New York, USA
- Nagraj, S.; Sinha, S.; Grant, H.; Lakhoo, K.; Hitchcock, R. & Johnson, P. (2006). The incidence of complications following primary inguinal herniotomy in babies weighing 5kg or less. *Pediatric Surgery International*, Vol. 22, No.6, (June 2006), pp. 500-502, ISSN 0179-0358
- Nwokoma, N.J.; Swindells, M.G.; Pahl, K.; Mathur, A.B.; Minocha, A.; Kulkarni, M. & Tsang TT. Pediatric advanced appendicitis: open versus laparoscopic approach. *Surgical Laparoscopy, Endoscopy & Percutaneous Techniques*, Vol.19, No.2, (April 2009), pp. 110-113, ISSN 1530-4515

- Nwokoma, N.J.; Hassett, S. & Tsang TT. (2009). Trocar site adhesions following laparoscopic surgery in children. *Surgical Laparoscopy, Endoscopy & Percutaneous Techniques*, Vol.19, No.6, (December 2009), pp. 511-513, ISSN 1530-4515
- O'Neill Jr., J.A.; Grosfeld J.L.; Fonkalsrud E.W.; Coran A.G.; Caldamone, A.A. (2004). Diagnostic Laparoscopy, In: *Principles of Pediatric Surgery*, Second edition, (Eds.), 163, Mosby, ISBN 0323-01827-0, St. louis, Missouri, USA
- Pacilli, M.; Pierro, A.; Kingsley, C.; Curry, J.I.; Herod, J. & Eaton S. (2006). Absorption of carbon dioxide during laparoscopy in children measured using a novel mass spectrometric technique. *British Journal of Anaesthesia*, Vol.97, No.2, (August 2006), pp. 215-219, ISSN 0007-0912
- Panteli, C.; Desai, A.; Manoharan, S.; Bouhadiba, N.; Singh, S. & Tsang, T. (2008). Emergency laparoscopic appendectomy: the results in the hands of trainees. *Journal of Pediatric Surgical Specialties*, Vol.2, No.3, (December 2008), pp. 14-17, ISSN 2066-2009
- Panteli, C.; Minocha, A.; Kulkarni, M.S. & Tsang, T. (2009). The role of laparoscopy in the management of adnexal lesions in children. *Surgical Laparoscopy, Endoscopy & Percutaneous Techniques*, Vol.19, No.6, (December 2009), pp. 514-517, ISSN 1530-4515
- Parkinson, E.J. & Pierro, A. (2006). Inguinal and umbilical hernias, In: *Pediatric Surgery and Urology – Long Term Outcomes*, M.D. Stringer, K.T. Oldham KT, P.D.E. Mouriquand PDE, (Eds.), Second edition, 286-288, Cambridge University Press, ISBN 0-521-83902-5, New York, USA
- Pelosi, M.A. & Pelosi, M.A. 3rd (1992). Laparoscopic appendectomy using a single umbilical puncture (minilaparoscopy). *Journal of Reproductive Medicine*, Vol.37, No.7, pp. 588-594, ISSN 0024-7758
- Peng, Y.; Zheng, M.; Ye, Q.; Chen, X.; Yu, B. & Liu, B. (2008). Heated and humidified CO2 prevents hypothermia, peritoneal injury and intra-abdominal adhesions during prolonged laparoscopic insufflations. *Journal of Surgical Research*, Vol. XX, No. X, (October 2008), pp.1-8, ISSN 0022-4804
- Ponsky, T.A. & Krpata, D.M. (2011). Single-port laparoscopy: considerations in children. *Journal of Minimal Access Surgery*, Vol.7, No.1, (January-March 2011), pp. 96-98, ISSN 0972-9941
- Raveenthiran, V. (2010). Pediatric laparoscopy: facts and factitious claims. *Journal of Indian Association of Pediatric Surgeons*, Vol.15, No.4, (October-December 2010), pp. 122-128, ISSN 0971-9261
- Rehman, M.R.; Panteli, C. & Tsang, T. (2010). Laparoscopic repair of Amyand hernia in an 8-week-old infant. *Hernia*, Vol.14, No.4, (August 2010), pp. 443-445, ISSN 1265-4906
- Sajid, M.S.; Mallick, A.S.; Rimpel, J. Bokari, S.A.; Cheek, E. & Baig, M.K. Effect of heated and humidified carbon dioxide on patients after laparoscopic procedures: a meta-analysis. *Surgical Laparoscopy, Endoscopy & Percutaneous Techniques*, Vol.18, No.6, (December 2008), pp. 539-546, ISSN 1530-4515
- Sandoval, C.; Strom, K. & Stringel, G. (2004). Laparoscopy in the management of pediatric intra-abdominal tumors. *Journal of the Society of Laparoendoscopic Surgeons*, Vol.8, No.2, (April-June 2004), pp. 115-118, ISSN 1086-8089
- Semm, K. (1983). Endoscopic appendectomy. *Endoscopy*, Vol.15, No.2, (March 1983), pp. 59-64, ISSN 0013726X

- Tantoco, J.G.; Glick, P.L. & Levitt, M.A. (2005). History of pediatric minimal access surgery, In: *Pediatric Minimal Access Surgery*, J.C. Langer, C. T. Albanese, (Eds.), 12, Taylor & Francis Group, ISBN 0-8247-5447-6, Florida, USA
- Tytgat, S.H.; Zwaveling, S.; Kramer, W.L. & van der Zee, D.C. (2010). Laparoscopic treatment of gastric and duodenal perforation in children after blunt abdominal trauma. *Injury*, December 1 2010 (Epub) PMID: 21129741
- Ure, B.M.; Bax, N.M.A. & van der Zee, D.C. (2000). Laparoscopy in infants and children: a prospective study on feasibility and the impact on routine surgery. *Journal of Pediatric Surgery*, Vol.35, No.8, (August 2000), pp. 1170-1173, ISSN 0022-3468
- van der Zee, D.C. & Bax, N.M.A. (1999). Laparoscopic approach to intestinal obstruction in children, In: *Endoscopic Surgery in Children*, N.M.A. Bax, K.E. Georgeson, A. Najmaldin, J.S. Valla. (Eds.), 215 -219, Springer, ISBN 3540640738, Verlag, Berlin, Germany



Advanced Laparoscopy

Edited by Prof. Ali Shamsa

ISBN 978-953-307-674-4

Hard cover, 190 pages

Publisher InTech

Published online 30, September, 2011

Published in print edition September, 2011

The present book, published by InTech, has been written by a number of highly outstanding authors from all over the world. Every author provides information concerning treatment of different diseases based on his or her knowledge, experience and skills. The chapters are very useful and innovative. This book is not merely devoted to urology sciences. There are also clear results and conclusions on the treatment of many diseases, for example well-differentiated papillary mesothelioma. We should not forget nor neglect that laparoscopy is in use more extensively than before, and in the future new subjects such as use of laparoscopy in treatment of kidney cysts, simple nephrectomy, pyeloplasty, donor nephrectomy and even robotic laparoscopy will be researched further.

How to reference

In order to correctly reference this scholarly work, feel free to copy and paste the following:

Ngozi Joy Nwokoma and Thomas Tsang (2011). Laparoscopy in Children and Infants, Advanced Laparoscopy, Prof. Ali Shamsa (Ed.), ISBN: 978-953-307-674-4, InTech, Available from:
<http://www.intechopen.com/books/advanced-laparoscopy/laparoscopy-in-children-and-infants>

INTECH

open science | open minds

InTech Europe

University Campus STeP Ri
Slavka Krautzeka 83/A
51000 Rijeka, Croatia
Phone: +385 (51) 770 447
Fax: +385 (51) 686 166
www.intechopen.com

InTech China

Unit 405, Office Block, Hotel Equatorial Shanghai
No.65, Yan An Road (West), Shanghai, 200040, China
中国上海市延安西路65号上海国际贵都大饭店办公楼405单元
Phone: +86-21-62489820
Fax: +86-21-62489821

© 2011 The Author(s). Licensee IntechOpen. This chapter is distributed under the terms of the [Creative Commons Attribution-NonCommercial-ShareAlike-3.0 License](#), which permits use, distribution and reproduction for non-commercial purposes, provided the original is properly cited and derivative works building on this content are distributed under the same license.