

The Gingival Fibromatoses

Sofia Douzgou¹ and Bruno Dallapiccola²

¹*Department of Genetics, Institute of Child Health
"Aghia Sophia" Children's Hospital, Athens*

²*Division of Medical Genetics, "Bambino Gesù" Pediatric Hospital IRCCS, Rome*

¹*Greece*

²*Italy*

1. Introduction

1.1 Definition

Gingival fibromatosis (GF) is a slowly progressive, benign, non-bleeding, painless, localized or generalized overgrowth of the maxillary and mandibular keratinized gingiva (Baptista, 2002). It is also recognized as congenital hypertrophy of the gums, gingivae elephantiasis, gingival gigantism, symmetrical fibroma of the palate, gingival hyperplasia, gingival overgrowth (GO), and congenital macrogingiva (Emerson, 1965). The condition occurs both in isolated and syndromic forms, and results from either genetic or acquired mechanisms. The most common causes accounting for the isolated forms include the effect of a systemic drug treatment and single gene mutations (hereditary GF or HGF). In addition GF can manifest within a systemic disease (Häkkinen and Csiszar, 2007).

1.2 Clinical presentation

Gingival overgrowth's dimensions are classified in three grades: grade I: growth confined to the interdental papilla, grade II: growth involving both papilla and marginal gingiva, grade III: growth which covers three quarters or more of the dental crown (Bökenkamp et al., 1994). In referral to the period of onset, the overgrowth can be classified as: pre-eruptive (<6 months of age), during the deciduous dentition (from 6 months to 6 years), during the mixed dentition period (6 to 12 years) and during the permanent dentition periods, before (12 to 20 years) and after adolescence (age 20 or later). The overgrowth results in dental defects, including diastemata, malocclusion, delayed eruption of permanent dentition or prolonged retention of primary dentition, causing aesthetic and functional problems. Treatment with functional gingivectomy is often followed by recurrence of the overgrowth. Given the rarity of HGF, available information about its clinical presentation is based on individual observations. The phenotypic spectrum is considerably wide and varies both for the number of teeth involved and the degree of clinical expression. The localized forms of HGF usually involve the maxillary tuberosities and labial gingiva around the mandibular molars. However, the symmetric, generalized form of HGF, involving the labial, lingual and palatal gingiva is the most common. Males and females are equally affected. Hyperplastic gums may be normal or erythematous and consist of dense, fibrous tissue that feels fixed and nodular on palpation. Although the alveolar bone is not usually involved, gingival

hyperplasia causes periodontal problems because of difficult oral hygiene. The overgrowth can also result in functional and aesthetic problems, create diastemata, prevent or slow the growth of teeth and determine facial changes as a result of lip protrusion. The overgrowth can also lead to serious speech and chewing problems and may prevent the normal closure of the lips (Baptista, 2002).

The onset of GO usually coincides with the eruption of the permanent incisors, or, sometimes, with the eruption of primary dentition. In very rare cases, it can also be congenital (Anderson et al., 1969). Since HGF has never been observed in edentulous patients, it seems that the presence of dentition is necessary for the development of GO.

1.3 Histology

Histological characterization and differentiation has not been possible, to date, for all forms of HGF, especially for the syndromic ones. The various forms of HGF have similar histological features, suggesting that the pathogenic mutations affect different levels of the same cellular or molecular pathway. Hereditary gingival fibromatosis is characterized by moderate hyperplasia of the hyperkeratotic epithelium, comprised a network of elongated ridges. The epithelial hyperplasia may also be secondary to acanthosis, which has, however, only been found in areas of chronic inflammation. Fibrosis occurs with accumulation of collagen and elastic and oxytalan fibers in the connective tissue, comprised a few fibroblasts and blood vessels. Fibroblasts seem to alternate with thin or thick collagen fibrils. Unlike the characteristic "woven basket" arrangement of collagen fibers in the normal gingiva, the ones of fibrotic gingiva appear parallel. Rarely, osseous calcifications may be present as well as many neurovascular bundles (Kelekis-Cholakis et al., 2002, Doufexi et al., 2005).

The diagnosis of HGF is based on the collection of clinical history and on clinical examination, since no specific immunohistochemical markers have been identified, to date.

2. Isolated gingival fibromatosis

2.1 Drug-induced gingival fibromatosis

The most common cause of isolated GO involves anticonvulsant drug therapy, the use of calcium channel blockers for treating angina and hypertension or cyclosporine A for preventing the rejection of organs transplanted in subjects affected by autoimmune diseases.

Anticonvulsants	Calcium channel blockers	Antibiotics
Phenytoin	Nifedipine	Cyclosporin A
Carbamazepine	Amlodipine	
Etosuximide	Bepriidil	
Sodium valproate	Felodipine	
Primidone	Nitrendipine	
Fenoprofen	Nicardine	
Felbamate	Verapamil	
Mephenytoin	Nimodipine	
Mesuximide		
Phenobarbital		
Phensuximide		

Table 1. Drugs that may induce gingival fibromatosis (Doufexi et al., 2005)

Among the first two drugs' categories, phenytoin and nifedipine are responsible for the most frequent forms of GF. The prevalence of GF secondary to drug treatment ranges in different studies, from 0 to 100% following long term phenytoin therapy, 0.5 to 83% after nifedipine and 8 to 81% following treatment with cyclosporin A (Kataoka et al., 2005). The variability of these figures, which reflects heterogeneity of investigated cases, does not allow at present to suggest any empiric risk of developing an adverse reaction to these medications. In addition, to date, a correlation between the administered dose and the prevalence and severity of GF cannot be established. Nevertheless, it has been found that the combined regimen of nifedipine and cyclosporine in children undergoing organ transplants increases both the prevalence and severity of GF (Somacarrera et al., 1994). The development of GF after drug exposure has been related to an underlying individual genetic susceptibility. Possible candidate risk factors have been considered the polymorphic mutations in genes affecting the activity of cytochrome P450, which is responsible for the hepatic metabolism of drugs implicated in GF (Seymour et al., 2000).

2.2 Hereditary gingival fibromatosis

Hereditary gingival fibromatosis is a rare disorder (about one in 750,000 individuals), transmitted either as an autosomal dominant or, rarely, an autosomal recessive trait (Jorgenson and Cocker, 1974, Takagi et al., 1991). Different inheritance patterns, ages at onset and severity of the clinical manifestations in these patients, along with the presence of both isolated and syndromic forms reflect the underlying genetic heterogeneity. To date, four loci for isolated HGF have been identified, on chromosomes 2p21 (GINGF1, MIM # 135300), 5q13-q22 (GINGF2, MIM 605544), 2p23.3-p22.3 (GINGF3, MIM 609955) and 11p15 (GINGF4, MIM 611010). An additional locus has been assigned to chromosome 2p16-p13. Sequencing of the 16 known genes, which mapped...GINGF1, in the critical region of GINGF1 disclosed a heterozygous frameshift mutation in Son-of-Sevenless-1 (SOS-1) gene, which co-segregated with the disease in a Brazilian family (Hart et al., 2002).

Emerson described in 1965, the segregation of isolated GF in a family, for 4 generations. The disease was transmitted to the children from an affected parent, with the exception of a woman who, though not affected, transmitted the disease to subsequent generations through affected children, down to her great-grandchildren. The only affected male did not have children (Emerson, 1965). The transmission of the disease through an unaffected woman may be related to a lack of penetrance of the mutation or to mutations of an imprinted gene that is expressed only if maternally transmitted.

Linkage analysis of the entire genome in a Brazilian family with isolated, autosomal dominant GF, led to the identification of a locus on chromosome 2p21-p22, named GINGF1. Among the 32 family members identified, 12 had GF of varying severity; the youngest patient was 4 years old (Hart et al., 1998). Shashi et al have extended linkage analysis to more members of the family previously described and characterized the duplication 2p13-p21, already observed in a child by Fryns et al. (1989). This study restricted the disease-locus to a region of 8 Mb on chromosome 2p21, while the chromosomal region found duplicated in the child, was proximal to the first, on 2p13-p16 (Fryns et al., 1989, Shashi et al., 1999). Genotyping of four Chinese families with the same method, localized the disease-locus in a region of 8.7 cM on chromosome 2p21, which overlaps with that found in the Brazilian family, by 3.8 cM (Xiao et al., 2000). The sequencing of the 16 known genes present in the candidate region, has led to the identification of a heterozygous frameshift mutation, the insertion of a cytosine (g.126.142-126.143insC) in the Son-Of-Sevenless gene, 1 (SOS-1). The

mutation causes premature termination of the protein and the formation of a chimeric product, that consists of 1,105 amino acids, 1,083 amino of which are preserved, towards the NH₂-terminal, followed by 22 new ones. The premature termination eliminates four functional domains near the COOH-terminal, rich in proline, that are necessary for binding with wild type Grb2 (Hart et al., 2002).

Wild type SOS protein consists of three functional segments: the catalytic segment, consisting of the Cdc25 domain and the domain of exchange with Ras (REM), a regulatory NH₂-terminal segment that contains the histone domain, the DH domain and the PH domain (homologous to pleckstrin) that interacts with PIP₂ phosphatidic acid, and the COOH-terminal segment that contains binding sites for various proteins including Grb2.

SOS1 protein acts as a guanine exchange factor (GEF), which links receptor tyrosine kinases to the Ras pathway and controls, therefore, cell proliferation, differentiation, vesicle trafficking and regulation of the cytoskeleton's actin. Under the supervision of two classes of regulatory proteins, the GEF and those activating the GTPase, the Ras protein functions as a molecular switch in the cycle of GDP/GTP. Three Ras-GEFs have been characterized, SOS, the guanine nucleotide-releasing factor and the guanylate nucleotide-releasing protein. All three control the activity of Ras by catalyzing the release of GDP and the association with GTP. Two regulatory regions determine the GEF activity of SOS1: a catalytic site that interacts with the nucleotide-free form of Ras and an allosteric site that enhances the exchange activity when linked to the nucleotide-bound form of Ras. Growth factors induce a rapid dimerization and self-phosphorylation of their receptors. Phosphotyrosine residues in the catalytic region of the receptors act as binding sites for the SH2 domains of various proteins that function as intracellular messengers. By stimulating the growth factor, SOS is recruited from the cytoplasm to the cell membrane as a result of its interaction with Grb2, which is linked to the tyrosine residues of the phosphorylated receptor through its SH2 domain. In this way the interaction between Grb2 and SOS causes the translocation of the complex to the cell membrane, where GDP is exchanged with GTP and Ras is activated. Although the complex Grb2-SOS1 functions exclusively as a Ras activator, SOS1 may also function as a GEF that is specific to the Rac1 GTPase.

Further studies of the mechanism of Ras activation evidenced the following: after growth factor stimulation, SOS translocates to the cell membrane through at least two independent sites, the Grb2 binding site located near the COOH-terminal and the lipid-binding domain, PH. In addition to facilitate the anchor to the membrane, the interaction with the Grb2 protein overcomes the negative self-regulation of SOS mediated by its COOH terminal. The contact of the PH domain with the membrane phospholipids induces conformational changes that allow the binding of Ras.GDP to the allosteric site of SOS, lowering SOS activity. The Ras.GTP generated during the low activity period of SOS binds to the same allosteric site, carrying this way SOS to its maximum activity. This model explains the mechanism of translocation to the cell membrane in association with the regulation of the catalytic activity of SOS. Moreover, the interaction of SOS with Ras.GDP or Ras.GTP further its position on the membrane (Gureasko et al., 2008). It has also been demonstrated that after stimulation with growth factor, Ras is activated both at the Golgi apparatus level and at the cell membrane. Activation of Ras at the cell membrane is transitory, while its action at the Golgi is delayed and prolonged (Buday et al., 2008).

Jang et al showed that the total level of SOS1 transcript is lower in gingival fibroblasts of patients with HGF in respect to those of normal subjects, suggesting that the mutated SOS1 transcript is significantly lower than the wild type transcript. However, the silencing of the

transcript using RNA interference caused a significant reduction of cell proliferation than the one caused by the silencing of the wild type transcript. This suggests that the increased proliferation of HGF fibroblasts is mainly due to the function of mutated SOS1. The authors also noted that the mutation in the SOS1 protein did not alter its distribution on the cell membrane or at the level of organelles and that the mutated SOS1 protein was capable of maintaining the activation of the Ras/MAPK pathway, in the absence of stimulation by growth factors. Therefore, this study evidenced that the HGF mutation determined the gain of function of SOS1, which, in this way, was implicated in the proliferation of fibroblasts regardless of binding with Grb2. The authors also proposed the application of RNA interference as a method of allele-specific depletion of the HGF mutated SOS1 as a control measure of gym hyperplasia (Jang et al., 2007).

The locus 2p23.3-p22.3 (GINGF3) was identified in a Chinese family of 5 generations with autosomal dominant isolated GF, with onset between 2 and 6 years, around the period of tooth eruption. The 12 patients examined had GO that varied from mild to severe. Over 70 genes mapped in the region identified. The direct sequencing of the *GPR113* and *SEL1* genes, selected as candidates based on their functions in signal transduction and tumor suppression respectively, evidenced no mutations (Ye et al., 2005).

In 2001, the analysis of a Chinese family with autosomal dominant isolated GF segregating through 4 generations, led to the identification of the 5q13-q22 locus (GINGF2). Ten of the 20 family members examined showed GF of very early onset, on average between 1 and 6 months of age. Forty-five genes were mapped located in the region identified, some with known functions in the control of cell growth or cell cycle (*LY64*, *RAD17*, *THBS4*, *CETN3*, *GPR11*, *NAIP*, *OCLN*, *RASA1*, *EFNA5*, *FER*). Among these the gene encoding the protein kinase IV, calcium/calmodulin-dependent was proposed as a candidate, given the presence of the phenocopy induced by calcium channel blockers (*CAMK4*, MIM 114080) (Xiao et al., 2001).

Zhu et al observed two large Chinese families with isolated HGF. The disease occurred only in the offspring of affected or carrier females, suggesting a defect of imprinting. The disease segregated, respectively, for 5 and 4 generations and manifested within the first year of life. Linkage analysis of the entire genome was positive for the 11p15 locus. The 11p15 chromosomal region contains at least 14 genes that are subject to imprinting, divided into two groups, and is a region rich in tumor suppressor genes. The authors researched possible mutations or epimutations in the 14 known genes, localized within the region, with negative results. This study did not exclude, however, the presence of small interstitial deletions in the regulatory regions of the analyzed genes, not detectable with the techniques used or in other genes with maternal expression, localized in the region but unknown so far (Zhu et al., 2007).

2.3 Leukemic gingival fibromatosis

Gingival overgrowth is frequently associated with FAB M4 and M5 subtypes of acute myelogenous leukemia and, rarely, myelodysplastic syndrome (chronic myelomonocytic leukemia). The gingival biopsy shows diffuse tumor infiltration, subepithelial. The neoplastic cells appear large with pleomorphic nuclei, large nucleoli and eosinophilic cytoplasm. Although a risk factor for the development of lesions in cases of extramedullary acute myelogenous leukemia, is the presence of cytogenetic abnormalities (*t(8; 21)*, *inv16*), there is, to date, no correlation between specific cytogenetic abnormalities and gingival involvement (Vural et al., 2004).

2.4 Differential diagnosis

The drug-induced forms are clinical and histological phenocopies of the hereditary forms, which can be distinguished only based on positive family history. In addition, acquired forms can be recognized based on the presence of dental plaques and regression following elimination of the pathogenic noxa (Doufexi et al., 2005). Generalized GO may also result from local inflammation, pregnancy or leukemia. Although the leukemic forms resemble HGF, they can be differentiated based on negative family history and histological evidence of neoplastic infiltration.

3. Syndromic gingival fibromatosis

We classified GF syndromes in two large groups of known and unknown aetiology. In the first group, GF has been described as an occasional or constant sign of some syndromes of known aetiology, characterized by the fact that the causative molecular lesions affect the same cellular pathway.

The second group consists of the rare reports of GF associated with a variable constellation of signs and symptoms that, taken together, represent the group of syndromic GF of unknown aetiology. The significant phenotypic overlap of these conditions is underlined by the presence of intermediate phenotypes that, to date, cannot be classified with certainty in distinct clinical entities. This clinical heterogeneity is reflected into a genetic heterogeneity, evidenced by the presence of observations of autosomal dominant or recessive transmission. The different conditions or observations are described below, based on a range of variable expression, which extends between the association of GF with hypertrichosis up to the multi-systemic syndromes of Zimmermann-Laband and Ramon.

3.1 Definition of hypertrichosis

Hypertrichosis is defined as the excessive growth of hair, which is distributed normally according to a variable spectrum, compared to the one of individuals of the same age, sex and ethnicity. Hypertrichosis may present with localized or generalized distribution and consist of immature or terminal hair. In the case of generalized hypertrichosis (GH), facial hair is accentuated on the frontal, temporal and preauricular regions. The eyebrows may be thick or confluent. On the back, hair converges along the midline, where it often forms whirls over the spine. The distribution can also be localized, associated with nevi or a *spina bifida occulta*, a previous trauma or irritation from chemicals and some inherited conditions autosomal dominant or recessive. Hypertrichosis should be distinguished from hirsutism that is excessive hair growth with distribution of male type (upper lip, chin, chest, *linea alba*, thighs and armpits), and that can be idiopathic or associated with overproduction of androgens. In contrast to hypertrichosis, the presence of hirsutism in childhood should orient towards the exclusion of endocrine causes of virilization. Generalized hypertrichosis may be one of the signs of a syndrome or of a metabolic disease (Baumeister, 1995).

3.2 Syndromic gingival fibromatosis of known aetiology

The syndromic forms of GF of known aetiology, include some phacomatoses, such as neurofibromatosis type 1, tuberous sclerosis and certain metabolic diseases such as alpha-mannosidosis (MIM #248500), Salla disease (MIM #604369), and I cell disease (MIM #252500). In the case of the phacomatoses, the overgrowth is characterized by fibrotic changes typical of gum neurofibromas/angiofibromas. In the case of metabolic diseases,

histology shows the accumulation of gum-specific molecules, identical to those identified in other tissues (Ishigami et al., 1995, Gorlin et al., 2001). Almost all patients with Robinow syndrome (MIM # 268310) have gingival hyperplasia with dental crowding (Wilkie, 2008). The gingival hyperplasia is observed in 65% of patients with Costello syndrome (Hennekam, 2003) and in patients with leprechaunism or Donohue syndrome (MIM #246200) (Gorlin et al., 2001). Gingival hyperplasia is a constant feature of the multiple osteolysis syndrome of Murray-Puretic-Drescher, while it occurs occasionally in Winchester syndrome (MIM #277950) (Gorlin et al., 2001, Mosig et al., 2008). A single epileptic patient with Bardet-Biedl syndrome manifested GF, probably secondary to carbamazepine therapy (Drugowick et al., 2007). With the exception of the phacomatoses and Costello syndrome, that are due to autosomal dominant mutations, all other known disorders with GF are inherited as autosomal recessive traits. Sun et al. (2009) demonstrated that generalized hypertrichosis terminalis with or without gingival hyperplasia is a contiguous gene disorder caused by deletion of chromosome 17q24.2-q24.3. One of the affected individuals displayed a phenotype resembling Julia Pastrana (1834-1860), the first known case of GF, hypertrichosis, macrocephaly and coarse facies (Bondeson e Miles, 1993).

3.2.1 Ras-MAPK pathway and gingival overgrowth

Gingival overgrowth may be an occasional or recurrent feature in some genetic disorders caused by alterations in the proteins of the RAS-MAPK pathway. This pathway is regulated by the action of the SOS-1 protein, which is mutated in a subset of patients with isolated GF. Hart et al., (2007) demonstrated that the overall level of SOS-1 transcript is lower in HGF1 fibroblasts. The relative level of wild-type SOS-1 transcript appeared to be higher than the mutant transcript in HGF1 fibroblasts. The targeting of mutant transcripts by methods of RNA interference produced more profound effects on reduction of cell proliferation than the targeting of the wild-type, suggesting that the increased proliferation of HGF1 fibroblasts was chiefly dependent upon the function of mutant SOS-1.

Ras proteins are enzymes associated to the cell membrane that fluctuate from the active state of binding the active guanosine triphosphate (GTP) to the inactive state of binding with guanosine bisphosphate (GDP). The Ras GTPases are key mediators in pathways that transmit extracellular stimuli, through receptors on the cell surface, to the cell nucleus. They act as molecular switches in the processes of proliferation, differentiation, survival and cell death and are activated by different types of cellular receptors or calcium channels, upstream of the pathway. The exchange reaction between GDP and GTP is triggered by guanine nucleotide exchange factors, including the SOS-1 protein. The activated form of association with the GTP interacts with a broad spectrum of effector proteins including Raf, MEK1/2 and ERK1/2, and triggers downstream pathways (Aoki et al., 2008).

The SOS-1 protein is expressed in various tissues and cells, including human gingiva, where it can be localized inside the epithelial and stromal cells. The SOS-1-Ras-ERK1/2 pathway seems to be the central switch of expression of key molecules of the fibrosis process and of HGF. In fact, the activation of this pathway increases the expression of type IV collagen, the connective tissue growth factor CTGF, growth factor TGF- β , of the collagenase inhibitors TIMP and decreases the expression of metalloprotease MMP that degrades extracellular matrix components. The loss of function of metalloprotease type 2, that causes Winchester syndrome, results, therefore, in an altered homeostasis of connective tissue with accumulation of its physiological substrates, including collagen, fibronectin and laminin. Thus, the increased activation of the Ras/MAPK pathway by mutations of the SOS-1 gene

that determine a permanently active form of the coded protein, result in the increase of the expression of all pro-fibrotic molecules mentioned above.

Drugs that induce GF disturb the metabolic pathways involved in the translation of signals on behalf of the intracellular calcium ions (Ca^{2+}). This suggests that this pathway is involved in the development of fibrosis. Several ion channels located on the cell membrane regulate the flow of Ca^{2+} ions, which, in turn, affects the signal transduction pathways, including the Ras/MAPK pathway, directly or indirectly, through proteins that bind Ca^{2+} . Among these, the best characterized to date are the calmodulins (CaM) that reduce the expression of TGF- β and the activation of ERK1/2.

Ras proteins also participate in the communication between the insulin-receptor complex on the cell surface and the activation of cytosolic proteins downstream. In particular, the insulin receptor interacts with the proteins Gab-1, p60dok, Cbl, APS and isoforms of Shc10. The phosphorylated tyrosine residues of the activated insulin receptor act as docking sites for proteins containing SH2 domains (Src-homology-2). Many of these molecules are "adaptors", including proteins PI(3)K and Grb2, which, in turn, bind to the guanine nucleotide exchange factors, including the SOS protein-1 and activate the Ras/MAPK pathway (Saltiel and Kahn, 2001). However, it is not known whether insulin receptors are expressed in gingival tissue.

In conclusion, the SOS-1-Ras-ERK1/2 pathway regulates genes whose expression is altered in HGF and are involved in the process of fibrosis. It might be suggested that a defect at any level of this signaling cascade, which increases the expression of pro-fibrotic genes, promotes the development of GF.

It is interesting to observe a gingival phenotype both in NF1, which is caused by loss of function of neurofibromin, a negative regulator of Ras activation, and in Costello syndrome, caused by gain of function mutations of the *H-Ras* gene. Although the biochemical functions of tuberin and hamartin are not known to date, coded respectively by the *TSC1* and *TSC2* genes, we know that tuberin contains a region of homology with proteins that activate small GTPases such as Ras protein. The loss of function of tuberin could lead to a continuous stimulation of the pathways triggered by Ras. The CMG2 protein, mutated in the Murray-Puretic-Drescher syndrome, which is consistently associated with gingival hyperplasia, is an integrin-like molecule of the cell membrane that regulates cell adhesion to laminin and to collagen type IV. The metabolic pathways regulated by CMG2 are not known in detail, to date, but it is known that the cell adhesion pathway transmits signals to SOS-1-Ras-ERK1/2 and therefore there is a possible link between CMG2 and this signaling cascade. The differential involvement of multiple tissues or of the gingiva exclusively seems to depend on the functional importance of each of the mutated genes in the different cells and tissues (Häkkinen and Csiszar, 2007).

Several heterozygous, gain of function mutations of the *SOS-1* gene have been associated with a distinct form of Noonan syndrome with high prevalence of ptosis and pulmonary valve stenosis, ectodermal symptoms and, generally, the absence of mental and developmental retardation. None of the affected with confirmed *SOS-1* mutations described to date, presented with GF or was predisposed to the development of tumors. Furthermore, the mutations described are not associated with any type of tumor (Tartaglia et al., 2007, Roberts et al., 2007, Zenker et al., 2007). There were no further observations of HGF due to *SOS-1* mutations. The C.3248-3249insC mutation in exon 21 of the gene, linked to HGF, has not been observed to date in people with Noonan syndrome. All *SOS-1* mutations result in a gain of function but the one related to HGF is the only frameshift one, resulting in a

chimeric, truncated protein. All other *SOS-1* mutations described to date do not result in truncated proteins. The HGF mutation affects the *SOS-1* domain of binding to Grb2 correlated to its self-negative regulation, but functional studies have shown that this mutation does not alter the intracellular localization of *SOS-1* or its function of activating the Ras/MAPK pathway via ERK1/2 (Jang et al., 2007).

Mutations in key components of the MAPK pathway that cause prolonged activation of ERK are related to the formation of tumors (Aoki et al., 2005). The formation of skin tumors has been highlighted in transgenic mice for *SOS-1*, artificially constructed, with deletion of the COOH terminal (Sibilia et al., 2000). It is believed that the activity of the strong promoters used in these experiments produces high levels of expression of the mutant protein that causes significant increase of ERK activity and leads to transformation. This means, there is probably a threshold of protein expression beyond which transformation happens. It is assumed that the benign form of the overgrowth in HGF can be interpreted as follows: the low levels of mutant *SOS-1* that is partially free from self-inhibition could lead to a continuous activation of ERK that could be sufficient to cause increased proliferation but not cell transformation (Jang et al., 2007). In the presence of a cellular environment with EGFR receptor of reduced activity, transgenic mice do not form skin cancers, despite the gain of function, and thus the continued activation of the MAPK on behalf of the artificial *SOS-1* protein (Sibilia et al., 2000).

In conclusion, it is not yet known why the various *SOS-1* mutations produce distinct phenotypes or why the overgrowth in HGF is confined in the gingival tissue. A specific mutation-disease correlation could be hypothesized, secondary to the specific functions of the *SOS-1* protein in gingival tissue or a tolerance/compensation of the gain of function caused by the frameshift mutation, in the other tissues (Jang et al., 2007).

3.3 Syndromic gingival fibromatosis of unknown aetiology

A number of subjects with GF associated with variable signs and symptoms can be regarded as examples of GF syndromes of unknown etiology, which, in descending order of number of observations, include GF, hypertrichosis, epilepsy and/or mental retardation (MR) syndrome; Zimmermann-Laband syndrome (MIM %135500); Jones syndrome (Jones et al., 1997); Ramon syndrome (MIM 2662700); Rutherford syndrome (MIM %180900), GF syndrome and characteristic facies (MIM 228560). GO is an occasional feature of Sturge-Weber syndrome (MIM 185300). This anomaly is secondary to angiomatous proliferation, worsened by GF caused by treatment of the epileptic symptoms (Bhansali et al., 2008). In general, these cases are rare and mostly sporadic, with the exception of Ramon syndrome, an autosomal recessive disorder, and single reports of affected sibs pairs, born to unaffected parents, presenting with GF, hypertrichosis, epilepsy and/or MR or manifesting the Zimmermann-Laband syndrome or intermediate phenotypes (Gorlin et al., 2001).

Taking into account the GF syndromic forms of unknown aetiology mentioned above, the existence in the literature of not clearly distinct phenotypes becomes evident, given the rarity of the observations and the significant overlap of signs/symptoms. There are "wide" clinical spectrums such as Ramon and ZL syndromes, which include a set of signs/symptoms that have also been observed individually associated with GF. The constant segregation of the association of GF with acro-osteolysis or cherubism, all three very rare signs, suggests that the ZL and Ramon syndromes are distinct clinical genetic entities. The two syndromes share, with different frequencies, the observations of GF, hypertrichosis, epilepsy and MR, an association described as an isolated clinical entity,

and retinal alterations of the pigmentosum type (Koch et al., 1992, Parkin and Law, 2001). It has been suggested that the association of isolated GF with hypertrichosis is the minimum clinical expression of the phenotypic spectrum of the ZLS (Lacombe et al., 1994) but that should probably be differentiated, given the absence of any further signs/symptoms (Robertson et al., 1998). An important hallmark is the finger hypoplasia, especially of the feet, and/or of the nails with or without an underlying hypoplasia of the terminal phalanges, especially in a patient without cognitive impairment and/or organomegaly, both non-mandatory symptoms of the ZLS. Based on the observation of the association of this last sign to GF and a hyperextensibility of the small joints Bakaeen and Scully (1991) reported the recurrence of the syndrome of ZL, in the children of a couple of cousins.

The unclear distinction between the phenotype of ZL and GF, hypertrichosis, epilepsy, MR, has been highlighted by several observations of intermediate phenotypes. Vontobel et al (1973) described a sporadic patient, who presented GF, congenital generalized hypertrichosis, mild hypoplasia of the fingernails and, especially, the feet, and acromegaloid features acromegaloidi that were not due to an underlying endocrinological disorder. The patient had psychomotor retardation (she walked alone at the age of 2 years, spoke the first phrases at 3-4 years), but her IQ was normal. Göhlich-Ratman et al (2000) observed the recurrence, in two sisters, daughters of first cousins, of coarse facies, profound MR with severe language impairment, early onset gingival hyperplasia, hypertrichosis and generalized tonic-clonic seizures with onset at 2 years of age. Both also had brachydactyly type E with bilateral shortness of metacarpals III-V and brachitephalangy of the first finger, hypoplastic toenails, and bilateral sandal gap. The authors rule out ZLS for the lack of open bite and hepatomegaly, signs, however, that are not present in all patients with ZL reported in the literature. They speculate, however, that this is a broader phenotype than that observed by Anavi et al (1989) or a distinct syndrome of autosomal recessive GF.

However, the assumption that all these clinical features are part of the same phenotypic spectrum seems validated by the observation of segregation of distinct phenotypes from a father to his two sons. The father, at the age of 45, presented with GF, hypertrichosis, hearing loss and hypotelephalangism with brachydactyly and nail hypoplasia of the thumbs. His 13-year-old son had the same clinical picture, along with hypertrichosis, in the absence of MR. A second son, of 10 months, had inherited the paternal GF and defects of the fingers. The mother and the only daughter were not affected (Haytac and Ozcelik, 2007).

Gingival overgrowth variably associated with GH, MR or epilepsy has been described as a distinct, isolated disorder, with an autosomal dominant inheritance pattern (Anderson et al., 1969, Horning et al., 1985, Cuestas-Carnero and Bornancini, 1988), or as a manifestation of more complex disorders similar to ZLS (Gorlin et al., 2001). It was suggested that the association of GO, GH, MR or epilepsy could represent the mildest expression of ZLS. Distinguishing features in the former include absence of additional features, in particular nail hypoplasia with or without hypotelephalangism, mostly affecting the hands (Lacombe et al., 1994, Robertson et al., 1998). Clinical variability between patients with GO, GH, MR or epilepsy likely reflects genetic heterogeneity is also supported by different inheritance patterns (Nevin et al., 1971, Bakaeen and Scully, 1991, Haytac and Ozcelik, 2007). All these disorders can be lumped in a continuum of increasing severity, from the mildest phenotypes displaying GO, GH, MR and epilepsy to the most complex disorders reported by Göhlich-Ratman et al (2000) and Ramon et al (1967).

4. Generalized hypetrichosis, tonic-clonic seizures with onset in the first months of life, severe mental retardation and gingival overgrowth unrelated to the antiepileptic treatment

We had the opportunity to evaluate an 8-year old girl that was referred for genetic counselling because of MR and convulsions. She was the first daughter of healthy non-consanguineous Italian parents. A younger sister was clinically normal. At birth, the mother was 24-years-old and the father 29. Family history was unremarkable. Pregnancy was complicated by threatened miscarriage during the first trimester, for which the mother was advised with bed rest and treated with isoxuprine. No exposure to teratogenic agents was reported. Serologic tests for cytomegalovirus, toxoplasmosis and rubella, and triple serum marker screening were negative. A standard ultrasound scan at 22½ weeks of gestation was normal. The patient was born at 36 weeks of gestation with the use of forceps. Birth weight was 3,130 g (50th percentile), length 47 cm (10th percentile) and OFC 34 cm (25th percentile). She presented with delayed after birth cry and there was, transitory, self-resolving cyanosis, obvious generalised hypertrichosis and jaundice, which was treated with phototherapy. Apgar scores were not recorded. Cord blood gas values were normal, no resuscitation was required and paediatric monitoring did not reveal any end-organ dysfunction. The patient developed tremors from the first days of life, that, by age of 2 years turned into recalcitrant, generalized, tonic-clonic seizures. The episodes were initially unsuccessfully treated with phenobarbital that was substituted with sodium valproate. Treatment with sodium valproate easily controlled the seizures but this was changed to topiramate after 14 months because the patient was frequently observed lethargic. Developmental milestones were delayed: she sat at 9 months and walked at 2 years. At the time of the evaluation she was undergoing psychomotricity since the last 6 years.

On physical examination she had presented excessive growth of apparently terminal hair, distributed over the upper lip, cheeks, back, arms and forearms and legs. The hair on the back converged over the midline, forming whorls over the lower spine. The face and hands were otherwise unremarkable. Oral inspection disclosed a grade III GO, covering at least threequarters of the tooth crowns (Bökenkamp et al., 1993). Enlarged gingiva was normal in colour and felt firm on palpation. The patient was mentally retarded and had not acquired yet any language skills. She was 120 cm tall and weighed 21 kg (both on the 3rd percentile). On clinical evaluation, the parents were normal.

Electroencephalography disclosed bilateral parossistic activity over the frontal and temporal regions, with a right-side prevalence. Brain computed tomography and magnetic resonance imaging, spine radiographs, heart and abdominal ultrasound were unremarkable. Auditory brainstem response test and ophthalmologic evaluation were normal. The effect of anticonvulsant therapy was monitored with computerized bone mineralometry, which showed unremarkable results. Blood levels of total and free testosterone and DHEA-S were normal. Metabolic workout including serum lactate, ammonia, amino acids, organic acids, cholesterol, very long chain fatty acids, lysosomal enzymes, transferrin isoelectric focusing and urinary mucopolisaccharides was normal. Fibroblast chromosome analysis at the 550 bands level and aCGH analysis at 125 kb of resolution yielded normal results. Parents did not give their permission to perform gum biopsy.

This latter patient presented with a unique association of GH, tonic-clonic seizures with onset in the first months of life, severe MR and GO unrelated to antiepileptic treatment, in

the absence of other signs and/or symptoms (Douzgou et al., 2009). The clinical features of this patient overlapped in part those found in cases of GO associated with GH, MR, epilepsy and ZLS or related phenotypes (Araiche and Brode, 1959, Nevin et al., 1971, Vontobel et al., 1973, Bakaeen and Scully, 1991, Haytac and Ozcelik, 2007). Tonic-clonic seizures have been reported so far only in a single patient with ZLS, who did not manifest GH (Chodirker et al., 1986). Two patients with the GH of Cantu syndrome (CS) presented with GO but manifested additional features and had no seizure (Rosser et al., 1989). Following the original observation of Anavi et al (1989), concerning a brother-sister pair born to consanguineous parents, two additional patients have been reported with similar clinical characteristics, including central nervous system (CNS) anomalies and neurological features (Snyder, 1965, Kiss, 1990). CNS anomalies were not found in our patient, arguing for a different origin of her neurological manifestations. Our patient also resembled Snyder's case 2, but absence of ataxia appeared as the major distinguishing criteria.

ZLS and Ramon syndrome are considered separate disorders, characterized by the association of GO with hypotelephalangism or cherubism. GH, MR, epilepsy and retinal changes can be overlapping features (Gorlin et al., 2001, Koch et al, 2002). It seems that these two diseases represent the extreme spectrum of the phenotypes exhibiting GO, GH, MR and epilepsy. All these disorders can be lumped in a continuum of increasing severity, from the mildest phenotypes displaying GO, GH, MR and epilepsy to the most complex disorders reported by Göhlich-Ratman et al (2000) and Ramon et al (1967). The unique phenotype of our patient, displaying GO, GH, MR and epilepsy without other signs and/or symptoms overlaps, in part, with the features observed in the three autosomal recessive disorders sharing GO, GH, MR and epilepsy and seems to represent a further example of clinical variability within the occurring in GO plus conditions (**Table 2**).

4.1 Genetic counselling of gingival fibromatosis

The genetic counselling of a person with GF begins with the collection of anamnestic data such as exposure to GF-inducing drugs, the presence of systemic conditions (pregnancy, leukemia), other family members affected, presence of psychomotor retardation and/or seizures. Physical examination can evaluate a number of signs/symptoms that may orient towards the definition of the recurrence risk (RR). In the absence of other signs/symptoms associated, the *SOS-1* gene can be sequenced. In case the molecular analysis is negative, a linkage analysis of the *GINGF2-4* known loci, to date, can be undertaken. The presence of hearing loss (Jones syndrome) or corneal opacities (Rutherford syndrome) or the association with hypertrichosis suggest an autosomal dominant segregation. The presence of cherubism confirms the diagnosis of Ramon syndrome, which is autosomal recessive. The finding of macrocephaly orients towards the clinical entities described by Canun et al. (2003) and Goldblatt and Singer (1992), with different modes of transmission, depending on the associated dysmorphisms. The recognition of a pattern of multisystemic anomalies (heart disease and/or short stature and/or genitourinary anomalies) associated to GF and hypertrichosis may point to specific, rare syndromes of defined RR. The nail hypoplasia with or without hypotelephalangism allows the diagnosis of ZL, but does not define the RR. Regarding possible patients with the combination of variable GF, hypertrichosis, epilepsy and MR, cerebral magnetic resonance imaging and X-rays of hands and/or a metacarpophalangeal profile may confirm a 25% RR in the cases, respectively, of CNS anomalies or brachydactyly/metacarpus (**Figure 1**).

Feature	GO, GH, MR or epilepsy			Intermediate phenotypes					ZLS	CS	GO, GH, MR, epilepsy and other neurological signs				RS	Douzgov et al., 2009
	1	2	3	4	5	6	7	8			11, P2	12	13	14		
GO	+	+	+	+	+	+	+	+	9	10	+	+	+	9	+	
GH	+	+	+	-	-	+	-	+/-	+/-	+	+	+	+	+/-	+	
Tonic-clonic seizures, onset <4y	+	-	-	-	+	-	-	+/-	+/-	-	+	+	+	+	+	
MR	-	+	+/-	+	+	+	+	+/-	+/-	+/-	+	+	+	+	+	
Other	-	-	-	+	+	+	+	+	+	+	+	+	+	+	+	
Dysmorphic face and/or cherubism	-	-	-	-	-	+	+	+	+	+	+	+	+	+	-	
Neurological signs and/or CNS anomalies	-	-	-	-	-	-	-	+/-	+	+	-	+	+	+	-	
Nail hypodysplasia	-	-	-	-	-	-	-	-	-	BA/-	At	Hp, BA	SP, BA	-	-	
Brachydactyly	-	-	-	-	-	+	+	+	+	-	-	-	-	-	-	
Contractures	-	-	-	-	-	+	+	+	-	-	-	-	-	-	-	
Joint hyperextensibility	-	-	-	-	-	-	-	-	-	-	-	-	-	-	-	
Skeletal dysplasia, generalised	-	-	-	-	-	-	-	-	+/-	-	-	-	-	-	-	
Heart defect	-	-	-	-	-	-	-	-	-	+	-	-	-	-	-	
Hepato/splenomegaly	-	-	-	-	-	-	-	-	+/-	+	-	-	-	-	-	
Urogenital anomalies	-	-	-	-	-	-	-	-	+/-	+/-	-	-	-	+/-	-	
Deafness	-	-	-	+	-	-	-	+	-	-	-	-	-	+/-	-	
Ocular anomalies	-	-	-	-	-	-	-	-	-	-	-	-	-	+/-	-	
Nevi, multiple	-	-	-	-	-	-	-	-	+/-	-	-	-	-	+/-	+	
Growth retardation, postnatal	-	-	-	-	-	-	-	-	-	-	-	-	-	-	-	
Segregation	-	-	AD	-	AR	-	AR	AD	AD	AD	-	AR	-	AR	-	

1, Horning et al. (1985); 2, Anderson et al. (1969); 3, Cuestas-Carnero and Bornancini (1988); 4, Araiche and Brode (1959); 5, Nevin et al. (1971); 6, Vontobel et al. (1973); 7, Bakaeen and Scully (1991); 8, Haytak and Oczelik (2007); 9, Gorlin et al. (2001); 10, Rosser (1998); 11, Snyder (1965); 12, Anavi et al. (1989); 13, Kiss (1990); 14, Göhlich-Ratman et al. (2000); +, present; - absent; +/-, variable; GO, gingival overgrowth; GH generalized hypertrichosis; MR, mental retardation; y, years; RS, Ramon syndrome; ZLS, Zimmermann-Laband syndrome; CS, Cantu syndrome; P2, patient 2; BDE, brachydactyly type E; CNS, central nervous system; At, ataxia; BA, brain atrophy; SP, spastic paraparesis; Hp, hypotonia; AR, autosomal recessive; AD, dominant.

Table 2. Clinical features in patients with GF syndromic disorders.

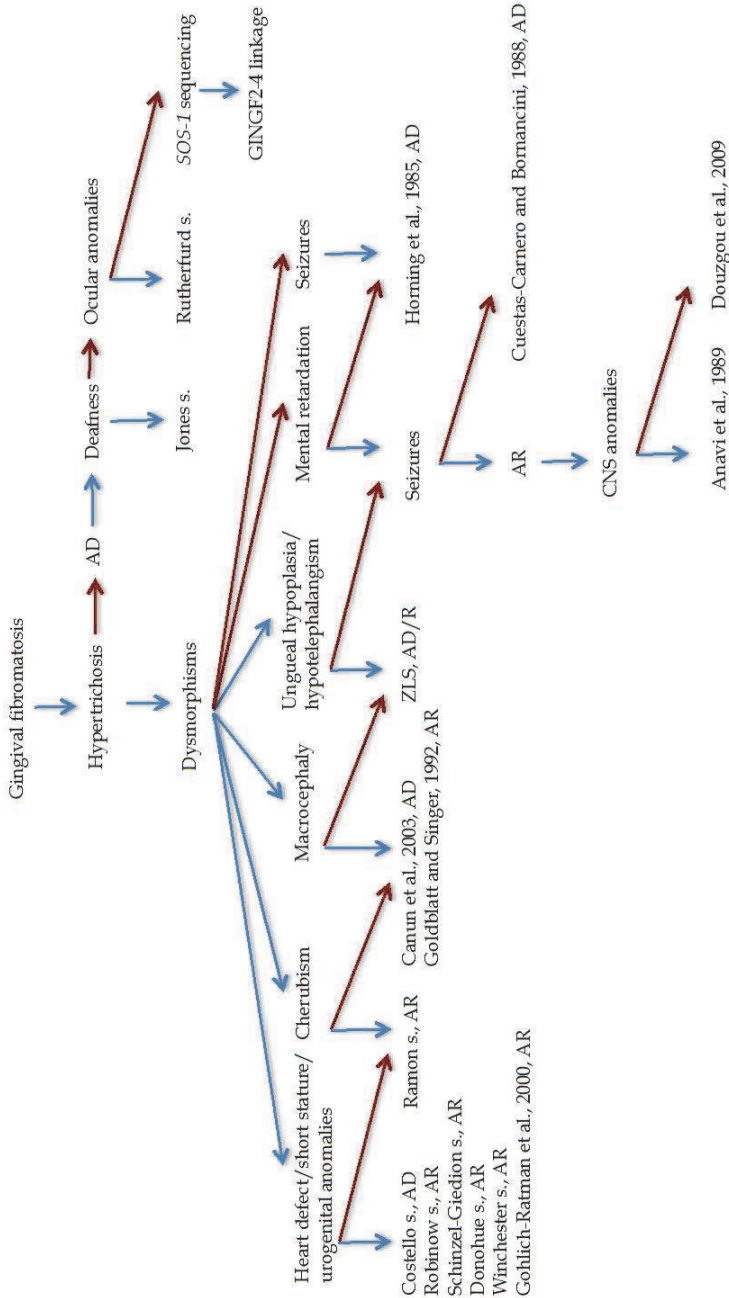


Fig. 1. HGF genetic counselling algorithm; blue arrows, presence; red arrows, absence.

The prognosis of patients with syndromic GF is related to the presence of MR, postnatal growth failure, epilepsy, heart disease and predisposition to cancer. In the specific patient that we described, given a possible diagnosis of ZLS, the monitoring of cardiorespiratory function before the age of 18 years or before embarking on exercise programs is suggested.

5. Conclusion

The patient that we observed is an example of an extremely rare developmental defect present at birth, which is not obvious to the methods currently used for prenatal diagnosis. Her condition is part of the 2-3% of congenital dysmorphisms that require genetic counselling. The absence of a known genetic lesion narrows the diagnostic approach to the clinical-observational aspect. The comparison and classification of this very rare clinical observation was essential in defining the risk of recurrence of the family and the patient's prognosis. The clinical classification of rare genetic conditions is an essential step, along with the descriptions of additional observations and the advances in research, for the discovery of their molecular causes, and thus for the care of the patients and their families.

Of all the branches of medical genetics, genetic counselling of rare congenital dysmorphisms represents the field with the greatest impact of the clinical geneticist. This is justified by such an association of factors as the high incidence of birth defects and hence the increased demand of services of genetic counselling and the rarity of the individual observations, which does not, therefore, permit the diagnosis in first level health services and/or by staff with a general training in medical genetics. The organization of the clinical genetics service in a second or third level facility allows the grouping of these observations in registers or databases that permits the comparison of clinical pictures among different patients as well as the exchange of opinions with other experts. All these processes depict the clinical geneticist as the central, decision-making figure of the genetic counselling of patients with rare dysmorphisms.


6. References

- [1] Anavi Y, Lerman P, Mintz S, Kiviti S. Idiopathic familial gingival fibromatosis associated with mental retardation, epilepsy and hypertrichosis. *Dev Med Child Neurol* 1989;31:538-42.
- [2] Anderson J, Cunliffe WJ, Roberts DF, Close H. Hereditary gingival fibromatosis. *Br Med J* 1969;3:218-19.
- [3] Aoki Y, Niihori T, Kawame H, Kurosawa K, Ohashi H, Tanaka Y, Filocamo M, Kato K, Suzuki Y, Kure S, Matsubara Y. Germline mutations in HRAS proto-oncogene cause Costello syndrome. *Nat Genet* 2005;37:1038-40.
- [4] Aoki Y, Niihori T, Narumi Y, Kure S, Matsubara Y. The RAS/MAPK syndromes: novel roles of the RAS pathway in human genetic disorders. *Hum Mutat.* 2008;29:992-06.
- [5] Araiche M, Brode H. A case of fibromatosis gingivae. *Oral Surg Oral Med Oral Pathol* 1959;12:1307-10.
- [6] Bakaeen G, Scully C. Hereditary gingival fibromatosis in a family with the Zimmermann-Laband syndrome. *J Oral Pathol Med* 1991;20:457-9.
- [7] Baptista IP. Hereditary gingival fibromatosis: a case report. *J Clin Periodontol* 2002;29:871-4.

- [8] Baumeister FA, Schwarz HP, Stengel-Rutkowski S. Childhood hypertrichosis: diagnosis and management. *Arch Dis Child* 1995;72:457-9.
- [9] Bhansali RS, Yeltiwar RK, Agrawal AA. Periodontal management of gingival enlargement associated with Sturge-Weber syndrome. *J Periodontol* 2008;79:549-55.
- [10] Bökenkamp A, Bohnhorst B, Beier C, Albers N, Offner G, Brodehl J. Nifedipine aggravates cyclosporine A-induced gingival hyperplasia. *Pediatr Nephrol* 1994;8:181-5.
- [11] Bondeson J, Miles AE. Julia Pastrana, the nondescript: an example of congenital, generalized hypertrichosis terminalis with gingival hyperplasia. *Am J Med Genet* 1993;47:198-212.
- [12] Buday L, Downward J. Many faces of Ras activation. *Biochim Biophys Acta*. 2008 May 21.
- [13] Canún S, Guevara-Sanginés EG, Elvira-Morales A, Sierra-Romero Mdel C, Rodríguez-Asbun H. Hypertrichosis terminalis, gingival hyperplasia, and a characteristic face: a new distinct entity. *Am J Med Genet A* 2003;116A:278-83.
- [14] Chodirker BN, Chudley AE, Toffler MA, Reed MH. Zimmerman-Laband syndrome and profound mental retardation. *Am J Med Genet* 1986;25(3):543-7.
- [15] Cuestas-Carnero R, Bornancini CA. Hereditary generalized gingival fibromatosis associated with hypertrichosis: report of five cases in one family. *J Oral Maxillofac Surg* 1988;46:415-20.
- [16] Doufexi A, Mina M, Ioannidou E. Gingival overgrowth in children: epidemiology, pathogenesis, and complications. A literature review. *J Periodontol* 2005;76:3-10.
- [17] Drugowick RM, Da Rós Gonçalves L, Barrôso AS, Feres-Filho EJ, Maia LC. Treatment of gingival overgrowth in a child with Bardet-Biedl syndrome. *J Periodontol* 2007;78:1159-63.
- [18] Emerson TG. Hereditary gingival hyperplasia. a family pedigree of four generations. *Oral Surg Oral Med Oral Pathol* 1965;19:1-9.
- [19] Fryns JP, Kleczkowska A, Kenis H, Decock P, Van den Berghe H. Partial duplication of the short arm of chromosome 2 (dup(2)(p13---p21) associated with mental retardation and an Aarskog-like phenotype. *Ann Genet* 1989;32:174-6.
- [20] Göhlich-Ratmann G, Lackner A, Schaper J, Voit T, Gillessen-Kaesbach G. Syndrome of gingival hypertrophy, hirsutism, mental retardation and brachymetacarpia in two sisters: specific entity or variant of a described condition? *Am J Med Genet Part A* 2000;95:241-6.
- [21] Goldblatt J, Singer SL. Autosomal recessive gingival fibromatosis with distinctive facies. *Clin Genet* 1992;42:306-8.
- [22] Gorlin RJ, Cohen MM, Hennekam RCM. *Syndromes of the Head and Neck*, 3rd edn. New York: Oxford University Press 2001: 847-858.
- [23] Gureasko J, Galush WJ, Boykevich S, Sondermann H, Bar-Sagi D, Groves JT, Kuriyan J. Membrane-dependent signal integration by the Ras activator Son of sevenless. *Nat Struct Mol Biol* 2008;15:452-61.
- [24] Häkkinen L, Csiszar A. Hereditary gingival fibromatosis: characteristics and novel putative pathogenic mechanisms. *J Dent Res* 2007;86:25-34.
- [25] Hart TC, Pallos D, Bowden DW, Bolyard J, Pettenati MJ, Cortelli JR. Genetic linkage of hereditary gingival fibromatosis to chromosome 2p21. *Am J Hum Genet* 1998;62:876-83.

- [26] Hart TC, Zhang Y, Gorry MC, Hart PS, Cooper M, Marazita ML, et al. A mutation in the *SOS1* gene causes hereditary gingival fibromatosis type 1. *Am J Hum Genet* 2002;70:943-954.
- [27] Haytac MC, Ozcelik O. The phenotypic overlap of syndromes associated with hereditary gingival fibromatosis: follow-up of a family for five years. *Oral Surg Oral Med Oral Pathol Oral Radiol Endod* 2007;103:521-7.
- [28] Hennekam RC. Costello syndrome: an overview. *Am J Med Genet C Semin Med Genet* 2003;117C:42-8.
- [29] Horning GM, Fisher JG, Barker BF, Killoy WJ, Lowe JW. Gingival fibromatosis with hypertrichosis. A case report. *J Periodontol*. 1985;56:344-7.
- [30] Ishigami T, Schmidt-Westhausen A, Philipsen HP, Baiborodin SI, Gelderblom H, Reichart PA. Oral manifestations of alpha-mannosidosis: report of a case with ultrastructural findings. *J Oral Pathol Med* 1995;24:85-8.
- [31] Jang SI, Lee EJ, Hart PS, Ramaswami M, Pallos D, Hart TC. Germ line gain of function with *SOS1* mutation in hereditary gingival fibromatosis. *J Biol Chem* 2007;282:20245-5.
- [32] Jorgenson RJ, Cocker ME. Variation in the inheritance and expression of gingival fibromatosis. *J Periodontol* 1974;45:472-7.
- [33] Kataoka M, Kido J, Shinohara Y, Nagata T. Drug-induced gingival overgrowth—a review. *Biol Pharm Bull* 2005;28:1817-21.
- [34] Kelekis-Cholakias A, Wiltshire WA, Birek C. Treatment and longterm follow-up of a patient with hereditary gingival fibromatosis: a case report. *J Can Dent Assoc* 2002;68:290-4.
- [35] Kiss P. Gingival fibromatosis, mental retardation, epilepsy and hypertrichosis. *Dev Med Child Neurol* 1990;32:459-60.
- [36] Koch P, Wettstein A, Knauber J, Zaun H. A new case of Zimmermann-Laband syndrome with atypical retinitis pigmentosa. *Acta Derm Venereol* 1992;72:376-9.
- [37] Lacombe D, Bioulac-Sage P, Sibout M, Daussac E, Lesure F, Manchart JP, Battin J. Congenital marked hypertrichosis and Laband syndrome in a child: overlap between the gingival fibromatosis-hypertrichosis and Laband syndromes. *Genet Couns* 1994;5:251-6.
- [38] Mosig RA, Dowling O, Martignetti JA. MMP2 and the Multicentric Osteolysis, Nodulosis and Arthropathy (MONA). *Inborn Errors of Development: The Molecular Basis of Clinical Disorders of Morphogenesis*. Oxford Monographs on Medical Genetics. 2nd edn. 2008.
- [39] Parkin B, Law C. Axenfeld anomaly and retinal changes in Ramon syndrome: follow-up of two sibs. *Am J Med Genet* 2001;104:131-4.
- [40] Perkoff D. Primary generalized hypertrophy of the gums. *Lancet* 1929;1:1294-7.
- [41] Ramon Y, Berman W, Bubis JJ. Gingival fibromatosis combined with cherubism. *Oral Surg Oral Med Oral Pathol* 1967;24:435-48.
- [42] Roberts AE, Araki T, Swanson KD, Montgomery KT, Schiripo TA, Joshi VA, Li L, Yassin Y, Tamburino AM, Neel BG, Kucherlapati RS. Germline gain-of-function mutations in *SOS1* cause Noonan syndrome. *Nat Genet* 2007;39:70-4.
- [43] Robertson SP, Lipp H, Bankier A. Zimmermann-Laband syndrome in an adult. Long-term follow-up of a patient with vascular and cardiac complications. *Am J Med Genet* 1998;78:160-4.

- [44] Saltiel AR, Kahn CR. Insulin signalling and the regulation of glucose and lipid metabolism. *Nature* 2001;414:799-806.
- [45] Seymour RA, Ellis JS, Thomason JM. Risk factors for drug-induced gingival overgrowth. *J Clin Periodontol* 2000;27:217-23.
- [46] Sibilila M, Fleischmann A, Behrens A, Stingl L, Carroll J, Watt FM, Schlessinger J, Wagner EF. The EGF receptor provides an essential survival signal for SOS-dependent skin tumor development. *Cell* 2000;102:211-20.
- [47] Shashi V, Pallos D, Pettenati MJ, Cortelli JR, Fryns JP, von Kap-Herr C, Hart TC. Genetic heterogeneity of gingival fibromatosis on chromosome 2p. *J Med Genet* 1999;36:683-6.
- [48] Snyder CH. Syndrome of gingival hyperplasia, hirsutism, and convulsions; dilantin intoxication without dilantin. *J Pediatr* 1965;67:499-502.
- [49] Somacarrera ML, Hernández G, Acero J, Moskow BS. Factors related to the incidence and severity of cyclosporin-induced gingival overgrowth in transplant patients. A longitudinal study. *J Periodontol* 1994;65:671-5.
- [50] Takagi M, Yamamoto H, Mega H, Hsieh KJ, Shioda S, Enomoto S. Heterogeneity in the gingival fibromatoses. *Cancer* 1991;68:2202-12.
- [51] Tartaglia M, Pennacchio LA, Zhao C, Yadav KK, Fodale V, Sarkozy A, Pandit B, Oishi K, Martinelli S, Schackwitz W, Ustaszewska A, Martin J, Bristow J, Carta C, Lepri F, Neri C, Vasta I, Gibson K, Curry CJ, Siguero JP, Digilio MC, Zampino G, Dallapiccola B, Bar-Sagi D, Gelb BD. Gain-of-function SOS1 mutations cause a distinctive form of Noonan syndrome. *Nat Genet* 2007;39:75-9.
- [52] Vontobel F. Idiopathic gingival hyperplasia and hypertrichosis associated with acromegaloid features. *Helv Paediatr Acta* 1973;28:401-11.
- [53] Vural F, Ozcan MA, Ozsan GH, Demirkan F, Piskin O, Ates H, Kargi A, Undar B. Gingival involvement in a patient with CD56+ chronic myelomonocytic leukemia. *Leuk Lymphoma* 2004;45:415-8.
- [54] Wilkie AOM. ROR2 and Brachydactyly type B and Recessive Robinow Syndrome. *Inborn Errors of Development: The Molecular Basis of Clinical Disorders of Morphogenesis*. Oxford Monographs on Medical Genetics. 2nd edn. 2008.
- [55] Xiao S, Wang X, Qu B, Yang M, Liu G, Bu L, Wang Y, Zhu L, Lei H, Hu L, Zhang X, Liu J, Zhao G, Kong X. Refinement of the locus for autosomal dominant hereditary gingival fibromatosis (GINGF) to a 3.8-cM region on 2p21. *Genomics* 2000;68:247-52.
- [56] Xiao S, Bu L, Zhu L, Zheng G, Yang M, Qian M, et al. A new locus for hereditary gingival fibromatosis (GINGF2) maps to 5q13-q22. *Genomics* 2001;74:180-185.
- [57] Ye X, Shi L, Cheng Y, Peng Q, Huang S, Liu J, et al. A novel locus for autosomal dominant hereditary gingival fibromatosis, GINGF3, maps to chromosome 2p22.3-p23.3. *Clin Genet* 2005;68:239-244.
- [58] Zenker M, Horn D, Wiczorek D, Allanson J, Pauli S, van der Burgt I, Doerr HG, Gaspar H, Hofbeck M, Gillessen-Kaesbach G, Koch A, Meinecke P, Mundlos S, Nowka A, Rauch A, Reif S, von Schnakenburg C, Seidel H, Wehner LE, Zweier C, Bauhuber S, Matejas V, Kratz CP, Thomas C, Kutsche K. SOS1 is the second most common Noonan gene but plays no major role in cardio-facio-cutaneous syndrome. *J Med Genet* 2007;44:651-6.
- [59] Zhu Y, Zhang W, Huo Z, Zhang Y, Xia Y, Li B, Kong X, Hu L. A novel locus for maternally inherited human gingival fibromatosis at chromosome 11p15. *Hum Genet* 2007;121:113-23.



Underlying Mechanisms of Epilepsy

Edited by Prof. Fatima Shad Kaneez

ISBN 978-953-307-765-9

Hard cover, 354 pages

Publisher InTech

Published online 26, September, 2011

Published in print edition September, 2011

This book is a very provocative and interesting addition to the literature on Epilepsy. It offers a lot of appealing and stimulating work to offer food of thought to the readers from different disciplines. Around 5% of the total world population have seizures but only 0.9% is diagnosed with epilepsy, so it is very important to understand the differences between seizures and epilepsy, and also to identify the factors responsible for its etiology so as to have more effective therapeutic regime. In this book we have twenty chapters ranging from causes and underlying mechanisms to the treatment and side effects of epilepsy. This book contains a variety of chapters which will stimulate the readers to think about the complex interplay of epigenetics and epilepsy.

How to reference

In order to correctly reference this scholarly work, feel free to copy and paste the following:

Sofia Douzgou and Bruno Dallapiccola (2011). The Gingival Fibromatoses, Underlying Mechanisms of Epilepsy, Prof. Fatima Shad Kaneez (Ed.), ISBN: 978-953-307-765-9, InTech, Available from: <http://www.intechopen.com/books/underlying-mechanisms-of-epilepsy/the-gingival-fibromatoses>

INTECH

open science | open minds

InTech Europe

University Campus STeP Ri
Slavka Krautzeka 83/A
51000 Rijeka, Croatia
Phone: +385 (51) 770 447
Fax: +385 (51) 686 166
www.intechopen.com

InTech China

Unit 405, Office Block, Hotel Equatorial Shanghai
No.65, Yan An Road (West), Shanghai, 200040, China
中国上海市延安西路65号上海国际贵都大饭店办公楼405单元
Phone: +86-21-62489820
Fax: +86-21-62489821

© 2011 The Author(s). Licensee IntechOpen. This chapter is distributed under the terms of the [Creative Commons Attribution-NonCommercial-ShareAlike-3.0 License](#), which permits use, distribution and reproduction for non-commercial purposes, provided the original is properly cited and derivative works building on this content are distributed under the same license.