

## Post-Inflammatory Nephropathy

Beata Bieniaś, Małgorzata Zajączkowska, Halina Borzęcka,  
Przemysław Sikora, Marek Majewski,  
Ewelina Książek and Andrzej Borzęcki  
*Medical University of Lublin  
Poland*

### 1. Introduction

Post-inflammatory nephropathy is a progressive renal scarring which may be a consequence of one or more episodes of acute pyelonephritis.

Macroscopically, post-inflammatory nephropathy leads to gradual decrease in kidney size and deformity and dilation of pelvicalyceal system. These alternations are due to tubulointerstitial fibrosis and glomerular sclerosis followed by renal parenchymal atrophy and kidney cirrhosis development (Bernstein, 1994). It was demonstrated that there was positive correlation between severity of renal scarring and loss of renal function (Eddy et al., 2000; Eddy, 2000).

Post-inflammatory nephropathy is the leading cause of end-stage renal failure. In Europe, children with end-stage renal failure due to post-inflammatory nephropathy constitutes 10-24% of those on renal replacement therapy (Broyer et al., 1993).

The development of post-inflammatory nephropathy is influenced by age and gender of patient, the number of acute pyelonephritis episodes, the presence of anatomical and/or functional urinary system abnormalities, the virulence of invading pathogen, the time of appropriate treatment initiation and genetic predisposition.

The majority of studies demonstrated that the risk of renal scarring decreases with age and is highest in children in the first year of life (Hansson et al., 1999; Vernon et al., 1997; Arant, 1991; Benador et al., 1997; Smellie et al., 1998; Sheu et al., 2009). This may be related to the correction of anatomical and/or functional urinary system abnormalities and the decrease in susceptibility of renal parenchyma to infection due to defense mechanisms maturation (Benador et al., 1997; Rushton et al., 1992). Dissimilar results were obtained by Pecile et al. (2009). The authors showed that the lowest risk of renal scarring after first episode of febrile urinary tract infection was in children in the first year of life and the highest one - in children aged 5-14 years.

It was also demonstrated that the male gender is an independent risk factor for renal scarring (Silva et al., 2009; Mohanan et al., 2008).

The risk of post-inflammatory nephropathy development increases with the number of acute pyelonephritis episodes. Renal scarring develops in 15% of children after the first episode of acute pyelonephritis. After two episodes of acute pyelonephritis renal scarring occurs in 35% of children and after three or more episodes - in 60% of children. The study by Orellana et al. (2004) showed that one episode of pyelonephritis caused permanent renal parenchymal injury in 55.9% of children whereas recurrent urinary tract infection - in 72.6% of children.

Anatomical and functional abnormalities of urinary system particularly predispose to post-inflammatory nephropathy development, although renal scarring may occur after acute pyelonephritis in children without these abnormalities (Gordon et al., 1987; Vanderfaeillie et al., 1998).

Numerous studies emphasized the significance of invading pathogen virulence for post-inflammatory nephropathy development. P, I and F1C fimbriae of *Escherichia coli* give rise to secretion of interleukins 6 and 8 by uroepithelial cells (Backhed et al., 2001; Hedlund et al., 1996, 2001). In addition, lipopolysaccharides of Gram-negative bacteria stimulate the release of cytotoxic nitric oxide and proinflammatory cytokines (Backhed et al., 2001; De Man et al., 1989; Traylor & Mayeux, 1997) whereas lipid A stimulates synthesis of nitric oxide (Traylor & Mayeux, 1997). Alfa-hemolysins of *Escherichia coli* give rise to cytolysis (Uhlen et al., 2000) and induce apoptosis of tubular cells (Chen et al., 2003, 2004).

Immediate initiation of appropriate therapy is of utmost importance in prevention of renal scarring development. Antibacterial treatment initiated within 24 hours prevents migration of neutrophils to inflammatory foci (Ransley & Risdon, 1981). A delay in initiation of therapy increases the risk of renal scarring from 5% to over 15%.

In numerous studies, the importance of genetic predisposition to renal scarring was emphasized. An association between polymorphism of angiotensin-converting enzyme gene and renal scarring was demonstrated (Haszon et al., 2002; Hohenfellner et al., 1999; Ohtomo et al., 2001; Ozen et al., 1999; Pardo et al., 2003). Similarly, polymorphism of transforming growth factor  $\beta$  gene (Kowalewska-Pietrzak et al., 2008; Hussein et al., 2010) and polymorphism of vascular endothelium growth factor gene (Hussein et al., 2010) had impact on severity of renal scarring.

Post-inflammatory nephropathy may be classified into reflux nephropathy due to vesico-ureteral reflux and obstructive nephropathy due to urinary tract obstruction (Marra et al., 2004; Orikasa et al., 1995; Smellie et al., 1981).

## 2. Pathogenesis of post-inflammatory nephropathy

Pathogenesis of post-inflammatory nephropathy is complex and not fully understood (Fig.1). In the last years, the investigators paid particular attention to the role of molecular factors in initiation and progression of post-inflammatory nephropathy. Numerous studies concerning molecular mechanisms leading to renal scarring were published (Eddy, 2000; Eddy et al., 2000; Guroze et al., 2005; Jahnukainen et al., 2005; Lane et al., 2002, Nath, 1998; Solari et al., 2004; Strutz et al., 1995,1996,1999, 2003; Weiss et al., 1994). The process of renal scarring may be divided into four phases: induction, fibrogenic signaling, fibrogenic, and destructive phases (Eddy, 2000). Induction phase is also known as cellular activation and injury phase. The interstitial space is infiltrated by both neutrophils and monocytes. In acute inflammation, the migration of neutrophils is primarily observed whereas in chronic inflammation monocytes predominate.

Neutrophils release numerous cytokines, lysosomal enzymes and free oxygen radicals. In addition, neutrophils may activate fibroblasts directly or indirectly via release of elastase and thus they participate in fibrogenic process (Bailey, 1973; Kishimoto & Harano, 1988).

Monocytes transform into macrophages which also participate in fibrogenic process (Lane et al., 2002; Nath, 1998). Solari et al. (2004) demonstrated that in reflux nephropathy, an increase in number of mastocytes was observed. Mastocytes produce numerous cytokines among others profibrogenic transforming growth factor  $\beta$  (TGF- $\beta$ ) and basic fibroblast

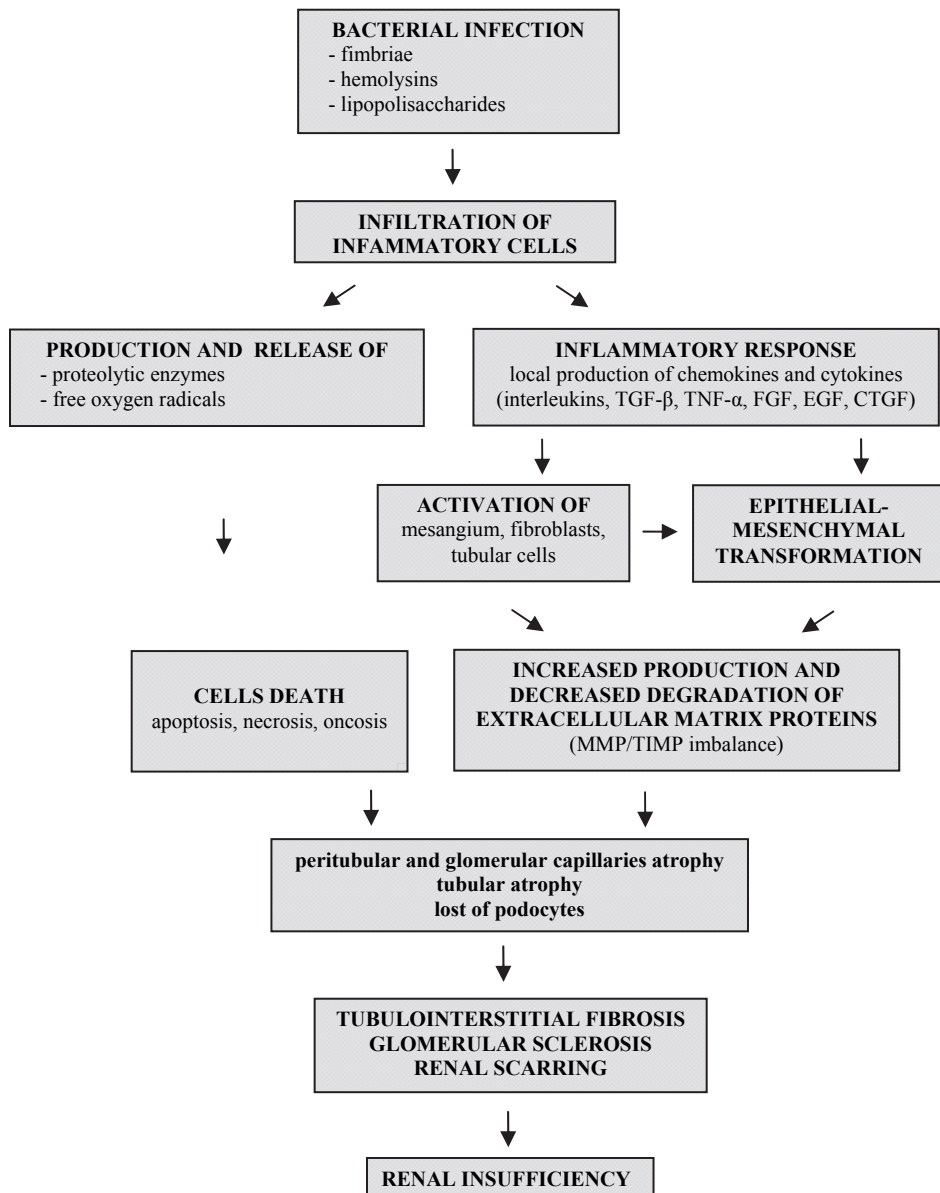


Fig. 1. Pathogenesis of post-inflammatory nephropathy.

growth factor (bFGF). In addition, mastocytes produce enzymes – tryptase and chymase. Tryptase stimulates type I collagen production by fibroblasts whereas chymase releases TGF- $\beta$  from inactive complexes and converts angiotensin I to angiotensin II. This suggests participation of mastocytes in fibrogenic process.

Inflammatory infiltration cells produce other cytokines such as interleukins 1, 6, 8 (IL-1, IL-6, IL-8) and tumor necrosis factor  $\alpha$  (TNF- $\alpha$ ).

The study by Wolfs et al. (2002) demonstrated that Toll-like receptors-2,-4 (TLR-2, TLR-4) were responsible for defense response during acute pyelonephritis. Activated by endogenous danger signals TLR-2 expression is also of significance in induction of inflammation during progressive renal injury (Leemans et al., 2009).

During acute interstitial inflammation activated tubular cells directly participate in activation of myofibroblasts and fibroblasts (Abbate et al., 2002; Alpers et al., 1994; Roberts et al., 1997) and produce monocyte chemoattractant protein-1 (MCP-1) (Okada et al., 2000), endothelin-1 (ET-1) (Bruzzi et al., 1997), angiotensin II causing vasoconstriction, and transferrin (Chen et al., 1998) activating free oxygen radicals (Chertin et al., 2002).

As a result of acute interstitial inflammation expression of novel antigens on tubular cells occurs and these new antigens stimulate an immune response of lymphocyte T which enhances inflammation and progression of nephropathy (Szeto et al., 2005).

In addition, tubular cells and fibroblasts transform into myofibroblasts. This process is called epithelial-mesenchymal transformation or transition (EMT). Numerous authors confirmed the possibility of EMT (Oldfield et al., 2001; Rastaldi et al., 2002; Strutz et al., 1995; Zeisberg et al., 2001). Myofibroblast, unlike typical interstitial fibroblasts, are characterized by their expression of the myocyte protein  $\alpha$ -smooth muscle actin. These cells are considerably more profibrotic than interstitial fibroblasts.

During acute interstitial inflammation activation of complement system via classic and alternative pathway is also observed. C3a and C5a component are known to be chemotactic for monocytes. There is evidence for participation of complement system in inflammatory infiltration formation, tubular atrophy and tubulointerstitial fibrosis (Nangaku et al., 1999).

In pathogenesis of chronic interstitial inflammation leukocyte adhesion molecules such as integrins, selectins and members of the immunoglobulin superfamily (intercellular adhesion molecules - ICAMs and vascular cell adhesion molecules - VCAMs) seem to play a crucial role but details remain unclear. ICAMs, VCAMs and osteopontin are chemoattractant for monocytes (Okada et al., 2000; Ricardo et al., 1996).

An early phase of acute interstitial inflammation is reversible provided that nociceptive factor is eliminated (Eddy, 2000; Eddy et al., 2000).

In fibrogenic signaling phase, numerous fibrogenic factors are released, including TGF- $\beta$ 1, tissue growth factor (TGF), angiotensin II, ET-1, platelet growth factor (PDGF-BB), bFGF, TNF- $\alpha$ , and IL-1. Fibrogenic factors activate their cognate receptors expressed by tubulointerstitial cells and subsequent extracellular matrix accumulation along tubular basement membranes and within the interstitial space occurs.

In fibrogenic phase, fibrogenic factors activate a new group of genes that lead to excessive accumulation of extracellular matrix proteins and polysaccharides within the interstitial space (Beck-Schimmer et al., 1998; Pichler et al., 1996). In this phase, disequilibrium between extracellular matrix production and its degradation is observed.

A main cause of impairment of extracellular matrix remodeling and degradation is a decrease in activity of metalloproteinases (MMP) due to induction of tissue inhibitors of metalloproteinases (TIMP). Four major TIMP have been identified (TIMP-1, TIMP-2, TIMP-3, and TIMP-4). In the majority of progressive renal diseases, marked induction of TIMP-1 is observed (Chromek et al., 2003,2004; Eddy et al., 2000; Kim et al., 2001). Within kidney, TIMP-1 is produced by tubular cells, fibroblasts and macrophages. Production of TIMP-1 is stimulated by growth factors (TGF- $\beta$ 1, TGF- $\alpha$ , epithelial growth factor (EGF), PDGF, TNF-

$\alpha$ ), interleukins (IL-1, IL-6, IL-10), oncostatin M, endotoxin and thrombin. Recently, the induction of plasminogen activator inhibitor-1 (PAI-1) in progressive renal diseases was documented. This may suggest its participation in tubulointerstitial fibrosis. PAI-1 is produced by tubular cells, fibroblasts and myofibroblasts. Its expression is induced by TGF- $\beta$ , EGF, PDGF, TNF- $\alpha$  and bFGF (as cited in Eddy, 2000).

In destructive phase, a gradual loss of functioning nephrons occurs as a result of excessive accumulation of extracellular matrix. Glomerular sclerosis, peritubular capillaries and tubular atrophy lead to progressive renal failure (Orphanides et al., 1997; Seron et al., 1990). TGF- $\beta$ , TNF- $\alpha$ , IL-1 $\beta$ , IL-6 and IL-8 seem to play a major role in renal scarring.

Transforming growth factor  $\beta$  (TGF- $\beta$ )

TGF- $\beta$  is released primarily by macrophages, neutrophils, lymphocytes and platelets. TGF- $\beta$  is produced as an inactive complex with LAP (*latent associated protein*) and LTBP (*latent TGF- $\beta$  binding protein*) which are components of extracellular matrix. These proteins have potential to store and release of TGF- $\beta$ . Five isoforms of TGF- $\beta$  (TGF- $\beta$  1-5) have been identified. In mammals, only TGF- $\beta$  1-3 are found. Active TGF- $\beta$  is a homodimeric 25kD protein. Within kidneys numerous factors increase TGF- $\beta$  expression, including angiotensin II, endothelin I, interleukin 1 $\beta$ , platelet activating factor (PAF), thromboxane, thrombospondin, glucose, insulin, atrial natriuretic peptide (ANP), secreted protein acidic and rich in cysteine (SPARC), and hypoxia (Pichler et al., 1996). Increased TGF- $\beta$  expression in kidneys is also caused by TNF- $\alpha$  and connective tissue growth factor (CTGF) (Zhang et al., 2004). In addition, proteoglycans accumulated within the interstitial space may be a reservoir of TGF- $\beta$ .

TGF- $\beta$  stimulates production of proinflammatory cytokines (IL-1, IL-6, IL-8 and TNF- $\alpha$ ). It is known to be chemotactic for monocytes, neutrophils, and fibroblasts. TGF- $\beta$  stimulates production of extracellular matrix proteins such as fibronectin, collagen and proteoglycans. In addition, it increases expression of TIMPs. This contributes to depressed activity of MMP and stabilization of extracellular matrix (Boettinger & Bitzer, 2002; Boettinger et al., 1997; Broder et al., 1994; Cotton et al., 2002; Deng et al., 2006; Fan et al., 1999; Goumneos et al., 2002; Guo et al., 1997; Jahnukainen et al., 2005; Korzon et al., 2004; Lane et al., 2002; Liapis, 2003). Poncelet & Schnaper (1998) documented that TGF- $\beta$  stimulates production of collagen I, III and IV by mesangial cells. Experimental studies on transgenic mice showed that overexpression of TGF- $\beta$  resulted in glomerular and interstitial fibrosis (Kelly et al., 1999). In experimental model of ureteral obstruction (Shinozaki et al., 1998) and in proteinuric state (Jernigan et al., 1996), overexpression of the type II receptor for TGF- $\beta$  gave rise to increased accumulation of collagen within the interstitial space.

TGF- $\beta$  induces EMT (Fan et al., 1999; Ng et al., 1998) and inhibits apoptosis of myofibroblasts (Zhang & Phan, 1999; Fan et al., 1999; Frazier et al., 2000). In addition, TGF- $\beta$  induces apoptosis of endothelial cells. This results in peritubular and glomerular capillaries atrophy followed by fibrosis (Choi & Ballermann, 1995; Kang et al., 2002; Ohashi et al., 2000). TGF- $\beta$  is also known to induce apoptosis of tubular cells leading to tubular atrophy with subsequent fibrosis (Dai et al., 2003; Gobe & Axelsen, 1987; Kopp et al., 1996; Lane et al., 2002; Ortiz et al., 1997; Sanderson et al., 1995).

Experimental studies demonstrated increased TGF- $\beta$  mRNA expression during infection with *Escherichia coli* (Khalil et al., 2000). Increased urinary TGF- $\beta$  excretion was showed in children with urinary tract infection (Farmaki et al., 2005).

An association between TGF- $\beta$  gene polymorphism and susceptibility to renal scarring was observed. Solari et al. (2005) documented that the risk of reflux nephropathy was higher in

patients with -509CT and Leu10Pro genotypes. Khalil et al. (2005) showed that homozygosity for -509T and Arg25 resulted in more rapid progression of renal failure whereas patients with -800GA genotype were less susceptible to renal scarring (Cotton et al., 2002).

Numerous studies confirmed a significant participation of TGF- $\beta$  in pathogenesis of obstructive nephropathy (Blom et al., 2001; Chevalier, 2004; Duncan et al., 1999; Kaneto et al., 1999; Klahr & Morrissey, 1998, 2002, 2003; Sato et al., 2003; Schnaper et al., 2003). In this type of nephropathy, increased angiotensin II production is observed and angiotensin II enhances TGF- $\beta$  expression. Thus angiotensin II plays a key role in initiating of tubulointerstitial fibrosis in obstructive nephropathy. Recently, in patients with ureteropelvic junction obstruction, increased urinary TGF- $\beta$  excretion was observed (Almodhen et al., 2009, Sager et al., 2009).

#### Tumor necrosis factor $\alpha$ (TNF- $\alpha$ )

TNF- $\alpha$  also known as cachectin is produced by several cells within kidneys, including proximal tubular cells, mesangial cells, interstitial fibroblasts and macrophages. The most potent stimulus for TNF- $\alpha$  production is lipopolysaccharides of Gram-negative bacteria. TNF- $\alpha$  stimulates production of proinflammatory cytokines (IL-1 and IL-6) by macrophages and increases macrophages cytotoxicity. In addition, it is known to be chemotactic for fibroblasts and stimulates their proliferation. TNF- $\alpha$  has also antifibrotic effects because it enhances collagenase activity and inhibits collagen gene expression. In addition, TNF- $\alpha$  diminishes activity of TIMP and increases production of latent MMP-9 (Nee et al., 2004).

Profibrogenic effects of TNF- $\alpha$  was confirmed in study by Guo et al. (1999). The authors demonstrated less severe renal scarring in mice genetically deficient of receptors specific for TNF- $\alpha$ . In addition, TNF- $\alpha$  contributes to renal scarring by releasing IL-1 $\beta$  and TGF- $\beta$  from inflammatory infiltration cells (Jahnukainen et al., 2005). Recently, experimental study demonstrated less severe renal scarring in rats with nephritis when monoclonal antibodies against TNF- $\alpha$  were administered (Khan et al., 2005). Wolfs et al. (2002) showed that TNF- $\alpha$  induced overexpression of TLR-2 and -4. TNF- $\alpha$  contributes to the development of obstructive nephropathy. Overexpression of TNF- $\alpha$  is due to increased angiotensin II secretion observed in upper urinary tract obstruction.

#### Interleukin 1 (IL-1)

IL-1 is one of the major regulator inflammatory and immune reactions. It may be produced by several cells within the kidney, including macrophages, mesangial cells, endothelial cells and macrophages. It is also known to be chemotactic for neutrophils and monocytes. Other activities of IL-1 include: - stimulation of production of IL-1, IL-6, IL-8 and TNF- $\alpha$  by macrophages, - stimulation of production of IL-6 and collagenase by fibroblasts, - stimulation of fibroblast proliferation and possibly of extracellular matrix production, - activation of endothelial cells, - induction of smooth muscle cells lysis. Fibrosis-promoting effects of IL-1 were also demonstrated (Ichino et al., 2008, Mittal et al., 2009). It also inhibits MMP-9 activity which degrades type IV collagen of extracellular matrix and diminishes activity of IL-1 receptor antagonist (IL-1Ra).

Vesey et al. (2002, 2002) demonstrated that IL-1 $\beta$  stimulated proliferation of interstitial fibroblast and enhanced production of type I collagen, fibronectin, TGF- $\beta$  and nitric oxide.

Study by Zang et al. (2005) showed that IL-1 $\beta$  induced transformation of tubular cells into myofibroblasts. In addition, IL-1 $\beta$  stimulates production of IL-6 and IL-8. This intensifies inflammation and promotes interstitial fibrosis (Lonnemann et al., 1995).

Kassem et al. (2005) demonstrated increased urinary IL-1 $\beta$  excretion in children with acute pyelonephritis. The authors also revealed positive correlation between urinary IL-1 $\beta$  and IL-8 excretion. The survey by Wetmore et al. (2005) showed an association between IL-1 gene polymorphism and occurrence of chronic renal diseases which resulted in impairment of renal function. Elevated urinary IL-1 $\beta$  excretion was demonstrated in patients with chronic renal failure. The highest urinary IL-1 $\beta$  excretion was observed in pre-dialysis patients. In those patients, considerably higher plasma IL-1Ra level as compared to controls was disclosed (Pereira et al., 1994).

#### Interleukin 6 (IL-6)

IL-6 is produced by several cells within kidney, including macrophages, interstitial fibroblasts and endothelial cells. The study by Patel et al. (2005) demonstrated that IL-6 intensified inflammation and impaired renal function. Increased urinary IL-6 excretion in children with urinary tract infection and positive correlation between urinary IL-6 excretion and severity of proteinuria, hematuria and pyuria were also observed (Benson et al., 1996; Gendrel et al., 1998; Jantusch et al., 2000; Nicolle et al., 1993; Otto et al., 1999; Mizuano et al., 2001). Experimental studies revealed increased expression of renal IL-6 in mice with acute pyelonephritis due to ureteral obstruction (Kabore et al., 1999; Rugo et al., 1992) and increased serum IL-6 level in the majority of mice with acute pyelonephritis (Rugo et al., 1992). Khalil et al. (2000) demonstrated increased mortality in mice with acute pyelonephritis and IL-6 deficiency. The authors also disclosed more severe histopathological changes in kidneys of IL-6 deficient mice. Numerous studies demonstrated that urinary IL-6 excretion was higher in patients with acute pyelonephritis than in those with asymptomatic bacteriuria (Benson et al., 1994; Hedges et al., 1992; Kassem et al., 2005; Ko et al., 1993; Ohta et al., 1992; Otto et al., 1999; Roilides et al., 1999). Positive correlation between urinary IL-6 excretion and the risk of renal scarring was also disclosed (Benson et al., 1996; Jacobson et al., 1998; ; Roilides et al., 1999; Tullus et al., 1994). Wang et al. (2001) observed significant correlation between urinary IL-6 excretion and renal scars diagnosed by static renoscintigraphy in children with vesicoureteral reflux. In those children, there were positive correlations between urinary IL-6 excretion and serum  $\alpha$ 1- microglobulin,  $\beta$ 2- microglobulin, creatinine levels and urinary albumin excretion. These authors (Wang et al., 2001) also performed immunohistochemical evaluation of specimens obtained from removed scarred kidneys. Overexpression of IL-6 in renal tubules and scars was observed. Data on serum IL-6 level in patients with urinary tract infection and post-inflammatory nephropathy are scarce and conflicting. Smólko et al. (2004) revealed higher serum IL-6 level in children with vesicoureteral reflux of high grade as compared to controls. The study by Gokce et al. (2010) showed the similar results. Increased serum IL-6 level was observed primarily in patients with febrile urinary tract infection (Benson et al., 1994; Hedges et al., 1991,1992; Jacobson et al., 1994, 1998).

IL-6 gene polymorphism influenced susceptibility to urinary tract infections but had no effect on renal parenchymal scarring (Cotton et al., 2000).

#### Interleukin 8 (IL-8)

Within kidney IL-8 is produced primarily by macrophages, interstitial fibroblasts, tubular and endothelial cells. It has bactericidal and pro-inflammatory activity because it causes chemotaxis and degranulation of neutrophils. In patients with acute urinary tract infection and post-inflammatory nephropathy, increased serum IL-8 level and increased urinary IL-8

excretion were observed (Kassem et al., 2005; Tikhonov et al., 1997; Haraoka et al., 1996). Increased urinary IL-8 excretion is thought to be a marker of vesicoureteral reflux and post-inflammatory nephropathy (Galanakis et al., 2006; Gokce et al., 2010; Haraoka et al., 1996; Smółko et al., 2004). Taha et al. (2003) demonstrated increased urinary IL-8 excretion in patients with acute and chronic urinary tract infections. The authors also disclosed higher urinary IL-8 excretion in females as compared to males and positive correlation between urinary IL-8 excretion and markers of inflammation, including leukocytosis and serum C-reactive protein level.

In patients with urinary tract infection, increased urinary IL-8 excretion was observed in numerous studies (Jacobson et al., 1994; Kassem et al., 2005; Nicolle et al., 1993; Olszyna et al., 2000; Otto et al., 1999; Rao et al., 2001; Sheu et al., 2009; Tullus et al., 1994). Roilides et al. (1999) and Ko et al. (1993) revealed increased urinary IL-8 excretion in newborns with abnormal static renoscintigraphy result. Increased urinary IL-8 excretion was also revealed in patients with chronic pyelonephritis (Rebenok et al., 1999; Tikhonov et al., 1997). Experimental studies in mice and rabbits with urinary tract infection and without or mutated IL-8 receptor disclosed more severe course of infection, massive renal scarring and considerable impairment of renal function (Freundeus et al., 2001; Hang et al., 2000). The authors suggested that overproduction of IL-8 promoted clearance of bacteria from kidneys and thus diminished the risk of renal scarring. There is an opinion that overproduction of IL-8 in response to urinary tract infection results in univocal and distinct symptoms leading to prompt diagnosis and early initiation of appropriate treatment and thus diminishes the risk of renal scarring (Jahnukainen et al., 2005).

## 2.1 Reflux nephropathy

Reflux nephropathy (RN) refers to renal scarring due to vesicoureteral reflux. Chronic renal failure as a result of RN is observed in 5%-40% of children aged below 16 years and in 5%-20% of adults (Kenda et al., 1997; Noe, 1992; Wan & Greenfield, 1996). RN is also a frequent cause of end-stage renal failure.

Vesicoureteral reflux is a back-flow of urine from the bladder into the ureter and pelvicalyceal system. The back-flow of urine from pelvicalyceal system into collecting ducts is called intrarenal reflux. When urine is infected, intrarenal reflux results in renal infection. The prevalence of intrarenal reflux is particularly high in children aged below 5 years. In 1960, Hodson and Edwards (as cited in Sieniawska & Wszyńska, 2003) first demonstrated that there was association between vesicoureteral reflux and chronic pyelonephritis. Antenatal renal damage due to vesicoureteral reflux may also develop (Arant, 1991; Bailey, 1973; Lerner, 1994; Smellie, 1975; Peters & Rushton, 2010).

Classification of grades of vesicoureteral reflux according to International Reflux study Committee, (1981) is showed on Fig. 2.

Vesicoureteral reflux may be primary or secondary. Primary vesicoureteral reflux is due to congenital abnormal lateralization of ureteral orifice. Secondary vesicoureteral reflux is a result of anatomical and/or functional abnormalities of lower urinary tract.

Primary vesicoureteral reflux is the most common congenital abnormality of urinary system and is diagnosed in 20% - 60% of children with urinary tract infection (Ataei et al., 2004; Zajackowska et al., 2001; Alvarez et al., 2009). In the noninfected general population, the prevalence of vesicoureteral reflux is 1% -2% and in siblings of children with vesicoureteral reflux and urinary tract infection - 5% -50% (Noe, 1992).



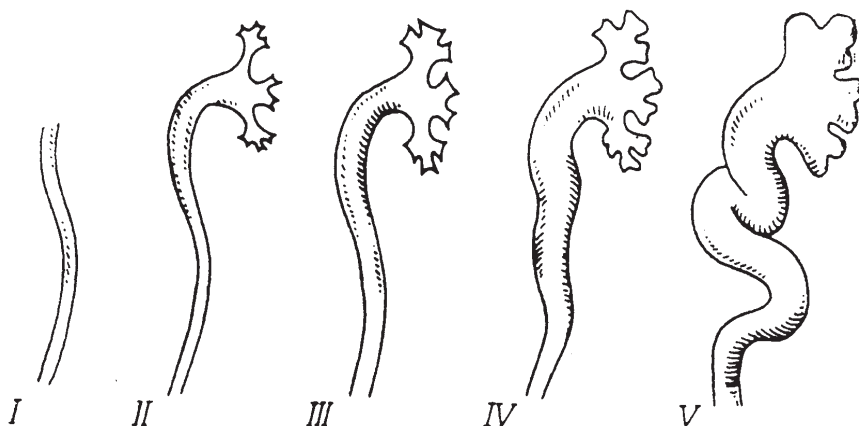


Fig. 2. The International Reflux Study classifies reflux grades as follows: I) reflux into ureter only; II) reflux into ureter, pelvis, and calyces, no dilation, normal calyceal fornices; III) mild or moderate dilation and/or tortuosity of the ureter and mild or moderate dilation of renal pelvis but no or little blunting of the fornices; IV) moderate dilation and/or tortuosity of the ureter and moderate dilation of the renal pelvis and calyces V) gross dilation and tortuosity of the ureter and gross dilation of the renal pelvis and calyces. Papillary impressions are no longer visible in the majority of calyces. There is complete obliteration of the sharp angle of the fornices, but maintenance of papillary impressions in major calyces.

Relation between urinary tract infection, vesicoureteral reflux and renal scarring has been known since a long time (Bailey, 1973; Kincaid-Smith, 1975; Smellie et al., 1975; Van den Abbeele et al., 1987). In the early 1970s, Bailey (1973) coined the term "reflux nephropathy" to describe renal scarring in patients with vesicoureteral reflux. The study by Sheikh et al. (2010) confirmed higher risk of renal scarring in patients with vesicoureteral reflux. Orellana et al. (2004) demonstrated that prevalence of renal scarring is higher in children with vesicoureteral reflux than in those without that anomaly (72% versus 52%). In addition, it was revealed significant association between vesicoureteral reflux diagnosed after first episode of urinary tract infection and chronic renal failure (Marra et al., 2004).

Previously, vesicoureteral reflux was thought to be an independent risk factor for renal scarring. Nowadays, this hypothesis is questioned. However, an association between urinary tract infection in children with vesicoureteral reflux and renal scarring remains unquestionable (Faust et al., 2009; Jahnukainen et al., 2005; Muinuddin et al., 2008). This was confirmed by recent studies that demonstrated an increase in the risk of renal scarring after acute pyelonephritis in patients with vesicoureteral reflux (Kanellopoulos et al., 2006; Lee et al., 2006; Polito et al., 2006; Oh et al., 2008). Studies by Svensson et al. (2005) and Mohanan et al. (2008) disclosed that renal scarring was detected less frequently in infants with vesicoureteral reflux and without urinary tract infection than in those with vesicoureteral reflux and urinary tract infection. In study by Ylinen et al. (2003) renal scarring was found more frequently in infants in whom vesicoureteral reflux was diagnosed after the first episode of urinary tract infection than in those in whom vesicoureteral reflux was detected antenatally. The risk of acute pyelonephritis and thus renal scarring increases along with grade of vesicoureteral reflux (Arant, 1991; Oh et al., 2008; Shaikh et al., 2010; Silva et al.,

2010) because vesicoureteral reflux of high grade occurs throughout micturition in contrast to vesicoureteral reflux of low grade which occurs only at the peak of micturition (Jacobsson et al., 1992).

In the last years, an association between ACE gene polymorphism and development/progression of RN was demonstrated. The D allele of ACE gene polymorphism was associated with higher converting enzyme activity and thus higher concentration of angiotensin II in plasma and tissues. This resulted in more rapid development and progression of RN (Haszon et al., 2002; Hohenfellner et al., 1999; Ohtomo et al., 2001; Ozen et al., 1999). Some studies questioned the significance of ACE gene polymorphism as an independent risk factor for the development and progression of RN (Dudley et al., 2002; Pardo et al., 2003). An association between TGF- $\beta$ 1 gene polymorphism and the risk of renal scarring in patients with vesicoureteral reflux was also disclosed Kowalewska-Pietrzak et al. (2008), whereas Hussein et al. (2010) demonstrated an association between vascular endothelium growth factor (VEGF) gene polymorphism and the risk of the development of RN.

## 2.2 Obstructive nephropathy

Obstructive nephropathy (ON) refers to renal scarring due to mechanical obstruction to urine flow (Liapis, 2002).

Obstruction to urine flow may be congenital or acquired. It can occur at any level of urinary tract, including renal tubules, renal pelvis, ureters, bladder and urethra. Obstruction to urine flow most commonly occurs at ureteropelvic junction (Koff, 1990; Norbeck et al., 1993). The severity of obstructive nephropathy depends on severity of obstruction, its location and duration, age of occurrence and concomitant infection.

Complete or severe obstruction to urine flow leads to obstructive nephropathy more rapidly than incomplete one. In addition, the higher the obstruction is located the more severe obstructive nephropathy develops. Age of patient is of great significance. Fetal and neonatal kidneys are at greatest risk for damage. Antenatal urinary tract obstruction disturbs kidney development and results in polycystic dysplasia or hypodysplasia (Chevalier, 2004).

Re-expression of Pax-2 (Li et al., 2010) gene and decreased expression of Bcl-1 gene (Zhang et al. 2001) enhance susceptibility to the development of obstructive nephropathy.

In the development and progression of obstructive nephropathy, primarily cytokines and vasoactive substances are implicated (Chevalier, 2004; Chevalier et al., 2009; Chiou et al., 2004; Grande et al., 2010; Klahr, 2001; Klahr & Marrissey, 1998, 2002, 2003; Rice et al., 2004). Nowadays, TGF- $\beta$ 1 and TNF- $\alpha$  are thought to play a crucial role in renal damage. Obstruction to urine flow and alternations in intra-renal hemodynamics result in increased secretion of angiotensin II which in turn enhances TGF- $\beta$ 1 and TNF- $\alpha$  expression (Grande et al., 2010; Leonova et al., 2007; Manucha, 2007; Padillo et al., 2007; Pimentel et al., 1995; Sager et al., 2009; Wang et al., 2010). Due to urine stasis urinary tract infection may develop. Infection is an additional factor which causes renal damage.

Bilateral complete or severe urinary tract obstruction are the most dangerous anomalies. In this clinical settings, even early surgery does not always protect kidneys from permanent damage leading to end stage renal failure during childhood (Chevalier et al., 2000). Patients after surgical correction of urinary tract obstructions requires careful monitoring in order to early detect of obstructive nephropathy symptoms and initiation of nephroprotective therapy.

### 3. History and clinical manifestations of post-inflammatory nephropathy

The clinician needs to obtain a detailed history about the type and duration of symptoms. Most often there is a history of recurrent urinary tract infections which cease or occur less frequently after surgical correction of anatomical anomaly, appropriate therapy of functional disturbances of lower urinary tract and/or antibacterial prophylaxis. Severe and developed early in life post-inflammatory nephropathy leads to dwarfism and body weight deficit (Polito et al., 1999; Seidel et al., 1993). The patient may complain of loin or abdominal pain which may be a result of urinary tract infection, dilation of urinary tract due to obstruction or urolithiasis secondary to urine stasis. The patient should be asked questions about difficulty initiating urination, decreases in the force of urine stream, posturination dribbling, and incomplete emptying. In addition, the patient should be questioned about nocturia as chronic renal failure is characterized by the lack of ability to concentrate urine during the night. Post-inflammatory nephropathy may also be asymptomatic.

20% of children with post-inflammatory nephropathy develop end-stage renal failure before 18<sup>th</sup> year of age and approximately 50% of them - in the fourth decade of life .

Post-inflammatory nephropathy may lead to arterial hypertension due to ischemia of renal scars and resultant increase in renin production (Wyszynska & Litwin, 2000). Arterial hypertension develops most commonly in patients with diffuse bilateral renal scarring (Hamed et al., 1992; Kohler et al., 1997, 2003). According to Rushton (1997) it may occur at any age but its beginning is most commonly observed in the third decade of life. Arant (1991) diagnosed arterial hypertension in 20% of children with post-inflammatory nephropathy and the majority of them was over 5 years of age. In Polish children aged 7 -10 years with post-inflammatory nephropathy, the prevalence of arterial hypertension was approximately 50% (Wyszynska & Litwin, 2000). In children with obstructive nephropathy, arterial hypertension seems to be sodium-dependent and occurs more commonly when urinary tract obstruction is bilateral.

A late consequence of post-inflammatory nephropathy may be urolithiasis which was observed in 18% patients with renal scarring (Kohler et al., 2003; Vachvanichsanong, 2007).

In pregnant with reflux nephropathy, recurrent urinary tract infections, arterial hypertension, gestosis and/or renal failure may occur (Vachvanichsanong, 2007) therefore they are at risk for spontaneous abortion and premature delivery. Increased mortality of newborns from these mothers was observed.

### 4. Diagnosis of post-inflammatory nephropathy

Diagnostics of post-inflammatory nephropathy include laboratory and imaging studies. Initially, urinalysis may be normal or may show sparse proteinuria and/or microhematuria. Proteinuria may gradually increase with time. Slightly decreased ability to concentrate and acidify urine may also be observed (Polito et al., 1999; Seidel et al., 1993).

An acetyl-beta-D-glucose aminidase and  $\beta$ 2-microglobulin are a widely used markers of tubulointerstitial fibrosis. Recently, early and more specific markers of tubulointerstitial fibrosis have been introduced such as neutrophil gelatinase-associated lipocalin (NGAL) (Ichnio et al., 2010; Wasilewska et al., 2011), kidney injury molecule-1 (KIM-1) (Wasilewska et al., 2011), type IV collagen and glutathione S-transferases alpha and pi (GST- $\alpha$  and GST- $\pi$ ) (Cawood et al., 2010, Branten et al., 2000). GST- $\alpha$  is a marker of proximal tubular injury

whereas GST- $\pi$  -distal tubular injury. Chromek et al. (2003, 2004) recommended ratios of MMP-1, MMP-2 and MMP-9 to their tissue inhibitors TIMP-1 and TIMP-2 as markers of tubulointerstitial fibrosis.

Valuable diagnostic clues are provided by radiologic evaluation, including ultrasonography, static renoscintigraphy ( $^{99m}\text{Tc}$  DMSA) and dynamic renoscintigraphy ( $^{99m}\text{Tc}$ DTPA,  $^{99m}\text{Tc}$ EC,  $^{99m}\text{Tc}$ MAG-3). Urography and voiding cystourethrography (VCUG) are also helpful.

Kersnik et al. (2002) evaluated ultrasonography efficacy in detection of renal scarring. They demonstrated that sensitivity of ultrasonography in detection of benign, moderate and severe renal scarring was 34.1%, 79.2% and 100%, respectively. The study by Moorthy et al. (2004) revealed that in detection of renal scarring, ultrasonography was characterized by higher specificity (91.8%) and lower sensitivity (47.2%) as compared to static renoscintigraphy. At present, ultrasonography still remains an important tool in evaluation of renal scarring.

The advent of static renoscintigraphy using dimercaptosuccinic acid labeled by  $^{99m}\text{Tc}$  technetium ( $^{99m}\text{Tc}$ DMSA) was a turning-point in diagnostic evaluation of post-inflammatory nephropathy.  $^{99m}\text{Tc}$ DMSA is thought to be the gold standard for detection and monitoring of renal scarring.  $^{99m}\text{Tc}$ DMSA undoubtedly contributes to expansion of our knowledge concerning pathogenesis of post-inflammatory nephropathy (Gordon, 1987; Orleana et al., 2004; Rushton, 1997; Shapiro et al., 1988; Smellie, 1985; Stokland et al., 1996). On the basis of  $^{99m}\text{Tc}$ DMSA, the classification of severity of renal scarring was made (Fig. 3.) (Goldraich et al., 1983).

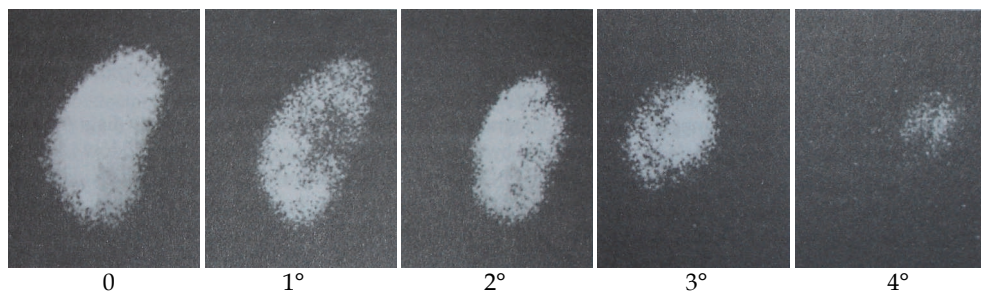


Fig. 3. Classification of renal scarring according to findings at  $^{99m}\text{Tc}$ DMSA renal scan: 0 - normal, 1° - no more than 2 scarred areas, 2° - more than 2 scars with some areas of normal parenchyma, 3° - generalized damage to the whole kidney, 4° - cirrhotic kidney with little or no uptake of DMSA.

Dynamic renoscintigraphy also has potential to detect renal scarring reliably (Gad et al., 2004; Narayana et al., 2004). In addition, it evaluates renal function as well as status of pelvicalyceal systems and ureters. In dynamic renoscintigraphy, diethylene triaminepentaacetic acid (DTPA), ethylenodicycysteine (EC), and mercaptoacetyl triglycerin (MAG-3) labeled by  $^{99m}\text{Tc}$  technetium are used.

Nowadays, urography is performed less commonly because there are more effective methods of urinary system visualization. In addition, urography is viewed as more harmful than beneficial for patients. Urography enables to evaluate renal size and margins. It also visualizes pelvicalyceal systems and ureters and thus has potential to detect anatomical obstruction location.

VCUG is performed in order to detect vesicoureteral reflux and anatomical anomalies of the bladder and urethra. In the presence of vesicoureteral reflux, VCUG may demonstrate dilation and deformity of renal calyces and occasionally intrarenal refluxes. VCUG may give only a suspicion of post-inflammatory nephropathy. VCUG visualizes the bladder and urethra and thus has potential to detect anatomical obstruction to urine flow. Instead of VCUG videocystometry is more and more commonly performed because it is able to detect both vesicoureteral reflux and anatomical/functional abnormalities of lower urinary tract.

## 5. Management of post-inflammatory nephropathy

Management of post-inflammatory nephropathy include therapy and prophylaxis of urinary tract infection, correction of anatomical and functional abnormalities of urinary tract and nephroprotection based primarily on inhibition of production or activity of TGF- $\beta$ . Nowadays, a proven nephroprotective activity is displayed by angiotensin-converting enzyme inhibitors, angiotensin II receptor blockers (Khalil et al., 2000, Wang et al., 2005), aldosterone antagonists (eplerenone), renin inhibitors (aliskiren) and anti-oxidants ( $\alpha$ -tocopherol) (Chan et al., 2001; Cojocel et al., 2005; Saborio et al., 2000).

Novel drugs which inhibit tubulointerstitial fibrosis include low-molecular leucine-rich proteoglycans, decorin, and biglycan. They have potential to permanent bond with TGF- $\beta$  and thus they inhibit its activity (Solari et al., 2005). Inhibition of tubulointerstitial fibrosis was also observed after blockade of type II TGF- $\beta$  receptor (Jernigan et al., 1996; Kasuga et al., 2001; Kushibiki et al., 2005) and as a result of therapy with antibodies against TGF- $\beta$  (Gagliardini & Benigni, 2006). Inhibition of activity of tissue transglutaminases which participate in activation of TGF- $\beta$  may be a therapeutic option in patients with post-inflammatory nephropathy in future (Shweke et al., 2008). Other factors which are likely to inhibit tubulointerstitial fibrosis are hepatocyte growth factor (HGF) (Mizuno et al., 2001) and bone morphogenic protein 7 (BMP-7) (Kopp, 2002). The latest studies demonstrated nephroprotective activity of Lefty-A which inhibits and even reverses transformation of tubular cells into myofibroblasts (Li et al., 2010, Yao et al., 2011).

## 6. Serum concentrations of selected cytokines in children with reflux and obstructive nephropathy – original studies

The purposes of the study were - to assess serum TGF- $\beta_1$ , TNF- $\alpha$ , IL-1  $\beta$ , IL-6 and IL-8 levels in children with post-inflammatory nephropathy (reflux and obstructive nephropathy), - to compare serum TGF- $\beta_1$ , TNF- $\alpha$ , IL-1  $\beta$ , IL-6 and IL-8 levels between children with unilateral and bilateral vesicoureteral reflux, and between those with vesicoureteral reflux of high and low grade, - to compare serum TGF- $\beta_1$ , TNF- $\alpha$ , IL-1  $\beta$ , IL-6 and IL-8 levels between children with and without hypertension, and between those with and without proteinuria.

Patients and methods: The study comprised 70 children (24 boys and 46 girls) aged 1-17 years with renal scarring diagnosed scintigraphically. All children had a history of recurrent urinary tract infections including at least one episode of acute pyelonephritis. Vesicoureteral reflux and unilateral ureteropelvic/vesicoureteric junction obstruction were detected in 85.7% (60/70) and 14.3% (10/70) of children, respectively. Arterial hypertension was diagnosed in 17.2% (12/70) of patients. Proteinuria was observed in 25.7% (18/70) of children. Renal insufficiency developed in 5,7% (4/70) of patients. Serum TGF- $\beta_1$ , TNF- $\alpha$ , IL-1  $\beta$ , IL-6 and IL-8 concentrations were measured by ELISA.

Results: In children with reflux/obstructive nephropathy, the mean serum TGF- $\beta_1$  and IL-1 $\beta$  concentrations were significantly lower than in controls. Similarly, serum IL-8 concentrations were lower in both studied groups than in controls but the differences were not statistically significant. There were no statistically significant differences in the mean serum TNF- $\alpha$  and IL-6 concentrations between children with reflux/obstructive nephropathy and controls.

There were no statistically significant differences in the mean serum TGF- $\beta_1$ , TNF- $\alpha$ , IL-1  $\beta$ , IL-6 and IL-8 levels between children with unilateral vesicoureteral reflux and those with bilateral vesicoureteral reflux. There were also no statistically significant differences in the mean serum TGF- $\beta_1$ , TNF- $\alpha$ , IL-1  $\beta$ , IL-6 and IL-8 levels between children with vesicoureteral reflux of high grade and those with vesicoureteral reflux of low grade.

Statistically significant differences in the mean serum TGF- $\beta_1$ , TNF- $\alpha$ , IL-1  $\beta$ , IL-6 and IL-8 levels between children with arterial hypertension and the remaining patients were not observed.

In children with proteinuria, the mean serum TGF- $\beta_1$  level was significantly lower than in the remaining patients. There were no statistically significant differences in the mean serum TNF- $\alpha$ , IL-1  $\beta$ , IL-6 and IL-8 levels between children with proteinuria and the remaining patients.

## 7. Conclusions

1. The low serum TGF- $\beta_1$  and IL-1 $\beta$  concentrations in patients with reflux and obstructive nephropathy seems to be a result of increased influx of this cytokines into renal parenchyma and/or increased urinary TGF- $\beta_1$  and IL-1 $\beta$  excretion due to tubular damage associated with nephropathy.
2. The lower serum concentration of TGF- $\beta_1$  in patients with proteinuria secondary to post-inflammatory nephropathy may confirm participation of this factor in progression of nephropathy

## 8. References

- Abbate M., Zoja C., Rottoli D., Corna D., Tomasowi S. & Remuzzi G. (2002). Proximal tubular cells promote fibrogenesis by TGF- $\beta_1$ -mediated induction of peritubular myofibroblasts, *Kidney Int* 62:2066-2077.
- Almodhen F, Loutochin O, Capolicchio JP, Jednak R & El-Sherbiny M. (2009). The role of bladder urine transforming growth factor- $\beta_1$  concentrations in diagnosis and management of unilateral prenatal hydronephrosis, *J Urol*. 182(1):292-298.
- Alpers C.E., Hudkins K.L., Floege J. & Johnson R.J. (1994). Human renal cortical interstitial cells with some features of smooth muscle cells participate in tubulointerstitial and crescentic glomerular injury, *J Am Soc Nephrol* 5:201-209.
- Alvarez MD, Batista BA, Córdova RP, Arias MI & Marrero BD. (2009). Prevalence and characteristics of the vesicoureteral reflux in infants who suffered neonatal urinary tract infection, *Arch Argent Pediatr* 107(4):329-334.
- Arant B.S. (1991). Vesicoureteric reflux and renal injury, *Am J Kidney Dis* 17:491-511.
- Ataei N., Madani A., Esfahani S.T., Kejbafzadeh A., Ghaderi O., Jalili S. & Sharafi B. (2004). Screening for vesicoureteral reflux and renal scars in siblings of children with known reflux, *Pediatr Nephrol* 19: 1127-1131.

- Backhed F., Soderhall M., Ekman P., Normark S. & Richter-Dahlfors A. (2001). Induction of innate immune responses by *Escherichia coli* and purified lipopolysaccharide correlate with organ- and cell-specific expression of Toll-like receptors within the human urinary tract, *Cell Microbiol* 3:153-158.
- Bailey R.R. (1973). The relationship of vesicoureteric reflux and chronic pyelonephritis-reflux nephropathy, *Clin Nephrol* 1:132-141.
- Beck-Schimmer B., Oertli B., Pasch T. & Wuthrich R.P. (1998). Hyaluronan induces monocyte chemoattractant protein-1 expression in renal tubular epithelial cells, *J Am Soc Nephrol* 9:2283-2290.
- Benador D., Benador N., Slosman D., Mermillod B. & Girardin E.R. (1997). Are younger children at highest risk of renal sequelae after pyelonephritis?, *Lancet* 349:17-19.
- Benson M., Jodal U., Agace W., Hellstrom M., Marild S., Rosberg S., Sjostrom M., Wettergren B., Jonsson S. & Svanborg C. (1996). Interleukin (IL)-6 and IL-8 in children with febrile urinary tract infection and asymptomatic bacteriuria, *J Infect Dis* 174:1080-1084.
- Benson M., Jodal U., Andreasson A., Karlsson A., Rydberg J. & Svanborg C. (1994). Interleukin 6 response to urinary tract infection in childhood, *Pediatr Infect Dis J* 13:612-616.
- Bernstein J. (1994). Interstitial injury with vesicoureteral reflux, *Pediatr Nephrol* 8:633-635.
- Blom I.E., van Dijk A.J., Wieten L., Duran K., Ito Y., Kleij L., deNichilo M., Rabelink T.J., Weening J.J., Aten J. & Goldschmeding R. (2001). In vitro evidence for differential involvement of CTGF, TGF $\beta$ , and PDGF-BB in mesangial response to injury, *Nephrol Dial Transplant* 16:1139-1148
- Boettinger E.P. & Bitzer M. TGF- $\beta$  signaling in renal disease, (2002). *J Am Soc Nephrol* 13:2600-2610.
- Boettinger E.P., Letterio J.J. & Roberts A.R. (1997). Biology of TGF-  $\beta$  in knockout and transgenic mouse models, *Kidney Int* 51:1355-1360.
- Branten AJ, Mulder TP, Peters WH, Assmann KJ & Wetzels JF. (2000). Urinary excretion of glutathione S transferases alpha and pi in patients with proteinuria: reflection of the site of tubular injury, *Nephron* 85(2):120-126.
- Broder W.A. & Noble N.A. (1994). Transforming growth factor beta in tissue fibrosis, *N Eng J Med* 331:1286-1292.
- Broyer M., Chantler C., Donckerwolcke R., Ehrich J.H., Rizzoni G. & Scharer K. (1993). The paediatric registry of the European Dialysis and Transplant Association: 20 years' experience, *Pediatr Nephrol* 7:758-768.
- Bruzzi I., Corna D., Zoja C., Orisio S., Schiffrin E.L., Cavallotti D., Remuzzi G. & Benigni A. (1997). Time course and localization of endothelin-1 gene expression in a model of renal disease progression, *Am J Pathol* 151:1241-1247.
- Cawood T.J., Bashir M., Brady J., Murray B., Murray P.T. & O'Shea D. (2010). Urinary Collagen IV and  $\alpha$ 1-GST: Potential Biomarkers for Detecting Localized Kidney Injury in Diabetes - A Pilot, *Am J Nephrol* 32:219-225
- Chan W., Krieg R.J., Ward K., Santos F., Lin K. & Chan J.C.M. (2001). Progression after release of obstructive nephropathy, *Pediatr Nephrol* 16:238-244.
- Chen L., Boadle R.A. & Harris D.C. (1998). Toxicity of holotransferrin but not albumin in proximal tubule cells in primary culture, *J Am Soc Nephrol* 9:77-84.

- Chen M., Bao W., Aizman R., Huang P., Aspevall O., Gustafsson L.E., Ceccatelli S. & Celsi G. (2004). Activation of extracellular signal-regulated kinase mediates apoptosis induced by uropathogenic *Escherichia coli* toxins via nitric oxide synthase: protective role of heme oxygenase-1, *J Infect Dis* 190:127-135.
- Chen M., Jahnukainen T., Bao W., Dare E., Ceccatelli S. & Celsi G. (2003). Uropathogenic *Escherichia coli* toxins induce caspase-independent apoptosis in renal proximal tubular cells via ERK signaling, *Am J Nephrol* 23:140-151.
- Chertin B., Rolle U., Farkas A. & Puri P. (2002). The role of nitric oxide in reflux nephropathy, *Pediatr Surg Int* 18:630-634.
- Chevalier R.L. (2004). Biomarkers of congenital obstructive nephropathy: past, present and future, *J Urol* 172:852-857.
- Chevalier R.L., Goyal S., Wolstenholme J.T. & Thornhill B.A. (1998). Obstructive nephropathy in the neonatal rat is attenuated by epidermal growth factor, *Kidney Int* 54:38-47.
- Chevalier R.L., Thornhill B.A. & Chang A.Y. (2000). Unilateral ureteral obstruction in neonatal rats leads to renal insufficiency in adulthood, *Kidney Int* 58:1987-1995.
- Chevalier RL, Forbes MS & Thornhill BA. (2009). Ureteral obstruction as a model of renal interstitial fibrosis and obstructive nephropathy, *Kidney Int* 75(11):1145-52.
- Chiou Y.Y., Chiu N.T., Wang S.T., Cheng H.L. & Tang M.J. (2004). Factors associated with outcomes of children with unilateral ureteropelvic junction obstruction, *J Urol* 171:397-402.
- Choi M.E. & Ballermann B.J. (1995). Inhibition of capillary morphogenesis and associated apoptosis by dominant negative mutant transforming growth factor-beta receptors, *J Biol Chem* 270:21144-21150.
- Chromek M., Tullus K., Hertting O., Jaremko G., Khalil A., Li Y.H. & Brauner A. (2003). Matrix metalloproteinase-9 and tissue inhibitor of metalloproteinases-1 in acute pyelonephritis and renal scarring, *Pediatr Res* 53:698-705.
- Chromek M., Tullus K., Lundahl J. & Brauner A. (2004). Tissue inhibitor of metalloproteinase 1 activates normal human granulocytes, protects them from apoptosis, and blocks their transmigration during inflammation, *Infect Immun* 72:82-88.
- Cojocel C., Al-Maghrebi M., Thomson M.S., Rawoot P. & Raghupathy R. (2005). Modulation of the transforming growth factor beta1 by vitamin E in early nephropathy, *Med Princ Pract* 14:422-429.
- Cotton S.A., Gbadegesin R.A. Watson C.J., Brenchley P.E.C. & Webb N.S.A. (2000). Association between pro-inflammatory cytokines IL-6, IL-1beta, IL-1RA and TNF-alpha gene polymorphisms and acute pyelonephritis following childhood urinary tract infection, *J Am Soc Nephrol* 11:558A-566A.
- Cotton S.A., Gbadegesin R.A., Williams S., Brenchley P.E. & Webb N.J. (2002). Role of TGF beta-1 in renal parenchymal scarring following childhood urinary tract infection, *Kidney Int* 61, 1, 61-67.
- Dai C., Yang J. & Liu Y. (2003). Transforming growth factor-beta 1 potentiates renal tubular epithelial cell death by a mechanism independent signaling, *J Biol Chem* 278:12537-12545.



- De Man P., van Kooten C., Aarden L., Engberg I., Linder H. & Svanborg Eden C. (1989). Interleukin-6 induced at mucosal surfaces by gram-negative bacterial infection, *Infect Immun* 57:3383-3388.
- Deng C.L., Song X.W., Liang H.J., Feng C., Sheng Y.J. & Wang M.Y. (2006). Chronic hepatitis B serum promotes apoptotic damage in human renal tubular cells, *World J Gastroenterol* 12:1752-1756.
- Dudley J., Johnston A., Gardner A. & McGraw M. (2002). The deletion polymorphism of ACE gene is not an independent risk factor of renal scarring in children with vesicoureteric reflux, *Nephrol Dial Transplant* 17:652-654.
- Duncan M.R., Frazier K.S., Abramson S., Williams S., Klapper H., Huang X. & Grotendorst G.R. (1999). Connective tissue growth factor mediates transforming growth factor beta-induced collagen synthesis, down-regulation by cAMP, *FASEB J* 13:1774-1786.
- Eddy A.A., Kim H., Lopez-Guisa J., Oda T. & Soloway P.D. (2000) Interstitial fibrosis in mice with overload proteinuria: deficiency of TIMP-1 is not protective, *Kidney Int* 58:618-628.
- Eddy A.A. (2000): Molecular basis of renal fibrosis, *Pediatr Nephrol* 15:290-301.
- Fan J.M., Ng Y.Y., Hill P.A., Nikolic-Paterson D.J., Mu W., Atkins R.C. & Lan H.Y. (1999). Transforming growth factor-beta regulates tubular epithelial-myofibroblast transdifferentiation in vitro, *Kidney Int* 56:1455-1467.
- Farmaki E., Papachristou F., Winn R.M., Karatzas N., Sotiriou J. & Roilides E. (2005). Transforming growth factor- $\beta$ 1 in the urine of young children with urinary tract infection, *Pediatr Nephrol* 20:180-183.
- Faust W.C., Diaz M. & Pohl H.G. (2009). Incidence of post-pyelonephritic renal scarring: a meta-analysis of the dimercapto-succinic acid literature, *J Urol* 181(1):290-298.
- Frazier K.S., Paredes A., Dube P. & Styer E. (2000). Connective tissue growth factor expression in the rat remnant kidney model and association with tubular epithelial cells undergoing transdifferentiation, *Vet Pathol* 37:328-335.
- Friendés B., Godaly G., Hang L., Karpman D. & Svanborg C. (2001). Interleukin-8 receptor deficiency confers susceptibility to acute pyelonephritis, *J Infect Dis*, 183: 56-60.
- Gad H.M., Shokeir A.A. & Mohy El-Din M.S. (2004).  $^{99m}\text{TC}$ -MAG3 dynamic imaging in diagnosis of pyelonephritic changes and renal scarring : a comparative study with  $^{99m}\text{TC}$ -DMSA, Abstract, *Alasbimn Journal*, 6.
- Gagliardini E. & Benigni A (2006): Role of anti-TGF-beta antibodies in the treatment of renal injury, *Cytokine Growth Factor Rev* 17:89-96.
- Galanakis E., Bitsori M., Dimitriou H., Giannakopoulou Ch., Karkavitsas N.S. & Kalmanti M. (2006). Urine interleukin -8 as a marker of vesicoureteral reflux in infants, *Pediatrics* 117:863-867.
- Gendrel D. (1998). Urinary tract infection and biological markers: C-reactive protein, interleukins and procalcitonin, *Arch Pediatr* 5:269-273.
- Gobe G.C. & Axelsen R.A. (1987). Genesis of renal tubular atrophy in experimental hydronephrosis in the rat. Role of apoptosis, *Lab Invest* 56:273-281.
- Gokce I., Alpay H., Biyikli N., Unluguzel G., Dede F. & Topuzoglu A. (2010). Urinary levels of interleukin-6 and interleukin-8 in patients with vesicoureteral reflux and renal parenchymal scar, *Pediatr Nephrol* 25(5):905-912.
- Goldraich I.H., Goldraich N.P. & Ramos O.L. (1983). Classification of reflux nephropathy according to findings at DMSA renal scan, *Eur J Pediatr* 140:212-218.

- Goldraich N.P. & Goldraich I.H. (1992). Follow up of conservatively treated children with high and low grade vesicoureteral reflux. A prospective study, *J Urol* 148:1688-1692.
- Goldraich N.P., Ramos O.L. & Goldraich I.H. (1989). Urography versus DMSA scan in children with vesicoureteric reflux, *Pediatr Nephrol* 3:1-5.
- Gordon I. (1987). Indications for 99mtechnetium dimercapto-succinic acid scan in children, *J Urol* 137:464-467.
- Goumenos D.S., Tsakas S., El Nahas A.M., Alexandri S., Oldroyd S., Kalliakmani P. & Vlachojannis J.G. (2002). Transforming growth factor-beta(1) in the kidney and urine of patients with glomerular disease and proteinuria, *Nephrol Dial Transplant* 17: 2145-2152.
- Grande M.T., Pérez-Barriocanal F. & López-Novoa J.M. (2010). Role of inflammation in tubulo-interstitial damage associated to obstructive nephropathy, *J Inflamm* 22;7:19
- Guo G., Morrissey J., McCracken R., Tolley T. & Klahr S. (1999). Role of TNFR1 and TNFR2 receptors in tubulointerstitial fibrosis of obstructive nephropathy, *Am J Physiol* 277:F766-772.
- Guo N., Krutzsch H.C., Inman J.K. & Roberts D.D. (1997). Thrombospondin 1 and type I repeat peptides of thrombospondin 1 specifically induce apoptosis of endothelial cells, *Cancer Res* 57:1735-1742.
- Guroze M.K., Akarsu S., Yilmaz E., Godekmerdan A., Akca Z., Cifte I. & Avgun A.D. (2005). Proinflammatory cytokines and procalcitonin in children with acute pyelonephritis, *Pediatr Nephrol* 20:1445-1448.
- Hamed R.M., Ellis G., Levy M., McLorie G.A. & Balfe J.W. (1992). Captopril test in children with reflux nephropathy, *Pediatr Nephrol* 6:33-37.
- Hang L., Freundus B., Godaly G. & Svanborg C. (2000). Interleukin-8 receptor knockout mice have subepithelial neutrophil entrapment and renal scarring following acute pyelonephritis, *J Infect Dis* 182:1738-1748.
- Hansson S., Bollgren I., Esbjorner E., Jakobsson B. & Marild S.R. (1999). Urinary tract infections in children below two years of age: a quality assurance project in Sweden. The Swedish Pediatric Nephrology Association, *Acta Paediatr* 88:270-274.
- Haraoka M., Senoh K., Ogata N., Furukawa M., Matsumoto T. & Kumazawa J. (1996). Elevated interleukin-8 levels in the urine of children with renal scarring and/or vesicoureteral reflux, *J Urol* 155:678-680.
- Haszon I., Friedman A.L., Papp F., Bereczki C., Baji S., Bodrogi T., Karoly E., Endreffy E. & Turi S. (2002). ACE gene polymorphism and renal scarring in primary vesicoureteric reflux, *Pediatr Nephrol* 17:1027-1031.
- Hedges S., Anderson P., Lidin-Janson G., de Man P. & Svanborg C. (1991). Interleukin-6 response to deliberate colonization of the human urinary tract with gram-negative bacteria, *Infect Immun* 59:421-427.
- Hedges S., Stenqvist K., Lidin-Janson G., Martinell J., Sandberg T. & Svanborg C. (1992). Comparison of urine and serum concentrations of interleukin-6 in women with acute pyelonephritis or asymptomatic bacteriuria, *J Infect Dis* 166:653-656.
- Hedlund M., Freundus B., Wachtler C., Hang L., Fischer H. & Svanborg C. (2001). Type 1 fimbriae deliver an LPS- and TLR4-dependent activation signal to CD14-negative cells, *Mol Microbiol* 39:542-552.

- Hedlund M., Svensson M., Nilsson A., Duan R.D. & Svanborg C. (1996). Role of the ceramide-signaling pathway in cytokine responses to P-fimbriated *Escherichia coli*, *J Exp Med* 183:1037-1044.
- Hohenfellner K., Hunley T.E., Brezinska R., Brodhag P., Shyr Y., Brenner W., Habermehl P. & Kon V. (1999). ACE I/D gene polymorphism predicts renal damage in congenital uropathies, *Pediatr Nephrol* 13:514-518.
- Hussein A., Askar E., Elsaied M. & Schaefer F. (2010). Functional polymorphisms in transforming growth factor-beta-1 (TGFbeta-1) and vascular endothelial growth factor (VEGF) genes modify risk of renal parenchymal scarring following childhood urinary tract infection, *Nephrol Dial Transplant* 25(3):779-85.
- Ichino M., Kusaka M., Kuroyanagi Y., Mori T., Morooka M., Sasaki H., Shiroki R., Shishido S., Kurahashi H. & Hoshinaga K. (2010) Urinary neutrophil-gelatinase associated lipocalin is a potential noninvasive marker for renal scarring in patients with vesicoureteral reflux, *J Urol* 183(5):2001-2007.
- Ichino M., Mori T., Kusaka M., Kuroyanagi Y., Ishikawa K., Shiroki R., Kowa H., Kurahashi H. & Hoshinaga K. (2008). Global gene expression profiling of renal scarring in a rat model of pyelonephritis, *Pediatr Nephrol* 23(7):1059-71.
- Ingraham S.E., Saha M., Carpenter A.R., Robinson M., Ismail I., Singh S., Hains D., Robinson M.L., Hirselj D.A., Koff S.A., Bates C.M. & McHugh K.M. 2010 Pathogenesis of Renal Injury in the Megabladder Mouse: A Genetic Model of Congenital Obstructive Nephropathy, *Pediatr Res* 68:500-507.
- International Reflux Study Committee (1981). Medical versus surgical treatment of primary vesicoureteral reflux: report of the, *Pediatrics* 67:392-400.
- Jacobson S.H., Hylander B., Wretling B. & Brauner A. (1994). Interleukin-6 and interleukin-8 in serum and urine in patients with acute pyelonephritis in relation to bacterial-virulence-associated traits and renal function, *Nephron* 67:172-179.
- Jacobson S.H., Lu Y. & Brauner A. (1998) Soluble interleukin-6 receptor, interleukin-10 and granulocyte colony-stimulating factor in acute pyelonephritis: relationship to markers of bacterial virulence and renal function, *Nephron* 80:401-407.
- Jahnukainen T., Chen M. & Celsi G. (2005). Mechanisms of renal damage owing to infection, *Pediatr Nephrol* 20:1043-1053.
- Jakobsson B., Nolstedt L., Svensson L., Soderlundh S. & Berg U. (1992). 99mTechnetium-dimercaptosuccinic acid scan in the diagnosis of acute pyelonephritis in children: relation to clinical and radiological findings, *Pediatr Nephrol* 6:328-334.
- Jantusch B.A., O'Donnell R. & Wiedermann B.L. (2000). Urinary interleukin-6 and interleukin-8 in children with urinary tract infection, *Pediatr Nephrol* 15:236-240.
- Jernigan S., Wing D., Schnaper H.W., Poncelet A.C., Lopez-Guisa J., Ueno H. & Eddy A.A. (1996). Effects of chronic blockade with soluble TGF- $\beta$  II receptor in rats with overload proteinuria. Abstract, *J Am Soc Nephrol* 10:573.
- Kabore A.F., Simard M. & Bergeron M.G. (1999). Local production of inflammatory mediators in an experimental model of acute obstructive pyelonephritis, *J Infect Dis* 179:1162-1172.
- Kanellopoulos T.A., Salakos C., Spiliopoulou I., Ellina A., Nikolakopoulou N.M. & Papanastasiou D.A. (2006). First urinary tract infection in neonates, infants and young children: a comparative study, *Pediatr Nephrol* 21:1131-1137.

- Kaneto H., Ohtani H., Fukuzaki A., Ishidoya S., Takeda A., Ogata Y., Nagura H. & Orikasa S. (1999). Increased expression of TGF- $\beta$ 1 but not of its receptors contributes to human obstructive nephropathy, *Kidney Int* 56:2137-2146.
- Kang D.H., Kanellis J., Hugo C., Truong L., Anderson S., Kerjaschki D., Schreiner G.F. & Johnson R.J. (2002). Role of the microvascular endothelium in progressive renal disease, *J Am Soc Nephrol* 13:806-816.
- Kapoor R., Reddy K., Liatsikos E.N., Smith A.D. & Singhal P.C. (2001). Escherichia coli-human uroepithelial cell interaction products enhance fibroblast migration and matrix accumulation, *J Endourol* 15:155-159.
- Kassem J.A., Wasilewska A.M. & Zoch-Zwierz W.M. (2005). Urinary concentration of proinflammatory cytokines with regard to infected urinary tract region, *Wiad Lek* 58:14-19.
- Kasuga H., Ito Y., Sakamoto S., Kawachi H., Shimizu F., Yuzawa Y. & Matsuo S. (2001). Effects of anti-TGF-beta type II receptor antibody on experimental glomerulonephritis, *Kidney Int* 60:1745-1755.
- Kelly F.J., Anderson S., Thompson M.M., Oyama T.T., Kennefick T.M., Corless C.L., Roman R.J., Kurtzberg L., Pratt B.M. & Ledbetter S.R. (1999). Acute and chronic renal effects of recombinant human TGF-beta2 in the rat, *J Am Soc Nephrol* 10:1264-1273.
- Kenda R.B., Zupancic Z., Fettich J.J. & Meglic A. (1997). A follow-up study of vesico-ureteric reflux and renal scars in asymptomatic siblings of children with reflux, *Nucl Med Commun* 18:827-831.
- Kersnik Levart T., Kenig A., Fettich J.J., Ključevšek D., Novljan G. & Kenda R. (2002). Sensitivity of ultrasonography in detecting renal parenchymal defects in children, *Pediatr Nephrol* 17:1059-1062.
- Khalil A., Tullus K., Bakhiet M., Burman L.G. Jaremko G. & Brauner A. (2000). Angiotensin II type 1 receptor antagonist (losartan) down-regulates transforming growth factor-beta in experimental acute pyelonephritis, *J Urol* 164:186-191.
- Khalil A., Tullus K., Bartfai T., Bakhiet M., Jaremko G. & Brauner A. (2000). Renal cytokine responses in acute escherichia coli pyelonephritis in IL-6-deficient mice, *Clin Exp Immunol* 122:200-206.
- Khalil M.S., El Nahas A.M. & Blakemore A.I.F. (2005). Transforming growth factor- $\beta$ 1 SNPs, genetic and phenotypic correlations in progressive kidney insufficiency, *Nephron Exp Nephrol* 101:31-41.
- Khan S.B., Cook H.T., Bhangal G., Smith J., Tam F.W.K. & Pusey C.D. (2005). Antibody blockade of TNF- $\alpha$  reduces inflammation and scarring in experimental crescentic glomerulonephritis, *Kidney Int* 67:1812-1820.
- Kim H., Oda T., Lopez-Guisa J., Wing D., Edwards D.R., Soloway P.D. & Eddy A.A. (2001). TIMP-1 deficiency does not attenuate interstitial fibrosis in obstructive nephropathy, *J Am Soc Nephrol* 12(4):736-748.
- Kincaid-Smith P. (1975). Glomerular lesions in atrophic pyelonephritis and reflux nephropathy, *Kidney Int* 4:81-83.
- Kishimoto T. & T. Harano. (1988). Molecular regulation of B lymphocyte response, *Annu Rev Immunol* 6:485-512.
- Klahr S. (2001). Urinary tract obstruction, *Semin Nephrol* 21:133-145.
- Klahr S. & Morrissey J. (2002). Obstructive nephropathy and renal fibrosis, *Am J Renal Physiol* 283:861-875.

- Klahr S. & Morrissey J.J. (2003). Obstructive nephropathy and renal fibrosis: The role of bone morphogenic protein-7 and hepatocyte growth factor, *Kidney Int Suppl* 87:S105-112.
- Klahr S. & Morrissey J.J. (1998). The role of growth factors, cytokines, and vasoactive compounds in obstructive nephropathy, *Semin Nephrol* 18:622-632.
- Ko Y.C., Mukaida N., Ishiyama S., Tokue A., Kawai T., Matsushima K. & Kasahara T. (1993). Elevated interleukin-8 levels in the urine of patients with urinary tract infections, *Infect Immun* 61:1307-1314.
- Koff S.A. (1990). Pathophysiology of ureteropelvic junction obstruction. Clinical and experimental observations, *Urol Clin North Am* 17:263-272.
- Kohler J., Tencer J., Thysell H. & Forsberg L. (1997). Vesicoureteral reflux diagnosed in adulthood. Incidence of urinary tract infections, hypertension, proteinuria, back pain and renal calculi, *Nephrol Dial Transplant* 12:2580-2587.
- Kohler J.R., Tencer J., Thysell H., Forsberg L. & Hellstrom M. (2003). Long-term effects of reflux nephropathy on blood pressure and renal function in adults, *Nephron Clin Pract* 93:C35-C46.
- Kopp J.B., Factor V.M., Mozes M., Nagy P., Sanderson N., Bottinger E.P., Klotman P.E. & Thorgeirsson S.S. (1996). Transgenic mice with increased plasma levels of TGF- $\beta$  1 develop progressive renal disease, *Lab Invest* 74:991-1003.
- Kopp J.B. (2002). BMP-7 and the proximal tubule, *Kidney Int* 61: 351-352
- Korzon M., Liberek A., Marek A. Szlagatys-Sidorkiewicz A. & Marek K. (2004). Rola transformującego czynnika wzrostu beta 1 (TGF- $\beta$ 1) i jego polimorfizmu genowego w etiopatogenezie i przebiegu klinicznym niektórych stanów chorobowych u ludzi, *Ped Pol* 79:963-970.
- Kowalewska-Pietrzak M., Klich I. & Mlynarski W. (2008). TGF- $\beta$ 1 gene polymorphisms and primary vesicoureteral reflux in childhood, *Pediatr Nephrol* 23(12):2195-2200.
- Kushibiki T., Nagata-Nakajima N., Sugai M., Shimizu A. & Tabata Y. (2005). Delivery of plasmid DNA expressing small interference RNA for TGF- $\beta$  type II receptor by cationized gelatin to prevent interstitial renal fibrosis, *J Control Release* 105:318-331.
- Lane A., Johnson D.W., Pat B., Winterford C., Endre Z., Wei M. & Gobe G.C. (2002). Interacting roles of myofibroblasts, apoptosis and fibrogenic growth factors in the pathogenesis of renal tubulo-interstitial fibrosis, *Growth Factors* 20:109-119.
- Lee J.H., Son C.H., Lee M.S. & Park Y.S. (2006). Vesicoureteral reflux increases the risk of renal scars: a study of unilateral reflux, *Pediatr Nephrol* 21:1281-1284.
- Leemans J.C., Butter L.M., Pulskens W.P., Teske G.J., Claessen N., van der Poll T. & Florquin S. (2009). The role of Toll-like receptor 2 in inflammation and fibrosis during progressive renal injury, *PLoS One* 27;4(5):e5704.
- Leonova L.V., Severgina E.S., Popova O.P., Kononov D.M., Petruchina Iu.V. & Simonova N.A. (2007). Transforming growth factor as a marker beta of nephrogenetic disturbance in congenital obstructive uropathies, *Arkh Pato* 69(4):35-8.
- Lerner G.R. (1994). Urinary tract infections in children, *Pediatr Ann* 23:463, 466-473.
- Li L., Wu Y. & Zhang W. (2010). PAX2 re-expression in renal tubular epithelial cells and correlation with renal interstitial fibrosis of rats with obstructive nephropathy, *Ren Fail* 32(5):603-611.

- Li Y., Zhang J., Fang L., Luo P., Peng J. & Du X. (2010). Lefty A attenuates the TGF-beta1-induced epithelial to mesenchymal transition of human renal proximal epithelial tubular cells, *Mol Cell Biochem* 39(1-2):263-270.
- Liapis H. (2003). Biology of congenital obstructive nephropathy, *Nephron Exp Nephrol* 93:e87-91.
- Lonnemann G., Engler-Blum G., Muler G.A., Koch K.M. & Dinarello C.A. (1995). Cytokines in human renal interstitial fibrosis. II. Intrinsic interleukin (IL)-1 synthesis and IL-1-dependent production of IL-6 and IL-8 by cultured kidney fibroblasts, *Kidney Int* 47:845-854.
- Manucha W. (2007). Biochemical-molecular markers in unilateral ureteral obstruction, *Biocell* 31(1):1-12.
- Marra G., Oppizzo C., Ardissino G., Dacco V., Testa S., Avolio L., Taioli E. & Sereni F. (2004). Italkid Project. Severe vesicoureteral reflux and chronic renal failure: a condition peculiar to male gender?, *J Pediatr* 144:677-681.
- Mittal R., Sharma S., Chhibber S. & Harjai K. (2009). Evaluation of tumour necrosis factor-alpha and interleukin-1beta in an experimental pyelonephritis model induced with planktonic and biofilms cells of *Pseudomonas aeruginosa*, *Can J Infect Dis Med Microbiol* 20(3):e35-42.
- Mizuno S., Matsumoto K. & Nakamura T. (2001). Hepatocyte growth factor suppresses interstitial fibrosis in a mouse of obstructive nephropathy, *Kidney Int* 59:1304-1314.
- Mohan N., Colhoun E. & Puri P. (2008). Renal parenchymal damage in intermediate and high grade infantile vesicoureteral reflux, *J Urol* 180:1635-1638.
- Moorthy I., Wheat D. & Gordon I. (2004). Ultrasonography in the evaluation of renal scarring using DMSA scan as the gold standard, *Pediatr Nephrol* 19:153-156.
- Muinuddin G., Rahman H., Hossain M.M., Jahan S. & Begum A. (2008). Urinary tract infection and vesicoureteric reflux in children, *Mymensingh Med J* 17:S28-31.
- Nangaku M., Pippin J. & Couser W.G. (1999). Complement membrane attack complex (C5b-9) mediates interstitial disease in experimental nephrotic syndrome, *J Am Soc Nephrol* 10:2323-2331.
- Narayana C., Tripathi M., Kumar A., Gowda N.K., Phom H., Chandra P., Bandopadhyaya G. & vBal C. (2004). Technetium-99m-L,L-ethylenedicycysteine renal scan as a single-modality investigation for the evaluation of renal morphology and function: a comparative study with technetium-99m-dimercaptosuccinic acid, *Nucl Med Commun* 25:743-747.
- Nath K.A. (1998). The tubulointerstitium in progressive renal disease, *Kidney Int* 54:992-994.
- Nee L.E., Mc Morrow T., Campbell E., Slattery C. & Ryan M.P. (2004). TNF-alpha and IL-1beta-mediated regulation of MMP-9 and TIMP-1 in renal proximal tubular cells, *Kidney Int* 66:1376-1386.
- Ng Y.Y., Huang T.P., Yang W.C., Chen Z.P., Yang A.H., Mu W., Nikolic-Paterson D.J., Atkins R.C. & Lan H.Y. (1998). Tubular epithelialmyofibroblast transdifferentiation in progressive tubulointerstitial fibrosis in 5/6 nephrectomized rats. *Kidney Int* 54: 864-876.
- Nicolle L.E., Brunka J., Orr P., Wilkins J. & Harding G.K. (1993). Urinary immunoreactive interleukin-1 alpha and interleukin-6 in bacteriuric institutionalized elderly subjects, *J Urol* 149:1049-1053.

- Noe H.N. (1992) The long-term results of prospective sibling reflux screening, *J Urol* 148:1739-1742.
- Norbeck J.C., Ritchey M.R. & Bloom D.A. (1993). Labial fusion causing upper urinary tract obstruction, *Urology* 42:209-211.
- Oh M.M., Jin M.H., Bae J.H., Park H.S., Lee J.G. & Moon du G. (2008). The role of vesicoureteral reflux in acute renal cortical scintigraphic lesion and ultimate scar formation, *J Urol* 180(5):2167-2170.
- Ohashi R., Kitamura H. & Yamanaka N. (2000). Peritubular capillary injury during the progression of experimental glomerulonephritis in rats, *J Am Soc Nephrol* 11: 47-56.
- Ohta K., Takano N., Seno A., Yachie A., Miyawaki T., Yokoyama H., Tomosugi N., Kato E. & Taniguchi N. (1992). Detection and clinical usefulness of urinary interleukin-6 in the diseases of the kidney and the urinary tract, *Clin Nephrol* 38:185-189.
- Ohtomo Y., Nagaoka R., Kaneko K., Fukuda Y., Miyano T. & Yamashiro Y. (2001). Angiotensin converting enzyme gene polymorphism in primary vesicoureteral reflux, *Pediatr Nephrol* 16:648-652.
- Okada H, Moriwaki K., Kalluri R., Imai H., Ban S., Takahama M. & Suzuki H. (2000). Inhibition of monocyte chemoattractant protein-1 expression in tubular epithelium attenuates tubulointerstitial alteration in rat Goodpasture syndrome, *Kidney Int* 57:927-936.
- Okada H., Moriwaki K., Kalluri R., Takenaka T., Imai H., Ban S., Takahama M. & Suzuki H. (2000). Osteopontin expressed by renal tubular epithelium mediates interstitial monocyte infiltration in rats, *Am J Physiol Renal Physiol* 278:F110-121.
- Oldfield M.D., Bach L.A., Forbes J.M., Nikolic-Paterson D., McRobert A., Thallas V., Atkins R.C., Osicka T., Jerums G. & Cooper M.E. (2001). Advanced glycation end products cause epithelial-myofibroblast transdifferentiation via the receptor for advanced glycation end products (RAGE), *J Clin Invest* 108:1853-1863.
- Olszyna D.P., Opal S.M., Prins J.M., Horn D.L., Speelman P., van Deventer S.J.H. & van der Poll T. (2000). Chemotatic activity of CXC chemokines interleukin-8, growth-related oncogene- $\alpha$ , and epithelial cell-derived neutrophil-activating protein-78 in urine of patients with urosepsis, *J Infect Dis* 182:1731-1737.
- Orikasa S., Fukuzaki A. & Konda R. (1995). Obstructive and reflux nephropathy. Abstract, *Nippon Rinsho* 53:2019-2026.
- Orleana P., Bagedano P., Rangarajan V., Zhao J.H., Chee Eng N.D., Fettich J., Chaiwatanarat T., Sonmezoglu K., Kumar D., Park Y.H., Samuel A.M., Sixt R., Bhtnagar V. & Padhy A.K. (2004). Relation ship between acute pyelonephritis, renal scarring, and vesicoureteral reflux, *Pediatr Nephrol* 19:1122-1126.
- Orphanides C., Fine L.G. & Norman J.T. (1997). Hypoxia stimulates proximal tubular cell matrix production via a TGF-beta1-independent mechanism, *Kidney Int* 52:637-647.
- Ortiz A., Ziyadeh F.N. & Neilson E.G. (1997). Expression of apoptosis regulatory genes in renal proximal tubular epithelial cells exposed to high ambient glucose and in diabetic kidneys, *J Investig Med* 45:50-56.
- Otto G., Braconier J., Andreasson A. & Svanborg C. (1999). Interleukin-6 and disease severity in patients with bacteremic and nonbacteremic febrile urinary tract infection, *J Infect Dis* 179:172-179.

- Ozen S., Alikasifoglu M., Saatci U., Bakkaloglu A., Besbas N., Kara N., Kocak H., Erbas B., Unsal I. & Tuncbilek E. (1999). Implications of certain genetic polymorphisms in scarring in vesicoureteric reflux: importance of ACE polymorphism, *Am J Kidney Dis* 34:140-145.
- Padillo F.J., Cruz A., Segura-Jiménez I., Ruiz-Rabelo J., Vázquez-Ezquerria M.R., Perea-Alvarez M.D., Peña J., Briceño J. & Muntané J. (2007). Anti-TNF-alpha treatment and bile duct drainage restore cellular immunity and prevent tissue injury in experimental obstructive jaundice, *Int J Immunopathol Pharmacol* 20(4):855-60.
- Pardo R., Malaga S., Coto E., Navarro M., Alvarez V., Espinosa L., Alvarez R., Vallo A., Loris C. & Branga S. (2003). Renin-angiotensin system polymorphisms and renal scarring, *Pediatr Nephrol* 18:110-114.
- Patel N.S., Chatterjee P.K., Di Paola R., Mazzon E., Brotti D., De Sarro A., Cuzzocrea S. & Thiemermann C. (2005). Endogenous interleukin-6 enhances the renal injury, dysfunction, and inflammation caused by ischemia/reperfusion, *J Pharmacol Exp Ther* 312:1170-1178.
- Pecile P., Miorin E., Romanello C., Vidal E., Contardo M., Valent F. & Tenore A. (2009). Age-related renal parenchymal lesions in children with first febrile urinary tract infections, *Pediatrics* 124(1):23-9.
- Pereira B.J., Shapiro L., King A.J., Falagas M.E., Strom J.A. & Dinarello C.A. (1994). Plasma levels of IL-1beta, TNF-alfa and their specific inhibitors in undialyzed chronic renal failure, CAPD and hemodialysis patients, *Kidney Int* 45:890-896.
- Peters C. & Rushton H.G. (2010). Vesicoureteral reflux associated renal damage: congenital reflux nephropathy and acquired renal scarring, *J Urol* 184(1):265-273.
- Pichler R.H., Hugo C., Shankland S.J., Reed M.J., Bassuk J.A., Andoh T.F., Lombardi D.M., Schwartz S.M., Bennett W.M., Alpers C.E., Sage E.H., Johnson R.J. & Couser W.G. (1996). SPARC is expressed in renal interstitial fibrosis and in renal vascular injury, *Kidney Int* 50:1978-1989.
- Pimentel J.L. (1995). Role of angiotensin II in the expression and regulation of transforming growth factor-beta in obstructive nephropathy, *Kidney Int* 48:1233-1246.
- Polito C., La Manna A., Mansi L., Rambaldi P.F., Papale M.R., Marte A. & Di Toro R. (1999). Body growth in early diagnosed vesicoureteric reflux, *Pediatr Nephrol* 13:876-879.
- Polito C., Rambaldi P.F., Signoriello G., Mansi L. & La Manna A. (2006). Permanent renal parenchymal defects after febrile UTI are closely associated with vesicoureteric reflux, *Pediatr Nephrol* 21:521-526.
- Poncelet A.C. & Schnaper H.W. (1998). Regulation of human mesangial cell collagen expression by transforming growth factor- $\beta$ 1, *Am J Physiol* 275:458-466.
- Ransley P.G. & Risdon R.A. (1981). Reflux nephropathy: effects of antimicrobial therapy on the evolution of the early pyelonephritic scar, *Kidney Int* 20:733-742.
- Rao W.H., Evans G.S. & Finn A. (2001). The significance of interleukin 8 in urine, *Arch Dis Child* 85:256-262.
- Rastaldi M.P., Ferrario F., Giardino L., Dell'Antonio G., Grillo C., Grillo P., Strutz F., Muller G.A., Colasanti G. & D'Amico G. (2002). Epithelial-mesenchymal transition of tubular epithelial cells in human renal biopsies, *Kidney Int* 62:137-146.
- Rebenok A.Z., Tikhonov I.I. & Chizh A.S. (1999). Role of IL-8 defensins in pathogenesis of chronic glomerulonephritis and pyelonephritis, *Ter Arkh* 71:62-67.

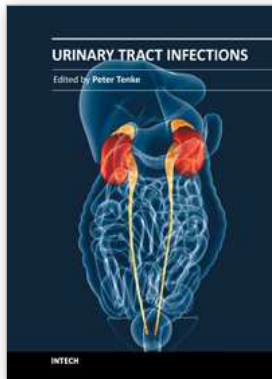


- Ricardo S.D., Levinson M.E., DeJoseph M.R. & Diamond J.R. (1996) Expression of adhesion molecules in rat renal cortex during experimental hydronephrosis, *Kidney Int* 50:2002-2010.
- Rice E.K., Nikolic-Paterson D.J., David J.R., Bucala R., Metz Ch.N., Atkins R.C. & Tesch G.H. (2004). Macrophage accumulation and renal fibrosis are independent of macrophage migration inhibitory factor in mouse obstructive nephropathy, *Nephrology* 9:278-287.
- Roberts A.B. & Sporn M.B. (1987). Transforming growth factor-beta: potential common mechanisms mediating its effects on embryogenesis, inflammation-repair, and carcinogenesis, *Int J Rad Appl Instrum B* 14:435-439.
- Roberts I.S., Burrows C., Shanks J.H., Venning M. & McWilliam L.J. (1997). Interstitial myofibroblasts: predictors of progression in membranous nephropathy, *J Clin Pathol* 50:123-127.
- Roilides E., Papachristou F., Gioulekas E., Tsaparidou S., Karatzas N., Sotiriou J. & Tsiouris J. (1999). Increased urine interleukin-6 concentrations correlate with pyelonephritic changes on <sup>99m</sup>Tc-dimercaptosuccinic acid scans in neonates with urinary tract infections, *J Infect Dis* 180:904-907.
- Rugo H.S., O'Hanley P., Bishop A.G., Pearce M.K., Abrams J.S., Howard M. & O'Gara A. (1992). Local cytokine production in a murine model of Escherichia coli pyelonephritis, *J Clin Invest* 89:1032-1039.
- Rushton H.G. (1997). Urinary tract infections in children. Epidemiology, evaluation, and management, *Pediatr Clin North Am* 44:1133-1169.
- Rushton H.G., Majd M., Jantusch B., Wiedermann B.L. & Belman A.B. (1992). Renal scarring following reflux and nonreflux pyelonephritis children: evaluation with <sup>99m</sup>technetium dimercaptosuccinic acid scintigraphy, *J Urol* 147:1327-1332.
- Rushton H.G. (1997). The evaluation of acute pyelonephritis and renal scarring with technetium <sup>99m</sup>-dimercaptosuccinic acid renal scintigraphy: evolving concepts and future directions, *Pediatr Nephrol* 11:108-120.
- Saborio P., Krieg R.J., Kuemmerle N.B., Norokus E.P., Schwartz Ch.C. & Chan J.C.M. (2000).  $\alpha$ -Tocopherol modulates lipoprotein cytotoxicity in obstructive nephropathy, *Pediatr Nephrol* 14:740-746.
- Sager C., Lopez J.C., Duran V., Burek C. & Perazzo E. (2009) Transforming growth factor-beta1 in congenital ureteropelvic junction obstruction: diagnosis and follow-up. *Int Braz J Urol* 35(3):315-323.
- Sanderson N., Factor V., Nagy P., Kopp J., Kondaiah P., Wakefield L., Roberts A.B., Sporn M.B. & Thorgeirsson S.S. (1995). Hepatic expression of mature transforming growth factor beta 1 in transgenic mice results in multiple tissue lesions, *Proc Natl Acad Sci USA* 92:2572-2576.
- Sato M., Muragaki Y., Saika S., Roberts A.B. & Ooshima A. (2003). Targeted disruption of TGF- $\beta$ 1/Smad3 signaling protects against renal tubulointerstitial fibrosis induced by unilateral ureteral obstruction, *J Clin Invest* 112:1486-1494.
- Schnaper H.W., Hayashida T., Hubchak S.C. & Poncelet A.C. (2003). TGF-beta signal transduction and mesangial cell fibrogenesis, *Am J Physiol Renal Physiol* 284:243-252.
- Seidel C., Schaefer F. & Scharer K. (1993). Body growth in urinary tract malformations, *Pediatr Nephrol* 7:151-155.

- Seron D., Alexopoulos E., Raftery M.J., Hartley B. & Cameron J.S. (1990). Number of interstitial capillary cross-sections assessed by monoclonal antibodies: relation to interstitial damage, *Nephrol Dial Transplant* 5:889-893.
- Shaikh N., Ewing A.L., Bhatnagar S. & Hoberman A. (2010). Risk of renal scarring in children with a first urinary tract infection: a systematic review, *Pediatrics* 126(6):1084-1091.
- Shapiro E., Slovis T.L., Perlmutter A.D. & Kuhns L.R. (1988). Optimal use 99mtechnetium-glucoheptonate scintigraphy in the detection of pyelonephritic scarring in children: a preliminary report, *J Urol* 149:1175-1177.
- Sheu J.N., Chen S.M., Meng M.H. & Lue K.H. (2009). The role of serum and urine interleukin-8 on acute pyelonephritis and subsequent renal scarring in children, *Pediatr Infect Dis J* 28(10):885-90.
- Shinozaki M., Ueno H., Ando T., Kashiwagi M., Fukusa K., Hirakata H., Okuda S. & Fujishima M. (1998). Marked suppression of interstitial fibrosis with adenovirus-mediated In vivo gene transfer of soluble TGF- $\beta$  II receptor in experimental hydronephrosis. Abstract, *J Am Soc Nephrol* 9:527A.
- Shweke N., Boulous N., Jouanneau C., Vandermeersch S., Melino G., Dussaule J.C., Chatziantoniou C., Ronco P. & Boffa J.J. (2008). Tissue transglutaminase contributes to interstitial renal fibrosis by favoring accumulation of fibrillar collagen through TGF-beta activation and cell infiltration, *Am J Pathol* 173(3):631-642.
- Sieniawska M. & Wyszzyńska T. (2003). Nefrologia dziecięca, t.2. Ośrodek Informacji Naukowej „Polfa” Sp. z o.o. Warszawa.
- Silva J.M., Diniz J.S., Lima E.M., Pinheiro S.V., Marino V.P., Cardoso L.S., Colosimo E.A., Silva A.C. & Oliveira E.A. (2009). Independent risk factors for renal damage in a series of primary vesicoureteral reflux: a multivariate analysis, *Nephrology (Carlton)* 14(2):198-204.
- Smellie J.M., Edwards D., Hunter N., Normand I.C.S. & Prescod N. (1975). Vesico-ureteric reflux and renal scarring, *Kidney Int* 4:62-72.
- Smellie J.M., Normand I.C. & Katz G. (1981). Children with urinary tract infection: a comparison of those with and those without vesicoureteral reflux, *Kidney Int*, 20:717-722.
- Smellie J.M., Prescod N.P., Shaw P.J., Risdon R.A. & Bryant T.N. (1998). Childhood reflux and urinary infection: a follow-up of 10-41 years in 226 adults, *Pediatr Nephrol* 12: 727-736.
- Smellie J.M., Ransley P.G., Normand I.C., Prescod N. & Edwards D. (1985). Development of new renal scars: a collaborative study, *Br Med J* 29:1957-1960.
- Smółko M., Zoch-Zwierz W. & Wasilewska A. (2004). Ocena stężenia interleukiny 6 i 8 w moczu i surowicy dzieci z odpływami pęcherzowo-moczowodowymi, *Prob Lek* 43:22.
- Smółko M., Zoch-Zwierz W., Wasilewska A. & Kassem J.A.D. (2004). Ocena stężenia TGF-  $\beta_1$  w moczu u dzieci z odpływami pęcherzowo-moczowodowymi, *Ped Pol*, 79:115-119.
- Solari V., Owen D. & Puri P. (2005). Association of transforming growth factor-beta1 gene polymorphism with reflux nephropathy, *J Urol* 174:1609-1611.
- Solari V., Unemoto K., Piaseczna-Piotrowska A. & Puri P. (2004). Increased expression of mast cells in reflux nephropathy, *Pediatr Nephrol* 19:157-163.
- Stokland E., Hellstrom M., Jacobsson B. & Jodal U. (1996). Renal damage one year after first urinary tract infection: role of dimercaptosuccinic acid scintigraphy, *J Pediatr* 129:815-820.

- Strutz F. & Muller G.A. (1999). Interstitial pathomechanisms underlying progressive tubulointerstitial damage, *Kidney Blood Press Res* 22:71-80.
- Strutz F., Muller G.A. & Neilson E.G. (1996). Transdifferentiation, a new angle on renal fibrosis, *Experimental Nephrol* 4:267-270.
- Strutz F. & Neilson E.G. (2003). New insights into mechanisms of fibrosis in immune renal injury, *Springer Semin Immunopathol* 24:459-476.
- Strutz F., Okada H., Lo C.W., Danoff T., Carone R.L., Tomaszewski J.E. & Neilson E.G. (1995). Identification and characterization of a fibroblast marker: FSP1, *J Cell Biol* 130:393-405.
- Svensson M., Irjala H., Alam P., Holmqvist B., Lundstedt A.C. & Svanborg C. (2005). Natural history of renal scarring in susceptible mIL-8Rh<sup>-/-</sup> mice, *Kidney Int* 67: 103-110.
- Szeto C.C., Chan R.W.Y., Lai K.B., Szeto C.Y.K., Chow K.m., Li P.K.T. & Lai F.M.M. (2005). Messenger RNA Expression of target genes in the urinary sediment of patients with chronic kidney diseases, *Nephrol Dial Transplant* 20:105-113.
- Taha A.S., Grant V. & Kelly R.W. (2003). Urinalysis for interleukin-8 in the non-invasive diagnosis of acute and chronic inflammatory diseases, *Postgrad Med J* 79:159-163.
- Tikhonov I., Rebenok A. & Chyzh A. (1997). A study of interleukin-8 and defenses in urine and plasma of patients with pyelonephritis and glomerulonephritis, *Nephrol Dial Transplant* 12:2557-2561.
- Traylor L.A. & Mayeux P.R. (1997). Nitric oxide generation mediates lipid A-induced oxidant injury in renal proximal tubules, *Arch Biochem Biophys* 338:129-135.
- Tullus K., Fituri O., Linne T., Escobar-Billing R., Wikstad I., Karlsson A., Burman L.G., Wretling B. & Brauner A. (1994). Urine interleukin-6 and interleukin-8 in children with acute pyelonephritis, in relation to DMSA scintigraphy in the acute phase and at 1-year follow-up, *Pediatr Radiol* 24:513-515.
- Uhlen P., Laestadius A., Jahnukainen T., Soderblom T., Backhed F., Celsi G., Brismar H., Normark S., Aperia A. & Richter-Dahlfors A. (2000). Alpha-haemolysin of uropathogenic E. coli induces Ca<sup>2+</sup> oscillations in renal epithelial cells, *Nature* 405:694-697.
- Vachvanichsanong P. (2007). Urinary tract infection: one lingering effect of childhood kidney diseases--review of the literature, *J Nephrol* 20(1):21-8.
- Van den Abbeele A.D., Treves S.T., Lebowits R.L., Bauers Davis R.T., Retik A. & Colodny A. (1987). Vesicoureteral reflux in asymptomatic siblings of patients with known reflux: radionuclide cystography, *Pediatrics* 79:147-153.
- Vanderfaellie A., Flamen P., Wilikens A., Desprechins B. & Piepsz A. (1998). Technetium-99m-dimercaptosuccinic acid renal scintigraphy in children over 5 years, *Pediatr Nephrol* 12:295-297.
- Vernon S.J., Coulthard M.G., Lambert H.J., Keir M.J. & Matthews J.N. (1997). New renal scarring in children who at age 3 and 4 years had had normal scans with dimercaptosuccinic acid: follow up study, *BMJ* 315:905-908.
- Vesey D.A., Cheung K.W.Y., Cuttle L., Endre Z.A., Gobe G. & Johnson D.W. (2002). Interleukin-1 $\beta$  induces human proximal tubule cell injury,  $\alpha$ -smooth muscle actin expression and fibronectin production, *Kidney Int* 62:31.
- Vesey D.A., Cheung C., Cuttle., Endre Z., Gobe G. & Johnson D.W. (2002). Interleukin-1 $\beta$  stimulates human renal fibroblast proliferation and matrix protein production by means of a transforming growth factor- $\beta$ -dependent mechanism, *J Lab Clin Med* 140: 342-350.

- Wan J., Greenfield SP., Ng M., Zerlin M., Ritchey M.L. & Bloom D. (1996). Sibling reflux: a dual center retrospective study, *J Urol* 156:677-679.
- Wang J., Konda R., Sato H., Sakai K., Ito S. & Orikasa S. (2001). Clinical significance of urinary interleukin-6 in children with reflux nephropathy, *J Urol* 165:210-214.
- Wang P.X., Fan M.Q., Huang C.B., Feng J.Y., Xiao Y., Fang Z.Q. & Zhang Y.P. (2005). Effect of losartan on slowing progression of chronic allograft nephropathy, *Chin Med Sci J* 20:231-236.
- Wang S., Wilkes M.C., Leof E.B. & Hirschberg R. (2010). Noncanonical TGF-beta pathways, mTORC1 and Abl, in renal interstitial fibrogenesis, *Am J Physiol Renal Physiol* 298:F142-F149.
- Wasilewska A., Taranta-Janusz K., Dębek W., Zoch-Zwierz W. & Kuroczycka-Saniutycz E. (2011). KIM-1 and NGAL: new markers of obstructive nephropathy, *Pediatr Nephrol* 26(4):579-586.
- Weiss R.A., Madaio M.P., Tomaszewski J.E. & Kelly C.J. (1994). T cells reactive to an inducible heat shock protein induce disease in toxin-induced interstitial nephritis, *J Exp Med* 180:2239-2250.
- Wetmore J.B., Hung A.M., Lovett B.H., Sen S., Quershy O., Johansen K.L. (2005). Interleukin-1 gene cluster polymorphisms predict risk of ESRD, *Kidney Int* 68: 278-284.
- Wolfs T.G.A.M., Buurman W.A., Van Schadewijk A., De Vries B., Daemen M.A.R.C., Hiemstra P.S. & Van't Veer C. (2002). In vivo expression of toll-like receptor 2 and 4 by renal epithelial cells: INF-gamma and TNF-alpha mediated up-regulation during inflammation, *J Immunol* 168:1286-1293.
- Wyszyńska T. & Litwin M. (2000). Nadciśnienie tętnicze u dzieci i młodzieży, *PZWL Warszawa*.
- Yao Y., Zhang J., Ye D.F., Tan D.Q., Peng J.P., Xie M. & Fang L. (2011). Left-right determination factor is down-regulated in fibrotic renal tissue of human hydronephrosis, *BJU Int* 107(6):1002-1008.
- Ylinen E., Ala-Houhala M. & Wikstrom S. (2003). Risk of renal scarring in vesicoureteral reflux detected either antenatally or during the neonatal period, *Urology* 61:1238-1242.
- Zajączkowska M., Zinkiewicz Z., Duda B., Kołacz A. & Szajner-Milart I. (2001). Zaburzenia anatomiczne i czynnościowe dróg moczowych u dzieci z zakażeniem układu moczowego, *Pol Merk Lek* 58:213-215.
- Zeisberg M., Bonner G., Maeshima Y., Colorado P., Müller G.A., Strutz F. & Kaluri R. (2001). Collagen composition and assembly regulates epithelial-mesenchymal transdifferentiation, *AJP* 159:1313-1321.
- Zhang C., Meng X., Zhu Z., Liu J. & Deng A. (2004). Connective tissue growth factor regulates the key events in tubular epithelial to myofibroblast transition in vitro, *Cell Bio Int* 28:863-873.
- Zhang G., Oldroyd S.D., Huang L.H., Yang B., Li Y., Ye R. & El Nahas AM. (2001). Role of apoptosis and Bcl-2/Bax in the development of tubulointerstitial fibrosis during experimental obstructive nephropathy, *Exp Nephrol* 9(2):71-80
- Zhang H. & Phan S. (1999). Inhibition of myofibroblast apoptosis by transforming growth factor  $\beta_1$ , *Am J Respir Cell Mol Biol* 21:658-665.
- Zhang M., Tang J., Li X. Interleukin-1 $\beta$ -induced Transdifferentiation of renal proximal tubular cells is mediated by activation of JNK and p38 MAPK. *Nephron Experimental Nephrol* 2005, 99:68-76.



## **Urinary Tract Infections**

Edited by Dr. Peter Tenke

ISBN 978-953-307-757-4

Hard cover, 360 pages

**Publisher** InTech

**Published online** 30, September, 2011

**Published in print edition** September, 2011

Urinary tract infections (UTIs) are among the most common bacterial infections worldwide, and they are also the leading cause of hospital-acquired infections. Therefore, the appropriate management of UTIs is a major medical and financial issue. This book covers different clinical manifestations of UTI, with special emphasis on some hard-to-treat diseases, and special conditions in respect of treatment; antibiotic resistance and the available alternative strategies for the prevention and treatment of UTIs and it deals with urinary tract infections in children. The aim of this book is to give a summary about the different aspects of the diagnosis, management and prevention of urinary tract infections for all medical disciplines.

### **How to reference**

In order to correctly reference this scholarly work, feel free to copy and paste the following:

Beata Bieniaś, Małgorzata Zajączkowska, Halina Borzęcka, Przemysław Sikora, Marek Majewski, Ewelina Książek and Andrzej Borzęcki (2011). Post-Inflammatory Nephropathy, Urinary Tract Infections, Dr. Peter Tenke (Ed.), ISBN: 978-953-307-757-4, InTech, Available from: <http://www.intechopen.com/books/urinary-tract-infections/post-inflammatory-nephropathy>

# **INTECH**

open science | open minds

### **InTech Europe**

University Campus STeP Ri  
Slavka Krautzeka 83/A  
51000 Rijeka, Croatia  
Phone: +385 (51) 770 447  
Fax: +385 (51) 686 166  
[www.intechopen.com](http://www.intechopen.com)

### **InTech China**

Unit 405, Office Block, Hotel Equatorial Shanghai  
No.65, Yan An Road (West), Shanghai, 200040, China  
中国上海市延安西路65号上海国际贵都大饭店办公楼405单元  
Phone: +86-21-62489820  
Fax: +86-21-62489821

© 2011 The Author(s). Licensee IntechOpen. This chapter is distributed under the terms of the [Creative Commons Attribution-NonCommercial-ShareAlike-3.0 License](#), which permits use, distribution and reproduction for non-commercial purposes, provided the original is properly cited and derivative works building on this content are distributed under the same license.