

# Current Management of Urinary Tract Infection in Children

Yusuf Kibar

*Gulhane Military Medical Academy, Department of Urology,  
Section of Pediatric Urology,  
Ankara,  
Turkey*

## 1. Introduction

Urinary tract infection (UTI) is the most commonly diagnosed bacterial infection of childhood, and has a significant healthcare impact. Renal parenchymal infection and scarring are well-established complications of UTI in children and can lead to renal insufficiency, hypertension and renal failure. Although frequently encountered and well researched, diagnosis and management of UTI continue to be a controversial issue with many challenges for the clinician.

The evolving state of knowledge about pediatric UTI leaves many questions and controversies. The goal of this chapter is to provide an up-to-date summary of the literature with particular attention to practical questions about diagnosis and management for the clinician. This chapter reviews also recent evidence regarding the epidemiology and evaluation of children with UTI.

## 2. Definitions

UTI is defined as the presence of bacteria in urine along with symptoms of infection. However, since asymptomatic colonization of the urinary tract can occur, other features such as the presence of inflammatory markers or follow-up cultures may be needed to definitively diagnose a UTI.

UTIs have been classified in many ways: upper versus lower urinary tract, complicated versus uncomplicated, first episode versus recurrent, symptomatic versus asymptomatic, and according to severity simple versus severe infection.

Pediatric UTIs are most simply categorized into two types: first infections and recurrent infections. Recurrent UTI is defined as two or more UTIs over a six-month period (Ditchfield et al., 1994). Recurrent UTI increases the risk of subsequent renal scarring. Recurrent UTI may be subclassified into three groups (Ma & Shortliffe, 2004):

1. *Unresolved infection*: due to subtherapeutic level of antimicrobial (because of poor renal concentrating ability or gastrointestinal malabsorption), non-compliance with treatment, and resistant pathogens. Most unresolved infections are treated successfully when proper culture and antimicrobial sensitivity patterns are available.

2. *Bacterial persistence*: may be due to a nidus in the urinary tract (Shortliffe, 1995). Surgical correction or medical treatment for urinary dysfunction may be needed. The surgically correctable sources of bacterial persistence are infection stones, infected nonfunctioning or poorly functioning kidneys or renal segments, infected ureteral stumps after nephrectomy, fistulas with bowels, infected necrotic papillae, and infected urachal cyst.
3. *Reinfection*: each episode is a new infection acquired from periurethral, perineal or rectal flora.

First childhood UTIs are considered *complicated* because of the evaluation and management implications. Lower UTI's include bladder infections (cystitis), whereas upper UTI's include pyelonephritis and perinephric and renal abscess. Ascending infection of the urinary tract is a complex process that has been associated with bacterial adhesion, virulence, and motility properties as well as host anatomic, humoral, and genetic factors (Svanborg & Godaly, 1997). The presence of fever, chills, and flank pain has usually been considered clinical evidence of upper tract infection.

From the clinical point of view, UTI could also be classified as *simple* or *severe UTI*. Severe UTI is related to the presence of fever of  $> 39^{\circ}\text{C}$ , the feeling of being ill, persistent vomiting, and moderate or severe dehydration. A child with a simple UTI may have only mild pyrexia, but is able to take fluids and oral medication. The child is only slightly or not dehydrated and has a good expected level of compliance. When a low level of compliance is expected, such a child should be managed as one with a severe UTI.

*Breakthrough UTI* may be caused by a change in the resistance pattern of organisms colonizing the urethra, noncompliance, vesicoureteral reflux (VUR) or dysfunctional voiding. Recognizing and addressing these associated factors are essential in treating breakthrough UTI.

It is certainly possible to have bacteria within the urinary tract and be asymptomatic without having clinical infection or renal scarring. The prevalence of *asymptomatic bacteriuria* has been documented to be approximately 0.9% among young schoolgirls. Of these patients, 10% were found to have VUR without any renal scarring. Controversy continues regarding the need for antibiotic treatment of asymptomatic bacteriuria (Schoen, 1990; Ahmed, 1996). If recurrent bacteriuria is truly asymptomatic, no antimicrobial treatment may be the best option, as some studies have shown that asymptomatic children are at very low risk of renal scarring, and prophylactic treatment did not decrease the risk of UTI recurrence (Shortliffe, 1995).

### 3. Epidemiology

The epidemiology of UTI during childhood varies by age, gender, and other factors. The incidence of UTI in infants ranges from approximately 0.1 to 1.0 percent in all newborn infants to as high as 10 percent in low-birth-weight infants (Klein & Long, 1995). It represents the most common bacterial infection in children less than 2 years of age. It is the most common cause of fever of unknown origin in boys less than 3 years (Jodal, 1987). In the first year of life, mostly the first 3 months, UTI is more common in boys (3.7%) than in girls (2%), after which the incidence changes, being 3% in girls and 1.1% in boys (Foxman, 2002). Two studies of the prevalence of UTI among children presenting to an emergency department with fever found rates ranging from 3.5 to 5.5% (Hoberman et al., 1993; Shaw et al., 1998). Girls were more than twice as likely as boys to have UTI, and among boys, uncircumcised infants had an eightfold higher risk. This finding compares well with

population-based studies of UTI which document a 4- to 10-fold increase in risk of UTI among uncircumcised males during the first year of life, likely due to colonization of the mucosal surface of the foreskin with bacteria (To et al., 1998). White children were significantly more likely to have UTI than black children in both prevalence studies, with rates as high as 16 to 17% among white girls (Shaw et al., 1998). The reason for this increase associated with race is unclear, and referral bias may be a factor for these emergency department-based studies. However, some studies of white females suggest that there may be genetic tendencies for UTI, such as lack of secretion of carbohydrates that protect against bacterial adherence in the urinary tract (Jantusch et al., 1994; Sheinfeld et al., 1989).

#### 4. Importance of UTI

The clinical significance of UTI has been controversial. In the preantibiotic era, UTI had a mortality rate as high as 20%, although acute complications in healthy children are now uncommon except in young infants, who may progress to systemic infection (Dayan et al., 2004; Hansson et al., 1997). Long-term complications of UTI have been associated with renal scarring and include hypertension, chronic renal failure, and toxemia in pregnancy. Long-term follow-up data are limited, although one Swedish study found that children diagnosed with renal scarring due to pyelonephritis during the 1950s and 1960s developed high rates of hypertension (23%) and end-stage renal disease (10%) (Jacobson et al., 1989). More recent studies question the association between pyelonephritis and end-stage renal disease (Esbjorner et al., 1997; Sreenarasimhaiah & Hellerstein, 1998). Although the individual risks associated with UTI remain unclear, the high prevalence of UTI and potential morbidity associated with complications require careful attention to diagnosis and management.

#### 5. Etiology

Clinically important infections usually occur due to bacteria, although viruses, fungi, and parasites can also cause infection. Common bacterial pathogens include gram-negative species such as *Escherichia coli*, *Klebsiella*, *Proteus*, *Enterobacter*, *Pseudomonas*, and *Serratia* spp. and gram-positive organisms, including group B streptococci, *Enterococcus* sp., and *Staphylococcus aureus*. *Escherichia coli* is the most common infecting pathogen in children, accounting for up to 90 percent of UTIs (Shapiro, 1992). Gram-positive organisms represent 5-7% of cases. Groups A and B streptococci are relatively common in the newborn (Richards et al., 1999). There is an increasing trend towards the isolation of *Staphylococcus saprophyticus* in UTIs in children, although the role of this organism is still debatable (Abrahamsson et al., 1993). The virulence of the invading bacteria and the susceptibility of the host are of primary importance in the development of UTI (Feld, 1991).

Fungi can cause cystitis in certain settings and with associated risk factors. Fungi are the second most common cause of nosocomial UTI in children, and can spread systemically and can be life-threatening. Risk factors for fungal UTI's include the use of invasive devices (drains and catheters), previous broad-spectrum antibiotic exposure, and systemic immunosuppression. A true candidurial infection can be difficult to diagnose, since it can represent colonization, contamination, or infection, and may or may not have associated symptoms. The potential for candiduria to develop into invasive candidiasis in the neonatal intensive care unit is significant. Risk factors for this progression include prematurity, congenital urinary tract abnormalities, parenteral nutrition, respiratory intubation, and

umbilical artery or intravenous catheterization. Furthermore, the kidney is the most commonly affected organ in candidiasis, with “fungus balls” representing a life-threatening infection. As such, renal and bladder sonography is important in the evaluation of neonates with candiduria.

Viral cystitis represents another form of non-bacterial UTI affecting children. *Adenovirus types 11 and 21*, *Influenza A*, *polyomavirus BK*, and *Herpes simplex* viruses can cause irritative voiding symptoms, hemorrhagic cystitis and even VUR or urinary retention. In non-immunized or immunosuppressed children, *Herpes zoster* cystitis presents similarly. Fortunately, these forms of cystitis are self-limited. Immunosuppressed children undergoing kidney or bone marrow transplantation, or those receiving chemotherapy are especially susceptible to viral cystitis, including those caused by *Cytomegalovirus* and *Adenoviruses 7, 21 and 35*. Antivirals such as ribavirin and vidarabine may be helpful when viral cystitis is diagnosed.

## 6. Pathogenesis and risk factors

In neonates, the usual route of infection is presumed to be hematogenous. Later in life, infection is usually caused by ascension of bacteria into the urinary tract. Retrograde ascent is the most common mechanism of infection. Any condition that leads to urinary stasis (renal calculi, obstructive uropathy, VUR and dysfunctional voiding) may predispose to the development of UTI in children (Batsky, 1996). Obstruction and dysfunctional voiding are among the most common causes of UTI (Ma & Shortliffe, 2004). A wide variety of congenital urinary tract abnormalities can cause UTIs through obstruction, e.g. urethral valves, ureteropelvic and ureterovesical junctions’ obstructions, ureteroceles, ectopic ureters, bladder extrophy, or non-obstructive urinary stasis (e.g. prune belly syndrome, VUR). More mundane but significant causes of UTIs include labial adhesion and chronic constipation (Abrahamsson et al., 1993).

Phimosis is the inability to retract the foreskin, and is a normal physiologic occurrence in newborn boys. Phimosis can predispose to UTI (Craig et al., 1996; To et al., 1998). The prepuce can serve as a reservoir for potentially uropathogenic bacteria. Enterobacteria derived from intestinal flora colonize the preputial sac, glandular surface and the distal urethra. Among these organisms are strains of *E. coli* expressing P fimbriae which adhere to the inner layer of the preputial skin and to uroepithelial cells (Fussel et al., 1988). Neuropathic bladder dysfunction (spina bifida, sphincter dyssynergia, etc) may also lead to postvoid residual urine and secondary VUR (Schulman, 2004).

Dysfunctional voiding refers to dysfunction of the lower urinary tract in the absence of any apparent organic cause. The child with dysfunctional voiding habitually contracts the urethral sphincter during voiding. The term cannot be applied unless repeated uroflow measurements have shown curves with a staccato pattern or if verified by invasive urodynamic investigation. Dysfunctional voiding may result in infrequent bladder emptying aided by delaying manoeuvres, e.g. crossing legs, sitting on heels (Wan et al., 1995). It is often associated with daytime enuresis and constipation (Smith & Elder, 1994). Dysfunctional voiding can lead to secondary VUR, and may be exacerbated by chronic constipation because of alterations in pelvic floor activity caused by impacted stool. Normally, any bacteria that enter the bladder are flushed out of the bladder with complete and frequent voiding. Infrequent voiding and residual urine in the bladder allows bacteria that enter the bladder to grow and multiply enough to cause infection.

Incomplete relaxation of the pelvic floor during voiding can cause poor compliance and/or incomplete emptying, both of which are thought to contribute to bacteriuria and UTI. Girls with recurrent UTIs have a particularly high incidence of voiding dysfunction (Chen et al., 2004; Mingin et al., 2004) and should be screened with a thorough history, voiding diary, and appropriate clinical evaluation to rule out constipation. In children who demonstrate a high likelihood for this diagnosis, it may be appropriate to address these issues before proceeding to more invasive tests such as a VCUG. Treatment of voiding dysfunction includes timed voiding, treatment of constipation, prophylactic antibiotics and, in some cases, use of anticholinergic medication (e.g., oxybutynin) or biofeedback (Kibar et al., 2009, 2007a, 2007b; Yagci et al., 2005).

VUR is the abnormal retrograde flow of bladder urine into the upper urinary tract through an incompetent ureterovesical junction. Reflux in itself that is without bacterial contamination and low in pressure has not been documented to be deleterious. Reflux in the presence of bacteria as a risk factor for upper UTIs or pyelonephritis. In children without urologic symptoms or history of infection, the incidence of reflux is likely less than 1%. In children with a history of symptomatic UTI, the incidence of reflux has been estimated to range from 20% to 50%. Untreated upper UTIs have been shown to lead to acquired renal scarring or reflux nephropathy in children (Yeung et al., 1997). Controversy continues regarding the association of VUR with the pathogenesis of renal scarring, reflux nephropathy and pyelonephritis (Ditchfield et al., 1994; Egli & Tulchinsky, 1993). Studies reporting on investigation during a febrile UTI document initial defect and subsequent scarring in 34 to 70% and 9.5 to 38%, respectively (Benador et al., 1997; Ditchfield & Nadel, 1998; Hoberman et al., 2003; Majd & Rushton, 1992). Unfortunately, many studies do not have complete enough follow-up to determine the true incidence of scarring, as it has been shown that defects will change up to 6 months later (Ditchfield et al., 2002; Wallin et al., 2001). There is also the potential for interobserver variability in renal scans, with differences ranging from small to notable (Gacinovic et al., 1996)). Children less than one year of age with a UTI are at much greater risk for renal scarring than older children; children over five years of age uncommonly have new renal scarring with UTI (Andrich & Majd, 1992). While some researchers emphasize the risk of renal scarring from recurrent UTI without reflux (Gordon, 1995), others are just as adamant regarding the risk of scarring from reflux in the absence of infection (Blumenthal, 1995). The fact that renal scarring develops in only a minority of patients with pyelonephritis and/or VUR suggests that the development of renal scarring likely involves the interplay of several factors and cannot simply be attributed to the presence of infection or reflux alone.

## 7. Clinical presentation

The presenting symptoms of UTI depend on the anatomic site of the infection and the age of the patient. Regardless of UTI location, infants and many young children cannot describe their symptoms; hence it is critical to understand the observable signs and symptoms of infection to make the diagnosis. In a child with so-called "asymptomatic" bacteriuria, only subtle clues, such as enuresis or squatting, may be present. Alternatively, a systemically ill neonate may be lethargic and hypotensive.

Cystitis is second in frequency only to respiratory infection as a reason for pediatric medical visits. Classic symptoms of cystitis include urinary frequency, urgency, dysuria, hematuria, suprapubic pain, sensation of incomplete emptying, and even incontinence. Non-specific

symptoms can include poor feeding, irritability, lethargy, vomiting, diarrhea, ill appearance, and abdominal distension. Fever and flank pain are unusual symptoms for lower UTI.

Pyelonephritis, and to a lesser degree renal abscesses, typically begin as a lower UTI that proceeds to an upper UTI as the infections ascends. However, pyelonephritis and renal abscesses can also result from hematogenous spread of infection (e.g., bacteremia). Symptoms that occur with upper UTI's overlap those for cystitis, in part because cystitis is common in both. In upper UTI's, flank pain and fevers (classically intermittent and  $>39^{\circ}\text{C}$ ) are more pronounced and important

## 8. Diagnosis

A thorough history from parents, and the child if possible, and a physical examination are essential in the evaluation of pediatric UTI. There are no signs specific for UTI in the infant. If there is a gross genitourinary anatomic abnormality, a renal mass may be palpable, as found in children with xanthogranulomatous pyelonephritis or infected severe hydronephrosis. Palpation in the suprapubic and flank areas may cause pain in the older child, but generalized abdominal or upper quadrant pain may also be present. Perineal examination rarely shows an ectopic ureteral opening, ureterocele, or ureteral discharge in girls. It is mandatory to look for phimosis and labial adhesion. Signs such as back scars, sacral fat pads, or sacral dimples or pits may suggest neurogenic bladder and may require further investigation. On boys, the testes are abnormal if affected by epididymitis or epididymo-orchitis. The absence of fever does not exclude the presence of an infective process. The presence of irritative urinary symptoms in the absence of bacteria suggests a non-UTI cause such as vaginitis, urethritis, pinworms, or the use of bubble baths (Zelikovic, 1992).

The question of when to screen for UTI has been evaluated in a number of studies. The presence of specific symptoms for UTI, including dysuria, frequency, urgency, suprapubic discomfort, and flank pain, should lead to screening. However, young children with UTI may present with nonspecific symptoms, such as poor feeding, vomiting, irritability, jaundice (in newborns), or fever alone may be appropriate.

Dipstick urinalysis is the most common initial laboratory testing, and may be the most cost-effective screen for infant UTI. Urine cultures and blood cultures (if sepsis is suspected) are the mainstays of diagnosis. However, diagnosis is complicated by contamination from fecal bacteria that colonize the perineal area and distal urethra. The guideline issued by the American Academy of Pediatrics (AAP) for the evaluation of fever ( $39.0^{\circ}\text{C}$  [ $102.2^{\circ}\text{F}$ ] or higher) of unknown origin suggests urinalysis in all cases and a urine culture in all boys younger than six months of age and all girls younger than two years of age (Baraff et al., 1993).

The definitive diagnosis of infection in children requires a positive urine culture (Ma & Shortliffe, 2004). Urine must be obtained under bacteriologically reliable conditions when undertaking a urine specimen culture (Zorc et al., 2005). A positive urine culture is defined as the presence of more than 100,000 cfu/mL of one pathogen. Most UTIs are caused by a single organism; the presence of two or more organisms usually suggests contamination. The urine specimen may be difficult to obtain in a child less than 4 years old and different methods are advised since there is a high risk of contamination (Watson, 2004).

The final concentration of bacteria in urine is directly related to the method of collection, diuresis, and method of storage and transport of the specimen. In order to obtain a urine

sample in the best condition in children under 2 years of age (girls and uncircumcised boys without sphincteric control), it is better to use suprapubic bladder aspiration or bladder catheterization. In older children with sphincteric control, clean-voided midstream specimen is possible and reliable (Ma & Shortliffe, 2004). Voided specimen should be obtained after cleansing of the urethral meatus. Girls should be positioned backwards on the toilet seat to help spread the labia. Suprapubic bladder aspiration is the most sensitive method, but has a low rate of success unless aided by ultrasound visualization of urine in the bladder. Urine may be obtained in 23-99% of cases (Ma & Shortliffe, 2004). Bladder catheterization is also a sensitive method, even though there is the risk of introduction of nosocomial pathogens (Hellerstein, 2002). Urine from bagged and voided specimens are easier for the child, but have significant false positive rates, ranging from 85-99% (Ma & Shortliffe, 2004). It is helpful when the culture is negative and has a positive predictive value of 15% (Cavagnaro, 2005). Any number of colonies from a suprapubic bladder aspiration, more than  $10^3$  colonies from an intermittent catheterization, and more than  $10^5$  colonies from a midstream clean-catch urine collection indicate UTI (Batisky, 1996).

Although urine culture is the gold standard for diagnosis of UTI, results are not available for 24 to 48 h. Rapid techniques to predict UTI include urine dipstick tests for leukocyte esterase and nitrites and various forms of urinalysis, including standard microscopy on a centrifuged specimen, high-powered microscopy with a hemacytometer, and Gram stain of unspun urine for organisms.

Nitrite is the degradation product of the nitrates of bacterial metabolism, particularly of Gram-negative bacteria. When an infection is caused by Gram-positive bacteria, the test may be negative (Ma & Shortliffe, 2004; Cavagnaro, 2005). Limitations of the nitrite test include: not all uropathogens reduce nitrate to nitrite (e.g. *Pseudomonas aeruginosa*, enterococci), even nitrite-producing pathogens may show a negative test result (due to the short transit time in the bladder in cases of high diuresis and urine dilution, e.g. neonates). The nitrite test has a sensitivity of only 45-60%, but a very good specificity of 85-98% (Ma & Shortliffe, 2004; Watson, 2004; Deville et al., 2004).

Leucocyte esterase is produced by the activity of leucocytes. The test for leucocyte esterase has a sensitivity of 48-86% and a specificity of 17-93% (Ma and Shortliffe, 2004; Watson, 2004; Hoberman & Wald, 1997; Deville et al., 2004). A combination of nitrite and leucocyte esterase testing improves sensitivity and specificity, but carries the risk of false-positive results (Deville et al., 2004). Back-up urine culture should be sent to detect the approximately 12% of UTIs that will be missed by the dipstick test (Huicho et al., 2002). The dipstick test has become useful to exclude rapidly and reliably the presence of a UTI, provided both nitrite and leucocyte esterase tests are negative. If the tests are positive, it is better to confirm the results in combination with the clinical symptoms and other tests (Watson, 2004; Deville et al., 2004).

The presence or absence of pyuria on urinalysis, along with a urine culture, help make the diagnosis of pediatric UTI. Pyuria with a negative urine culture suggests viral infection, infection with fastidious organisms such as mycobacterium or haemophilus, or noninfectious cystitis. The lack of pyuria and a negative urine culture suggests a non-infectious etiology for cystitis. A positive urine culture along with pyuria likely represents bacterial or fungal infection. A positive urine culture without pyuria may indicate contamination or an immunosuppressed host.

## 9. Evaluation after UTI

After establishing the diagnosis of UTI, certain children require additional testing to determine possible causes for their infection. This is important as eradication of UTI with antibiotics may not be possible without correction of underlying structural abnormalities. In addition, the early diagnosis of anatomically based UTI's can prevent or ameliorate long-term sequelae of persistent or recurrent infections. The evaluation of children after a UTI was once thought to be quite straightforward and focused primarily on detecting and treating VUR in order to prevent end-stage renal disease from reflux nephropathy. Hutch and Hodson were among the first to describe a relationship between reflux and renal scarring. Subsequently, a relationship was established between reflux and chronic pyelonephritis (Smellie et al., 1964; Williams & Eckstein, 1965). Until recently, further evaluation of UTI has centered on the search for reflux with anatomic studies. AAP has suggested guidelines for radiologic imaging of children with UTIs. Urinary tract imaging is recommended in a febrile infant or young child between the ages of 2 months and 2 years with a first documented UTI. Typically this involves a renal and bladder ultrasound and a voiding cystourethrogram (VCUG) (AAP, 1999).

## 10. Standard radiological studies

There is more controversy than consensus regarding the appropriateness of different diagnostic imaging modalities in the evaluation of UTI in children (Slovic, 1995). A "Gold Standard" imaging technique has to be cost-effective, painless, safe, with minimal or no radiation, and an ability to detect any significant structural anomaly. Current techniques do not fulfil all such requirements. Imaging is indicated if patients have known anatomic structural abnormalities, unusual uropathogens such as *Proteus* or *Mycobacterium tuberculosis*, fail to improve with appropriate antimicrobial therapy, or have an unclear source of infection. VCUG should be performed as soon as a child is infection-free and bladder irritability has passed, since delaying the VCUG is associated with losing patients to follow-up. Other radiologic studies are computerized tomography (CT), magnetic resonance imaging (MRI), intravenous urography (IVU), and technetium-99m labeled dimercaptosuccinic acid (DMSA) and technetium-99m labeled mercaptoacetyl triglyceride (MAG-3) scans. The most commonly used imaging techniques are discussed in the following sections. IVU provides a precise anatomic image of the kidneys and can readily identify some urinary tract abnormalities (e.g., cysts, hydronephrosis) (Smellie, 1995a). The major disadvantages of IVU include decreased sensitivity compared with renal scintigraphy in the detection of both pyelonephritis and renal scarring (Smellie, 1995a). Higher dosage of radiation and risk of reaction to contrast medium are also reasons for concern. Given these disadvantages, IVU appears to have little role in the work-up of UTI in children, and the role of IVU is declining with the increasing technical superiority of CT (Huang et al., 1992) and MRI. However, the indication for their use is still limited in UTI.

Although IVU has been a time-honored examination in the initial radiologic evaluation of UTI in children, ultrasonography (US) has largely replaced IVU as the initial screening examination (Rushton et al., 1992). US has become very useful in children because of its safety, speed and high accuracy in identifying the anatomy and size of the renal parenchyma and collecting system (Pickworth et al., 1995). Most physicians believe that it is an appropriate screening test to rule out major abnormalities. US alone is not generally



adequate for investigation of UTI in children, as it is unreliable in detecting VUR, renal scarring or inflammatory changes (Smellie, 1995a). It is subjective and therefore operator-dependent, and gives no information on renal function. However, scars can be identified, although not as well as with DMSA scanning (Pickworth et al., 1995).

VCUG is considered mandatory in the evaluation of UTIs in children less than 1 year of age. Typically, the contrast study is chosen for the first study due to its greater anatomic detail, although the radionuclide cystography has been shown in some studies to have a higher sensitivity (Polito et al., 2000). Radionuclide cystography is performed by prolonging the period of scanning after the injection of DTPA or MAG-3 as part of a dynamic renography. It represents an attractive alternative to conventional cystography, especially when following patients with reflux, because of its lower dose of radiation. Radiation dose used for this technique is only 1 percent of that used for standard VCUG (Batsky, 1996). Its continuous monitoring is also more sensitive for identifying reflux than the intermittent fluoroscopic monitoring of VCUG. Disadvantages are a poor image resolution and difficulty in detecting lower urinary tract abnormalities (De Sadeleer et al., 1994; Piaggio et al., 2003). While debate exists regarding the timing of a VCUG study, it is generally accepted that it can be performed once the child is afebrile and has a negative urine culture, because VUR may be the transient effect of infection (Mahant et al., 2001). Compliance also appears to be better when the VCUG is performed early after a UTI (McDonald et al., 2000). However, because of low sensitivity and specificity, and because VCUG involves gonadal irradiation and catheterization, its use in diagnosing VUR has been questioned (Ditchfield et al., 1994; Haycock, 1991). In recent years, tailored low-dose fluoroscopic VCUG has been used for the evaluation of VUR in girls in order to minimize radiological exposure (Kleinman et al., 1994). VCUG is mandatory in the assessment of febrile childhood UTI, even in the presence of normal ultrasonography. Up to 23% of these patients may reveal VUR (Kass et al., 2000). It can be performed as a standard contrast study or with a radionuclide.

Renal cortical scintigraphy has replaced IVU as the standard technique for the detection of renal inflammation and scarring (Eggl & Tulchinsky, 1993). Technetium-99m labeled DMSA is a radiopharmaceutical that is bound to the basement membrane of proximal renal tubular cells. This technique is highly sensitive and specific. This technique ensures an accurate diagnosis of cortical scarring by showing areas of hypoactivity indicating lack of function. DMSA scanning offers the advantages of earlier detection of acute inflammatory changes and permanent scars compared with US or IVU (Bircan et al., 1995; MacKenzie et al., 1994). It is also useful in neonates and patients with poor renal function. UTI interferes with the uptake of this radiotracer by the proximal renal tubular cells, and may show areas of focal defect in the renal parenchyma. A star-shaped defect in the renal parenchyma may indicate an acute episode of pyelonephritis. A focal defect in the renal cortex usually indicates a chronic lesion or a renal scar (Kass, 1994; Britton, 1998). A focal scarring or a smooth uniform loss of renal substance has generally been regarded as being associated with VUR (reflux nephropathy) (Rosenberg et al., 1992). The use of Tc-99m DMSA scans can be helpful in the early diagnosis of acute pyelonephritis. About 50-85% of children will show positive findings in the first week. Minimal parenchymal defects, when characterized by a slight area of hypoactivity, can resolve with antimicrobial therapy (Risdon et al., 1994). However, defects lasting longer than 5 months are considered to be renal scarring (Jakobsson & Svensson, 1997). CT is sensitive and specific for the detection of acute pyelonephritis, but CT is more expensive than scintigraphy and exposes the patient to higher levels of radiation, and its use is not supported by evidence.

Contrast material-enhanced voiding ultrasonography has been introduced for the diagnoses of VUR without irradiation (Westwood et al., 2005; Piaggio et al., 2003). Further studies are necessary to determine the role of this new imaging modality in UTI.

When voiding dysfunction is suspected, e.g. incontinence, increased residual urine, increased bladder wall thickness, urodynamic evaluation with uroflowmetry and electromyography should be considered.

## 11. Schedule of investigation

Screening of infants for asymptomatic bacteriuria is unlikely to prevent pyelonephritic scar formation, as these usually develop very early in infancy. Only a minority of children with a UTI have an underlying urological disorder, but when present such a disorder can cause considerable morbidity. Thus, after a maximum of two UTI episodes in a girl and one episode in a boy, investigations should be, but not in the case of asymptomatic bacteriuria (Piaggio et al., 2003; Melis et al., 1992; Smellie 1995b). The need for DTPA/MAG-3 scanning is determined by the ultrasound findings, particularly if there is suspicion of an obstructive lesion.

## 12. Treatment

Therapeutic trials in children with UTI are rare and poorly controlled (Helwig, 1994). Thus, controversy regarding dosage or length of therapy with antimicrobials continues. Treatment's goals are elimination of symptoms and eradication of bacteriuria in the acute episode, prevention of a recurrent UTI, prevention of renal scarring, and correction of associated urological lesions. Initial antibiotic therapy should be based on age, clinical severity, location of infection, presence of structural abnormalities, and allergy to certain antibiotics.

Hospitalization is suggested for symptomatic young infants (less than three months of age) and all children with clinical evidence of acute severe pyelonephritis (high fever, toxic appearance, severe flank pain) (Berman, 1991). Parenteral fluid replacement and appropriate antimicrobial treatment, preferably with cephalosporins (third generation) should be given. In patients with an allergy to cephalosporins, aztreonam or gentamicin may be used. If a Gram-positive UTI is suspected by Gram stain, it is useful to administer aminoglycosides in combination with ampicillin or amoxicillin/clavulanate (Smellie, 1995b). Treatment generally begins with a broad-spectrum antibiotic, but it may need to be changed based on the results of urine culture and sensitivity testing.

When the child becomes afebrile and is able to take fluids, he/she may be given an oral agent to complete the 10-14 days of treatment, which may be continued on an outpatient basis (Hoberman & Wald, 1997). The preferred oral antimicrobials are: trimethoprim (TMP), TMP plus sulphamethoxazole (co-trimoxazole), an oral cephalosporin, or amoxicillin/clavulanate. In children less than 3 years of age, who have difficulty taking oral medications, parenteral treatment for 7-10 days seems advisable, with similar results to those with oral treatment (Bloomfield et al., 2005).

The choice of antibiotic may be affected by local resistance patterns and other considerations. Amoxicillin was traditionally the first-line therapy for outpatient treatment of UTI in children. However, increased rates of *Escherichia coli* resistance have made amoxicillin a less acceptable choice, and studies have found higher cure rates for co-

trimoxazole (AAP, 1999). Fluoroquinolones are widely used in adult patients, although concerns about potential effects on musculoskeletal joint development based on animal data have restricted their use in young children. A recent review of the use of for pediatric UTI noted a high rate of efficacy among patients with complex medical conditions or multidrug resistance, although data on the safety of these agents are limited (Koyle et al., 2003). Fluoroquinolones may be used as second-line therapy in the treatment of serious infections (Grady, 2003). Chloramphenicol, sulphonamides, tetracyclines, rifampicin and amphotericin B should be avoided. The use of ceftriaxone must also be avoided due to its undesired side effect of jaundice.

The duration of outpatient treatment for patients with a less toxic appearance and uncomplicated UTI (no systemic signs of infection) is also controversial (Zelikovic et al., 1992) Evidence is lacking for the use of short-course therapy in children with UTI (Hellerstein, 1994). Oral empirical treatment with TMP, an oral cephalosporin or amoxicillin/clavulanate is recommended, according to the local resistance pattern. The duration of treatment in uncomplicated UTIs treated orally should be 5-7 days (Michael et al., 2003; Tran et al., 2001). A single parenteral dose may be used in cases of doubtful compliance and with a normal urinary tract (Khan, 1994). If the response is poor or complications develop, the child must be admitted to hospital for parenteral treatment (Hellerstein, 1995).

There is no consensus regarding the treatment of pediatric candiduria. Measures include stopping antibiotics, removing or changing indwelling catheters, and antifungal therapy. Commonly used antifungal agents include oral fluconazole and parenteral or intravesical amphotericin B. In patients with obstruction or failure to improve with medical management, urgent percutaneous nephrostomy tube placement to drain the kidney may be needed. Additional measures include amphotericin B irrigation of the nephrostomy tube, or even nephrectomy in severe cases.

### 13. Prophylaxis

If there is an increased risk of pyelonephritis, e.g. VUR, and recurrent UTI, low-dose antibiotic prophylaxis is recommended (Smellie et al., 1988; Arant, 2001). It may also be used after an acute episode of UTI until the diagnostic work-up is completed. The most effective antimicrobial agents are: nitrofurantoin, TMP, cephalixin and cefaclor (Smellie et al., 1988).

### 14. Conclusions

UTI is a common pediatric problem with the potential to produce long-term morbidity. Renal parenchymal infection and scarring are well-established complications of UTI in children and can lead to renal insufficiency, hypertension and renal failure. The clinical presentation of UTI is variable. Young children presenting with fever may have nonspecific symptoms of UTI, and a high index of suspicion is appropriate in this setting. Although culture of the urine remains the gold standard for diagnosing and treating UTIs, technical considerations including method of collection of the urine as well as the time necessary for culture results remain problematic. The appropriate treatment of UTI is controversial and becomes more complex with the emergence of resistance to commonly used antibiotics. The length of antibiotic therapy for UTI in children is also an area of controversy. Therapeutic trials in children with UTI are rare and poorly controlled. Thus, controversy regarding

dosage or length of therapy with antimicrobials continues. The diagnostic work-up should be tailored to uncover functional and structural abnormalities such as dysfunctional voiding, VUR and obstructive uropathy. A more aggressive work-up, including renal cortical scintigraphy, ultrasound and voiding cystourethrography, is recommended for patients at greater risk for pyelonephritis and renal scarring, including infants less than one year of age and all children who have systemic signs of infection concomitant with a UTI. Antibiotic prophylaxis is used in patients with reflux or recurrent UTI who are at greater risk for subsequent infections and complications.

## 15. References

- AAP. (1999). Practice parameter: the diagnosis, treatment, and evaluation of the initial urinary tract infection in febrile infants and young children. American Academy of Pediatrics. Committee on Quality Improvement. Subcommittee on Urinary Tract Infection. *Pediatrics*, Vol. 103, pp. 843-52, ISSN 0031-4005.
- Abrahamsson, K., Hansson, S., Jodal, U. & Lincoln, K. (1993). Staphylococcus saprophyticus urinary tract infections in children. *Eur J Pediatr*, Vol. 152, No. 1, pp. 69-71, ISSN 1432-1076.
- Ahmed, SM. (1996). Acute urinary tract infection in children, In: *Manual of Medical Therapeutics*, Rakel, RE. (Ed.), 547-9, Saunders, ISSN 0021-972X, Philadelphia, USA
- Andrich, MP., & Majd, M. (1992). Diagnostic imaging in the evaluation of the first urinary tract infection in infants and young children. *Pediatrics*, Vol. 90, No. 3, pp. 436-41, ISSN 0031-4005.
- Arant, BS Jr. (2001). Vesicoureteral reflux and evidence-based management. *J Pediatr*, Vol. 139, No. 5, pp. 620-1, ISSN 0022-3476.
- Baraff, LJ., Bass, JW., Fleisher, GR., Klein, JO., McCracken, GH., Powell, KR. & Schriger, DL. (1993). Practice guideline for the management of infants and children 0 to 36 months of age with fever without source. *Pediatrics*, Vol. 92, pp. 1-12, ISSN 0031-4005.
- Batisky, D. (1996). Pediatric urinary tract infections. *Pediatr Ann*, Vol. 25, No. 266, pp. 269-76, ISSN 0090-4481.
- Benador, D., Benador, N., Slosman, D., Mermillod, B., & Girardin, E. (1997). Are younger children at highest risk of renal sequelae after pyelonephritis? *Lancet* Vol. 349, pp. 17-19, ISSN 0140-6736.
- Berman, S. (1991). Urinary tract infection, In: *Pediatric Decision Making*, Berman, S. (Ed.), 204-7, Decker, ISBN 1556641419, Philadelphia, USA
- Bircan, ZE., Buyan, N., Hasanoglu, E., Ozturk, E., Bayhan, HI. & Sik, S. (1995). Radiologic evaluation of urinary tract infection. *Int Urol Nephrol*, Vol. 27, No. 1, pp. 27-32, ISSN 0301-1623.
- Bloomfield, P., Hodson, EM. & Craig, JC. (2005). Antibiotics for acute pyelonephritis in children. *Cochrane Database Syst Rev*, Vol. 25, No. 1, pp. CD003772, ISSN 1469-493X.
- Blumenthal, I. (1995). Vesico-ureteric reflux, urinary-tract infection, and renal damage in children. *Lancet*, Vol. 346, pp. 900, ISSN 0140-6736.
- Britton, KE. (1998). Renal radionuclide studies, In: *Textbook of Genitourinary Surgery*, Whitfield, HN., Hendry, WF., Kirby, RS., Duckett, W. (Eds), 76-103, Blackwell Science, ISSN 0042-1138, Oxford.

- Cavagnaro, F. (2005). Urinary tract infection in childhood. *Rev Chilena Infectol*, Vol. 22, No. 2, pp. 161-8, ISSN 0716-1018.
- Chen, JJ., Mao, W., Homayoon, K., & Steinhardt, GF. (2004). A multivariate analysis of dysfunctional elimination syndrome, and its relationships with gender, urinary tract infection and vesicoureteral reflux in children. *J Urol*, Vol. 171, pp. 1907-10, ISSN 0022-5347.
- Craig, JC., Knight, JF., Sureshkuman, P., Mantz, E. & Roy, LP. (1996). Effect of circumcision on incidence of urinary tract infection in preschool boys. *J Pediatr*, Vol. 128, no. 1, pp. 23-7, ISSN 0022-3476.
- Dayan, P S., Hanson, E., Bennett, JE., Langsam, D. & Miller, SZ. (2004). Clinical course of urinary tract infections in infants younger than 60 days of age. *Pediatr Emerg Care*, Vol. 20, pp. 85-88, ISSN 1535-1815.
- De Sadeleer, C., De Boe, V., Keuppens, F., Desprechins, B., Verboven, M. & Piepsz, A. (1994). How good is technetium-99m mercaptoacetyl triglycine indirect cystography? *Eur J Nucl Med*, Vol. 21, No. 3, pp. 223-7, ISSN 1619-7089.
- Deville, WL., Yzermans, JC., van Duijn, NP., Bezemer, PD., van der Windt, DA. & Bouter, LM. (2004). The urine dipstick test useful to rule out infections. A meta-analysis of the accuracy. *BMC Urol* Vol. 4, pp. 4, ISSN 1471-2490.
- Ditchfield, MR., de Campo, JF., Nolan, TM., Cook, DJ., Grimwood, K., Powell, HR., Sloane, R., Grimwood, K. & Cahill S.(1994). Risk factors in the development of early renal cortical defects in children with urinary tract infection. *AJR Am J Roentgenol*, Vol. 162, pp. 1393-7, ISSN 1546-3141.
- Ditchfield, MR. & Nadel, HR. (1998). The DMSA scan in paediatric urinary tract infection. *Australasian Radiol*, Vol. 42, pp. 318-20, ISSN 1440-1673.
- Ditchfield, M R., Grimwood, K., Cook, DJ., Powell, HR., Sloane, R., Nolan, TM. & de Campo, JF. (2002). Time course of transient cortical scintigraphic defects associated with acute pyelonephritis. *Pediatr Radiol*, Vol. 32, pp. 849-852, ISSN 1432-1998.
- Eggl, DF. & Tulchinsky, M. (1993). Scintigraphic evaluation of pediatric urinary tract infection. *Semin Nucl Med*, Vol. 23, pp. 199-218, ISSN 0001-2998.
- Esbjorner, E., Berg, U. & Hansson, S. (1997). Epidemiology of chronic renal failure in children: a report from Sweden 1986-1994. Swedish Pediatric Nephrology Association. *Pediatr Nephrol*, Vol. 11, pp. 438-442, ISSN 0931-041X.
- Feld, LG. (1991). Urinary tract infections in childhood: definition, pathogenesis, diagnosis, and management. *Pharmacotherapy*, Vol. 11, pp. 326-35, ISSN 1492-2525.
- Foxman, B. (2002). Epidemiology of urinary infections: incidence, morbidity, and economic costs. *Am J Med*, Vol. 8, No. 113 (Suppl), pp. 1A:5S-13S, ISSN 0002-9343.
- Fussell, EN., Kaack, MB., Cherry, R. & Roberts, JA. (1998). Adherence of bacteria to human foreskins. *J Urol*, Vol. 140. No. 5, pp. 997-1001, ISSN 0022-5347.
- Gacinovic, S., Buscombe, J., Costa, DC., Hilson, A., Bomanji, J. & Ell PJ. (1996). Interobserver agreement in the reporting of 99Tcm-DMSA renal studies. *Nuclear Med Commun*, Vol. 17, pp. 596-602, ISSN 1473-5628.
- Gordon, I. (1995). Vesico-ureteric reflux, urinary-tract infection, and renal damage in children. *Lancet*, Vol. 346, pp. 489-90, ISSN 0140-6736.
- Grady, R. (2003). Safety profile of quinolone antibiotics in the pediatric population. *Pediatr Infect Dis J*, Vol. 22, No. 12, pp. 1128-32, ISSN 1532-0987.

- Hansson, S., Martinell, J., Stokland, E. & Jodal, U. (1997). The natural history of bacteriuria in childhood. *Infect Dis Clin North Am*, Vol. 11, pp. 499-512, ISSN 0002-9343.
- Haycock, GB. (1991). A practical approach to evaluating urinary tract infection in children. *Pediatr Nephrol*, vol. 5, No. 4, pp. 401-2, ISSN 0931-041X.
- Hellerstein, S. (1994). Evolving concepts in the evaluation of the child with a urinary tract infection. *J Pediatr*, Vol. 124, pp. 589-92, ISSN 0022-3476.
- Hellerstein, S. (1995). Urinary tract infections. Old and new concepts. *Pediatr Clin North Am*, Vol. 42, No. 6, pp. 1433-57, ISSN 0031-4005.
- Hellerstein, S. (2002). Urinary tract infection in children: pathophysiology, risk factors and management. *Infect Med*, Vol. 19, pp. 554-60, ISSN 0749-6524.
- Helwig, H. (1994). Therapeutic strategies for urinary tract infections in children. *Infection*, Vol. 22(Suppl 1), pp. S12-3, ISSN 0300-8126.
- Hoberman, A., Chao, HP, Keller, DM, Hickey, R, Davis, HW. & Ellis, D. (1993). Prevalence of urinary tract infection in febrile infants. *J Pediatr*, Vol. 123, pp.:7-23, ISSN 0022-3476.
- Hoberman, A. & Wald, ER. (1997). Urinary tract infections in young febrile children. *Pediatr Infect Dis J*, Vol. 16, No. 1, pp. 11-7, ISSN 1532-0987.
- Hoberman, A., Charron, M., Hickey, RW., Baskin, M., Kearney, DH. & Wald, ER. (2003). Imaging studies after a first febrile urinary tract infection in young children. *N Engl J Med*, Vol. 348, pp. 195-202, ISSN 0028-4793.
- Huang, JJ., Sung, JM., Chen, KW., Ruaan, MK., Shu, GH. & Chuang, YC. (1992). Acute bacterial nephritis: a clinicoradiologic correlation based on computer tomography. *Am J Med*, Vol. 93, No. 3, pp. 289-98, ISSN 0002-9343.
- Huicho, L., Campos-Sanchez, M. & Alamo, C. (2002). Metaanalysis of urine screening tests for determining the risk of urinary tract infection in children. *Pediatr Infect Dis J*, Vol. 21, pp. 1-88, ISSN 1532-0987.
- Jacobson, SH., Eklof, O., Eriksson, CG., Lins, LE, Tidgren, B. & Winberg, J. (1989). Development of hypertension and uraemia after pyelonephritis in childhood: 27 year follow up. *Br Med J*, Vol. 299, pp. 703-706, ISSN 09598138.
- Jakobsson, B. & Svensson, L. (1997). Transient pyelonephritic changes on 99mTechnetium-dimercaptosuccinic acid scan for at least five months after infection. *Acta Paediatr*, Vol. 86, No. 8, pp. 803-7, ISSN 0803-5253.
- Jantausch, B. A., V. R. Criss, R. O'Donnell, B. L. Wiedermann, M. Majd, H. G. Rushton, R. S. Shirey, and N. L. Luban. 1994. Association of Lewis blood group phenotypes with urinary tract infection in children. *J. Pediatr*. 124:863-868.
- Jodal, U. (1987). The natural history of bacteriuria in childhood. *Infect Dis Clin North Am*, Vol. 1, No. 4, pp. 713-29, ISSN 0002-9343.
- Kass, EJ. (1994). Imaging in acute pyelonephritis. *Curr Opin Urol*, Vol. 4, pp. 39-44, ISSN 0963-0643.
- Kass, EJ., Kernen, KM. & Carey, JM. (2000). Paediatric urinary tract infection and the necessity of complete urological imaging. *BJU Int*, Vol. 86, No. 1, pp. 94-6, ISSN 1464-410X.
- Khan, AJ. (1994). Efficacy of single-dose therapy of urinary tract infection in infants and children: a review. *J Natl Med Assoc*, Vol. 86, No. 9, pp. 690-6, ISSN 0027- 9684.

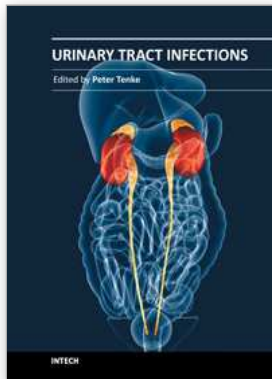
- Kibar, Y., Demir, E., Irkilata, HC., Ors, O., Gok, F. & Dayanc, M. (2007). Effect of biofeedback treatment on spinning top urethra in children with voiding dysfunction. *Urology*, Vol. 70, No. 4, pp. 781-4, ISSN 0090-4295.
- Kibar, Y., Ors, O., Demir, E., Kalman, S., Sakallioglu, O. & Dayanc, M. (2007). Results of biofeedback treatment on reflux resolution rates in children with dysfunctional voiding and vesicoureteral reflux. *Urology*, Vol. 70, No. 3, pp. 563-6, ISSN 0090-4295.
- Kibar, Y., Piskin, M., Irkilata, HC., Aydur, E., Gok, F. & Dayanc, M. (2009). Management of abnormal postvoid residual urine in children with dysfunctional voiding. *Urology*, Vol. 75, No. 6, pp. 1472-5, ISSN 0090-4295.
- Klein, JO. & Long, SS. (1995). Bacterial infections of the urinary tract, In: *Infectious Diseases of the Fetus and Newborn Infant*, Remington, JS., Klein, JO. (Eds.), 925-34, Saunders, ISSN 1058-4838, Philadelphia, USA
- Kleinman, PK., Diamond, BA., Karellas, A., Spevak, MR., Nimkin, K. & Belanger, P. (1994). Tailored low-dose fluoroscopic voiding cystourethrography for the reevaluation of vesicoureteral reflux in girls. *AJR Am J Roentgenol*, Vol. 162, No. 5, pp. 1151-6, ISSN 1546-3141.
- Koyle, MA., Barqawi, A., Wild, J., Passamaneck, M. & Furness, PD. (2003). Pediatric urinary tract infections: the role of fluoroquinolones. *Pediatr Infect Dis J*, Vol. 22, pp. 1133-37, ISSN 1532-0987.
- Ma, JF. & Shortliffe, LM. (2004). Urinary tract infection in children: etiology and epidemiology. *Urol Clin North Am*, Vol. 31, No. 3, pp. 517-26, ISSN 1063-5777.
- MacKenzie, JR., Fowler, K., Hollman, AS., Tappin, D., Murphy, AV., Beattie, TJ. & Azmy, AF. (1994). The value of ultrasound in the child with an acute urinary tract infection. *BJU Int*, Vol. 74, No. 2, pp. 240-4, ISSN 1464-410X.
- Mahant, S., To, T. & Friedman, J. (2001). Timing of voiding cystourethrogram in the investigation of urinary tract infections in children. *J Pediatr*, Vol. 139, pp. 568-71, ISSN 0022-3476.
- Majd, M. & Rushton, HG. (1992). Renal cortical scintigraphy in the diagnosis of acute pyelonephritis. *Semin Nuclear Med*, Vol. 22, pp. 98-111, ISSN 0001-2998.
- McDonald, A., Scranton, M., Gillespie, R., Mahajan, V. & Edwards, GA. (2000). Voiding cystourethrograms and urinary tract infections: how long to wait? *Pediatrics*, Vol. 105, No. 4, pp. E50, ISSN 0031-4005.
- Melis, K., Vandevivere, J., Hoskens, C., Vervaet, A., Sand, A. & Van Acker, KJ. Involvement of the renal parenchyma in acute urinary tract infection: the contribution of <sup>99m</sup>Tc dimercaptosuccinic acid scan. *Eur J Pediatr*, Vol. 151, No. 7, pp. 536-9, ISSN 1432-1076.
- Michael, M., Hodson, EM., Craig, JC., Martin, S. & Moyer, VA. (2003). Short versus standard duration oral antibiotic therapy for acute urinary tract infection in children. *Cochrane Database Syst Rev*, Vol. 1, pp. CD003966, ISSN 1469-493X.
- Mingin, GC., Hinds, A., Nguyen, HT. & Baskin, LS. (2004). Children with a febrile urinary tract infection and a negative radiologic workup: factors predictive of recurrence. *Urology*, Vol. 63, pp. 562-65, ISSN 0090-4295.
- Piaggio, G., Degl' Innocenti, ML., Toma, P., Calevo, MG. & Perfumo, F. (2003). Cystosonography and voiding cystourethrography in the diagnosis of

- vesicoureteral reflux. *Pediatr Nephrol*, Vol. 18, No. 1, pp. 18-22, ISSN 0931-041X.
- Pickworth, FE., Carlin, JB., Ditchfield, MR., de Campo, MP., de Campo, JF., Cook, DJ., Nolan, T., Powell, HR., Sloane, R. & Grimwood, K. (1995). Sonographic measurement of renal enlargement in children with acute pyelonephritis and time needed for resolution: implications for renal growth assessment. *AJR Am J Roentgenol*, Vol. 165, No. 2, pp. 405-8, ISSN 1546-3141.
- Polito, C., Rambaldi, PF., La Manna, A., Mansi, L. & Di Toro R. (2000). Enhanced detection of vesicoureteric reflux with isotopic cystography. *Pediatr Nephrol*, Vol. 14, pp. 827-830, ISSN 0931-041X.
- Richards, MJ., Edwards, JR., Culver, DH. & Gaynes, RP. (1999). Nosocomial infections in pediatric intensive care units in the United States. National Nosocomial Infections Surveillance System. *Pediatrics*, Vol. 103, No. 4, pp. e39, ISSN 0031-4005.
- Risdon, RA., Godley, ML., Parkhouse, HF., Gordon, I. & Ransley, PG. (1994). Renal pathology and the <sup>99m</sup>Tc-DMSA image during the evolution of the early pyelonephritic scar: an experimental study. *J Urol*, Vol. 151, No. 3, pp. 767-73, ISSN 0022-5347.
- Rushton, HG., Majd, M., Jantusch, B., Wiedermann, BL. & Belman, AB. (1992). Renal scarring following reflux and nonreflux pyelonephritis in children: evaluation with a <sup>99m</sup> technetium-dimercaptosuccinic acid scintigraphy. *J Urol*, Vol. 147, pp. 1327-32, ISSN 0022-5347.
- Rosenberg, AR., Rossleigh, MA., Brydon, MP., Bass, SJ., Leighton, DM. & Farnsworth, RH. Evaluation of acute urinary tract infection in children by dimercaptosuccinic acid scintigraphy: a prospective study. *J Urol*, Vol. 148, No. 5 Pt 2, pp. 1746-49, ISSN 0022-5347.
- Schoen, EJ. (1990). The status of circumcision of newborns. *N Engl J Med*, Vol. 322, pp. 1308-12, ISSN 0028-4793.
- Schulman, SL. (2004). Voiding dysfunction in children. *Urol Clin North Am*, Vol. 31, No. 3, pp. 481-90, ISSN 1063-5777.
- Shapiro, ED. (1992). Infections of the urinary tract. *Pediatr Infect Dis J*, Vol. 11, No. 2, pp. 165-8, ISSN 1532-0987.
- Shaw, KN., Gorelick, M., McGowan, K L., Yakscoe, NM. & Schwartz, JS. (1998). Prevalence of urinary tract infection in febrile young children in the emergency department. *Pediatrics*, Vol. 102, pp. e16, ISSN 0031-4005.
- Sheinfeld, J., A. J. Schaeffer, C. Cordon-Cardo, A. Rogatko, and W. R. Fair. 1989. Association of the Lewis blood-group phenotype with recurrent urinary tract infections in women. *N. Engl. J. Med.* 320:773-777.
- Shortliffe, LM. (1995). The management of urinary tract infections in children without urinary tract abnormalities. *Urol Clin North Am*, Vol. 22, pp. 67-73, ISSN 1063-5777.
- Slovis, TL. (1995). Is there a single most appropriate imaging workup of a child with an acute febrile urinary tract infection? *Pediatr Radiol*, Vol. 25 (Suppl 1), pp. S46-9, ISSN 1432-1998.



- Smellie, JM., Hodson, CJ., Edwards, D. & Normand, IC. (1964). Clinical and radiological features of urinary infection in childhood. *Br Med J*, Vol. 1, pp. 1222-26, ISSN 09598138.
- Smellie, JM., Gruneberg, RN., Bantock, HM. & Prescod, N. (1988). Prophylactic cotrimoxazole and trimethoprim in the management of urinary tract infection in children. *Pediatr Nephrol*, Vol. 2, No. 1, pp. 12-7, ISSN 0931-041X.
- Smellie, JM. (1995). The intravenous urogram in the detection and evaluation of renal damage following urinary tract infection. *Pediatr Nephrol*, Vol. 9, pp. 213-20, ISSN 0931-041X.
- Smellie, JM., Rigden, SP. & Prescod, NP. (1995). Urinary tract infection: a comparison of four methods of investigation. *Arch Dis Child*, Vol. 72, No. 3, pp. 247-50, ISSN 1743-0585.
- Smith, EM. & Elder, JS. (1994). Double antimicrobial prophylaxis in girls with breakthrough urinary tract infections. *Urology*, Vol. 43, pp. 708-13, ISSN 0090-4295.
- Sreenarasimhaiah, S. & Hellerstein, S. (1998). Urinary tract infections per se do not cause end-stage kidney disease. *Pediatr Nephrol*, Vol. 12, pp. 210-13, ISSN 0931-041X.
- Svanborg, C. & Godaly, G. (1997). Bacterial virulence in urinary tract infection. *Infect Dis Clin North Am*, Vol. 11, pp. 513-29, ISSN 0002-9343.
- To, T., Agha, M., Dick, PT. & Feldman, W. (1998). Cohort study on circumcision of newborn boys and subsequent risk of urinary-tract infection. *Lancet*, Vol. 352, No. 9143, pp. 1813-6, ISSN 0140-6736.
- Tran, D., Muchant, DG. & Aronoff, SC. (2001). Short-course versus conventional length antimicrobial therapy for uncomplicated lower urinary tract infections in children: a meta-analysis of 1279 patients. *J Pediatr*, Vol. 139, No. 1, pp. 93-9, ISSN 0022-3476.
- Wallin, L., Helin, I. & Bajc, M. (2001). Follow-up of acute pyelonephritis in children by Tc-99m DMSA scintigraphy: quantitative and qualitative assessment. *Clin Nuclear Med*, Vol. 26, pp. 423-32, ISSN 0363-9762.
- Wan, J., Kaplinsky, R. & Greenfield, S. (1995). Toilet habits of children evaluated for urinary tract infection. *J Urol*, Vol. 154, No. 2 Pt 2, pp. 797-9, ISSN 0022-5347.
- Watson, AR. (2004). Pediatric urinary tract infection. *EAU Update Series 2*, pp. 94-100, ISSN 1570-1924.
- Westwood, ME., Whiting, PF., Cooper, J., Watt, IS. & Kleijnen, J. (2005). Further investigation of confirmed urinary tract infection (UTI) in children under five years: a systematic review. *BMC Pediatr*, Vol. 5, No. 1, pp. 2, ISSN 1471-2431.
- Williams, DI. & Eckstein, HB. (1965). Surgical treatment of reflux in children. *BJU Int*, Vol. 37, pp. 13-24, ISSN 1464-410X.
- Yagci, S., Kibar, Y., Akay, O., Kilic, S., Erdemir, F., Gok, F. & Dayanc, M. (2005). The effect of biofeedback treatment on voiding and urodynamic parameters in children with voiding dysfunction. *J Urol*, Vol. 174, No. 5, pp. 1994-97, ISSN 0022-5347.
- Yeung, CK., Godley, ML., Dhillon, HK., Gordon, I., Duffy, PG. & Ransley, PG. (1997). The characteristics of primary vesico-ureteric reflux in male and female infants with pre-natal hydronephrosis. *BJU Int*, Vol. 80, No. 2, pp. 319-27, ISSN 1464-410X.

- Zelikovic, I., Adelman, RD. & Nancarrow, PA. (1992). Urinary tract infections in children. An update. *West J Med*, Vol. 157, pp. 554-61, ISSN 0093-0415.
- Zorc, JJ., Kiddoo, DA. & Shaw, KN. (2005). Diagnosis and management of pediatric urinary tract infections. *Clin Microbiol Rev*, Vol. 18, No. 2, pp. 417-22, ISSN 0893-8512.



## **Urinary Tract Infections**

Edited by Dr. Peter Tenke

ISBN 978-953-307-757-4

Hard cover, 360 pages

**Publisher** InTech

**Published online** 30, September, 2011

**Published in print edition** September, 2011

Urinary tract infections (UTIs) are among the most common bacterial infections worldwide, and they are also the leading cause of hospital-acquired infections. Therefore, the appropriate management of UTIs is a major medical and financial issue. This book covers different clinical manifestations of UTI, with special emphasis on some hard-to-treat diseases, and special conditions in respect of treatment; antibiotic resistance and the available alternative strategies for the prevention and treatment of UTIs and it deals with urinary tract infections in children. The aim of this book is to give a summary about the different aspects of the diagnosis, management and prevention of urinary tract infections for all medical disciplines.

### **How to reference**

In order to correctly reference this scholarly work, feel free to copy and paste the following:

Yusuf Kibar (2011). Current Management of Urinary Tract Infection in Children, Urinary Tract Infections, Dr. Peter Tenke (Ed.), ISBN: 978-953-307-757-4, InTech, Available from:  
<http://www.intechopen.com/books/urinary-tract-infections/current-management-of-urinary-tract-infection-in-children>

# **INTECH**

open science | open minds

### **InTech Europe**

University Campus STeP Ri  
Slavka Krautzeka 83/A  
51000 Rijeka, Croatia  
Phone: +385 (51) 770 447  
Fax: +385 (51) 686 166  
[www.intechopen.com](http://www.intechopen.com)

### **InTech China**

Unit 405, Office Block, Hotel Equatorial Shanghai  
No.65, Yan An Road (West), Shanghai, 200040, China  
中国上海市延安西路65号上海国际贵都大饭店办公楼405单元  
Phone: +86-21-62489820  
Fax: +86-21-62489821

© 2011 The Author(s). Licensee IntechOpen. This chapter is distributed under the terms of the [Creative Commons Attribution-NonCommercial-ShareAlike-3.0 License](#), which permits use, distribution and reproduction for non-commercial purposes, provided the original is properly cited and derivative works building on this content are distributed under the same license.