

Transthyretin Amyloidosis in Aged Vervet Monkeys, as a Candidate for the Spontaneous Animal Model of Senile Systemic Amyloidosis

Shinichiro Nakamura¹, Mitsuharu Ueda², Naohide Ageyama³,
Yukio Ando² and Ryuzo Torii¹

¹*Research Center for Animal Life Science, Shiga University of Medical Science,*

²*Department of Diagnostic Medicine, Graduate School of Medical Sciences,
Kumamoto University,*

³*Tsukuba Primate Research Center, National Institute of Biomedical Innovation,
Japan*

1. Introduction

Transthyretin (TTR) amyloidosis is classified into systemic senile amyloidosis (SSA), due to senescent events caused by the wild type TTR gene, and familial amyloidotic cardiomyopathy (FAC) and familial amyloidotic polyneuropathy (FAP), which are inherited diseases caused by mutant TTR genes (Ando et al., 2005; Buxbaum, 2009; Rapezzi et al., 2010). TTR is biochemically stable as a tetramer; however unstable as a monomer when the amyloid fibrillogenesis is higher (Damas et al., 2005). Non-fibrillar TTR deposits can be first detected immunohistochemically in the heart of humans with SSA, and finally in the peripheral nerves of those with FAP. After the non-fibrillar TTR deposits, congophilic and/or fibrillar amyloids consisting of TTR can be detected and are consistent with immunopositive lesions for TTR (Damas et al., 2005; Sousa et al., 2002).

Although animal models of SSA and FAP are strong tools to develop therapeutic agents and diagnostic materials, as well as to understand the pathomechanism (Buxbaum, 2009), spontaneous TTR amyloidosis has not yet been reported in animals. Therefore, a model has been developed using transgenic (Tg) techniques, such as Tg mice and rats with human mutant TTR genes (Buxbaum, 2009; Ueda et al., 2007). However, these model rodents do not show enough phenotypes resembling the clinical signs and histopathological features of SSA and FAP. In histopathological examinations, some Tg rodents tended to be hardly detected with fibrillar amyloid deposits, even if they reveal abundant non-fibrillar TTR immunoreactivity.

Nakamura et al. (2008) observed SSA in an aged vervet monkey that showed typical clinical symptoms and histopathological features, as well as the human form of SSA. Furthermore, another group followed up on our findings (Chambers et al., 2010). Both cases revealed not only non-fibrillar TTR immunoreactivity but also fibrillar amyloid deposits. Thus, since the vervet monkey shows more mature TTR amyloid formation than Tg rodents, it could be a novel animal model for TTR amyloidosis.

2. Animal models for TTR amyloidosis

2.1 Rodent models

The main strategy used to develop an animal model for TTR amyloidosis is to transfect mutant human TTR genes to mice because spontaneous TTR amyloidosis has not been reported in mammalian species before 2008 other than in humans. Because TTR is synthesized from hepatocytes, most Tg rodent lines are produced using the hepatocyte-specific metallothionein promoter (Karin et al., 1987). The first Tg mice, transfected with human V30M TTR (valine substituted for methionine at the human TTR 30 residue), expressed mutant TTR in the fetal liver and yolk sac (Yamamura et al., 1987) and showed significant increase in serum concentrations of a TTR variant (Sasaki et al., 1986) but failed to show TTR immunoreactivity or amyloid deposits. Yi et al. (1991) improved the next Tg mouse line, which they attempted to create by transfecting mice with an increased number of TTR V30M gene copies. This Tg line showed slight TTR amyloid deposition in the gastrointestinal and cardiovascular organs in 6-month-old mice, which revealed SSA-like systemic amyloid deposits at 24 months. Takaoka et al. (1997) inserted 0.6 kb or 6 kb fragments upstream of the V30M TTR gene. Tg mice with the 6-kb upstream insert showed a high enough concentration of human TTR in serum, corresponding with that in normal humans, but 10-fold greater than that in wild type-mice. An increasing TTR concentration was seen in 1-month-old animals with the 6-kb upstream insert, whereas TTR amyloid deposits appeared in the gastrointestinal tract of mice at 9 months and in their systemic organs at 21 months. In Tg mice with the 0.6-kb upstream insert, some amyloid deposits appeared at 15 months, particularly in the gastrointestinal tract. The density of the amyloid deposits in mice with the 6-kb upstream insert was more severe than in mice with the 0.6-kb insert. However, no TTR immunoreactivity or amyloid deposits were found in peripheral nerves of either mouse types.

Additional TTR Tg mice transfected with the human wild type TTR gene and an L55P mutant TTR gene (leucine substituted for proline at the human TTR 55 residue) were developed by Sousa and Teng et al. (Sousa et al., 2001; Teng et al., 2001). Mice with the L55P TTR mutant did not reveal amyloid deposition at 2.5 years because they had only one copy of the inserted gene. In contrast, mice with wild type TTR gene, which had 100 copies inserted, revealed amyloid deposits consisting of TTR in the heart, gastrointestinal tract, and kidneys at 18 months. Amyloid-affected male mice were more abundant than amyloid-affected female mice. Thus, the incidence and histopathological features mimicked human SSA. Furthermore, TTR immunoreactivity was observed in both females and males before the appearance of congophilic amyloid deposits formed, as the early stage of FAP (Sousa et al., 2002).

However, amyloid deposits in Tg mice are less frequently observed than in human SSA or FAP cases. Indeed, amyloid formation is inhibited by the human/mouse hybrid heterotetramer TTR in all Tg mice lines, which is extremely stable biochemically (Reixach et al., 2008; Tagoe et al., 2007). Human TTR immunoreactivity of amyloid deposits increased in interstitial tissues of a crossbreed between L55P TTR Tg and TTR null-mice due to decreased formation of the hybrid hetero-tetramer TTR (Tagoe et al., 2007).

An association between co-factors and TTR-amyloid formation in Tg mice is easy to confirm. Another line of crossbred mice (KO) was developed between L55P TTR Tg and heat shock factor protein 1 (HSF1), a TTR molecular chaperone protein in KO mice (Santos et al., 2010). These mice showed 2–3-fold more frequent amyloid deposits than in wild type TTR Tg mice and revealed TTR immunoreactivity not only in the cutaneous tissues and gastrointestinal system but also in the peripheral nerves at 3 months of age. The extra-neural tissue lesions developed further into congophilic amyloid deposits, whereas those in peripheral nerves

did not. TTR immunoreactivity in peripheral nerves is thought to be an early change prior to congophilic amyloid formation (Sousa et al., 2001).

A retinol-binding site occurs at residue 84 in the TTR amino acid sequence. TTR Tg mice with I84S (isoleucine substituted for serine at human TTR residue 84) failed to show any amyloid deposits (Waits et al., 1995).

According to the findings from these crossbred mice, strong overexpression of the mutant TTR gene is insufficient for TTR amyloid fibrogenesis. Amyloid formation increase in V30M TTR Tg mice were maintained under standard conditions but not under specific pathogen-free conditions (Inoue et al., 2008; Noguchi et al., 2002), suggesting that microbiological conditions and consequent immunological events are closely associated with amyloid formation. Amyloid formation is required not only for misfolding of the precursor proteins but also other factors including microbiological exposure to the immune system (Muchowski, 2002; Noguchi et al., 2002). Moreover, possible associations with chaperone proteins, such as amyloid P component, apolipoprotein E, and HSF1 should also be considered (Nakamura et al., 2008; Santos et al., 2010; Wood et al., 2005).

Other than Tg rodents, amyloid deposits consisting of mouse endogenous TTR have been found in senescence-accelerated mice, but this is supported by only one spontaneous report of TTR amyloidosis in rodents (Higuchi et al., 1991), although the strain in this report possessed a unique genetic background. Ueda et al. (2007) reported a TTR Tg rat transfected with V30M TTR that was TTR immunoreactive but did not have congophilic amyloid deposition in the gastrointestinal tract.

2.2 Nonhuman primate models

TTR amyloidosis has been reported in two male vervet monkeys (Table 1, cases 3 and 5) (Chambers et al., 2010; Nakamura et al., 2008), and we obtained one additional aged male case (Table 1, case 4) that revealed TTR amyloid deposits (data not shown). The remaining four monkeys (Table 1, cases 1, 2, 6, and 7) were examined histopathologically but did not contain amyloid deposits. Although all positive cases were males (similar to human SSA findings), understanding the epidemiological aspects of the disease is expected with additional cases. A characteristic symptom in case 5, mimicking human SSA, was an arrhythmia detected by electrocardiography (Fig. 1), whereas the SSA characteristics were confirmed by gross and histopathological findings in case 3. In both cases, the hearts revealed dilatation of both ventricles at necropsy, but the dilatation in case 3 was more severe than in case 5. In contrast, the histopathological density of amyloid deposits was more severe in case 5 than in case 3. The most severe amyloid deposits were observed in the heart of case 5. Myocardium and stroma were multifocally replaced by hyaline deposits as amyloid. The amyloid deposits were further found in the thyroid gland, tonsils, salivary glands, trachea, esophagus, thymus, lungs, gastrointestinal organs, kidneys, prostate gland, urinary bladder, lymph nodes, and skeletal muscle. In case 3, amyloid deposits were observed not only in the heart, gastrointestinal tract, liver, spleen, and kidneys, but also in the tenosynovium tissues, which were grossly hemorrhaged. These amyloid deposits are resistant to potassium permanganate, show apple green birefringence under a polarizing microscope (Fig. 2), and are TTR immunopositive (Fig. 3). Although most amyloid deposits in vervet monkeys are consistent with TTR immunoreactivity, TTR immunopositivity without congophilic amyloids was observed only in the testes of case 5. These were thought to be non-fibrillar precursor amyloid deposits that occur prior to congophilic amyloid deposits (Sousa et al., 2001; Teng et al., 2001).

Case No.	Age (Year)	Sex *	Facility **	Cause of death ***	TTR-amyloid deposits
1	17	F	E	Uterine myoma	-
2	25	M	E	Cardiac failure	-
3	26	M	Z	Cardiac failure	+
4	27	M	E	Thoracic tumor	+
5	29	M	E	Cardiac failure	+
6	>30	F	E	ND	-
7	>30	F	Z	ND	-

*: F; Female, M; Male

** : E; Experimental Animal Facility, Z; Zoo

***: ND; Not determined

+: Positive

-: Negative

Table 1. Profiles of postmortem specimen of aged vervet monkey.

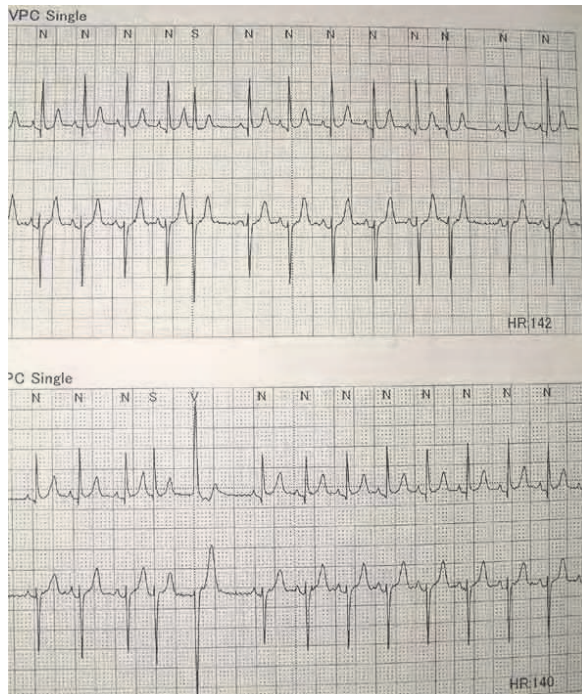


Fig. 1. Arrhythmia detected by electrocardiography in case 5.

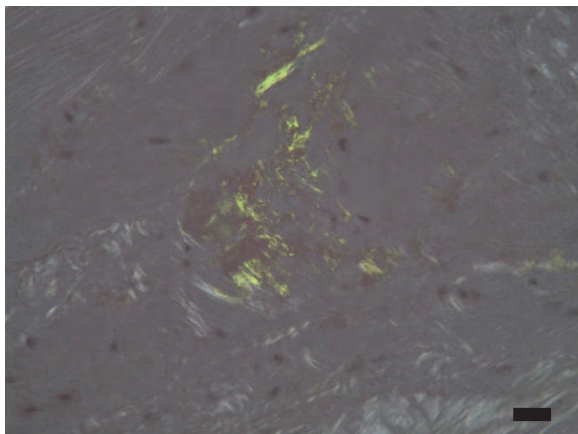


Fig. 2. Apple green birefringence was observed under a polarizing microscope in the heart of case 5; Congo red staining; bar, 25 μm .

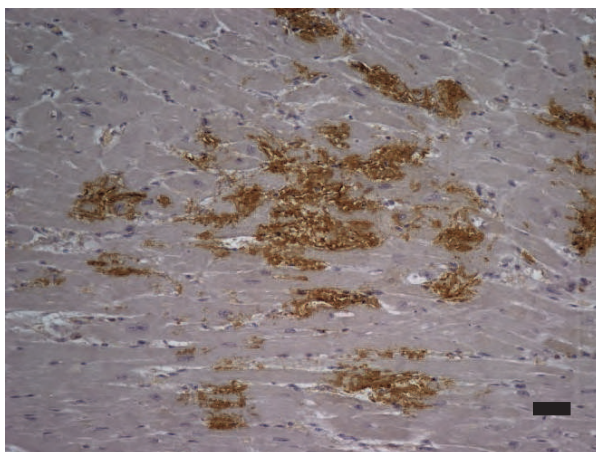


Fig. 3. Transthyretin (TTR) immunoreactivity in the heart of case 5; TTR immunostain; bar, 50 μm .

We observed seven vervet monkey cases (Table 1; average age, 26.3 ± 1.71 years; range, 17–30 years). Three of the four males were positive for amyloid deposits, whereas all three females were negative. The incidence of TTR in aged male monkeys seems to be very high and reflects the features of human SSA (Rapezzi et al., 2010). In contrast, 42 cynomolgus monkeys (*Macaca fascicularis*; average age, 18.5 ± 1.33 years; range, 4–36 years) failed to show any TTR immunoreactivity or amyloid deposits in heart specimens (data not shown).

Both vervet and cynomolgus monkeys belong to Cercopithecoidea, and they have a close evolutionary relationship. However, the onset of TTR amyloidosis differs, which may be due to differences in amino acid sequences. The TTR amino acid sequence in nonhuman

primates has been clarified in the chimpanzee (*Pan troglodytes*, AAV41026; Nadezhdin et al., 2001), orangutan (*Pongo abelii*, CAI29591), cynomolgus monkey (BAC20609), rhesus monkey (*Macaca mulatta*, XP_001099005), common marmoset (*Callithrix jacchus*, XP_002757195), and Bolivian squirrel monkey (*Saimiri boliviensis*, AAV74285) (Fig. 4). Homologies between human and nonhuman primate TTRs (including the signal peptide) are 97.3% with chimpanzee, 95.2% with orangutan, 93.9% with cynomolgus monkey, 93.2% with rhesus monkey, and 78.9% with the common marmoset and Bolivian squirrel monkey. The lower homology with New world monkeys (marmoset and squirrel monkey) is due to a deletion of four to six residues and some TTR N-terminal substitutions. The homology of human and mouse TTRs is 81.0%. Although human FAP is induced by an amino acid substitution, major residues with substitution in FAP (residues at 30, 33, 45, 53, 55, 60, 69, 77, 84, 88, 111, and 122) (Rapezzi et al., 2010) are conserved as human wild type in nonhuman primate species. The TTR amino acid sequence in vervet monkeys is expected to be clarified and is predicted to be very similar to cynomolgus and rhesus monkeys because they are very closely related species, belonging to Cercopithecoidea. However, substitution at the mutated residue position in FAP is predicted in vervet monkeys.

		Signal peptide																																										
		20	19	18	17	16	15	14	13	12	11	10	9	8	7	6	5	4	3	2	1	1	2	3	4	5	6	7	8	9	10	11	12	13	14	15	16	17	18	19				
Human	M A S H R L L L L L L C L A G L V F V S E A																					G P T G T G E S K C P L M V K V L D A																						
Chimpanzee	M A S H R L L L L L L C L A G L V F V S E A																					G P T G T G E S K C P L M V K V L D A																						
Orangutan	M A S H R L L L L L L C L A G L V F V S E A																					G P T G A G E S K C P L M V K V L D A																						
Cynomolgus monkey	M A S H R L L L L L L C L A G L V F V S E A																					G P T G V D E S K C P L M V K V L D A																						
Rhesus monkey	M A S H R L L L L L L C L A G L V F V S E A																					G P T G V D E S K C P L M V K V L D A																						
Marmoset	M A S H R L L L L L L C L A G L V F V S E A																					G P T - - - G Y S C P L M V K V L D A																						
Bolivian squirrel monkey	M A S H R L L L L L L C L A G L V F V S E A																					G H T - - - G Y S C P L M V K V L D A																						
Mouse	M A S L R L F L L L C L A G L V F V S E A																					G P A G A G E S K C P L M V K V L D A																						
Human	R G S P A I N V A V H V F R K A A D D T W E P P F A S G K T S E S G E L H G L T T	21	22	23	24	25	26	27	28	29	30	31	32	33	34	35	36	37	38	39	40	41	42	43	44	45	46	47	48	49	50	51	52	53	54	55	56	57	58	59	60			
Chimpanzee	R G S P A I N V A V H V F R K A A D D T W E P P F A S G K T S E S G E L H G L T T																																											
Orangutan	R G S P A V N V A V N V F K R A A D E T W E P P F A S G K T S E S G E L H G L T T																																											
Cynomolgus monkey	R G S P A V N V A V N V F K K A A D E T W A P P F A S G K T S E S G E L H G L T T																																											
Rhesus monkey	R G S P A V N V A V N V F K K A A D E T W A P P F A S G K T S E S G E L H G L T T																																											
Marmoset	Q G R P A V N V A V S V F K K A A D E T W E P P F A F G K T S E S G E L H G L T T																																											
Bolivian squirrel monkey	Q G R P A I N V A V S V F K K A A D E T W E P P F A L G K T S E S G E L H G L T T																																											
Mouse	R G S P A V D V A V K V F K K T S E G S W E P P F A S G K T A E S G E L H G L T T																																											
Human	E E F V E G I Y K V E I D T K S Y W K A L G I S P P F H E H A E V V F T A N D S	61	62	63	64	65	66	67	68	69	70	71	72	73	74	75	76	77	78	79	80	81	82	83	84	85	86	87	88	89	90	91	92	93	94	95	96	97	98	99	100			
Chimpanzee	E E F V E G I Y K V E I D T K S Y W K A L G I S P P F H E H A E V V F T A N D S																																											
Orangutan	E E F V E G I Y K V E I D T K S Y W K A L G I S P P F H E H A E V V F A N D S																																											
Cynomolgus monkey	E E F V E G I Y K V E I D T K S Y W K S L G I S P P F H E H A E V V F T A N D S																																											
Rhesus monkey	E E F V E G I Y K V E I D T K S Y W K S L G I S P P F H E H A E V V F T A N D S																																											
Marmoset	E E K F V K G V Y K V E I N S K S Y W H T L G I T S P F H E H A D V V F T A N D S																																											
Bolivian squirrel monkey	E E K F V K G I Y K V E I D S K S Y W H N L G I A S F H E H A D V V F A N E S																																											
Mouse	D E K F V E G V Y R V E I D T K S Y W K T L G I S P P F H E F A D V V F T A N D S																																											
Human	G P R R Y T I A A L L S P Y S Y S T A V V T N P K E	101	102	103	104	105	106	107	108	109	110	111	112	113	114	115	116	117	118	119	120	121	122	123	124	125	126	127	Homology (%)															
Chimpanzee	G P R R Y T I A A L L S P Y S Y S T A V V T N P K E																												100.0															
Orangutan	G P R R Y T I A A L L S P Y S Y S T A V V T N P K E																												97.3															
Cynomolgus monkey	G P R H Y T I A A L L S P Y S Y S T A V V T N P K E																												95.2															
Rhesus monkey	G P R H Y T I A A L L S P Y S Y S T A V V T N P K E																												93.9															
Marmoset	G P R H Y I V A A L L S P Y S Y S T A V V S D P P R K																												93.2															
Bolivian squirrel monkey	G P R H Y I V A A L L S P Y S Y S T A V V S D P P K N																												78.9															
Mouse	G H R H Y T I A A L L S P Y S Y S T A V V S N P Q N																												78.9															
Mouse	G H R H Y T I A A L L S P Y S Y S T A V V S N P Q N																												81.0															

Fig. 4. Amino acid sequences of TTR in nonhuman primate species, as compared with that in human and mice.

3. Discussion and conclusion

At present, animal models for TTR amyloidosis are restricted to Tg rodents and vervet monkeys. The vervet monkey more obviously reflects the clinical symptoms and histopathological features of human SAA compared to those of TTR Tg mice (Nakamura et al., 2008), as some Tg mice lines do not reveal sufficient congophilic amyloid deposits. Because mice do not show spontaneous TTR amyloidosis but form extensive amyloid deposits following transfection with the human wild type or mutant TTR genes, the higher homology of TTR with humans may be important. Thus, the TTR amino acid sequence is key for primary amyloid formation. However, even if mutant TTR genes are strongly expressed in mice, amyloid formation has not been found in the peripheral nerves of any TTR Tg mice lines. Vervet monkeys also do not form TTR amyloid deposits in peripheral nerves, even if abundant TTR amyloid is deposited in extra-neural organs. Amyloid deposition of TTR in peripheral nerves is exclusively a human phenomenon, observed as terminal TTR amyloidosis lesions. Namely, other factors, such as molecular chaperones, immunological events, and time are required for development of TTR amyloidosis lesions prior to deposits in peripheral nerves.

For example, differences between human and animals are well known in animal models of Alzheimer's disease (AD). Senile plaques (SPs), consisting of amyloid protein ($A\beta$) and amyloid formation, are found in various mammalian species other than rodents (Selkoe et al., 1987), whereas neurofibrillary tangles (NFTs), consisting of phosphorylated tau, are found mostly in humans. In general, SPs appear first and NFTs appear consequently in the brain during the development of AD pathology. In mammalian species other than humans, the formation of NFTs is restricted to very old macaque monkeys (Oikawa et al., 2010). The $A\beta$ amino acid sequence is completely homologous between humans and most mammalian species but not in rodents (Selkoe et al., 1987), and SPs can be found in various mammalian species. Furthermore, Tg mice transfected with mutant $A\beta$ precursor protein (APP) show well developed SP formation but little or only slight formation of NFTs, whereas double Tg mice lines with APP and one of some other factors, such as presenilin-1, also form NFTs (Ashe et al., 2010). Thus, the formation of NFTs at the later stage of AD pathology is a phenomenon particular to humans, and not only $A\beta$ amino acid sequence homology but also some other factors are required to develop NFTs in mammalian species.

When animals develop the pathological changes of TTR and $A\beta$ amyloidosis, the lesions seem to stop developing at the middle period before reaching the terminal period, as in humans. Unfortunately, the factors participating as thresholds for the onset of these diseases are unknown. Absolute time, amino acid sequence, the presence of molecular chaperones, and other factors may lead to these differences between humans and animals. Of these factors, life span is easy to understand. The longest lived cynomolgus monkey was 36 years (Oikawa et al., 2010), which is less than one-third of the longest lived human. More importantly, how a long term event that occurs in humans is shortened by model animals may be very difficult to ascertain.

TTR Tg mice are useful for basic *in vivo* studies, whereas aged male vervet monkeys are useful for developing novel therapeutic chemicals and diagnostic materials in preclinical studies. Vervet monkeys have often been used to provide red blood cells for the measles hemagglutination inhibition test. However, the number of captive vervet monkeys is decreasing in Japan because of new diagnostic methods for measles (Fujino et al., 2007). Although there is a US primate center with a vervet monkey colony

(http://www.ncrr.nih.gov/comparative_medicine/resource_directory/primates.asp#verv), funds are insufficient for maintaining such a huge facility in Japan. Shimozawa et al. (2010) developed embryonic stem cells from a vervet monkey, which may help reproduce them in the future. Now, captive vervet monkeys possess a novel raison d'être under the field of biomedical science based on characteristics similar to human SSA. Here, we propose vervet monkeys as a novel biomedical science resource that will contribute to understanding TTR amyloidosis.

4. Acknowledgment


We thank Dr. Yumi Une and Dr. James Kenn Chambers for providing some of the vervet monkey cases.

5. References

- Ashe, KH. & Zahs, KR. (2010). Probing the biology of Alzheimer's disease in mice. *Neuron*, Vol.66, No.5, pp. 631-645, ISSN 0896-6273
- Ando, Y., Nakamura, M. & Araki, S., (2005). Transthyretin-related familial amyloidotic polyneuropathy. *Arch Neurol*, Vol.62, No.7, pp. 1057-1062, ISSN 0003-9942
- Buxbaum, JN. (2009). Animal models of human amyloidosis: Are transgenic mice worth the time and trouble? *FEBS Lett*, Vol.583, No.16, pp. 2663-2673, ISSN 0014-5793
- Chambers, JK., Kanda, T., Shirai, A., Higuchi, K., Ikeda, S. & Une, Y. (2010). Senile systemic amyloidosis in an aged savannah monkey (*Cercopithecus aethiops*) with tenosynovial degeneration. *J Vet Med Sci*, Vol.72, No.5, pp. 657-659, ISSN 0916-7250
- Damas, AM. & Saraiva, MJ. (2005). *Transthyretin*, In: *Amyloid proteins*, Sipe JD. (Ed), pp. 571-588, WILEY-VCH, ISBN 3-527-31072-X, Weinheim, Germany
- Fujino, M., Yoshida, N., Kimura, K., Zhou, J., Motegi, Y., Komase, K. & Nakayama, T. (2007). Development of a new neutralization test for measles virus. *J Virol Methods*, Vol.142, No.1-2, pp. 15-20, ISSN 0166-0934
- Higuchi, K., Naiki, H., Kitagawa, K., Hosokawa, M. & Takeda, T. (1991). Mouse senile amyloidosis. ASSAM amyloidosis in mice presents universally as a systemic age-associated amyloidosis. *Virchows Arch B Cell Pathol Incl Mol Pathol*, Vol.60, No.4, pp. 231-238, ISSN 0340-6075
- Inoue, S., Ohta, M., Li, Z., Zhao, G., Takaoka, Y., Sakashita, N., Miyakawa, K., Takada, K., Tei, H., Suzuki, M., Masuoka, M., Sakaki, Y., Takahashi, K. & Yamamura K. (2008). Specific pathogen free conditions prevent transthyretin amyloidosis in mouse models. *Transgenic Res*, Vol.17, No.5, pp. 817-826, ISSN 0962-8819
- Karin, M., Haslinger, A., Heguy, A., Dietlin, T. & Imbra, R. (1987). Transcriptional control mechanisms which regulate the expression of human metallothionein genes. *Experientia Suppl*, Vol.52, pp. 401-405, ISSN 0071-335X
- Muchowski, PJ. (2002). Protein Misfolding, Amyloid Formation, and Neurodegeneration: A Critical Role for Molecular Chaperones? *Neuron*, Vol.35, No.1, pp. 9-12, ISSN 0896-6273
- Nadezhdin, EV., Vinogradova, TV. & Sverdlov, ED. (2001). Interspecies subtractive hybridization of cDNA from human and chimpanzee brains. *Dokl Biochem Biophys*, Vol.381, No.5, pp. 415-418, ISSN 1607-6729

- Nakamura, S., Okabayashi, S., Ageyama, N., Koie, H., Sankai, T., Ono, F., Fujimoto, K. & Terao, K. (2008). Transthyretin amyloidosis and two other aging-related amyloidoses in an aged vervet monkey. *Vet Pathol*, Vol.45, No.1, pp. 67-72, ISSN 0300-9858
- Noguchi, H., Ohta, M., Wakasugi, S., Noguchi, K., Nakamura, N., Nakamura, O., Miyakawa, K., Takeya, M., Suzuki, M., Nakagata, N., Urano, T., Ono, T. & Yamamura, K. (2002). Effect of the intestinal flora on amyloid deposition in a transgenic mouse model of familial amyloidotic polyneuropathy. *Exp Anim*, Vol.51, No.4, pp. 309-316, ISSN 1341-1357
- Oikawa, N., Kimura, N. & Yanagisawa, K. (2010). Alzheimer-type tau pathology in advanced aged nonhuman primate brains harboring substantial amyloid deposition. *Brain Res*, Vol.1315, No.22, pp. 137-149, ISSN 0006-8993
- Rapezzi, C., Quarta, CC., Riva, L., Longhi, S., Gallelli, I., Lorenzini, M., Ciliberti, P., Biagini, E., Salvi, F. & Branzi, A., (2010). Transthyretin-related amyloidoses and the heart: a clinical overview. *Nat Rev Cardiol*, Vol.7, No.7, pp. 398-408, ISSN 1759-5002
- Reixach, N., Foss, TR., Santelli, E., Pascual, J., Kelly, JW. & Buxbaum, JN., (2008). Human-murine transthyretin heterotetramers are kinetically stable and non-amyloidogenic. A lesson in the generation of transgenic models of diseases involving oligomeric proteins. *J Biol Chem*, Vol.283, No.4, pp. 2098-2107, ISSN 0021-9258
- Santos, SD., Fernandes, R. & Saraiva, MJ., (2010). The heat shock response modulates transthyretin deposition in the peripheral and autonomic nervous systems. *Neurobiol Aging*, Vol.31, No.2, pp. 280-289, ISSN 0197-4580
- Sasaki, H., Tone, S., Nakazato, M., Yoshioka, K., Matsuo, H., Kato, Y. & Sakaki Y. (1986). Generation of transgenic mice producing a human transthyretin variant: a possible mouse model for familial amyloidotic polyneuropathy. *Biochem Biophys Res Commun*, Vol.139, No.2, pp. 794-799, ISSN 0006-291X
- Selkoe, DJ., Bell, DS., Podlisy, MB., Price, DL. & Cork, LC. (1987). Conservation of brain amyloid proteins in aged mammals and humans with Alzheimer's disease. *Science*, Vol.235, No.4791, pp. 873-877, ISSN 1095-9203
- Shimozawa, N., Nakamura, S., Takahashi I, Hatori, M. & Sankai, T. (2010). Characterization of a novel embryonic stem cell line from an ICSI-derived blastocyst in the African green monkey. *Reproduction*, Vol.139, No.3, pp. 565-573, ISSN 1470-1626
- Sousa, MM., Cardoso, I., Fernandes, R., Guimarães, A. & Saraiva, MJ. (2001). Deposition of transthyretin in early stages of familial amyloidotic polyneuropathy: evidence for toxicity of nonfibrillar aggregates. *Am J Pathol*, Vol.159, No.6, pp. 1993-2000, ISSN 0002-9440
- Sousa, MM., Fernandes, R., Palha, JA., Taboada, A., Vieira, P. & Saraiva, MJ. (2002). Evidence for early cytotoxic aggregates in transgenic mice for human transthyretin Leu55Pro. *Am J Pathol*, Vol.161, No.5, pp. 1935-1948, ISSN 0002-9440
- Tagoe, CE., Reixach, N., Friske, L., Mustra, D., French, D., Gallo, G. & Buxbaum, JN. (2007). In vivo stabilization of mutant human transthyretin in transgenic mice. *Amyloid*, Vol.14, No.3, pp. 227-236, ISSN 1350-6129
- Takaoka, Y., Tashiro, F., Yi, S., Maeda, S., Shimada, K., Takahashi, K., Sakaki, Y. & Yamamura K. (1997). Comparison of amyloid deposition in two lines of transgenic mouse that model familial amyloidotic polyneuropathy, type I. *Transgenic Res*, Vol.6, No.4, pp. 261-269, ISSN 0962-8819

- Teng, MH., Yin, JY., Vidal, R., Ghiso, J., Kumar, A., Rabenou, R., Shah, A., Jacobson, DR., Tagoe, C., Gallo, G. & Buxbaum, J. (2001). Amyloid and nonfibrillar deposits in mice transgenic for wild-type human transthyretin: a possible model for senile systemic amyloidosis. *Lab Invest*, Vol.81, No.3, pp. 385-396, ISSN 0023-6837
- Ueda, M., Ando, Y., Hakamata, Y., Nakamura, M., Yamashita, T., Obayashi, K., Himeno, S., Inoue, S., Sato, Y., Kaneko, T., Takamune, N., Misumi, S., Shoji, S., Uchino, M. & Kobayashi, E. (2007). A transgenic rat with the human ATTR V30M: a novel tool for analyses of ATTR metabolisms. *Biochem Biophys Res Commun*, Vol.352, No.2, pp. 299-304, ISSN 0006-291X
- Waits, RP., Uemichi, T., Zeldenrust, SR., Hull, MT., Field, L. & Benson, MD., (1995). Development of lines of transgenic mice expressing the human transthyretin Ser 84 variant, In Proc III Int. Symp. FAP and other TTR Disorders, Vol.6, pp. S31
- Wood, SP. & Coker, AR. (2005). Serum amyloid P component - structural fetures and amyloid recognition, In: Amyloid proteins, Sipe JD. (Ed). pp. 189-209, WILEY-VCH, ISBN 3-527-31072-X, Weinheim, Germany.
- Yamamura, K., Wakasugi, S., Maeda, S., Inomoto, T., Iwanaga, T., Uehira, M., Araki, K., Miyazaki, J. & Shimada, K. (1987). Tissue-specific and developmental expression of human transthyretin gene in transgenic mice. *Dev Genet*, Vol.8, No.4, pp. 195-205, ISSN 0192-253X
- Yi, S., Takahashi, K., Naito, M., Tashiro, F., Wakasugi, S., Maeda, S., Shimada, K., Yamamura, K. & Araki, S. (1991). Systemic amyloidosis in transgenic mice carrying the human mutant transthyretin (Met30) gene. Pathologic similarity to human familial amyloidotic polyneuropathy, type I. *Am J Pathol*, Vol.138, No.2, pp. 403-412, ISSN 0002-9440



Amyloidosis - Mechanisms and Prospects for Therapy

Edited by Dr. Svetlana Sarantseva

ISBN 978-953-307-253-1

Hard cover, 216 pages

Publisher InTech

Published online 22, September, 2011

Published in print edition September, 2011

Amyloidoses are a heterogeneous group of diverse etiology diseases. They are characterized by an endogenous production of abnormal proteins called amyloid proteins, which are not hydrosoluble, form depots in various organs and tissue of animals and humans and cause dysfunctions. Despite many decades of research, the origin of the pathogenesis and the molecular determinants involved in amyloid diseases has remained elusive. At present, there is not an effective treatment to prevent protein misfolding in these amyloid diseases. The aim of this book is to present an overview of different aspects of amyloidoses from basic mechanisms and diagnosis to latest advancements in treatment.

How to reference

In order to correctly reference this scholarly work, feel free to copy and paste the following:

Shinichiro Nakamura, Mitsuharu Ueda, Naohide Ageyama, Yukio Ando and Ryuzo Torii (2011). Transthyretin Amyloidosis in Aged Vervet Monkeys, as a Candidate for the Spontaneous Animal Model of Senile Systemic Amyloidosis, *Amyloidosis - Mechanisms and Prospects for Therapy*, Dr. Svetlana Sarantseva (Ed.), ISBN: 978-953-307-253-1, InTech, Available from: <http://www.intechopen.com/books/amyloidosis-mechanisms-and-prospects-for-therapy/transthyretin-amyloidosis-in-aged-vervet-monkeys-as-a-candidate-for-the-spontaneous-animal-model-of->

INTECH

open science | open minds

InTech Europe

University Campus STeP Ri
Slavka Krautzeka 83/A
51000 Rijeka, Croatia
Phone: +385 (51) 770 447
Fax: +385 (51) 686 166
www.intechopen.com

InTech China

Unit 405, Office Block, Hotel Equatorial Shanghai
No.65, Yan An Road (West), Shanghai, 200040, China
中国上海市延安西路65号上海国际贵都大饭店办公楼405单元
Phone: +86-21-62489820
Fax: +86-21-62489821

© 2011 The Author(s). Licensee IntechOpen. This chapter is distributed under the terms of the [Creative Commons Attribution-NonCommercial-ShareAlike-3.0 License](#), which permits use, distribution and reproduction for non-commercial purposes, provided the original is properly cited and derivative works building on this content are distributed under the same license.