

The Anatomy and Physiology of the Healthy Periodontium

Anthony Palumbo
Stony Brook University
USA

1. Introduction

The anatomy and physiology of the healthy periodontium will be described in its relationship to the natural dentition, jaws, and the oral environment. The periodontium serves as the supporting apparatus for the teeth in function and in occlusal relationships. It consists of the alveolar mucosa, gingiva, cementum, periodontal ligament, and alveolar bone. The embryonic origin, composition, and histological and clinical appearance with normal physiologic variations are presented in order to facilitate an understanding of their relationships in health and to understand the processes that occur in pathology. This will include macroscopic, microscopic, and radiographic details of the components of the periodontium. The knowledge of the details of the tissue compartments, the cells which are involved, and how the cellular products and the cells interact will provide a greater understanding of the functional operation of the periodontium. The response to aging and the normal maturation of the periodontium will also be discussed in relation to its macroscopic, microscopic, and radiographic changes to enhance the appreciation of the changes in the appearance, properties, and responses to functional and physiologic stimuli. A thorough understanding of the components that form the supporting structures of the teeth will provide the necessary starting point from which to establish an appreciation of the interactive and adaptive nature of the system as well as a reference point of how the periodontium changes when pathologic, normal and excessive physiologic, and inflammatory stimuli stress the components.

2. Macroscopic appearance of the periodontium

The periodontium is composed of the gingiva, alveolar mucosa, cementum, periodontal ligament, and alveolar bone (Fig. 1). These components serve to support the teeth in their alveolar bone. The tissues typically seen on clinical inspection are only those of the oral mucosa. The oral mucosa can be divided into three types: the masticatory, lining, and specialized mucosa. The gingiva is firmly bound to the underlying bone and is continuous with the alveolar mucosa that is situated apically and is unbound. The border of these two tissue types is clearly demarcated and is called the mucogingival junction. There is no mucogingival junction on the palatal aspect of the maxilla as the gingiva is continuous with the palatal mucosa. The gingiva consists of a free gingival margin and attached gingiva. The free gingival margin is situated about 2mm coronal to the cemento-enamel junction of the tooth and the attached gingiva extends from the base of the free gingiva to the mucogingival

junction (Ainamo and Loe 1966). The gingiva is typically coral pink in color, but may vary due to physiologic pigmentation among some races, whereas the alveolar mucosa is deep red in color (Fig2a/b).

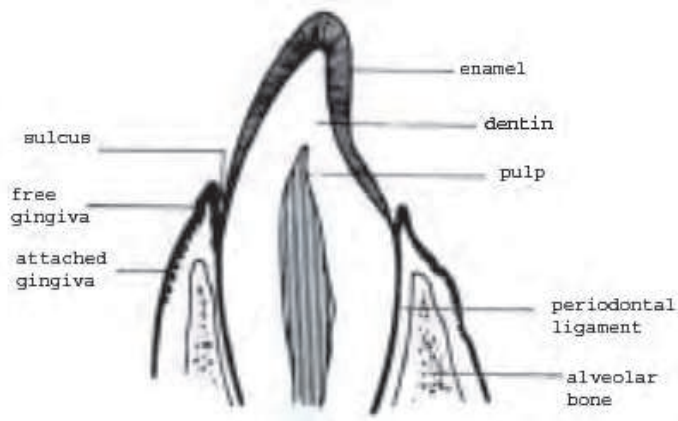
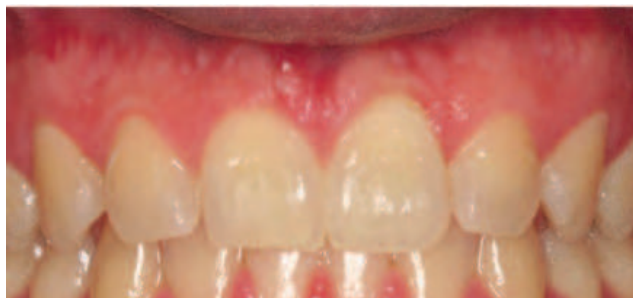
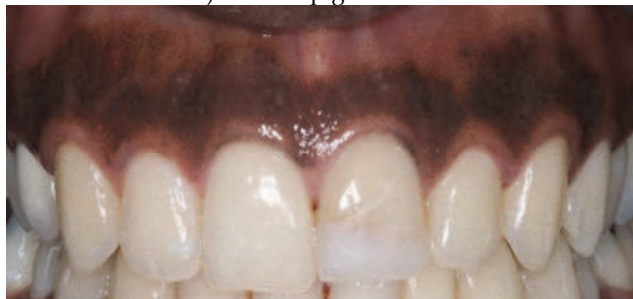
Fig. 1. Components of the periodontium (Garant 2003)



a) Normal pigmentation



b) Physiologic pigmentation

Fig. 2. Normal variation in the appearance of the gingival tissues

The tissue that resides in the interproximal embrasure is called the interproximal papilla. The shape of this tissue is influenced by the shape of the interproximal contact, the width of the

interproximal area, and the position of the cemento-enamel junction of the involved teeth. The shape of this papilla varies from triangular and knife-edge in the anterior regions due to point sized contacts of the teeth to broader and more square shaped tissue in the posterior sextants due to the teeth having broad contact areas. Also present in the wider papillary areas is the col. This is a valley-like structure situated apical to the contact area (Fig 3).

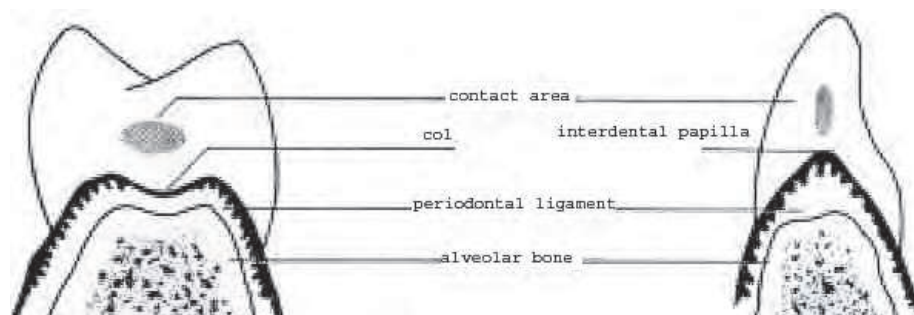


Fig. 3. Interdentary tissue shapes (Garant 2003)

The texture of the gingiva varies with age and is typically smooth in youth, stippled in adulthood, and again becomes smoother with advanced age. Stippled tissue has a texture similar to the rind of an orange and its presence does not necessarily mean health. (Fig 4). Another feature that does not appear in all of healthy periodontiums is the free gingival groove. The free gingival groove is a depression that appears in about 50% of population. The groove appears at the border of the free and attached gingiva and usually represents the base of the gingival sulcus. The gingival sulcus is the invagination around a tooth bounded by the free gingival margin.

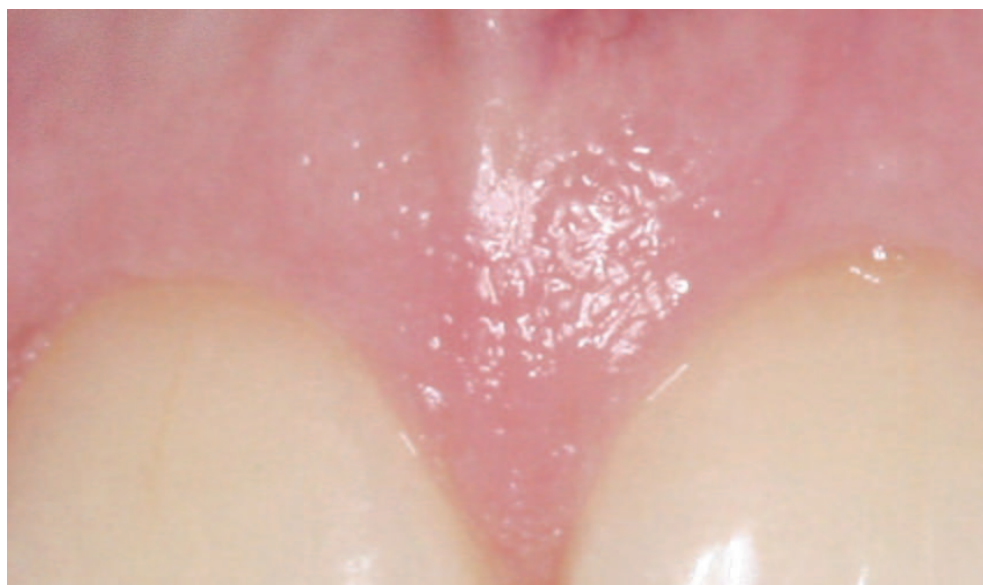

Fig. 4. Stippling of gingival tissue.

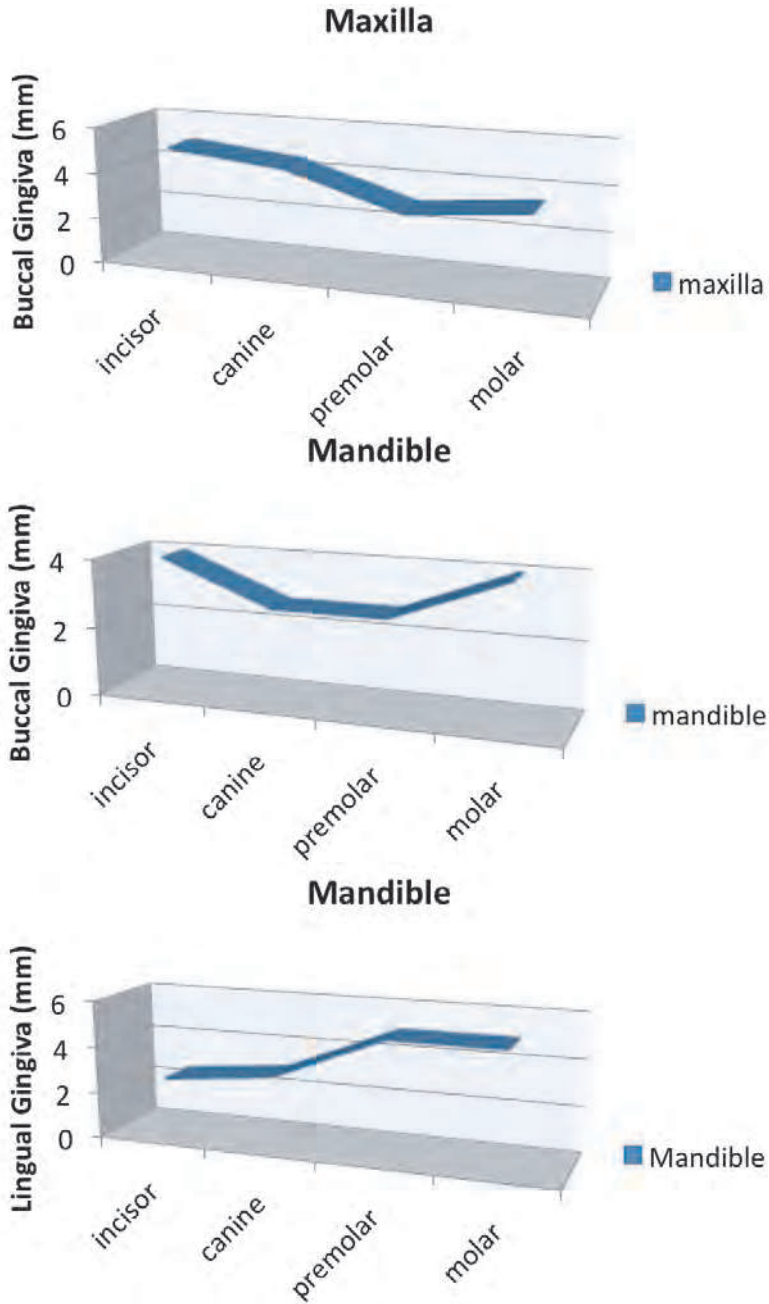


Fig. 5. Width of attached gingiva in specific areas

When a periodontal probe is placed into this space, a measure may be recorded which is very useful for diagnosis. Studies have shown an average depth of 0.7mm but variations may range from 0 to 6mm (Gargiulo 1961)). The width of the attached gingiva varies with the location in the oral cavity as well as with physiologic age. The facial gingiva is typically widest in the incisor region and narrowest in the premolar region for the maxillary arch and ranged from 1-9mm. In the mandible, the facial attached gingiva is narrowest in the premolar and canine regions (Bowers 1963). When the lingual attached gingiva was examined, it was found that the widest areas were on the mandibular molars and the narrowest were on the incisor and canine regions, about 1.8mm (Voigt 1978) (Fig. 5). There is a general increase from the primary to permanent dentition as well as with increasing age (Ainamo and Talari 1976)(Fig. 6).

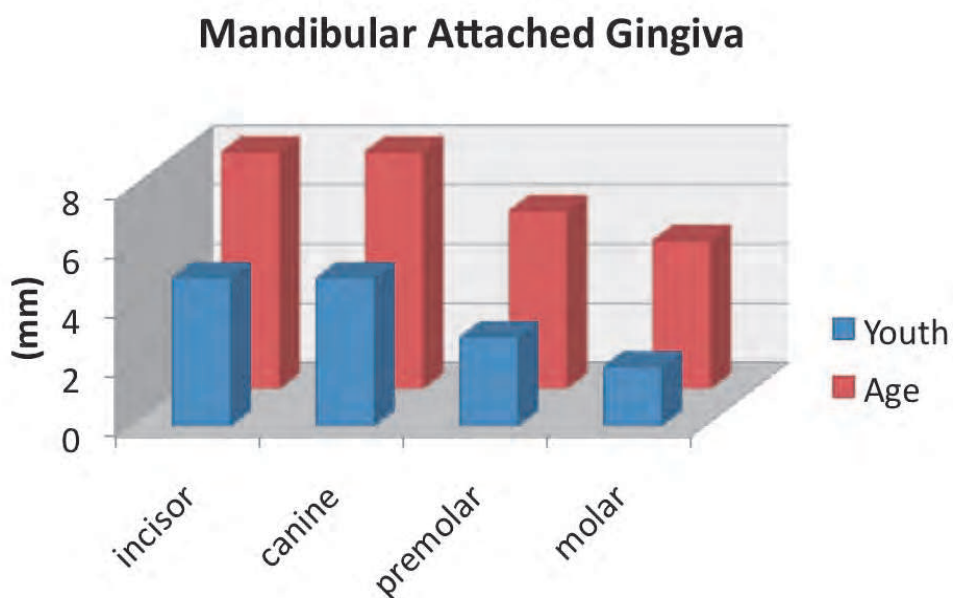


Fig. 6. Changes in the amount of attached tissue with age.

Using radiographs one can visualize several of the components of the periodontium as well as their size and relation to the teeth (Fig. 7). Although the radiograph is a two-dimensional depiction of a three-dimensional object, the location of the alveolar bone crest relative to the cemento-enamel junction is seen along with the space occupied by the periodontal ligament. Since the periodontal ligament itself is not a mineralized tissue, the radiograph will show a radiolucent area that it occupies. The cortical bone that houses the teeth is known as the lamina dura. The alveolar bone also follows a path that parallels the positions of the cemento-enamel junctions of teeth (Ritchev and Orban 1953). In health the interdental bone is 1.0mm from the cemento-enamel junction and increases with age to 2.8mm (Gargiulo 1961).

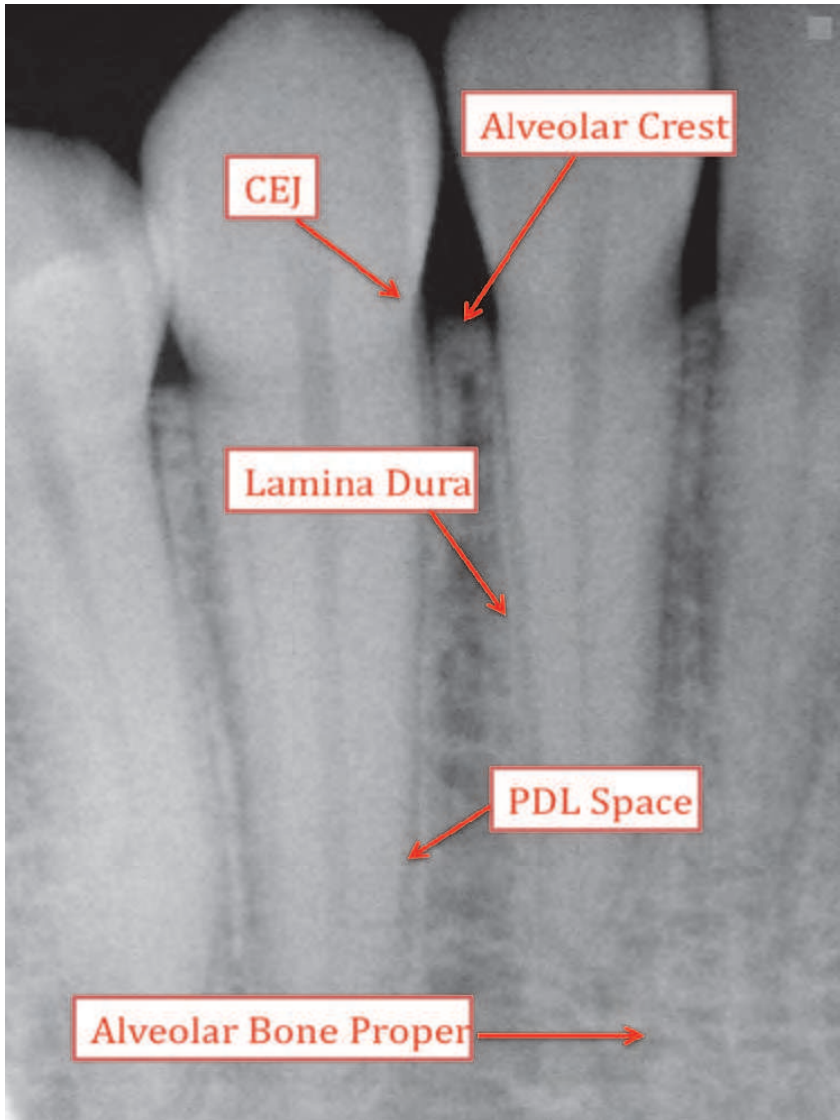


Fig. 7. Appearance and location of periodontal components on a periapical radiograph

3. Microscopic appearance of the periodontium

Greater detail of the periodontium is obtained histologically. The schematic cross-section of the periodontal attachment and components is seen in Fig. 1. The components are again the alveolar bone, gingiva, periodontal ligament, and cementum. The gingiva consists of a surface epithelium and underlying connective tissue termed the lamina propria. There are three types of epithelium present, the oral, sulcular, and the junctional epithelium. The oral

epithelium is continuous with the epithelium of the oral cavity. The sulcular epithelium is adjacent to the tooth but not connected or attached to the tooth surface. The junctional epithelium is at the base of the sulcus and is in direct contact with the tooth (Carranza 2002)(Fig. 8).

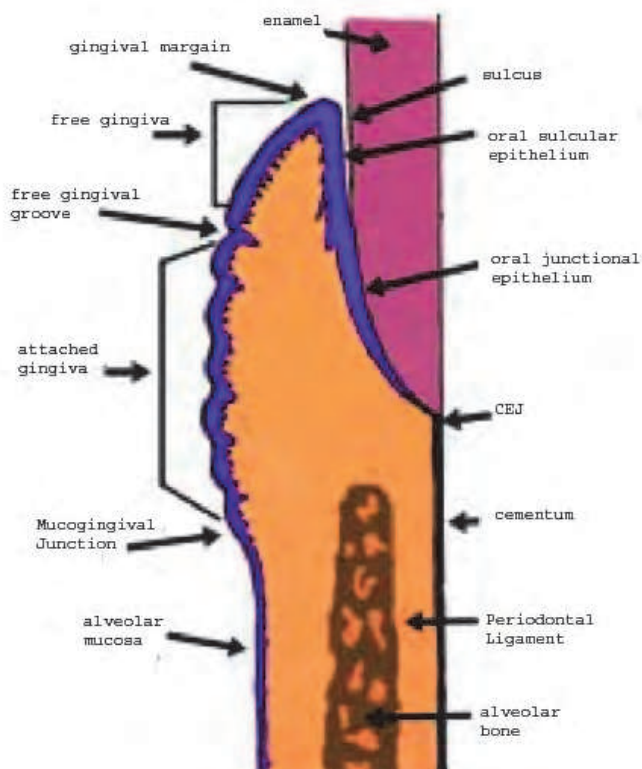


Fig. 8. Types of epithelium in the periodontium (Garant 2003)

The border of the connective tissue and epithelium is undulating (Fig. 9). These epithelial extensions are known as epithelial ridges or rete pegs. The connective tissue layer is also termed the lamina propria or the dental papillae. In health, this is a characteristic finding in the attached gingiva, but are absent in the sulcular and junctional epithelium.

The gingival epithelium is quite similar to the epidermis in its structure. The gingiva consists of keratinized, stratified, squamous epithelium. The major cell type is the keratinocyte. There are four distinct layers; the stratum basale, stratum spinosum, stratum granulosum, and the stratum corneum (Fig. 10). The stratum basale or basal layer consists of one to two layers of cells cuboidal in shape. These are the most undifferentiated of the cells and serve to replenish cells as they are shed during their maturation and exfoliation. The basal cells are immediately adjacent to the connective tissue from which it is separated by a basement membrane. The basement membrane consists of a two zones, the lamina lucida and lamina densa. The lamina lucida contacts the cell surface and has many hemidesmosomes. Hemidesmosomes are specialized structures that connect an epithelial

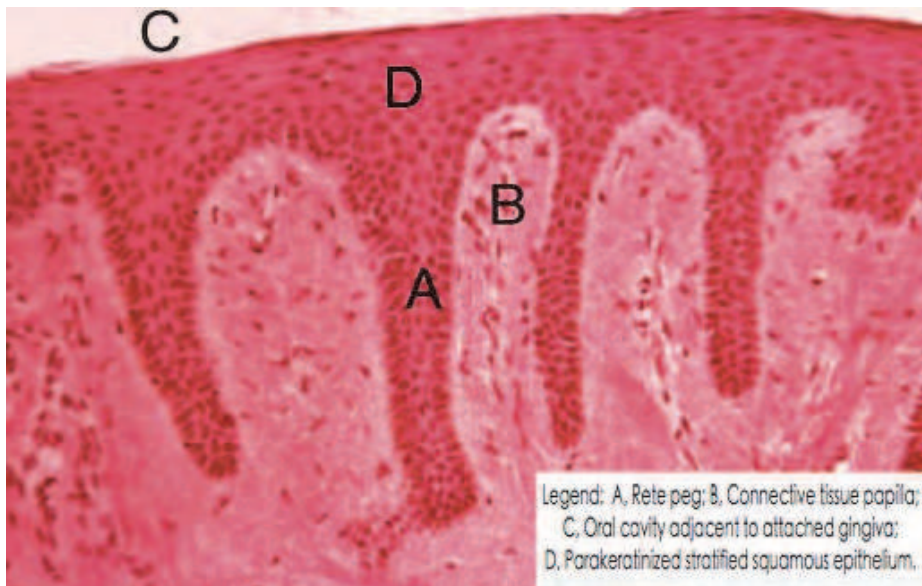

Fig. 9. Rete pegs (Garant 2003)

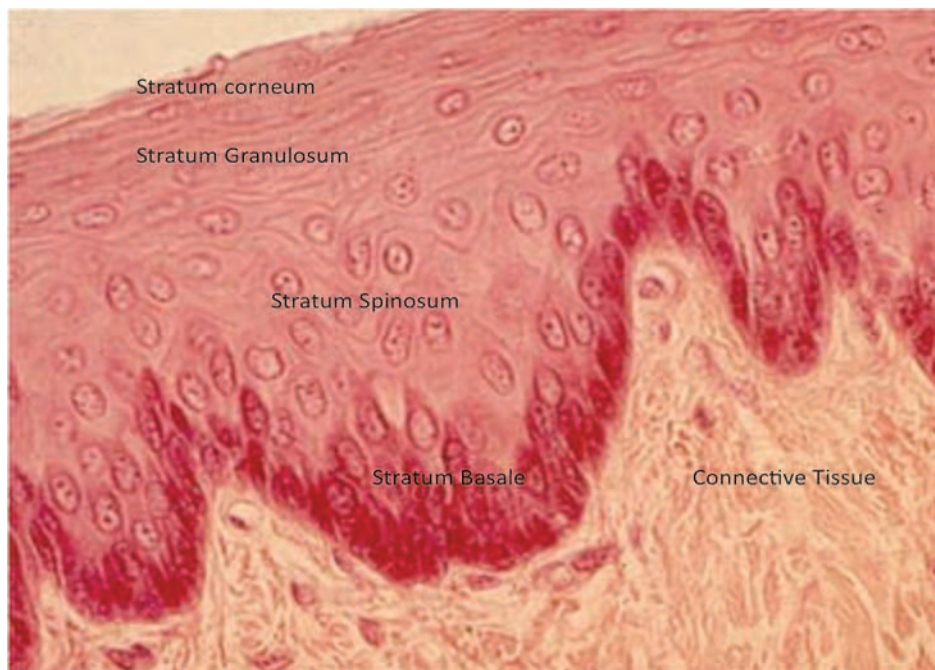


Fig. 10. Cellular layers of epithelium (Garant 2003)

cell to the basement membrane. In the lamina densa, anchoring fibrils formed from Type VII collagen bind to the Type I and III collagen of the extracellular matrix (Listgarten 1972; Schroeder 1997).

The stratum spinosum consists of larger cells with cytoplasmic processes that resemble spines. There are typically 10-20 layers of cell in this stratum. The cells are bound to each other by desmosomes, which are in essence pairs of hemidesmosomes. The cells contain many keratin filament bundles known as tonofibrils. Other cells found in this layer include melanocytes, Langerhan's cells and Merkel cells. Melanocytes produce the pigment melanin which is contained in granules. Langerhan's cells are part of the immune system and serve as antigen presenting cells. The Merkel cells are responsible for the perception of sensation. In the stratum granulosum, keratohyalin bodies and tonofibrils are seen extensively. As the cells proceed from the basal layer and reach the stratum granulosum, a dramatic decrease in organelles can be observed. The stratum corneum is seen abruptly after the stratum granulosum. It consists of layers of flattened cells that may exhibit different patterns of keratinization depending on location and external stimuli (Carranza 2002).

This keratinization process as the cells mature through the layers is considered differentiation. Orthokeratinized cells are flattened and have no discernible nuclei and cytoplasmic organelles. Parakeratinized refers to cells that exhibit incomplete keratinization and cells that contain remnants of nuclei and cellular organelles. The location most keratinized is the palate, followed by the gingiva and tongue, and finally the buccal mucosa (Miller 1951). The degree of keratinization of the oral mucosa generally decreases with age and with the onset of menopause (Pacic 1950). The sulcular epithelium is thin, non-keratinized epithelium.

In health, the depth of the sulcular epithelium is less than 3mm and ends at the corneal surface of the junctional epithelium. Cadaver studies found the depth of the sulcus to be an average of 0.69mm (Gargiulo 1961). Rete pegs are not present in the sulcular epithelium. The junctional epithelium contains cells that are directly attached to the tooth surface. An internal basal lamina attaches the cells to the tooth surface through hemidesmosomes and an external basal lamina attaches the cells to the underlying connective tissue. Early in life it typically consists of a few stratified squamous cell layers, but with age the number of layers increases to between 10-20. The average width of the junctional epithelium is 1mm (Gargiulo 1961). The junctional epithelium also has wide intercellular spaces and functions as a permeable barrier. This is an important property since it acts as a semi-permeable barrier through which bacteria and their components and byproducts may pass into and invade the tissue. It also facilitates the passage of leukocytes (e.g. neutrophils) and immune components (e.g. complement), enzymes, and gingival crevicular fluid. Gingival crevicular fluid is a modified inflammatory exudate produced that resembles serum. The col areas share similar characteristics to the junctional epithelium. These areas are also non-keratinized and have a high level of turnover (Garant 2003). In summary, the junctional epithelium differs from the oral epithelium in having cells of smaller size, larger intercellular spaces, and fewer desmosomes.

Beneath the epithelial layer is a connective tissue layer also known as the lamina propria. This layer is composed of a papillary and a reticular layer. The papillary layer is adjacent to the basal cells of the epithelium and their rete pegs. The reticular layer is adjacent to the underlying alveolar bone. Collagen Type I is the predominant component of the lamina propria. Also residing in this layer are cells, nerves, blood vessels, and ground substance. The cells present are fibroblasts, mast cells, and immunologic cells. Mast cells contain vesicles with vasoactive substances such as histamine and proteolytic enzymes. Once

activated by stimuli, the cells can degranulate and induce changes in blood flow to the area and increase tissue permeability. The immunologic cells present are macrophages, neutrophils, lymphocytes, and plasma cells. These cells are present to initiate and maintain a response to a foreign substance or cell present in the area. Ground substance is a gel-like substance composed of glycosaminoglycans and proteoglycans. These substances cause a large amount of water retention which maintains the shape and structure of the area when force is applied. This substance also serves as a medium for the transportation of electrolytes, nutrients, and metabolites (Rose 2004).

The fibroblasts are the predominant cells and function to synthesize collagen and extracellular matrix. These cells are elongated and elliptical in shape and their microscopic appearance is characteristic of a cell producing large amounts of cellular products, a well-developed rough endoplasmic reticulum and Golgi apparatus, and many mitochondria. Collagen is formed by both an intracellular and extracellular process. Intracellularly tropocollagen, the smallest unit of collagen, is produced. Tropocollagen consists of three polypeptide chains of 1000 amino acids in an α -helical formation and is 3000 Å long and has a 15Å diameter. A significant percentage of the amino acid composition is glycine, proline, and hydroxyproline. The later is unique to collagen and when assayed can be used to determine the amount of collagen in the sample. The tropocollagen is excreted into the extracellular environment, where the remainder of the formation takes place. Tropocollagen is arranged into protofibrils and then collagen fibrils. The fibrils are then bundled together

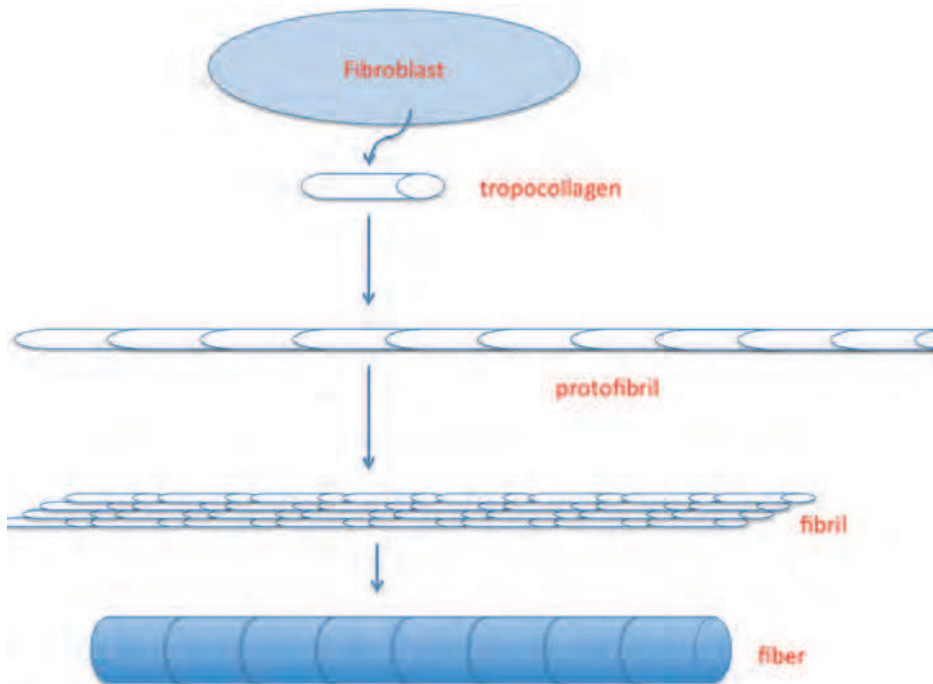


Fig. 11. Formation of collagen. (top to bottom) (tropocollagen, protofibril, collagen fibril, and collagen fiber)

and collagen fibers are created with a typical cross-banding pattern of 700 Å. (Fig 11). As collagen matures and ages it develops greater cross-linking making the collagen less soluble and resistant to breakdown (Rose 2004).

Most collagen present in the gingiva and connective tissue is irregularly arranged but some distinct arrangements of fibers can be observed. These include the dentogingival, circular, and transseptal group. The dentogingival group fibers may run from the root surface to the periosteum of the bone, from the root surface to the gingiva, and from the alveolar bone to the gingiva. Circular fibers run circumferentially around the tooth within the gingiva and do not touch the tooth itself. The transseptal group runs from the root surface of one tooth to the root surface of another tooth transversing the alveolar bone (Garant 2003) (Fig. 12).

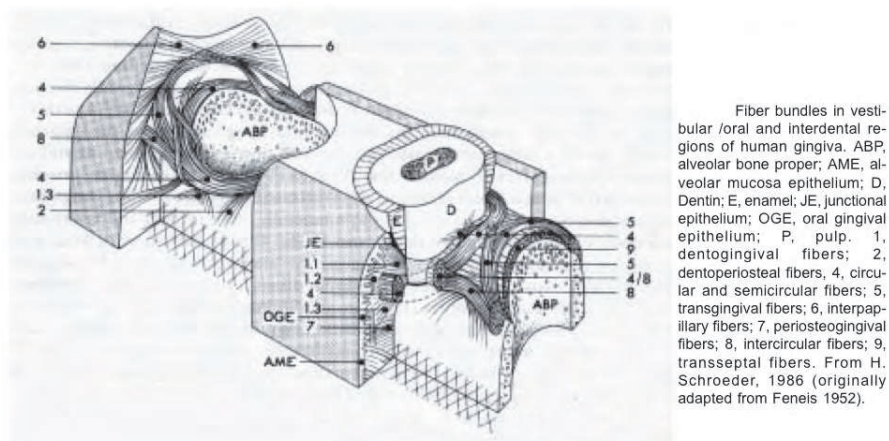


Fig. 12. Gingival fiber groups. (Garant 2003)

The periodontal ligament is the connective tissue that connects the tooth to the alveolar bone. The periodontal ligament serves to allow forces to be distributed to the alveolar bone during mastication and occlusal function. The majority of the volume of the ligament is occupied by dense connective tissue and the minority by loose connective tissue with neurovascular structures. Cells present in this tissue include osteoblasts, cementoblasts, osteoclasts, multipotent stem cells, epithelial remnants, and fibroblasts, which are the most abundant (Carranza 2003) Since the periodontal ligament contains such a variety of cells, it plays an important role in healing and repair. This potential is also a focus for to periodontal regenerative procedures (Melcher 1976). The ligament is about 0.15mm to 0.25mm in width and has an hourglass shape with the mid root level having the narrowest width. The width of the ligament can adapt to forces by decreasing in lowered function and a widening of the ligament with increased occlusal load or hyperfunction. With age there is a decrease in vascularity, cell mitotic activity, fiber number and in fibroblasts there is a slight decrease in width (Van der Velden 2004).

With root development principle fibers, which are collagenous bundles, insert their terminal ends into the root cementum and alveolar bone and are termed Sharpey's fibers or periodontal ligament fibers. These collagen fibers are produced by fibroblasts, chondroblasts, osteoblasts and other cells in a manner described previously. The fibers are

typically Type I collagen. The fibers can also be arranged by their position and orientation. The six groups are the transseptal, horizontal, alveolar, oblique, apical, and radicular groups (Fig. 13). The transseptal group extends from the cementum of one tooth over the interseptal bone to the cementum of an adjacent tooth. The horizontal group attaches the cementum to the alveolar crest and run perpendicular to the root and alveolar surfaces. The alveolar group attaches the cementum to the alveolar bone and originates apical of the cemento enamel junction. The oblique group constitutes the majority of the fibers and run obliquely from the root cementum to the alveolar bone. These fibers provide support from intrusive forces from mastication. The apical fiber group emerges from the cementum near the apex of the root and connects to the alveolar bone. The radicular group is seen in multirouted teeth near the furcation and connects the cementum of that area to the neighboring bone. Other fibers present include oxytalan fibers, which run parallel to the root surface vertically, and elaunin fibers that are similar to immature elastic fibers (Rose 2004; Garant 2003).

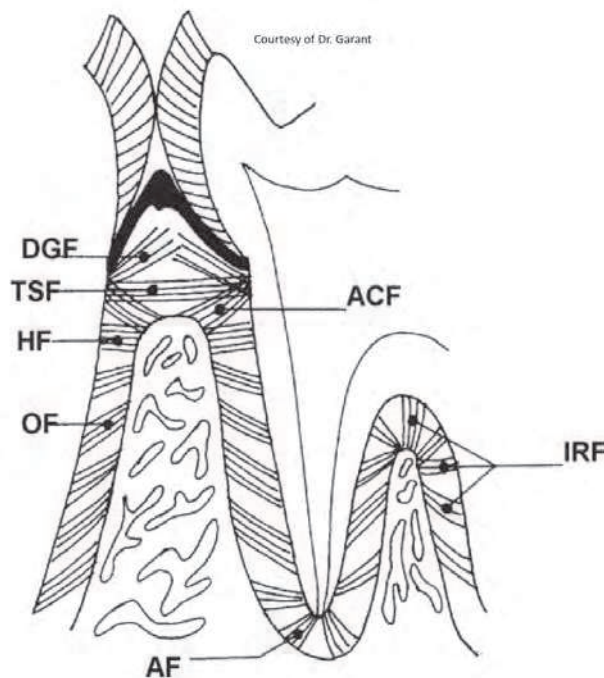


Fig. 13. Periodontal fiber groups (Garant 2003)

The cementum is a mineralized tissue covering the anatomic root of the tooth. Cementum is avascular and has no direct innervation. It is made of collagen fibers within a mineralized matrix. Fibers present in the cementum may be classified as extrinsic or intrinsic. The extrinsic fibers are created by the fibroblasts in the periodontal ligament and the intrinsic fibers are produced by cementoblasts. The mineralized matrix is composed of mainly hydroxyapatite $[Ca_{10}(PO_4)_6(OH)_2]$. Cementum has some characteristics that are both

biochemically and physically similar to bone due to its composition. Cementum is continuously deposited throughout life and the apical third of the root typically has the thickest deposition. In doing so, the deposited cementum compensates for the eruption of teeth from attrition. The thickness of the cementum varies from 15 to 150 microns depending on the location on the root and age of the patient. There is some permeability of cementum to organic substances, ions, and bacterial products. Typically the permeability of cementum diminishes with age. The extent of cementum coronally exhibits different patterns (Fig. 14). In most instances the cementum overlaps the enamel (~60%), and less frequently it has a butt-joint (~30%), and least frequently it ends short of the enamel (5-10%). This anatomical variation among the position the enamel and cementum board is clinically relevant when gingival recession occurs and patients may present with exposed dentin and root hypersensitivity (Carranza 2003).

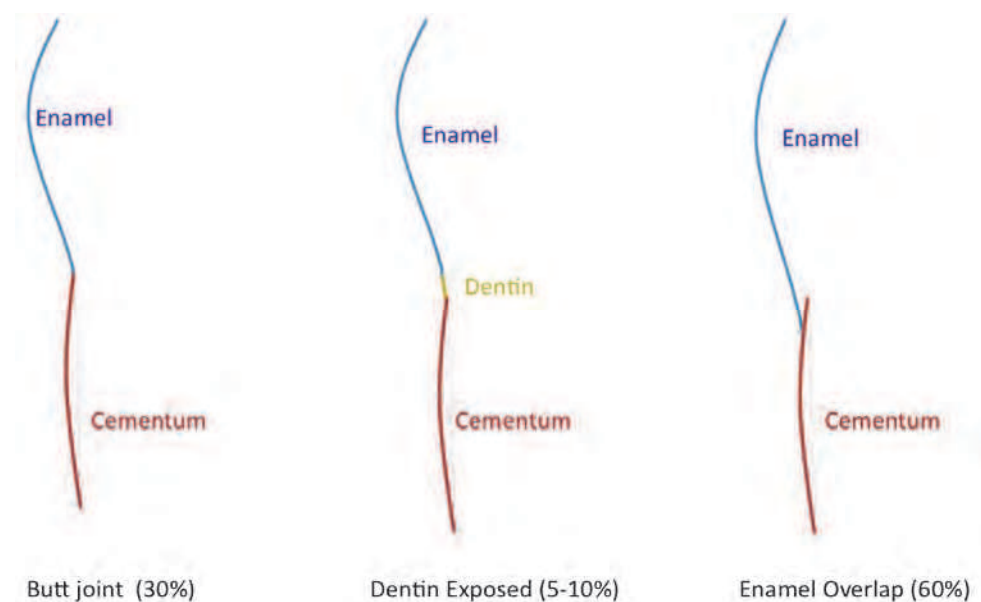


Fig. 14. Configurations of dentin, cementum, and enamel at the cemento-enamel junction.

Cementum is characterized into acellular and cellular types. Acellular afibrillar cementum is located near the coronal aspect of the root and has no cells and no extrinsic or intrinsic collagen fibers within it. Acellular extrinsic fibrillar cementum is found in the middle and coronal parts of the root and lacks cells. This type of cementum has Sharpey's fibers, collagen fibers that attach from the cementum to the alveolar bone. Cellular mixed stratified cementum is present in the apical third and in the area of furcations. It also contains Sharpey's fibers and intrinsic fibers. Cellular intrinsic fibrillar cementum has cementocytes, which are cementoblasts trapped within the mineral they deposited, and does not contain extrinsic collagen fibers (Garant 2003).

The alveolar process is the osseous tissue of the maxillary and mandibular jaws which houses and supports the sockets of the teeth. The process consists of an external cortical

plate, the inner socket wall known as the alveolar bone proper and is compact bone, and a cancellous trabecular bone in between the two boney layers. The bone is typically thicker in the palatal and lingual areas when compared to the buccal areas. Some areas may present with defects known as dehiscences and fenestrations. Dehiscences are areas where bone has been lost on a root surface and the root is only covered by periosteum and gingiva. Fenestrations are small areas or “windows” where bone has been lost on a root surface and is only covered by periosteum and gingiva. (Fig. 15). These defects were shown to occur in about 20% of all teeth. Dehiscences were more prevalent in the mandible, whereas fenestrations are more common in the maxilla (Elliot and Bowers 1963). Some areas may be predisposed to these defects by having teeth with prominent root morphology, dental crowding, and a position extending beyond the dental arch. These areas become crucial if periodontal disease occurs or if gingival recession takes place since they may complicate therapy and adversely affect the area’s prognosis.

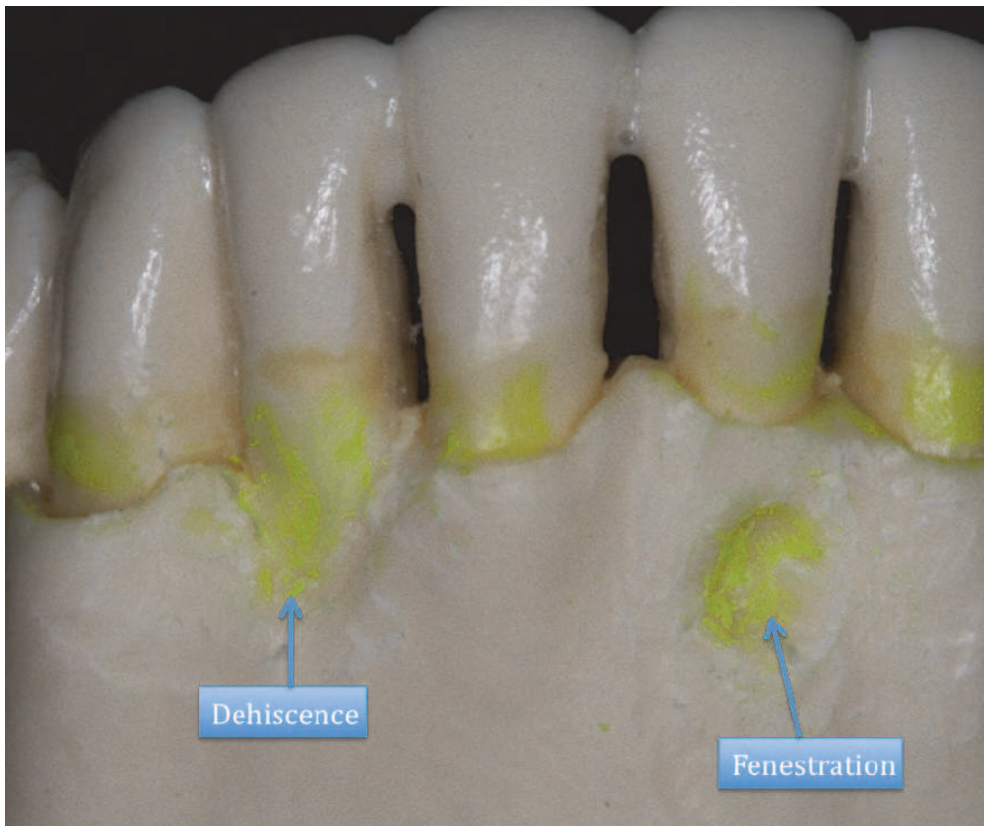


Fig. 15. Diagram of fenestration and dehiscence defects.

The alveolar bone proper is cribiform in appearance and this allows for a connection to the neurovascular structures. The bone is created by osteoblasts during development (modeling) and is constantly remodeled throughout life from the intricate osteoblastic/osteoclastic

relationship. The osteoblasts produce collagen, glycoproteins and proteoglycans to produce the bone matrix that is then mineralized with calcium and phosphate. The mineral is hydroxyapatite and the mineral content is about 60%. When osteoblasts have laid down osseous tissue they become trapped within the tissue and are termed osteocytes. Osteocytes reside in lacunae and connect and communicate with each other through canaliculi. A group of osteocytes surround themselves around the neurovascular bundles (Haversian canals) and are termed osteons. An osteon is the fundamental unit of compact bone and are cylindrical structures. Volkmann's canals which run within osteons, carry nerves and blood vessels, and are perpendicular to the Haversian canals (Fig. 16). An analogy can be that the Haversian canals are elevators of a tall building and the Volkmann's canals are hallways on specific floors. Cancellous bone consists of trabeculae and has irregular marrow spaces. Cancellous or trabecular bone is found interdentally. The bone quality of the maxilla and mandible are generally different and overall the maxilla has more cancellous bone compared to the mandible (Sodek 2000; Rose 2004; Carranza 2003).

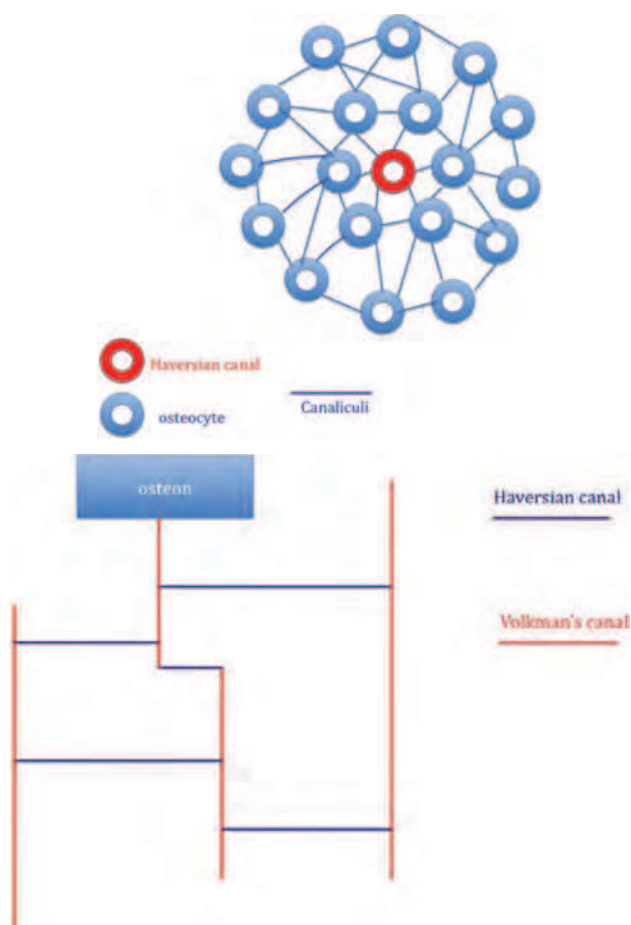


Fig. 16. Microscopic configuration of osseous tissue. A)osteon B)vascular configuration

Osteoclasts are derived from monocytes and resorb bone by a specialized feature called a ruffled border. This structure seals off an area and then vesicles stored within the osteoclast are released to cause the breakdown. These enzymes include acid phosphatase, cathepsins, and matrix metalloproteinases. The interaction between the osteoclasts and osteoblasts is regulated by the RANK pathway (receptor activator of nuclear factor- $\kappa\beta$) which is a balance of the ligand for RANK (RANKL) and a competitive inhibitor osteoprotegerin (OPG). The creation of RANKL involves osteoblasts themselves which activate precursor cells to differentiate, in the presence of macrophage colony stimulating factor, to become osteoclasts. The outer surface of bone is covered by layers of connective tissue called the periosteum. The periosteum contains osteoblasts, stem and progenitor cells, fibroblasts, and vascular and nervous tissue. The inner layer of bone is lined with endosteum which is comprised of connective tissue containing osteoblasts (Garant 2003).

The periodontium's blood supply is derived from the superior and inferior alveolar arteries. These arteries produce branches that extend into the periodontal ligament and into the alveolar bone and periosteum. The gingiva receives its vascular supply from three different sources: the interdental septum, the periodontal ligament, and the connective tissue and periosteum all anastomose and supply the gingiva through a vascular network of capillaries. This vast network enables many periodontal procedures to be performed without depriving the periodontium and dental structures of a vascular supply. Innervation of the periodontium is from branches of the trigeminal nerve. These branches provide sensory function for the periodontal ligament, periosteum, the gingiva, and connective tissue. (Carranza 2003; Rose 2004).

4. Embryonic development of the teeth and periodontium

The development of the dentition and supporting structures begins at about the fifth week embryonically. Cells from the neural tube, known as neural crest cells, migrate to the first branchial arch. Neural crest cells are pluripotent neuroepithelial cells. Neural crest cells give rise to osteoblasts, chondrocytes, fibroblasts, cementoblasts, odontoblasts, and ganglia and other nervous structures. The migrated neural crest form a layer known as ectomesenchyme beneath the oral epithelium. An intricate epithelial-ectomesenchymal interaction takes place led by the ectomesenchyme. Studies have shown that the ectomesenchyme and dental organ contain all the necessary information to create the tooth and its attachment apparatus (Ten Cate 1998). A dental lamina is formed from an ingrowth of oral ectoderm surrounded by the ectomesenchyme. A projection off the dental lamina develops which forms the tooth bud. The ectomesenchyme surrounding the tooth bud begins to form immature bone known as woven bone. The tooth bud will differentiate morphologically into the dental organ and proceed through stages known as the bud, cap, and bell stages chronologically (Fig. 17).

During the cap stage, the ectomesenchyme condenses and forms the dental papilla. Also forming are distinct layers during the cap and bell stage within the dental organ known as the inner enamel epithelium, the outer enamel epithelium, the stellate reticulum, and the stratum intermedium (Fig. 18). The outer enamel epithelium is composed of cells cuboidal in shape and contact the star shaped cells of the stellate reticulum. The stratum intermedium lies between stellate reticulum and inner enamel epithelium. One or two layers of cuboidal cells make up this layer. The inner enamel epithelium consists of columnar shaped cells. The

inner enamel epithelium will give rise to ameloblasts that create the enamel of the tooth. A dental follicle also forms from the ectomesenchyme and surrounds the dental organ and dental papilla. The dental papilla will eventually give rise to the crown, root dentin and the cellular elements of the dental pulp. It has been shown that the shape of the dental papilla dictates the shape of the final crown of the tooth (Ten Cate 1998). The cells of the dental follicle will eventually differentiate and become cementoblasts, fibroblasts, and osteoblasts that create the periodontal ligament and alveolar bone proper respectively.

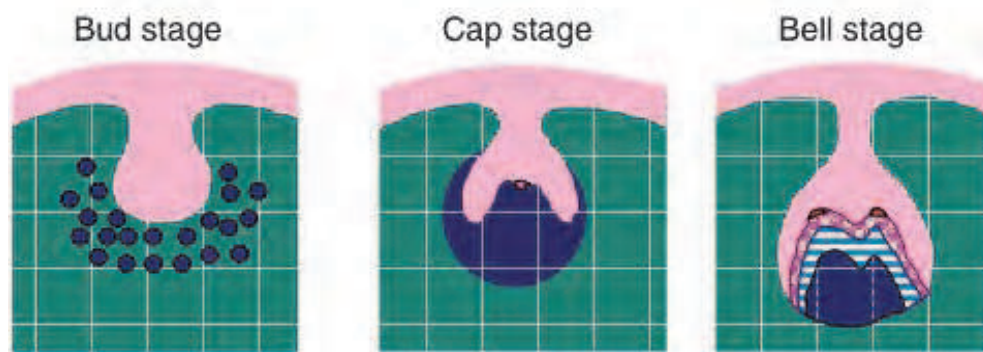


Fig. 17. Initial Stages of tooth development. (Garant 2003)

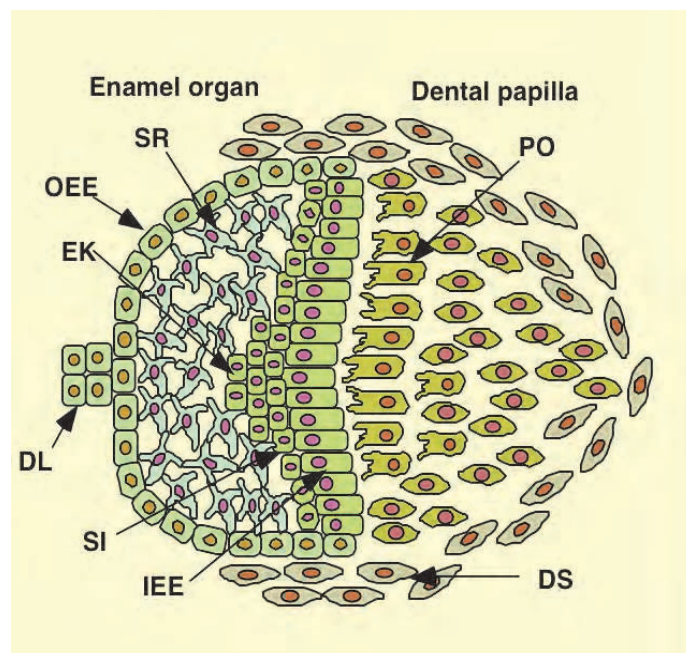


Diagram of the enamel organ and dental papilla. The outer enamel epithelium (OEE) forms the convex surface of the enamel organ and is separated from adjacent dental sac and general mesenchyme (not shown) by a basement membrane. The stellate reticulum (SR) lies between the OEE and the stratum intermedium (SI). The SI cells are closely juxtaposed to the cells of the inner enamel epithelium (IEE). The enamel knot (EK) represents a small group of nondividing cells near the IEE. The IEE is separated from the preodontoblasts of the dental papilla (Fig.6) by a basement membrane (see figure 4). DL, remnant of the dental lamina; DS, dental sac cells.

Fig. 18. Detail of the bell stage (Garant 2003)

As the development of the future crown progresses, the development of the periodontal structures and root takes place. The inner and outer enamel epithelium proliferate and fuse and become the Hertwig's epithelial root sheath at apical end of the root. This structure is composed of a double layer of epithelial cells. Cells of the dental papilla that are adjacent to Hertwig's epithelial root sheath begin to form dentin on the surface of the root. Hertwig's epithelial root sheath begins to disintegrate and epithelial rests of Malassez are created. These are epithelial remnants of the Hertwig's epithelial root sheath and they will reside in the periodontal ligament. Clinically these remnants may become significant, as they are a possible cause of radicular cysts (Garant 2003; Rose 2004).

As the epithelial root sheath becomes discontinuous and the root dentin is exposed, cells from the dental follicle will begin to produce cementoblasts to create cementum over the surface. The first type of cementum formed is acellular fibrillar cementum. The collagen fibers secreted by the cementoblasts are oriented at right angles to the root and will eventually connect with the collagen fibers of the periodontal ligament to form Sharpey's fibers.

Cellular cementum is formed when tooth formation is near completion. The cells on the outer part of the dental follicle will begin to produce osteoblasts and produce alveolar bone. In between the osteoblasts and cementoblasts, cells of the dental follicle will become fibroblasts and produce collagen that will become the periodontal ligament. As the cementum and alveolar bone increase in thickness, the periodontal ligament narrows in size and fibers become fixed within the mineralizing tissues. This process creates the Sharpey's fibers that attach the tooth to the alveolar bone through collagen fibers (Garant 2003). The developmental process is also important for periodontal and oral regenerative procedures. Proteins produced by Hertwig's epithelial root sheath (i.e. enamel matrix derivatives) are used to induce acellular cementum formation and also cause fibroblast differentiation and proliferation in the periodontal ligament. Applications of the developmental process are also of interest with current biologic agents and future stem cell technology to create conditions that would encourage regeneration of oral structures that have been lost.

When the process of enamel formation has concluded, the ameloblasts become reduced in size and become the reduced enamel epithelium. This layer attaches itself to the enamel of the tooth through hemidesmosomes and this is called the primary epithelial attachment. This reduced enamel epithelium exists from the time the enamel is mineralized to the time of tooth eruption. During the process of eruption, the epithelium of the primary epithelial attachment fuses with the oral epithelium. The oral epithelium replaces the cells of the primary attachment and is called the secondary epithelial attachment. This section of multilayer cells is also attached to the tooth through hemidesmosomes (Garant 2003; Rose 2004).

Tooth eruption can be broken down into two phases, active and passive. Active eruption is the physical eruption of the teeth into the oral cavity. Passive eruption takes place when the teeth are in occlusion. During passive eruption, a continued apical movement of the gingival margin and epithelial attachment takes place. Gargiulo and others divided this process into stages. The final stage places the gingival margin at a level slightly coronal of the cementoenamel junction and the sulcus and junctional epithelium are apical of the cementoenamel junction (Gargiulo 1961). This process may take place later in some individuals and caution must be taken when gingival esthetics of young adults is being

evaluated since interventional therapy may not be warranted if the tissues have not settled to the lower apical level.

5. Conclusion

The periodontium is the foundation for the dentition. It is formed by the alveolar bone, periodontal ligament, cementum, and oral mucosa. These components allow for the interaction of the teeth with external forces and helps prevent damage in function. Knowing the structure and origins of the components that constitute the periodontium, the interaction with each other and their biological and physical limits is crucial if one is to understand the changes seen in the periodontium when affected by disease and excessive occlusal forces.

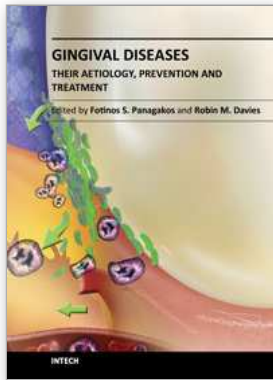
6. Acknowledgements

I would like to thank Dr. Vincent Iacono for his help in this endeavor. His guidance, encouragement, and support were instrumental in this work. I would also like to thank Dr. Philias Garant for use of his illustrations in this text.

7. References

- Ainamo J, Loe H. (1966). Anatomical characteristics of gingiva. A clinical and microscopic study of the free and attached gingival, *J Periodontol* 37:5-13.
- Ainamo, J., Talari, A. (1976). The increase with age of the width of attached gingiva. *Journal of Periodontal Research* 11, 182-188.
- Bowers GM. (1963). A study of the width of the attached gingiva. *J Periodontol* ;34:201-209.
- Carranza FA, Bernard GW(2003) *Carranza's Clinical Periodontology*, ed 9, WB Saunders Philadelphia. (pp 36-57).
- Elliot R, Bowers G. (1963). Alveolar dehiscence and fenestration. *Periodontics* :1:245-248.
- Garant PR. (2003). *Oral Cells and Tissues*. 1st ed. Quintessence. ISBN 0867154292. Chicago.
- Gargiulo AW, Wentz FM, Orban B. (1961). Dimensions and relations of the dentogingival junction in humans. *J Periodontol*; 32:261-267.
- Listgarten, M.A. (1972). Normal development, structure, physiology and repair of gingival epithelium. *Oral Science Review* 1, 3-67.
- Melcher AH. (1976). On the repair potential of periodontal tissues. *J Periodontol* 47: 256-260.
- Miller SC, Soberman A, Stahl S (1951). A study of the cornification of the oral mucosa of young male adults. *J Dent Res*. 30:4.
- Papic M and Glickman I. (1950). Keratinization of the human gingiva in the menstrual cycle and menopause. *Oral Surg*. 3:504.
- Ritchey, B. and Orban, B. (1953). The crests of interdental alveolar septa. *J. Periodontol*, 24:75-87.
- Rose, Louis F (2004). *Periodontics: Medicine, Surgery and Implants*. Mosby. ISBN 0801679788. St. Louis.
- Schroeder, H.E. & Listgarten, M.A. (1997). The gingival tissues: the architecture of periodontal protection. *Periodontology* 2000 13, 91-120.

- Sodek J, McKee MD (2000). Molecular and cellular biology of alveolar bone, *Periodontol 2000* 24:99–126.
- Ten Cate AR. (1998). *Oral histology, development, structure and function*, 5th ed, Mosby. ISBN 032304557X. St. Louis.
- Van der Velden U (1984). Effect of age on the periodontium, *J Clin Periodontol* 11:281–294.
- Voigt JP, Goran ML, Fleisher RM. (1978) The width of lingual mandibular attached gingiva. *J Periodontol*; 49:77-80.



Gingival Diseases - Their Aetiology, Prevention and Treatment

Edited by Dr. Fotinos Panagakos

ISBN 978-953-307-376-7

Hard cover, 230 pages

Publisher InTech

Published online 22, September, 2011

Published in print edition September, 2011

Gingival diseases are a family of distinct pathological entities that involve the gingival tissues. These signs and symptoms of these diseases are so prevalent in populations around the world that they are often considered to be "normal" features. The diseases are now classified into two main groups namely: Plaque-Induced and Non-Plaque Induced Gingival Diseases. This book provides dentists, dental hygienists, dental therapists and students with a comprehensive review of gingival diseases, their aetiology and treatment.

How to reference

In order to correctly reference this scholarly work, feel free to copy and paste the following:

Anthony Palumbo (2011). The Anatomy and Physiology of the Healthy Periodontium, *Gingival Diseases - Their Aetiology, Prevention and Treatment*, Dr. Fotinos Panagakos (Ed.), ISBN: 978-953-307-376-7, InTech, Available from: <http://www.intechopen.com/books/gingival-diseases-their-aetiology-prevention-and-treatment/the-anatomy-and-physiology-of-the-healthy-periodontium>

INTECH

open science | open minds

InTech Europe

University Campus STeP Ri
Slavka Krautzeka 83/A
51000 Rijeka, Croatia
Phone: +385 (51) 770 447
Fax: +385 (51) 686 166
www.intechopen.com

InTech China

Unit 405, Office Block, Hotel Equatorial Shanghai
No.65, Yan An Road (West), Shanghai, 200040, China
中国上海市延安西路65号上海国际贵都大饭店办公楼405单元
Phone: +86-21-62489820
Fax: +86-21-62489821

© 2011 The Author(s). Licensee IntechOpen. This chapter is distributed under the terms of the [Creative Commons Attribution-NonCommercial-ShareAlike-3.0 License](#), which permits use, distribution and reproduction for non-commercial purposes, provided the original is properly cited and derivative works building on this content are distributed under the same license.