

Laparoscopic Adrenalectomy

Craig N Parnaby and Patrick J O'Dwyer
*University of Glasgow, Glasgow
United Kingdom*

1. Introduction

Laparoscopic adrenalectomy (LA) was first described by Gagner et al in 1992 (Gagner et al., 1992). Since this time LA has become the procedure of choice for most adrenal pathologies. Multiple case-control studies have consistently demonstrated the benefits of LA compared to open adrenalectomy (OA) in terms of blood loss, analgesic requirements, postoperative complications, hospital stay and earlier return to normal activity.

2. Clinical presentation

Clinical presentation can often be non-specific or the patient can present after incidental adrenal gland imaging.

2.1 Conn's syndrome

Conn's syndrome is an aldosterone producing adenoma. The symptoms and signs are non-specific and include hypertension and hypokalaemia.

2.2 Cushing's syndrome

Symptoms and signs are related to excess cortisol production. These include: truncal obesity, decreased libido, thin skin, hypertension, hirsutism, depression, easy bruising, glucose intolerance and general weakness.

2.3 Pheochromocytoma

A pheochromocytoma is usually associated with excess production of catecholamines. The tumour can be suspected when a patient presents with: episodic episodes of headaches, sweating and palpitations with poorly controlled persistent or intermittent hypertension.

2.4 Incidentaloma

Adrenal incidentaloma is an adrenal tumour (≥ 1 cm) discovered on an imaging study for other unrelated pathologies. Over the last one and a half decades incidental adrenal gland imaging is increasingly performed as computed tomography for other abdominal pathologies has become common. This has led to an increase in patients with an incidental adrenal tumour referred for surgical and endocrine assessment (Saunders et al., 2004). Presently between 4-6% of the imaged population have incidentalomas (Bovio et al., 2006; Kloos et al., 1995). Almost all these lesions will be benign in a patient without a known history of cancer (Song et al., 2007; Young, 2000).

2.5 Adrenal metastasis

Adrenal metastasis should be considered in any patient with known extraadrenal malignancy and an isolated adrenal lesion >2cm or an adrenal mass increasing in size on serial imaging (Bonnet et al.,2008).

3. Assessment of adrenal tumours

Adrenal tumours are characterised by radiological and hormonal assessment.

3.1 Hormonal assessment

All adrenal tumours require a hormone evaluation. The hormone studies are performed to check for: phaeochromocytoma, hypercortisolism and hyperaldosteronism. However, there is no consensus regarding the best hormone diagnostic approach.

A suggested approach would be:

1. A phaeochromocytoma screen included a 24 hour urine collection for catecholamines (norepinephrine, epinephrine and dopamine) and metabolites (metanephrine, normetanephrine, vanillylmandelic acid).
2. Hypercortisolism assessment included an overnight dexamethasone suppression test. If positive a suppressed morning plasma ACTH and DHEAS level can be used to support the diagnosis (Nieman, 2010).
3. Hyperaldosteronism should be excluded in hypertensive patients. A screen included urea and electrolytes, plasma aldosterone-to-renin ratio. Adrenal vein sampling can be used for patients with suspected Conn's syndrome when imaging does not demonstrate an obvious adenoma.

3.2 Radiological assessment

The main modalities of choice in the evaluation of an adrenal tumour are computed tomography (CT) or magnetic resonance imaging (MRI). Most investigators use CT as the initial modality of choice as it is readily available and cheaper. Occasionally when CT or MRI studies are inconclusive patients are referred for combined positron emission tomography and computed tomography (PET-CT).

Adrenal tumours can be characterized using imaging alone. Characterisation of the adrenal tumour depends on a number of factors which include: morphology, perfusion differences and intracellular lipid concentration (Boland et al., 2008).

Morphology appearances which may suggest malignancy include: increased size, large necrotic areas, increased heterogeneity, irregular borders and local invasion. Available data suggests, at a size threshold of ≥ 4 cm the likelihood of malignancy doubles and is more than ninefold higher for tumours ≥ 8 cm (Sturgeon et al., 2006).

Lipid sensitive imaging by CT or MRI exploit the fact that most adenomas contain abundant intracellular fat where as almost all malignant lesions do not (Korobkin et al., 1996). It has been reported an unenhanced CT densitometry technique can effectively differentiate many adrenal adenomas from malignant adenomas. Figure 3.1 shows a typical adrenal adenoma from an unenhanced CT.

If the CT attenuation threshold is set at 10 Hounsfield units the sensitivity and specificity for characterising adenomas versus non-adenomas has been reported 71% and 98% respectively (Boland et al.,1998). This method has limitations which include: up to 30 % of adenomas are

lipid poor and most CT scans for other pathologies are contrast enhanced (Boland et al., 2008). Therefore, using attenuation values in these cases would be considered indeterminate or difficult to interpret.

More recently studies have reported improved results using CT perfusion washout scans or chemical shift MR imaging. For CT, an initial non-contrast or contrast enhanced scan is performed followed by a contrast enhanced examination after a variable delay (often 15 minutes). Benign lesions typically demonstrate more than 50% washout. A threshold enhancement washout value is then calculated. Chemical shift MR imaging utilises the different resonant frequencies of fat and water protons. Benign lesions typically show signal intensity decrease when compared with in-phase images. From the available data, CT perfusion washout scan appears to offer the highest sensitivity and specificity for adrenal adenoma characterization (Park et al., 2007).

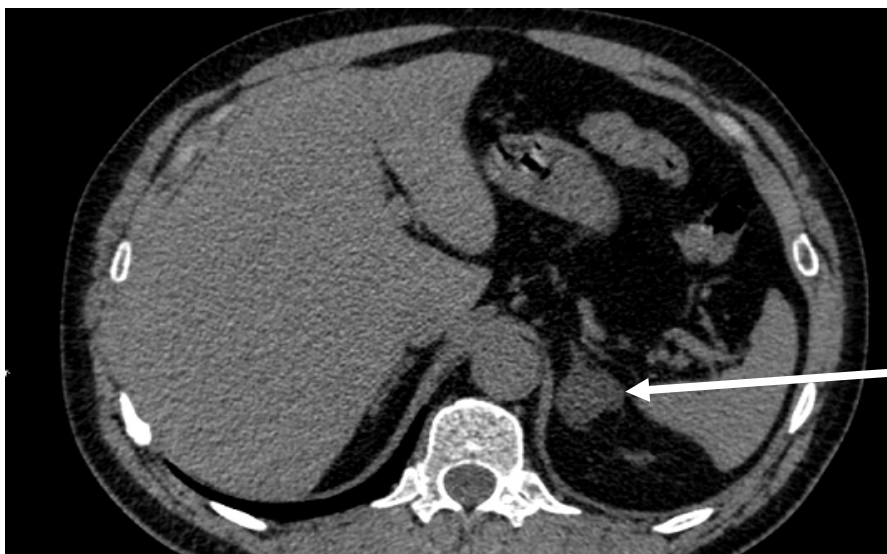

Fig. 3.1 Unenhanced CT of a left adrenal adenoma (arrow)

PET-CT allows adrenal lesion morphology and metabolic activity to be coregistered on the same image. This would allow a more accurate anatomic localization of any PET abnormalities. In current practice patients would only be referred for PET-CT rarely if CT or MR results are inconclusive (Boland et al., 2008).

¹²³I-MIBG is concentrated in catecholamine storage vesicles. A meta-iodobenzylguanidine (MIBG) scan can help identify pheochromocytoma, extra-adrenal pheochromocytoma and metastatic deposits from the pheochromocytoma.

Despite the above techniques, the only reliable imaging findings to differentiate between malignant and benign adrenal tumours remain the presence of regional invasion or metastatic disease.

3.3 Adrenal fine-needle aspiration (FNA)

Ultrasound or computed tomography guided FNA is unhelpful to distinguish between benign and malignant adrenal tumours due to the high false negative rate (Sasano et

al.,1995). The only potential use of FNA is to help diagnose metastasis when adrenal resection is not planned and detection would alter patient management (Lee et al., 1998).

3.4 Suggested hormonal and radiological approach to an adrenal tumour

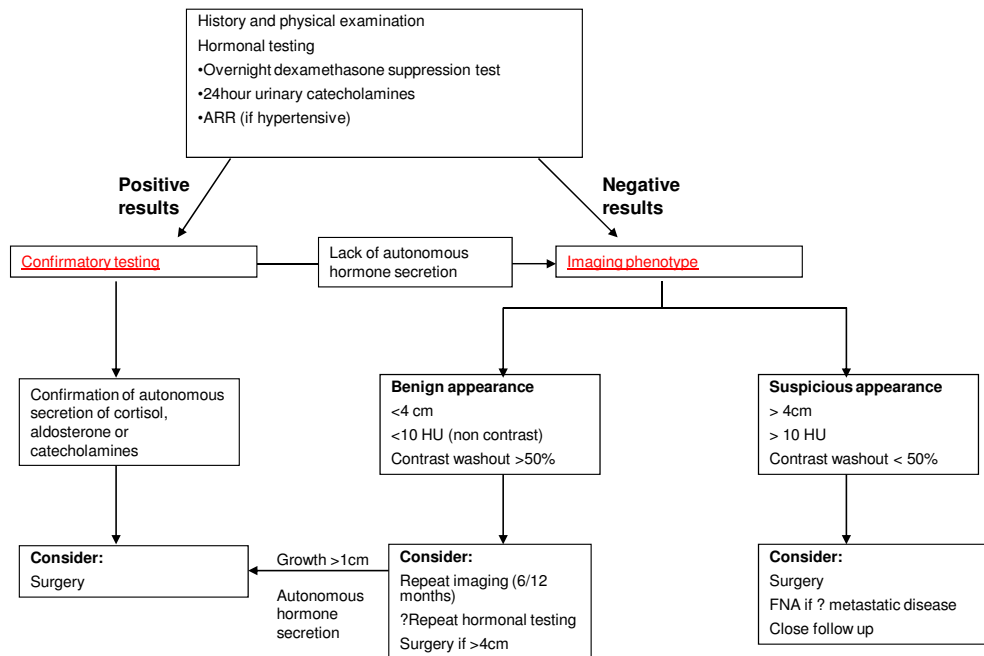


Fig. 3.2 gives a suggested algorithm for the evaluation of an adrenal tumour

4. Indication for adrenalectomy

Adrenalectomy is indicated for all hormonally active adrenal lesions, suspicion of adrenal malignancy on imaging (size ≥ 4 cm, local invasion, tumour heterogeneity, high attenuation and irregular tumour margins) and isolated adrenal metastases. Resection of non functioning adrenal tumours < 4 cm was indicated for patients with evidence of tumour growth on serial radiological imaging.

Management of a non functioning adrenal lesion remains debatable. All authors advocate resection of large ≥ 6 cm non functional adrenal tumours due to the increased risk of malignancy. No prospective controlled studies exist for the role of adrenalectomy for adrenal masses of 3-6 cm. Different authors have advocated size tumour thresholds of 3,4,5 and 6cm for resection of non functioning adrenal tumours (Duh, 2002; Thompson et al., 2003; Eldeiry & Garber, 2008). Sturgeon et al characterized the relationship between tumour size and malignancy risk compared the National Cancer Institute's Surveillance, Epidemiology, and End Results (SEER) database for adrenocortical carcinoma with their own experience with benign adrenal cortical adenomas from a similar time period. From the SEER database 457 adrenal cortical carcinomas were identified (376 had size data) and 47

patients from their own series with benign adrenal cortical adenomas. The authors found a tumour threshold of 4cm has a sensitivity and specificity of 96% and 52% for malignancy versus 90% and 80% for a tumour threshold of 6cm. The authors advocated that all tumours ≥ 4 cm should be surgically resected (Sturgeon et al., 2006).

4.1 Indications for laparoscopic adrenalectomy

Within a specialised centre, we feel the only contraindication to laparoscopy were large locally invasive adrenal carcinoma or the requirement of an additional open operation.

5. Perioperative management

5.1 Bilateral adrenalectomy

Bilateral adrenalectomy can be indicated following relapse after pituitary surgery, bilateral adrenal hyperplasia or hereditary pheochromocytoma. Perioperative intravenous hydrocortisone is required to prevent acute adrenal insufficiency. When oral intake has been established lifelong oral steroids are required. Increased doses are required at times of stress (eg trauma, infection).

5.2 Autonomous cortisol secretion

For patients with autonomous cortisol secretion after hormonal testing a perioperative 'stress dose' of hydrocortisone is recommended. A post operative in-patient short SYNACTHEN test would follow. If the test indicates adrenal insufficiency (low level of stimulated cortisol) steroid replacement should continue as this indicates hypothalamic-pituitary-adrenal (HPA) axis suppression. Patients are then reviewed as an out-patient to test for HPA axis recovery. If the test indicates adequate cortisol response (functioning HPA axis) steroid replacement therapy can stop.

5.3 Pheochromocytoma

The perioperative medical management of patients with pheochromocytomas is essential to reduce the effects of circulating catecholamines (Plouin et al., 2001; Kinney et al., 2000). These can include severe hypertension (systolic blood pressure >200 mmHg), tachycardia, arrhythmias and death. Immediate surgery is rarely essential.

Medical management aims to control blood pressure, heart rate and arrhythmias. Traditional preoperative regimens have included phenoxybenzamine (a long-acting non-selective alpha blocker) and propranolol (beta blocker) (Ross et al., 1967). Other agents have been used effectively including selective alpha blockers and calcium channel antagonists (Prys-Roberts & Farndon., 2002; Lebuffe et al., 2005). No randomised trial exists comparing the traditional regimen with other medical managements. Currently, the most effective perioperative drug regimen for patients undergoing pheochromocytoma resection is unknown.

Despite preoperative medical management, intraoperative tumour manipulation or introduction of pneumoperitoneum (laparoscopic adrenalectomy) may cause severe haemodynamic responses requiring further treatment with short acting alpha blockers (eg phentolamine) or short acting beta blockers (eg labetalol) (Joris et al., 1999; Tazuin-Fin et al., 2004).

The current regimen we use at the Western Infirmary, Glasgow, is as follows. At initial endocrine assessment, all patients with a suspected pheochromocytoma received oral

phenoxybenzamine as the primary alpha blocker (range 10-60mg/day). This was titrated to achieve a blood pressure measurement <160/90 mmHg. Patients were not routinely beta-blocked in the preoperative period. Hypertension was controlled in all phaeochromocytoma patients prior to elective resection.

All patients in the phaeochromocytoma group received an infusion of phenoxybenzamine (1mg kg⁻¹, a non selective long acting alpha blocker) the day before LA. Oral phenoxybenzamine was discontinued the day before theatre.

Arterial blood pressure is monitored using a radial arterial line. During surgery, episodes of hypertension (SBP>180mmHg) were treated with intravenous phentolamine (boluses 1 to 2mg) and/or labetalol (boluses 5 to 10mg). Tachycardia was treated with intravenous labetalol (boluses 5 to 10mg). Hypotension was treated with fluid boluses (crystalloid or colloid) and/or an intravenous vasopressor (metaraminol).

There is some concern that the persistent α -adrenoceptor blockade caused by phenoxybenzamine after resection can cause persistent hypotension resistant to adrenergic arteriolar constrictors and large volumes of intravascular fluid (Prys-Roberts et al., 2002). This has not been realised in our series. From January 1999 – January 2009, there were 42 consecutive LA performed for phaeochromocytoma. No patient experienced persistent hypotension (systolic blood pressure <80mmHg >10 minutes) in the recovery room period.

6. Laparoscopic adrenalectomy

Laparoscopic adrenalectomy was first described by Gagner et al in 1992 (Gagner et al., 1992). They described a successful anterior transabdominal approach in 3 patients (Cushing's syndrome, Cushing's disease and a phaeochromocytoma). The authors felt that LA may reduce morbidity, reduce analgesic requirements and reduce post operative stay when compared to open adrenalectomy (OA).

Since this time, multiple case-control studies have consistently demonstrated the benefits of LA compared OA in terms of blood loss, analgesic requirements, post operative complications, hospital stay and earlier return to normal activity for a variety of adrenal gland pathologies. Table 6.1 gives an overview of outcomes for studies comparing LA versus OA.

Despite the lack of Level 1 evidence comparing LA with OA, it seems unlikely randomized controlled trials will be performed. This is primarily due to the benefits consistently demonstrated in favour of LA.

Therefore, LA has become the procedure of choice for most adrenal gland pathologies in high-volume centres.

6.1 Laparoscopic operative technique

Laparoscopic approaches to the adrenal gland include the lateral transabdominal approach, the retroperitoneal approach or the anterior transabdominal approach.

The lateral transabdominal approach is the most popular approach in published case series. Reasons include: easiest to learn due to presence of an increased number of anatomical landmarks compared to the retroperitoneal approach and the ability to perform large adrenal tumour (≥ 6 cm) resection.

The retroperitoneal approach was first described in 1995 (Mercan et al., 1995) and subsequent series have since reported a safety and efficacy comparable to other laparoscopic approaches (Hanssen et al., 2006; Bonjer et al., 2000; Walz et al., 2006). Potential drawbacks to this approach include lack of familiarity amongst most general surgeons, limited working

Author	Year	No. of patients		Blood loss (mls)*		Analgesia requirements (LA versus OA)	Complications (%)		Length of stay (days)*	
		LA	OA	LA	OA		LA	OA	LA	OA
(Brunt et al., 1996)	1996	24	42	104	387	Reduced analgesia requirement	17	64	3.2	7.5
(MacGillivray, Shichman, Ferrer, & Malchoff, 1996)	1996	17	12	198	500	n.a.	21	56	3	7.9
(Staren & Prinz, 1996)	1996	21	20	n.a.		n.a.	n.a.		2.2	6.1
(G. B. Thompson et al., 1997)	1997	50	50	n.a.		Reduced analgesia requirement	6	72	3.1	5.7
(Jacobs, Goldstein, & Geer, 1997)	1997	19	19	109	263	n.a.	5	38	2.3	5.1
(Linon et al., 1997)	1997	18	147	n.a.		Reduced duration of PCA use	0	12	2.2	6.3
(Vargas et al., 1997)	1997	20	20	245	283	Reduced analgesia requirement	10	25	3.1	7.2
(Winfield, Hamilton, Bravo, & Novick, 1998)	1998	21	17	183	266	Reduced analgesia requirement	29	76	2.7	6.2
(Ting, Lo, & Lo, 1998)	1998	12	56	50	150	Reduced analgesia requirement	0	9	3	5
(Imai, Kikumori, Ohiwa, Mase, & Funahashi, 1999)	1999	40	40	40	172	Reduced analgesia requirement	5	50	12	18
(Dudley & Harrison, 1999)	1999	36	23	n.a.		n.a.	6	52	3.5	8.5
(Soares, Monchik, Migliori, & Amaral, 1999)	1999	12	7	132	278	Reduced analgesia requirement	8	0	2.1	5.4
(Schell, Talamini, & Udelsman, 1999)	1999	22	17	n.a.		n.a.	n.a.		1.7	6.7
(Shen et al., 1999)	1999	42	38	n.a.		n.a.	0	11	n.a.	
(Rayan & Hodin, 2000)	2000	19	48	n.a.		n.a.	3	60	1.5	6.3
(Hazzan et al., 2001)	2001	24	28	n.a.		Reduced analgesia requirement	16	39	4	7.5
(Ortega, Sala, Garcia, & Lledo, 2002)	2002	10	10	n.a.		n.a.	10	30	3.7	5.8

*Values are mean. LA, laparoscopic adrenalectomy; OA, open adrenalectomy; PCA, patient controlled analgesia; n.a., data not available

Table 6.1. Outcomes for laparoscopic adrenalectomy versus open adrenalectomy

space and the unsuitability for resection of large adrenal tumours ($\geq 6\text{cm}$). Potential advantages include: avoidance of the peritoneal cavity in patients with previous upper gastrointestinal surgery and no need to change position in bilateral adrenalectomy (if prone jackknife position used). From available studies, patient outcome remains similar compared to the lateral transabdominal approach for small-medium sized tumours.

The anterior transabdominal approach is practised infrequently and therefore the evidence favouring this approach is scarce. The main reason for its unpopularity is the increased dissection, adjacent structure retraction difficulties and longer operating times compared to other procedures.

In summary, the lateral transabdominal approach is favoured by most surgeons (including the current authors) followed by the retroperitoneal approach. Both techniques will be described in detail.

6.1.1 Lateral transabdominal laparoscopic adrenalectomy

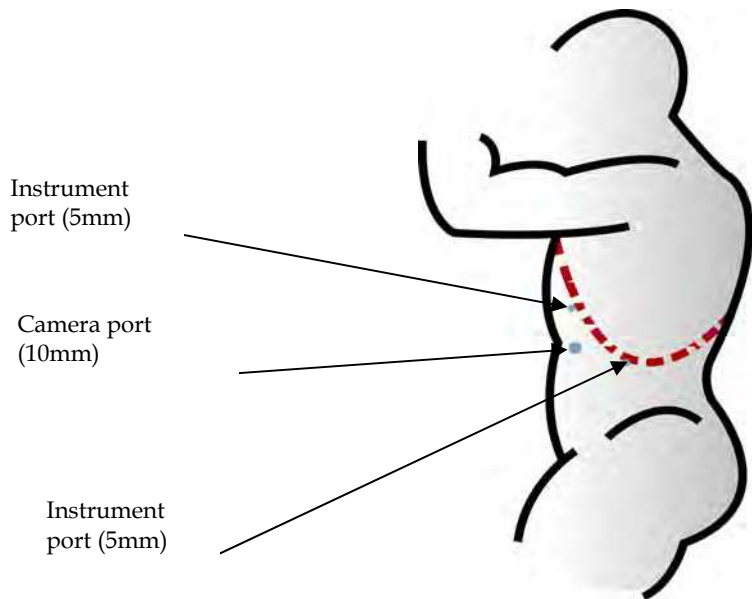
Patient positioning

The patient placed is in the lateral decubitus position with the operative side up. The table is broken to increase the space between the costal margin and iliac crest.

Left side

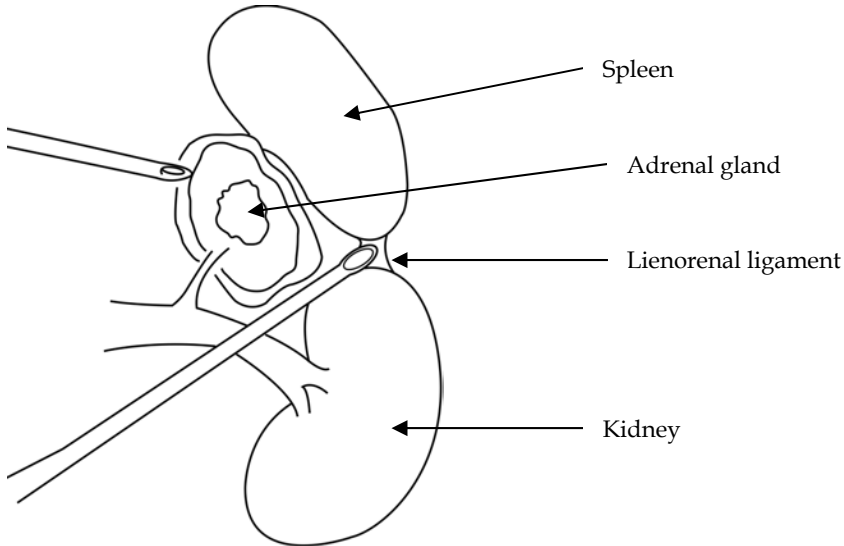
Step 1. Port placement

The port placements are illustrated in Figure 6.1. The middle port (10mm) is for a 30° camera and inserted using an open technique at a point just lateral to the rectus at the level of the umbilicus (a veress needle technique is an acceptable alternative). Two instrument ports (5mm, 5mm) are inserted under direct vision. One 5mm port is inserted parallel to the costal margin in the mid-clavicular line. The other 5mm port is inserted under the eleventh rib in the mid-axillary line. A further 5mm port is occasionally required to assist with splenic retraction.

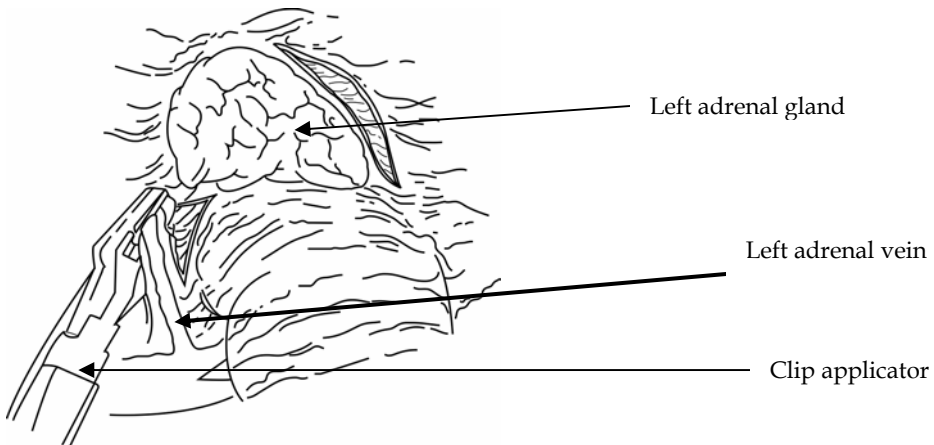


Step 2. Splenic flexure and spleen mobilisation

We use ultrasonic dissection to mobilise the splenic flexure of the colon and the lienorenal ligament of the spleen. The colon can then be displaced inferiorly and the spleen displaced medially (Figure 6.2). This allows access to the superior pole of the kidney and the adrenal gland.

**Step 3. Adrenal vein identification and division**

Gerota's fascia is then opened to expose the periadrenal fat. Dissection starts at the inferomedial aspect to allow early visualisation of the left renal and then the left adrenal vein (Figure 6.3). The adrenal vein is then divided between clips. Care is taken to ensure there is no duplicate main adrenal vein.



Step 4. Adrenal gland mobilisation

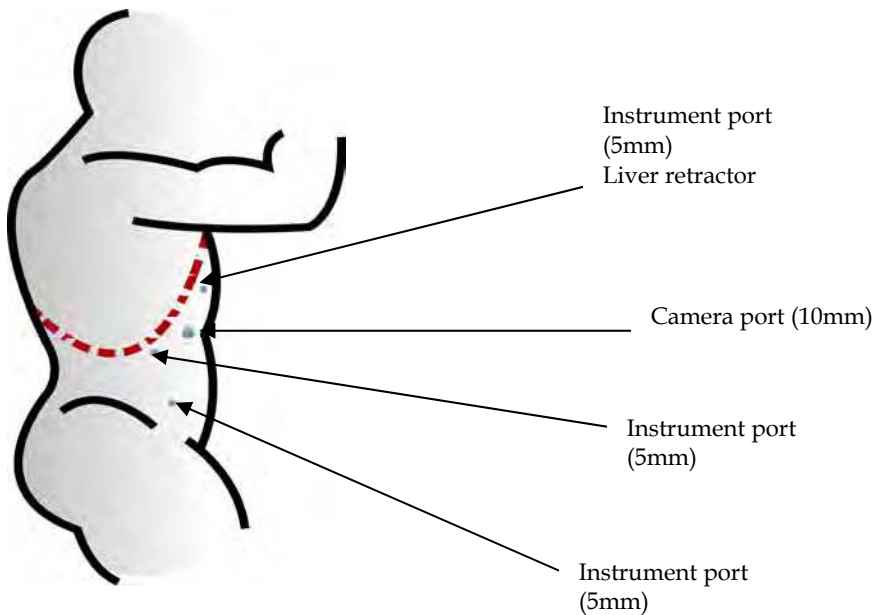
Avoid grasping the adrenal gland directly as it is fragile and will tear. The adrenal gland together with its surrounding fat are mobilised using ultrasonic dissection from its superior, lateral and posterior attachments. Multiple small adrenal arteries and veins will be encountered and these can all usually be divided using the harmonic scalpel.

Step 5. Adrenal gland removal

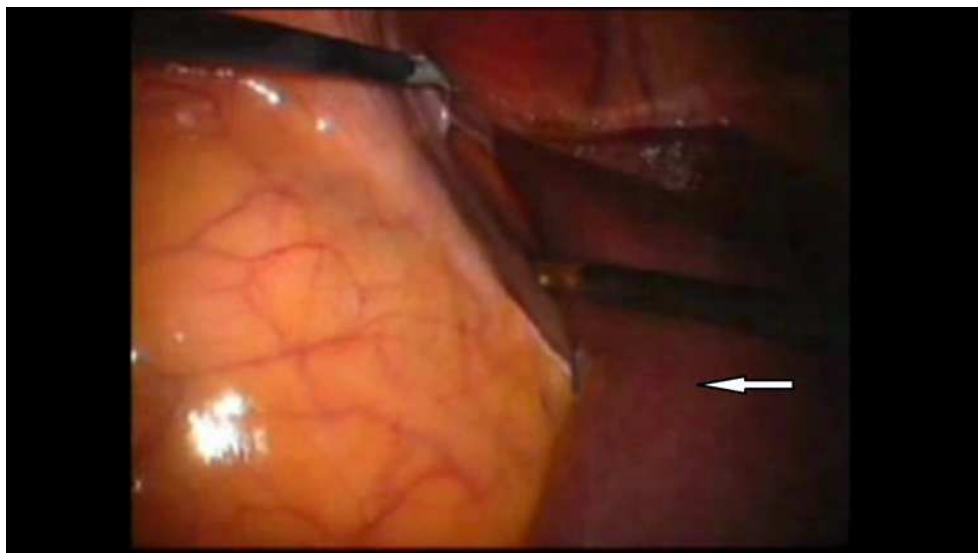
The adrenal gland is then removed via the camera port using an impermeable retrieval bag. The wound may require extension to allow retrieval.

Right side**Step 1.** Port placement

The port placements are illustrated in Figure 6.4. The camera port (10mm) is inserted just lateral to the rectus at the level of the umbilicus (30° laparoscope). Two 5mm instrument ports are placed as for the left side and a third is placed in the right iliac fossa. The most medial port is used to retract the right liver lobe. We have found an atraumatic grasper offers reasonable retraction.

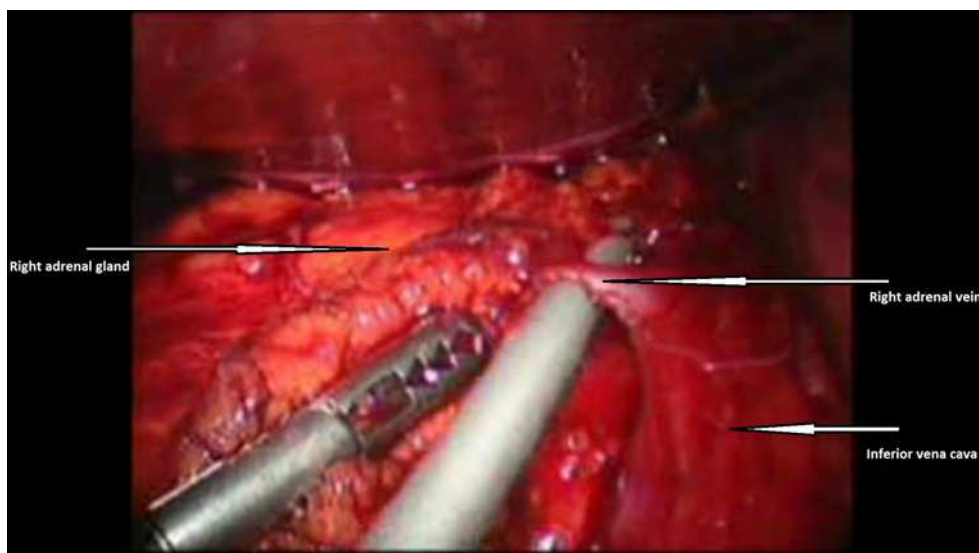
**Step 2.** Right liver lobe mobilisation

The right lobe of liver is mobilised from its lateral and posterior attachments and retracted (Figure 6.5). This allows access to the adrenal gland and inferior vena cava.



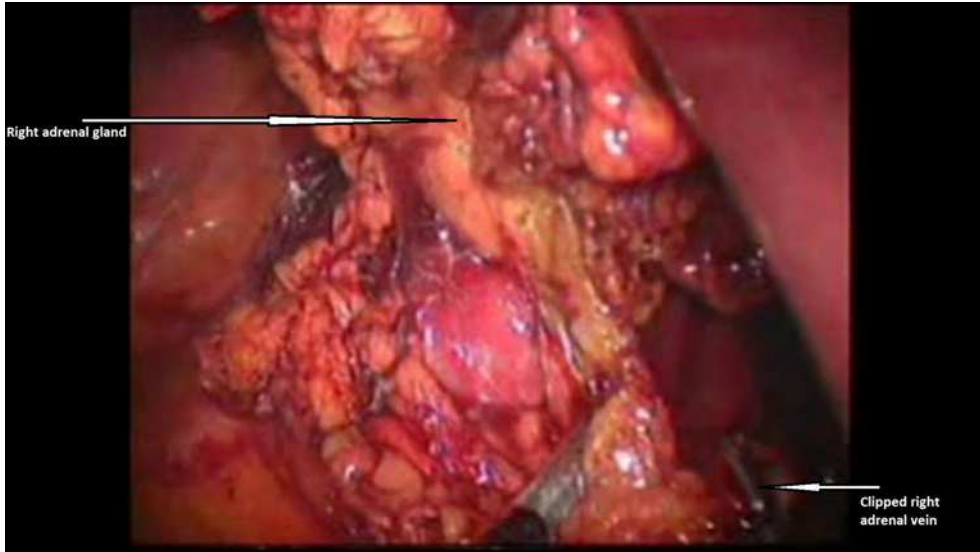
Step 3. Inferior vena cava and right adrenal vein

The peritoneum overlying the lateral edge of the inferior vena cava is divided carefully. The lateral border of the inferior vena cava is dissected from the inferior part of the liver to the origin of the right renal vein. The short main adrenal vein will be located between these points. After careful dissection the adrenal vein is divided between clips (Figure 6.6). Care should be taken as occasionally there can be a duplicate main adrenal vein.



Step 4. Adrenal gland mobilisation

The adrenal gland together with its surrounding fat is then completely mobilised using ultrasonic dissection (Figure 6.7).

**Step 5. Step 5 Adrenal gland removal**

The adrenal gland and tumour is removed in the same manner as for left adrenalectomy.

6.1.2 Lateral transabdominal technique modifications for larger adrenal tumours

The laparoscopic technique was modified for large adrenal tumours. On the right side, initial dissection of the inferior vena cava and the adrenal vein is often impossible due to tumour size. We like other authors (Henry et al.,2002) start dissecting laterally, superiorly and inferiorly (often alternating between these sites). This progressive mobilisation then allows access to the inferior vena cava and the procedure continues as described above. Similarly, on the left, initial adrenal vein dissection may not be possible due to tumour size. Primary lateral, superior, inferior dissection and mobilisation allows access to the adrenal vein. Often, it is not possible to insert these large tumours into a retrieval bag. In these cases a wound protector is inserted and the tumour is removed directly through the wound.

6.1.3 Retroperitoneal laparoscopic adrenalectomy

The following operative technique has been described and then developed by Walz and colleagues (Barczynski et al.,2007).

Patient position

Patient is placed in the prone jackknife position

Left side**Step 1. Port placement**

The initial 10-12mm camera port is placed using an open technique just below the 12th rib. The retroperitoneum was accessed by digital perforation of Gerota's fascia. A 30°

laparoscope was inserted and the retroperitoneal cavity was bluntly gently enlarged. Two 5mm ports were inserted, 4-5cm either side of the camera port. The retroperitoneal pressure was set at 20-25mmHg.

Step 2. Creation of a retroperitoneal space

A large retroperitoneal space is created using blunt dissection with the laparoscope and blunt dissectors. The adrenal gland tumour and upper pole of the kidney are identified.

Step 3. Initial adrenal gland mobilisation

The upper pole of the kidney is mobilised this allows access to the lower part of the adrenal gland. The inferomedial border of the adrenal gland is then carefully mobilised.

Step 4. Identification and division of main adrenal vein

The main adrenal vein is located lying below the adrenal gland and medial to the upper kidney pole. The adrenal vein is then clipped and divided.

Step 5. Completion of adrenal gland mobilisation

The adrenal gland is then fully mobilised using ultrasonic dissection. The final part of the operation is to mobilise the adrenal gland off the peritoneum. If the peritoneum is opened, it does not require subsequent closure.

Step 6. Extraction of the adrenal gland

The adrenal gland is removed through the middle port in an extraction bag. For large adrenal tumours the extraction site can be extended.

Right side

Step 1. Port placement

The camera and instrument ports are placed on the right side using the same technique as the left side.

Step 2. Creation of a retroperitoneal space

A large retroperitoneal space is created using blunt dissection with the laparoscope and blunt dissectors. The adrenal gland tumour and upper pole of the kidney are identified.

Step 3. Initial adrenal gland mobilisation

The upper pole of the kidney is mobilised this allows access to the lower part of the adrenal gland. The adrenal gland is then mobilised laterally around the top of the adrenal gland and continued medially. The adrenal gland arteries were divided by ultrasonic dissection and the posterior surface of the inferior vena cava was identified.

Step 4. Identification and division of main adrenal vein

The inferior vena cava is carefully demonstrated. The short adrenal vein can be seen running postero-laterally. The vein is then clearly identified, clipped and divided.

Step 5. Completion of adrenal gland mobilisation

The fatty tissue between the kidney and adrenal gland are separated. The anterior adhesions between the adrenal gland and peritoneum are separated allowing completion of the mobilisation.

Step 6. Extraction of the adrenal gland

The adrenal gland is removed through the middle port in an extraction bag. For large adrenal tumours the extraction site can be extended.

6.1.4 Uncertainty of laparoscopic adrenalectomy for large (≥ 6 cm) potentially malignant tumours

It is uncertain if the resection of large (≥ 6 cm) potentially malignant adrenal tumours is appropriate due to concern over incomplete resection and local recurrence. However, an

increasing number of series have demonstrated the safety of this approach together with low rates of local recurrence. Table 6.2 shows the outcome of studies for the laparoscopic removal of large adrenal tumours.

Author	LA≥6cm over Total LA*	No of patients with malignancy	Tumour size (cm)†	Conversion for large tumours	Incomplete resection	Local recurrence	Mets	Follow-up† (months)
(Henry et al., 2002)	19/233 (8%)	6 (6)	7 (6-8)	2	0	0	1	35 (17-59)
(MacGillivray, Whalen, Malchoff, Oppenheim, & Shichman, 2002)	12/60 (20%)	3 (1)	8 (6-12)	0	0	0	1	24.5 (4-42)
(Walz et al., 2005)	33/429 (8%)	6 (2)	7.3 (2.1)¶	2	n.a.	2	5	n.a.
(Palazzo et al., 2006)	19/391 (5%)	3(3)	6.5 (6-8)	0	n.a.	1	2	25 (13-46)
(Soon et al., 2008)	16/140 (11%)	3 (3)	n.a.	4	n.a.	0	1	18 (n.a.)
(Ramacciato et al., 2008)	20/107† (19%)	4 (2)	8 (7-9)	3	0	0	1	n.a.
Authors series (1999-2009)	69/176 (39%)	20 (10)	8 (6.5-9)	6	0	0	3	41 (22-76)

* Values in parentheses are percentage of LA for tumours ≥6cm or ≥7cm in the case series

† Tumours are 7cm or larger

° Values in parentheses are numbers of primary adrenal cortical carcinomas

† Values are median (IQR) unless stated

¶ Value is mean (range)n.a. , data not available

Table 6.2. Laparoscopic adrenalectomy for large adrenal tumours

Currently, we feel like other authors, adopting a policy of LA only for tumours <6cm or highly selecting those with tumours >6cm would prevent a large number of patients receiving the benefits of the laparoscopic approach. Even in the presence of malignancy, laparoscopic resection can achieve very favourable oncological outcomes after long-term follow-up. The laparoscopic approach gives an excellent view of large tumours and radical

resection with a low blood loss can be performed without the need for large abdominal or thoracoabdominal incisions in these patients.

In our series (1999-2009), 69 out of 176 LA were performed for adrenal masses ≥ 6 cm. There were six conversions in this group, mainly for local tumour invasion. Post operative stay for patients with adrenal tumours ≥ 6 cm was a day longer compared to those < 6 cm (3 days versus 2 days). After a median follow up of 41 months, there has been no clinical or radiological evidence of local recurrence in any patient that has had an attempted laparoscopic approach.

6.2 Laparoscopic subtotal adrenalectomy

Laparoscopic subtotal adrenalectomy has emerged as a feasible option allowing either bilateral adrenal medulla resection or partial adrenal cortex resection in patients with a single remaining adrenal gland (Hardy & Lennard,2008). Case series have reported the procedure is most strongly indicated in patients with bilateral phaeochromocytoma (familial) or patients with aldosterone or cortisol producing tumours who have had previous contralateral adrenalectomy. This has been shown to preserve endogenous steroid production and allow independence from oral steroid therapy in the majority of patients (Brauckhoff et al.,2003).

Selection for subtotal adrenalectomy has generally been performed in small, well circumscribed, peripherally located lesions. It remains unclear from the literature, the true incidence of this procedure as totality of adrenalectomy practice is rarely reported. Results from small studies have reported no incomplete resections or local recurrences (follow-up range:3 months - 3 years) (Walz et al.,1998;Kok&Yapp,2002).

7. Follow-up

7.1 Phaeochromocytomas

Follow-up should be performed indefinitely as the phaeochromocytoma can recur. Follow-up investigations include: urinary catecholamines, CT, MRI and MIBG.

7.2 Adrenocortical carcinoma

For functioning adrenocortical carcinomas, hormonal markers should be measured every 3 months for early detection of tumour recurrence.

Restage by CT (chest, abdomen) every 3-6 months for at least 5 years. This is because recurrent surgical resection is a valid treatment option.

7.3 Conn's syndrome

Following resection, patient is followed up after six weeks. The blood pressure, urea and electrolytes and plasma aldosterone-to-renin ratio are checked. If the results are satisfactory the patients can often be discharged.

7.4 Cushing's syndrome

For patients with Cushing's syndrome (ACTH-independent) resolution of cortisol excess is checked in the postoperative stay. However, the majority of patients remain on steroids and are reviewed in clinic to assess recovery of HPA axis. If this is satisfactory then steroids can be stopped. Postoperative imaging is not usually required.

8. Conclusions

Within an experienced centre (consisting of endocrinologists, anaesthetists and surgeons), laparoscopic adrenalectomy has become the procedure of choice for the vast majority of adrenal pathologies. A large number of case series have consistently demonstrated the improved outcomes of LA compared to the open procedure. We feel, the only contraindications to LA were locally invasive adrenal mass on CT or MRI or the requirement of an additional open surgical procedure. Currently there is no evidence to suggest one laparoscopic approach is better than another. However, the lateral transabdominal approach is currently recommended for adrenal tumours ≥ 6 cm.

9. References


- Barczynski M, Konturek A, Golkowski F, Cichon S, Huszno B, Peitgen K, Walz MK. (2006). Posterior retroperitoneoscopic adrenalectomy: a comparison between the initial experience in the invention phase and introductory phase of the new surgical technique. *World J Surg*, 31,65-71.
- Boland, G. W., Blake, M. A., Hahn, P. F., & Mayo-Smith, W. W. (2008). Incidental adrenal lesions: Principles, techniques, and algorithms for imaging characterization. *Radiology*, 249(3), 756-775.
- Boland, G. W., Lee, M. J., Gazelle, G. S., Halpern, E. F., McNicholas, M. M., & Mueller, P. R. (1998). Characterization of adrenal masses using unenhanced CT: An analysis of the CT literature. *AJR.American Journal of Roentgenology*, 171(1), 201-204.
- Bonjer, H. J., Sorm, V., Berends, F. J., Kazemier, G., Steyerberg, E. W., de Herder, W. W., et al. (2000). Endoscopic retroperitoneal adrenalectomy: Lessons learned from 111 consecutive cases. *Annals of Surgery*, 232(6), 796-803.
- Bonnet, S., Gaujoux, S., Leconte, M., Thillois, J. M., Tissier, F., & Dousset, B. (2008). Laparoscopic adrenalectomy for metachronous metastasis from renal cell carcinoma. *World Journal of Surgery*, 32(8), 1809-1814.
- Bovio, S., Cataldi, A., Reimondo, G., Sperone, P., Novello, S., Berruti, A., et al. (2006). Prevalence of adrenal incidentaloma in a contemporary computerized tomography series. *Journal of Endocrinological Investigation*, 29(4), 298-302.
- Brauckhoff, M., Gimm, O., Thanh, P. N., Bar, A., Ukkat, J., Brauckhoff, K., et al. (2003). Critical size of residual adrenal tissue and recovery from impaired early postoperative adrenocortical function after subtotal bilateral adrenalectomy. *Surgery*, 134(6), 1020-1027.
- Brauckhoff, M., Stock, K., Stock, S., Lorenz, K., Sekulla, C., Brauckhoff, K., et al. (2008). Limitations of intraoperative adrenal remnant volume measurement in patients undergoing subtotal adrenalectomy. *World Journal of Surgery*, 32(5), 863-872.
- Brauckhoff, M., Thanh, P. N., Gimm, O., Bar, A., Brauckhoff, K., & Dralle, H. (2003). Functional results after endoscopic subtotal cortical-sparing adrenalectomy. *Surgery Today*, 33(5), 342-348.
- Brunt, L. M., Doherty, G. M., Norton, J. A., Soper, N. J., Quasebarth, M. A., & Moley, J. F. (1996). Laparoscopic adrenalectomy compared to open adrenalectomy for benign adrenal neoplasms. *Journal of the American College of Surgeons*, 183(1), 1-10.

- Dudley, N. E., & Harrison, B. J. (1999). Comparison of open posterior versus transperitoneal laparoscopic adrenalectomy. *British Journal of Surgery*, 86(5), 656-660.
- Duh, Q. Y. (2002). Adrenal incidentalomas. *British Journal of Surgery*, 89(11), 1347-1349.
- Eldeiry, L. S., & Garber, J. R. (2008). Adrenal incidentalomas, 2003 to 2005: Experience after publication of the national institutes of health consensus statement. *Endocrine Practice*, 14(3), 279-284.
- Gagner, M., Lacroix, A., & Bolt, E. (1992). Laparoscopic adrenalectomy in cushing's syndrome and pheochromocytoma. *New England Journal of Medicine*, 327(14), 1033-1033.
- Gagner, M., Pomp, A., Heniford, B. T., Pharand, D., & Lacroix, A. (1997). Laparoscopic adrenalectomy: Lessons learned from 100 consecutive procedures. *Annals of Surgery*, 226(3), 238-246.
- Hanssen, W. E., Kuhry, E., Casseres, Y. A., de Herder, W. W., Steyerberg, E. W., & Bonjer, H. J. (2006). Safety and efficacy of endoscopic retroperitoneal adrenalectomy. *British Journal of Surgery*, 93(6), 715-719.
- Hardy, R., & Lennard, T. W. (2008). Subtotal adrenalectomy. *British Journal of Surgery*, 95(9), 1075-1076.
- Hazzan, D., Shiloni, E., Golijanin, D., Jurim, O., Gross, D., & Reissman, P. (2001). Laparoscopic vs open adrenalectomy for benign adrenal neoplasm. *Surgical Endoscopy*, 15(11), 1356-1358.
- Henry, J. F., Sebag, F., Iacobone, M., & Mirallie, E. (2002). Results of laparoscopic adrenalectomy for large and potentially malignant tumors. *World Journal of Surgery*, 26(8), 1043-1047.
- Imai, T., Kikumori, T., Ohiwa, M., Mase, T., & Funahashi, H. (1999). A case-controlled study of laparoscopic compared with open lateral adrenalectomy. *American Journal of Surgery*, 178(1), 50-53.
- Jacobs, J. K., Goldstein, R. E., & Geer, R. J. (1997). Laparoscopic adrenalectomy. A new standard of care. *Annals of Surgery*, 225(5), 495-501.
- Joris, J. L., Hamoir, E. E., Hartstein, G. M., Meurisse, M. R., Hubert, B. M., Charlier, C. J., et al. (1999). Hemodynamic changes and catecholamine release during laparoscopic adrenalectomy for pheochromocytoma. *Anesthesia & Analgesia*, 88(1), 16-21.
- Kinney, M. A., Warner, M. E., vanHeerden, J. A., Horlocker, T. T., Young, W. F., Jr, Schroeder, D. R., et al. (2000). Perianesthetic risks and outcomes of pheochromocytoma and paraganglioma resection. *Anesthesia & Analgesia*, 91(5), 1118-1123.
- Kloos, R. T., Gross, M. D., Francis, I. R., Korobkin, M., & Shapiro, B. (1995). Incidentally discovered adrenal masses. *Endocrine Reviews*, 16(4), 460-484.
- Kok, K. Y., & Yapp, S. K. (2002). Laparoscopic adrenal-sparing surgery for primary hyperaldosteronism due to aldosterone-producing adenoma. *Surgical Endoscopy*, 16(1), 108-111.
- Korobkin, M., Giordano, T. J., Brodeur, F. J., Francis, I. R., Siegelman, E. S., Quint, L. E., et al. (1996). Adrenal adenomas: Relationship between histologic lipid and CT and MR findings. *Radiology*, 200(3), 743-747.

- Lebuffe, G., Dosseh, E. D., Tek, G., Tytgat, H., Moreno, S., Tavernier, B., et al. (2005). The effect of calcium channel blockers on outcome following the surgical treatment of pheochromocytomas and paragangliomas. *Anaesthesia*, 60(5), 439-444.
- Lee, J. E., Evans, D. B., Hickey, R. C., Sherman, S. I., Gagel, R. F., Abbruzzese, M. C., et al. (1998). Unknown primary cancer presenting as an adrenal mass: Frequency and implications for diagnostic evaluation of adrenal incidentalomas. *Surgery*, 124(6), 1115-1122.
- Linou, D. A., Stylopoulos, N., Boukis, M., Souvatzoglou, A., Raptis, S., & Papadimitriou, J. (1997). Anterior, posterior, or laparoscopic approach for the management of adrenal diseases?. *American Journal of Surgery*, 173(2), 120-125.
- MacGillivray, D. C., Shichman, S. J., Ferrer, F. A., & Malchoff, C. D. (1996). A comparison of open vs laparoscopic adrenalectomy. *Surgical Endoscopy*, 10(10), 987-990.
- MacGillivray, D. C., Whalen, G. F., Malchoff, C. D., Oppenheim, D. S., & Shichman, S. J. (2002). Laparoscopic resection of large adrenal tumors. *Annals of Surgical Oncology*, 9(5), 480-485.
- Mercan, S., Seven, R., Ozarmagan, S., & Tezelman, S. (1995). Endoscopic retroperitoneal adrenalectomy. *Surgery*, 118(6), 1071-1075.
- Nieman LK. (2010). Approach to the patient with an adrenal incidentaloma. *J Clin Endocrinol Metab*, 95(9), 4106-4113.
- Ortega, J., Sala, C., Garcia, S., & Lledo, S. (2002). Cost-effectiveness of laparoscopic vs open adrenalectomy: Small savings in an expensive process. *Journal of Laparoendoscopic & Advanced Surgical Techniques. Part A*, 12(1), 1-5.
- Palazzo, F. F., Sebag, F., Sierra, M., Ippolito, G., Souteyrand, P., & Henry, J. F. (2006). Long-term outcome following laparoscopic adrenalectomy for large solid adrenal cortex tumors. *World Journal of Surgery*, 30(5), 893-898.
- Park, B. K., Kim, C. K., Kim, B., & Lee, J. H. (2007). Comparison of delayed enhanced CT and chemical shift MR for evaluating hyperattenuating incidental adrenal masses. *Radiology*, 243(3), 760-765.
- Plouin, P. F., Duclos, J. M., Soppelsa, F., Boubilil, G., & Chatellier, G. (2001). Factors associated with perioperative morbidity and mortality in patients with pheochromocytoma: Analysis of 165 operations at a single center. *Journal of Clinical Endocrinology & Metabolism*, 86(4), 1480-1486.
- Prys-Roberts, C. (2000). Pheochromocytoma--recent progress in its management. *British Journal of Anaesthesia*, 85(1), 44-57.
- Prys-Roberts, C., & Farndon, J. R. (2002). Efficacy and safety of doxazosin for perioperative management of patients with pheochromocytoma. *World Journal of Surgery*, 26(8), 1037-1042.
- Ramacciato, G., Mercantini, P., La Torre, M., Di Benedetto, F., Ercolani, G., Ravaioli, M., et al. (2008). Is laparoscopic adrenalectomy safe and effective for adrenal masses larger than 7 cm?. *Surgical Endoscopy*, 22(2), 516-521.
- Rayan, S. S., & Hodin, R. A. (2000). Short-stay laparoscopic adrenalectomy. *Surgical Endoscopy*, 14(6), 568-572.

- Ross, E. J., Prichard, B. N., Kaufman, L., Robertson, A. I., & Harries, B. J. (1967). Preoperative and operative management of patients with pheochromocytoma. *British Medical Journal*, 1(5534), 191-198.
- Sasano, H., Shizawa, S., & Nagura, H. (1995). Adrenocortical cytopathology. *American Journal of Clinical Pathology*, 104(2), 161-166.
- Saunders, B. D., Wainess, R. M., Dimick, J. B., Upchurch, G. R., Doherty, G. M., & Gauger, P. G. (2004). Trends in utilization of adrenalectomy in the united states: Have indications changed?. *World Journal of Surgery*, 28(11), 1169-1175.
- Schell, S. R., Talamini, M. A., & Udelsman, R. (1999). Laparoscopic adrenalectomy for nonmalignant disease: Improved safety, morbidity, and cost-effectiveness. *Surgical Endoscopy*, 13(1), 30-34.
- Shen, W. T., Lim, R. C., Siperstein, A. E., Clark, O. H., Schecter, W. P., Hunt, T. K., et al. (1999). Laparoscopic vs open adrenalectomy for the treatment of primary hyperaldosteronism. *Archives of Surgery*, 134(6), 628-631.
- Soares, R. L., Jr, Monchik, J., Migliori, S. J., & Amaral, J. F. (1999). Laparoscopic adrenalectomy for benign adrenal neoplasms. *Surgical Endoscopy*, 13(1), 40-42.
- Song, J. H., Chaudhry, F. S., & Mayo-Smith, W. W. (2007). The incidental indeterminate adrenal mass on CT (> 10 H) in patients without cancer: Is further imaging necessary? follow-up of 321 consecutive indeterminate adrenal masses. *AJR.American Journal of Roentgenology*, 189(5), 1119-1123.
- Soon, P. S., Yeh, M. W., Delbridge, L. W., Bambach, C. P., Sywak, M. S., Robinson, B. G., et al. (2008). Laparoscopic surgery is safe for large adrenal lesions. *European Journal of Surgical Oncology*, 34(1), 67-70.
- Staren, E. D., & Prinz, R. A. (1996). Adrenalectomy in the era of laparoscopy. *Surgery*, 120(4), 706-709.
- Sturgeon, C., Shen, W. T., Clark, O. H., Duh, Q. Y., & Kebebew, E. (2006). Risk assessment in 457 adrenal cortical carcinomas: How much does tumor size predict the likelihood of malignancy?. *Journal of the American College of Surgeons*, 202(3), 423-430.
- Tauzin-Fin, P., Sesay, M., Gosse, P., & Ballanger, P. (2004). Effects of perioperative alpha1 block on haemodynamic control during laparoscopic surgery for pheochromocytoma. *British Journal of Anaesthesia*, 92(4), 512-517.
- Thompson, G. B., Grant, C. S., van Heerden, J. A., Schlinkert, R. T., Young, W. F., Jr, Farley, D. R., et al. (1997). Laparoscopic versus open posterior adrenalectomy: A case-control study of 100 patients. *Surgery*, 122(6), 1132-1136.
- Thompson, G. B., & Young, W. F., Jr. (2003). Adrenal incidentaloma. *Current Opinion in Oncology*, 15(1), 84-90.
- Ting, A. C., Lo, C. Y., & Lo, C. M. (1998). Posterior or laparoscopic approach for adrenalectomy. *American Journal of Surgery*, 175(6), 488-490.
- Vargas, H. I., Kavoussi, L. R., Bartlett, D. L., Wagner, J. R., Venzon, D. J., Fraker, D. L., et al. (1997). Laparoscopic adrenalectomy: A new standard of care. *Urology*, 49(5), 673-678.
- Walz, M. K., Alesina, P. F., Wenger, F. A., Deligiannis, A., Szuczik, E., Petersenn, S., et al. (2006). Posterior retroperitoneoscopic adrenalectomy--results of 560 procedures in 520 patients. *Surgery*, 140(6), 943-948.

- Walz, M. K., Peitgen, K., Saller, B., Giebler, R. M., Lederbogen, S., Nimtz, K., et al. (1998). Subtotal adrenalectomy by the posterior retroperitoneoscopic approach. *World Journal of Surgery*, 22(6), 621-626.
- Walz, M. K., Petersenn, S., Koch, J. A., Mann, K., Neumann, H. P., & Schmid, K. W. (2005). Endoscopic treatment of large primary adrenal tumours. *British Journal of Surgery*, 92(6), 719-723.
- Winfield, H. N., Hamilton, B. D., Bravo, E. L., & Novick, A. C. (1998). Laparoscopic adrenalectomy: The preferred choice? A comparison to open adrenalectomy. *Journal of Urology*, 160(2), 325-329.
- Young, W. F., Jr. (2000). Management approaches to adrenal incidentalomas. A view from rochester, minnesota. *Endocrinology & Metabolism Clinics of North America*, 29(1), 159-185.



Laparoscopy - An Interdisciplinary Approach

Edited by Dr. Ivo Meinhold-Heerlein

ISBN 978-953-307-299-9

Hard cover, 146 pages

Publisher InTech

Published online 12, September, 2011

Published in print edition September, 2011

Over the last decades an enormous amount of technical advances was achieved in the field of laparoscopy. Many surgeons with surgical, urological, or gynaecological background have contributed to the improvement of this surgical approach which today has an important and fixed place in the daily routine. It is therefore comprehensible to compose a book entitled laparoscopy serving as a reference book for all three disciplines. Experts of each field have written informative chapters which give practical information about certain procedures, indication of surgery, complications and postoperative outcome. Wherever necessary, the appropriate chapter is illustrated by drawings or photographs. This book is advisable for both beginner and advanced surgeon and should find its place in the libraries of all specialties "surgery, urology, and gynecology.

How to reference

In order to correctly reference this scholarly work, feel free to copy and paste the following:

Craig N Parnaby and Patrick J O'Dwyer (2011). Laparoscopic Adrenalectomy, Laparoscopy - An Interdisciplinary Approach, Dr. Ivo Meinhold-Heerlein (Ed.), ISBN: 978-953-307-299-9, InTech, Available from: <http://www.intechopen.com/books/laparoscopy-an-interdisciplinary-approach/laparoscopic-adrenalectomy>

INTECH
open science | open minds

InTech Europe

University Campus STeP Ri
Slavka Krautzeka 83/A
51000 Rijeka, Croatia
Phone: +385 (51) 770 447
Fax: +385 (51) 686 166
www.intechopen.com

InTech China

Unit 405, Office Block, Hotel Equatorial Shanghai
No.65, Yan An Road (West), Shanghai, 200040, China
中国上海市延安西路65号上海国际贵都大饭店办公楼405单元
Phone: +86-21-62489820
Fax: +86-21-62489821

© 2011 The Author(s). Licensee IntechOpen. This chapter is distributed under the terms of the [Creative Commons Attribution-NonCommercial-ShareAlike-3.0 License](#), which permits use, distribution and reproduction for non-commercial purposes, provided the original is properly cited and derivative works building on this content are distributed under the same license.