

Ultrasound in Abdominal Aortic Aneurysm

Reidar Brekken^{1,2}, Torbjørn Dahl^{1,3} and Toril A. N. Hernes^{1,2}

¹Norwegian University of Science and Technology, Dept. Circulation and Medical Imaging

²SINTEF, Dept. Medical Technology

³St. Olav's Hospital, The University Hospital of Trondheim

Norway

1. Introduction

Formation and growth of abdominal aortic aneurysms (AAA) may lead to rupture resulting in life threatening haemorrhage. Elective treatment of asymptomatic AAA, either as open surgery or endovascular repair, is recommended when the maximum diameter of the aneurysm exceeds 50-55mm or increases rapidly (Brewster et al., 2003), whereas smaller aneurysms are recommended kept under surveillance. Risk factor modification, such as cessation of smoking, treatment of hypertension and pharmaceutical inhibition of inflammation and protease, could reduce growth in aneurysms kept under surveillance (Baxter et al., 2008; Chaikof et al., 2009; Moll et al., 2011).

The size and growth of the aneurysm is monitored using different radiological imaging modalities. Imaging is also important during image guided endovascular repair, and in follow-up examinations after treatment. In this chapter, we describe how ultrasound is currently used in management of abdominal aortic aneurysm, and discuss future potential and challenges of ultrasound for assisting in improved clinical management with regard to patient selection, treatment alternatives and follow-up.

2. Ultrasound

Ultrasound does not depend on ionizing radiation, and it is relatively inexpensive compared with other imaging modalities. Ultrasound equipment is also portable, and can be used both bedside as well as outside of hospitals. Ultrasound is a fast imaging modality, and presents images in real-time. Therefore, in addition to imaging anatomical structures, ultrasound can also be used for studying function by investigating blood flow or organ motion, e.g. dynamics of the heart. Being a real-time imaging modality, ultrasound further provides an opportunity to interactively investigate the anatomy and potential pathologies. Ultrasound has a certain operator dependency; specifically that it requires skills both to obtain good images, and to interpret the images. Also, in some cases, the image quality suffers from limited view due to bowel gas or obesity. Practical training and knowledge of principles and artefacts is therefore beneficial for successful application of ultrasound.

The physical foundation for medical ultrasound is high frequency waves that are transmitted into the body. The waves are reflected from structures within the body, and the echoes are analysed for retrieving diagnostic information. **Structural imaging** was first obtained using amplitude (A) mode, directly visualizing the amplitude of the echo as a

function of depth. Brightness (B)-line displays the amplitudes as grayscale values. In motion (M) mode imaging, several B-lines in the same direction are drawn consecutively as a function of time for examination of dynamical properties. By combining spatially adjacent B-lines, two-dimensional (2D) B-mode images are obtained and can be visualized in real time. More recently, new ultrasound probes and visualization techniques have made three-dimensional (3D) imaging of anatomical structures possible. 3D images (or volumes) are obtained either by mechanically sweeping the scanplane in the elevation direction to cover a 3D sector, or in real-time by steering the ultrasound beam in 3D using 2D transducer arrays. In addition to structural imaging, ultrasound can be used for extracting information about function. One example is imaging of blood flow. The **Doppler** effect can be measured with ultrasound to quantify the velocity of blood and moving tissue. In short, the Doppler effect refers to a shift in frequency of a signal that is transmitted (or reflected) from a moving object. The frequency shift is proportional to the velocity of the moving object. By detecting the shift in frequency content of a reflected ultrasound signal relative to the transmitted signal, the velocity of the moving object can therefore be estimated. The velocity information can be presented either by visualizing the Doppler frequency spectrum as a function of time, or by visualizing the velocity as a colour-coded overlay on the B-mode image (Colour Doppler or Duplex imaging). Another example of functional imaging is **strain imaging or elastography**, which displays a quantitative measure of the response of tissues under compression (Garra, 2007; Ophir et al., 1991). The compression can be due to natural motion, e.g. heart contractions or pulsating arteries, or enforced by an external compression, e.g. movement of the ultrasound probe. The ultrasound pulse itself can also be used for enforcing compression, in which case the method is often referred to as artificial radiation force imaging (ARFI) (Nightingale et al., 2002). Clinical applications of strain imaging and elastography include assessment of left ventricular myocardial function, and differentiation of stiff tumours from surrounding normal tissues. Examples of B-mode and colour Doppler images of an abdominal aorta are shown in Fig. 1.

For some applications, it is beneficial to use contrast imaging by injecting **contrast agents** (microbubbles) in the blood to increase the echo obtained from blood. The microbubbles respond differently than human tissue under influence of the ultrasound pulse, thus allowing for specialized detection methods separating the contrast agents from surrounding tissues (Frinking et al., 2000; Hansen & Angelsen, 2009). Contrast agents may provide better images of the ventricles of the heart and larger blood vessels as well as visualization of microcirculation, which is interesting for detection of e.g. myocardial perfusion (Lindner et al., 2000). Targeted microbubbles that attach to specific molecular signatures may provide new possibilities for diagnosis of various diseases, e.g. tumours or atherosclerosis (Anderson et al., 2011; ten Kate et al., 2010).

Ultrasound is most commonly used for diagnostic purposes, but may also be used therapeutically. One application is ultrasound imaging for guidance during surgery, biopsy or needle insertion. Another therapeutic use of ultrasound is **high intensity focused ultrasound (HIFU)**, exploiting that ultrasound, being mechanical waves, can be used for focused delivery of high energies. Sonic waves (extracorporeal shock wave lithotripsy) can be used for destruction of kidney stones (Gallucci et al., 2001). Other applications include focused ultrasound surgery (FUS), thrombolysis and hemostasis (Kim et al., 2008; Vaezy et al., 2001). Burgess et al. (2007) reported HIFU for hemostasis in the posterior liver of 17 pigs. The probe was placed on the anterior surface of the liver and aimed at the bleeding. 17 became hemostatic, whereas 7 controls (sham-HIFU) did not become hemostatic, illustrating

the potential of HIFU as a pro-coagulant. Local treatment of various diseases may be possible by using nanotechnology for producing targeted microbubbles, which may be loaded with drugs or genes. The microbubbles can be monitored by ultrasound and destroyed for local drug release. Bio-effects of the destruction can be used for disrupting cell membranes for killing malicious cells, or for increased drug uptake.

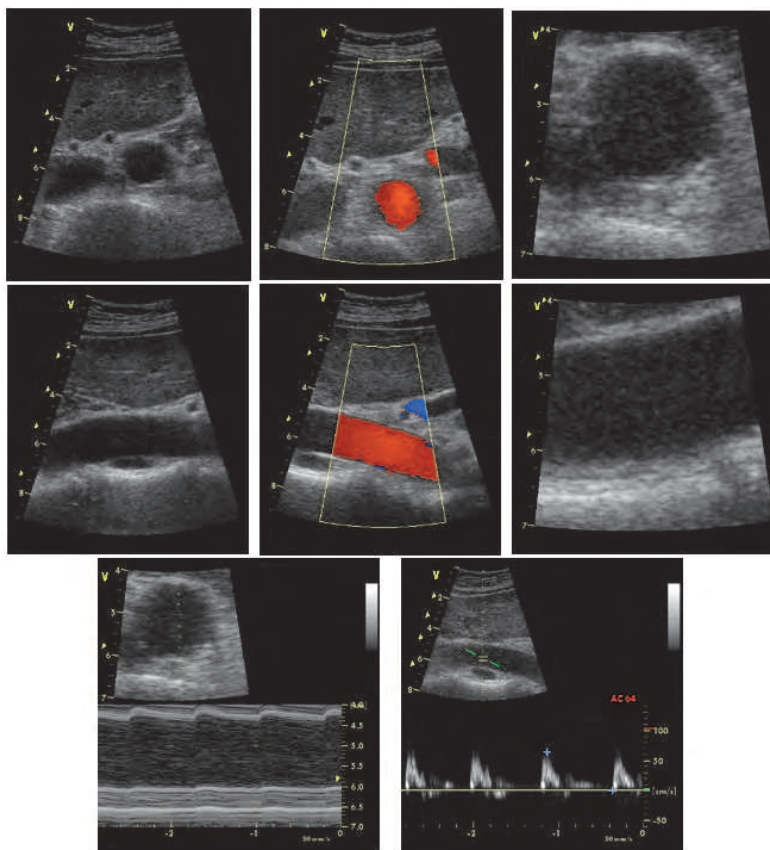


Fig. 1. Ultrasound images of abdominal aorta. Upper row: Cross-sectional view, 2D B-mode, colour Doppler (duplex) and zoomed B-mode image, respectively. Mid row: Same as upper row, but with longitudinal view. Lower row: M-mode (left) and Doppler velocity spectrum.

3. Ultrasound in AAA management

Use of ultrasound in the management of AAA was reported in the late 1960ies. Segal et al. (1966) published a case report of ultrasound for detection and size measurement of an AAA, and Goldberg et al. (1966) investigated 10 normal and 10 aneurysmal aortas. It was recognized that ultrasound could be used for detection of AAA, determination of size and monitoring of growth. During the following decade, several reports demonstrated favourable results for ultrasound in assessment of AAA, including analysis of pulsation,

detection of aneurysms, measurement of diameter and amount of thrombus (Brewster et al., 1977; Hassani & Bard, 1974; Lee et al., 1975; McGregor et al., 1975; Mulder et al., 1973; Wheeler et al., 1976; Winsberg & Cole, 1972). Bernstein et al. (1976) used ultrasound for studying growth rates of small AAA. During the recent decades, ultrasound has been dramatically improved through development of new technology and processing methods assisting in improved patient management in several clinical areas. We present an overview of the current clinical use, and discuss potential future use related to ultrasound in detection and monitoring of AAA, prediction of growth and rupture, and treatment and follow-up.

3.1 Detection and monitoring

AAA is most often asymptomatic until rupture, and coincidentally detected during examination for other diseases. Ultrasound has been recommended for detection of AAA in symptomatic patients and for asymptomatic patients in risk groups. A number of studies suggest that population screening reduces AAA mortality in subgroups with increased AAA susceptibility (Cosford & Leng, 2007; Ferket et al., 2011; Takagi et al., 2010). Screening may still represent an ethical dilemma because growth and rupture is difficult to predict, and it is therefore disputable when to recommend repair on a patient-specific basis, considering the risk involved in surgical or endovascular treatment.

High degree of validity of ultrasound for detection of AAA has been reported. Numbers indicate a sensitivity and specificity of almost 100% (Cosford & Leng, 2007; Lindholt et al., 1999). The accuracy and operator dependencies of size measurements are especially important in order to reliably monitor growth. Fig. 2 shows cross-sectional and longitudinal images of AAA. Singh et al. (1998) reported intra- and inter-observer variability less than 4mm, and concluded that maximal diameter could be measured by ultrasound with high degree of accuracy. Also Thomas et al. (1994) concluded that ultrasound diameter measurements were reproducible between ultrasonographers. However, compared to measurements from X-ray computed tomography (CT), ultrasound was found to consistently give lower values for maximum AAA diameter, with a mean underestimation of 4.4mm. Similar results were reported using duplex ultrasound (Dalainas et al., 2006; Manning et al., 2009). Sprouse et al. (2004) suggested that ultrasound is more accurate than axial CT in determining the true perpendicular diameter. This was based on use of orthogonally reconstructed CT, which varied insignificantly from US, while axial CT overestimated the diameter when the aortic angulation was high. It has also been noted that the variation using internal or external wall diameter would give discrepancies of 5-6mm (Thapar et al., 2010). It is important that measurements be carried out consistently, and being aware of differences between imaging modalities compared to evidence from different clinical trials (Lederle et al., 1995). When care is taken to adjust the critical limits for intervention for a modality, reproducibility is the most important characteristic.

Detection of AAA in emergencies

Emergency ultrasound is becoming more widespread as the development in ultrasound technology provides more portable and even handheld ultrasound scanners at an affordable cost. Ultrasound can be used bedside or in the ambulance for fast examination and early decision making. This development has a potential for reducing AAA mortality by early detection of ruptured (or otherwise symptomatic) aneurysms, allowing early surgery without having to use time for additional examinations in the emergency entrance. Sebesta et al. (1998) investigated the importance of fast treatment of ruptured aneurysms by

studying 103 patients with ruptured AAA. They concluded that “delay in surgical treatment caused both by time consuming confirmative evaluation and patient's lengthy transfers is responsible for ominous protraction of the original shock”. Further, renal failure was found to be a leading cause of postoperative mortality. In combination with hemorrhagic shock, it should be considered that X-ray contrast material cause additional burden to renal function.

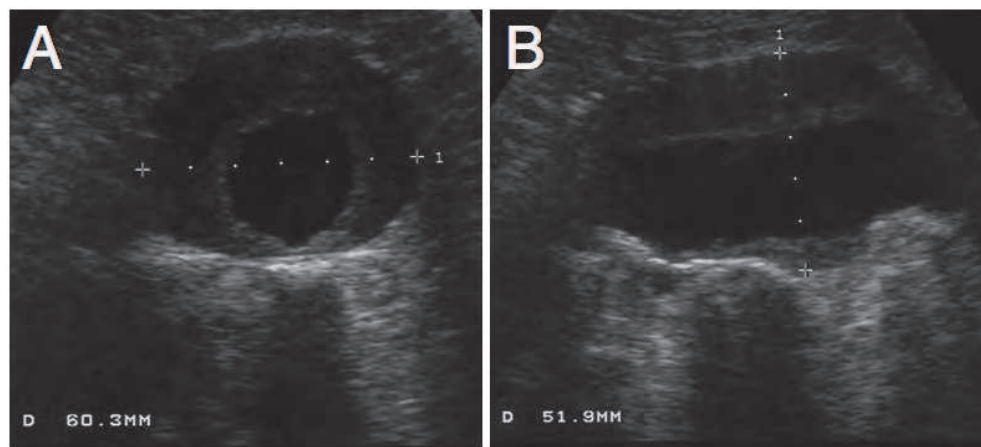


Fig. 2. Ultrasound images of AAA. Cross-sectional (A) and longitudinal (B) views. Courtesy of Asbjørn Ødegård, St. Olav's Hospital, Trondheim, Norway.

The sensitivity and specificity of detection of AAA in emergency medicine ultrasound is almost 100% (Kuhn et al., 2000). With appropriate training, emergency residents accurately determine both presence as well as size of AAA (Bentz & Jones, 2006; Costantino et al., 2005). Hoffmann et al. (2010) concluded that more experienced emergency department sonographers perform better in detecting aneurysms, and suggested training on more than 25 cases, including technically difficult cases, for credentialing personnel for the process. Although rupture of AAA could be indirectly diagnosed from clinical signs and symptoms and presence of an aneurysm, B-mode ultrasound can also reveal direct and indirect signs of rupture (Catalano & Siani, 2005a). Also, Catalano et al. (2005b) further examined 8 ruptured AAA using contrast-enhanced ultrasound, concluding that contrast-enhanced ultrasound may be as effective as CT in detecting rupture, and does not delay surgery significantly. Further considerations on AAA emergency ultrasound can be found in Reardon et al. (2008). The appearance of rupture in different modes of ultrasound images is shown in Fig. 3.

3.2 Prediction of growth and rupture

The validity of aneurysm size and growth as prognostic parameters has been questioned. Specifically, rupture does occur in aneurysm with diameter less than 5 to 5.5 cm, while on the other hand, several aneurysms with diameter larger than 5.5 cm are observed without rupture. Brewster et al. (2003) summarized findings from several studies, and estimated annual rupture risk versus size to be 0% (<4cm), 0.5-5% (4-5cm), 3-15% (5-6cm), 10-20% (6-7cm), 20-40% (7-8cm) and 30-50% (>8cm). Women appeared to have higher risk of rupture for a given diameter. These population-based values should be balanced against the expected risk associated with repair to determine appropriate time for intervention.

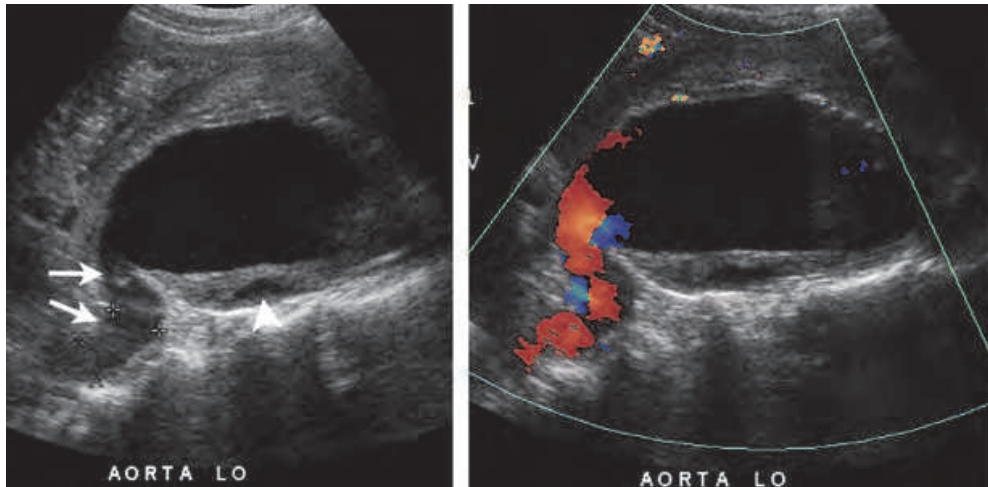


Fig. 3. Ultrasonic appearance of rupture. Left: Longitudinal B-mode image demonstrating a “tubular hypoechoic structure (arrows), which is continuous with the lumen of the aneurysm sac”. The hypoechoic area in the thrombus (arrowhead) is a sign of aortic wall rupture. Right: Corresponding duplex image demonstrating an active bleeding. *In Bhatt et al. (2007), used with permission.*

Although diameter is currently the dominating population based indicator of rupture risk, additional indicators are warranted to predict rupture on an individual level. Improved patient specific assessment of rupture risk would provide better patient selection and reduce harm to patients as well as reducing societal cost. In a study by Hafez et al. (2008), 4308 patients were followed for research purpose after ultrasound screening showing a normal aorta. 3.9% (166/4308) were found to later develop AAA. Improved prediction of growth and rupture (prognostic monitoring) would 1) reduce the number of unnecessary examinations and interventions, and 2) make screening programs more favourable. Both would contribute to reduce AAA mortality.

Substantial efforts have been devoted to improved selection of patients for AAA repair through systematic assessment of risk factors of AAA growth and rupture, as well as individualized risk associated with repair. In this text, we will focus on image-based assessment of growth and rupture risk, specifically ultrasound imaging. Several groups have for more than a decade developed increasingly sophisticated numerical simulation tools for analysing the mechanical state of aneurysms, based on patient specific geometries. By applying solid-state stress analysis, Fillinger et al. (2003) found that peak wall stress was a better predictor of rupture than was maximum diameter. Further details on biomechanical analysis of AAA can be found in e.g. the reviews by Malkawi et al. (2010) and Vorp (2007). Patient specific geometries applied for numerical analysis are most often based on CT, which is easily obtainable for AAA patients, and gives a good representation of the full 3D geometry of the aneurysm and blood vessels. Ultrasound imaging may be beneficial for early and consecutive measurements (i.e. screening/ detection and repeated monitoring). Real time 3D ultrasound imaging is used in cardiology, but gives a limited sector, and is not yet adapted to abdominal imaging. A possible alternative would be to obtain 3D volume by reconstruction of 2D ultrasound slices acquired with position tracking (Solberg et al., 2007).

An interesting application of ultrasound in analysis of AAA mechanics is due to the dynamical properties of ultrasound. Ultrasound is a fast imaging modality, which makes it possible to study the dynamical behaviour of the aneurysm when exposed to the blood pulse. Imura et al. (1986) presented a method using ultrasound for tracking the dynamic diameter of the abdominal aorta over the cardiac cycle in order to quantify the elastic properties of human abdominal aorta *in vivo*.

Analysis of the dynamical properties of the AAA may be motivated by the association between evolution of aneurysms and alteration of the elastic properties of the vessel wall. This alteration has been linked to matrix-metalloproteinase (MMP) activity (Freestone et al., 1995). It has been suggested that growth is associated with degradation of elastin, whereas rupture may be caused by degradation of collagen (Petersen et al., 2002). Consistent with this, it has been shown that aneurysm tissue is stiffer than normal tissue, but that softer aneurysm tissue is more prone to rupture than stiff aneurysm tissue (Di Martino et al., 2006). Several authors have used ultrasound to study the elastic properties of AAA by tracking dynamical change in diameter over the cardiac cycle, and obtained interesting, but to some extent diverging, results. Wilson et al. (1998) reported results that might support the hypothesis of aneurysms being stiffer than normal tissue, while less stiff aneurysms may be more prone to rupture. Later studies reported that large aneurysms tended to be stiffer than smaller, but with large variations for equally sized aneurysms (Wilson et al., 1999), and that increased distensibility over time (compared to baseline) indicated significantly reduced time to rupture (Wilson et al., 2003). However, Long et al. (2005) used tissue Doppler imaging, and reported a trend toward increased distensibility with increased AAA diameter. Ultrasonic tracking of diameter has demonstrated that the aorta is stiffer in men than age-matched women, that stiffness increases with age, and that aneurysm tissue is much stiffer than normal aorta (Länne et al., 1992; Sonesson et al., 1993). However, Sonesson et al. (1999) studied 285 AAA patients and found no difference in "aneurysmal aortic wall mechanics in those AAAs that subsequently ruptured compared with electively operated AAAs. The results indicate that it is not possible to use aneurysmal aortic wall stiffness as a predictor of rupture."

Measuring the dynamical change in diameter over the cardiac cycle gives a stiffness measure representing an average over the cross section of the aneurysm wall. The mechanical properties of the wall are however known to vary heterogeneously over the wall (Thubrikar et al., 2001). Ultrasound strain imaging estimates local deformation of tissue due to applied load, and may therefore have a potential for better assessment and characterization of the local properties of the wall. In a study by Brekken et al. (2006), 2D cross-sectional ultrasound data with high frame rate (~40-50 fps, depending on the size of the aneurysm) was used to derive patient-specific information about *in-vivo* elastic properties of the aneurysm wall of 10 patients. For each dataset, points were semi-automatically selected along the aneurysm circumference in one ultrasound image. These points were then automatically traced over the cardiac cycle. A measure of cyclic circumferential strain was estimated by calculating the time varying distance between the points relative to the initial (diastolic) distance. (Fig. 4.) The preliminary patient study showed that the strain values were inhomogeneous along the circumference, thus indicating that additional information could be obtained as compared to maximum diameter alone. Further clinical trials are necessary to investigate the method's potential for improved prediction of growth and rupture.

In addition to potentially carry clinically relevant information in itself, the strain estimates could be integrated with computational methods to contribute to more patient specific analysis of wall stress. In order to relate the strain estimates to the geometry of the

aneurysm, and hence relate to biomechanical simulations based on 3D geometries, Brekken et al. (2007) reported attachment of a positioning sensor to the ultrasound probe for placing the ultrasound cross-section in a 3D space. The ultrasound data were then registered to CT data from the same patient, and strain was visualized together with the 3D geometry segmented from the CT data. (Fig. 5.) This allows for direct comparison of ultrasound based strain measurements with biomechanical simulations, and opens for more patient specific simulations by including elasticity measures from ultrasound.

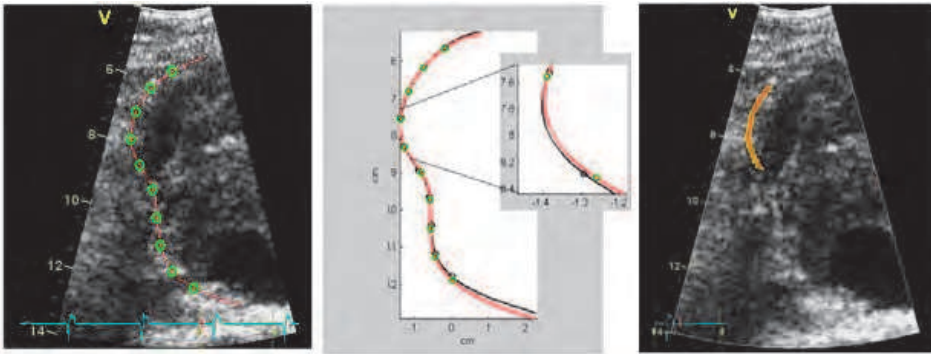


Fig. 4. Strain processing and ultrasound strain. Left: The aneurysm wall is manually identified (red line). A number of points (green) are placed equidistantly along the curve, and automatically traced over the cardiac cycle. Mid: Illustrating the points in diastole and systole. Right: Colour-coded strain in systole relative to diastole. It is noted that one part of the wall experiences elevated cyclic strain. *In Brekken et al. (2006), used with permission.*

Future research should be aimed at investigation also of longitudinal strain, and eventually estimation of full 3D strain, e.g. by developing probes and methods for 3D ultrasound acquisition and analysis. Also, low signal-to-noise ratio in abdominal ultrasound images reduces accuracy of tracking and thus strain estimation. Methods for noise reduction should therefore be explored. In addition, use of ultrasound Doppler for blood velocity estimation could provide further information to be used as input to patient specific simulations.

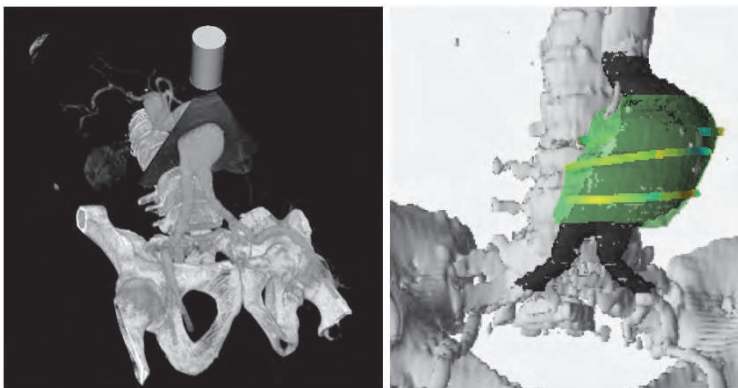


Fig. 5. Left: CT and ultrasound in the same scene. Right: 3D visualization of strain. *In Brekken et al. (2007), used with permission.*

3.3 Endovascular treatment and follow-up

Ultrasound in endovascular treatment

Radiological imaging is used in pre-operative planning of endovascular aneurysm repair (EVAR) and for intra-operative guidance and control. In pre-operative planning, imaging is used to get a measure of the 3D anatomy for investigating eligibility of EVAR and for choosing or customizing stentgrafts. A common imaging modality for this purpose is CT angiography (Broeders & Blankensteijn, 1999). CT has the advantage of visualizing the entire anatomical area of interest. Transabdominal 3D ultrasound offers only a limited sector, and, in addition, parts of the relevant anatomy will be obscured by acoustical shadows or absorption.

Some of these challenges are avoided in intravascular ultrasound (IVUS). IVUS has been used for pre-operative planning in combination with CT, for guidance and for control after device placement. (Fig. 6.) Several authors have concluded that IVUS gave accurate and reproducible measurements of the geometry of the aneurysm, and assisted in correct selection of stentgraft or final correction of stentgraft diameter or length. IVUS further assisted in rapid identification of fixation sites, and assessment of accuracy and patency of device placement (Eriksson et al., 2009; Garret et al., 2003; Tutein et al., 2000; van Essen et al., 1999; White et al., 1997; Zanchetta et al., 2003).

Ultrasound guidance during minimally invasive therapy has been reported and is in regular use within some clinical applications. Especially within neurosurgery ultrasound has been found beneficial for intra-operative imaging (Unsgaard et al., 2011). Intra-operative guidance during EVAR is usually performed with X-ray fluoroscopy. Both intraoperative CT (Dijkstra et al., 2011) as well as fluoroscopy in combination with navigation using electromagnetic sensors (Manstad-Hulaas et al., 2007) has been investigated for guiding insertion of fenestrated grafts. Some investigators have also reported transabdominal ultrasound for guidance of EVAR. Lie et al. (1997) studied the use of 2D transabdominal ultrasound during EVAR. They found that ultrasound could be useful for guiding the insertion of guidewire and control the wire position before connecting second graft limb to the main limb of bifurcated grafts (Fig. 6.). Kaspersen et al. (2003) reported a feasibility study registering ultrasound acquired during EVAR to pre-acquired CT data. This may be useful for updating the CT data used for navigation due to e.g. respiratory motion and deformation of the blood vessels during the procedure. With recent advances in ultrasound technology, we believe that real-time 3D ultrasound has potential for further advancing insertion of stentgraft, especially delivery of fenestrated stentgrafts. Specifically, it is easier to track e.g. the tip of guidewires in 3D, while simultaneously visualizing a focused area of the 3D anatomy in real-time, perhaps in combination with CT. Contrast-enhanced ultrasound has also been used intraoperatively for localization of fixation sites and identification of endoleaks (Kopp et al., 2010). The fixation sites were visualized in >80% of the 17 patients investigated with contrast-enhanced ultrasound, and more endoleaks were detected than with conventional EVAR. It was noted that ultrasound was especially beneficial in case of patients with contraindications for usage of X-ray contrast material.

Percutaneous EVAR, i.e. minimally invasive femoral access, is an alternative to open femoral access. A systematic review by Malkawi et al. (2010) concluded that percutaneous EVAR was associated with fewer access related complications and reduced operating time. In a study by Arthurs et al. (2008), it was shown that use of ultrasound guided access significantly reduced access-related complications compared to percutaneous access without

ultrasound guidance. Successful ultrasound guidance in secondary interventions, for sealing endoleak after EVAR, has also been reported. Boks et al. (2005) described transabdominal embolization using duplex ultrasound guidance, and Kasthuri et al. (2005) used ultrasound for guiding percutaneous thrombin injection.

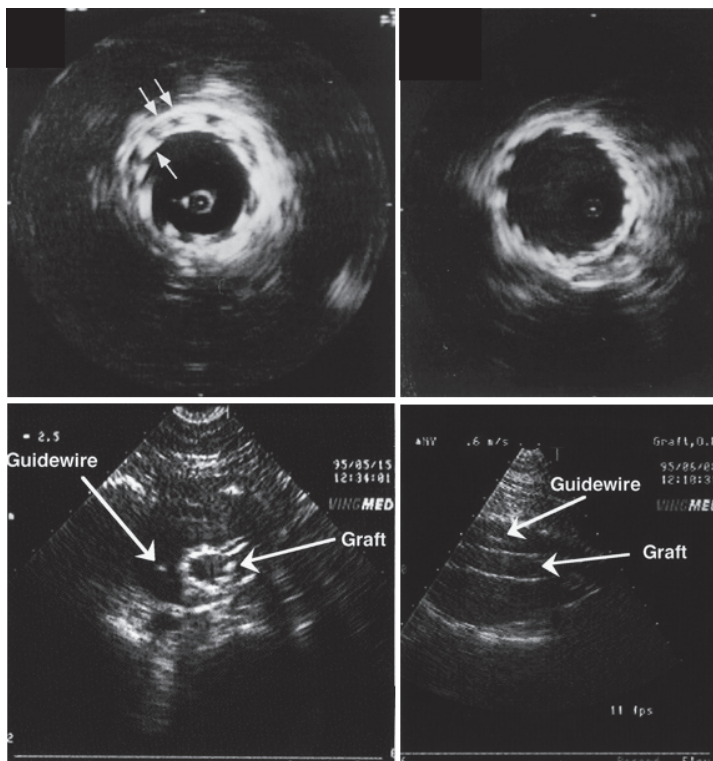


Fig. 6. Upper: IVUS during EVAR, left: incomplete stent expansion, right: stent correctly placed after additional dilation. *In White et al. (1995), used with permission.* Lower: Transabdominal ultrasound guidance during EVAR. Guidewire and stentgraft is visible inside the aneurysm. *In Lie et al. (1997), used with permission.*

Ultrasound in post-operative surveillance

Due to incidences of complications such as endoleak or continued growth after EVAR, it is necessary to conduct long-term follow-up. CT is in widespread use, but due to the repeated investigations, there is a significant radiation dose involved. Also, for some patients, the use of X-ray contrast material may cause allergic reactions or impair the renal function. Ultrasound has been suggested as an alternative that reduces these risks as well as the cost associated with follow-up of EVAR patients.

Several authors have investigated duplex ultrasound for detection of endoleak. In comparison with CT, duplex ultrasound is by some authors considered not to be sensitive or specific enough for replacing CT (Mirza et al., 2010; Sun, 2006). Other authors have found that duplex ultrasound may be sufficient in groups of patients, specifically those

with a stable aneurysm (Bargellini et al., 2009; Chaer et al., 2009; Nagre et al., 2011). Patel & Carpenter (2010) suggested that duplex ultrasound could be sufficient for long-term follow-up if the initial postoperative CT angiography was normal. Collins et al. (2007) also compared duplex ultrasound with CT, and found that three endoleaks determined from CT could not be seen with ultrasound due to bowel gas, body habitus or hernia, whereas out of 41 endoleaks discovered by ultrasound, only 14 were visible on a CT scan. A number of studies have reported use of contrast-enhanced ultrasound for detection of endoleaks. Generally, it is considered to be more accurate than ultrasound without contrast, and similar to magnetic resonance imaging (MR) and CT (Cantisani et al., 2011; Iezzi et al., 2009; Mirza et al., 2010; Sun 2006). McWilliams et al. (2002) investigated 53 patients and found contrast enhanced ultrasound to be more sensitive than unenhanced ultrasound in detection of endoleak when compared to CT, but concluded that ultrasound (with or without contrast) was less reliable than CT. On the contrary, several other authors have concluded that contrast enhanced ultrasound may perform better than CT in detection of endoleak (Carrafiello et al., 2006; Clevert et al., 2008; Henao et al., 2006; Ten Bosch et al., 2010). Bakken & Illig (2010) presented a review summarizing use of ultrasound for detection of endoleak. They concluded that ultrasound was suitable for “monitoring the evolution of aneurysm sac post-EVAR and, in combination with endoleak evaluation, seems to provide follow-up comparable to CT and sufficient to identify complications requiring intervention”. In addition to capture the majority of endoleaks, the authors suggested that ultrasound could also provide better characterization and localization of the endoleak than with CT. The sensitivity of ultrasound for endoleak detection is likely to be underestimated by comparing it to CT as the reference standard because some endoleaks are missed also by CT. Therefore, the validity of ultrasound for endoleak detection should ideally be tested against clinically relevant outcome measures rather than to CT. Operator dependency of ultrasound may be an additional cause for diverging results. The introduction of 3D ultrasound could provide simpler protocols for detection of endoleak, and reduce user dependency. Fig. 7 shows examples of endoleak appearance in duplex and contrast-enhanced ultrasound.

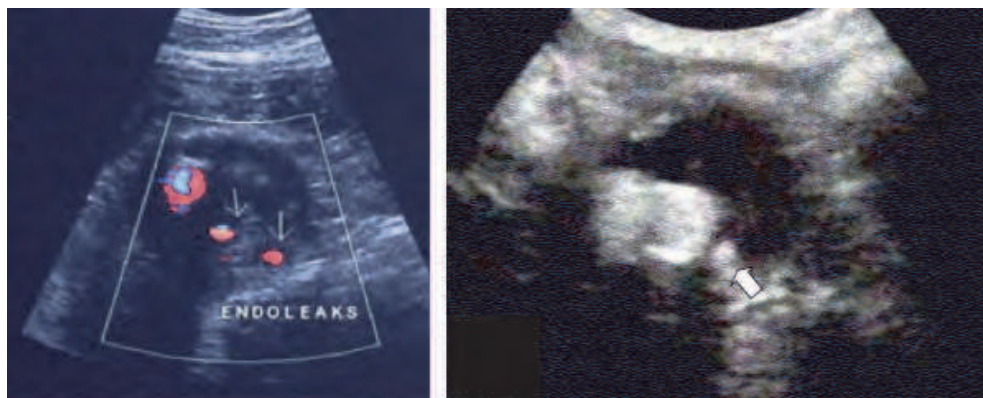


Fig. 7. Ultrasound for detection of endoleak. Left: Type II endoleaks with duplex ultrasound. In Beeman et al. (2010), used with permission. Right: Contrast-enhanced ultrasound illustrating flow inside the aneurysmal sac. In Henao et al. (2006), used with permission.

Another use of ultrasound in follow-up after EVAR is to study the pulsatile diameter. Malina et al. (1998) found that pulsatile wall motion was significantly reduced after EVAR as compared to before, and that endoleak was associated with smaller reduction. However, Lindblad et al. (2004) reported a similar study with more patients, and concluded that the reduction in pulsatile motion was not significantly different in the presence of endoleak. Using the ultrasound strain method previously described, Brekken et al. (2008) measured strain before and after insertion of stentgraft, confirming that the method detected a reduction in strain after endovascular repair. Pulsatility was observed after EVAR, and the strain values were heterogeneous along the circumference also after EVAR. It remains to investigate if the method is sensitive and accurate enough for detecting possible changes due to endoleak. Also, some aneurysms continue to grow without evidence of endoleak (Gilling-Smith et al., 2000). It is uncertain whether this is because of imaging modalities not being sensitive enough to detect all endoleaks, or other reasons. Therefore, in addition to monitor size, it is worth investigating if ultrasound strain could be used to predict growth or rupture, with or without endoleak, during follow-up after endovascular repair.

3.4 Functional and molecular imaging

The main pathophysiological mechanisms in development and progression of AAA are inflammation, proteolysis and apoptosis (Zankl et al., 2007). As these mechanisms and their role in AAA become more clear, new alternatives for detection, risk prediction and treatment may become available.

Compared to traditional imaging modalities, there is a need for alternative imaging to investigate pathophysiological mechanisms in-vivo, which could eventually identify high risk patients and monitor results of treatment. Hong et al. (2010) reviewed different modalities for imaging of AAA. They classified the modalities into anatomical, functional and molecular imaging. Anatomical imaging displays the structure of organs, whereas functional imaging can reveal physiological activities by detecting "changes in the metabolism, blood flow, regional chemical composition and absorption". Molecular imaging "introduces molecular agents (probes) to determine the expression of indicative molecular markers at different stages of disease." Functional and molecular imaging may be performed using SPECT, optical imaging and PET in combination with the appropriate contrast agents.

In addition to imaging functional properties using ultrasound Doppler or strain imaging, the use of ultrasound contrast agents constitutes a research area of great interest for imaging both functional and molecular properties. By injection of microbubbles in the blood stream, microcirculation has been imaged for investigation of myocardial perfusion and detection of neovascularization in relation to tumours and atherosclerosis (Fig. 8). (Anderson et al., 2011; Lindner et al., 2000 ; ten Kate et al., 2010). Staub et al. (2010a) demonstrated that adventitial vasa vasorum and plaque neovascularization of the carotid artery correlated with cardiovascular disease and past cardiovascular events using contrast-enhanced ultrasound in a retrospective study of 147 patients. Neovascularization or angiogenesis is also found in relation to AAA (Herron et al., 1991; Holmes et al., 1995; Thompson et al., 1996). Choke et al. (2006) found that rupture of AAA was associated with increased medial neovascularization. Assessment of neovascularization by contrast enhanced ultrasound may therefore have a significant potential for assisting in more accurate prediction of rupture.

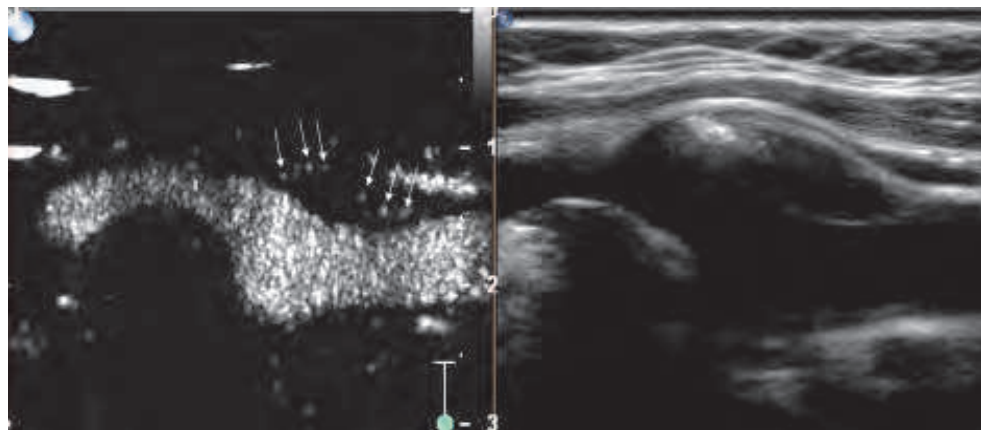


Fig. 8. Left: Contrast-enhanced ultrasound showing neovascularization in carotid artery plaque. Microbubbles within the plaque are indicated by arrows. Right: Corresponding B-mode ultrasound image without contrast. *In Staub et al. (2010b), used with permission.*

With recent advances in nanotechnology (nanomedicine), it is possible to produce targeted contrast agents, which connect to specific receptors. Due to current investigation of markers associated with AAA, targeted ultrasound imaging may be a future option (Moxon et al., 2010; Villanueva 2008). With increased knowledge of pathophysiological mechanisms, pharmacotherapy or gene therapy may be available for stabilization of aneurysms (Baxter et al., 2008; Cooper et al., 2009; Golledge et al., 2009; Raffetto & Khalil, 2008; Twine & Williams, 2011). It may then be interesting to apply drug- or gene-loaded contrast agents, which could be monitored and destructed using ultrasound for local drug delivery. Targeted drug delivery might benefit higher doses (locally) without increased risk of side effects.

4. Conclusions

The general aim of AAA research is to provide cost effective management for reducing mortality of AAA. Management includes screening/detection, monitoring, risk prediction, treatment and follow-up. We have described current and future potential of ultrasound for assisting in clinical management of AAA. Advantages of using ultrasound are that it is inexpensive, safe and portable, and allows for real-time dynamic imaging. New techniques, along with more widespread use of ultrasound, could contribute in several manners to improved AAA management.

Ultrasound is highly suitable for detection and monitoring of AAA size for screening and surveillance. In emergencies, ultrasound should be used for AAA detection and assessment of rupture as early as possible and preferably pre-hospital. Contrast enhanced ultrasound may be beneficial in detection of ruptured aneurysms. Early detection can provide early treatment and thereby reduce mortality of ruptured AAA. Ultrasound, and especially contrast enhanced ultrasound, is also a good alternative for detection of endoleak after EVAR. Ultrasound is cost-effective, does not include ionizing radiation or X-ray contrast material, and sensitivity may be better than CT. IVUS may be beneficial during EVAR for optimal measurement of stentgraft diameter, length and fixation site, as well as for post-operative control. Further research may find both IVUS and 3D transabdominal real-time

ultrasound guidance during EVAR to be useful in insertion of stentgrafts, especially fenestrated grafts. Ultrasound could also be used for guiding access to femoral artery in percutaneous EVAR.

A potential new application is to use ultrasound for analysing in-vivo mechanical properties of the aneurysm wall. This could provide additional parameters in predicting growth and rupture, or contribute to more patient-specific adaptation of numerical simulations both before and after EVAR. Improved prediction of growth and rupture would reduce the number of unnecessary examinations and interventions, reduce mortality and further benefit screening for detection of AAA. Another potential use of ultrasound in AAA management is in detection of neovascularization or other relevant markers by using general or targeted contrast agents. Contrast agents may also have a potential in treatment as drug carriers. Drug-loaded contrast agents can be monitored and destructed using ultrasound for local drug-delivery.

Obstacles for further use of ultrasound may be that ultrasound to some extent is operator dependent, and that abdominal ultrasound often is obscured from bowel gas, obesity and noise due to ultrasound propagation through the abdominal wall. Technology development will hopefully advance ultrasound image quality. An improvement was obtained with the introduction of tissue harmonic imaging (Caidahl et al., 1998). Several research groups are working on techniques for further improving quality of ultrasound images, such as suppression of reverberation and aberration correction. Due to operator dependencies, it might be necessary to investigate validity of ultrasound in the individual clinical surroundings before implementation in AAA management. Further, for ultrasound to become a widespread useful tool for AAA assessment, health personnel should be trained in focused assessment of presence and size of aneurysms, and detection of rupture and endoleak. Experts should be trained for more sophisticated examinations, such as analysis of wall mechanics and studies of microcirculation using contrast agents.

5. Acknowledgment

This work was funded by the Liaison Committee between the Central Norway Regional Health Authority and the Norwegian University of Science and Technology, SINTEF Department of Medical Technology and the National Centre for 3D Ultrasound in Surgery.

6. References

- Anderson CR, Hu X, Zhang H, Tlaxca J, Declèves AE, Houghtaling R, Sharma K, Lawrence M, Ferrara KW, Rychak JJ. (2011). Ultrasound molecular imaging of tumor angiogenesis with an integrin targeted microbubble contrast agent. *Invest Radiol.* Vol.46, No.4, (April), pp. 215-224.
- Arthurs ZM, Starnes BW, Sohn VY, Singh N, Andersen CA. (2008). Ultrasound-guided access improves rate of access-related complications for totally percutaneous aortic aneurysm repair. *Ann Vasc Surg.* Vol.22, No.6, (Nov), pp. 736-741.
- Bakken AM, Illig KA. (2010). Long-term follow-up after endovascular aneurysm repair: is ultrasound alone enough? *Perspect Vasc Surg Endovasc Ther.* Vol.22, No.3, (Sep), pp. 145-151.
- Bargellini I, Cioni R, Napoli V, Petrucci P, Vignali C, Cicorelli A, Sardella S, Ferrari M, Bartolozzi C. (2009). Ultrasonographic surveillance with selective CTA after

- endovascular repair of abdominal aortic aneurysm. *J Endovasc Ther.* Vol.16, No.1, (Feb), pp. 93-104.
- Baxter BT, Terrin MC, Dalman RL. (2008) Medical management of small abdominal aortic aneurysms. *Circulation.* Vol.117, No.14, (Apr), pp. 1883-1889.
- Beeman BR, Murtha K, Doerr K, McAfee-Bennett S, Dougherty MJ, Calligaro KD. (2010). Duplex ultrasound factors predicting persistent type II endoleak and increasing AAA sac diameter after EVAR. *J Vasc Surg.* Vol.51, No.5, (Nov), pp. 1147-1152.
- Bentz S, Jones J. (2006). Towards evidence-based emergency medicine: best BETs from the Manchester Royal Infirmary. Accuracy of emergency department ultrasound scanning in detecting abdominal aortic aneurysm. *Emerg Med J.* Vol.23, No.10, (Oct), pp. 803-804.
- Bernstein EF, Dilley RB, Goldberger LE, Gosink BB, Leopold GR. (1976). Growth rates of small abdominal aortic aneurysms. *Surgery.* Vol.80, No.6, (Dec), pp. 765-773.
- Bhatt S, Ghazale H and Dogra VS. (2007). Sonographic Evaluation of the Abdominal Aorta. *Ultrasound Clin.* Vol.2, No.3, (Jul), pp. 437-453.
- Boks SS, Andharyswara T, de Smet AA, Vroegindeweij D. (2005). Ultrasound-guided percutaneous transabdominal treatment of a type 2 endoleak. *Cardiovasc Intervent Radiol.* Vol.28, No.4, (Jul-Aug), pp. 526-529.
- Brekken R, Bang J, Ødegård A, Aasland J, Hernes TA, Myhre HO. (2006). Strain estimation in abdominal aortic aneurysms from 2D Ultrasound. *Ultrasound Med Biol.* Vol.32, No.1, (Jan), pp. 33-42.
- Brekken R, Dahl T, Hernes TAN, Myhre HO. (2008). Reduced strain in abdominal aortic aneurysms after endovascular repair. *J Endovasc Ther.* Vol. 15, No.4, (Aug), pp. 453-461.
- Brekken R, Kaspersen JH, Tangen GA, Dahl T, Hernes TAN, Myhre HO. (2007). 3D visualization of strain in abdominal aortic aneurysms based on navigated ultrasound imaging. *Proceedings of SPIE Medical Imaging: Physiology, Function, and Structure from Medical Images*, 65111H, San Diego, CA, USA, February 18, 2007.
- Brewster DC, Cronenwett JL, Hallett JW Jr, Johnston KW, Krupski WC & Matsumura JS. (2003). Guidelines for the treatment of abdominal aortic aneurysms. Report of a subcommittee of the Joint Council of the American Association for Vascular Surgery and Society for Vascular Surgery. *J Vasc Surg.* Vol.37, No.5 (May), pp. 1106-1117.
- Brewster DC, Darling RC, Raines JK, Sarno R, O'Donnell TF, Ezpeleta M, Athanasoulis C. (1977). Assessment of abdominal aortic aneurysm size. *Circulation.* Vol.56, No.3S, (Sep), pp. II164-II169.
- Broeders IA, Blankensteijn JD. (1999). Preoperative imaging of the aortoiliac anatomy in endovascular aneurysm surgery. *Semin Vasc Surg.* Vol.12, No.4, (Dec), pp. 306-314.
- Burgess S, Zderic V, Vaezy S. (2007). Image-guided acoustic hemostasis for hemorrhage in the posterior liver. *Ultrasound Med Biol.* Vol.33, No.1, (Jan), pp. 113-119.
- Caidahl K, Kazzam E, Lidberg J, Neumann Andersen G, Nordanstig J, Rantapää Dahlqvist S, Waldenström A, Wikh R. (1998). New concept in echocardiography: harmonic imaging of tissue without use of contrast agent. *Lancet.* Vol.352, No.9136, (Oct), pp. 1264-1270.
- Cantisani V, Ricci P, Grazhdani H, Napoli A, Fanelli F, Catalano C, Galati G, D'Andrea V, Biancari F, Passariello R. (2011). Prospective Comparative Analysis of Colour-

- Doppler Ultrasound, Contrast-enhanced Ultrasound, Computed Tomography and Magnetic Resonance in Detecting Endoleak after Endovascular Abdominal Aortic Aneurysm Repair. *Eur J Vasc Endovasc Surg*. Vol. 41, No.2, (Feb), pp. 186-192.
- Carrafiello G, Laganà D, Recaldini C, Mangini M, Bertolotti E, Caronno R, Tozzi M, Piffaretti G, Genovese EA, Fugazzola C. (2006). Comparison of contrast-enhanced ultrasound and computed tomography in classifying endoleaks after endovascular treatment of abdominal aorta aneurysms: preliminary experience. *Cardiovasc Intervent Radiol*. Vol.29, No.6, (Nov-Dec), pp. 969-974.
- Catalano O and Siani A. (2005a). Ruptured Abdominal Aortic Aneurysm: Categorization of Sonographic Findings and Report of 3 New Signs. *J Ultrasound Med*. Vol.24, No.8, (Aug), pp. 1077-1083.
- Catalano O, Lobianco R, Cusati B, Siani A. (2005b). Contrast-Enhanced Sonography for Diagnosis of Ruptured Abdominal Aortic Aneurysm. *Am J Roentgenol*. Vol.184, No.2, (Feb), pp. 423-427.
- Chaer RA, Gushchin A, Rhee R, Marone L, Cho JS, Leers S, Makaroun MS. (2009). Duplex ultrasound as the sole long-term surveillance method post-endovascular aneurysm repair: a safe alternative for stable aneurysms. *J Vasc Surg*. Vol.49, No.4, (Apr), pp. 845-849.
- Chaikof EL, Brewster DC, Dalman RL, Makaroun MS, Illig KA, Sicard GA, Timaran CH, Upchurch GR Jr, Veith FJ. (2009). The care of patients with an abdominal aortic aneurysm: the Society for Vascular Surgery practice guidelines. *J Vasc Surg*. Vol.50, No.4S, (Oct), pp. S2-S49.
- Choke E, Thompson MM, Dawson J, Wilson WR, Sayed S, Loftus IM, Cockerill GW. (2006). Abdominal aortic aneurysm rupture is associated with increased medial neovascularization and overexpression of proangiogenic cytokines. *Arterioscler Thromb Vasc Biol*. Vol.26, No.9, (Sep), pp. 2077-2082.
- Clevert DA, Minaifar N, Weckbach S, Kopp R, Meimarakis G, Clevert DA, Reiser M. (2008). Color duplex ultrasound and contrast-enhanced ultrasound in comparison to MS-CT in the detection of endoleak following endovascular aneurysm repair. *Clin Hemorheol Microcirc*. Vol.39, No.1-4, pp. 121-132.
- Collins JT, Boros MJ, Combs K. (2007). Ultrasound surveillance of endovascular aneurysm repair: a safe modality versus computed tomography. *Ann Vasc Surg*. Vol.21, No.6, (Nov), pp. 671-675.
- Cooper DG, King JA, Earnshaw JJ. (2009). Role of medical intervention in slowing the growth of small abdominal aortic aneurysms. *Postgrad Med J*. Vol.85, No.1010, (Dec), pp. 688-692.
- Cosford PA, Leng GC. (2007). Screening for abdominal aortic aneurysm. *Cochrane Database Syst Rev*. Vol.18, No.2, (Apr), CD002945.
- Costantino TG, Bruno EC, Handly N, Dean AJ. (2005). Accuracy of emergency medicine ultrasound in the evaluation of abdominal aortic aneurysm. *J Emerg Med*. Vol.29, No.4, (Nov), pp. 455-460.
- Dalainas I, G. Nano, P. Bianchi, R. Casana, T. Lupattelli and S. Stegher, Malacrida G, Tealdi DG. (2006). Axial computed tomography and duplex scanning for the determination of the maximal abdominal aortic diameter in patients with abdominal aortic aneurysms. *Eur Surg*. Vol. 38, No.4, pp. 312-314.

- Di Martino ES, Bohra A, Vande Geest JP, Gupta N, Makaroun MS, Vorp DA. (2006). Biomechanical properties of ruptured versus electively repaired abdominal aortic aneurysm wall tissue. *J Vasc Surg*. Vol.43, No.3, (Mar), pp. 570-576.
- Dijkstra ML, Eagleton MJ, Greenberg RK, Mastracci T, Hernandez A. (2011). Intraoperative C-arm cone-beam computed tomography in fenestrated/branched aortic endografting. *J Vasc Surg*. Vol.53, No.3, (Mar), pp. 583-590.
- Eriksson MO, Wanhainen A, Nyman R. (2009). Intravascular ultrasound with a vector phased-array probe (AcuNav) is feasible in endovascular abdominal aortic aneurysm repair. *Acta Radiol*. Vol.50, No.8, (Oct), pp. 870-875.
- Ferret BS, Grootenboer N, Colkesen EB, Visser JJ, van Sambeek MR, Spronk S, Steyerberg EW, Hunink MG. (2011). Systematic review of guidelines on abdominal aortic aneurysm screening. *J Vasc Surg*. Epub: Feb 14.
- Fillinger MF, Marra SP, Raghavan ML, Kennedy FE. (2003). Prediction of rupture risk in abdominal aortic aneurysm during observation: wall stress versus diameter. *J Vasc Surg*. Vol.37, No.4, (Apr), pp. 724-732.
- Freestone T, Turner RJ, Coady A, Higman DJ, Greenhalgh RM, Powell JT. (1995). Inflammation and matrix metalloproteinases in the enlarging abdominal aortic aneurysm. *Arterioscler Thromb Vasc Biol*. Vol.15, No.8, (Aug), pp. 1145-1151.
- Frinking PJ, Bouakaz A, Kirkhorn J, Ten Cate FJ, de Jong N. (2000). Ultrasound contrast imaging: current and new potential methods. *Ultrasound Med Biol*. Vol.26, No.6, (Jul), pp. 965-975.
- Gallucci M, Vincenzoni A, Schettini M, Fortunato P, Cassanelli A, Zaccara A. (2001). Extracorporeal shock wave lithotripsy in ureteral and kidney malformations. *Urol Int*. Vol.66, No.2, pp. 61-65.
- Garra BS. (2007). Imaging and estimation of tissue elasticity by ultrasound. *Ultrasound Q*. Vol.23, No.4, (Dec), pp. 255-268.
- Garret HE Jr, Abdullah AH, Hodgkiss TD, Burgar SR. (2003). Intravascular ultrasound aids in the performance of endovascular repair of abdominal aortic aneurysm. *J Vasc Surg*. Vol.37, No.3, (Mar), pp. 615-618.
- Gilling-Smith GL, Martin J, Sudhindran S, Gould DA, McWilliams RG, Bakran A, Brennan JA, Harris PL. (2000). Freedom from endoleak after endovascular aneurysm repair does not equal treatment success. *Eur J Vasc Endovasc Surg*. Vol.19, No.4, (Apr), pp. 421-425.
- Goldberg BB, Ostrum BJ, Isard HJ. (1966). Ultrasonic aortography. *JAMA*. Vol.198, No.4, (Oct), pp. 353-358.
- Golledge J, Dalman RL, Norman PE. (2009). Developments in non-surgical therapies for abdominal aortic aneurysm. *Curr Vasc Pharmacol*. Vol.7, No.2, (Apr), pp. 153-158.
- Hafez H, Druce PS, Ashton HA. (2008). Abdominal aortic aneurysm development in men following a "normal" aortic ultrasound scan. *Eur J Vasc Endovasc Surg*. Vol.36, No.5, (Nov), pp. 553-558.
- Hansen R, Angelsen BA. SURF imaging for contrast agent detection. (2009). *IEEE Trans Ultrason Ferroelectr Freq Control*. Vol.56, No.2, (Feb), pp. 280-290.
- Hassani S, Bard R. (1974). Ultrasonic diagnosis of abdominal aortic aneurysms. *J Natl Med Assoc*. Vol.66, No.4, (Jul), pp. 298-299.
- Henao EA, Hodge MD, Felkai DD, McCollum CH, Noon GP, Lin PH, Lumsden AB, Bush RL. (2006). Contrast-enhanced Duplex surveillance after endovascular abdominal

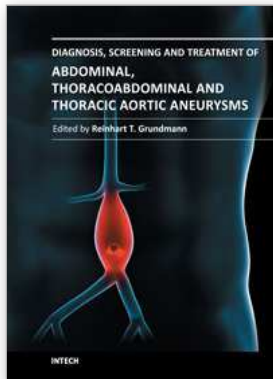
- aortic aneurysm repair: improved efficacy using a continuous infusion technique. *J Vasc Surg*. Vol.43, No.2, (Feb), pp. 259-264.
- Herron GS, Unemori E, Wong M, Rapp JH, Hibbs MH, Stoney RJ. (1991). Connective tissue proteinases and inhibitors in abdominal aortic aneurysms. Involvement of the vasa vasorum in the pathogenesis of aortic aneurysms. *Arterioscler Thromb*. Vol.11, No.6, (Nov-Dec), pp. 1667-1677.
- Hoffmann B, Bessman ES, Um P, Ding R, McCarthy ML. (2010). Successful sonographic visualisation of the abdominal aorta differs significantly among a diverse group of credentialed emergency department providers. *Emerg Med J*. Epub: Aug 2.
- Holmes DR, Liao S, Parks WC, Thompson RW. (1995). Medial neovascularization in abdominal aortic aneurysms: a histopathologic marker of aneurysmal degeneration with pathophysiologic implications. *J Vasc Surg*. Vol.21, No.5, (May), pp. 761-771.
- Hong H, Yang Y, Liu B, Cai W. (2010). Imaging of Abdominal Aortic Aneurysm: the present and the future. *Curr Vasc Pharmacol*. Vol.8, No.6, (Nov), pp. 808-819.
- Iezzi R, Basilico R, Giancristofaro D, Pascali D, Cotroneo AR, Storto ML. (2009). Contrast-enhanced ultrasound versus color duplex ultrasound imaging in the follow-up of patients after endovascular abdominal aortic aneurysm repair. *J Vasc Surg*. Vol.49, No.3, (Mar), pp. 552-560.
- Imura T, Yamamoto K, Kanamori K, Mikami T, Yasuda H. (1986). Non-invasive ultrasonic measurement of the elastic properties of the human abdominal aorta. *Cardiovasc Res*. Vol.20, No.3, (Mar), pp. 208-214.
- Kaspersen JH, Sjølie E, Wesche J, Asland J, Lundbom J, Odegård A, Lindseth F, Nagelhus Hernes TA. (2003). Three-dimensional ultrasound-based navigation combined with preoperative CT during abdominal interventions: a feasibility study. *Cardiovasc Intervent Radiol*. Vol.26, No.4, (Jul-Aug), pp. 347-356.
- Kasthuri RS, Stivaros SM, Gavan D. (2005). Percutaneous ultrasound-guided thrombin injection for endoleaks: an alternative. *Cardiovasc Intervent Radiol*. Vol.28, No.1, (Jan-Feb), pp. 110-112.
- Kim YS, Rhim H, Choi MJ, Lim HK, Choi D. (2008). High-intensity focused ultrasound therapy: an overview for radiologists. *Korean J Radiol*. Vol.9, No.4, (Aug), pp. 291-302.
- Kopp R, Zürn W, Weidenhagen R, Meimarakis G, Clevert DA. (2010). First experience using intraoperative contrast-enhanced ultrasound during endovascular aneurysm repair for infrarenal aortic aneurysms. *J Vasc Surg*. Vol.51, No.5, (May), pp. 1103-1110.
- Kuhn M, Bonnin RLL, Davey MJ, Rowland JL, Langlois S. (2000). Emergency Department Ultrasound Scanning for Abdominal Aortic Aneurysm: Accessible, Accurate, and Advantageous. *Ann Emerg Med* Vol.36, No.3, (Sep), pp. 219-223.
- Länne T, Sonesson B, Bergqvist D, Bengtsson H, Gustafsson D. (1992). Diameter and compliance in the male human abdominal aorta: influence of age and aortic aneurysm. *Eur J Vasc Surg*. Vol.6, No.2, (Mar), pp. 178-184.
- Lederle FA, Wilson SE, Johnson GR, Reinke DB, Littooy FN, Acher CW, Messina LM, Ballard DJ, Ansel HJ. (1995). Variability in measurement of abdominal aortic aneurysms. Abdominal Aortic Aneurysm Detection and Management Veterans Administration Cooperative Study Group. *J Vasc Surg*. Vol.21, No.6, (Jun), pp. 945-952.

- Lee KR, Walls WJ, Martin NL, Templeton AW. (1975). A practical approach to the diagnosis of abdominal aortic aneurysms. *Surgery*. Vol.78, No.2, (Aug), pp. 195-201.
- Lie T, Lundbom J, Hatlinghus S, Grønningsaeter A, Ommedal S, Aadahl P, Saether OD, Myhre HO. (1997). Ultrasound imaging during endovascular abdominal aortic aneurysm repair using the Stentor bifurcated endograft. *J Endovasc Surg*. Vol.4, No.3, (Aug), pp. 272-278.
- Lindblad B, Dias N, Malina M, Ivancev K, Resch T, Hansen F, Sonesson B. (2004). Pulsatile wall motion (PWM) measurements after endovascular abdominal aortic aneurysm exclusion are not useful in the classification of endoleak. *Eur J Vasc Endovasc Surg*. Vol.28, No.6, (Dec), pp. 623-628.
- Lindholt JS, Vammen S, Juul S, Henneberg EW, Fasting H. (1999). The validity of ultrasonographic scanning as screening method for abdominal aortic aneurysm. *Eur J Vasc Endovasc Surg*. Vol.17, No.6, (Jun), pp. 472-475.
- Lindner JR, Villanueva FS, Dent JM, Wei K, Sklenar J, Kaul S. (2000). Assessment of resting perfusion with myocardial contrast echocardiography: theoretical and practical considerations. *Am Heart J*. Vol.139, No.2pt1, (Feb), pp. 231-240.
- Long A, Rouet L, Bissery A, Rossignol P, Mouradian D, Sapoval M. (2005). Compliance of abdominal aortic aneurysms evaluated by tissue Doppler imaging: correlation with aneurysm size. *J Vasc Surg*. Vol.42, No.1, (Jul), pp. 18-26.
- Malina M, Länne T, Ivancev K, Lindblad B, Brunkwall J. (1998). Reduced pulsatile wall motion of abdominal aortic aneurysms after endovascular repair. *J Vasc Surg*. Vol.27, No.4, (Apr), pp. 624-631.
- Malkawi AH, Hinchliffe RJ, Holt PJ, Loftus IM, Thompson MM. (2010). Percutaneous access for endovascular aneurysm repair: a systematic review. *Eur J Vasc Endovasc Surg*. Vol.39, No.6, (Jun), pp. 676-682.
- Malkawi AH, Hinchliffe RJ, Xu Y, Holt PJ, Loftus IM, Thompson MM. (2010). Patient-specific biomechanical profiling in abdominal aortic aneurysm development and rupture. *J Vasc Surg*. Vol.52, No.2, (Aug), pp. 489-488.
- Manning BJ, Kristmundsson T, Sonesson B, Resch T. (2009). Abdominal aortic aneurysm diameter: a comparison of ultrasound measurements with those from standard and three-dimensional computed tomography reconstruction. *J Vasc Surg*. Vol.50, No.2, (Aug), pp. 263-268.
- Manstad-Hulaas F, Ommedal S, Tangen GA, Aadahl P, Hernes TN. (2007). Side-branched AAA stent graft insertion using navigation technology: a phantom study. *Eur Surg Res*. Vol.39, No.6, (), pp. 364-371.
- McGregor JC, Pollock JG, Anton HC. (1975). The value of ultrasonography in the diagnosis of abdominal aortic aneurysm. *Scott Med J*. Vol.20, No.3, (May), pp. 133-137.
- McWilliams RG, Martin J, White D, Gould DA, Rowlands PC, Haycox A, Brennan J, Gilling-Smith GL, Harris PL. (2002). Detection of endoleak with enhanced ultrasound imaging: comparison with biphasic computed tomography. *J Endovasc Ther*.9, No.2, (Apr), pp. 170-179.
- Mirza TA, Karthikesalingam A, Jackson D, Walsh SR, Holt PJ, Hayes PD, Boyle JR. (2010). Duplex ultrasound and contrast-enhanced ultrasound versus computed tomography for the detection of endoleak after EVAR: systematic review and bivariate meta-analysis. *Eur J Vasc Endovasc Surg*. Vol.39, No.4, (Apr), pp. 418-428.

- Moll FL, Powell JT, Fraedrich G, Verzini F, Haulon S, Waltham M, van Herwaarden JA, Holt PJ, van Keulen JW, Rantner B, Schlösser FJ, Setacci F, Ricco JB. (2011). Management of abdominal aortic aneurysms clinical practice guidelines of the European society for vascular surgery. *Eur J Vasc Endovasc Surg*. Vol.41, No.S1, (Jan), pp. S1-S58.
- Moxon JV, Parr A, Emeto TI, Walker P, Norman PE, Golledge J (2010). Diagnosis and Monitoring of Abdominal Aortic Aneurysm: Current Status and Future Prospects. *Curr Probl Cardiol*. Vol.35, No.10, (Oct), pp. 512-548.
- Mulder DS, Winsberg F, Cole CM, Blundell PE, Scott HJ. (1973). Ultrasonic "B" scanning of abdominal aneurysms. *Ann Thorac Surg*. Vol.16, No.4, (Oct), pp. 361-367.
- Nagre SB, Taylor SM, Passman MA, Patterson MA, Combs BR, Lowman BG, Jordan WD Jr. (2011). Evaluating outcomes of endoleak discrepancies between computed tomography scan and ultrasound imaging after endovascular abdominal aneurysm repair. *Ann Vasc Surg*. Vol.25, No.1, (Jan), pp. 94-100.
- Nightingale K, Soo MS, Nightingale R, Trahey G. (2002). Acoustic radiation force impulse imaging: in vivo demonstration of clinical feasibility. *Ultrasound Med Biol*. Vol.28, No.2, (Feb), pp. 227-235.
- Ophir J, Céspedes I, Ponnekanti H, Yazdi Y, Li X. (1991). Elastography: a quantitative method for imaging the elasticity of biological tissues. *Ultrason Imaging*. Vol.13, No.2, (Apr), pp. 111-134.
- Patel MS, Carpenter JP. (2010). The value of the initial post-EVAR computed tomography angiography scan in predicting future secondary procedures using the Powerlink stent graft. *J Vasc Surg*. Vol.52, No.5, (Nov), pp. 1135-1139.
- Petersen E, Wagberg F, Angquist KA. (2002). Proteolysis of the abdominal aortic aneurysm wall and the association with rupture. *Eur J Vasc Endovasc Surg*. Vol.23, No.2, (Feb), pp. 153-157.
- Raffetto JD, Khalil RA. (2008). Matrix metalloproteinases and their inhibitors in vascular remodeling and vascular disease. *Biochem Pharmacol*. Vol.75, No.2, (Jan), pp. 346-359.
- Reardon, RF; Cook, T; Plummer, D (2008). Abdominal aortic aneurysm, In *Emergency Ultrasound 2nd Edition*, O.J. Ma; J.R. Mateer; M. Blaiwas (Eds), 149-167. The McGraw-Hill Companies, Inc. ISBN 978-0-07-147904-2. China.
- Sebesta P, Klika T, Zdrahal P, Kramar J. (1998). Ruptured abdominal aortic aneurysm: role of initial delay on survival. *J Mal Vasc*. Vol.23, No.5, (Dec), pp. 361-367.
- Segal BL, Likoff W, Asperger Z, Kingsley B. (1966). Ultrasound diagnosis of an abdominal aortic aneurysm. *Am J Cardiol*. Vol.17, No.1, (Jan), pp. 101-103.
- Singh K, Bønaa KH, Solberg S, Sørli DG, Bjørk L. (1998). Intra- and interobserver variability in ultrasound measurements of abdominal aortic diameter. The Tromsø Study. *Eur J Vasc Endovasc Surg*. Vol.15, No.6, (Jun), pp.497-504.
- Solberg OV, Lindseth F, Torp H, Blake RE, Nagelhus Hernes TA. (2007). Freehand 3D ultrasound reconstruction algorithms--a review. *Ultrasound Med Biol*. Vol.33, No.7, (Jul), pp. 991-1009.
- Sonesson B, Hansen F, Stale H, Länne T. (1993). Compliance and diameter in the human abdominal aorta--the influence of age and sex. *Eur J Vasc Surg*. Vol.7, No.6, (Nov), pp. 690-697.

- Sonesson B, Sandgren T, Länne T. (1999). Abdominal aortic aneurysm wall mechanics and their relation to risk of rupture. *Eur J Vasc Endovasc Surg*. Vol.18, No.6, (Dec), pp. 487-493.
- Sprouse L.R., G.H. Meier, F.N. Parent, R.J. DeMasi, M.H. Glickman and G.A. Barber. (2004). Is ultrasound more accurate than axial computed tomography for determination of maximal abdominal aortic aneurysm diameter? *Eur J Vasc Endovasc Surg*. Vol.28, No.1, (Jul), pp. 28-35.
- Staub D, Patel MB, Tibrewala A, Ludden D, Johnson M, Espinosa P, Coll B, Jaeger KA, Feinstein SB. (2010a). Vasa vasorum and plaque neovascularization on contrast-enhanced carotid ultrasound imaging correlates with cardiovascular disease and past cardiovascular events. *Stroke*. Vol.41, No.1, (Jan), pp. 41-7.
- Staub D, Schinkel AF, Coll B, Coli S, van der Steen AF, Reed JD, Krueger C, Thomenius KE, Adam D, Sijbrands EJ, ten Cate FJ, Feinstein SB. (2010b). Contrast-enhanced ultrasound imaging of the vasa vasorum: from early atherosclerosis to the identification of unstable plaques. *JACC Cardiovasc Imaging*. Vol.3, No.7, (Jul), pp. 761-771.
- Sun Z. (2006). Diagnostic value of color duplex ultrasonography in the follow-up of endovascular repair of abdominal aortic aneurysm. *J Vasc Interv Radiol*. Vol.17, No.5, (May), pp. 759-764.
- Takagi H, Goto SN, Matsui M, Manabe H, Umemoto T. (2010). A further meta-analysis of population-based screening for abdominal aortic aneurysm. *J Vasc Surg*. Vol.52, No.4, (Oct), pp. 1103-1108.
- Ten Bosch JA, Rouwet EV, Peters CT, Jansen L, Verhagen HJ, Prins MH, Teijink JA. (2010). Contrast-enhanced ultrasound versus computed tomographic angiography for surveillance of endovascular abdominal aortic aneurysm repair. *J Vasc Interv Radiol*. Vol.21, No.5, (May), pp. 638-643.
- ten Kate GL, Sijbrands EJ, Valkema R, ten Cate FJ, Feinstein SB, van der Steen AF, Daemen MJ, Schinkel AF. (2010). Molecular imaging of inflammation and intraplaque vasa vasorum: a step forward to identification of vulnerable plaques? *J Nucl Cardiol*. Vol.17, No.5, (), pp. 897-912.
- Thapar A, Cheal D, Hopkins T, Ward S, Shalhoub J, Yusuf SW. (2010). Internal or external wall diameter for abdominal aortic aneurysm screening? *Ann R Coll Surg Engl*. Vol.92, No.6, (Sep), pp. 503-505.
- Thomas PR, Shaw JC, Ashton HA, Kay DN, Scott RA. (1994). Accuracy of ultrasound in a screening programme for abdominal aortic aneurysms. *J Med Screen*. Vol.1, No.1, (Jan), pp. 3-6.
- Thompson MM, Jones L, Nasim A, Sayers RD, Bell PR. (1996). Angiogenesis in abdominal aortic aneurysms. *Eur J Vasc Endovasc Surg*. Vol.11, No.4, (May), pp. 464-469.
- Thubrikar MJ, Labrosse M, Robicsek F, Al-Soudi J, Fowler B. (2001). Mechanical properties of abdominal aortic aneurysm wall. *J Med Eng Technol*. Vol.25, No. 4, (Jul-Aug), pp. 133-142.
- Tutein Nolthenius RP, van den Berg JC, Moll FL. (2000). The value of intraoperative intravascular ultrasound for determining stent graft size (excluding abdominal aortic aneurysm) with a modular system. *Ann Vasc Surg*. Vol.14, No.4, (Jul), pp. 311-317.

- Twine CP, Williams IM. (2011). Systematic review and meta-analysis of the effects of statin therapy on abdominal aortic aneurysms. *Br J Surg*. Vol.98, No.3, (Mar), pp. 346-353.
- Unsgård G, Solheim O, Lindseth F, Selbekk T. (2011). Intra-operative imaging with 3D ultrasound in neurosurgery. *Acta Neurochir Suppl*. Vol.109, pp. 181-186.
- Vaezy S, Martin R, Crum L. (2001). High intensity focused ultrasound: a method of hemostasis. *Echocardiography*. Vol.18, No.4, (May), pp. 309-315.
- van Essen JA, Gussenhoven EJ, van der Lugt A, Huijsman PC, van Muiswinkel JM, van Sambeek MR, van Dijk LC, van Urk H. (1999). Accurate assessment of abdominal aortic aneurysm with intravascular ultrasound scanning: validation with computed tomographic angiography. *J Vasc Surg*. Vol.29, No.4, (Apr), pp. 631-638.
- Villanueva FS. (2008). Molecular imaging of cardiovascular disease using ultrasound. *J Nucl Cardiol*. Vol. 15, No.4, (Jul-Aug); pp. 576-586.
- Vorp DA. (2007). Biomechanics of abdominal aortic aneurysm. *J Biomech*. Vol.40, No.9, (), pp. 1887-1902.
- Wheeler WE, Beachley MC, Ranniger K. (1976). Angiography and ultrasonography. A comparative study of abdominal aortic aneurysms. *Am J Roentgenol*. Vol.126, No.1, (Jan), pp. 95-100.
- White RA, Donayre C, Kopchok G, Walot I, Wilson E, de Virgilio C. (1997). Intravascular ultrasound: the ultimate tool for abdominal aortic aneurysm assessment and endovascular graft delivery. *J Endovasc Surg*. Vol.4, No.1, (Feb), pp. 45-55.
- White RA, Verbin C, Kopchok G, Scoccianti M, de Virgilio C, Donayre C. (1995). The role of cinefluoroscopy and intravascular ultrasonography in evaluating the deployment of experimental endovascular prostheses. *J Vasc Surg*. Vol.21, No.3, (Mar), pp. 365-74.
- Wilson K, Bradbury A, Whyman M, Hoskins P, Lee A, Fowkes G, McCollum P, Ruckley CV. (1998). Relationship between abdominal aortic aneurysm wall compliance and clinical outcome: a preliminary analysis. *Eur J Vasc Endovasc Surg*. Vol.15, No.6, (Jun), pp. 472-477.
- Wilson K, Whyman M, Hoskins P, Lee AJ, Bradbury AW, Fowkes FG, Ruckley CV. (1999). The relationship between abdominal aortic aneurysm wall compliance, maximum diameter and growth rate. *Cardiovasc Surg*. Vol.7, No.2, (Mar), pp. 208-213.
- Wilson KA, Lee AJ, Lee AJ, Hoskins PR, Fowkes FG, Ruckley CV, Bradbury AW. (2003). The relationship between aortic wall distensibility and rupture of infrarenal abdominal aortic aneurysm. *J Vasc Surg*. Vol.37, No.1, (Jan), pp. 112-117.
- Winsberg F, Cole CM. (1972). "Continuous ultrasound visualization of the pulsating abdominal aorta. *Radiology*. Vol.103, No.2, (May), pp. 455-457.
- Zanchetta M, Rigatelli G, Pedon L, Zennaro M, Ronsivalle S, Maiolino P. (2003). IVUS guidance of thoracic and complex abdominal aortic aneurysm stent-graft repairs using an intracardiac echocardiography probe: preliminary report. *J Endovasc Ther*. Vol.10, No.2, (Apr), pp. 218-226.
- Zankl AR, Schumacher H, Krumsdorf U, Katus HA, Jahn L, Tiefenbacher CP. (2007). Pathology, natural history and treatment of abdominal aortic aneurysms. *Clin Res Cardiol*. Vol.96, No.3, (Mar), pp-140-151.



Diagnosis, Screening and Treatment of Abdominal, Thoracoabdominal and Thoracic Aortic Aneurysms

Edited by Prof. Reinhart Grundmann

ISBN 978-953-307-466-5

Hard cover, 414 pages

Publisher InTech

Published online 12, September, 2011

Published in print edition September, 2011

This book considers mainly diagnosis, screening, surveillance and treatment of abdominal, thoracoabdominal and thoracic aortic aneurysms. It addresses vascular and cardiothoracic surgeons and interventional radiologists, but also anyone engaged in vascular medicine. The high mortality of ruptured aneurysms certainly favors the recommendation of prophylactic repair of asymptomatic aortic aneurysms (AA) and therewith a generous screening. However, the comorbidities of these patients and their age have to be kept in mind if the efficacy and cost effectiveness of screening and prophylactic surgery should not be overestimated. The treatment recommendations which will be outlined here, have to regard on the one hand the natural course of the disease, the risk of rupture, and the life expectancy of the patient, and on the other hand the morbidity and mortality of the prophylactic surgical intervention. The book describes perioperative mortality after endovascular and open repair of AA, long-term outcome after repair, and the cost-effectiveness of treatment.

How to reference

In order to correctly reference this scholarly work, feel free to copy and paste the following:

Reidar Brekken, Torbjørn Dahl and Toril A. N. Hernes (2011). Ultrasound in Abdominal Aortic Aneurysm, Diagnosis, Screening and Treatment of Abdominal, Thoracoabdominal and Thoracic Aortic Aneurysms, Prof. Reinhart Grundmann (Ed.), ISBN: 978-953-307-466-5, InTech, Available from:
<http://www.intechopen.com/books/diagnosis-screening-and-treatment-of-abdominal-thoracoabdominal-and-thoracic-aortic-aneurysms/ultrasound-in-abdominal-aortic-aneurysm>

INTECH
open science | open minds

InTech Europe

University Campus STeP Ri
Slavka Krautzeka 83/A
51000 Rijeka, Croatia
Phone: +385 (51) 770 447
Fax: +385 (51) 686 166
www.intechopen.com

InTech China

Unit 405, Office Block, Hotel Equatorial Shanghai
No.65, Yan An Road (West), Shanghai, 200040, China
中国上海市延安西路65号上海国际贵都大饭店办公楼405单元
Phone: +86-21-62489820
Fax: +86-21-62489821

© 2011 The Author(s). Licensee IntechOpen. This chapter is distributed under the terms of the [Creative Commons Attribution-NonCommercial-ShareAlike-3.0 License](#), which permits use, distribution and reproduction for non-commercial purposes, provided the original is properly cited and derivative works building on this content are distributed under the same license.