

Coronary Arteriovenous Fistula

Recep Demirbag
Harran University Medical Faculty, Sanliurfa
Turkey

1. Introduction

Coronary anomalies are defined as rare anatomic patterns and are seen in approximately 1 to 5% of all patients undergoing coronary angiography (Tuncer et al., 2006; Angelini, 1999; Friedman et al., 2007). Classification of anomalies of the coronary arteries is shown in table-1 (Angelini, 2007).

1. Anomalies of origination and course
<ul style="list-style-type: none"> • Absent left main trunk, • Anomalous location of coronary ostium within aortic root or near proper aortic sinus of Valsalva (for each artery) • Anomalous location of coronary ostium outside normal "coronary" aortic sinuses • Anomalous location of coronary ostium at improper sinus (which may involve joint origination or "single" coronary pattern) • Single coronary artery
2. Anomalies of intrinsic coronary arterial anatomy
<ul style="list-style-type: none"> • Congenital ostial stenosis or atresia • Coronary ostial dimple • Coronary ectasia or aneurysm • Absent coronary artery • Coronary hypoplasia • Intramural coronary artery (muscular bridge) • Subendocardial coronary course • Coronary crossing • Anomalous origination of posterior descending artery from the anterior descending branch or a septal penetrating branch • Split right or left coronary arteries • Ectopic origination of first septal branch
3. Anomalies of coronary termination
<ul style="list-style-type: none"> • Inadequate arteriolar/capillary ramifications • Coronary artery fistulas
4. Anomalous anastomotic vessels

Table 1. Classification of anomalies of the coronary arteries according to Angelini

Coronary artery fistulae (CAF) are classified as abnormalities of termination and are defined as congenital or acquired an abnormal communication between the right or left coronary arterial systems and a cardiac chamber or vessel, having bypassed the myocardial capillary bed (Friedman et al., 2007). They comprise 13% of congenital coronary artery anomalies (Table-2) (Yamanaka et al., 1990).

	No	Incidence (%)	Anomalies (%)
Total coronary arteriograms	126.595		
Total coronary anomalies	1,686	1.33	
Anomalies of origin and distribution	1,461	1.15	87
Coronary artery fistulae	225	0.18	13

Table 2. Isolated congenital coronary artery anomalies (Yamanaka et al. 1990)

The CAFs were first described by Josef Hyrtl in 1851 (Friedman et al., 2007). The incidence of the CAFs is changes according to genetic or ethnic racial factors or either to different geographical regions (Table-3). The true incidence is difficult to evaluate because about most of the cases may be asymptomatic and clinically indictable until an echocardiogram or catheterization is performed. The incidence of CAFs is 0.3-0.8% in patient's undergone diagnostic cardiac catheterizations (Angelini, 1999; Cebi et al., 2008). Echocardiographic studies estimated the incidence of congenital CAFs in children at 0.06 to 0.2% (Sherwood et al., 1999; Hsieh et al., 2002).

Sex predilection is controversial. In a study it is found out that males are more affected than females, with a ratio of 2.3 to 1 (Ata et al., 2009). Another study shows that there is no sex predilection for CAF (Chiu et al., 2008).

Author	Patients	CAFs	Incidence (%)	Population
Gillebert 1986	14,708	20	0.13	Belgian
Yamanaka et al., 1990	126.295	225	0.18	American
Bhandari 1993	4,486	8	0.11	Indian
Cebi 2008	18,272	10	0.05	German
Vavuranakis 1995	33,600	34	0.10	American
Nawa 1996	704	15	2.1	Japanese
Kardos 1997	7,694	5	0.06	Hungarian
Yıldız 2010	12,450	12	0.09	Turkish
Said 2006	30,829	51	0.16	Dutch
Chiu et al. 2008	28.210	125	0.44	Chinese

Table 3. Angiographic incidence of CAFs in different adult population.

Major sites of origin of the fistulae are from the right coronary artery (40-60%), left anterior descending (30-60%), circumflex and a combination thereof (Gupta-Malhotra, 2010). The CAFs predominantly drain into the right side of the heart (92%) into the right ventricle in 41%, the right atrium in 26%, the coronary sinus in 7%, the pulmonary in 17%, and superior vena cava in 1% of cases (Levin et al., 1978). Its connection between coronary sinus; left atrium, and left ventricle is unusual (Table-4) (Said, 2010).

Termination sites	McNamara 1969 (n=172)	Levin 1978 (n=363)	Hobbs 1982 (n=122)	Kaniya 2002 (n=266)
Right Ventricle	40	41	3	34
Right atrium	35	26	7	18
Pulmonary artery	16	17	66	38
Coronary sinus	-	7	-	-
Left atrium	6	5	7	2
Left ventricle	3	3	17	5
Superior Vena Cava	-	1	-	-
Other sites	-	-	-	3

Table 4. Termination sites of congenital solitary CAFs (%) (Said, 2010)

Approximately 10-30% of patients with CAFs also have another congenital cardiovascular anomaly (Cheung et al., 2001; Holzer et al., 2004). Congenital CAFs may occur as an isolated finding or may appear in the context of other congenital cardiac anomalies or structural heart defects, most frequently in critical pulmonary stenosis or atresia with an intact interventricular septum and in pulmonary artery branch stenosis, tetralogy of Fallot, coarctation of the aorta, hypoplastic left heart syndrome, patent ductus arteriosus, ventricular septal defect, atrial septal defect, and aortic atresia (luo et al., 2006; Ata et al., 2009).

2. Etiology

Exact etiologies of CAFs have not been identified. They are usually occurring congenitally or acquiredly. The congenital causes are responsible for most of them. Congenital fistulous connections between the coronary system and a cardiac chamber appear to represent persistence of embryonic intertrabecular spaces and sinusoids (Lin et al., 2009).

The acquired causes of CAFs include coronary atherosclerosis, Takayasu arteritis, polymyositis, cardiac surgery, percutaneous coronary intervention, septal myectomy, closed-chest ablation of accessory pathway, permanent pacemaker placement, transbronchial lung biopsy, acute myocardial infarction, and after repeated myocardial biopsies in cardiac transplantation (Table-5). The penetrating and nonpenetrating chest trauma may also lead to CAF. Traumatic CAFs are most common between the right coronary artery and the right side of the heart. Although acquired causes are reported to be rare, it is likely that the true incidence is underestimated (Luo et al., 2006).

Seventy-six patients (1985-1995) with 96 CAFs were identified from a review of the literature by Said et al. They reported a congenital origin in 64% of these 76 cases and an acquired cause in 36% (Said et al., 1997).

3. Pathophysiology

Normally, 2 coronary arteries arise from the root of the aorta and taper progressively as they branch to supply the cardiac parenchyma. A fistula exists if a substantive communication arises bypassing the myocardial capillary phase and communicates with a low-pressure cardiac cavity (atria or ventricle) or with a branch of the systemic or pulmonary systems. Anomalies of the coronary arteries can be considered as the result of a rudimentary

persistence of an embryologic coronary arterial structure, a failure of normal coronary development, a failure of the normal atrophic process of development, or the misplacement of a connection of an otherwise normal coronary artery. CAFs may appear as a persistence of sinusoidal connections between the lumens of the primitive tubular heart that supply myocardial blood flow in the early embryologic period. The mechanism is related to the diastolic pressure gradient and runoff from the coronary vasculature to a low-pressure receiving cavity. If the fistula is large, the intracoronary diastolic perfusion pressure diminishes progressively. Normal thin-walled vessels exist at the arteriolar level that may drain into the cardiac cavity (arteriosinusoidal vessels) and venous communications (thebesian veins) to the right atrium. These small vessels do not steal significant nutrient flow and do not constitute fistulous connections. Fistulae usually are large (>250 mm) and dilated or ectatic, and they tend to enlarge over time. Often, the limits of what constitutes a fistula and what constitutes a normal vessel are debated (Friedman et al., 2007).

A. Congenital
1. Embryonic
2. Multiple; systemic hemangioma
B. Acquired
1. Closed-chest ablation of accessory pathway
2. Percutaneous coronary balloon angioplasty
3. Hypertrophic cardiomyopathy
4. Right/left ventricular septal myectomy
5. Penetrating and nonpenetrating trauma
6. Acute myocardial infarction
7. Dilated cardiomyopathy
8. Mitral valve surgery
9. "Sign" of mural thrombus
10. Tumor
11. Permanent pacemaker placement
12. Cardiac transplant
13. Endomyocardial biopsy
14. Coronary artery bypass grafting

Table 5. Causes and Associations of Coronary Artery Fistula (Angelini, 1999)

Over time, the coronary artery leading to the fistulous tract progressively dilates, which, in turn, may progress to frank aneurysm formation, intimal ulceration, medial degeneration, intimal rupture, atherosclerotic deposition, calcification, side-branch obstruction, mural thrombosis, and, rarely, rupture (Gupta-Malhotra, 2010). The histopathologic findings which are reported in the literature are myocardial hypertrophy with focal fibrosis, dilatation of the involved vessel, and mural thinning of the fistula wall with fresh thrombosis and concomitant atherosclerosis (Zenooz et al., 2009)

CAFs were classified into 2 types according to different patterns of morphology and pathology: type I was a solitary coronary to cardiac chamber or great vessel fistula, whereas type II comprised coronary artery left ventricle (LV) multiple microfistulas. Type I CAFs were also classified into 2 different sizes: macro (diameter ≥ 1.5 mm (Figure-1) and small (diameter <1.5 mm) (Chiu et al., 2008).

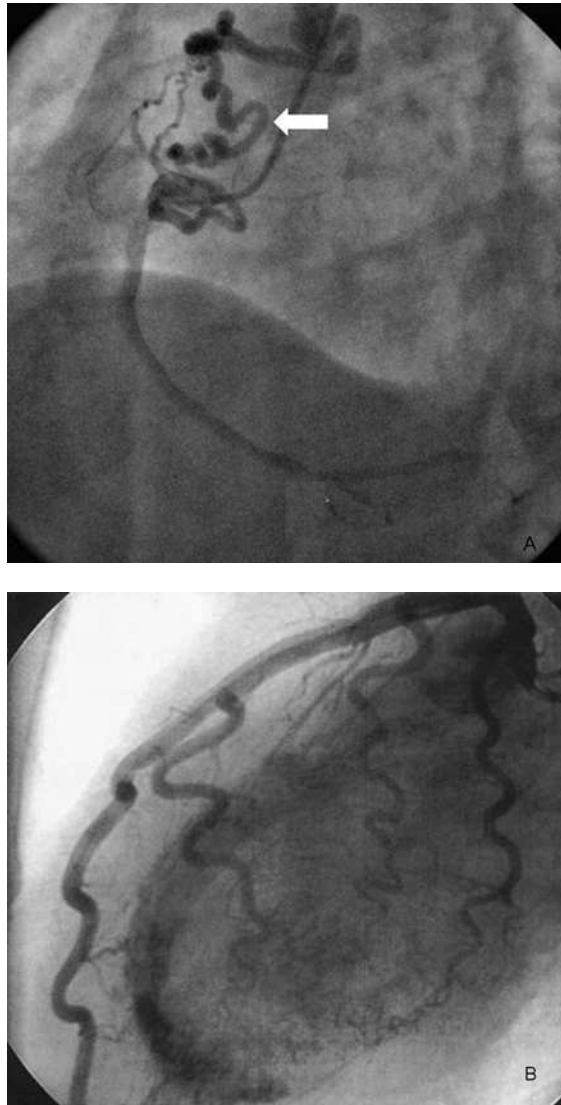


Fig. 1. A. Coronary angiography in the left anterior oblique view (60 degree) shows a large tortuous coronary fistula (thick white arrows) from the proximal right coronary artery (RCA) to the main pulmonary artery (Chiu et al., 2008).

B. Angiogram (left lateral projection) shows the multiple fistulae originating from the left coronary system (Kose et al., 2005)

Origin, termination and pathway of CAFs are explained by Said et al (Said et al.,2006). He reported that recognized for the origin and termination each, two morphological types: single or multiple channels and for the pathways three different types: tortuous/multiple,

tortuous/single and straight/single channels with or without aneurysmal formation or dilatation of the fistula-related artery (Figure-2). Fistulas with single communications are much more higher compared with multiple fistulas (Kose & G. Heper, 2005).

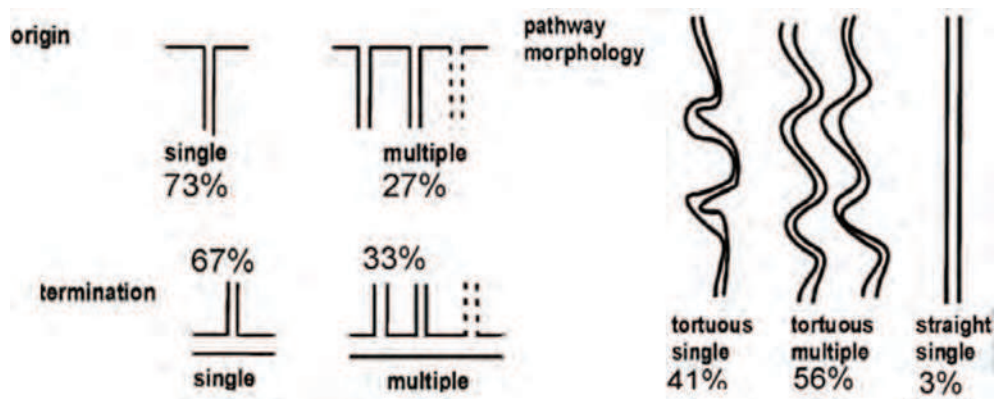


Fig. 2. An art drawing illustrating origin, pathways and ending of CAFs (Said 2006)

The mechanism of myocardial ischemia or heart failure induced by CAFs is thought to be the result of a shunting and steal phenomenon of normal coronary flow, flow-mediated inflammatory vascular changes, vascular trauma or dissection, coronary compression, abnormal myocardial perfusion pressure due to intravascular stenoses or to abnormal drainage compartments, micro- or macro-vascular venous thrombosis, and micro- or macrovascular arterial thrombosis (Chiu et al., 2008; Valente et al., 2010; Gowda et al., 2006). Mechanisms of coronary thrombosis in CAF include abnormal flow patterns associated with vascular ectasia, coronary tortuosity, abrupt changes in vessel caliber, and abnormal vascular connections; potential for congenitally intrinsic local or circulating changes in the clotting or fibrinolytic cascade; and effects of direct vascular trauma (Fahey et al., 2008)

The coronary arterial fistula can be direct in its course and connection, or it can take a convoluted and worm-like path to its site of drainage. Occasionally, the fistulous connections can become aneurysmal. The involved coronary artery is typically dilated when the distal fistula is large, as there is preferential flow, or "steal", from the coronary arterial system into the lower resistance chamber or vessel. The steal phenomenon associated with CAF is classified by two types. One type is the *persistent steal* caused by the existence of large fistulous tracts. The other type, *episodic steal*, is caused by physiologic factors which can be seen in small and multiple CAF (Angelini, 2002b)

When the fistula drains into the right side of the heart, the volume load is increased in this side as well as in the pulmonary vascular bed, the left atrium and the left ventricle. When the fistula drains into the left atrium or the left ventricle, although there is volume overloading of these chambers, there is no increase in the pulmonary blood flow. A left-to-right shunt exists in over 90% of cases. The size of the shunt is determined by the size of the fistula and the pressure difference between the coronary artery and the chamber into which the fistula drains. However, the shunt ratio is generally small regardless of age; in many cases, a shunt is not detectable. Large shunts are particularly prevalent when the fistula terminates in the atrial chambers (Nakayama et al., 2010). If a large left-to-right shunt exists,

CAFs are complicated as pulmonary hypertension and congestive heart failure; others include rupture or thrombosis of the fistula or associated arterial aneurysm or coronary steal phenomena (Qureshi, 2006; Friedman et al., 2007).

4. Clinical features

The clinical presentation of coronary artery fistulas is mainly dependent on the severity of the left-to-right shunt. The majority of adult patients with CAFs are usually asymptomatic. However, their natural history can be variable and they may cause symptoms in some patients at any age. The type of fistula, shunt volume, site of the shunt, and the presence of other cardiac conditions are associated with the clinical findings of CAF. While small coronary artery fistulae are usually asymptomatic due to small shunt flow, large coronary artery fistulae are mostly symptomatic causing cardiac heart failure, pulmonary arterial hypertension, myocardial infarction, arrhythmias, endocarditis, or rupture (Dursun et al., 2009). The symptoms of CAFs in adult patients usually begin in the 5th or 6th decade (Qureshi, 2006). A smaller percentage of pediatric patients tend to be asymptomatic, unlike adults. It is mentioned in an article that most patients with these fistulas younger than 20 years were asymptomatic compared with patients older than 20 years (Liberthson et al., 1979). It is very rare to diagnose a CAF in the neonate (Zenooz et al., 2010).

Dyspnea on exertion is the most common symptom of CAFs. The other symptoms of CAFs are angina, fatigue, palpitations and paroxysmal nocturnal dyspnea. Angina pectoris may be rarely seen in patients without arteriosclerotic coronary artery disease. Patients with angina pectoris are mostly older than 40 years old and they have coexistent coronary artery stenosis and/or have large or multiple fistulas. Rarely, the presenting feature can be pericardial effusion or sudden death (Chiue et al., 2008; Gowda et al., 2006).

It is commonly believed that the lesion is incidentally detected on routine examination or is an incidental finding during coronary angiogram (Juraschek et al., 2011). The most common clinical presentation of CAF is a continuous heart murmur. CAFs are usually suspected when a murmur is detected in asymptomatic individuals. The prevalence of a continuous murmur varies in different reports depending on the population studied. The location on the chest wall where the murmur is the loudest depends on where the fistula enters the heart. It was reported that a continuous murmur was found in 3-9 % in patients with CAFs (luo et al., 2006). The characteristic of murmur is a soft, at a grade of 2/6-4/6, continuous murmur that tends to be crescendo- decrescendo in both systole and diastole but louder in diastole. The murmur is often confused with other conditions, such as patent ductus arteriosus, arteriovenous shunts, pulmonary arteriovenous fistula, ruptured sinus of Valsalva aneurysm, aortopulmonary window, prolapse of the right aortic cusp with a suprasternal ventricular septal defect, internal mammary artery to pulmonary artery fistula, and systemic arteriovenous fistula. It is to be underlined that in these conditions, continuous murmurs reach their peak intensity at the time of the second heart sound. CAFs should be considered in many symptomatic or asymptomatic patients with cardiac murmurs (Ata et al., 2009).

5. Diagnostic methods

Most frequently used diagnostic methods are: usually include physical examination, electrocardiography, chest X-ray, echocardiography, multidetector computed tomography

and angiocardiology. The other technical methods are rarely used in the diagnosis of CAF. Cardiac enzyme and brain natriuretic peptid levels may be elevated in patients with CAF. The screening and the treatment guideline suggested by Angelini is shown in Figure-3 (Angelini, 2002b).

Although the electrocardiogram shows the left ventricular volume overload and occasionally ischaemic changes, it is usually unhelpful in CAFs. Generally, the chest x-ray is normal, but occasionally moderate cardiomegaly may be present when there is a large left-to-right shunt (Qureshi, 2006). The treadmill evaluation of coronary function is largely negated by the consistently high incidence of false-positive and false-negative results. This is why the treadmill is not to be used frequently and reliably. Myocardial perfusion scintigraphic studies may be used to assess myocardial ischaemia before and after treatment of CAFs. Magnetic resonance imaging may also help in confirming the diagnosis, as the proximal coronary arteries or even the whole length of the fistula vessel may be seen. Intravascular Doppler ultrasonography provides further insight into the pathophysiology of CAFs.

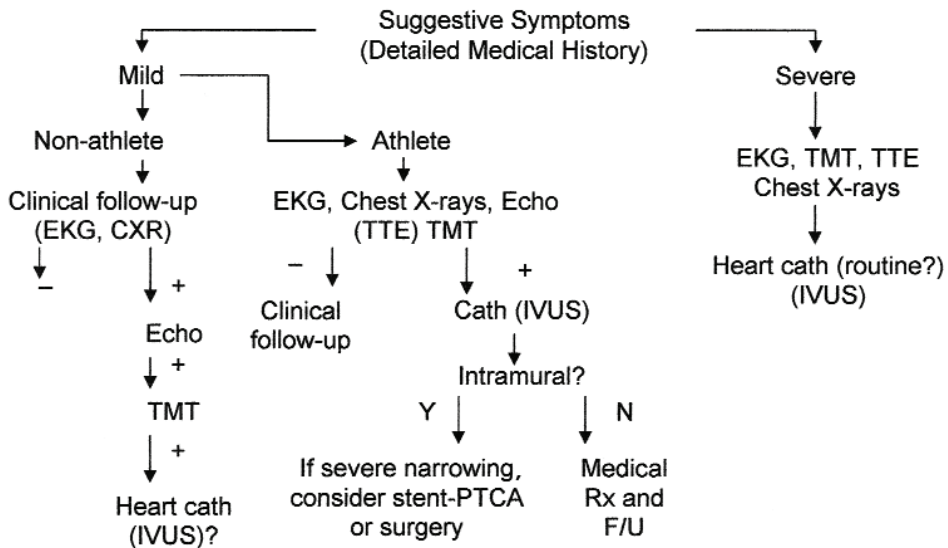


Fig. 3. Proposed diagnostic protocol for adult patients who are at risk for coronary artery anomalies.

- = negative test result; + = positive test result; CXR = chest x-ray; echo = echocardiogram; EKG = electrocardiogram; F/U = follow-up; IVUS = intravascular ultrasound; N = no; PTCA = percutaneous transluminal coronary angioplasty; Rx = treatment; TMT = treadmill test; TTE = transthoracic echocardiogram; Y = yes (Angelini, 2002b)

5.1 Angiography

Coronary angiography is the main diagnostic technique for the precise diagnosis of the CAFs, and its dynamic implication, cannot be ascertained entirely from non-invasive modalities. Cardiac catheterisation and angiography have been used as a method of technique evaluation of CAFs. The catheterization provides the hemodynamic evaluation of the CAFs. Cardiac catheterization remains the modality of choice for defining coronary

artery patterns of structure and flow. Most frequently, intracardiac pressures are normal and shunt flow is modest. Aortography or selective coronary arteriography also provide the most detailed anatomy of the fistula, in particular, the size, the origin, the course, presence of any stenosis and the drainage site (Figure-4). In addition, therapeutic embolization using occlusive coils or devices may be performed via catheterization (Krishnamoorth et al., 2004).

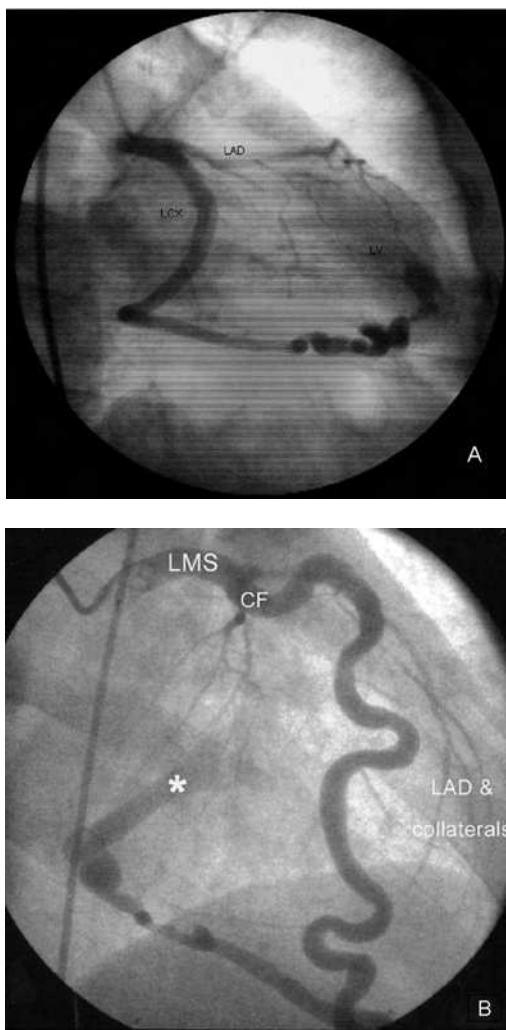


Fig. 4. A. Selective injection shows the fistula from the left circumflex coronary artery to the left ventricle (Dursun et al, 2009).

B. The coronary fistula from the left main coronary artery to the right ventricle, and the coronary steal with rudimentary distal coronary arteries (Marijon et al., 2007).

CF; coronary fistula, LAD; left anterior descending coronary artery, LCX; left circumflex coronary artery, LMS; left main coronary artery, LV; left ventricle.

Coronary angiography still remains the gold standard for imaging the coronary arteries, but sometimes origin and relation of CAFs to adjacent cardiac structures may be ambiguous. It is difficult to measure and observe abnormal tortuous blood vessels with coronary angiography in one section, under such conditions non-invasive methods such as transthoracic and transoesophageal echocardiography, magnetic resonance imaging and contrast enhanced multislice tomography can be used as adjunct to coronary angiography.

5.2 Echocardiography

Echocardiography is helpful in diagnosing most fistulae. Two-dimensional echocardiograms may reveal left atrial and left ventricular enlargement as a consequence of significant shunt flow or decreased regional or global dysfunction as a consequence of myocardial ischemia. A markedly enlarged coronary artery can usually be detected with echocardiography. Echocardiography is not suitable for the evaluation of the functional status of CAFs (Angelini, 2002b).

A coronary artery fistula should be suspected when two dimensional imaging of the main coronary arteries in the parasternal-short axis view shows one coronary artery dilated while the other coronary artery is of normal size. Multiple two-dimensional echocardiographic planes were used in coursing the dilated left coronary artery in the parasternal short-axis plane. But position of the probe, cardiac motion and curvilinear nature of the vessel may limit visualization. High-volume flow may be detected by color-flow imaging at the origin or along the length of the vessel (Figure-5). Carefully seek the site of drainage; often, it is evident as a disturbed flow signal, most frequently within the right ventricle. Recently, some authors have recommended the transesophageal echocardiography for the diagnosis of fistulas because of its better resolution. Transesophageal echocardiogram may be also useful in delineating the origin, course, and drainage of a fistula (Juraschek et al., 2011).

Widespread use of echocardiography coupled with increased awareness and availability of surgical and transcatheter repair of congenital lesions have led to greater potential to perform intervention on CAFs (Valente et al., 2010).

5.3 Multidetector computed tomography

Although echocardiography is often used to detect CAFs, detailed evaluation may be difficult in some patients. Overweight patients present a particular difficulty because of their insufficient acoustic window for echocardiography. In this latter group, Multidetector Computed Tomography (MDCT) may allow excellent adjunctive anatomical delineation, notably of the origin intervening anatomy and distal entry sites of CAFs with high resolution (Lee et al., 2007).

Distal vessel entry depiction by MDCT allows an assessment for the presence or absence of obstruction, which determines the likelihood of a coronary artery steal presentation (Figure-6 and -7). A contrast opacification into the receiving chamber/vessel is useful in confirming the CAFs entry site and patency of the shunt (Dodd et al., 2008)

Cardiac catheterization is the best diagnostic method for identification of CAFs, but it is invasive and has got roughly 1.5% morbidity, 0.15% mortality risk (Lee et al., 2007). Therefore, in patients where echocardiography and angiography are unable to provide adequate anatomical and physiological information, MDCT may provide additional precise details of CAFs, enabling more optimal therapeutic planning (Dodd et al., 2008). Many studies suggest that MDCT has a potential in thoracic imaging, involving not only evaluation of the coronary arteries but other thoracic vessels and coronary-extracoronary communications.

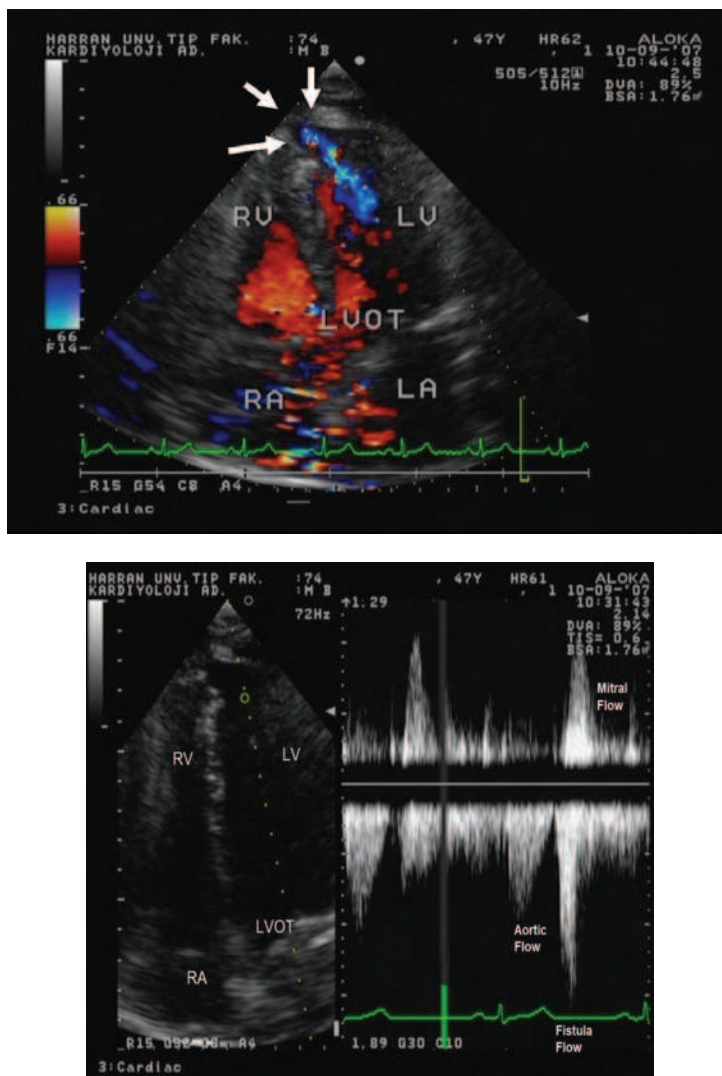


Fig. 5. Colour Doppler and continuo Doppler show fistula form coronary artery to left ventricle. Colour Doppler and continuo Doppler at apical four-chamber view from a transthoracic echocardiogram shows drainage of fistula into the left ventricle apex in diastolic period. IVS; inter-ventricular septum, LV; Left ventricle, LVOT; left ventricular outflow tract, RV; Right ventricle, RA; Right atrium.

The MCDT takes far less time than catheter angiography and requires less skill to carry out. Catheter-related risks, including bleeding at puncture site, haematoma formation, occurrence of arteriovenous fistula etc., are completely eliminated. It also eliminates the more serious complications of catheter angiography like coronary artery dissection, stroke and a small but definite incidence of mortality. The procedure is carried out as an outpatient

procedure, and hence, hospitalization is not needed. Thus, MDCT is considered as a good alternative to echocardiography and coronary angiography. The major limitation of MDCT is radiation exposure, which can be substantially lowered by techniques such as automatic tube current modulation and shielding (Zenooz et al., 2009; Srinivasan, 2008).

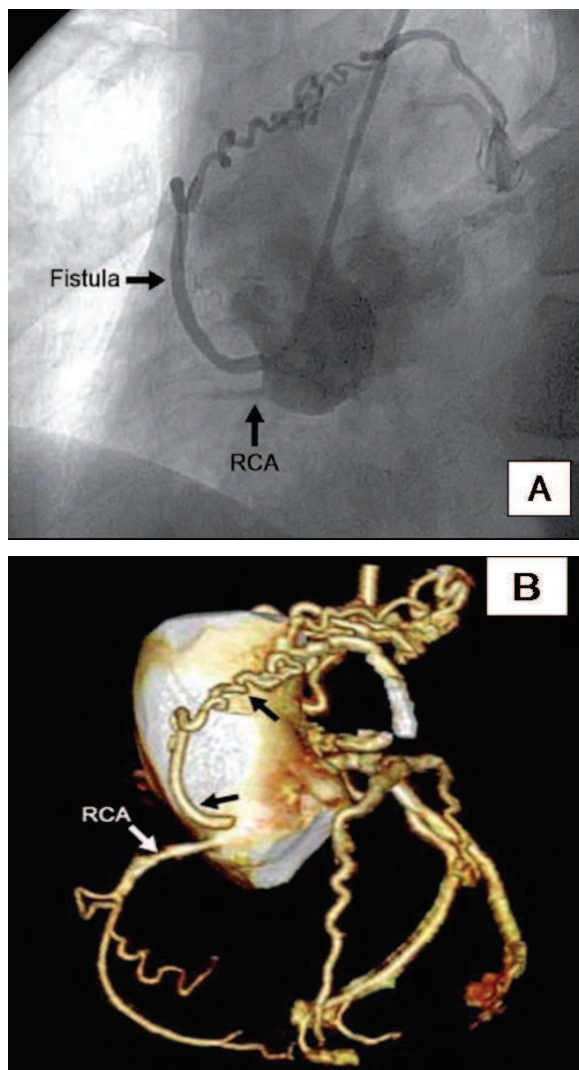


Fig. 6. A: Left anterior oblique view showing the fistula originating from the right sinus of Valsalva and draining into the pulmonary artery.
 B: Computed tomographic coronary angiography. Fistula (black arrows) from the circumflex coronary artery to the pulmonary artery. B: Fistula (black arrows) from the right sinus of Valsalva to the pulmonary artery (Acar et al., 2010)
 CX - left circumflex artery; LAD - left anterior descending artery; RCA - right coronary artery.

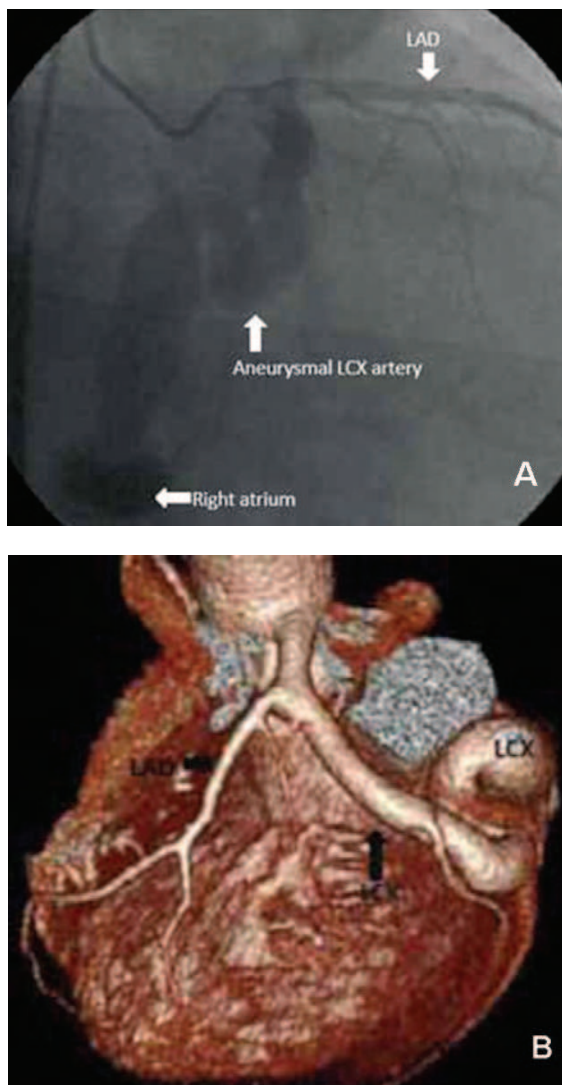


Fig. 7. (A) Coronary angiogram showing a tortuous aneurysmal circumflex artery opacifying the right atrium. (B) Multislice cardiac-gated computed tomography scans showing the left anterior descending artery and a giant circumflex aneurysm with a very tortuous course terminating in a large fistulous connection into the coronary sinus (Pala et al, 2011). LAD: Left anterior descending artery; LCx: Left circumflex artery.

6. Treatment of CAF

The management strategy of patients with CAFs depends on the size of the fistula, presence of symptoms, the anatomy of the fistula, the patient's age and whether the patient has other

associated cardiovascular disorders (Lin et al., 2009). Spontaneous closure is rare but may occur in small fistulae. Spontaneous closure is likely to occur in infants younger than 2 years if the CAFs drains into the right heart, especially the right ventricle (Wong et al., 2000). Small fistulous connections in the asymptomatic patients need to be monitored. The majority of small, asymptomatic CAFs in adults do not need surgical or coronary intervention and medical treatment (Angelini et al, 2002b). In borderline situations, close echocardiographic or angiographic follow-up imaging identifying the enlargement of feeding vessel in asymptomatic patients provide significant information. Larger fistulae progressively enlarge over time, and complications, such as congestive heart failure, myocardial infarction, arrhythmias, infectious endocarditis, aneurysm formation, rupture, and death, are more likely to arise in older patients. These complications may be avoided by early closure of the fistula.

Most symptomatic patients with CAFs are treated by closure with transcatheter or surgical ligation. Transcatheter embolization is advised to all large fistulae but the small fistulous connections. Patients with multiple openings, or significantly aneurysmal dilatation may not be optimal candidates for transcatheter closure. These CAFs are not suitable for the transcatheter approach and preferably are to be addressed surgically.

The preferred method of approach for any patient depends on the anatomy of the fistula, the presence or absence of associated defects and the experience of the interventional cardiologists and surgeons. For the treatment of traumatic CAFs and iatrogenic CAFs, early operative intervention needs to be preferred. Patients which are managed conservatively may develop life-threatening complications. Aneurysmal degeneration, which can lead to mural thrombosis, rupture, or side-branch obstruction, is needed to be treated. For asymptomatic patients, indications for surgery are similar to those diseases which have left to right shunts (e.g., Qp/Qs>1.5 or right ventricular volume overload).

6.1 Transcatheter treatment

Transcatheter closure of CAFs avoids the need for surgical intervention, cardiopulmonary bypass, and median sternotomy. In 1983, Reidy and his colleagues first successfully performed transcatheter closure of CAFs (Reidy et al., 1983). Since then, transcatheter closure of CAFs has been reported with satisfactory results, and this is now considered the treatment of choice for this anomaly.

The main indications for embolization are proximal location of the fistulous vessel, single drain site, extraanatomic termination of the fistula away from the normal coronary arteries, older patient age, and the absence of concomitant cardiac disorders requiring surgical intervention (Zenooz et al., 2009). The main technical limitations of embolization consist of extreme vessel tortuosity, small diameter of the coronary artery and presence of multiple drainage sites or coronary branches at the site of optimal device position.

6.1.1 Devices

The choice of device and technique depends on the anatomic characteristics of the CAFs which include tortuosity, the presence of high flow in the fistula, aneurysmal dilation of the feeding vessel and the point of the intended occlusion. Other important determinants comprise the age and the size of the patient, the catheter size that can be used in the patient, the size of the vessel to be occluded and the tortuosity of the catheter course to reach the intended point of occlusion (Qureshi, 2006).

Various occlusion devices are available for the closure of the CAFs. These are Gianturco and polyester-covered stainless steel coils, detachable balloons, umbrella devices, covered stent polyvinyl alcohol particles, glue and a combination of these instruments (Tacoy et al., 2009; Zhu et al., 2010).

The above mentioned coils are used primarily in smaller CAFs (Figure-8). Their advantages are smaller sheath and catheter delivery sizes, and their cost. Multiple coil placements may be necessary for closing of the severe, tortuous, high-flow fistula. Mechanical detachable coils are used in patients with high-flow velocity coronary fistulae and these play an important role in avoiding coil migration and these are safe in coil embolization (Naber et al., 2004). Electrically detachable coils are particularly safe with minimal risk of migration due to high-flow velocity (Okamoto et al., 2006).

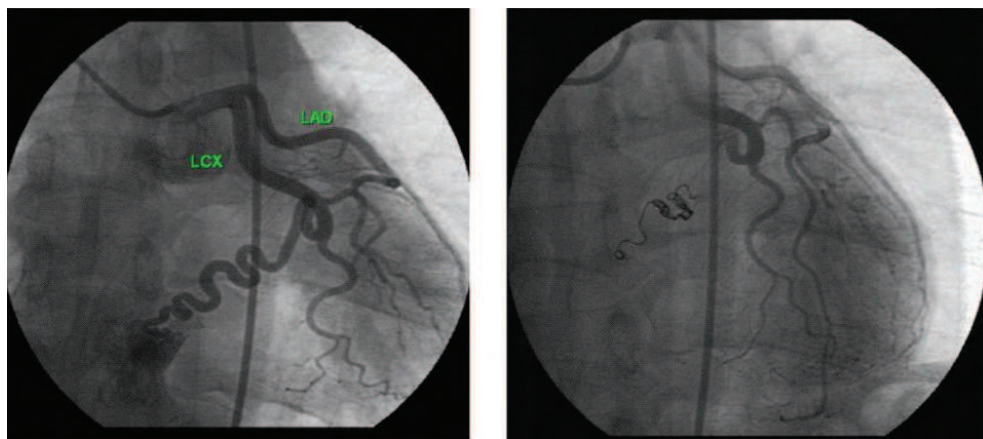


Fig. 8. (A) Selective coronary angiography of the left coronary artery reveals the severe tortuous fistula arising from the distal portion of circumflex artery and draining into the coronary sinus. (B) Complete occlusion following transvenous placement of Guglielmi detachable coils (Tacoy et al., 2009).

The Amplatzer duct occluder is an ideal device for CAFs closure provided the drainage is large enough to allow the passage of the long sheath. This device can be deployed antegradely or retrogradely, and usually use of a single device is enough for complete closure. Another useful device for CAFs closure is the Amplatzer vascular plug. It has wide range of device sizes and can be delivered through a 5–8 French standard coronary guiding catheter. Compared with umbrella devices, the plug affords greater opportunity to close the tortuous fistulae as it can be delivered through a flexible guiding catheter. Detachable coils can also be delivered through a guiding catheter, however, it seems that the plug has advantages over the detachable coil in ease of delivery and incidence of residual flow (Zhu et al, 2010). Double umbrella devices allow more precise positioning and are used in larger fistulae with coronary branches close to the occlusion site (Figure-9) (Armsby et al., 2002).

6.1.2 Technique

The transcatheter approach is a fairly complicated intervention and requires an experienced operator and interventional specialist with expertise in both coronary arteriography and

embolization techniques. A wide range of equipment should be available to deal with all the fistulas, as well as possible complications of the techniques.

Access is usually needed in both the femoral arteries and one femoral vein and sheaths are inserted initially. Afterwards, heparin needs to be administered (100 units/kg). After hemodynamic data is obtained, aortic root angiography and selective coronary angiography are performed in order to demonstrate the anatomy of the fistula, its drainage site, and in order to identify distal coronary branches (Zhu et al, 2010). Coronary angiograms are analyzed using different systems and the diameter of the fistula is measured. Approach to closure is determined by the number and the location of drainage sites, the location of the proximal coronary branches, and the ability to cannulate the distal part of the fistula. Device deployment is performed either antegrade (via the femoral vein) or retrograde (via the femoral artery). Antegrade deployment avoids potential damage to the femoral artery, and allows the use of larger catheters and affords a straighter catheter course. Retrograde deployment is to be attempted if there is a difficulty in establishing an arteriovenous wire loop through the fistula.

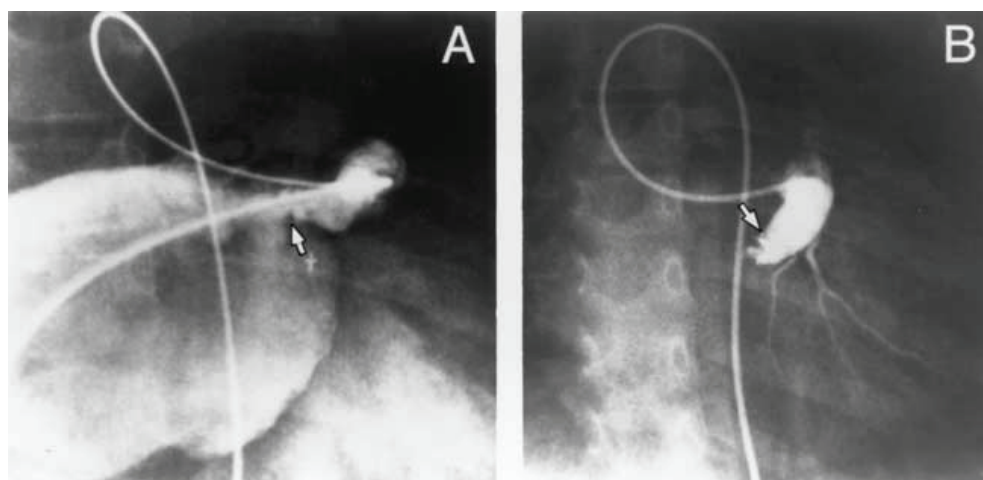


Fig. 9. Coronary artery fistula from left coronary artery to left atrium. (A) Arteriovenous wire loop enabling passage of venous catheter across the atrial septum into the fistula drainage site (**arrow**). (B) Angiogram following transvenous deployment of a 12-mm Rashkind device (**arrow**), showing coronary artery fistula occlusion and coronary artery side branches that were not evident in angiograms performed without balloon occlusion (Armsby et al., 2002).

A Berman or Swan-Ganz type of balloon catheter is passed and the balloon inflated with contrast in order to temporarily occlude the vessel. The purpose of this is to test for ischaemia. In the absence of ischaemic changes, the site, where the balloon has been kept inflated or its beyond, is an acceptable site for occlusion of the fistula (Qureshi, 2006). Afterwards, a guiding coronary catheter is positioned in the artery. With the standard guidewire advanced into the fistula, the guiding catheter may be passed to the point of intended occlusion and then, either Gianturco or Cook-PDA coils can be deployed through this catheter to achieve occlusion. The coil should be up to 30% larger than the vessel to be

occluded at the point of occlusion to avoid inadvertent embolisation of the coil. Once the first coil is in correct position, different sizes of coils can be deployed subsequently to form a tight nest (Qureshi, 2006).

Amplatzer occluder type of devices is suitable to the fistula which can be reached via the right side of the heart (Zhou et al, 2006). The fistula vessel should be large, have easy and straight access from the right heart, if needed with the help of an arteriovenous guidewire circuit, and allow a guiding sheath to be passed into the vessel for the occlusion device. In these, either femoral venous or internal jugular venous access is used. Detachable balloons are rarely used nowadays. They can be floated out with the arterial flow and achieve immediate occlusion and then the balloon is detached. They are complex to use and require large introducer catheters (6–8 Fr). Early deflation and premature detachment of these balloons incur further problems, which have made most operators avoid of using them (Qureshi, 2006). Selective coronary angiography in multiple projections is essential before, during and after coil implantation (Olgunturk et al., 2006).

The advantages of the transcatheter closure of CAFs are: shorter hospital stays, less myocardial damage, less invasion, and fewer complications compared with conventional open surgery possible for the patients. Successful occlusion of the CAFs at catheterization was reported in >83-95% of patients. In the remaining patients, they are to be managed conservatively or with surgery (Nakayama et al., 2010).

The procedural complications include transient ischemic changes, unretrieved device embolization, fistula dissection, transient T-wave changes, transient bundle branch block, myocardial infarction, and transient atrial arrhythmia and death. All these complications are rare, apart from inadvertent coil migration, which may occur as a result of high flow in the large fistulas or with undersized coils. Even if the coils do migrate, they can be retrieved with snares (Qureshi, 2006). Catheter-based closure of CAFs has a better clinical outcome and the operative mortality is 1.4% 0% in current transcatheter closure (Olivotti et al, 2008; Armsby et al., 2002; Qureshi, 2006). Intimal dissection of the coronary artery, thrombosis or pericardial effusion may also occur. However, morbidity and mortality rates generally are considered to be low. The pericardial effusion may be associated with increased hydrostatic pressure of pericardial vessels, pericardial inflammation or it is similar to the postpericardiotomy syndrome after open heart surgery. After pericardial tap and anti-inflammatory agents with aspirin, the effusion disappears gradually (Fue et al., 1997).

In order to reduce complications during the procedure, several procedural and clinical details mandate special attention. First, precise identification of the distal coronary branches is difficult before the fistula is closed due to fast blood flow through the fistula vessel. Thus, the optimal site for device placement is the fistula drainage. However, even after the device is placed at the fistula drainage, it does not mean that a small area of myocardial infarction would not occur. Therefore, it is necessary to monitor ST-T changes for 24 to 48 hours after CAFs closure. Secondly, the sizing of the device is difficult due to variation of the fistula morphology. Undersizing of the device may lead to complications such as residual shunt and device migration, especially when the patient is a child (Zhu et al., 2010).

6.2 Surgical treatment

The first surgical treatment of CAFs was performed by Bjork and Crafoord in 1947 (Ata et al. 2009). The indications for surgery include a large CAF characterized by high fistula flow, multiple communications, very tortuous pathways, multiple terminations, significant aneurysmal formation, simultaneous distal bypass, or presence of large vascular branches

that can be accidentally embolized (Zenooz et al, 2009). If the placement of the occlusion device is considered to be difficult due to aneurysmatic change and tortuous vessel, or if it occludes a coronary artery branch, operation is needed. In addition, it has been reported that surgery should be carried out earlier for a low surgical risk patient, considering future CAF-related problems, even if the patient does not have symptoms (McMahon et al., 2001).

6.2.1 Techniques

Surgical repair usually is approached via a median sternotomy and cardiopulmonary bypass. Identify the feeding vessel and delineate its course and site of insertion. Identify the site of presumed fistulous drainage prior to institution of the cardiopulmonary bypass. A typical procedure includes opening the chamber into which the fistula drains, identifying the fistula, and then closes it either by external ligation or by internal patching of the orifices (Liberthson et al., 1979).

If the fistula enters the ventricle or if the feeding vessel is large, the coronary artery is opened, and the opening to the fistula is closed with a running suture. The arteriotomy is closed. Large aneurysms may require excision. Rarely, when the fistula is an end artery, it may be ligated with or without bypass.

Some authors have reported successful surgical occlusion of CAFs on beating heart without cardiopulmonary bypass. Ligation of the CAFs may be performed on the outside of the beating heart when it is easily accessible. But some recommend exploration of the pulmonary artery with the use of cardiopulmonary bypass especially in patients who have CAFs in combination with a vascular malformation (Ata et al., 2009).

Complete occlusion of the fistula may be achieved in >95% of cases after surgery. Complications of surgery include myocardial ischemia and/or infarction (reported in 3% of patients) and recurrence of the fistula (4% of patients). The reason for the recurrence includes the fact that there may be multiple fistulas present which are difficult to deal with by surgery.

6.3 Follow-up after transcatheter and surgical closure

The outcome of transcatheter occlusion is as good as that of surgical correction. Patients which are closed by using transcatheter techniques need to be closely followed up for complications such as residual shunts, new fistula formation, formation of thrombus, coronary aneurysma and coronary artery stenosis. Clinical experiences show that the short-, middle- and long-term outcome of transcatheter closure of CAFs has been satisfactory. Residual or recurrent shunts after transcatheter closure have been reported in 10–20% of patients and these may require further procedures to achieve complete occlusion (Liang et al, 2010; Zhu et al, 2010). A study shows that an incidence of major complications which occurs late after closure of CAFs with transcatheter and surgical interventions is 15% (Valente et al, 2010). Mortality related to surgical closure or transcatheter closure of isolated CAFs is low (<1%) (Qureshi, 2006; Urrutia-S et al., 1983).

All patients should be controlled on the following day after a chest radiograph, electrocardiogram, and Doppler echocardiography study and the physical status, electrocardiogram, and Doppler echocardiography need to be followed regularly every 3–6 months during the first year and annually thereafter. Close long-term follow-up with coronary angiography and myocardial scintigraphy after transcatheter or surgical closure of CAFs is very important in order to be able to recognize possible recanalization and

complications (Luo et al., 2006; Angelini, 2002b). The late complications are presence of myocardial infarction, coronary thrombosis, ventricular tachycardia, or heart failure. The etiology of the late complications is associated with angiographic and clinical features of CAFs. The drainage of the CAFs into the coronary sinus may lead to late complications of CAFs. Clinical predictors associated with adverse outcomes include older age, tobacco use, diabetes, systemic hypertension, and hyperlipidemia (Valente et al., 2010).

6.4. Medical treatment

Medical treatment is the most common choice for the mild symptoms. (Sam et al., 2006). Patients who are conservatorily treated should be followed up closely for appearance of symptoms. Most of the adult patients who are asymptomatic remain free of symptoms for long periods (Gowda et al., 2006).

Medical management of patients with angina due to CAFs is similar to management of angina in the absence of CAFs. Beta-blockers or calcium channel blockers are usually recommended in angina related diseases. Nitrates must be used cautiously, as they can cause dilation of the fistula and they decrease the end-diastolic pressure of the recipient ventricle, both of which can lead to increased shunt flow and coronary "steal".

Medical management after complete CAFs occlusion remains controversial in the literature. Most studies do not suggest antiaggregan and anticoagulation treatment. However, in view of the persistence of the fistulous cul-de-sac, coronary artery dilation, and potential for thrombus formation (which may lead to myocardial infarction), aspirin is indicated. For severe coronary artery dilatation (>10 mm), some authors advocate anticoagulation with warfarin. Patients treated surgically and with transcatheter techniques should receive maintenance doses of antiplatelet agents and, perhaps, an anticoagulant regime for the first 6 months postoperatively, until the operative surface has endothelialized.

CAFs that drain into the coronary sinus are particularly at high risk of long-term morbidities after CAFs closure, and strategies, including long-term anticoagulation, should be considered in these patients (Valente et al., 2008).

Patients remain at risk for development of endocarditis until the flow is stopped and should receive antibiotic prophylaxis for any dental, gastrointestinal tract, and urologic procedures. Therefore, prophylaxis for bacterial endocarditis is recommended in all CAF patients and in patients after complete fistula occlusion for at least 1 year.

Since advanced age and modifiable coronary risk factors, such as hyperlipidemia, systemic hypertension, diabetes, and tobacco use, are associated with increased risk of CAFs complications, control of these factors is needed.

7. Conclusion

With increased experience and improved devices and techniques, transcatheter closer techniques of CAFs are emerging as a successful therapeutic strategy. The safe and effective results of both surgical closure and transcatheter closer support the current convention of elective closure of clinically significant CAFs in childhood. The preferred method of approach for any individual will depend on the anatomy of the fistula, the presence or the absence of the associated defects and the experience of the interventional cardiologists and surgeons.

Coronary artery fistulas can be safely and effectively closed using transcatheter techniques. Anatomical variations and different sizes of coronary artery fistulas necessitate availability of different sizes and types of devices at the time of catheterization for successful closure.

Recent results of both transcatheter and surgical approaches indicate a good prognosis. Life expectancy is considered normal. Patients need to be closely followed up for complication such as residual shunts, new fistula formation and coronary artery stenosis.

8. Acknowledgment

I am particularly grateful to Assoc. Prof. Recep Cigdem, Paolo Angelini, MD, Salah Said, MD, Gulden Tacoy, MD, and others who gave permission to use their materials.

9. References

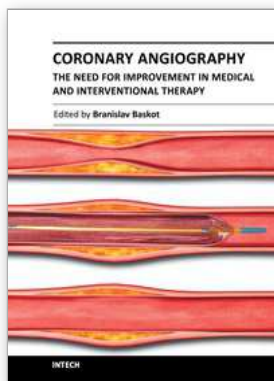
- Acar, G. et al. (2010). Bilateral coronary artery fistula originating from the right sinus of Valsalva and left circumflex artery, and draining into the pulmonary artery. *Hellenic J Cardiol*. Vol.51, No.5, pp.458-459, ISSN: 1109-9666
- Angelini, P.; Villason, S.; Chan, A.V. & Diez, J.G. (1999). Normal and anomalous coronary arteries in humans. In: Angelini P, ed. *Coronary Artery Anomalies*. pp. 27-150. Lippincott Williams & Wilkins ISBN 978-0781710183, Philadelphia.
- Angelini, P. et al. (2002a). Coronary anomalies: incidence, pathophysiology, and clinical relevance. *Circulation*, Vol. 105, No.20, pp.2449-2454, ISSN: 0009-7322
- Angelini, P. (2002b). Coronary Artery Anomalies—Current Clinical Issues Definitions, Classification, Incidence, Clinical Relevance, and Treatment Guidelines. *Tex Heart Inst J*, Vol.29, No.4, pp.271-278, ISSN:0730-2347
- Angelini, P. (2007). Coronary artery anomalies: an entity in search of an identity. *Circulation*, Vol.115, No.10, pp.1296-1305, ISSN: 0009-7322
- Armsby, L.R. et al. (2002). Management of coronary artery fistulae. Patient selection and results of transcatheter closure. *J Am Coll Cardiol*. Vol.39, No.6, pp.1026-1032, ISSN: 0735-1097
- Ata, Y. et al. (2009). Coronary arteriovenous fistulas in the adults: natural history and management strategies. *J Cardiothorac Surg*. Vol.6, no.4, pp.62, ISSN: 1749-8090
- Bhandari, S. et al. (1993). Coronary artery fistulae without audible murmur in adults. *Cardiovasc Intervent Radiol*, Vol:16, No.4, pp.219-223, ISSN: 7415-5101
- Cebi, N. et al. (2008). Heuer H. Congenital coronary artery fistulas in adults: concomitant pathologies and treatment. *Int J Cardiovasc Imaging*. Vol.24, No.4, pp.349-355, ISSN: 1569-5794
- Chiu C.Z. et al. (2008). Angiographic and Clinical Manifestations of Coronary Fistulas in Chinese People 15-Year Experience. *Circ J*, Vol. 72, No.8, pp.1242-1248, ISSN: 1346-9843
- Cheung, D.L., et al. (2001). Coronary artery fistulas: long-term results of surgical correction. *Ann Thorac Surg*, Vol.71, No.1, pp.190-195, ISSN; 1552-6259
- Davis, J.T, et al. (1994). Coronary artery fistula in the pediatric age group: a 19-year institutional experience. *Ann Thorac Surg*, Vol.58, No.3, pp.760-763, ISSN; 1552-6259
- Dodd, J.D., et al. (2008). Evaluation of efficacy of 64-slice multidetector computed tomography in patients with congenital coronary fistulas. *J Comput Assist Tomogr*. Vol.32, No.2, pp.265-270, ISSN: 0363-8715

- Dursun, A, et al. (2009). Diagnosis of the left circumflex coronary artery fistula drainage into the left ventricle by echocardiographic color Doppler flow imaging. *Int J Cardiol*, Vol.134, No.3, pp. e85–e86, ISSN: 0167-5273
- Fahey, J.T. & Asnes, J. (2008). Coronary recanalization due to presumed thrombosis following surgical ligation of a large right coronary artery to right ventricle fistula. *Congenit Heart Dis*, Vol.3, No.4, pp.295-298, ISSN: 1747-0803
- Friedman, A.H. et al. (2007). Identification, imaging, functional assessment and management of congenital coronary arterial abnormalities in children. *Cardiol Young*. Vol.17, No.Suppl. 2, pp.56–67, ISSN 1047-9511
- Fu, Y.C. et al (1997). Transcatheter embolization of coronary artery fistula: a case report. *Zhonghua Yi Xue Za Zhi (Taipei)*, Vol.59, No.3, pp.194-198, ISSN: 0578-1337
- Gillebert, C. Et al. (1986). Coronary artery fistulas in an adult population. *Eur Heart J*, Vol.7, No.5, pp.437-443, ISSN: 1522-9645
- Gowda, R.M. et al. (2006). Coronary artery fistulas: clinical and therapeutic considerations, *Int J Cardiol*. Vol.107, No.1, pp.7–10, ISSN: 0167-5273
- Gupta-Malhotra, M. (Jan 12, 2010). Coronary artery fistula. In: *Pediatrics Cardiac Disease and Critical Care Medicine*, <http://emedicine.medscape.com/article/895749-overview?src=emailthis>
- Holzer, R. et al. (2004). Review of an institutional experience of coronary arterial fistulas in childhood set in context of review of the literature. *Cardiol Young*, Vol.14, No.4, pp.380-385, ISSN: 1047-9511
- Hobbs, R.E. et al. (1982). Coronary artery fistulae: a 10-year review. *Cleve Clin Q*, Vol. 49, No.4, pp.191-197, ISSN: 0009-8787
- Hsieh, K.S. et al. (2002). Coronary artery fistulas in neonates, infants, and children: Clinical findings and outcome. *Pediatr Cardiol*, Vol.23, No.4, pp.415-419, ISSN: 1432-1971
- Juraschek, S.P. et al. (2011). Heart failure with transient left bundle branch block in the setting of left coronary fistula. *Cardiol Res Pract*. Vol. 2011, No.786287, pp.1-3, ISSN: 2090-0597
- Iglesias, J.F. et al. (2010). Transcatheter coil embolization of multiple bilateral congenital coronary artery fistulae. *J Invasive Cardiol*, Vol.22, No.3, pp.142-145, ISSN: 1042-3931
- Kardos, A. et al. (1997). Epidemiology of congenital coronary artery anomalies: a coronary arteriography study on a central European population. *Cathet Cardiovasc Diagn*, Vol.42, No.3, pp.270-275, ISSN: 0098-6569
- Kamiya, H. et al. (2002). Surgical treatment of congenital coronary artery fistulas: 27 years' experience and a review of the literature. *J Card Surg*, Vol.17, No.2, pp.173-177, ISSN: 0886-0440
- Kose, S. & Heper, G. (2005). Increased myocardial ischemia during nitrate therapy: caused by multiple coronary artery-left ventricle fistulae? *Tex Heart Inst J*, Vol.32, No.1, pp.50-52, ISSN: 0730-2347
- Krishnamoorthy, K.M., et al. (2004). Transesophageal echocardiography for the diagnosis of coronary arteriovenous fistula. *Int J Cardiol*, Vol.96, No.2, pp. 281– 283, ISSN: 0167-5273

- Wong, K. et al. (2000). Coronary arterial fistula in childhood. *Cardiol Young*, Vol.10, No.1, pp.15– 20, ISSN: 1467-1107
- Lee, C.M. et al. (2007). Identification of a Coronary-to-Bronchial-Artery Communication With MDCT Shows the Diagnostic Potential of This New Technology Case Report and Review. *J Thorac Imaging*, Vol.22, No.3, pp.274–276, ISSN: 0883-5993
- Levin, D.C. et al. (1978). Hemodynamically significant primary anomalies of the coronary arteries: angiographic aspects. *Circulation*, Vol.58, No.1, pp.25 – 34, ISSN: 0009-7322
- Liberthson, R.R. et al. (1979). Congenital coronary arteriovenous fistula. Report of 13 patients, review of the literature and delineation of management. *Circulation*. Vol.59, No.5, pp.849-854, ISSN: 0009-7322
- Lin, C.T. & Lin, T. K. (2009). The Current Status of Coronary Artery Fistula. *J Intern Med Taiwan*, Vol.20, No.6, pp.484-489, ISSN: 1016-7390
- Luo, L. et al. (2006). Coronary arterial fistulas. *Am J Med Sci*, Vol.332, No.2, pp.79–84, ISSN: 1538-2990
- Marijon, E. et al. (2007). Coronary fistula as an unusual cause of angina in a middle-aged man. *Pediatr Cardiol*, Vol.209, No.5, pp.993-994. ISSN: 0172-0643
- McMahon, C.J. et al. (2001). Coronary artery fistula: management and intermediate-term outcome after transcatheter coil occlusion. *Tex Heart Inst J*, Vol.28, No.1, pp.21–25, ISSN: 0730-2347
- McNamara, J.J. & Gross, R.E. (1969). Congenital coronary artery fistula. *Surgery*; Vol.65, No.1, pp.59-69, ISSN: 0039-6060.
- Naber, C.K. et al. (2004). Percutaneous coil embolization of a large, congenital coronary–pulmonary fistula using hydrophiliccoated detachable platinum coils. *Herz*, Vol.29, No.2, pp.218-219, ISSN: 1615-6692
- Nakayama, Y. et al. (2010). Surgical repair of complicated coronary arteriovenous fistula and coronary artery aneurysm in an elderly patient after 26 years of conservative therapy. *Heart Vessels*, Vol.26, No.1 pp. 111-116, ISSN: 1615-2573
- Nawa, S. Et al. (1996). Clinical and angiographic analysis of congenital coronary artery fistulae in adulthood. Is there any new trend? *Jpn Heart J*, Vol.37, No.1, pp.95-104, ISSN: 0021-4868
- Okamoto, M. et al. (2006). Successful coil embolization with assistance of coronary stenting in an adult patient with a huge coronary arterial–right atrial fistula. *Intern Med*, Vol.45, No.14, pp.865-870. ISSN: 1445-5994
- Olgunturk, R. et al. (2006). Transcatheter closure of a rare form of coronary arteriovenous fistula (circumflex artery to coronary sinus). *Int J Cardiol*, Vol.113, No.2, pp.261–263, ISSN: 0167-5273
- Olivotti, L. et al. (2008). Percutaneous closure of a giant coronary arteriovenous fistula using free embolization coils in an adult patient. *J Cardiovasc Med (Hagerstown)*, Vol.9, No.7, pp.733-736. ISSN: 1558-2035
- Pala, S. et al. (2011). Noninvasive evaluation of a giant circumflex coronary artery aneurysm fistulized into the coronary sinus by multislice computed tomography. *Arch Turk Soc Cardiol*, Vol.39, No.1, pp. 39:88

- Qureshi, S.A. (2006), Coronary arterial fistulas. *Orphanet J Rare Dis*, Vol.1, No.51, pp.1-6, ISSN: 1750-1172
- Qureshi, S.A. et al. (1996). Use of interlocking detachable coils in embolization of coronary arteriovenous fistulas. *Am J Cardiol*, Vol.78, No.1, pp:110-113, ISSN: 1879-1913
- Gowda, R.M. et al. (2006). Coronary artery fistulas: Clinical and therapeutic considerations. *Int J Cardiol*, Vol.107, No.1, pp.7-10, ISSN: 0167-5273
- Reidy, J.F. et al. (1983). Transcatheter occlusion of coronary to bronchial anastomosis by deta balloon combined with coronary angioplasty at same procedure. *Br Heart J*, Vol.49, No.3, pp.284-287, ISSN: 0007-0769
- Said, S.A.M. & Wert, T. (2006). Dutc survey of congenital coronary artery fistulas in adults: Coronary artery-left ventricular multiple micro-fistulas multi-center observational survey in the Netherlands. *Int J Cardiol*, Vol.110, No.1, pp.33-39, ISSN: 0167-5273
- Said, S.A.M. (2010). Congenital solitary coronary artery fistulas characterized by their drainage sites. *World J Cardiol*. Vol.2, No.1, pp. 6-12, ISSN: 1949-8462
- Shewood, M.C. et al. (1999). Prognostic significance of clinically silent coronary artery fistulas. *Am J Cardiol*, Vol.83, No.3, pp.407-411, ISSN: 0002-9149
- Srinivasan, K.G. (2008). Congenital coronary artery anomalies: diagnosis with 64 slice multidetector row computed tomography coronary angiography: a single-centre study. *J Med Imaging Radiat Oncol*. Vol.52, No.2, pp.148-154, ISSN: 1754-9485
- Tacoy, G. et al. (2009). Congenitally severe tortuous circumflex artery fistula draining into the coronary sinus: Transcatheter closure with Guglielmi detachable coils via different delivery system. *J Cardio*, Vol.54, No.2, pp.317-321, ISSN: 1876-4738
- Urrutia-S, C.O. et al. (1983). Surgical management of 56 patients with congenital coronary artery fistulas. *Ann Thorac Surg*, Vol.35, No.3, pp.300-307, ISSN: 1552-6259
- XU Liang, X.U. et al. (2010). Transcatheter closure of coronary artery fistula in children. *Chin Med J*, Vol.123, No.7, pp.822-826, ISSN: 0366-6999
- Valente, A.M. et al. (2010). Predictors of Long-Term Adverse Outcomes in Patients With Congenital Coronary Artery Fistulae. *Circ Cardiovasc Interv*. No.3, No.2, pp.134-139, ISSN: 1941-7632
- Vavuranakis, M. et al. (1995). Coronary artery fistulas in adults: incidence, angiographic characteristics, natural history. *Cathet Cardiovasc Diag*, Vol.35, No.2, pp.116-120, ISSN: 0098-6569
- Yamanaka, O. Hobbs, R.E. (1990). Coronary artery anomalies in 126,595 patients undergoing coronary arteriography. *Cathet Curdiovasc Diugn*, Vol.21, No.1, pp.28-40, ISSN: 0098-6569
- Yildiz, A., et al. (2010). Prevalence of coronary artery anomalies in 12,457 adult patients who underwent coronary angiography. *Clin Cardiol*, Vol.33, No.12, pp.60-64, ISSN: 0160-9289
- Zenooz, N.A. et al. (2009). Coronary Artery Fistulas: CT Findings. *RadioGraphics*, Vol.29, No.3, pp.781-789, ISSN: 1527-1323
- Zhou, T. et al. (2006). Transcatheter closure of a giant coronary artery fistula with patent duct occluder. *Chin Med J (Engl)*, Vol.119, No.9, pp.779-781, ISSN: 0366-6999

Zhu, X.Y. et al. (2010). Transcatheter Closure of Congenital Coronary Artery Fistulae: Immediate and Long-Term Follow-Up Results. *Clin Cardiol*, Vol.32, No.9, pp.506–512, ISSN: 1932-8737



Coronary Angiography - The Need for Improvement in Medical and Interventional Therapy

Edited by Prof. Baskot Branislav

ISBN 978-953-307-641-6

Hard cover, 206 pages

Publisher InTech

Published online 06, September, 2011

Published in print edition September, 2011

In this book we examined a periprocedural complication of coronary angiography, and coronary intervention. That includes related to cardiac catheterization and diagnostic coronary angiography, and those that occur as a consequence of the specific equipment. However, improvements in devices, the use of stents, and aggressive antiplatelet therapy have significantly reduced the incident of major periprocedural complications. This book giving knowledge and experiences many of interventional cardiologists from all over the world, and provide possibility to recognize new approach in this domain. Book gives lecture on how we image and how we decide on what to treat, how to treat it, and then results of that treatment. They offer many answers to what we have today and what we will have tomorrow.

How to reference

In order to correctly reference this scholarly work, feel free to copy and paste the following:

Recep Demirbag (2011). Coronary Arteriovenous Fistula, *Coronary Angiography - The Need for Improvement in Medical and Interventional Therapy*, Prof. Baskot Branislav (Ed.), ISBN: 978-953-307-641-6, InTech, Available from: <http://www.intechopen.com/books/coronary-angiography-the-need-for-improvement-in-medical-and-interventional-therapy/coronary-arteriovenous-fistula1>

INTECH
open science | open minds

InTech Europe

University Campus STeP Ri
Slavka Krautzeka 83/A
51000 Rijeka, Croatia
Phone: +385 (51) 770 447
Fax: +385 (51) 686 166
www.intechopen.com

InTech China

Unit 405, Office Block, Hotel Equatorial Shanghai
No.65, Yan An Road (West), Shanghai, 200040, China
中国上海市延安西路65号上海国际贵都大饭店办公楼405单元
Phone: +86-21-62489820
Fax: +86-21-62489821

© 2011 The Author(s). Licensee IntechOpen. This chapter is distributed under the terms of the [Creative Commons Attribution-NonCommercial-ShareAlike-3.0 License](#), which permits use, distribution and reproduction for non-commercial purposes, provided the original is properly cited and derivative works building on this content are distributed under the same license.