

# We are IntechOpen, the world's leading publisher of Open Access books Built by scientists, for scientists

6,900

Open access books available

186,000

International authors and editors

200M

Downloads

Our authors are among the

154

Countries delivered to

TOP 1%

most cited scientists

12.2%

Contributors from top 500 universities



WEB OF SCIENCE™

Selection of our books indexed in the Book Citation Index  
in Web of Science™ Core Collection (BKCI)

Interested in publishing with us?  
Contact [book.department@intechopen.com](mailto:book.department@intechopen.com)

Numbers displayed above are based on latest data collected.  
For more information visit [www.intechopen.com](http://www.intechopen.com)



---

# Benign Tumors of Temporomandibular Joint

---

Mehmet Emre Yurttutan,  
Ayşegül Tüzüner Öncül and Hakan Alpay Karasu

Additional information is available at the end of the chapter

<http://dx.doi.org/10.5772/intechopen.72302>

---

## Abstract

The temporomandibular joint (TMJ) forms a complex functional system with teeth, bones, connected muscles and ligaments. Any discomfort in any of these structures directly affects the joint. The complaints are mostly pain, malocclusion and swelling. Temporomandibular joint tumors are very uncommon but show symptoms similar to intra-articular disorders that make up most of these disorders. The most common TMJ-specific benign tumors are classified after a brief literature review. Our classification also includes the osteoma of the TMJ, other than World Health Organization's (WHO) classification of soft tissue and bone tumors. This benign tumor was also included in the classification because of its higher frequency in the literature. The treatment of these neoplasms may be conservative or radical surgery.

**Keywords:** cartilage tumors, temporomandibular joint tumors, cartilage tumors, osteogenic tumors, osteochondroma, chondroma, chondroblastoma, pigmented villonodular synovitis, synovial chondromatosis, osteoma, juxta-articular myxoma

---

## 1. Introduction

Primary neoplasms of the bones are rare, amounting to only 0.2% of the overall human tumor. Primary neoplasms originating in the temporomandibular joint (TMJ) are extremely rare. Their clinical manifestations are usually related to the temporomandibular dysfunction (TMD) and include pre-auricular swelling, pain, trismus, deviation of mandibular movement and malocclusion. Such symptoms should not be neglected and advanced imaging methods should be used with the thought that it may be neoplasia. Also the clinical symptoms and radiological appearance of many tumors are similar. Therefore, the differential diagnosis must be made carefully [1].

TMJ-specific benign tumors		
Bone tumors	1. Cartilage tumors	Osteochondroma
		Chondroma
		Chondroblastoma
		Synovial chondromatosis
	2. Osteogenic tumors	Osteoma
		Osteoid osteoma
	Osteoblastoma	
	3. Giant cell tumors	Giant cell tumor
	4. Vascular tumors	Hemangioma
	5. Lipogenic tumors	Lipoma
	6. Bone-related odontogenic tumors	Ossifying fibroma
Soft tissue tumors	1. Fibrohistiocytic tumors	Pigmented villonodular synovitis
	2. Tumors of uncertain differentiation	Juxta-articular myxoma

**Table 1.** Benign temporomandibular joint tumors.

Temporomandibular joint consists of bone structures and soft tissues such as temporal bone, mandibular condyle, articular disc, articular capsule and ligaments. The tumors that will be formed in this region will also develop from bone and soft tissue origin.

The most common TMJ-specific benign tumors are classified after a brief literature review. Our classification also includes the osteoma of the TMJ, other than World Health Organization's (WHO) classification of soft tissue and bone tumors [2]. This benign tumor also included in the classification because of its higher frequency in the literature (**Table 1**).

**Table 1** represents benign TMJ tumors. These tumors are classified under two section.

## 2. Cartilage tumors

Tumors producing a chondroid matrix will be described in this group. Many benign cartilage tumors are asymptomatic. Radiographic findings are critical to diagnosis of cartilaginous tumors.

### 2.1. Osteochondroma

Osteochondroma is a common slow-growing tumor that cartilage-capped bony projection arising from the outside surface of bone containing a marrow cavity that is continuous with that of the underlying bone appears close to the growth plate at the end of long bones [3]. In very few cases of temporomandibular joint, osteochondroma have been reported [4]. Osteochondroma is usually located at the medial surface of mandibular condyle [5]. The average age of occurrence is 16.5 and males are affected 3 times as often as females [6].

The most common clinical symptoms are malocclusion, with unilateral posterior open bite on the affected side and a crossbite on the contralateral side, and progressive facial asymmetry, limited and often painful mandibular movements and clicking [7, 8].

The reason for osteochondroma is uncertain, but traumatic, developmental, neoplastic and reparative occasions have been considered as possible factors [6, 9]. The most commonly accepted view is a metaplastic change of the periosteum and/or the osteochondral layer in the condyle, leading to the production of cartilage, which subsequently ossifies [8]. Complications of OC are osseous deformity, fracture, vascular compromise, bursa generation and malignant transformation [6]. CT can provide excellent anatomy of the lesion and demonstrate calcification in the cartilage cap whereas MRI confirms the diagnosis by demonstrating the cartilaginous cap [4].

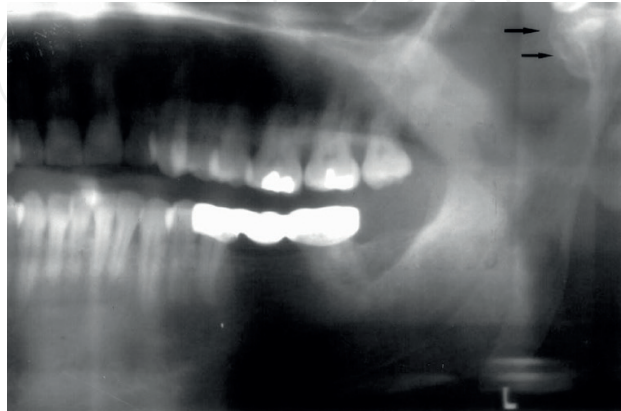
The differential diagnosis of benign neoplasms known to involve the mandibular condyle includes osteoma, osteblastoma, chondroma, chondroblastoma and osteochondroma. Osteomas are benign tumors that consist primarily of mature, compact, cancellous bone [9]. Chondromas consist of well-defined lobules of mature hyaline cartilage that may contain areas of calcification. Chondroblastomas consist of a proliferation of immature cartilage cells, with focal production of a variably differentiated cartilaginous matrix [10]. Osteochondroma is presumed to arise from herniation of cartilage through the epiphyseal plate in the formative years. Radiographically, the lesion is easily differentiated from chondroma because it is most frequently an extraneous appendage, rather than a rarefaction within the normal jaw confines, and is more radiopaque, which represents its true ossification [11].

Osteochondromas can be treated by total condylectomy or local resection of the lesion and condylar replacement if the tumor involves the mandibular condyle. On the other hand, if the tumor affects limited part of the condylar surface, preservation of the remaining part of the condyle and reshaping can be done [6, 12].

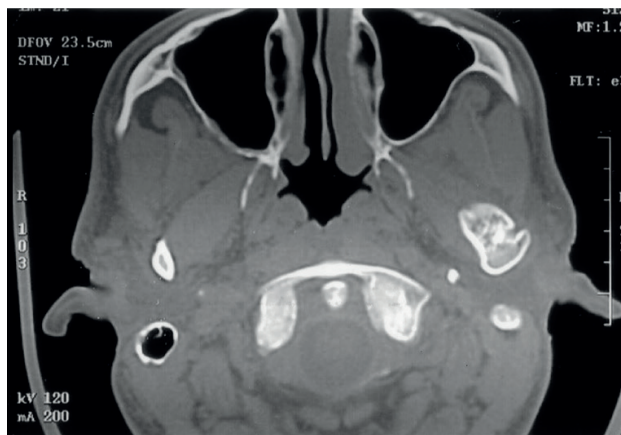
In the case of an osteochondroma of the author of this chapter, Dr Karasu, the tumor was removed under general anesthesia. On a panoramic radiograph, a well-defined, bone-like, radiopaque mass was seen in the left condylar head (**Figure 1**). Axial and coronal computed tomographic (CT) scans revealed an opaque mass around the mandibular condyle (**Figures 2 and 3**). The patient's three-dimensional CT image showed a large mass in the anteromedial region of the left condyle (**Figure 4**). The tumor was excised under general anesthesia. The upper and lower compartments of the temporomandibular joint were accessed through an auriculotemporal approach. The surgical field was expanded with retraction along the masseter muscle downward. The disc, which adhered to the lesion at the anterior aspect of the condyle, was resected. The tumor was resected en bloc. The lesion could be easily separated from the surrounding tissues (**Figure 5**). Histologically, it was noted that the nodular mass was covered with a proliferative cap of cartilage with underlying zones of cancellous bone and irregular calcified cartilage. The osteocytes and chondrocytes were individually housed in a lacuna with a single nucleus (**Figure 6**). Sixteen-year follow-up assessments revealed satisfactory function and occlusion. There was no evidence of recurrence [11].

## 2.2. Chondroma

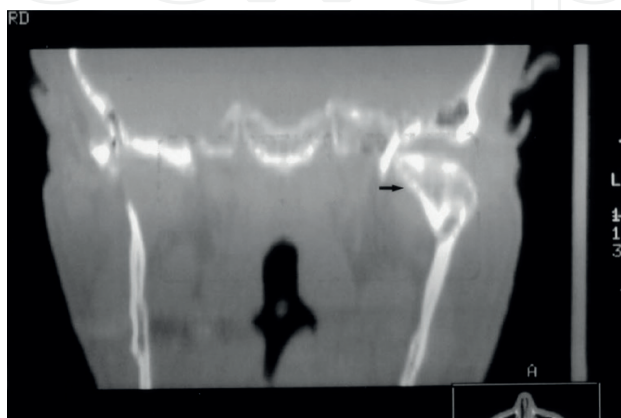
Chondroma is a rare, benign tumor of mature hyaline cartilage of mesenchymal origin [13]. Chondromas, are common in the small bones of the hands and feet, but are extremely rare in the TMJ area [14, 15]. Chondromas are classified into three types as (a) enchondroma that arises from medullary cavity, (b) juxtacortical that originate adjacent to the periosteum below



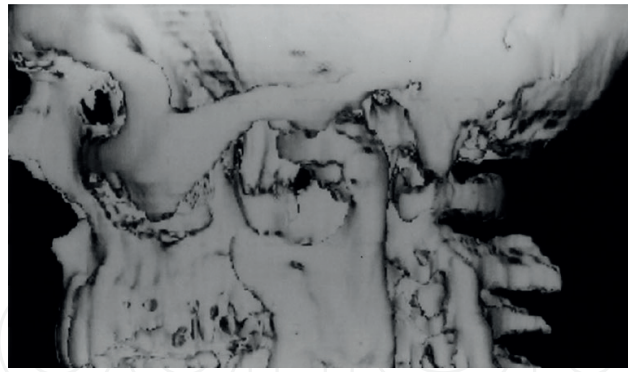
**Figure 1.** Panoramic radiograph, showing a bone-like, radiopaque mass in the left condylar head.



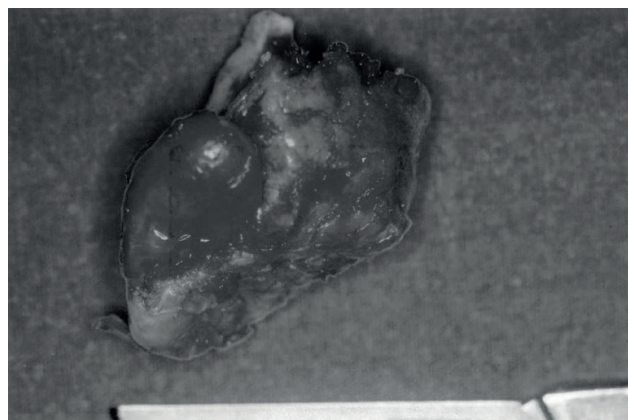
**Figure 2.** Axial CT scan, showing a well-defined, opaque mass.



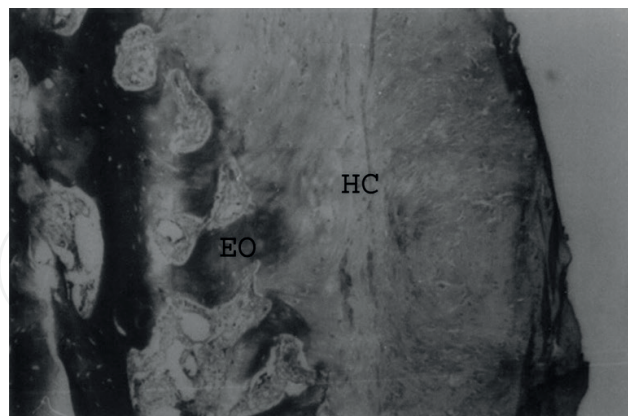
**Figure 3.** Coronal CT scan, showing localization of the osteochondroma.



**Figure 4.** Three-dimensional CT view of the osteochondroma.



**Figure 5.** Mass resected from the left condyle.



**Figure 6.** Histopathological aspect of the osteochondroma. The cancellous bone is surfaced by a cap of hyaline cartilage (HC). A zone of endochondral ossification (EO) appears between the cartilaginous cap and underlying cancellous bone (hematoxylin and eosin; magnification, 200).

the cortical face and (c) extra-skeletal that can be seen in the tongue and buccal mucosa [16, 17]. Chondromas are equally seen in men and women and most patients are 30–40 years old [14].

Chondromas are generally asymptomatic. Its signs and symptoms can mimic those of patients with more common disorders of facial asymmetry or dysfunction of the temporomandibular joint as clicking, limited mouth opening and deviation [18].

Radiographically, chondromas are irregular radiolucent or mottled region of the bone. There may be some calcification foci ranging from powder like to dense aggregates [19].

The differential diagnosis for bony or cartilaginous hyperplastic lesion of the temporomandibular joint may include condylar hyperplasia, osteochondroma, osteoma, chondroma, osteblastoma, fibrous dysplasia, ossifying fibroma (OF), chondromyxoid fibromas, synovial chondromatosis, chondroblastoma, chondrosarcoma and osteosarcoma [20, 21].

Chondromas can be treated as low-grade chondrosarcomas by surgical treatment of mandibular condyle to avoid recurrence [13].

### 2.3. Chondroblastoma

Chondroblastoma is a rare benign, cartilaginous, destructive tumor derived from immature cartilage cells which occurs infrequently in the head and neck area [22, 23]. Most chondroblastoma cases arise in the epiphysis of long bones such as distal femur, proximal tibia and proximal humerus [24]. It is more common in women [25].

Chondroblastoma shows similar clinical symptoms associated with temporomandibular disorders such as sound in the joint, decreased range of motion, swelling, pain, trismus and changing occlusion. If chondroblastoma occurs at the temporal bone, additional symptoms such as otalgia, paresthesia, hearing loss, ear noise and facial nerve weakness may be seen [26].

Computerized imaging (CT) and magnetic resonance imaging (MRI) are the most common diagnostic imaging techniques to identify chondroblastoma. On imaging, round radiolucent lesions with sharp bony edges are found in bone [27].

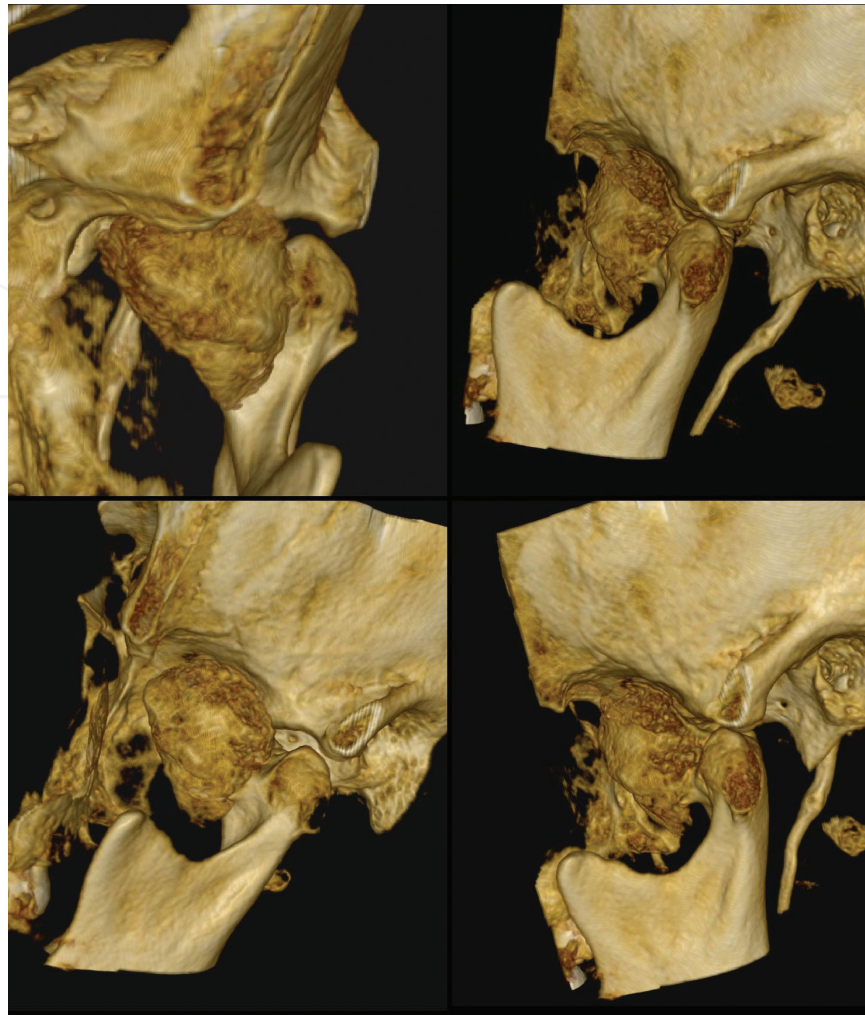
Differential diagnosis should be done with chondrosarcoma, chondromyxoid fibroma, synovial sarcoma, synovial chondromatosis and aneurysmal bone cyst. Biopsy is necessary for the definite diagnosis [28, 29].

Treatment alternatives are curettage, resection and excision. Chondroblastoma can be treated by conservative curettage when infiltration of bone has not occurred or is limited. Complete excision of the tumor reduces recurrence [30].

In the case of a chondroblastoma of the authors of this chapter, Dr Oncul and Dr Yurttutan, the tumor was removed under general anesthesia. A 35-year-old female patient had complaint of pain and asymmetry. The patient's three-dimensional CT image showed a large mass in the anteromedial region of the left condyle (**Figure 7**). The tumor was resected via a pre-auricular access (**Figures 8 and 9**), the mass was removed by performing condylectomy (**Figure 10**).

### 2.4. Synovial chondromatosis

Synovial chondromatosis (SC) is a rare benign nodular cartilaginous proliferative non-neoplastic lesion arising from the synovial membrane or the fibro-cartilaginous disc of the joints becoming loose bodies within the joint space [3, 31]. The first report of SC of the temporomandibular joint (TMJ) was in 1776 [32].



**Figure 7.** Three-dimensional CT view of the chondroblastoma.

The etiology of SC is unclear but it is thought to be a trauma history, occlusal disorders, bruxism and degenerative arthritis [33]. SC of TMJ is 2.5 times more common in females, mainly between 30 and 50 years old [34].

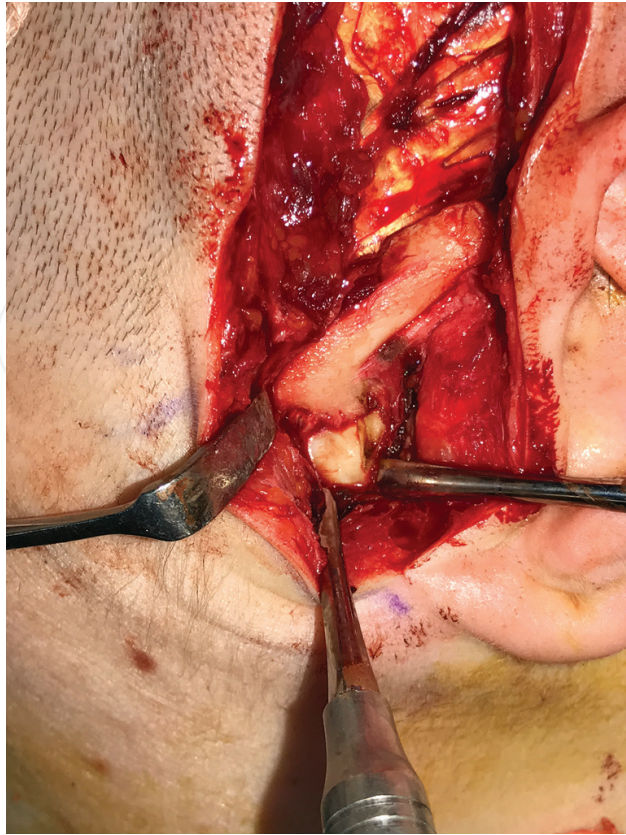
SC has three histological stages:

1. metaplasia found in the synovial membrane without the presence of detached particles.
2. metaplasia found in the synovial membrane with the presence of detached particles.
3. presence of detached particles which may vary in size [3].

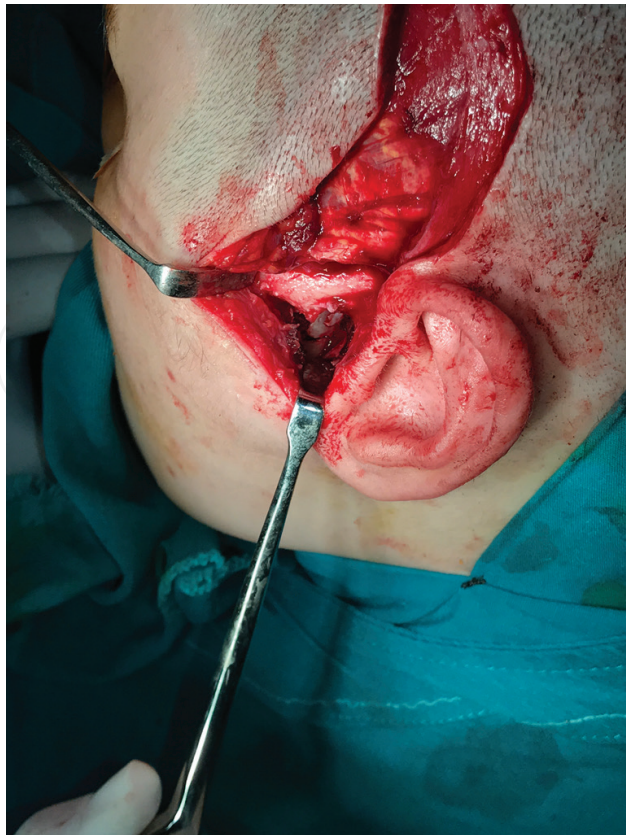Clinical signs and symptoms of SC is local diffuse pain, pre-auricular swelling, limitation of mandibular movement, joint sounds, tenderness, deviation of mouth opening [35].

Computerized imaging (CT), magnetic resonance imaging (MRI) and orthopantomography are the most common diagnostic imaging techniques. The main findings are widening of the joint space, changes in bone surface of joint and calcified loose bodies [36].

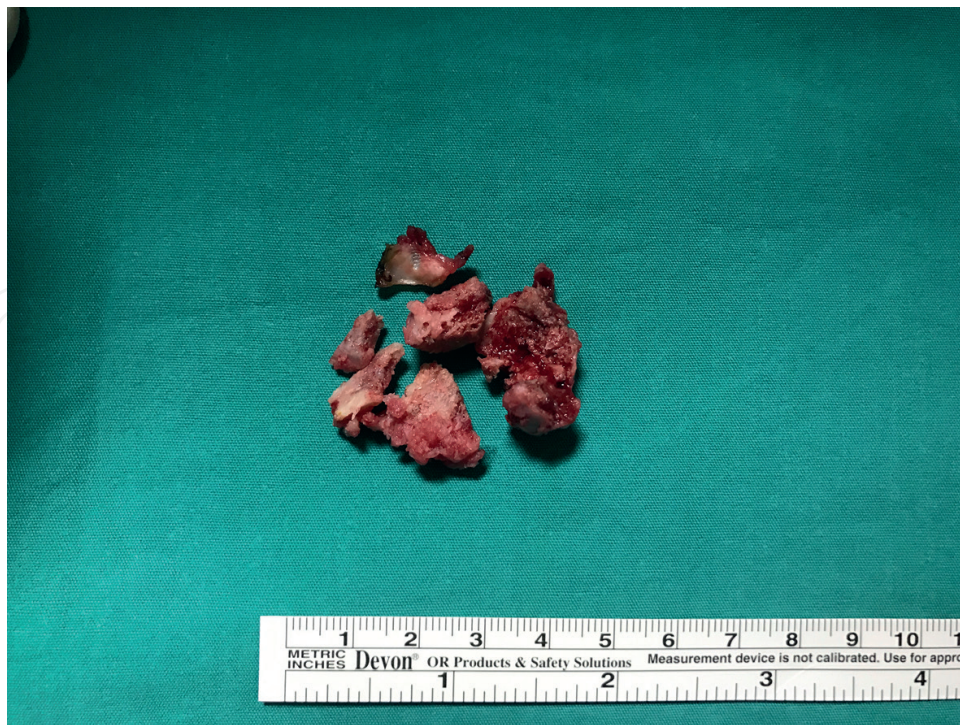



**Figure 8.** Intraoperative view of the condyle with the chondroblastoma.



**Figure 9.** Intraoperative view after the excision of chondroblastoma.



**Figure 10.** Macroscopic view of the pathology.

Differential diagnosis should be done with internal derangements, osteoarthritis, osteochondromas, villonodular synovitis, chondroblastoma and focal osteochondritis [37].

Synovectomy with removal of loose body from the joint space is the most preferred procedure. It can be applied in combination with discectomy or condylectomy. No recurrence when loose bodies are removed [38].

### 3. Osteogenic tumors

Osteogenic tumors are defined as neoplasms that produce an osteoid or bony matrix.

#### 3.1. Osteoma

Osteomas are benign osteogenic tumors involving compact or cancellous bone proliferation and arising from periosteum (peripheral osteoma), endosteum (central osteoma) and even extra-skeletal soft tissue, but they are actually hamartomas that can be seen in membranous bone [39, 40]. Most osteomas of the maxillofacial region occur in the mandible. Peripheral osteomas typically arise at the inferior border of the mandibular body [41, 42]. Only a few cases involving the temporomandibular joint have been reported [43]. Men seem to be more affected than women. The exact cause is unknown, whereas belief in reactive and neoplastic theories maintains [1].

Histologically, compact type osteomas (ivory) consist primarily of dense lamellar bone, and cancellous type osteomas have an abundance of bone marrow [42].

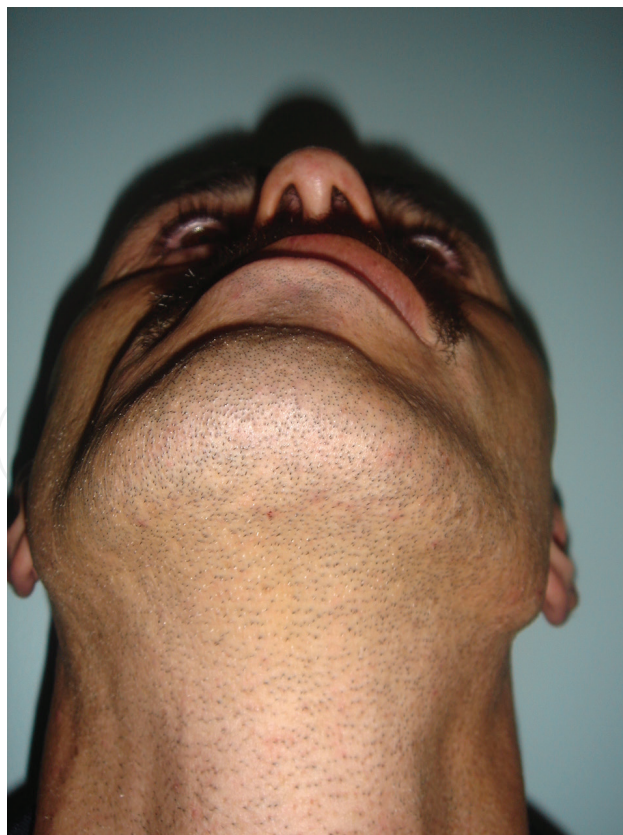The growth of osteomas occurring in TMJ may result in morphologic and functional disturbances, including facial asymmetry, malocclusion and limited mouth opening [44].

Radiographically, osteoma appears as a well-defined uniform radiopacity or as well-defined radiopacity with evidence of internal trabecular structure. In their centers such masses may exhibit a mixed radiolucent-radiopaque appearance depending on the amount of marrow tissues present [39, 45]. Panoramic radiography, CT, MRI and radionuclide scanning (scintigraphy) have been utilized for imaging of osteomas of the TMJ region [46].

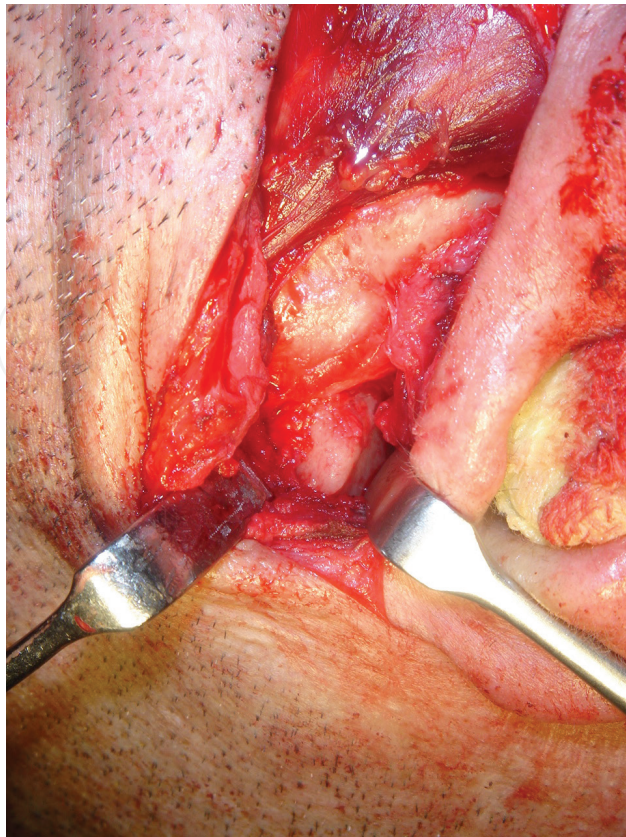
The differential diagnosis is established with exostoses, osteoid osteoma and osteoblastoma [46]. Osteomas of the condyle are lobulated; conversely, hyperplasia results in enlargement of the condyle that retains in its inventive form [47]. Osteoid osteoma and osteoblastoma are frequently painful and grow more rapidly than peripheral osteoma [1].

Large osteomas at TMJ can be treated by condylectomy and tumor resection. No recurrence is reported after surgery [43].

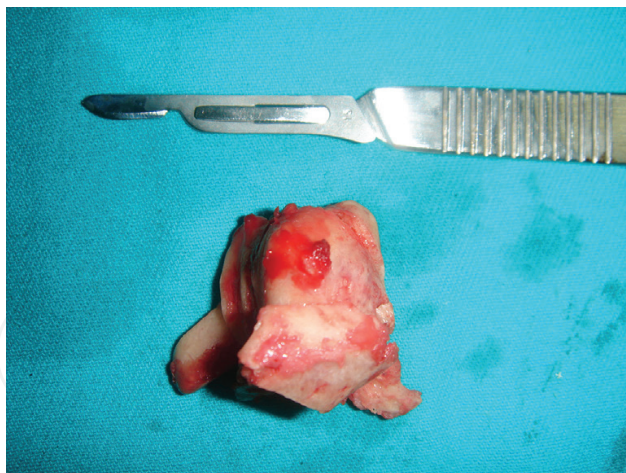
In the case of an osteoma of the author of this chapter, Dr Oncul, the tumor was removed under general anesthesia. A 45-year-old male patient had complaint of habitual luxation which had been present for 5 years and asymmetry (**Figure 11**). The tumor was resected via a pre-auricular access (**Figure 12**), the mass was removed by performing a condylectomy, preserving the articular meniscus (**Figure 13**). Microscopic examination showed a central nidus surrounded by a layer of dense cortical bone. The nidus consisted inconsiderable amount of interstitial connective tissue. No abnormal mitosis or malignancy findings were seen (**Figure 14**) [48].



**Figure 11.** Preoperative frontal view of the mandibular asymmetry.



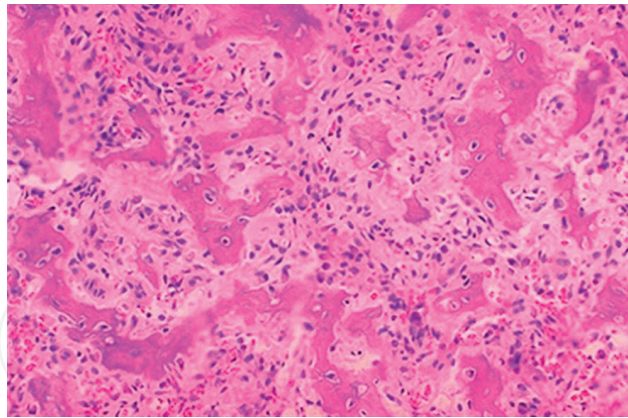
**Figure 12.** Intraoperative view of the condyle with the osteoma.



**Figure 13.** Macroscopic view of the pathology.

### **3.2. Osteoid osteoma**

Osteoid osteoma is a benign bone-forming tumor characterized by small size, limited growth potential and disproportionate pain. Osteoid osteoma usually affects children and adolescents, although it is occasionally seen in older individuals. It is more common in males [2]. Osteoid osteoma is rarely described in TMJ [49].



**Figure 14.** Histopathological aspect of the osteoma.

The trio of complaints for osteoid osteoma of the jaw is pain, swelling and tenderness [50].

The most typical symptom of osteoid osteoma is spontaneous pain, usually responsive to non-steroidal anti-inflammatory drugs (NSAIDs). At first, the pain is light and discontinuous, but later becomes severe and constant [51].

A characteristic radiographic finding is 'nidus', which represents a small, round, clear, non-calcified, well-demarcated radiolucency in the subjacent cortex surrounded by sclerotic bone, not larger than 2 cm [3]. CT and cone beam computed tomography (CBCT) are superior to MRI in diagnosing and precisely localizing these bone tumors in TMJ [46, 50].

The differential diagnosis of osteoid osteoma is established which includes bone island/solitary enostosis, intracortical bone abscess (Brodie abscess), sclerosing forms of osteomyelitis and early diagnosis of osteosarcoma or osteoblastoma, fibroma or fibrous dysplasia [14, 51].

However, the sequestrum of osteomyelitis is irregular rather than a well-demarcated round lesion and is usually located in the bone marrow, not in the cortical plate [50].

The most important criterion to distinguish osteoid osteoma from osteoblastoma: osteoid osteomas are typically <1 cm in size, whereas osteoblast [52] stomas are generally >2 cm. An osteoid osteoma usually contains only a single calcification, whereas an osteoblastoma contains multiple calcifications. However, the osteoblastoma differs from the osteoid osteoma in that it has a greater growth potential, is frequently painless, and becomes heavily calcified when subjected to radiological examination [51].

Surgical removal of the osteoid osteoma is the most advised treatment option if the pain is not relieved by NSAIDs. En bloc excision or cortical shaving and curettage of the nidus are sufficient and can provide immediate relief of symptoms. After the nidus is removed, all symptoms eventually disappear [46, 50, 53].

### 3.3. Osteoblastoma

Osteoblastoma is a rare benign bone-forming neoplasm which produces woven bone spicules, which are bordered by prominent osteoblasts. Osteoblastoma is uncommon, accounting for about 1% of all bone tumors and is more common in women and affects patients in the age

range of 10–30 years [2]. The tumor normally involves the long bones, spine and sacrum. Less than 10% of osteblastomas are located in the maxillofacial region [54, 55]. Osteblastoma involving the TMJ is very rare [56].

Complaints for osteblastoma are dull persistent pain and swelling [57]. Even if NSAIDs is used, the pain will not decrease in contrast to osteoid osteoma [56].

Osteblastoma has identical histological features to osteoid osteoma [2]. Osteblastomas are characterized by numerous plump osteoblastic cells producing and lining the haphazardly arranged lesional trabeculae of osteoid and woven bone. Numerous blood vessels are often seen in the osteoblastic and fibrous stroma filling the lesional inter-trabecular areas. Five scattered multinucleated giant cells resembling osteoclasts are also generally seen. Mitotic figures may be seen, but these are usually sparse and have a normal configuration [58]. Osteblastoma and osteoid osteoma are histopathologically very similar, and diagnosis is often based on the size of the lesion, with an osteoid osteoma being less than 1 cm in diameter and an osteblastoma being larger than 2 cm [59].

The radiographic features are well-defined expansile lesions contain small scattered calcifications [59]. Radiographic differential diagnosis of osteblastoma should include osteogenic sarcoma, chondrosarcoma, osteoid osteoma and aneurysmal bone cyst [3].

The treatment choice of osteblastoma for TMJ is conservative surgery. Recurrences after complete excision are uncommon [55].

## **4. Giant cell tumors**

Almost every lesion in the bone can contain giant cells, sometimes a large number. To be characterized as a giant cell tumor (GCT), the neoplasm must have oval mononuclear cells and more or less evenly distributed giant cells.

### **4.1. Giant cell tumor**

Giant cell tumors (GCTs) are a benign, locally aggressive neoplasm which is composed of sheets of neoplastic ovoid mononuclear cells interspersed with uniformly distributed large, osteoclast-like giant cells. GCT is classified as an “intermediate locally aggressive, rarely metastasizing” bone tumor by World Health Organization (WHO) [2]. The prevalence of GCTs peaks in adults in their 30s or 40s [60, 61]. GCTs are frequently identified at the epiphyses of long bones, particularly in the proximal tibia, distal femur and distal radius [62]. Craniofacial bone involvement is rare but has been reported to occur in the mandible, temporal bone, maxilla, occipital and sphenoid [63]. Less than 30 cases of GCT in the TMJ have been reported. Patients with GCTs at TMJ are presented with progressive pain and swelling. Due to compression or local invasion, hearing impairment, facial nerve paralysis, headache, visual area defects, double vision, visual loss, tinnitus, otalgia, vertigo and trismus can occur [64]. Discomforts as jaw locking, mandibular deviation and clicking can also be seen. These three symptoms and signs are also common with temporomandibular disorders [65].

Recent experiments have characterized GCTs as consisting of three cell types: (1) osteoclast-like, multinucleated giant cells; (2) round mononuclear cells resembling monocytes and (3) spindle-shaped, fibroblast-like stromal cells [66].

GCTs appear lytic, subarticular, eccentrically located and usually lack a sclerotic rim on radiographs. Local bony destruction, cortical breakthrough and soft tissue expansion may also be seen [67]. MRI is the preferred imaging modality for GCTs, as the diagnostic accuracy of MRI is high and it can detect soft tissue and intra-articular extension [68].

Important differential diagnoses of GCTs are giant cell reparative granuloma, hyperparathyroidism, non-ossifying fibroma, chondroblastoma, solid areas of aneurysmal bone cyst, malignant fibrous histiocytoma and osteogenic sarcoma [69].

Various modalities have been used in the treatment of GCTs including surgery, cryotherapy, radiotherapy, calcitonin, corticosteroids, an interferon and recently, the monoclonal antibody against receptor activator of nuclear factor kappa-B ligand (RANKL) denosumab [70, 71]. Intralesional curettage is not recommended for GCTs in the skull base because recurrence in this location would complicate further treatment and make it unresectable for reoperation [72]. However, because of the complexity of the craniofacial anatomy, wide excisions or en bloc resections for head and neck GCTs should be attempted. Radiotherapy can be applied for cases where wide excision cannot be achieved or for patients who are not fit for surgery [73]. But radiotherapy as a sole treatment modality is not recommended due to high (60–70%) recurrence rates [74]. Denosumab, a receptor activator of nuclear factor kappa-B ligand (RANKL) inhibitor can be used in recurrent and unresectable GCTs [75]. Denosumab specifically inhibits osteoclast-mediated bone destruction by GCTs [76]. Denosumab can be used to reduce the tumor size preoperatively [74].

## 5. Vascular tumors

Primary vascular tumors are rare in bone. Hemangiomas occur as coincidental findings in the skull or spine. X-ray features are almost always diagnostic. They rarely cause clinical symptoms.

### 5.1. Hemangioma

Intraosseous hemangiomas are benign vasoformative neoplasm or developmental condition of endothelial origin tumors occurring most often in the maxilla and mandible after the skull and vertebrae [2]. Clinically, hemangiomas of the mandible are often presented as slow-growing expansile lesions. They occur twice as often in women. Hemangiomas present as radiolucent lesions, which may have a unicystic- or multicystic-like “soap bubbly,” “honeycomb” or “trabeculated” appearance [77]. The differential diagnosis for this radiographic appearance must also include: ameloblastoma, odontogenic keratocyst, central giant cell granulomata, giant cell tumor of hyperparathyroidism, aneurysmal bone cyst and metastatic lesions [78]. Treatment may include embolization, sclerosing agents and surgery [79].

## 6. Lipogenic tumors

Lipomas are rare in the bones and are found incidentally in the X-rays and contain calcaneus. Radiography shows a well-defined area of lucency with a central calcification area.

### 6.1. Intraosseous lipoma

Lipoma of bone is a benign neoplasm of adipocytes that arises within the medullary cavity, cortex or on the surface of bone. Lipoma of bone is rare and accounts for less than 0.1% of primary bone tumors [2]. The jaw is its most uncommon bone location.

Etiology of lipoma is not clear but possible etiological factors may be dental trauma, disruption of the post-extraction healing process, retention of radicular remains, medullary bone infarction (common in elderly) or osteoporotic bones [80–82]. They are generally asymptomatic, being diagnosed by chance during a radiographic examination. Symptoms depend on its size, location, time of evolution and growth rate. Pain, swelling and numbness may occur [83, 84]. Radiological appearance of intraosseous lipoma is well-circumscribed radiolucent unilocular or multilocular lesion. Treatment involves curettage of the lesion, with or without grafting the cavity [85].

## 7. Bone-related odontogenic tumors

Odontogenic tumors are rare, some of them very rare, but they can be an important diagnostic and therapeutic problem.

### 7.1. Ossifying fibroma

Ossifying fibroma (OF) is a well-demarcated lesion composed of fibrocellular tissue and mineralized material of varying appearances [86]. The mandible (especially the molar region) is affected more often than the maxilla [87]. Ossifying fibroma is mainly diagnosed between the second and fourth decades of life, with women being affected more frequently than men [88, 89]. Ossifying fibroma of craniofacial bones is composed of two components: fibrous stroma and bone elements that show various degrees of maturation [90]. The treatment of choice is surgical excision. Enucleation and curettage could be suitable for small and well-defined lesions; however, larger masses require radical surgery [91]. Condylectomy may be performed with an immediate TMJ reconstruction [92].

## 8. Fibrohistiocytic tumors

Diffuse and localized forms of the giant cell tumor of the tendon sheath are more common with the descriptive category of fibrohistiocytic lesions.



### 8.1. Pigmented villonodular synovitis

Pigmented villonodular synovitis (PVNS) is a rare, benign tumor but is a locally aggressive tumor of the synovial membrane with an annual incidence [93]. Lesions originate from the joint capsule, tendon sheath or bursae and occur most commonly in the knee, hip and ankle [94]. The etiology of PVNS is not clear and may result from chronic inflammation, trauma or represent a distinct neoplastic process [95–97]. It is considered as fibrohistiocytic tumor by the World Health Organization classification of bone and soft tissue tumors. Tenosynovial giant cell tumor, diffuse-type giant cell tumor, villonodular synovitis, giant cell tumor of the tendon sheath and nodular tenosynovitis are the synonyms of that tumor [2]. PVNS of the temporomandibular joint (TMJ) is a rare variant with less than 80 cases reported in the literature [98]. This slow-growing tumor may be seen in all age groups. The peak age of occurrence is between 30 and 50 ages [99]. PVNS has been shown to have a synovial cell origin immunophenotypically and is reported to involve myofibroblastic differentiation [100, 101]. The tumor is composed of monocyte, multinucleated giant cells and foam cells distributing in a fibrous stroma, presenting hemosiderin deposition [102]. It has a higher gender predilection in females [103].

PVNS can enlarge into the middle cranial fossa, displacing the temporal lobe and invading the dura mater. Patients are generally present with an enlarging pre-auricular mass, pain, trismus or hearing loss [104]. The radiological appearance of PVNS on CT is a contrast-enhancing intra-articular lesion originating in the glenoid fossa, with focal areas of hyperdensity or cysts. It produces variable bony remodeling or erosion of the adjacent bone [105]. On MRI, the most characteristic finding is a mass with low signal intensity on T1 and GRE-T2 weighted sequences, reflecting the deposition of blood degradation products. Occasionally, hyperintense areas on T1 or GRE-T2 sequences may appear due to the presence of lipids or cysts, respectively [106].

The differential diagnosis is established with osteoarthritic change, chondroblastoma, chondrosarcoma, aneurysmal bone cyst, rhabdomyosarcoma, plasmacytoma, cholesteatoma, intraosseous meningioma, reparative granuloma, tumoral calcium pyrophosphate dihydrate crystal deposition disease, chondroma of the tendon sheath, synovial chondromatosis, tendon sheath fibroma, synovial hemangioma, synovial sarcoma, embryonal rhabdomyosarcoma, giant cell granuloma, brown tumor and malignant fibrous histiocytoma [107, 108].

Therapy for PVNS of the TMJ and temporal bone remains surgical. PVNS of the temporal bone most commonly acquires the diffuse form of disease involving the contiguous synovial space with extension into adjacent structures. Accordingly, limited resection or curettage carries a high rate of recurrence, whereas wide local resection, when feasible, is usually curative [104, 109]. The surgical approach must be carefully planned to allow for a complete removal of the tumor while minimizing surgical trauma [110].

## 9. Tumors of uncertain differentiation

For tumors in this category, in most cases, there is no clear idea on the differentiation line (or normal cellular counterpart) that these lesions repeat.

### 9.1. Juxta-articular myxoma

Juxta-articular myxoma is a rare, benign soft tissue tumor that usually arises in the vicinity of a large joint, has histological features resembling a cellular myxoma [2]. There are reported cases involving myxomas of the knee, shoulder, elbow, wrist and hip. To our knowledge, however, there is just one reported cases of juxta-articular myxomas of the temporomandibular joint (TMJ) [111]. The juxta-articular myxoma resembles the common myxoma, however, it is distinguished by its association with the underlying connective tissue components of the joint. These include the associated tendons, joint capsule, meniscus and synovium [112]. Palpable swelling is occasionally associated with pain, tenderness or a functional limitation may occur [113, 114]. Like the common myxoma, the treatment of choice for the juxta-articular myxomas is complete local excision [115]. Tumors extending into the infratemporal fossa are notoriously difficult to resect [116].

### Author details

Mehmet Emre Yurttutan\*, Ayşegül Tüzüner Öncül and Hakan Alpay Karasu

\*Address all correspondence to: yurttutan@ankara.edu.tr

Faculty of Dentistry, Department of Oral and Maxillofacial Surgery, Ankara University, Ankara, Turkey

### References

- [1] Fonseca RJ. Oral and Maxillofacial Surgery: Temporomandibular Disorders. USA: Saunders; 2000
- [2] Flether CDM, Unni KK, Mertens F. World Health Organization Classification of Tumours of Soft Tissue and Bone. IARC: Lyon; 2002
- [3] Robert EM, Stern D. Oral and Maxillofacial Pathology, A Rationale for Diagnosis and Treatment. India: Quintessence; 2003
- [4] Andrade NN, Gandhewar TM, Kapoor P, Thomas R. Osteochondroma of the mandibular condyle – Report of an atypical case and the importance of computed tomography. *Journal of oral Biology and Craniofacial Research*. 2014;4(3):208-213
- [5] Kurita K, Ogi N, Echiverre NV, Yoshida K. Osteochondroma of the mandibular condyle. A case report. *International Journal of Oral and Maxillofacial Surgery*. 1999;28(5):380-382
- [6] Murphey MD, Choi JJ, Kransdorf MJ, Flemming DJ, Gannon FH. Imaging of osteochondroma: Variants and complications with radiologic-pathologic correlation. *Radiographics: A Review Publication of the Radiological Society of North America, Inc*. 2000;20(5):1407-1434

- [7] Gaines RE Jr, Lee MB, Crocker DJ. Osteochondroma of the mandibular condyle: Case report and review of the literature. *Journal of Oral and Maxillofacial Surgery: Official Journal of the American Association of Oral and Maxillofacial Surgeons*. 1992;**50**(8):899-903
- [8] Koole R, Steenks MH, Witkamp TD, Slootweg PJ, Shaefer J. Osteochondroma of the mandibular condyle. A case report. *International Journal of Oral and Maxillofacial Surgery*. 1996;**25**(3):203-205
- [9] Henry CH, Granite EL, Rafetto LK. Osteochondroma of the mandibular condyle: Report of a case and review of the literature. *Journal of Oral and Maxillofacial Surgery: Official Journal of the American Association of Oral and Maxillofacial Surgeons*. 1992;**50**(10):1102-1108
- [10] Spahr J, Elzay RP, Kay S, Frable WJ. Chondroblastoma of the temporomandibular joint arising from articular cartilage: A previously unreported presentation of an uncommon neoplasm. *Oral Surgery, Oral Medicine, and Oral Pathology*. 1982;**54**(4):430-435
- [11] Karasu HA, Ortakoglu K, Okcu KM, Gunhan O. Osteochondroma of the mandibular condyle: Report of a case and review of the literature. *Military Medicine*. 2005;**170**(9):797-801
- [12] Utumi ER, Pedron IG, Perrella A, Zambon CE, Ceccheti MM, Cavalcanti MG. Osteochondroma of the temporomandibular joint: A case report. *Brazilian Dental Journal*. 2010;**21**(3):253-258
- [13] Marchetti C, Mazzoni S, Bertoni F. Chondroma of the mandibular condyle-relapse of a rare benign chondroid tumour after 5 years' follow-up: Case report. *The British Journal of Oral & Maxillofacial Surgery*. 2012;**50**(5):e69-e71
- [14] do Egito Vasconcelos BC, Porto GG, Bessa-Nogueira RV. Rare benign tumors of the mandibular condyle: Report of 2 cases and literature review. *Journal of Oral and Maxillofacial Surgery: Official Journal of the American Association of Oral and Maxillofacial Surgeons*. 2007;**65**(9):1830-1835
- [15] Heitz C, Vogt BF, Bergoli RD, Hirsch WD, de Souza CE, Silva DN. Chondroma in temporomandibular region – Case report and therapeutic considerations. *Oral and Maxillofacial Surgery*. 2012;**16**(1):75-78
- [16] Chandu A, Spencer JA, Dyson DP. Chondroma of the mandibular condyle: An example of a rare tumour. *Dento Maxillo Facial Radiology*. 1997;**26**(4):242-245
- [17] Chang SE, Lee MW, Choi JH, Sung KJ, Moon KC, Koh JKA. Case of lingual chondroma. *The British Journal of Dermatology*. 1999;**141**(4):773-774
- [18] Dhirawani RB, Anand K, Lalwani G, Pathak S, Thakkar B. True chondroma of the mandibular condyle: A rare case. *Annals of Maxillofacial Surgery*. 2014;**4**(2):220-223
- [19] Fechner RE, Mills SE. *Atlas of Tumor Pathology – Tumors of the Bones and Joints*. Armed Forces Institute of Pathology: Washington, DC; 1993
- [20] Shintaku WH, Venturin JS, Langlais RP, Clark GT. Imaging modalities to access bony tumors and hyperplastic reactions of the temporomandibular joint. *Journal of Oral and Maxillofacial Surgery: Official Journal of the American Association of Oral and Maxillofacial Surgeons*. 2010;**68**(8):1911-1921

- [21] Lazow SK, Pihlstrom RT, Solomon MP, Berger JR. Condylar chondroma: Report of a case. *Journal of Oral and Maxillofacial Surgery: Official Journal of the American Association of Oral and Maxillofacial Surgeons*. 1998;**56**(3):373-378
- [22] Payne M, Yusuf H. Benign chondroblastoma involving the mandibular condyle. *The British Journal of Oral & Maxillofacial Surgery*. 1987;**25**(3):250-255
- [23] Jaffe HL, Lichtenstein L. Benign chondroblastoma of bone: A reinterpretation of the so-called calcifying or chondromatous giant cell tumor. *The American Journal of Pathology*. 1942;**18**(6):969-991
- [24] Varvares MA, Cheney ML, Goodman ML, Ceisler E, Montgomery WW. Chondroblastoma of the temporal bone. Case report and literature review. *The Annals of Otolaryngology, Rhinology, and Laryngology*. 1992;**101**(9):763-769
- [25] Bui P, Ivan D, Oliver D, Busaidy KF, Wilson J. Chondroblastoma of the temporomandibular joint: Report of a case and literature review. *Journal of Oral and Maxillofacial Surgery: Official Journal of the American Association of Oral and Maxillofacial Surgeons*. 2009;**67**(2):405-409
- [26] Moon IS, Kim J, Lee HK, Lee WS. Surgical treatment and outcomes of temporal bone chondroblastoma. *European Archives of Oto-Rhino-Laryngology: Official Journal of the European Federation of Oto-Rhino-Laryngological Societies (EUFOS): Affiliated with the German Society for Oto-Rhino-Laryngology – Head and Neck Surgery*. 2008;**265**(12):1447-1454
- [27] Bloem JL, Mulder JD. Chondroblastoma: A clinical and radiological study of 104 cases. *Skeletal Radiology*. 1985;**14**(1):1-9
- [28] Warner BF, Luna MA, Robert Newland T. Temporomandibular joint neoplasms and pseudotumors. *Advances in Anatomic Pathology*. 2000;**7**(6):365-381
- [29] Kondoh T, Hamada Y, Kamei K, Seto K. Chondroblastoma of the mandibular condyle: Report of a case. *Journal of Oral and Maxillofacial Surgery: Official Journal of the American Association of Oral and Maxillofacial Surgeons*. 2002;**60**(2):198-203
- [30] Kim SM, Hong SW, Ryu DJ, Huh JK. Chondroblastoma of the temporomandibular joint lateral capsule: A case report. *Cranio: The Journal of Craniomandibular Practice*. 2015;**33**(4):306-311
- [31] Milgram JW. The classification of loose bodies in human joints. *Clinical Orthopaedics and Related Research*. 1977;**124**:282-291
- [32] Yokota N, Inenaga C, Tokuyama T, Nishizawa S, Miura K, Namba H. Synovial chondromatosis of the temporomandibular joint with intracranial extension. *Neurologia Medico-Chirurgica*. 2008;**48**(6):266-270
- [33] Holmlund AB, Eriksson L, Reinholt FP. Synovial chondromatosis of the temporomandibular joint: Clinical, surgical and histological aspects. *International Journal of Oral and Maxillofacial Surgery*. 2003;**32**(2):143-147

- [34] Mankin HJ, editor. *Synovial Chondromatosis in Pathophysiology of Orthopaedic Diseases*. Rosemont, IL: American Academy Orthopaedic Surgeons; 2006
- [35] Petitto AR, Bennett J, Assael LA, Carlotti AE Jr. Synovial chondromatosis of the temporomandibular joint: Varying presentation in 4 cases. *Oral Surgery, Oral Medicine, Oral Pathology, Oral Radiology, and Endodontics*. 2000;**90**(6):758-764
- [36] Guarda-Nardini L, Piccotti F, Ferronato G, Manfredini D. Synovial chondromatosis of the temporomandibular joint: A case description with systematic literature review. *International Journal of Oral and Maxillofacial Surgery*. 2010;**39**(8):745-755
- [37] Pinto AA, Jr, Ferreira e Costa R, de Sousa SF, Chagas MR, do Carmo MA, de Lacerda JC. Synovial chondromatosis of the temporomandibular joint successfully treated by surgery. *Head and Neck Pathology*. 2015;**9**(4):525-529
- [38] Ionna F, Amantea M, Mastrangelo F, Ballini A, Maglione MG, Aversa C, et al. Innovative surgical management of the synovial chondromatosis of temporomandibular joints: Highly conservative surgical technique. *The Journal of Craniofacial Surgery*. 2016;**27**(5):1197-1201
- [39] Yonezu H, Wakoh M, Otonari T, Sano T, Hashimoto S, Uchiyama T. Osteoma of mandibular condyle as cause of acute pain and limited-mouth-opening: Case report. *The Bulletin of Tokyo Dental College*. 2007;**48**(4):193-197
- [40] Yang C, Qiu WL. Osteoid osteoma of the eminence of the temporomandibular joint. *The British Journal of Oral & Maxillofacial Surgery*. 2001;**39**(5):404-406
- [41] Schneider LC, Dolinsky HB, Grodjesk JE. Solitary peripheral osteoma of the jaws: Report of case and review of literature. *Journal of Oral Surgery (American Dental Association: 1965)*. 1980;**38**(6):452-455
- [42] Kaplan I, Calderon S, Buchner A. Peripheral osteoma of the mandible: A study of 10 new cases and analysis of the literature. *Journal of Oral and Maxillofacial Surgery: Official Journal of the American Association of Oral and Maxillofacial Surgeons*. 1994;**52**(5):467-470
- [43] Kondoh T, Seto K, Kobayashi K. Osteoma of the mandibular condyle: Report of a case with a review of the literature. *Journal of Oral and Maxillofacial Surgery: Official Journal of the American Association of Oral and Maxillofacial Surgeons*. 1998;**56**(8):972-979
- [44] Bulut E, Acikgoz A, Ozan B, Gunhan O. Large peripheral osteoma of the mandible: A case report. *International Journal of Dentistry*. 2010;**2010**:834761
- [45] Siar CH, Jalil AA, Ram S, Ng KH. Osteoma of the condyle as the cause of limited-mouth opening: A case report. *Journal of Oral Science*. 2004;**46**(1):51-53
- [46] Misra N, Srivastava S, Bodade PR, Rastogi V. Osteoma of temporomandibular joint: a rarity. *BMJ case reports*. 2013;**2013**:1-5
- [47] Thoma KH. Tumors of the condyle and temporomandibular joint. *Oral Surgery, Oral Medicine, and Oral Pathology*. 1954;**7**(10):1091-1107

- [48] Tuzuner Oncul AM, Turalı S, Kadioglu MN, Ergul KC, Arpacı H, Karasu HA. Benign Tumoral Growths of the Mandibular Condyle. XXI Congress of the European Association for Cranio-Maxillo-Facial Surgery; Dubrovnik, Croatia. Dubrovnik: European Association for Cranio-Maxillo-Facial Surgery; 2012. p. 369-370
- [49] Deferm JT, Steens SCA, Vriens D, Bekers EM, Kalaykova SI, Borstlap WA. Chronic temporomandibular joint pain: Two cases of osteoid osteoma and a review of the literature. *International Journal of Oral and Maxillofacial Surgery*. 2017;**46**(9):1130-1137
- [50] An SY, Shin HI, Choi KS, Park JW, Kim YG, Benavides E, et al. Unusual osteoid osteoma of the mandible: Report of case and review of the literature. *Oral Surgery, Oral Medicine, Oral Pathology and Oral Radiology*. 2013;**116**(2):e134-e140
- [51] Tochiwara S, Sato T, Yamamoto H, Asada K, Ishibashi K. Osteoid osteoma in mandibular condyle. *International Journal of Oral and Maxillofacial Surgery*. 2001;**30**(5):455-457
- [52] Kroon HM, Schurmans J. Osteoblastoma: Clinical and radiologic findings in 98 new cases. *Radiology*. 1990;**175**(3):783-790
- [53] Goto T, Shinoda Y, Okuma T, Ogura K, Tsuda Y, Yamakawa K, et al. Administration of nonsteroidal anti-inflammatory drugs accelerates spontaneous healing of osteoid osteoma. *Archives of Orthopaedic and Trauma Surgery*. 2011;**131**(5):619-625
- [54] Ohkawa M, Fujiwara N, Tanabe M, Takashima H, Satoh K, Mori Y, et al. Benign osteoblastoma of the temporal bone. *AJNR – American Journal of Neuroradiology*. 1997;**18**(2):324-326
- [55] Wozniak AW, Nowaczyk MT, Osmola K, Golusinski W. Malignant transformation of an osteoblastoma of the mandible: Case report and review of the literature. *European Archives of Oto-Rhino-Laryngology: Official Journal of the European Federation of Oto-Rhino-Laryngological Societies (EUFOS): Affiliated with the German Society for Oto-Rhino-Laryngology – Head and Neck Surgery*. 2010;**267**(6):845-849
- [56] Jones AC, Prihoda TJ, Kacher JE, Odingo NA, Freedman PD. Osteoblastoma of the maxilla and mandible: A report of 24 cases, review of the literature, and discussion of its relationship to osteoid osteoma of the jaws. *Oral Surgery, Oral Medicine, Oral Pathology, Oral Radiology, and Endodontics*. 2006;**102**(5):639-650
- [57] Rawal YB, Angiero F, Allen CM, Kalmar JR, Sedghizadeh PP, Steinhilber AM. Gnathic osteoblastoma: Clinicopathologic review of seven cases with long-term follow-up. *Oral Oncology*. 2006;**42**(2):123-130
- [58] Neville B, Damm DD, Allen C, Chi A. *Oral and Maxillofacial Pathology*. 4 ed. Missouri: Elsevier; 2016
- [59] Emanuelsson J, Allen CM, Rydin K, Sjostrom M. Osteoblastoma of the temporal articular tubercle misdiagnosed as a temporomandibular joint disorder. *International Journal of Oral and Maxillofacial Surgery*. 2017;**46**(5):610-613
- [60] Nishimura K, Satoh T, Maesawa C, Ishijima K, Sato H. Giant cell tumor of the larynx: A case report and review of the literature. *American Journal of Otolaryngology*. 2007;**28**(6):436-440

- [61] van der Heijden L, Dijkstra PD, van de Sande MA, Kroep JR, Nout RA, van Rijswijk CS, et al. The clinical approach toward giant cell tumor of bone. *The Oncologist*. 2014;**19**(5):550-561
- [62] Bibas-Bonet H, Fauze RA, Lavado MG, Paez RO, Nieman J. Garcin syndrome resulting from a giant cell tumor of the skull base in a child. *Pediatric Neurology*. 2003;**28**(5):392-395
- [63] Bertoni F, Unni KK, Beabout JW, Ebersold MJ. Giant cell tumor of the skull. *Cancer*. 1992;**70**(5):1124-1132
- [64] Findlay JM, Chiasson D, Hudson AR, Chui M. Giant-cell tumor of the middle cranial fossa. Case report. *Journal of Neurosurgery*. 1987;**66**(6):924-928
- [65] Manfredini D, Guarda-Nardini L, Winocur E, Piccotti F, Ahlberg J, Lobbezoo F. Research diagnostic criteria for temporomandibular disorders: A systematic review of axis I epidemiologic findings. *Oral Surgery, Oral Medicine, Oral Pathology, Oral Radiology, and Endodontics*. 2011;**112**(4):453-462
- [66] Wulling M, Engels C, Jesse N, Werner M, Delling G, Kaiser E. The nature of giant cell tumor of bone. *Journal of Cancer Research and Clinical Oncology*. 2001;**127**(8):467-474
- [67] Wang CS, Lou JH, Liao JS, Ding XY, LJ D, Lu Y, et al. Recurrence in giant cell tumour of bone: Imaging features and risk factors. *La Radiologia Medica*. 2013;**118**(3):456-464
- [68] Purohit S, Pardiwala DN. Imaging of giant cell tumor of bone. *Indian Journal of Orthopaedics*. 2007;**41**(2):91-96
- [69] Zheng MH, Robbins P, Xu J, Huang L, Wood DJ, Papadimitriou JM. The histogenesis of giant cell tumour of bone: A model of interaction between neoplastic cells and osteoclasts. *Histology and Histopathology*. 2001;**16**(1):297-307
- [70] Lopez-Pousa A, Martin Broto J, Garrido T, Vazquez J. Giant cell tumour of bone: New treatments in development. *Clinical & Translational Oncology: Official Publication of the Federation of Spanish Oncology Societies and of the National Cancer Institute of Mexico*. 2015;**17**(6):419-430
- [71] Xu SF, Adams B, Yu XC, Xu M. Denosumab and giant cell tumour of bone-a review and future management considerations. *Current Oncology (Toronto, Ont)*. 2013;**20**(5):e442-e447
- [72] Prasad SC, Piccirillo E, Nuseir A, Sequino G, De Donato G, Paties CT, et al. Giant cell tumors of the skull base: Case series and current concepts. *Audiology & Neuro-Otology*. 2014;**19**(1):12-21
- [73] Chen ZX, DZ G, ZH Y, Qian TN, Huang YR, YH H, et al. Radiation therapy of giant cell tumor of bone: Analysis of 35 patients. *International Journal of Radiation Oncology, Biology, Physics*. 1986;**12**(3):329-334
- [74] Nicoli TK, Saat R, Kontio R, Piippo A, Tarkkanen M, Tarkkanen J, et al. Multidisciplinary approach to management of temporal bone giant cell tumor. *Journal of Neurological Surgery Reports*. 2016;**77**(3):e144-e149

- [75] Branstetter DG, Nelson SD, Manivel JC, Blay JY, Chawla S, Thomas DM, et al. Denosumab induces tumor reduction and bone formation in patients with giant-cell tumor of bone. *Clinical Cancer Research: An Official Journal of the American Association for Cancer Research*. 2012;**18**(16):4415-4424
- [76] Chawla S, Henshaw R, Seeger L, Choy E, Blay JY, Ferrari S, et al. Safety and efficacy of denosumab for adults and skeletally mature adolescents with giant cell tumour of bone: Interim analysis of an open-label, parallel-group, phase 2 study. *The Lancet Oncology*. 2013;**14**(9):901-908
- [77] DelBalso AM, Banyas JB, Wild LM. Hemangioma of the mandibular condyle and ramus. *AJNR – American Journal of Neuroradiology*. 1994;**15**(9):1703-1705
- [78] Lund BA, Dahlin DC. Hemangiomas of the mandible and maxilla. *Journal of Oral Surgery, Anesthesia, and Hospital Dental Service*. 1964;**22**:234-242
- [79] Guibert-Tranier F, Piton J, Riche MC, Merland JJ, Caille JM. Vascular malformations of the mandible (intraosseous haemangiomas). The importance of preoperative embolization. A study of 9 cases. *European Journal of Radiology*. 1982;**2**(4):257-272
- [80] Barker GR, Sloan P. Intraosseous lipomas: Clinical features of a mandibular case with possible aetiology. *The British Journal of Oral & Maxillofacial Surgery*. 1986;**24**(6):459-463
- [81] Basheer S, Abraham J, Shameena P, Balan A. Intraosseous lipoma of mandible presenting as a swelling. *Journal of Oral and Maxillofacial Pathology: JOMFP*. 2013;**17**(1):126-128
- [82] Hemavathy S, Roy S, Kiresur A. Intraosseous angioliipoma of the mandible. *Journal of Oral and Maxillofacial Pathology: JOMFP*. 2012;**16**(2):283-287
- [83] Buric N, Krasic D, Visnjic M, Katic V. Intraosseous mandibular lipoma: A case report and review of the literature. *Journal of Oral and Maxillofacial Surgery: Official Journal of the American Association of Oral and Maxillofacial Surgeons*. 2001;**59**(11):1367-1371
- [84] Gonzalez-Perez LM, Perez-Ceballos JL, Carranza-Carranza A. Mandibular intraosseous lipoma: Clinical features of a condylar location. *International Journal of Oral and Maxillofacial Surgery*. 2010;**39**(6):617-620
- [85] Sanjuan A, Dean A, Garcia B, Alamillos F, Roldan E, Blanco A. Condylar intramedullary intraosseous lipoma: Contribution of a new case and review of the literature. *Journal of Clinical and Experimental Dentistry*. 2017;**9**(3):e498-e502
- [86] Barnes L, Eveson JW, Reichart P, Sidransky D. World Health Organization Classification of Tumours. Pathology and Genetics of Head and Neck Tumours. IARC: Lyon; 2005
- [87] Vegas Bustamante E, Gargallo Albiol J, Berini Aytés L, Gay Escoda C. Benign fibro-osseous lesions of the maxillas: Analysis of 11 cases. *Medicina oral, patologia oral y cirugía bucal*. 2008;**13**(10):E653-E656
- [88] Speight PM, Carlos R. Maxillofacial fibro-osseous lesions. *Current Diagnostic Pathology* 2006;**12**:1-10



- [89] Eversole R, Su L, ElMofty S. Benign fibro-osseous lesions of the craniofacial complex. A review. *Head and Neck Pathology*. 2008;**2**(3):177-202
- [90] YS F, Perzin KH. Non-epithelial tumors of the nasal cavity, paranasal sinuses, and nasopharynx. A clinicopathologic study. II. Osseous and fibro-osseous lesions, including osteoma, fibrous dysplasia, ossifying fibroma, osteoblastoma, giant cell tumor, and osteosarcoma. *Cancer*. 1974;**33**(5):1289-1305
- [91] Chang CC, Hung HY, Chang JY, CH Y, Wang YP, Liu BY, et al. Central ossifying fibroma: A clinicopathologic study of 28 cases. *Journal of the Formosan Medical Association = Taiwan yi zhi*. 2008;**107**(4):288-294
- [92] Zavatiero E, Garzino-Demo P, Berrone S. Ossifying fibroma affecting the mandibular condyle: Report of an uncommon case. *The Journal of Craniofacial Surgery*. 2013;**24**(4):e351-e353
- [93] Myers BW, Masi AT. Pigmented villonodular synovitis and tenosynovitis: A clinical epidemiologic study of 166 cases and literature review. *Medicine*. 1980;**59**(3):223-238
- [94] Granowitz SP, D'Antonio J, Mankin HL. The pathogenesis and long-term end results of pigmented villonodular synovitis. *Clinical Orthopaedics and Related Research*. 1976;**114**:335-351
- [95] Oehler S, Fassbender HG, Neureiter D, Meyer-Scholten C, Kirchner T, Aigner T. Cell populations involved in pigmented villonodular synovitis of the knee. *The Journal of Rheumatology*. 2000;**27**(2):463-470
- [96] Choong PF, Willen H, Nilbert M, Mertens F, Mandahl N, Carlen B, et al. Pigmented villonodular synovitis. Monoclonality and metastasis – A case for neoplastic origin? *Acta Orthopaedica Scandinavica*. 1995;**66**(1):64-68
- [97] Vandeweyer E, Somerhausen ND, Andry G. Guess what! clinical course of the patient and histological findings. *European Journal of Dermatology: EJD*. 2000;**10**(8):639-640
- [98] Joshi K, Huang B, Scanga L, Buchman C, Chera BS. Postoperative radiotherapy for diffuse pigmented villonodular synovitis of the temporomandibular joint. *American Journal of Otolaryngology*. 2015;**36**(1):106-113
- [99] Vogrincic GS, O'Connell JX, Gilks CB. Giant cell tumor of tendon sheath is a polyclonal cellular proliferation. *Human Pathology*. 1997;**28**(7):815-819
- [100] Cavaliere A, Sidoni A, Bucciarelli E. Giant cell tumor of tendon sheath: Immunohistochemical study of 20 cases. *Tumori*. 1997;**83**(5):841-846
- [101] Carlson ML, Osetinsky LM, Alon EE, Inwards CY, Lane JI, Moore EJ. Tenosynovial giant cell tumors of the temporomandibular joint and lateral skull base: Review of 11 cases. *The Laryngoscope*. 2017;**127**(10):2340-2346
- [102] Somerhausen NS, Fletcher CD. Diffuse-type giant cell tumor: Clinicopathologic and immunohistochemical analysis of 50 cases with extraarticular disease. *The American Journal of Surgical Pathology*. 2000;**24**(4):479-492

- [103] Kisnisci RS, Tuz HH, Gunhan O, Onder E. Villonodular synovitis of the temporomandibular joint: Case report. *Journal of Oral and Maxillofacial Surgery: Official Journal of the American Association of Oral and Maxillofacial Surgeons*. 2001;**59**(12):1482-1484
- [104] Safaee M, Oh T, Sun MZ, Parsa AT, McDermott MW, El-Sayed IH, et al. Pigmented villonodular synovitis of the temporomandibular joint with intracranial extension: A case series and systematic review. *Head & Neck*. 2015;**37**(8):1213-1224
- [105] Le WJ, Li MH, Yu Q, Shi HM. Pigmented villonodular synovitis of the temporomandibular joint: CT imaging findings. *Clinical Imaging*. 2014;**38**(1):6-10
- [106] Kim KW, Han MH, Park SW, Kim SH, Lee HJ, Jae HJ, et al. Pigmented villonodular synovitis of the temporomandibular joint: MR findings in four cases. *European Journal of Radiology*. 2004;**49**(3):229-234
- [107] Stojadinovic S, Reinert S, Wildforster U, Jundt G. Destruction of the glenoid joint fossa by a tenosynovial giant-cell tumour of the skull base: A case report. *International Journal of Oral and Maxillofacial Surgery*. 1999;**28**(2):132-134
- [108] Rustin MH, Robinson TW. Giant-cell tumour of the tendon sheath – An uncommon tumour presenting to dermatologists. *Clinical and Experimental Dermatology*. 1989;**14**(6):466-468
- [109] Damodar D, Chan N, Kokot N. Pigmented villonodular synovitis of the temporomandibular joint: Case report and review of the literature. *Head & Neck*. 2015;**37**(12):E194-E199
- [110] Carlson ML, Osetinsky LM, Alon EE, Inwards CY, Lane JJ, Moore EJ. Tenosynovial giant cell tumors of the temporomandibular joint and lateral skull base: Review of 11 cases. *The Laryngoscope*. 2016
- [111] Ye ZX, Yang C, Chen MJ, Wilson JJ. Juxta-articular Myxoma of the temporomandibular joint. *The Journal of Craniofacial Surgery*. 2015;**26**(8):e695-e696
- [112] Allen PW. Myxoma is not a single entity: A review of the concept of myxoma. *Annals of Diagnostic Pathology*. 2000;**4**(2):99-123
- [113] Somford MP, de Vries JS, Dingemans W, de Jonge M, Maas M, Schaap GR, et al. Juxta-articular myxoma of the knee. *The Journal of Knee Surgery*. 2011;**24**(4):299-301
- [114] Korver RJ, Theunissen PH, van de Kreeke WT, van der Linde MJ, Heyligers IC. Juxta-articular myxoma of the knee in a 5-year-old boy: A case report and review of the literature (2009: 12b). *European Radiology*. 2010;**20**(3):764-768
- [115] Tse JJ, Vander S. The soft tissue myxoma of the head and neck region – Report of a case and literature review. *Head & Neck Surgery*. 1985;**7**(6):479-483
- [116] Mansour OI, Carrau RL, Snyderman CH, Kassam AB. Preauricular infratemporal fossa surgical approach: Modifications of the technique and surgical indications. *Skull Base: Official Journal of North American Skull Base Society*. 2004;**14**(3):143-151 discussion 51

