

We are IntechOpen, the world's leading publisher of Open Access books Built by scientists, for scientists

6,900

Open access books available

186,000

International authors and editors

200M

Downloads

Our authors are among the

154

Countries delivered to

TOP 1%

most cited scientists

12.2%

Contributors from top 500 universities



WEB OF SCIENCE™

Selection of our books indexed in the Book Citation Index
in Web of Science™ Core Collection (BKCI)

Interested in publishing with us?
Contact book.department@intechopen.com

Numbers displayed above are based on latest data collected.
For more information visit www.intechopen.com



Prognostic Impact of Perirenal Fat or Adrenal Gland Involvement in Renal Cell Carcinoma Exhibiting Venous Vascular Extension

Tetsuo Fujita, Masatsugu Iwamura, Shinji Kurosaka,
Ken-ichi Tabata, Kazumasa Matsumoto, Kazunari Yoshida and Shiro Baba
*Department of Urology, Kitasato University School of Medicine
Japan*

1. Introduction

Venous vascular extension is one of the aggressive tumor behaviors especially for renal cell carcinoma (RCC). It has been reported that 4% to 10% have tumor thrombus extending into the venous system among patients with newly diagnosed RCC (Marshall et al., 1970; Hoehn & Hermanek, 1983; Casanova & Zingg, 1991; Hatcher et al., 1991; Pagano et al., 1992). Compared with conservative treatment regimens, surgical resection remains the most effective treatment for these patients (Staehler & Brkovic, 2000). The mean 5-year survival rates of such patients with inferior vena cava involvement undergoing radical surgery for RCC have been reported as 32% to 64% (Neves & Zincke, 1987; Skinner et al., 1989; Montie et al., 1991; Swierzewski et al., 1994; Glazer & Novick, 1996).

Since the introduction of the tumor, node, metastasis (TNM) staging system, the pathologic stage has been considered the most important prognostic factor in RCC. According to the 2002 American Joint Committee on Cancer (AJCC) TNM staging classification (Greene et al., 2002), pT3 RCCs are subclassified into tumors invading perirenal fat and/or the ipsilateral adrenal gland (2002-pT3a), those presenting with tumor thrombus within the renal vein or the vena cava below the diaphragm (2002-pT3b) and those with vena cava thrombus above the diaphragm (2002-pT3c). This classification was very recently modified in 2009 (Edge et al., 2009), modified subclassification of pT3 RCCs are defined as tumors grossly extending into the renal vein or its segmental branches, or tumors invading perirenal and/or renal sinus fat but not beyond Gerota's fascia (2009-pT3a), those presenting with tumor thrombus within the vena cava below the diaphragm (2009-pT3b) and those with vena cava thrombus above the diaphragm or invaded the wall of the vena cava (2009-pT3c).

It has been debated that the TNM classification needs improvement in order to provide prognostic accuracy (Thompson et al., 2005; Leibovich et al., 2005; Ficarra et al., 2007). Several studies have discussed the correlation between prognosis and level of venous extension (Hatcher et al., 1991; Ljungberg et al., 1995; Tongaonkar et al., 1995; Glazer & Novick, 1996; Kuczyk et al., 1997; Staehler & Brkovic, 2000; Kim et al., 2004; Moinzadeh & Libertino, 2004). However, the prognostic impact of perirenal fat or adrenal gland involvement - based on the tumor characteristics of 2002 AJCC TNM staging classification

2002	2009
T1: Tumor 7 cm or less in greatest dimension, limited to the kidney	T1: Tumor 7 cm or less in greatest dimension, limited to the kidney
T1a: Tumor 4 cm or less in greatest dimension, limited to the kidney	T1a: Tumor 4 cm or less in greatest dimension, limited to the kidney
T1b: Tumor more than 4 cm but not more than 7 cm in greatest dimension, limited to the kidney	T1b: Tumor more than 4 cm but not more than 7 cm in greatest dimension, limited to the kidney
T2: Tumor more than 7 cm in greatest dimension, limited to the kidney	T2: Tumor more than 7 cm in greatest dimension, limited to the kidney
	T2a: Tumor more than 7 cm but less than or equal to 10 cm in greatest dimension, limited to the kidney
	T2b: Tumor more than 10 cm, limited to the kidney
T3: Tumor extends into major veins or invades adrenal gland or perinephric tissues but not beyond Gerota's fascia	T3: Tumor extends into major veins or perinephric tissues but not into the ipsilateral adrenal gland and not beyond Gerota's fascia
T3a: Tumor directly invades adrenal gland or perirenal and/or renal sinus fat but not beyond Gerota's fascia	T3a: Tumor grossly extends into the renal vein or its segmental (muscle containing) branches, or tumor invades perirenal and/or renal sinus fat but not beyond Gerota's fascia
T3b: Tumor grossly extends into the renal vein or its segmental (muscle-containing) branches, or vena cava below the diaphragm	T3b: Tumor grossly extends into the vena cava below the diaphragm
T3c: Tumor grossly extends into the vena cava above the diaphragm or invades the wall of the vena cava	T3c: Tumor grossly extends into the vena cava above the diaphragm or invades the wall of the vena cava
T4: Tumor invades beyond Gerota's fascia	T4: Tumor invades beyond Gerota's fascia (including contiguous extension into the ipsilateral adrenal gland)

Table 1. AJCC primary tumor staging classification of RCC

(2002-pT3a) – has not been seriously examined in patients with RCC exhibiting venous vascular extension. We hypothesized that RCC exhibiting venous vascular extension represents passive invasive features, since the low blood pressure in the renal vein allows tumors to easily extend into the venous system without aggressive characteristics, while perirenal fat or adrenal gland involvement represents active invasive features. Thus in this chapter, we describe the prognostic impact of perirenal fat or adrenal gland involvement in

patients with RCC exhibiting venous vascular extension and the proposal for reclassification of the current TNM staging.

2. RCC exhibiting venous vascular extension

Forty-three patients with RCC exhibiting venous vascular extension entirely below the diaphragm were evaluated. Patients were treated by radical nephrectomy with complete resection of tumor thrombus extending into the venous system. Venous extension was defined as gross involvement. The patients included 35 males and 8 females, with median age at surgery of 62 years (range 43-82 years). The median tumor size was 8.79 cm (range 2.3-17.0 cm). The tumor site was on the right in 20 cases and on the left in 23 cases.

All patients received a preoperative evaluation that included routine blood test, chest x-rays, ultrasonography, and computerized tomography (CT), magnetic resonance imaging, or both. They then underwent radical nephrectomy with complete resection of the tumor and thrombus. Regional lymphadenectomy was performed concurrently with the radical nephrectomy. Postoperative evaluations, performed at intervals of 1 to 3 months, included blood test, chest x-rays, and CT. Bone scans were obtained when indicated. Hospital charts were retrospectively reviewed, and patient status was ascertained via office visit or telephone call to the patient.

All histological samples were reviewed by a single pathologist and were defined as tumor thrombus only or as tumor thrombus with perirenal fat or adrenal gland involvement.

Nonparametric estimates of survival were performed using Kaplan-Meier curves. Survival curves were generated based on disease-specific survival, representing patients still alive at specified intervals from the time of surgery to the date of death or the last follow-up visit. Log-rank tests were used for statistical comparisons.

Differences in identified prognostic parameters between tumor thrombus only and tumor thrombus with perirenal fat or adrenal gland involvement were analyzed using *t* test and chi-square test. Survival analysis regression model was assessed by Cox proportional hazards model to estimate the relative importance of the variables.

Additionally, nonparametric Kaplan-Meier survival estimates were performed to compare perirenal fat or adrenal gland involvement only (2002-pT3a), tumor thrombus only, and tumor thrombus with perirenal fat or adrenal gland involvement. The perirenal fat or adrenal gland involvement only (2002-pT3a) cohort represented 65 cases with complete resection of the tumor. Survival curves and log-rank tests were analyzed.

3. Prognostic impact of perirenal fat or adrenal gland involvement

3.1 Patient characteristics

The tumor thrombus only cohort included 21 males and 2 females (total 23 patients; 53.5%) with a median age of 61 years (range 44-78 years) and median follow-up period of 37 months (range 2-106 months). The median tumor size was 9.0 cm (range 2.3-17.0 cm); tumor site was on the right in 10 cases and on the left in 13 cases.

The tumor thrombus with perirenal fat or adrenal gland involvement cohort included 14 males and 6 females (total 20 patients; 46.5%) with a median age of 64 years (range 43-82

years) and median follow-up period of 9.5 months (range 2-45 months). The median tumor size was 8.45 cm (range 4.0-16.0 cm); tumor site was on the right in 10 cases and on the left in 10 cases.

When several parameters were analyzed for differences between tumor thrombus only cohort and tumor thrombus with perirenal fat or adrenal gland involvement cohort using *t* test or chi-square test, two parameters - Eastern Cooperative Oncology Group (ECOG) performance status (PS) 0 and histological grade 3 - proved statistically significant ($P = 0.0329$ and 0.0377 , respectively; chi-square test).

Characteristic	Tumor thrombus only	Tumor thrombus with perirenal fat or adrenal gland involvement	P Value
Patients (<i>n</i>)	23	20	–
Follow-up period (month)			
Median	37	9.5	–
Range	2-106	2-45	–
Age § (year)			
Median	61	64	–
Range	44-78	43-82	–
Mean ± SE	60.1 ± 1.9	64.3 ± 2.3	0.1673
Gender (<i>n</i>)			
Male	21	14	0.1180
Female	2	6	
Tumor diameter § (cm)			
Median	9.0	8.45	–
Range	2.3-17.0	4.0-16.0	–
Mean ± SE	9.0 ± 0.9	8.3 ± 0.8	0.5240
Tumor site (<i>n</i>)			
Right	10	10	–
Left	13	10	–
ECOG PS 0 * (<i>n</i>)	15	6	0.0329
Initial symptom (<i>n</i>)	21	16	0.3929
Preoperative metastasis (<i>n</i>)	5	8	0.3184
Grade 3 * (<i>n</i>)	1	6	0.0377
pN (<i>n</i>)	1	5	0.0814
Clear cell (<i>n</i>)	21	14	0.1180
Spindle cell (<i>n</i>)	0	3	0.0924

KEY: ECOG PS = Eastern Cooperative Oncology Group performance status.

§ Analysis assessed by *t* test.

* Statistically significant.

Table 2. Patient characteristics and comparison among groups

3.2 Kaplan-Meier survival analysis

Nonparametric survival was analyzed by Kaplan-Meier survival curves, plotting both tumor thrombus only and tumor thrombus with perirenal fat or adrenal gland involvement.

Mean disease-specific survival time for patients with tumor thrombus with perirenal fat or adrenal gland involvement was 25.0 ± 4.4 (SE) months. On the other hand, mean survival time for those with tumor thrombus only was significantly longer at 70.9 ± 9.1 (SE) months ($P = 0.0032$, Fig. 1).

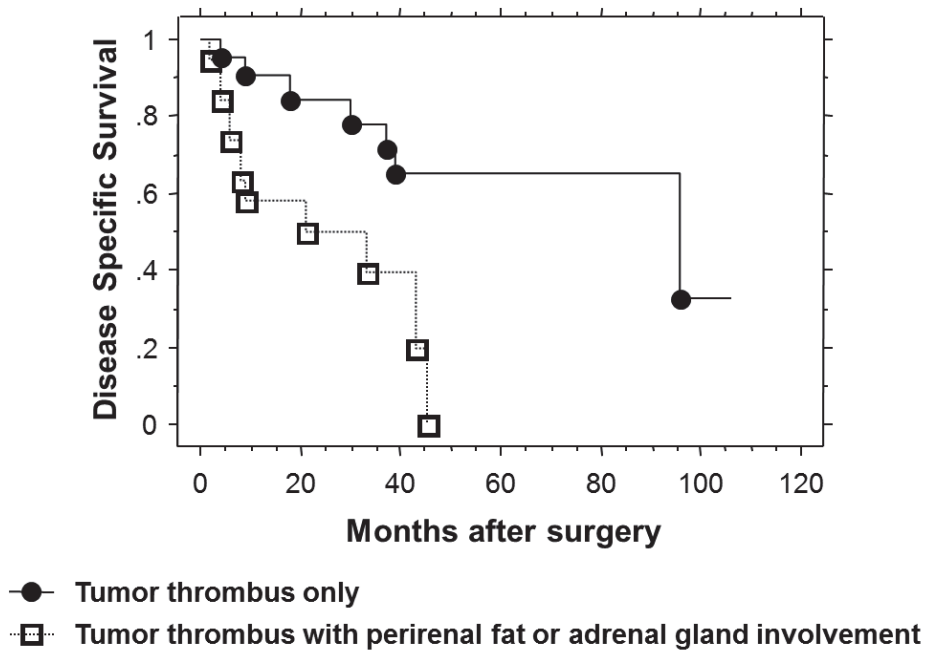


Fig. 1. Kaplan-Meier disease-specific survival after nephrectomy

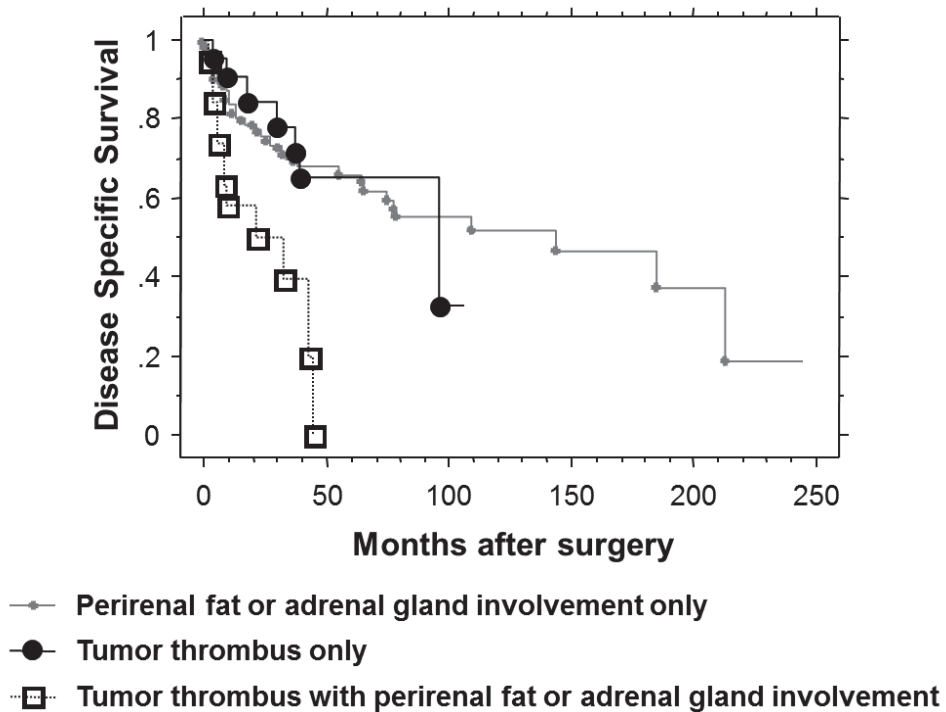


Fig. 2. Kaplan-Meier disease-specific survival after nephrectomy for those with perirenal fat or adrenal gland involvement only (2002-pT3a)

Mean disease-specific survival time for patients with perirenal fat or adrenal gland involvement only (2002-pT3a) was longer still at 116.1 ± 12.3 (SE) months. This value is significantly longer than for those with tumor thrombus with perirenal fat or adrenal gland involvement ($P = 0.0044$, Fig. 2), but not statistically significant different from that for those with tumor thrombus only.

3.3 Cox proportional hazards regression analysis

Univariate Cox proportional hazards regression analysis was performed for each variable. Significantly shorter disease-specific survival after surgery was predicted by presence of perirenal fat or adrenal gland involvement ($P = 0.0065$), preoperative metastasis ($P = 0.0025$), surgical specimens positive for lymph node metastasis ($P = 0.0183$), and spindle cell factor ($P = 0.0233$).

Variable	Hazard Ratio	95% CI	P Value
Perirenal fat or adrenal gland involvement *	4.11	1.49–11.4	0.0065
ECOG PS 0	1.34	0.54–3.34	0.5303
Initial symptom	2.13	0.28–16.2	0.4639
Preoperative metastasis *	4.32	1.68–11.2	0.0025
Tumor diameter	1.03	0.90–1.17	0.6984
Grade 3	0.34	0.11–1.11	0.0732
pN *	0.30	0.11–0.81	0.0183
Clear cell	1.76	0.57–5.39	0.3248
Spindle cell *	0.16	0.03–0.78	0.0233

KEY: CI = confidence interval; ECOG PS = Eastern Cooperative Oncology Group performance status.

* Statistically significant.

Table 3. Univariate analysis by Cox proportional hazards model

4. Prognostic factors for RCC exhibiting venous vascular extension

Although the pathologic stage highly correlates with outcome in patients with RCC, the prognosis may vary even among tumors of the same stage. Thus, additional prognostic factors are needed. For RCCs exhibiting venous vascular extension, several investigators have described the prognostic significance of the level of venous extension (Hatcher et al., 1991; Ljungberg et al., 1995; Tongaonkar et al., 1995; Glazer & Novick, 1996; Kuczyk et al., 1997; Staehler & Brkovic, 2000). Most recent series have reported that the level of tumor thrombosis in the inferior vena cava does not significantly effect long-term survival (Kim et al., 2004; Moinzadeh & Libertino, 2004). Local tumor stage and grade are better predictors of prognosis than extent of venous involvement (Kim et al., 2004), but the most significant factors for survival in patients with RCC exhibiting venous vascular extension are still unknown.

The impact of perirenal fat or adrenal gland involvement in patients with RCC exhibiting venous vascular extension has not been seriously examined. Only the impact of perirenal fat involvement on prognosis of RCC patients has been documented (Gettman et al., 2003). On

multivariate analyses, perirenal fat involvement led to a significantly worse prognosis, as did histological grade and metastasis (Gettman et al., 2003). However, perirenal fat involvement cannot be simply categorized, given the data we present here for the category of tumor thrombus with perirenal fat or adrenal gland involvement. This is the first investigation to specifically examine RCCs exhibiting tumor thrombus with perirenal fat or adrenal gland involvement and suggest that they represent a separate subcategory.

Tumor thrombus with perirenal fat or adrenal gland involvement has shorter disease-specific survival time than tumor thrombus only, or perirenal fat or adrenal gland involvement only (2002-pT3a). Tumors that are both tumor thrombus and perirenal fat or adrenal gland involvement are not the same as those that are only tumor thrombus. If patients with tumor thrombus also have perirenal fat or adrenal gland involvement, the prognosis is significantly poorer. The 5-year disease-specific survival estimate for tumor thrombus only was 65%, while that for tumor thrombus with perirenal fat or adrenal gland involvement was 0%. On univariate analyses, perirenal fat or adrenal gland involvement, preoperative metastasis, positive lymph node metastasis, and spindle cell factor were significant predictors of poor prognosis. Metastatic disease has been reported as an adverse predictor of disease-specific survival by several investigators (Neves & Zincke, 1987; Hatcher et al., 1991; Swierzewski et al., 1994; Tongaonkar et al., 1995; Nesbitt et al., 1997; Gettman et al., 2003). Generally, histological grade is identified as an independent prognostic factor in all RCCs (Méjean et al., 2003), but our results suggest histological grade does not affect survival in patients specifically having RCCs exhibiting tumor thrombus with perirenal fat or adrenal gland involvement.

5. Adrenal gland involvement in RCC

Patients with adrenal gland involvement have significantly worse survival than those with perirenal fat involvement (Han et al., 2003; Siemer et al., 2005). Direct ipsilateral adrenal gland involvement in RCC is rare, found in only 2.5% of radical nephrectomy specimens, and representing 13% of all 2002-pT3a lesions (Han et al., 2003). In this study, there were too few patients with RCCs exhibiting tumor thrombus with perirenal fat or adrenal gland involvement to allow a comparison of survival for patients with adrenal gland or perirenal fat involvement. However, previous investigators have emphasized that adrenal gland involvement should be reclassified because of the worse prognosis (Han et al., 2003; Siemer et al., 2005; Fujita et al., 2008). According to the 2002 AJCC TNM staging classification (Greene et al., 2002), pT4 RCC is defined as tumor invades beyond Gerota's fascia. The median disease-specific survival for patients with ipsilateral adrenal gland involvement was significantly worse than that for tumor infiltrating only the perirenal fat and was similar to that for patients with 2002-pT4 RCCs (Han et al., 2003). The 5-year disease-specific survival probabilities have been reported 20.2% (Thompson et al., 2005) and 0% (Fujita et al., 2008). Primary adrenal carcinoma that invades the kidney is classified as pT4 disease (Ng & Libertino, 2003; Norton et al., 2005). A number of previous reports have suggested that, analogously, RCC with adrenal gland involvement should be reclassified as 2002-pT4 (Sandock et al., 1997; Han et al., 2003; Siemer et al., 2005; Thompson et al., 2005). Based on these investigations, adrenal gland involvement has been classified pT4 in 2009 AJCC TNM staging classification (Edge et al., 2009).

6. Proposal for reclassification of the TNM staging

According to a commentary by the Union Internationale Contre le Cancer (UICC) regarding continuous improvement of the TNM classification, the criteria for instituting changes include clinical relevance for assessment, treatment and outcome, presence of evidence for improved prognostic ability, and acceptance by the members of the UICC TNM committee (Gospodarowicz et al., 2004). The 2002 AJCC TNM system for patients with pT3 RCC incorporates the features of tumor thrombus, perirenal fat invasion and direct ipsilateral adrenal gland involvement (Greene et al., 2002). Several studies addressing 2002-pT3 staging have been reported and debated (Thompson et al., 2005; Leibovich et al., 2005; Ficarra et al., 2007; Fujita et al., 2008). And very recently, AJCC TNM staging classification was updated (Edge et al., 2009). However, tumor thrombus with perirenal fat or adrenal gland involvement was not well included in this modification. The prognosis of patients with tumor thrombus with perirenal fat or adrenal gland involvement was poor, as well as adrenal gland involvement which was subclassified as pT4 in 2009 AJCC TNM classification (Fujita et al., 2008; Edge et al., 2009). Reclassification will be still needed for tumor thrombus with perirenal fat or adrenal gland involvement RCCs. Reclassification of the current TNM staging system for RCCs according to the available clinical data and in accordance with the proposed process to update the staging system will render it a more powerful tool for predicting patient outcomes (Ficarra et al., 2006). The resultant staging system should be intended to give prognostic information that will allow accurate patient counseling, therapeutic selection, and surveillance (Howard & Wood, 2006). Our suggested revisions to the TNM classification represent a significant improvement in its prognostic accuracy.

7. Conclusion

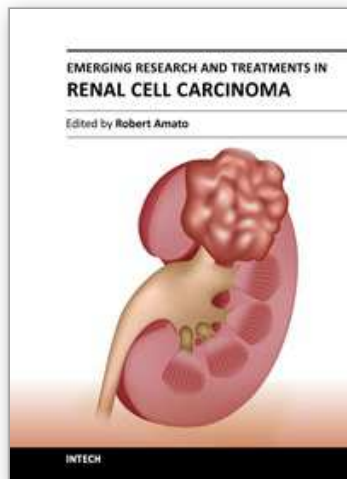
The presence of perirenal fat or adrenal gland involvement in patients with RCC exhibiting venous vascular extension entirely below the diaphragm leads to a significantly poorer prognosis. Presence of perirenal fat or adrenal gland involvement is important for such cases and calls for active investigation. Additionally, reclassification will be needed for tumor thrombus with perirenal fat or adrenal gland involvement RCCs.

8. References

- Casanova, G.A. & Zingg, E.J. (1991). Inferior Vena Caval Tumor Extension in Renal Cell Carcinoma. *Urologia Internationalis*, Vol.47, No.4, (no date), pp. 216-218, ISSN 0042-1138
- Edge, S.B., Byrd, D.R., Compton, C.C., Fritz, A.G., Greene, F.L. & Trotti, A., III. (2009). *AJCC Cancer Staging Manual* (7th ed.), Springer, ISBN 978-0-387-88440-0, New York, United States of America
- Ficarra, V. & Artibani, W. (2006). Staging System of Renal Cell Carcinoma: Current Issues. *European Urology*, Vol.49, No.2, (February 2006), pp. 223-225, ISSN 0302-2838
- Ficarra, V., Novara, G., Iafrate, M., Cappellaro, L., Bratti, E., Zattoni, F. & Artibani, W. (2007). Proposal for Reclassification of the TNM Staging System in Patients with Locally Advanced (pT3-4) Renal Cell Carcinoma According to the Cancer-Related Outcome. *European Urology*, Vol.51, No.3, (May 2007), pp. 722-731, ISSN 0302-2838
- Fujita, T., Iwamura, M., Yanagisawa, N., Muramoto, M., Okayasu, I. & Baba, S. (2008). Reclassification of the Current Tumor, Node, Metastasis Staging in pT3 Renal Cell Carcinoma. *International Journal of Urology*, Vol.15, No.7, (July 2008), pp. 582-586, ISSN 1442-2042

- Gettman, M.T., Boelter, C.W., Cheville, J.C., Zincke, H., Bryant, S.C. & Blute, M.L. (2003). Charlson Co-Morbidity Index as a Predictor of Outcome after Surgery for Renal Cell Carcinoma with Renal Vein, Vena Cava or Right Atrium Extension. *Journal of Urology*, Vol.169, No.4, (April 2003), pp. 1282-1286, ISSN 0022-5347
- Glazer, A.A. & Novick, A.C. (1996). Long-term Followup after Surgical Treatment for Renal Cell Carcinoma Extending into the Right Atrium. *Journal of Urology*, Vol.155, No.2, (February 1996), pp. 448-450, ISSN 0022-5347
- Gospodarowicz, M.K., Miller, D., Groome, P.A., Greene, F.L., Logan, P.A. & Sobin, L.H. (2004). The Process for Continuous Improvement of the TNM Classification. *Cancer*, Vol.100, No.1, (January 2004), pp. 1-5, ISSN 1097-0142
- Greene, F.L., Page, D.L., Fleming, I.D., Fritz, A.G., Balch, C.M., Haller, D.G. & Morrow M. (2002). *AJCC Cancer Staging Manual* (6th ed.), Springer-Verlag, ISBN 978-0-387-95271-0, New York, United States of America
- Han, K.R., Bui, M.H., Pantuck, A.J., Freitas, D.G., Leibovich, B.C., Dorey, F.J., Zisman, A., Janzen, N.K., Mukoyama, H., Figlin, R.A. & Belldegrun, A.S. (2003). TNM T3a Renal Cell Carcinoma: Adrenal Gland Involvement is not the Same as Renal Fat Invasion. *Journal of Urology*, Vol.169, No3, (March 2003), pp. 899-904, ISSN 0022-5347
- Hatcher, P.A., Anderson, E.E., Paulson, D.F., Carson, C.C. & Robertson, J.E. (1991). Surgical Management and Prognosis of Renal Cell Carcinoma Invading the Vena Cava. *Journal of Urology*, Vol.145, No.1, (January 1991), pp. 20-24, ISSN 0022-5347
- Hoehn, W. & Hermanek, P. (1983). Invasion of Veins in Renal Cell Carcinoma-Frequency, Correlation and Prognosis. *European Urology*, Vol.9, No.5, (no date), pp. 276-280, ISSN 0302-2838
- Howard, G.E. & Wood, C.G. (2006). Staging Refinements in Renal Cell Carcinoma. *Current Opinion in Urology*, Vol.16, No.5, (September 2006), pp. 317-320, ISSN 0963-0643
- Kim, H.L., Zisman, A., Han, K.R., Figlin, R.A. & Belldegrun, A.S. (2004). Prognostic Significance of Venous Thrombus in Renal Cell Carcinoma. Are Renal Vein and Inferior Vena Cava Involvement Different? *Journal of Urology*, Vol.171, No.2 pt 1, (February 2004), pp. 588-591, ISSN 0022-5347
- Kuczyk, M.A., Bokemeyer, C., Köhn, G., Stief, C.G., Machtens, S., Truss, M., Höfner, K. & Jonas, U. (1997). Prognostic Relevance of Intracaval Neoplastic Extension for Patients with Renal Cell Cancer. *British Journal of Urology*, Vol.80, No.1, (July 1997), pp. 18-24, ISSN 0007-1331
- Leibovich, B.C., Cheville, J.C., Lohse, C.M., Zincke, H., Kwon, E.D., Frank, I., Thompson, R.H. & Blute, M.L. (2005). Cancer Specific Survival for Patients with pT3 Renal Cell Carcinoma—Can the 2002 Primary Tumor Classification be Improved? *Journal of Urology*, Vol.173, No.3, (March 2005), pp. 716-719, ISSN 0022-5347
- Ljungberg, B., Stenling, R., Österdahl, B., Farrelly, E., Åberg T. & Roos G. (1995). Vein Invasion in Renal Cell Carcinoma: Impact on Metastatic Behavior and Survival. *Journal of Urology*, Vol.154, No.5, (November 1995), pp. 1681-1684, ISSN 0022-5347
- Marshall, V.F., Middleton, R.G., Holswade, G.R. & Goldsmith, E.I. (1970). Surgery for Renal Cell Carcinoma in the Vena Cava. *Journal of Urology*, Vol.103, No.4, (April 1970), pp. 414-420, ISSN 0022-5347
- Méjean, A., Oudard, S. & Thiounn, N. (2003). Prognostic Factors of Renal Cell Carcinoma. *Journal of Urology*, Vol.169, No.3, (March 2003), pp. 821-827, ISSN 0022-5347
- Moinzadeh, A. & Libertino, J.A. (2004). Prognostic Significance of Tumor Thrombus Level in Patients with Renal Cell Carcinoma and Venous Tumor Thrombus Extension. Is All T3b the Same? *Journal of Urology*, Vol.171, No.2 pt 1, (February 2004), pp. 598-601, ISSN 0022-5347

- Montie, J.E., el Ammar, R., Pontes, J.E., Medendorp, S.V., Novick, A.C., Strem, S.B., Kay, R., Montague, D.K. & Cosgrove D.M. (1991). Renal Cell Carcinoma with Inferior Vena Cava Tumor Thrombi. *Surgery, Gynecology and Obstetrics*, Vol.173, No.2, (August 1991), pp. 107-115, ISSN 0039-6087
- Nesbitt, J.C., Soltero, E.R., Dinney, C.P., Walsh, G.L., Schrupp, D.S., Swanson, D.A., Pisters, L.L., Willis, K.D. & Putnam, J.B., Jr. (1997). Surgical Management of Renal Cell Carcinoma with Inferior Vena Cava Tumor Thrombus. *Annals of Thoracic Surgery*, Vol.63, No.6, (June 1997), pp. 1592-1600, ISSN 0003-4975
- Neves, R.J. & Zincke, H. (1987). Surgical Treatment of Renal Cancer with Vena Cava Extension. *British Journal of Urology*, Vol.59, No.5, (May 1987), pp. 390-395, ISSN 0007-1331
- Ng, L. & Libertino, J.M. (2003). Adrenocortical Carcinoma: Diagnosis, Evaluation and Treatment. *Journal of Urology*, Vol.169, No.1, (January 2003), pp. 5-11, ISSN 0022-5347
- Norton, J.A. (2005). Adrenal tumors, In: *Cancer: Principles and Practice of Oncology* (7th ed.), DeVita, V.T. Jr., Hellman, S., Rosenberg, S.A. (eds.), pp. 1528-1540, Lippincott Williams & Wilkins, ISBN 0-781-74450-4, Philadelphia, United States of America
- Pagano, F., Dal Bianco, M., Artibani, W., Pappagallo, G. & Prayer Galetti, T. (1992). Renal Cell Carcinoma with Extension into the Inferior Vena Cava: Problems in Diagnosis, Staging and Treatment. *European Urology*, Vol.22, No.3, (September 1992), pp. 200-203, ISSN 0302-2838
- Sandock, D.S., Seftel, A.D. & Resnick, M.I. (1997). Adrenal Metastases from Renal Cell Carcinoma: Role of Ipsilateral Adrenalectomy and Definition of Stage. *Urology*, Vol.49, No.1, (January 1997), pp. 28-31, ISSN 0090-4295
- Siemer, S., Lehmann, J., Loch, A., Becker, F., Stein, U., Schneider, G., Ziegler, M. & Stöckle, M. (2005). Current TNM Classification of Renal Cell Carcinoma Evaluated: Revising Stage T3a. *Journal of Urology*, Vol.173, No.1, (January 2005), pp. 33-37, ISSN 0022-5347
- Skinner, D.G., Pritchett, T.R., Lieskovsky, G., Boyd, S.D. & Stiles, Q.R. (1989). Vena Caval Involvement by Renal Cell Carcinoma. Surgical Resection Provides Meaningful Long-term Survival. *Annals of Surgery*, Vol.210, No.3, (September 1989), pp. 387-394, ISSN 0003-4932
- Staehler, G. & Brkovic, D. (2000). The Role of Radical Surgery for Renal Cell Carcinoma with Extension into the Vena Cava. *Journal of Urology*, Vol.163, No.6, (June 2000), pp. 1671-1675, ISSN 0022-5347
- Swierzewski, D.J., Swierzewski, M.J. & Libertino, J.A. (1994). Radical Nephrectomy in Patients with Renal Cell Carcinoma with Venous, Vena Caval, and Atrial Extension. *American Journal of Surgery*, Vol.168, No.2, (August 1994), pp. 205-209, ISSN 0002-9610
- Thompson, R.H., Cheville, J.C., Lohse, C.M., Webster, W.S., Zincke, H., Kwon, E.D., Frank, I., Blute, M.L. & Leibovich, B.C. (2005). Reclassification of Patients with pT3 and pT4 Renal Cell Carcinoma Improves Prognostic Accuracy. *Cancer*, Vol.104, No.1, (July 2005), pp 53-60, ISSN 1097-0142
- Thompson, R.H., Leibovich, B.C., Cheville, J.C., Lohse, C.M., Frank, I., Kwon, E.D., Zincke, H. & Blute, M.L. (2005). Should Direct Ipsilateral Adrenal Gland Invasion from Renal Cell Carcinoma be Classified as pT3a? *Journal of Urology*, Vol.173, No.3, (March 2005), pp. 918-921, ISSN 0022-5347
- Tongaonkar, H.B., Dandekar, N.P., Dalal, A.V., Kulkarni, J.N. & Kamat, M.R. (1995). Renal Cell Carcinoma Extending to the Renal Vein and Inferior Vena Cava: Results of Surgical Treatment and Prognostic Factors. *Journal of Surgical Oncology*, Vol.59, No.2, (June 1995), pp. 94-100, ISSN 0022-4790



Emerging Research and Treatments in Renal Cell Carcinoma

Edited by Dr. Robert Amato

ISBN 978-953-51-0022-5

Hard cover, 442 pages

Publisher InTech

Published online 03, February, 2012

Published in print edition February, 2012

The field of renal cell cancer has undergone a significant resurgence. This book summarizes up-to-date research and innovative ideas for the future in this rapidly changing field, which encompasses medicine, surgery, radiation oncology, basic science, pathology, radiology, and supportive care. This book is aimed at the clinician or scientist who has an interest in renal cell cancer, whether they are academic or nonacademic. The book covers tumor biology, molecular biology, surgery techniques, radiation therapy, personal testimonies, and present and future treatments of the disease that are on the horizon. The goal was to produce a textbook that would act as an authoritative source for scientists and clinicians and interpret the field for trainees in surgery, medicine, radiation oncology, and pathology.

How to reference

In order to correctly reference this scholarly work, feel free to copy and paste the following:

Tetsuo Fujita, Masatsugu Iwamura, Shinji Kurosaka, Ken-ichi Tabata, Kazumasa Matsumoto, Kazunari Yoshida and Shiro Baba (2012). Prognostic Impact of Perirenal Fat or Adrenal Gland Involvement in Renal Cell Carcinoma Exhibiting Venous Vascular Extension, *Emerging Research and Treatments in Renal Cell Carcinoma*, Dr. Robert Amato (Ed.), ISBN: 978-953-51-0022-5, InTech, Available from: <http://www.intechopen.com/books/emerging-research-and-treatments-in-renal-cell-carcinoma/prognostic-impact-of-perirenal-fat-or-adrenal-gland-involvement-in-renal-cell-carcinoma-exhibiting-v>

INTECH
open science | open minds

InTech Europe

University Campus STeP Ri
Slavka Krautzeka 83/A
51000 Rijeka, Croatia
Phone: +385 (51) 770 447
Fax: +385 (51) 686 166
www.intechopen.com

InTech China

Unit 405, Office Block, Hotel Equatorial Shanghai
No.65, Yan An Road (West), Shanghai, 200040, China
中国上海市延安西路65号上海国际贵都大饭店办公楼405单元
Phone: +86-21-62489820
Fax: +86-21-62489821

© 2012 The Author(s). Licensee IntechOpen. This is an open access article distributed under the terms of the [Creative Commons Attribution 3.0 License](#), which permits unrestricted use, distribution, and reproduction in any medium, provided the original work is properly cited.

IntechOpen

IntechOpen