

PUBLISHED BY

# INTECH

open science | open minds

World's largest Science,  
Technology & Medicine  
Open Access book publisher



**3,350+**  
OPEN ACCESS BOOKS



**108,000+**  
INTERNATIONAL  
AUTHORS AND EDITORS



**115+ MILLION**  
DOWNLOADS



**BOOKS**  
DELIVERED TO  
151 COUNTRIES

AUTHORS AMONG

**TOP 1%**  
MOST CITED SCIENTIST



**12.2%**  
AUTHORS AND EDITORS  
FROM TOP 500 UNIVERSITIES



Selection of our books indexed in the  
Book Citation Index in Web of Science™  
Core Collection (BKCI)

**WEB OF SCIENCE™**

Chapter from the book *Insights and Perspectives in Rheumatology*

Downloaded from: <http://www.intechopen.com/books/insights-and-perspectives-in-rheumatology>

Interested in publishing with IntechOpen?  
Contact us at [book.department@intechopen.com](mailto:book.department@intechopen.com)

# Diagnostic and Prognostic Features of Sjögren's Syndrome

Muhammad S. Soyfoo<sup>1</sup> and Elie Cogan<sup>2</sup>

<sup>1</sup>*Departments of Rheumatology*

<sup>2</sup>*Internal Medicine*

*Erasme Hospital, Université Libre de Bruxelles, Belgium*

## 1. Introduction

Sjögren's syndrome (SS) is a chronic autoimmune disease characterized by the lymphocytic infiltration of salivary and lacrimal glands leading to xerostomia and keratoconjunctivitis sicca (KCS). The prevalence of SS is variable but recent studies have estimated it to be between 0.1-0.6% (Goransson et al., 2011; Trontzas & Andrianakos, 2005). As such, SS occurs in middle-aged patients with a high female predominance of 9 to 1 (Fox, 2005). SS is classified either as primary (pSS) when occurring alone or secondary (sSS) to other autoimmune diseases such as rheumatoid arthritis or systemic lupus erythematosus. Besides the involvement of exocrine glands entailing the classical sicca syndrome, systemic manifestations resulting from the lymphocytic infiltration of organs can be present in up to 20% of cases. There are actually no specific diagnostic criteria for SS, but for clinical studies and teaching purposes, SS is classified according to the American-European classification criteria, which include subjective and objective criteria of xerostomia and KCS as well as the presence of autoimmune antibodies and histopathological salivary gland involvement. Because of the lack of a "gold standard" for SS, the standard of reference being actually used is clinical diagnosis made by an experienced clinician. The lack of specific diagnostic tests combined with the high frequency of sicca symptoms in the general population makes the diagnosis of SS even more complicated. This holds true especially in early disease where the symptoms and signs are usually mild and might explain the time delay for the diagnosis of SS. The importance of making the diagnosis of pSS is cardinal because of the increased risk of developing lymphoma and serious systemic complications. In an endeavor to increase the likelihood of diagnosis of SS, newer diagnostic tools have been devised such as ultrasound sonography of salivary glands, magnetic resonance imaging of parotid glands as well as epigenetic biomarkers.

## 2. Pathophysiology of Sjögren's syndrome

Even if tremendous progress in the field of research has been made to unveil the different mechanistic processes underlying the development of SS, the initial triggering events of the disease have yet to be unearthed. Central to the pathophysiology of SS is chronic perpetual stimulation of the autoimmune system. Both B and T cells are implicated in the pathogenesis of the SS, even though the mechanisms underlying humoral and cellular abnormalities are not yet known (Delaleu et al., 2008; Mariette & Gottenberg, 2010).

It is actually believed that a combination of several factors is responsible for triggering disease initiation and perpetuation. In genetically predisposed individuals, psychological or physical stress and hormonal factors can lead to the activation of epithelial cells and to the up regulation of toll-like receptors. Initiation of disease is promoted by altered glandular architecture such as extracellular matrix modification favoring infiltration by cytokines, chemokines and lymphocytes. Up regulation of toll-like receptors leads to T cell activation and ensuing secretion of pro-inflammatory cytokines. Furthermore, activated epithelial cells not only can act as antigen presenting cells leading to the activation of T and B cells, but also activate dendritic cells through up regulation of proapoptotic molecules harboring the formation of exosomes and thereby also further activating B cells. In advanced stages of the disease process, enhanced B-cell activating factor (BAFF) activation and secretion leads to disproportionate activation of B cells thereby favoring aberrant lymphocyte homing, increased glandular destruction, formation of germinal centers and ensuing lymphoma (Figure 1)(Manoussakis & Kapsogeorgou, 2010).

### 3. Clinical characteristics of SS

The most frequent symptoms of SS include the triad of fatigue, polyarthralgia and sicca symptoms. Because of the higher frequency of these symptoms in the general population, many patients are often diagnosed as having fibromyalgia.

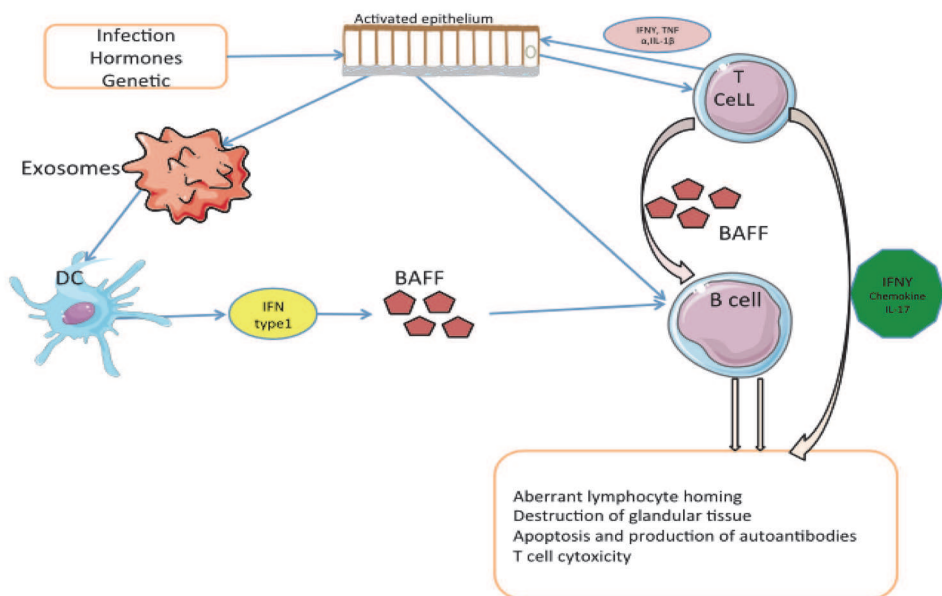


Fig. 1. Mechanisms underscoring the pathogenesis of SS. In the setting of appropriate genetic background, the conjuncture of viral aggression, hormones and environmental factors is thought to initiate epithelium activation which in turn, leads to T cell activation and hence pro-inflammatory cytokines secretion thereby further perpetuating activation of epithelial cells. This results in exosomes formation, dendritic cells (DC) activation and secretion of type I IFN and BAFF leading to B cell stimulation and proliferation, leading to

aberrant lymphocyte homing, T cell cytotoxicity, apoptosis and autoantibodies formation and further glandular destruction. BAFF: B-cell activating factor; Dc dendritic cells; IFN: interferon; IL-1 $\beta$ : interleukin-1 $\beta$ ; TNF- $\alpha$ : tumor necrosis factor  $\alpha$ .

The most prominent clinical feature of SS is the sicca syndrome of xerostomia and keratoconjunctivitis sicca (KCS) resulting from lymphocytic infiltration of salivary and lachrymal glands. The sicca syndrome is often extended to other organs and might result in skin dryness, vaginal dryness resulting in dyspareunia, and respiratory tract dryness.

### 3.1 Xerostomia

More than 90% of patients with SS complain of symptoms resulting from functional alteration of salivary glands. Patients often complain of unpleasant taste, difficulties in eating dry food, the need to drink more water or difficulties in controlling dentures. In the early stages of SS, the mouth may appear to be moist, but with disease progression, pooling of saliva in the floor of the mouth disappears, thereby unveiling the lines of contact between frothy saliva and oral soft tissue. With disease progression and especially in advanced stages of SS, the oral mucosa becomes extremely dry and tends to form wrinkles. The surface of the tongue becomes red and lobulated with partial or complete depapillation. The symptoms of xerostomia extend to a painful syndrome with the sensation of permanent burns, soreness, taste alteration, "clicking quality" in the speech of patients with SS, tongue fissuring, dysphagia and angular cheilitis. Gross accumulation of plaque might prevail. Infections by staphylococcus aureus or pneumococcus can result in acute sialadenitis. With further disease progression, teeth decay, periodontal infections, increased incidence of candidiasis infections and ultimately loss of teeth are possible complications (Fox, 2005, Kassin & Moutsopoulos, 2004).

### 3.2 Keratoconjunctivitis sicca

Ocular dryness in SS, also known as keratoconjunctivitis sicca (KCS), is often less prominent than xerostomia. A detailed anamnestic investigation is necessary to detect ocular dryness symptoms. The main complaint of KCS is foreign-body sensation, but other symptoms such as grittiness, thick rope like secretions at the inner canthus, photosensitivity, burns, and sensation of having a veil before the eyes, absence of tears after irritation or emotion are all frequent features of KCS. Ocular dryness is due to the lymphocytic infiltration of lacrimal glands leading to diminished lacrimal flow and tear composition, thereby altering corneal and conjunctival epithelia, characterizing the known condition of keratoconjunctivitis sicca (KCS). In more severe disease, functional disability with visual impairment occurs. Complications of KCS include corneal ulcerations that can lead to perforations and iridocyclitis (Fox, 2005).

### 3.3 Systemic manifestations

#### 3.3.1 Musculoskeletal manifestations

Approximately 70% of patients with SS complain of articular manifestations. The main articular features are predominantly arthralgia while arthritis is less frequent (Fauchais et al., 2010). Polyarthralgia is relapsing and remitting. Symmetric, non-erosive, polyarthrit

affecting the small joints can also be observed and can even precede the sicca syndrome. The frequency of arthritis in SS has been shown to be nearing 17%. More recently, it has been observed that subclinical synovitis might be more important with the use of ultrasonography and that the frequency of arthritis is around 25% (Iagnocco et al., 2010).

Myalgias are also a frequent feature, accompanied with asthenia, fatigue and muscle tenderness, realizing a fibromyalgia-like syndrome (Mavragani & Moutsopoulos, 2010).

### 3.3.2 Respiratory manifestations

Diminished secretion from nasal epithelial cells results in nasal crusting, epistaxis and recurrent sinusitis. Due to xerotrachea, patients complain of a dry non-productive cough and dyspnea. In more than 50% of SS patients, dry irritating cough was present without any radiographic abnormalities. Bronchial hyperreactivity due to lymphocytic infiltration might result in small airways obstruction and contribute to the development of cysts and bullae (Parke, 2008).

Interstitial lung disease (ILD) is a classic feature of SS. The clinical manifestations include cough, dyspnea on exertion, bilateral pulmonary infiltrates on plain chest radiographs and other abnormalities on computer tomography scanner such as wall thickening at the segmental bronchi. With disease progression, fibrosis and neutrophilic alveolitis are present (Parambil et al., 2006).

Lymphocytic interstitial pneumonia (LIP), previously considered as a hallmark of lung involvement for SS, forms part of the spectrum of ILD. As such, LIP is the corollary of bronchus associated lymphoid tissue proliferation (BALT). LIP is found in approximately 1% of patients who have SS. Even if LIP is steroid- responsive, approximately 5% of patients who have LIP progress to develop overt lymphoma, and the 5-year mortality for these patients can rise up to 50% (Parambil et al., 2006).

Patients with SS are at increased risk of developing lymphoma, usually low grade MALT lymphoma. Up regulation of the proliferation of BALT might result into malignant transformation with the development of primary pulmonary lymphoma. Typically these patients present with few clinical symptoms such as cough, mild weight loss, and dyspnea on exertion. Strikingly, these minimal symptoms are unparalleled by the severe radiographic changes encompassing micronodules, nodular bilateral and confluent infiltrates, thickening of bronchial walls, air bronchograms and ground glass images (Parke, 2008).

Pulmonary hypertension is a very rare finding in patients with SS. Only 17 cases have been documented in the literature. Prolonged vasospasm and vasculature remodeling have been assigned to contribute to the development of this pathology (Launay et al., 2007).

### 3.3.3 Renal manifestations

Tubulointerstitial nephritis is the most predominant clinical manifestation of renal involvement in SS. This is characterized by distal tubular acidosis (type I) and less frequently proximal tubular acidosis (type II) (Fanconi syndrome) (Bossini et al., 2001). Renal biopsy typically reveals interstitial lymphocytic infiltration. Most of the patients

present with hyposthenuria and hypokalemic, hyperchloremic distal renal tubular acidosis reflecting interstitial infiltration and destruction by lymphocytes. Distal tubular acidosis might be clinically silent but significant untreated renal tubular acidosis can lead to renal stones, nephrocalcinosis, and compromised renal function.

Glomerulonephritis is very rare in SS. When it occurs it is often due to cryoglobulinemia. Histopathological examination of the kidney shows proliferative glomerulonephritis (Aasarod et al., 2000).

### 3.3.4 Cutaneous features

Besides the classical features of dry skin, other skin manifestations might also be present. Purpura might be present in up to 30% of patients presenting as petechiae frequently localized on the lower limbs. They follow a remitting and relapsing course and are associated with worse prognosis of SS. Vasculitis is detected in approximately 10% of patients with pSS (Ramos-Casals et al., 2004). It is characterized by a high predominance of leucocytoclastic vasculitis, with life threatening vasculitis being related to cryoglobulinemia. These symptoms usually resolve with corticosteroids. Other manifestations of vasculitis in SS include recurrent urticaria and skin ulcerations. Cryoglobulinemia can be present in SS patients, and can present with a clinical picture of purpura. Other skin manifestations include erythema nodosa, vitiligo, and digital ulcers (Kittridge et al; 2011). One of the most characteristic non-vasculitic cutaneous manifestations of SS are polycyclic, photosensitive cutaneous lesions. These lesions are clinically similar to those observed in cutaneous lupus erythematosus.

### 3.3.5 Neurological manifestations

The spectrum of neurological disorders associated with SS is broad ranging from peripheral neuropathy to central nervous involvement. The frequency of neurological involvement in SS is relatively low (<5%). In up to 80% of cases, neurological involvement might even precede the diagnosis of SS (Segal et al., 2008).

#### 3.3.5.1 Central nervous system involvement

CNS involvement in SS is very much identical to that of systemic lupus erythematosus. As such, the clinical manifestations include hemiparesis, cranial neuropathy and more often optic nerve neuropathy, brainstem and cerebellar disorders, movement disorders, epilepsy. Spinal cord syndromes encompass transverse myelitis, Brown-Sequard syndrome and progressive myelitis. Due to the presence of optic neuropathy and myelitis, a diagnosis of multiple sclerosis is often evoked. Furthermore, MRI imaging discloses hyperintense lesions in the white matter. Neuromyelitis optica (also known as Devic's disease) is often associated with SS and is characterized by recurrent episodes of myelitis and optic neuropathy.

The clinical features of neuropsychiatric syndrome include often cognition, anxiety, mood changes, and depression and sleep disorders (Lafitte et al., 2001).

#### 3.3.5.2 Peripheral nervous system involvement

Peripheral neuropathy is much more frequent than CNS involvement ranging up to 30% of cases. In most of the cases (93%), peripheral neuropathy precedes the diagnosis of SS. Sensory neuronopathy is considered to be distinctive of SS but sensorimotor neuropathy,

sensory neuropathy, autonomic neuropathy, monoarthritis multiplex are amongst other features of peripheral nervous system involvement.

Trigeminal neuropathy is one of the most common vignettes of neurological involvement in SS, which can be either uni or bilateral, but, in essence, is a pure form of sensory neuropathy. It is characterized by painful paresthesias of the face and hypoesthesia (Lafitte et al., 2001).

### **3.3.6 Gastrointestinal features**

The manifestations of gastrointestinal tract are not very specific and include esophageal dysmotility and gastro-intestinal reflux. Patients often complain of dysphagia, nausea and epigastric pain. Subclinical pancreatic involvement is present in approximately 25% of cases.

There are no specific liver abnormalities, which can be attributed to SS, but autoimmune hepatitis and primary biliary cirrhosis can be associated diseases (Mavragani and Moutsopoulos, 2010, Fox, 2005).

### **3.3.7 Thyroid disease**

Hashimoto's thyroiditis is a commonly present in SS. Thirty to fifty percent of patients with SS has anti-thyroid antibodies and elevated basal thyroid stimulating hormone levels (Ramos-Casals et al., 2000).

### **3.3.8 Laboratory manifestations**

#### **3.3.8.1 Non-specific laboratory manifestations**

Several hematological features such as anemia, leucopenia and thrombopenia can exist. Mild anemia of chronic disease is present in up to 25% of cases but might also result from hemodilution due to polyclonal hypergammaglobulinemia (Tzioufas & Voulgarelis, 2007). Leucopenia < 4000/mm<sup>3</sup> is present in 30% of cases. Hypergammaglobulinemia is most frequent occurring in 80% of cases. In certain cases of major hypergammaglobulinemia, a hyperviscosity syndrome can be present (Fox RI, 2005).

Erythrocyte sedimentation rate is often elevated because of polyclonal hypergammaglobulinemia. In most of the cases serum IgG are increased, while IgA and IgM are normal. If hypogammaglobulinemia exists, lymphoma should be excluded. In 10% of cases, a monoclonal protein is observed. Type II and type III cryoglobulinemia are present in 5% of SS patients (Ramos-Casals et al., 1998).  $\beta$ 2-microglobulinemia is significantly increased in the sera of patients suffering from SS. There is significant positive correlation between  $\beta$ 2-microglobulinemia levels and disease activity (Skopouli et al., 2000, Gottenberg et al., 2005, Theander et al., 2006, Pertovaara & Korpela, 2011). Serum free light chains have been found to be increased in SS and correlate with disease activity (Gottenberg et al., 2007). Rheumatoid factor is found in 50% of cases in primary SS.

#### **3.3.8.2 Autoimmune laboratory manifestations**

Anti nuclear antibodies are frequently observed in the serum of SS patients. Anti-SSA autoantibodies are found in 30 to 50% of sera of patients with SS, while anti-SSB

autoantibodies are found in 20 to 30% of cases. In the majority of cases the presence of anti-SSB autoantibodies is associated with the presence of anti-SSA antibodies. Extraglandular manifestations are usually predominant in patients presenting with these autoantibodies. Antibodies against  $\alpha$ -fodrin have been exclusively (>95%) found in the sera of SS patients in only one German study while other studies have shown a relatively low sensitivity of 30% (Willeke et al., 2007). Because of the absence of adequate commercially available kit, this test is not routinely performed (Witte, 2005). Recently, new autoantibodies directed against the muscarinic receptors M3 and the proteasomes have been described in patients with SS (Feist et al., 1999, He et al., 2011). Abnormalities complement C4 levels are often associated with the presence of cryoglobulinemia.

### 3.3.9 Lymphoma

Patients with SS have a 20 to 40-fold risk of developing non-Hodgkin lymphoma (NHL) as compared to the general population (Voulgarelis et al., 1999, Theander et al., 2006, Voulgarelis & Moutsopoulos, 2008). NHL has a prevalence of about 4% in SS and occurs classically following a median of 7.5 years after its initial diagnosis (Skopouli et al., 2000). Various histologic subtypes of NHL for patients with SS have been described, including follicle center lymphomas, lymphoplasmacytoid lymphomas, diffuse large B-cell lymphomas (DLBCLs), and - in particular - mucosa-associated lymphoid tissue (MALT) lymphomas.

Extranodal marginal zone (MZ) B-cell lymphomas of the MALT type are the most frequent type of lymphomas in SS. Generally, MALT lymphomas follow an indolent course, frequently located in both mucosal and non mucosal extranodal sites, a common denominator being the presence of epithelium suggesting that the intrinsic feature of these cells is homing to epithelia rather than mucosa (Pelstring et al., 1999). Most of the organs in which MALT lymphomas arise are devoid of lymphoid tissue, and in the majority of cases MALT acquisition precedes lymphoma development. All of these lymphomas appear to derive from neoplastic transformation of MZ B lymphocytes in spite of the fact that they are associated with several infectious agents or autoimmune disorders such as SS or Hashimoto thyroiditis (Royer et al., 1997). The histological features of MALT lymphoma closely mimic those of Peyer's patch lymphoid tissue and include: (1) reactive lymphoid follicles, with or without colonization by neoplastic cells; (2) MZ and/or monocytoid B-cells (centrocyte-like cells) that infiltrate the overlying epithelium (lymphoepithelial lesions); (3) small B-lymphocytes; and (4) plasma cells, which might or not be of malignant origin.

In most cases MZ lymphomas of the MALT type in patients with SS are either primary low-grade or localized (stage I and II) with extranodal manifestations. The clinical course of the majority of NHL lymphoma is indolent and the clinical characteristics include small tumor burden and good performance status. The salivary glands are the most commonly affected site, but other extranodal sites - such as the stomach, nasopharynx, skin, liver, kidney, and lung - can also be involved. Twenty per cent of patients display involvement of more than one extranodal site at diagnosis, indicating that these lymphomas migrate preferentially to other mucosal sites, thereby emphasizing the importance for complete staging procedures in patients with SS with MALT lymphomas. Even if the lymphoma rarely involves peripheral lymph nodes, it frequently disseminates to locoregional lymph nodes. Presenting symptoms are the result of major gland enlargement, mainly bilateral parotid gland enlargement. The



clinical picture in these patients is not characterized by the classical presence of B symptoms (fever, night sweats and weight loss) and bone marrow infiltration is rare. However, in disseminated disease more than one extranodal site is usually involved. The clinical and biological factors heralding imminent lymphoma are low C4/C3 levels, palpable purpura, high  $\beta$ 2-microglobulin levels, CD4 lymphocytopenia, parotid gland swelling and persistent enlargement and hypocaptation on salivary scintigraphy, presence of germinal centers in salivary glands, mixed monoclonal cryoglobulinemia, leg ulcers, peripheral neuropathy, splenomegaly and the presence of serum or urine monoclonal bands (Theander et al., 2006, Skopouli et al., 2000). More recently, it has been shown that hypocomplementemia and lymphocytopenia at diagnosis of SS were the strongest predictors of developing lymphoma (Solans-laqué et al., 2011). Consequently, the presence of NHL should be considered at the initial assessment of a patient with SS depicting clinical signs such as significant enlargement of the salivary glands, lymphadenopathy, splenomegaly, skin vasculitis, and peripheral neuropathy.

In certain cases, lymphomas in patients with SS might progress towards a less differentiated cell type. The transition from benign chronic lymphoepithelial sialadenitis (LESA) to indolent extranodal MZ lymphomas of the MALT type and – possibly – to high-grade lymphoma (e.g. DLBCL), is generally considered to represent a multi-step, antigen-driven process. Transformation of MALT lymphoma to DLBCL is heralded by the emergence of an increased number of transformed blasts that form sheets or clusters and finally form a confluence effacing the preceding MALT lymphoma. Most high-grade lymphomas in salivary glands are DLBCLs. It is not known how many of the DLBCLs arise from pre-existing MALT lymphomas and how many are of nodal type or represent transformation of follicular lymphomas. There are several lines of evidence from immunohistochemical, karyotypic, and genotypic studies that the supervening large-cell lymphomas arise from the same clone as the low-grade lymphomas. As such, it can be implied that most of the high-grade lymphomas could represent a blastic variance of either MZ B-cell or follicular-center-cell lymphomas. The clinical manifestation during transformation to high-grade lymphoma is purported by further nodal and extranodal dissemination. Whilst MALT lymphoma in patients with SS carries a good prognosis, the histologic transformation to high grade lymphoma is not with a median overall survival estimated to be only 1.8 years (Voulgarelis et al., 1999).

In summary, NHLs in SS are dichotomized into two categories: the first relating to the majority of patients who develop an indolent extranodal MZ lymphoma and the second, less frequent, relating to those developing high-grade aggressive lymphomas, such as *de novo* or secondary DLBCLs.

## 4. Diagnostic tools for SS

### 4.1 Sialometry and sialochemistry

Salivary flow rates can be measured clinically for whole saliva or for separate secretions from the parotid or submandibular and sublingual glands, with or without stimulation. Patients with clinically overt SS have reduced flow. However, flow rates depend on many factors, such as age, sex, medication, and time of day. For analytical purposes, whole saliva is of limited value as it detects neither dysfunction of any of the separate salivary glands nor

gland specific sialochemical changes (Kalk et al., 2001). In patients with SS, lower submandibular/sublingual flow rates were observed as compared to controls. Measuring submandibular/sublingual flow rates may contribute to an early diagnosis of SS. In contrast, parotid flow rates are decreased in SS and Non-SS sicca patients. Sialochemistry of collected glandular saliva samples may show several characteristic changes in electrolytes and proteins (enzymes) in SS (Van der Reijden Kwaak et al., 1996). The Na<sup>+</sup> concentration level in the parotid glandular saliva is six fold higher in SS patients as compared to non-SS and healthy volunteers (Kalk et al., 2001).

## 4.2 Sialography

Sialography consists in the radiography of the salivary glands and its associated ducts following the injection of a contrast radiopaque substance. This technique enables the assessment of the anatomical changes occurring in the salivary gland ductal system. The procedure of sialography is indeed invasive in that it necessitates the cannulation of the salivary gland and ductal system being evaluated. Two types of radiocontrast substance can be utilized: fat soluble and water-soluble compounds. Water-soluble contrast media are usually preferred in that they induce less localized inflammation in contrast to fat-soluble compounds, which provide better radiographic imaging and contrast but can entail chronic inflammatory changes if leakage of the product occurs.

The changes observed in SS consist of salivary glands duct dilatations, duct strictures, sialectasis and occasionally peripheral duct narrowing. The sensitivity of parotid sialography ranges from 48% to 86% and specificity values stretching from 61% to 100%.

## 4.3 Salivary gland scintigraphy

Salivary scintigraphy is a valid and non-invasive procedure to assess the involvement of salivary glands in patients with xerostomia. After intravenous <sup>99m</sup>Tc-sodium pertechnetate administration, sequential images of the head, on anterior projection, are acquired during a variable time interval, usually between 20 and 40 minutes. The images are then stored and glandular regions of interest (ROI) and a background ROI, usually in the skull, are manually drawn. Computer software generates time-activity curves for each major salivary gland. Time-activity curves are divided in two phases: the uptake phase, corresponding to the accumulation of the tracer by the glandular parenchyma, the duration of which depends on the protocol; and the excretion phase, initiated by the administration of a salivary stimulus, usually lemon juice, which corresponds to the tracer elimination through the oral cavity, providing information on the patency of salivary ducts and the overall functional integrity of the system (Vinagre et al., 2009). Abnormal salivary scintigraphy findings include delayed uptake, reduced concentration and/or delayed uptake of the tracer, according to the method proposed by Schall (Schall et al., 1971). According to the Schall classification, salivary gland functional impairment is classified into four grades, following the intensity of uptake and activity present at the mouth after administration of the salivary stimulus; grade 1 classified as normal tracer uptake and grade 4 as complete absence of uptake and mouth activity. This widely diffused classification is considered the standard method for salivary scintigram interpretation but is observer dependent. The overall sensitivity and specificity of salivary scintigraphy is 54% and 98% respectively (Kohn et al., 1992). The most common and

early scintigraphic abnormality observed in SS is the impairment of excretion, followed by a decrease in tracer accumulation, reflecting glandular parenchyma destruction. The preferential involvement of the submandibular glands in SS and the decrease of non-stimulated salivary secretion by these glands are correlated to the degree of xerostomia. Recently, quantitative evaluation of salivary gland dysfunction has been developed and there is data supporting the fact that quantitative salivary scintigraphy can detect minimal salivary glands abnormalities, detecting as low as 25% of glandular destruction and is therefore important to identify glandular dysfunction in early SS (Bohuslavizki et al., 1995).

#### **4.4 Tear function tests**

##### **4.4.1 Schirmer's test**

The Schirmer's test consists in assessing the function of the lachrymal gland. The Schirmer's I test consists in measuring the amount of wetting on a strip of filter paper placed in the lower eyelid over 5 minutes. In the normal non-anesthetized eye, at least 15mm of wetting is expected in patients younger than 40 years old, and at least 10mm of wetting is expected in elderly patients. If no anesthetic is placed onto the eye, the expected wetting of the filter strip sums up to at least 10 mm in a healthy patient younger than 40 years and at least 5 mm in a patient older than 40years. The schirmer's I test is considered to be anormal if it results in less than 5 mm of wetting confirms the clinical diagnosis of dry eye syndrome. A result of 6–10 mm of wetting suggests a dry eye problem (Lemp, 2000). The Schirmer's II test is quite similar to the I test, the difference being that a cotton swab is used to trigger the tear reflex inside the nose.

The phenol red thread test has been developed to obviate the disadvantages of Schirmer's test by eliminating the need for anesthesia. Three millimeters of a fine dye-impregnated 75 mm cotton thread is placed under the lateral one fifth of the inferior palpebral lid margin for 15 seconds; alkalinity changes its color to bright orange from tear contact. Direct stimulation of the nasociliary nerve through irritation of the nasopharynx confirms the presence or absence of reflex tearing. More recently the combination of the phenol red thread test with the Schirmer's test was found to be highly predictive of severe ocular sicca syndrome (De Monchy et al., 2011).

Hyperosmolarity is a common endpoint for all dry eye syndromes and its measurement is a sensitive, but not specific, test since it does not distinguish between tear-deficient and tear-sufficient dry eye. Other rarely performed tests for reduced tear function include fluorophotometry for decreased protein content, lysozyme levels, ocular ferning, impression cytology, and lactoferrin assays.

##### **4.4.2 Diagnostic dye evaluation**

Fluorescein is a large molecule unable to traverse normal corneal epithelial tight junctions. In advanced dry eye syndrome, these junctions are disrupted, allowing characteristic diffuse subepithelial or punctate staining. Rose Bengal, a derivative of fluorescein, in a 1% solution or impregnated strips stains devitalized epithelial cells. Alternatively, lissamine green stains for cell death or degeneration, as well as cell-to-cell junction disruption, but does not irritate the eye. Van Bijsterveld created a grading scale for rose Bengal dye that divides the ocular

surface into three zones: nasal bulbar conjunctiva, cornea, and temporal bulbar conjunctiva, each graded 0–3 (0, none; 3, confluent staining) (Van Bijsterveld, 1969). A maximum of nine can be obtained and a score  $\geq 4$  is considered as positive test. The Van Bijsterveld score is the most specific ocular test for evaluation of SS (Kalk et al., 2002).

#### 4.4.3 Tear film stability

Tear film instability can be due to either tear deficiency or evaporative dry eye syndrome. In tear breakup time, fluorescein dye is instilled and the time interval is measured between a complete blink to the first appearance of a dry spot in the precorneal tear film. As such, tear breakup time shorter than the blink interval of 5 seconds could imply ocular surface damage while very short tear breakup time (less than 2 seconds) is suggestive of KCS.

#### 4.5 Salivary gland biopsy

The histopathology of labial salivary glands is a key feature in the diagnosis of SS. A widely accepted criterion for histopathological confirmation of SS is focal lymphocytic sialadenitis of the labial salivary glands. Minor labial salivary glands biopsy is performed by midline incision (of about 1.5–2.0 cm) of lower lip under local anesthesia. Four to six lobules of minor salivary glands are harvested because of prominent variation in the degree of inflammatory and destructive involvement of salivary glands and lobes (Greenspan et al., 1974)

Assessment of inflammatory infiltrates in the salivary gland is based on the number of foci present in the glands, classified as the focus score (FS) (Greenspan et al., 1974). The FS is the number of foci per 4mm<sup>2</sup> of salivary gland section. The FS represents an extension of the grade 4 classification of labial salivary gland biopsies of Chisholm and Masson (Table 1). The FS is graded from 0 to 12, with a FS of 0 representing the absence of one focus, while a FS of 12 represent those specimens where the foci are so numerous that they have become confluent. A FS  $\geq 1$  is considered as positive for the diagnosis of SS. It has to be underlined that a FS  $\geq 1$  can also be observed in other systemic autoimmune diseases such as RA, SLE and in 5–10% of healthy subjects thereby reducing its specificity for SS (Bodeutsch et al., 1992, Lindahl & Hedfors, 1989; Lindahl et al., 1989). Moreover, the sensitivity of FS is reduced in smokers and in patients taking corticosteroids ((Manthorpe et al., 2000), (Zandbelt et al., 2001). The combination of FS  $\geq 1$  and immunological staining for IgA has been shown to increase the diagnostic specificity for SS (Zandbelt et al., 2002). Indeed, the presence of a Fs  $\geq 1$  and quantitative immunohistological staining of IgA < 70%, had greater sensitivity and specificity than the FS alone.

Grade	Lymphocytes and plasma cells per 4mm <sup>2</sup> of gland tissue
0	Absent
1	Slight infiltrate
2	Moderate infiltrate or less than 50 lymphocytes/4mm <sup>2</sup>
3	One focus per 4mm <sup>2</sup>
4	More than one focus per 4 mm <sup>2</sup>

Table 1. represents the grading of labial salivary gland biopsies according to the classification by Chisholm and Mason (Chisholm & Mason, 1968).

Parotid gland biopsy can also be an adjunct diagnostic tool for the diagnosis of SS. Previous prospective studies have shown that the performance of minor salivary gland biopsy is comparable to parotid gland biopsy, which explains why parotid gland biopsy is less often performed (Pijpe et al. 2007, Wise et al., 1988). As such, incisional parotid biopsy is not performed because of the fear of facial nerve injury, sialoceles and fistulae. One of the advantages of parotid gland biopsy over labial salivary gland biopsy is that lymphoepithelial islands or lymphoepithelial lesions (LELs) are often observed in parotid gland tissue of SS patients. These LELs, a characteristic histological feature of the major salivary glands in SS develop as a result of hyperplasia of ductal basal cells within a lymphocytic infiltrate. In addition, well-formed lymphoid follicles or germinal centers, often adjacent to ductal epithelium, can be found in the major salivary glands (Jordan & Speight, 1996).

#### 4.6 New diagnostic tools in SS

Ultrasonography is an inexpensive, noninvasive technique that is used to detect several abnormalities in the major salivary glands. The normal parotid gland appears homogeneous, with increased echogenicity relative to adjacent muscle on ultrasonography. Ultrasonography of salivary gland is a useful tool to detect anatomical changes in the parotid and submandibular glands, with similar diagnostic ability to sialography. Hypoechoic or anechoic areas are believed to represent lymphocytic infiltration, damaged salivary parenchyma, and dilated ducts. As the disease progresses, numerous cystic spaces appear, which most likely reflect progressive glandular destruction and prominent intraglandular sialectasis (Madani & Beale, 2006). Moreover, submandibular glands of patients with SS have a lower volume and increased parenchymal heterogeneity compared with normal individuals. Receiver operating characteristic (ROC) curve analyses showed that these findings could reliably discriminate patients from healthy individuals (specificity >90%), but could detect only one-half of patients with SS (sensitivity 48–64%). Detection of hypoechoic areas, echogenic streaks, cysts and irregular gland margins are highly suggestive of SS (Takagi et al., 2010).

Similarly, parotid MRI can also prove to be an adjunct diagnostic tool to detect heterogeneity in the salivary glands and specific cystic lesions (Roberts et al., 2008). Niemela *et al.* recently showed that magnetic resonance sialography was the most sensitive method for detecting glandular changes (96%), followed by MRI (81%) and ultrasonography (78%) (Niemela et al., 2001). However, the changes detected did not correlate with saliva secretion, whereas the focus scores the intensity of lymphocytic infiltration in salivary gland biopsy specimens were related only to parotid MRI findings (Niemela et al., 2004).

The involvement of epigenetic mechanisms in disease processes were established when DNA methylation was first identified as an important factor in tumor biology. Nevertheless, impaired epigenetic control has been linked to various autoimmune diseases including rheumatoid arthritis, systemic lupus erythematosus, systemic sclerosis and SS (Pan & Sawalha, 2009; Richardson, 2007). In salivary glands from SS patients undergoing extracellular matrix remodelling, mechanotransduction may affect epigenetic control of gene expression (Gonzalez et al., 2011a). Global DNA methylation of salivary glands from SS patients appears to be decreased, while specific genes appear to be hypermethylated (i.e: BP230) (Gonzalez et al., 2011b). Over-expression of 2 miRNAs (miR-574 and miR-768-3p)

also contributes to the epigenetic control of gene expression in salivary glands from SS patients (Alevizos et al., 2011). These two micro-RNAs were associated with high degree inflammation and correlated with the histological focus score. Moreover, the distinctive signatures of these micro-RNA's could also distinguish SS patients from normal healthy controls (Alevizos & Illei, 2010). As such, they could represent future diagnostic and prognostic biomarkers of inflammation in SS patients.

#### 4.7 Diagnosis and classification criteria for SS

SS is a complex autoimmune disease with protean nonspecific features, thereby hampering the diagnostic process.

Because of this, many patients often remain either under diagnosed or diagnosis is made after a long lapse of time when full-fledged symptoms are obvious. The seminal importance of making an early diagnosis relies on the fact that appropriate treatment can be tailored and proper management of patients set down. Actually, there are no definite diagnostic criteria for SS and diagnosis is essentially based on the clinical insights of the experienced physician in the light of a set of biological and clinical manifestations. Even if classification criteria have been established for SS, they do not have a sensitivity and specificity of 100%, and therefore cannot be used as diagnostic criteria. As a general rule, classification criteria are used as diagnostic criteria in clinical studies in order to standardize diagnosis for patients participating in multicenter clinical studies and therefore enable analysis of data in an unbiased fashion, or for teaching purposes. The stumbling block for devising diagnostic criteria for SS as in other autoimmune diseases is the temporal progression of the clinical manifestations. In very early disease, the clinical manifestations are not overt, thereby fostering further hurdles in the adequate diagnosis.

In 2002, an American-European consensus group was created and a new set of classification criteria for SS has been proposed (Table 2) (Vitali et al., 2002). These criteria comprise subjective criteria: ocular symptoms and oral symptoms, and objective criteria: ocular signs, histopathological signs (focus score  $\geq 1$ ), oral signs, and serological signs (presence of antinuclear antibodies: anti-SSA or anti-SSB). Patients are classified as SS if 4 of the 6 mentioned criteria are present, as long as histopathology or serology is positive, or if 3 of any 4 objective criteria are present.

1. Ocular symptoms

Ocular symptoms are present if there is a positive answer to at least one of the following questions:

- Have you had daily persistent, troublesome dry eyes for  $>3$  months?
- Do you have recurrent sensation of sand or gravel in the eyes?
- Do you use tear substitutes  $> 3$ times daily?

2. Oral symptoms

Oral symptoms are present if there is a positive response to at least one of the following questions:

- Do you have a daily feeling of dry mouth  $> 3$  months?
- Have you had recurrent or persistent swollen salivary glands as an adult?
- Do you drink frequently liquids to help in swallowing dry food?

3. Objective evidence of ocular involvement as defined by a positive result for at least one of the following tests:
  - Positive Schirmer's test without anesthesia ("5mm)
  - Rose Bengal or other ocular dye staining score ( $\geq 4$  according to Van Bijsterveld's scoring system)
4. Histopathology
  - Focal lymphocyte sialoadenitis in minor salivary glands, evaluated by an expert histopathologist, with a focus score  $\geq 1$  (defined as a number of lymphocytic foci that are adjacent to normal appearing mucous acini and contain more than 50 lymphocytes per  $4\text{mm}^2$  of glandular tissue)
5. Objective evidence of salivary gland involvement defined as positive result of at least one of the following diagnostic tests:
  - Parotid sialography showing the presence of diffuse sialectasis (punctuate, cavitary or destructive pattern) without evidence of obstruction of major salivary ducts
  - Salivary scintigraphy showing delayed uptake, reduced concentration and/or delayed excretion of tracer
6. Presence of autoantibodies to Ro/SSA or La/SSB, or both, in the serum.

#### **Exclusion Criteria**

- Past head and neck radiation treatment
- Hepatitis C or HIV infection
- Pre-existing lymphoma
- Sarcoidosis
- Graft versus host disease
- Use of anticholinergic drugs

#### **Classification of Primary and secondary Sjögren's syndrome**

In the absence of any underlying disease, primary Sjögren's syndrome is defined as the presence of any four diagnostic criteria as long as either item 4 (histopathology) or 6 (serologic autoantibody) is positive or as the presence of any 3 of the 4 objective criteria items (items 3,4,5,6).

In the presence of any potentially associated disease (such as another autoimmune disease; systemic lupus erythematosus for example), the presence of item 1 or 2 plus any other 2 items 3,4 and 5 might be suggestive of secondary Sjögren's disease.

Table 2. American-European classification criteria for SS

#### **4.8 Differential diagnosis of SS**

The differential diagnosis of SS includes diseases that present with sicca symptoms and parotid gland enlargement. Sarcoidosis can mimic SS, but salivary gland biopsy usually depicts non-caseating granuloma and autoantibodies are absent and clinical features such as hilar lymphadenopathy, uveitis or hypercalcemia are more suggestive of sarcoidosis (Ramos-Casals et al., 2004). Other medical conditions masquerading as SS include lipoproteinemias (types II, IV and V), chronic graft-versus-host disease, amyloidosis, and infection with viruses such as human immunodeficiency virus (HIV), human T-lymphocytic virus-I (HTLV-I) and HCV. Patients with HIV infection may present with sicca manifestations, parotid gland enlargement, pulmonary involvement, and lymphadenopathy.

These patients have an increased prevalence of HLA-DR5 alloantigen (Itescu et al., 1990). The two diseases can easily be distinguished, as patients with HIV infection are usually young males, have no autoantibodies to Ro (SS-A) and La (SS-B), and the lymphocytic infiltrates of the salivary glands consist of CD8+ T cells. HCV can produce a chronic lymphocytic sialadenitis that resembles SS (Haddad et al., 1992). These patients have a higher mean age, a lower prevalence of parotid gland enlargement and a higher prevalence of liver involvement than patients with pSS. However, patients with SS do not possess an increased frequency of antibodies to HCV in their sera. In cases with isolated dry mouth or dry eyes, other potential causes including deficiency disorders (vitamin A deficiency for example), drugs, infections, endocrinopathies, or degenerative diseases should be excluded.

#### 4.9 Measuring disease activity in SS

In an attempt to provide tools to assess pSS patients in clinical practice as well as in therapeutic trials, several disease activity indices have been designed. These include the SSDAI (SS Disease Activity Index), SCAI (Sjögren's Systemic Clinical Activity Index) and ESSDAI (EULAR SS Disease Activity Index). SSDAI and ESSDAI are global scores. SCAI is a composite score. Validity is a limitation for SSDAI and SCAI (Campar & Isenberg, 2010). ESSDAI is complemented by ESSPRI for the assessment of subjective features. It is more accurate in detecting changes in activity. Comparing the three disease activity indices, it was observed that for patients with improved activity, the 3 disease activity indices showed similar, large sensitivity to change. However, the ESSDAI seemed to detect changes in activity more accurately than other disease activity indexes. Notably, for patients with stable activity, the ESSDAI did not show erroneous improvement (Seror et al., 2010). The ESSDAI consists of 12 organ-specific domains, which are predominantly clinical; only 2 of them include haematological (cytopenias) or biological (clonal component, serum complement levels, serum IgG and cryoglobulins) findings (Seror et al., 2010). For each domain, features of disease activity were classified in 3 or 4 levels according to their severity (Table 3).

Domain	Activity level	Description
Constitutional	0-2	0=no symptoms; 1=mild fever and 5-10% weight loss; 2=severe fever and >10% weight loss
Lymphadenopathy	0-3	0= absence of the following features; 1=Lymphadenopathy $\geq 1$ cm in any nodal region or $\geq 2$ cm in inguinal region; 2=Lymphadenopathy $\geq 2$ cm in any nodal region or $\geq 3$ cm in inguinal region, and/or splenomegaly (clinically palpable or assessed by imaging); 3=Current malignant B-cell proliferative disorder
Glandular	0-2	0=no glandular swelling; 1=Small glandular swelling with enlarged parotid ( $\leq 3$ cm), or limited submandibular or lachrymal swelling; 2=Major glandular swelling with enlarged parotid ( $> 3$ cm), or important submandibular or lachrymal swelling



Domain	Activity level	Description
<b>Articular</b>	0-3	0= no articular symptoms; 1=Arthralgias in hands, wrists, ankles and feet accompanied by morning stiffness (>30 min); 2=1 to 5 (of 28 total count) synovitis; 3= $\geq 6$ (of 28 total count) synovitis.
<b>Cutaneous</b>	0-3	0=absence of active cutaneous involvement; 1=Erythema multiforma; 2=Limited cutaneous vasculitis, including urticarial vasculitis, or purpura limited to feet and ankle, or subacute cutaneous lupus; 3=Diffuse cutaneous vasculitis, including urticarial vasculitis, or diffuse purpura, or ulcers related to vasculitis
<b>Pulmonary</b>	0-3	0=absence of active pulmonary involvement; 1= Persistent cough or bronchial involvement with no radiographic abnormalities on radiography Or radiological or HRCT evidence of interstitial lung disease with: No breathlessness and normal lung function test; 2=Moderately active pulmonary involvement, such as interstitial lung disease shown by HRCT with shortness of breath on exercise (NHYA II) or abnormal lung function tests restricted to: $70\% >DL_{CO} \geq 40\%$ or $80\% >FVC \geq 60\%$ ; 3=Highly active pulmonary involvement, such as interstitial lung disease shown by HRCT with shortness of breath at rest (NHYA III, IV) or with abnormal lung function tests: $DL_{CO} < 40\%$ or $FVC < 60\%$ .
<b>Renal</b>	0-3	0=Absence of currently active renal involvement with proteinuria $< 0.5$ g/d, no hematuria, no leucocyturia, no acidosis, or long-lasting stable proteinuria due to damage; 1=Evidence of mild active renal involvement, limited to tubular acidosis without renal failure or glomerular involvement with proteinuria (between 0.5 and 1 g/d) and without hematuria or renal failure ( $GFR \geq 60$ ml/min); 2=Moderately active renal involvement, such as tubular acidosis with renal failure ( $GFR < 60$ ml/min) or glomerular involvement with proteinuria between 1 and 1.5 g/d and without hematuria or renal failure ( $GFR \geq 60$ ml/min) or histological evidence of extra-membranous glomerulonephritis or important interstitial lymphoid infiltrate; 3=Highly active renal involvement, such as glomerular involvement with proteinuria $> 1.5$ g/d or hematuria or renal failure ( $GFR < 60$ ml/min), or histological evidence of proliferative glomerulonephritis or cryoglobulinemia related renal involvement

Domain	Activity level	Description
Muscular	0-3	0= absence of muscular involvement; 1=Mild active myositis shown by abnormal EMG or biopsy with no weakness and creatine kinase ( $N < CK \leq 2N$ ); 2=Moderately active myositis proven by abnormal EMG or biopsy with weakness (maximal deficit of 4/5), or elevated creatine kinase ( $2N < CK \leq 4N$ ); 3=Highly active myositis shown by abnormal EMG or biopsy with weakness (deficit $\leq 3/5$ ) or elevated creatine kinase ( $>4N$ )
PNS	0-3	0 = absence of PNS involvement; 1=Mild active peripheral nervous system involvement, such as pure sensory axonal polyneuropathy shown by NCS or trigeminal (V) neuralgia; 2= Moderately active peripheral nervous system involvement shown by NCS, such as axonal sensory-motor neuropathy with maximal motor deficit of 4/5, pure sensory neuropathy with presence of cryoglobulinemic vasculitis, ganglionopathy with symptoms restricted to mild/moderate ataxia, inflammatory demyelinating polyneuropathy (CIDP) with mild functional impairment (maximal motor deficit of 4/5 or mild ataxia), Or cranial nerve involvement of peripheral origin (except trigeminal (V) neuralgia) ;3=Highly active PNS involvement shown by NCS, such as axonal sensory-motor neuropathy with motor deficit $\leq 3/5$ , peripheral nerve involvement due to vasculitis (mononeuritis multiplex etc.), severe ataxia due to ganglionopathy, inflammatory demyelinating polyneuropathy (CIDP) with severe functional impairment: motor deficit $\leq 3/5$ or severe ataxia
CNS	0-3	0= absence of CNS involvement; 1=Moderately active CNS features, such as cranial nerve involvement of central origin, optic neuritis or multiple sclerosis-like syndrome with symptoms restricted to pure sensory impairment or proven cognitive impairment; 3=Highly active CNS features, such as cerebral vasculitis with cerebrovascular accident or transient ischemic attack, seizures, transverse myelitis, lymphocytic meningitis, multiple sclerosis-like syndrome with motor deficit.

Domain	Activity level	Description
Hematological	0-3	0=absence of autoimmune cytopenia; 1=Cytopenia of autoimmune origin with neutropenia ( $1000 < \text{neutrophils} < 1500/\text{mm}^3$ ), and/or anemia ( $10 < \text{hemoglobin} < 12 \text{ g/dl}$ ), and/or thrombocytopenia ( $100,000 < \text{platelets} < 150,000/\text{mm}^3$ ) Or lymphopenia ( $500 < \text{lymphocytes} < 1000/\text{mm}^3$ ); 2= Cytopenia of auto-immune origin with neutropenia ( $500 \leq \text{neutrophils} \leq 1000/\text{mm}^3$ ), and/or anemia ( $8 \leq \text{hemoglobin} \leq 10 \text{ g/dl}$ ), and/or thrombocytopenia ( $50,000 \leq \text{platelets} \leq 100,000/\text{mm}^3$ ) Or lymphopenia ( $\leq 500/\text{mm}^3$ ); 3=Cytopenia of auto-immune origin with neutropenia ( $\text{neutrophils} < 500/\text{mm}^3$ ), and/or or anemia ( $\text{hemoglobin} < 8 \text{ g/dl}$ ) and/or thrombocytopenia ( $\text{platelets} < 50,000/\text{mm}^3$
Biological	0-2	0=absence of any of the following biological feature; 1=Clonal component and/or hypocomplementemia (low C4 or C3 or CH50) and/or hypergammaglobulinemia or high IgG level between 16 and 20 g/L; 2=Presence of cryoglobulinemia and/or hypergammaglobulinemia or high IgG level $> 20 \text{ g/L}$ , and/or recent onset hypogammaglobulinemia or recent decrease of IgG level ( $< 5 \text{ g/L}$ )

Table 3. ESSDAI index for measuring disease activity in SS (modified according to Seror et al., 2010)

#### 4.10 Biological markers of disease activity in SS

Biological biomarkers are of pivotal importance in determining which patients are at risks of developing systemic complications of SS and those who could benefit from therapeutic immunomodulation. Classical markers of inflammation such as C-reactive protein and erythrocyte sedimentation rate are of limited value to assess disease activity in SS. These past ten years, significant progress has been made in deciphering the molecular mechanisms underscoring the pathogenesis of SS. As such, the pivotal role of B-cell in pathophysiology of SS has been unearthed (Groom et al., 2002, Gottenberg et al., 2006, Mackay et al., 2007). The B-cell activating factor (BAFF) is significantly increased in the sera and in the salivary glands of pSS patients (Mariette et al., 2003, Lavie et al., 2004). BAFF levels in the sera of pSS patients correlate with the presence of anti-SSA autoantibodies and with the ESSDAI index. Serum beta macroglobulin, another marker of B lymphocyte activation, has been shown to be useful marker of disease activity in pSS, in that it correlated with the presence of disease flare as well as with the occurrence of extraglandular manifestations (Gottenberg et al., 2005). More recently, the levels of serum beta-microglobulin have been observed to correlate with the ESSDAI index (Pertovaara & Korpela, 2011). Serum free light chains have also been detected to be increased in pSS patients and shown to correlate with disease activity (Gottenberg et al., 2007). Several studies are ongoing to evaluate other biomarkers of disease

activity of pSS such as chemokines induced by interferon pathway and IL-21, and also other markers of B-cell activation are being currently investigated.

## 5. Prognostic features of SS

Much knowledge has been gathered these last ten years about the outcome of patients with SS. Although not a benign disease, primary SS has a slow insidious progression with no rapid deterioration in salivary gland function, systemic markers or dramatic changes in clinical manifestations (Gannot et al., 2000). Primary SS, as such is a relatively chronic stable condition, with only mild deterioration of main disease characteristics (Theander et al., 2005). Significant loss of glandular function and quality of life are highlighted during the first years of disease (median of 6 years) and remain stable afterwards. The presence of immunological abnormalities such as the presence of anti-SSA autoantibodies, hypocomplementemia, increased levels of IgG, high focus scores and low unstimulated whole saliva, is associated with more severe glandular dysfunction (Haldorsen et al., 2008), Theander et al., 2005, Pijpe et al. 2007). It has to be underlined that even if the clinical course of the disease is usually stable, similarly to other autoimmune diseases, individual patients might present some flares and remissions. However, there are two exceptions to this classical benign course, which include a high incidence of lymphoma and the development of systemic manifestations, pertaining to a worsened prognostic significance. The presence of autoantibodies is correlated with the number of systemic manifestations and more specifically anti-SSA autoantibodies are the strongest predictors of extra-glandular manifestations (Ter Borg et al., 2011). Furthermore, serum free light chains and serum  $\beta 2$  microglobulin are increased and correlate with extra-glandular involvement in pSS (Gottenberg et al., 2007; Gottenberg et al., 2005). These findings reflect that enhanced disturbance of the immune system portrayed by B-cell hyperactivity with hypergammaglobulinemia and autoantibody formation, is associated with systemic manifestations in primary SS. A steady clinical course is usually observed in patients with peri-epithelial lesions (tubulointerstitial nephritis, lung and liver involvement), while those presenting with extra-epithelial lesions such as polyneuropathy, vasculitis, glomerulonephritis, purpura and vasculitis, have increased morbidity and mortality (Skopouli et al., 2000, Ioannidis et al., 2002). The cardinal role of cryoglobulinemia has been underlined in this latter group of patients as being the harbinger of the extraepithelial manifestations. These extraepithelial characteristics are associated with a high risk of developing life-threatening conditions and require tailoring treatment with higher doses of corticosteroids and immunosuppressive agents. On the other hand, in patients presenting with peri-epithelial lesions, treatment requires less use of steroids and immunosuppressive drugs and a less frequent clinical monitoring is recommended.

Several reports have noted an increased incidence of malignant non-Hodgkin lymphomas (NHL) in SS patients, with an estimated risk of up to 44 times greater as compared to general population (Kassan et al., 1978). This risk increases with disease duration, is maintained with time and is not related to the patient age at time of diagnosis of pSS (Solans-Laque et al., 2011). Several predictors of lymphoma development have been detailed and include anemia, lymphadenopathy, lymphopenia, hypocomplementemia, peripheral neuropathy, cutaneous vasculitis, bilateral parotid gland swelling, severe involvement in parotid scintigraphy, and cryoglobulinemia (Voulgarelis, Dafni, Isenberg, & Moutsopoulos,

1999), (Brito-Zeron et al., 2007). It has been observed that patients with two of three following factors (parotid scintigraphy, vasculitis, hypocomplementemia) were associated with a lower survival as compared to patients with no factor. More recently, hypocomplementemia and lymphocytopenia were independent risk factors for developing lymphoma but only hypocomplementemia was related to earlier development of NHL and higher mortality ((Brito-Zeron et al., 2007; Solans-Laque et al., 2011). Furthermore, it has been also observed that the detection of germinal center-like lesions in pSS diagnostic salivary biopsies is a highly predictive marker of NHL (Theander et al., 2011). Patients with high-to-intermediated grade lymphoma have significantly worse survival while large tumor diameters and the presence of B symptoms are additional risk factors for increased mortality (Voulgarelis et al., 1999).

## 6. Conclusions

SS is a chronic autoimmune disease characterized by glandular and systemic manifestations. Because of the increased risk of developing lymphoma in pSS patients, making the diagnosis of SS is of pivotal importance. The herald of newer diagnostic tools could help clinicians and thereby provide significant relief to patients through earlier treatments. Deciphering mechanistic processes inherent to the pathophysiology of SS should in the future provide more sophisticated means for early diagnosis of SS.

## 7. References

- Aasarod, K., Haga, H. J., Berg, K. J., Hammerstrom, J., & Jorstad, S. (2000). Renal involvement in primary Sjogren's syndrome. *QJM: monthly journal of the Association of Physicians*, 93(5), 297-304.
- Alevizos, I., Alexander, S., Turner, R. J., & Illei, G. G. (2011). MicroRNA expression profiles as biomarkers of minor salivary gland inflammation and dysfunction in Sjogren's syndrome. *Arthritis and rheumatism*, 63(2), 535-544.
- Alevizos, I., & Illei, G. G. (2010). MicroRNAs as biomarkers in rheumatic diseases. [Review]. *Nature reviews. Rheumatology*, 6(7), 391-398.
- Bodeutsch, C., de Wilde, P. C., Kater, L., van Houwelingen, J. C., van den Hoogen, F. H., Kruize, A. A., et al. (1992). Quantitative immunohistologic criteria are superior to the lymphocytic focus score criterion for the diagnosis of Sjogren's syndrome. . *Arthritis and rheumatism*, 35(9), 1075-1087.
- Bohuslavizki, K. H., Brenner, W., Wolf, H., Sippel, C., Tonshoff, G., Tinnemeyer, S., et al. (1995). Value of quantitative salivary gland scintigraphy in the early stage of Sjogren's syndrome. *Nuclear medicine communications*, 16(11), 917-922.
- Bossini, N., Savoldi, S., Franceschini, F., Mombelloni, S., Baronio, M., Cavazzana, I., et al. (2001). Clinical and morphological features of kidney involvement in primary Sjogren's syndrome. *Nephrology, dialysis, transplantation: official publication of the European Dialysis and Transplant Association - European Renal Association*, 16(12), 2328-2336.
- Brito-Zeron, P., Ramos-Casals, M., Bove, A., Sentis, J., & Font, J. (2007). Predicting adverse outcomes in primary Sjogren's syndrome: identification of prognostic factors. *Rheumatology*, 46(8), 1359-1362.

- Campar, A., & Isenberg, D. A. (2010). Primary Sjogren's syndrome activity and damage indices comparison. *European journal of clinical investigation*, 40(7), 636-644.
- Chisholm, D. M., & Mason, D. K. (1968). Labial salivary gland biopsy in Sjogren's disease. *Journal of clinical pathology*, 21(5), 656-660.
- Delaleu, N., Jonsson, M. V., Appel, S., & Jonsson, R. (2008). New concepts in the pathogenesis of Sjogren's syndrome. *Rheumatic diseases clinics of North America*, 34(4), 833-845, vii.
- De Monchy, I., Gendron, G., Miceli, C., Pogorzalek, N., Mariette, X., & Labetoulle, M. (2011). Combination between Schirmer I test and Phenol Red Thread as a rescue strategy for diagnosis of ocular dryness associated with Sjogren's syndrome. *Investigative ophthalmology & visual science*.
- Fauchais, A. L., Ouattara, B., Gondran, G., Lalloue, F., Petit, D., Ly, K., et al. (2010). Articular manifestations in primary Sjogren's syndrome: clinical significance and prognosis of 188 patients. *Rheumatology*, 49(6), 1164-1172.
- Feist, E., Kuckelkorn, U., Dorner, T., Donitz, H., Scheffler, S., Hiepe, F., et al. (1999). Autoantibodies in primary Sjogren's syndrome are directed against proteasomal subunits of the alpha and beta type. *Arthritis and rheumatism*, 42(4), 697-702.
- Fox, R. I. (2005). Sjogren's syndrome. [Review]. *Lancet*, 366(9482), 321-331.
- Gannot, G., Lancaster, H. E., & Fox, P. C. (2000). Clinical course of primary Sjogren's syndrome: salivary, oral, and serologic aspects. *The Journal of rheumatology*, 27(8), 1905-1909.
- Gonzalez, S., Aguilera, S., Alliende, C., Urzua, U., Quest, A. F., Herrera, L., et al. (2011). Alterations in type I hemidesmosome components suggestive of epigenetic control in the salivary glands of patients with Sjogren's syndrome. [Research Support, Non-U.S. Gov't]. *Arthritis and rheumatism*, 63(4), 1106-1115.
- Gonzalez, S., Aguilera, S., Urzua, U., Quest, A. F., Molina, C., Alliende, C., et al. (2011). Mechanotransduction and epigenetic control in autoimmune diseases. *Autoimmunity reviews*, 10(3), 175-179.
- Goransson, L. G., Haldorsen, K., Brun, J. G., Harboe, E., Jonsson, M. V., Skarstein, K., et al. (2011). The point prevalence of clinically relevant primary Sjogren's syndrome in two Norwegian counties. *Scandinavian journal of rheumatology*, 40(3), 221-224.
- Gottenberg, J. E., Busson, M., Cohen-Solal, J., Lavie, F., Abbed, K., Kimberly, R. P., et al. (2005). Correlation of serum B lymphocyte stimulator and beta2 microglobulin with autoantibody secretion and systemic involvement in primary Sjogren's syndrome. *Annals of the rheumatic diseases*, 64(7), 1050-1055.
- Gottenberg, J. E., Cagnard, N., Lucchesi, C., Letourneur, F., Mistou, S., Lazure, T., et al. (2006). Activation of IFN pathways and plasmacytoid dendritic cell recruitment in target organs of primary Sjogren's syndrome. *Proceedings of the National Academy of Sciences of the United States of America*, 103(8), 2770-2775.
- Gottenberg, J. E., Aucouturier, F., Goetz, J., Sordet, C., Jahn, I., Busson, M., et al. (2007). Serum immunoglobulin free light chain assessment in rheumatoid arthritis and primary Sjogren's syndrome. *Annals of the rheumatic diseases*, 66(1), 23-27.
- Greenspan, J. S., Daniels, T. E., Talal, N., & Sylvester, R. A. (1974). The histopathology of Sjogren's syndrome in labial salivary gland biopsies. [Review]. *Oral surgery, oral medicine, and oral pathology*, 37(2), 217-229.

- Groom, J., Kalled, S. L., Cutler, A. H., Olson, C., Woodcock, S. A., Schneider, P., et al. (2002). Association of BAFF/BLYS overexpression and altered B cell differentiation with Sjogren's syndrome. [Comparative Study]. *The Journal of clinical investigation*, 109(1), 59-68.
- Haddad, J., Deny, P., Munz-Gotheil, C., Ambrosini, J. C., Trinchet, J. C., Pateron, D., et al. (1992). Lymphocytic sialadenitis of Sjogren's syndrome associated with chronic hepatitis C virus liver disease. *Lancet*, 339(8789), 321-323.
- Haldorsen, K., Moen, K., Jacobsen, H., Jonsson, R., & Brun, J. G. (2008). Exocrine function in primary Sjogren syndrome: natural course and prognostic factors. *Annals of the rheumatic diseases*, 67(7), 949-954.
- He, J., Guo, J. P., Ding, Y., Li, Y. N., Pan, S. S., Liu, Y., et al. (2011). Diagnostic significance of measuring antibodies to cyclic type 3 muscarinic acetylcholine receptor peptides in primary Sjogren's syndrome. *Rheumatology*, 50(5), 879-884.
- Iagnocco, A., Modesti, M., Priori, R., Alessandri, C., Perella, C., Takanen, S., et al. (2010). Subclinical synovitis in primary Sjogren's syndrome: an ultrasonographic study. *Rheumatology*, 49(6), 1153-1157.
- Itescu, S., Brancato, L. J., Buxbaum, J., Gregersen, P. K., Rizk, C. C., Crosson, T. S., et al. (1990). A diffuse infiltrative CD8 lymphocytosis syndrome in human immunodeficiency virus (HIV) infection: a host immune response associated with HLA-DR5. *Annals of internal medicine*, 112(1), 3-10.
- Jordan, R. C., & Speight, P. M. (1996). Lymphoma in Sjogren's syndrome. From histopathology to molecular pathology. *Oral surgery, oral medicine, oral pathology, oral radiology, and endodontics*, 81(3), 308-320.
- Kalk, W. W., Mansour, K., Vissink, A., Spijkervet, F. K., Bootsma, H., Kallenberg, C. G., et al. (2002). Oral and ocular manifestations in Sjogren's syndrome. *The Journal of rheumatology*, 29(5), 924-930.
- Kalk, W. W., Vissink, A., Spijkervet, F. K., Bootsma, H., Kallenberg, C. G., & Nieuw Amerongen, A. V. (2001). Sialometry and sialochemistry: diagnostic tools for Sjogren's syndrome. *Annals of the rheumatic diseases*, 60(12), 1110-1116.
- Kassan, S. S., Thomas, T. L., Moutsopoulos, H. M., Hoover, R., Kimberly, R. P., Budman, D. R., et al. (1978). Increased risk of lymphoma in sicca syndrome. *Annals of internal medicine*, 89(6), 888-892.
- Kittridge, A., Routhouska, S. B., & Korman, N. J. (2011). Dermatologic manifestations of Sjogren syndrome. [Review]. *Journal of cutaneous medicine and surgery*, 15(1), 8-14.
- Kohn, W. G., Ship, J. A., Atkinson, J. C., Patton, L. L., & Fox, P. C. (1992). Salivary gland <sup>99m</sup>Tc-scintigraphy: a grading scale and correlation with major salivary gland flow rates. *Journal of oral pathology & medicine : official publication of the International Association of Oral Pathologists and the American Academy of Oral Pathology*, 21(2), 70-74.
- Lafitte, C., Amoura, Z., Cacoub, P., Pradat-Diehl, P., Picq, C., Salachas, F., et al. (2001). Neurological complications of primary Sjogren's syndrome. *Journal of neurology*, 248(7), 577-584.
- Launay, D., Hachulla, E., Hatron, P. Y., Jais, X., Simonneau, G., & Humbert, M. (2007). Pulmonary arterial hypertension: a rare complication of primary Sjogren syndrome: report of 9 new cases and review of the literature. *Medicine*, 86(5), 299-315.


- Lavie, F., Miceli-Richard, C., Quillard, J., Roux, S., Leclerc, P., & Mariette, X. (2004). Expression of BAFF (BLyS) in T cells infiltrating labial salivary glands from patients with Sjogren's syndrome. *The Journal of pathology*, 202(4), 496-502.
- Lemp, M. A. (2000). Evaluation and differential diagnosis of keratoconjunctivitis sicca. *The Journal of rheumatology. Supplement*, 61, 11-14.
- Lindahl, G., & Hedfors, E. (1989). Lymphocytic infiltrates and epithelial HLA-DR expression in lip salivary glands in connective tissue disease patients lacking sicca: a prospective study. *British journal of rheumatology*, 28(4), 293-298.
- Lindahl, G., Lonquist, B., & Hedfors, E. (1989). Lymphocytic infiltrations of lip salivary glands in bone marrow recipients. A model for the development of the histopathological changes in Sjogren's syndrome? *Journal of autoimmunity*, 2(4), 579-583.
- Mackay, F., Groom, J. R., & Tangye, S. G. (2007). An important role for B-cell activation factor and B cells in the pathogenesis of Sjogren's syndrome. [Review]. *Current opinion in rheumatology*, 19(5), 406-413.
- Madani, G., & Beale, T. (2006). Inflammatory conditions of the salivary glands. *Seminars in ultrasound, CT, and MR*, 27(6), 440-451.
- Manoussakis, M. N., & Kapsogeorgou, E. K. (2010). The role of intrinsic epithelial activation in the pathogenesis of Sjogren's syndrome. [Review]. *Journal of autoimmunity*, 35(3), 219-224.
- Manthorpe, R., Benoni, C., Jacobsson, L., Kirtava, Z., Larsson, A., Liedholm, R., et al. (2000). Lower frequency of focal lip sialadenitis (focus score) in smoking patients. Can tobacco diminish the salivary gland involvement as judged by histological examination and anti-SSA/Ro and anti-SSB/La antibodies in Sjogren's syndrome? *Annals of the rheumatic diseases*, 59(1), 54-60.
- Mariette, X., Roux, S., Zhang, J., Bengoufa, D., Lavie, F., Zhou, T., et al. (2003). The level of BLyS (BAFF) correlates with the titre of autoantibodies in human Sjogren's syndrome. *Annals of the rheumatic diseases*, 62(2), 168-171.
- Mariette, X., & Gottenberg, J. E. (2010). Pathogenesis of Sjogren's syndrome and therapeutic consequences. *Current opinion in rheumatology*, 22(5), 471-477.
- Mavragani, C. P., & Moutsopoulos, H. M. (2010). The geoepidemiology of Sjogren's syndrome. [Review]. *Autoimmunity reviews*, 9(5), A305-310.
- Niemela, R. K., Paakko, E., Suramo, I., Takalo, R., & Hakala, M. (2001). Magnetic resonance imaging and magnetic resonance sialography of parotid glands in primary Sjogren's syndrome. *Arthritis and rheumatism*, 45(6), 512-518.
- Niemela, R. K., Takalo, R., Paakko, E., Suramo, I., Paivansalo, M., Salo, T., et al. (2004). Ultrasonography of salivary glands in primary Sjogren's syndrome. A comparison with magnetic resonance imaging and magnetic resonance sialography of parotid glands. *Rheumatology*, 43(7), 875-879.
- Pan, Y., & Sawalha, A. H. (2009). Epigenetic regulation and the pathogenesis of systemic lupus erythematosus. *Translational research : the journal of laboratory and clinical medicine*, 153(1), 4-10.
- Parambil, J. G., Myers, J. L., & Ryu, J. H. (2006). Diffuse alveolar damage: uncommon manifestation of pulmonary involvement in patients with connective tissue diseases. *Chest*, 130(2), 553-558.



- Parke, A. L. (2008). Pulmonary manifestations of primary Sjogren's syndrome. *Rheumatic diseases clinics of North America*, 34(4), 907-920, viii.
- Pelstring, R. J., Essell, J. H., Kurtin, P. J., Cohen, A. R., & Banks, P. M. (1991). Diversity of organ site involvement among malignant lymphomas of mucosa-associated tissues. *American journal of clinical pathology*, 96(6), 738-745.
- Pertovaara, M., & Korpela, M. (2011). Serum {beta}2 microglobulin correlates with the new ESSDAI in patients with Sjogren's syndrome. *Annals of the rheumatic diseases*.
- Pijpe, J., Kalk, W. W., Bootsma, H., Spijkervet, F. K., Kallenberg, C. G., & Vissink, A. (2007). Progression of salivary gland dysfunction in patients with Sjogren's syndrome. *Annals of the rheumatic diseases*, 66(1), 107-112.
- Pijpe, J., Kalk, W. W., van der Wal, J. E., Vissink, A., Kluin, P. M., Roodenburg, J. L., et al. (2007). Parotid gland biopsy compared with labial biopsy in the diagnosis of patients with primary Sjogren's syndrome. *Rheumatology*, 46(2), 335-341.
- Ramos-Casals, M., Anaya, J. M., Garcia-Carrasco, M., Rosas, J., Bove, A., Claver, G., et al. (2004). Cutaneous vasculitis in primary Sjogren syndrome: classification and clinical significance of 52 patients. *Medicine*, 83(2), 96-106.
- Ramos-Casals, M., Brito-Zeron, P., Garcia-Carrasco, M., & Font, J. (2004). Sarcoidosis or Sjogren syndrome? Clues to defining mimicry or coexistence in 59 cases. *Medicine*, 83(2), 85-95.
- Ramos-Casals, M., Cervera, R., Yague, J., Garcia-Carrasco, M., Trejo, O., Jimenez, S., et al. (1998). Cryoglobulinemia in primary Sjogren's syndrome: prevalence and clinical characteristics in a series of 115 patients. *Seminars in arthritis and rheumatism*, 28(3), 200-205.
- Ramos-Casals, M., Garcia-Carrasco, M., Cervera, R., Gaya, J., Halperin, I., Ubieta, I., et al. (2000). Thyroid disease in primary Sjogren syndrome. Study in a series of 160 patients. *Medicine*, 79(2), 103-108.
- Richardson, B. (2007). Primer: epigenetics of autoimmunity. *Nature clinical practice. Rheumatology*, 3(9), 521-527.
- Roberts, C., Parker, G. J., Rose, C. J., Watson, Y., O'Connor, J. P., Stivaros, S. M., et al. (2008). Glandular function in Sjogren syndrome: assessment with dynamic contrast-enhanced MR imaging and tracer kinetic modeling--initial experience. *Radiology*, 246(3), 845-853.
- Royer, B., Cazals-Hatem, D., Sibilia, J., Agbalika, F., Cayuela, J. M., Soussi, T., et al. (1997). Lymphomas in patients with Sjogren's syndrome are marginal zone B-cell neoplasms, arise in diverse extranodal and nodal sites, and are not associated with viruses. *Blood*, 90(2), 766-775.
- Schall, G. L., Anderson, L. G., Wolf, R. O., Herdt, J. R., Tarpley, T. M., Jr., Cummings, N. A., et al. (1971). Xerostomia in Sjogren's syndrome. Evaluation by sequential salivary scintigraphy. *JAMA : the journal of the American Medical Association*, 216(13), 2109-2116.
- Segal, B., Carpenter, A., & Walk, D. (2008). Involvement of nervous system pathways in primary Sjogren's syndrome. [Review]. *Rheumatic diseases clinics of North America*, 34(4), 885-906, viii.
- Seror, R., Mariette, X., Bowman, S., Baron, G., Gottenberg, J. E., Boostma, H., et al. (2010). Accurate detection of changes in disease activity in primary Sjogren's syndrome by

- the European League Against Rheumatism Sjogren's Syndrome Disease Activity Index. *Arthritis care & research*, 62(4), 551-558.
- Seror, R., Ravauud, P., Bowman, S. J., Baron, G., Tzioufas, A., Theander, E., et al. (2010). EULAR Sjogren's syndrome disease activity index: development of a consensus systemic disease activity index for primary Sjogren's syndrome. *Annals of the rheumatic diseases*, 69(6), 1103-1109.
- Skopouli, F. N., Dafni, U., Ioannidis, J. P., & Moutsopoulos, H. M. (2000). Clinical evolution, and morbidity and mortality of primary Sjogren's syndrome. *Seminars in arthritis and rheumatism*, 29(5), 296-304.
- Solans-Laque, R., Lopez-Hernandez, A., Angel Bosch-Gil, J., Palacios, A., Campillo, M., & Vilardell-Tarres, M. (2011). Risk, Predictors, and Clinical Characteristics of Lymphoma Development in Primary Sjogren's Syndrome. *Seminars in arthritis and rheumatism*.
- Takagi, Y., Kimura, Y., Nakamura, H., Sasaki, M., Eguchi, K., & Nakamura, T. (2010). Salivary gland ultrasonography: can it be an alternative to sialography as an imaging modality for Sjogren's syndrome? *Annals of the rheumatic diseases*, 69(7), 1321-1324.
- Ter Borg, E. J., Risselada, A. P., & Kelder, J. C. (2011). Relation of Systemic Autoantibodies to the Number of Extraglandular Manifestations in Primary Sjogren's Syndrome: A Retrospective Analysis of 65 Patients in the Netherlands. *Seminars in arthritis and rheumatism*, 40(6), 547-551.
- Theander, E., Andersson, S. I., Manthorpe, R., & Jacobsson, L. T. (2005). Proposed core set of outcome measures in patients with primary Sjogren's syndrome: 5 year follow up. *The Journal of rheumatology*, 32(8), 1495-1502.
- Theander, E., Henriksson, G., Ljungberg, O., Mandl, T., Manthorpe, R., & Jacobsson, L. T. (2006). Lymphoma and other malignancies in primary Sjogren's syndrome: a cohort study on cancer incidence and lymphoma predictors. *Annals of the rheumatic diseases*, 65(6), 796-803.
- Theander, E., Vasaitis, L., Baecklund, E., Nordmark, G., Warfvinge, G., Liedholm, R., et al. (2011). Lymphoid organisation in labial salivary gland biopsies is a possible predictor for the development of malignant lymphoma in primary Sjogren's syndrome. *Annals of the rheumatic diseases*, 70(8), 1363-1368.
- Trontzas, P. I., & Andrianakos, A. A. (2005). Sjogren's syndrome: a population based study of prevalence in Greece. The ESORDIG study. [Letter]. *Annals of the rheumatic diseases*, 64(8), 1240-1241.
- Tzioufas, A. G., & Voulgarelis, M. (2007). Update on Sjogren's syndrome autoimmune epithelitis: from classification to increased neoplasias. [Review]. *Best practice & research. Clinical rheumatology*, 21(6), 989-1010.
- Van Bijsterveld OP. Diagnostic tests in the Sicca syndrome. *Arch Ophthalmol* 1969; 82:10-14.
- Van der Reijden, W. A., van der Kwaak, J. S., Veerman, E. C., & Nieuw Amerongen, A. V. (1996). Analysis of the concentration and output of whole salivary constituents in patients with Sjogren's syndrome. *European journal of oral sciences*, 104(4 ( Pt 1)), 335-340.

- Vinagre, F., Santos, M. J., Prata, A., da Silva, J. C., & Santos, A. I. (2009). Assessment of salivary gland function in Sjogren's syndrome: the role of salivary gland scintigraphy. [Review]. *Autoimmunity reviews*, 8(8), 672-676.
- Voulgarelis, M., Dafni, U. G., Isenberg, D. A., & Moutsopoulos, H. M. (1999). Malignant lymphoma in primary Sjogren's syndrome: a multicenter, retrospective, clinical study by the European Concerted Action on Sjogren's Syndrome. *Arthritis and rheumatism*, 42(8), 1765-1772.
- Voulgarelis M & Moutsopoulos HM (2008). Mucosa-associated lymphoid tissue lymphoma in Sjögren's syndrome: risks, management, and prognosis *Rheum Dis Clin North Am*; 34:921-933.
- Willeke P, Gaubitz M, Schotte H, Becker H, Mickholz E, Domschke W & Schlüter B (2007). Clinical and immunological characteristics of patients with Sjögren's syndrome in relation to alpha-fodrin antibodies. *Rheumatology*; 46:479-483.
- Wise, C. M., Agudelo, C. A., Semble, E. L., Stump, T. E., & Woodruff, R. D. (1988). Comparison of parotid and minor salivary gland biopsy specimens in the diagnosis of Sjogren's syndrome. *Arthritis and rheumatism*, 31(5), 662-666.
- Witte, T. (2005). Antifodrin antibodies in Sjogren's syndrome: a review. [Review]. *Annals of the New York Academy of Sciences*, 1051, 235-239.
- Zandbelt, M. M., van den Hoogen, F. H., de Wilde, P. C., van den Berg, P. J., Schneider, H. G., & van de Putte, L. B. (2001). Reversibility of histological and immunohistological abnormalities in sublabial salivary gland biopsy specimens following treatment with corticosteroids in Sjogren's syndrome. [Case Reports]. *Annals of the rheumatic diseases*, 60(5), 511-513.
- Zandbelt, M. M., Wentink, J. R., de Wilde, P. C., van Damme, P. A., van de Putte, L. B., & van den Hoogen, F. H. (2002). The synergistic value of focus score and IgA% score of sublabial salivary gland biopsy for the accuracy of the diagnosis of Sjogren's syndrome: a 10-year comparison. *Rheumatology*, 41(7), 819-823.



## **Insights and Perspectives in Rheumatology**

Edited by Dr. Andrew Harrison

ISBN 978-953-307-846-5

Hard cover, 274 pages

**Publisher** InTech

**Published online** 13, January, 2012

**Published in print edition** January, 2012

This book offers a range of perspectives on pathogenesis, clinical features and treatment of different rheumatic diseases, with a particular focus on some of the interesting aspects of Sjögren's syndrome. It contains detailed and thorough reviews by international experts, with a diverse range of academic backgrounds. It will also serve as a useful source of information for anyone with a passive interest in rheumatology, from the genetic and molecular level, through to the psychological impact of pain and disability.

### **How to reference**

In order to correctly reference this scholarly work, feel free to copy and paste the following:

Muhammad S. Soyfoo and Elie Cogan (2012). Diagnostic and Prognostic Features of Sjögren's Syndrome, Insights and Perspectives in Rheumatology, Dr. Andrew Harrison (Ed.), ISBN: 978-953-307-846-5, InTech, Available from: <http://www.intechopen.com/books/insights-and-perspectives-in-rheumatology/diagnostic-and-prognostic-features-of-sjo-gren-s-syndrome>

# **INTECH**

open science | open minds

### **InTech Europe**

University Campus STeP Ri  
Slavka Krautzeka 83/A  
51000 Rijeka, Croatia  
Phone: +385 (51) 770 447  
Fax: +385 (51) 686 166  
[www.intechopen.com](http://www.intechopen.com)

### **InTech China**

Unit 405, Office Block, Hotel Equatorial Shanghai  
No.65, Yan An Road (West), Shanghai, 200040, China  
中国上海市延安西路65号上海国际贵都大饭店办公楼405单元  
Phone: +86-21-62489820  
Fax: +86-21-62489821