

We are IntechOpen, the world's leading publisher of Open Access books Built by scientists, for scientists

6,900

Open access books available

186,000

International authors and editors

200M

Downloads

Our authors are among the

154

Countries delivered to

TOP 1%

most cited scientists

12.2%

Contributors from top 500 universities



WEB OF SCIENCE™

Selection of our books indexed in the Book Citation Index
in Web of Science™ Core Collection (BKCI)

Interested in publishing with us?
Contact book.department@intechopen.com

Numbers displayed above are based on latest data collected.
For more information visit www.intechopen.com



Nontuberculous Mycobacterium Infections in Rheumatoid Arthritis Patients

Maiko Watanabe¹ and Shogo Banno²

¹Nagoya City University

²Aichi Medical University

Japan

1. Introduction

Nontuberculous mycobacteria (NTM) are a large, diverse group of ubiquitous environmental organisms found in tap water, soil, dust, plants, animals, and food. NTM infection can cause various diseases, such as pulmonary disease (PD), which are most frequently observed in immunocompromised individuals. Diseases associated with NTM are particularly severe in those receiving tumor necrosis factor (TNF)-alpha (α) blockers, which predispose individuals to NTM infection. Experts generally agree that patients with active NTM disease should receive TNF- α blockers only if they are also receiving adequate therapy for NTM disease. On the other hand, the Japanese College of Rheumatology recommends that TNF- α blockers not be used in patients with active NTM infection, because NTM is resistant to most antimycobacterial drugs.

Bronchiectasis is one of the most frequent manifestations of NTM infection, not only in NTM-PD patients, but also in rheumatoid arthritis (RA) patients. It is difficult to distinguish the bronchiectasis associated with NTM-PD from that with RA on chest radiography or high-resolution computed tomography (HRCT). Due to the ease of NTM contamination from the environment, the diagnosis of NTM-PD is extremely difficult. The most recent American Thoracic Society (ATS) and Infectious Disease Society of America (IDSA) guidelines recommend diagnosing NTM-PD via a combination of clinical, radiographic, bacteriologic (two positive sputum cultures, or one positive bronchoalveolar lavage (BAL) culture or transbronchial biopsy), and histological criteria. In NTM-PD patients receiving TNF- α blockers, *Mycobacterium avium* was the most common etiologic organism, accounting for half of all NTM isolates (Winthrop et al., 2009). Recently, Kitada et al. (2008) established an enzyme immunoassay (EIA) for the serological diagnosis of *M. avium*-complex (MAC)-PD by examining the level of serum IgA antibody to the glycopeptidolipid (GPL) core, which is a MAC-specific antigen. Unlike bronchoscopy and sputum culture examinations, EIA kits are less invasive and provide more rapid diagnosis of MAC-PD.

In this chapter, we discuss the characteristics of NTM, relationship between NTM infections and RA patients, particularly those receiving TNF- α blockers, and diagnosis of MAC-PD with RA patients using the recently developed EIA kit.

2. NTM infections

2.1 Etiology of NTM infections

NTM are environmental organisms found in not only in natural and tap water, but also in soil, dust, plants, animals, and food (Falkinham, 1996, 2002; Jarzebowski & Young, 2005; Sugita et al., 2000; Tortoli, 2006). Presently, NTM consist of more than 130 species, with approximately 60 of these being suspected or known to cause disease. However, NTM infections are not transmitted between humans or between animals and humans (Cook, 2010). NTM infection can result in skin and pulmonary disease, lymphadenitis, gastrointestinal disease, and in severely immunocompromised individuals, disseminated disease (McGrath, 2010). Moreover, the progression of NTM infection to clinical disease requires one or more predisposing host conditions; NTM-PD typically occurs in patients who are not obviously immunosuppressed, but who nearly always have pre-existing abnormalities.

Notably, approximately 80% of patients with NTM disease are middle-aged or elderly women (Cook, 2010), and it is suspected that the high rate of NTM lung disease in postmenopausal women is due to their lower estrogen levels (Koh & Kwon, 2005). Other hypotheses for the higher disease rate in women include differences in the anatomy and physiology of the respiratory tract, combined with repeated infections by different strains over time (Chalermkulrat et al., 2002). Most female patients have underlying bronchiectasis that typically requires computed tomography (CT) examination for detection and that is associated with previous histories of lung infection or other, often obscure, underlying causes.

Chronic pulmonary manifestations of NTM infections, which are among the most common in NTM-PD patients, include chronic obstructive pulmonary disease (COPD), bronchiectasis, periostitis, *Mycobacterium tuberculosis* (TB) infection, cystic fibrosis, and pneumoconiosis. Patients receiving treatment with TNF- α blockers, or those with certain body characteristics (e.g., pectus excavatum or scoliosis, particularly in postmenopausal women) are at higher risk for such manifestations, although NTM infection in individuals without risk factors is well reported (Griffith et al., 2007). Impairment of local immune function, including clearance of secretions, abnormal composition of airway surface liquid, and airway and mucosal damage due to chronic PD, may increase the propensity for NTM-PD (Morrissey, 2007). In addition, although a clear association exists between bronchiectasis and NTM disease (Cook, 2010), NTM infection also develops prior to the manifestation of bronchiectasis (Holling et al., 2002; Kubo et al., 1998; Moore, 1993; Primak et al., 1995). Thus, the observations in bronchiectasis patients suggest that bronchiectasis appears to be both a risk factor and a consequence of NTM infection (Barker, 2002).

2.2 Types of NTM-PD

Chest radiographs are not as sensitive as HRCT scanning for detecting abnormalities associated with NTM-PD (Kubo et al., 1998; Olivier, 1998; Swensen et al., 1994; Tanaka et al., 2001; Wintram & Weisbrad, 2002). CT can further characterize cavities and reveal associated bronchiectasis and pleural thickening (Ellisi & Hansell, 2002; Hartman et al., 1993). Three prototypical presentations of lung disease are reported in NTM-PD: (1) cavitory disease, (2) fibronodular bronchiectasis, and (3) hypersensitivity pneumonitis (HP) (Field & Cowie, 2006). The two former types are the most common manifestations observed in NTM-PD patients (Goo & Im, 2002).

1. Cavitory disease

This type of lung disease, which represents “a TB-like pattern” of disease, is quite similar to that associated with post-primary TB. Cavitory disease is often seen in older men with substantial smoking histories and chronic PD (*e.g.*, COPD, pneumoconiosis, prior TB, and sarcoidosis) (Bandoh et al., 2004; Christensen et al., 1981; Dhillon & Watanakunakorn, 2000; Fowler et al., 2006; Glassroth, 2008; Morita et al., 2005; Sonnenberg et al., 2000; Teosk & Lo, 1992; Wickremasinghe et al., 2005; Witly et al., 1994). Cavitory disease associated with NTM mostly occurs in the apical and posterior segments of the upper lobe, although multiple lung segments may be involved. Cavitations typically include thick walls and no air-fluid level, and are often associated with pleural thickening, which is more extensive than that seen in TB. However, pleural effusion and substantial lymph node enlargement are less common than in TB (Albelda et al., 1985; Christensen et al., 1981; Reich & Johnson, 1991; Woodring et al., 1987) (Fig. 1). The symptoms of NTM-induced cavitory disease include cough, fever, weight loss, weakness, haemoptysis, and respiratory insufficiency (Griffith et al., 2007; Piersimoni & Scarparo, 2008).

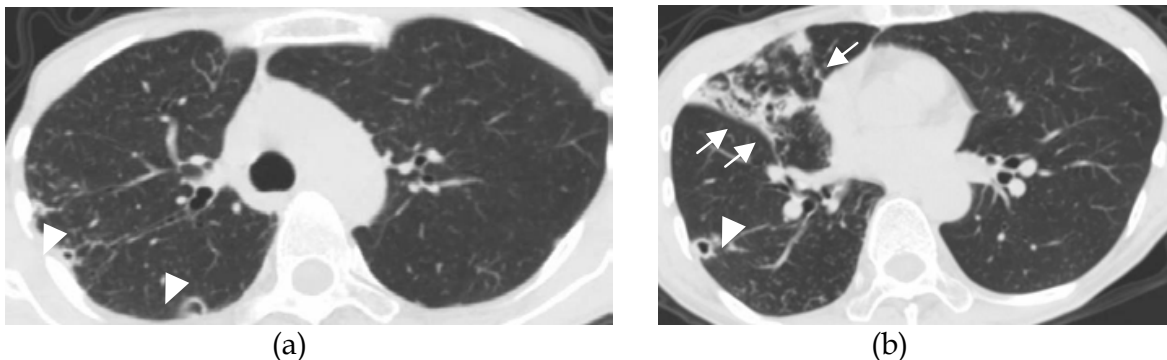


Fig. 1. HRCT images of the lungs of a 63-year-old woman with MAC-PD. *M. avium* was detected in several sputum cultures. (a) Cavities with thick walls and no air-fluid level were seen in the right upper lobe (arrowheads) (b) Bronchiectasis with infiltration in the right middle lobe (arrows) and a cavity in the right lower lobe (arrowhead) were detected.

2. Fibronodular bronchiectasis

In fibronodular bronchiectasis, CT findings are characterized by small centrilobular nodules or tree-in-bud opacities, with cylindrical bronchiectasis typically detected in the same lobe (Han et al., 2003; Hartman et al., 2003; Moore, 1993; Obayashi et al., 1999; Primack et al., 1995; Swensen et al., 1994) (Fig. 2). Bronchiectasis is more commonly associated with NTM than in TB (Primack et al., 1995), with bilateral bronchiectasis and bronchiolitis occurring in one third of NTM patients, as detected by HRCT. However, the coexistence of bronchiectasis and bronchiolitis (*i.e.*, centrilobular nodules and mosaic pattern) is also highly suggestive of NTM infection (Koh et al., 2005). Typical HRCT findings are often observed in the right middle lobe or lingual, which are anatomically predisposed to impaired clearance of secretions, a condition referred to as “Lady Windermere syndrome” (Reich & Johnson, 1992). Fibronodular bronchiectasis is most common in elderly women without preexisting pulmonary conditions or histories of tobacco abuse, but who often have anatomic abnormalities of the chest (Chan et al., 2007; Daley & Griffith, 2002; Dhillon & Watanakunakorn, 2000; Field & Cowie, 2006; Iseman et al., 1991; Jarzembowski & Young, 2008; Okumura et al., 2008; Prince et al., 1989; Taiwo & Glassroth, 2010). The major symptom

of fibronodular bronchiectasis is a persistent cough, and the disease can result in severe lung damage, although many patients experience a less aggressive, chronic course (Prince et al., 1989; Taiwo & Glassroth, 2010).

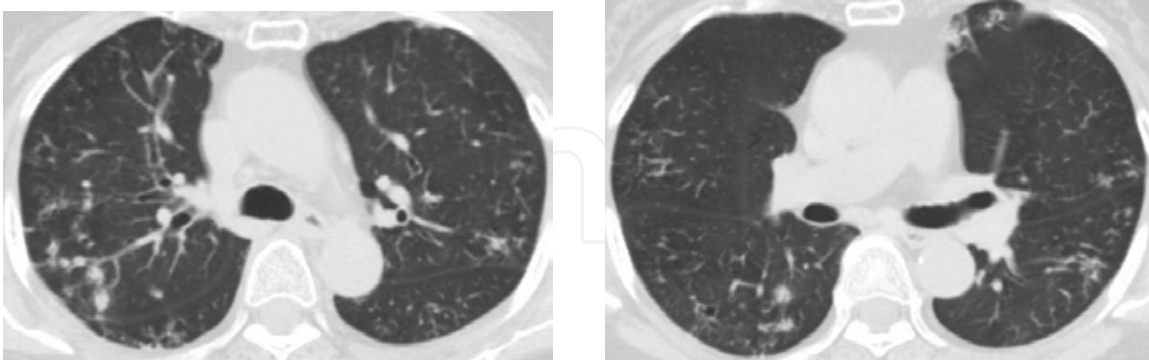


Fig. 2. HRCT images of the lungs of a 69-year-old woman with MAC-PD. Multiple diffuse, small, centrinodular nodules and tree-in bud opacities were seen in the all lobes.

3. Hypersensitive pneumonitis

The third presentation of lung disease in NTM-PD is HP, which has first recognized as having a presentation similar to hypersensitivity lung disease (Griffith et al., 2007). HP can occur after the use of hot tubs and medicinal baths (Khour et al., 2001). The lung inflammation and infection associated with HP are thought to lead to unique pathological features that differ distinctly from those of other NTM lung diseases. It is unclear whether MAC antigens are solely responsible for triggering host responses or whether there are other hot-tub associated cofactors (organic or inorganic) or host predispositions that may be contributing to the disease process (Griffith et al., 2007).

2.2 Diagnosis and treatment of NTM

As NTM are ubiquitous environmental saprophytes often found in water supplies, it is difficult to determine whether the growth of NTM isolates from a patient specimen represents true disease and transient colonization of a nonsterile site, such as the lung, or is a result of laboratory contamination. Pseudo-outbreaks of NTM have been described as a result of contamination of hospital laboratories, water supplies, and instruments such as bronchoscopes (Gubler et al., 1992). Once the diagnosis of NTM infection has been made, a treatment of long duration of is typically required (Stout, 2006). As the risk of contamination of the sputum by environmental mycobacteria is high, the misattribution of the clinical significance of a positive detection would lead to a useless treatment for the patient (Tortoli, 2008).

The ATS/IDSA guidelines of 2007 set criteria for the diagnosis of NTM and recommend that the minimum evaluation of a patient suspected of having NTM-PD should include the following: (1) chest radiograph or, in the absence of cavitations, chest HRCT scan, (2) collection of three or more sputum specimens for acid-fast bacterium (AFB) analysis, and (3) exclusion of other disorders such as TB and lung malignancy. Furthermore, diagnosis of NTM pulmonary infection requires the fulfillment of both clinical and microbiological criteria. Clinically, it necessary that both of the following criteria are met: (1) pulmonary symptoms, nodular or cavity opacities on chest radiograph, or a HRCT scan showing multifocal bronchiectasis with multiple small nodules, and (2) appropriate exclusion of other diagnoses. Microbiologically, only one of the following criteria are required: (1) positive culture result from at least two

separate expectorated sputum samples, (2) positive culture result from at least one bronchial wash or lavage, or (3) transbronchial or other lung biopsy with mycobacterial histopathologic features (granulomatous inflammation or AFB) and positive culture for NTM, or biopsy showing mycobacterial histopathologic features and one or more sputum or bronchial washings that are culture positive (Griffith et al., 2007).

NTM patients with multiple positive cultures for the identical NTM pathogen and cavitary PD or major areas of bronchiectasis usually require therapy (Cook, 2010). Treatment of NTM infection should include at least three effective drugs, such as macrolides, for a minimum of 12 months after sputum samples appear similar to negative controls. However, long-term treatment with macrolides can lead to resistance, which is most frequently due to 23S rRNA gene mutations at positions 2058-2059. It was reported that 76% of patients receiving macrolide monotherapy or macrolide plus a fluoroquinolone developed resistance, whereas resistance only developed in 4% of patients treated with a regimen of clarithromycin, etambutol, and a rifamycin (Griffith et al., 2006). Due to the long duration of treatment, side effects, and the impact of these factors on patient compliance, the treatment outcomes of NTM are variable and often poor (Glassroth, 2008; Piersimoni & Scarparo, 2008).

2.3 Mycobacterium avium complex

Mycobacterium avium complex (MAC) is the term used to describe a group of slow-growing, nonpigmented (although a yellow pigment may be produced in the absence of light) AFB (Griffith et al., 2007; Inderljed et al., 1993; Tortoli, 2006). MAC species are found worldwide, but are isolated more frequently in temperate regions, including the USA, Europe, Japan, and South Africa (Inderljed et al., 1993). MAC consists of at least two major mycobacterial species, *M. avium* and *M. intracellulare*, which cannot be differentiated on the basis of traditional physical and biochemical tests, and require specific DNA probes for identification. MAC is the most common cause of NTM infections and predominantly results in pulmonary or disseminated disease (Haverkort, 2003; Marin-Casabona et al., 2004; Thomsen et al., 2002). *M. avium* is the more important pathogen in disseminated disease, whereas *M. intracellulare* is the more common respiratory pathogen.

MAC-PD is predominantly observed in postmenopausal, non-smoking, Caucasian females (Griffith et al., 2007). In Japan, among 273 newly diagnosed MAC-PD cases between 1996 and 2002, 70.3% were female with a mean age of 63.2 years (Okumura et al., 2008). The HRCT findings of MAC-PD also exhibit all three forms of lung disease, as described for NTM-PD, namely cavitary disease, fibronodular bronchiectasis, and HP (Cappelluti et al., 2003; Embil et al., 1997; Glassroth, 2008; Kahana et al., 1997). Fibronodular bronchiectasis caused by MAC is most frequently observed in women >60 years old, and compared to patients with other types of NTM infection, the lingual and right middle lobe tend to be more severely and progressively involved (Hollings et al., 2002; Kim et al., 2005; Kubo et al., 1998; Obayashi et al., 1999; Prince et al., 1989; Tanaka et al., 2001). In a recent clinical study, MAC was cultured from the sputum of 25% of the patients with fibronodular bronchiectasis, and MAC infection was documented in 50% of bronchoscopies, including BAL and transbronchial biopsies (Griffith et al., 2007). Although the cornerstones of MAC treatment are the macrolides clarithromycin, azithromycin, and ethambutol, MAC species are saprophytic and possess cell walls that are relatively impenetrable to an array of chemicals, endowing them with intrinsic resistance to many antimicrobials (Mdluli et al., 1998).

2.4 The role of TNF- α in NTM infection

Host defenses of the lung against NTM involve both anatomical and functional integrity of the airway system and specific cellular immune responses (Arend et al., 2009). Disorders of the cellular immune system are associated predominantly with disseminated NTM infection, and are also found in patients receiving immunosuppressive drugs for inflammatory disorders, such as TNF- α blockers. TNF- α blockers are also associated with an increased risk of TB, as well as susceptibility to other opportunistic infections by intracellular pathogens (Arend et al., 2009; Crum et al., 2005; Kaene, 2005, 2008). TNF- α is released by a variety of inflammatory cells in response to immune recognition of mycobacterial lipoarabinomannan. Interferon- γ and interleukin (IL)-12 control mycobacteria in large part through the up-regulation of TNF- α , which is predominantly produced by monocytes/macrophages (Ehlers et al., 1999; Gardam et al., 2003; Griffith et al., 2007). TNF- α binds to the macrophage membrane-bound TNF- α receptors 1 and 2 and acts through the intracellular nuclear factor- κ B pathway to modulate gene expression (Griffith et al., 2007; Jacob et al., 2007; Mutlu et al., 2006). Intracellular signaling through TNF receptor 1 is essential for efficacious host defense against intracellular pathogens, such as *M. tuberculosis* (Bean et al., 1999; Pfeffer et al., 1993), whereas TNF receptor 2 plays only a minimal role in this process. TNF- α recruits and activates other inflammatory cells, and is essential for granuloma formation (Kindler et al., 1989), which has a crucial role in the control of infections due to intracellular pathogens, including *M. tuberculosis*, *Listeria monocytogens*, *Histoplasma capsulatum*, and NTM (Ehlers, 2005; Wallis, 2004). As TNF- α blockers interfere with granuloma formation, one of their side effects is increased susceptibility to mycobacterial disease (Keane et al., 2001; Marie et al., 2005; Wallis et al., 2004). As with TB, TNF- α blockers represent important, new, potent factors for predisposing individuals to NTM infections (Griffith, 2010). However, the incidence of NTM infections during treatment with TNF- α blockers, such as infliximab and etanercept, was several-fold lower than that of TB (Wallis et al., 2004). The risks underlying predisposition to NTM infections and those promoting progression of active NTM infection are unknown (Griffith et al., 2007).

2.5 Biologics used in RA patients and adverse side effects, including NTM infections

RA is a systemic autoimmune disorder characterized by chronic polyarticular synovial inflammation that often leads to irreversible joint damage, disability, and deformity. Joint inflammation is a result of the excessive production of pro-inflammatory cytokines, such as TNF- α , IL-1, and IL-6, by activated T cells and the stimulation of immunoglobulin production by B cells. Over the last two decades, numerous effective biotherapies have been developed to lower pro-inflammatory cytokine production. Prior to biotherapy, the incidence rate of infections in the RA population was nearly twice as high as that in matched non-RA controls. In post-marketing surveillance and observational studies of TNF- α blockers, serious NTM infections appear to be the most frequent adverse event, with a reported prevalence of 6%-18% and an incidence rate of approximately 6 per 100 patient-years, representing a two- to three-fold higher incidence in patients receiving TNF- α blockers compared with controls (Salliot et al., 2009).

Presently, nine biologics for treating RA are available: five TNF- α blockers (Infliximab (Remicade®), etanercept (Enbrel®), adalimumab (Humira®), certolizumab pegol (Cimzia®), golimumab (Simponi®), an anti-IL-1 therapy (anakinra (Kineret®)), an anti-CTLA4 therapy (abatacept (Orencia®)), an anti-CD20 therapy (rituximab (Rituxan® or Mabthera®)), and an

anti-IL-6 therapy (tocilizumab (Actemura®)). TNF- α blockers include both soluble receptors that serve as decoy receptors competing with TNF receptors (etanercept) and monoclonal antibodies that target TNF receptors (infliximab, adalimumab, golimumab, and certolizumab pegol). Anakinra is an IL-1 receptor antagonist that targets IL-1, which is an important cytokine in RA pathogenesis. Rituximab is a monoclonal antibody that selectively targets the chimeric anti-CD20, which is found primarily on B-cells. Abatacept is a recombinant human fusion protein consisting of a monoclonal antibody against CTLA-4 and a domain of CTLA-4, and serves to down-regulate T-cell activation (Salliot et al., 2009).

According to the most recent meta-analysis of adverse effects of biologics based on randomized controlled trials, controlled clinical trials, and open-label extension studies, biologics as a group, after adjusting for dose, were associated with a statistically higher rate of total adverse events odds ratio (OR; 1.19) and withdrawals due to adverse events (OR 1.32), and an increased risk of TB reactivation (OR 4.68) compared to controls (Gauhar et al., 2007). Notably, TB reactivation with TNF- α blockers was drug specific, and the incidence in the biologic group was 0.149%, whereas that in control group was 0.030% (Gauhar et al., 2007). Although the risk of TB was analyzed in this report, the incidence of NTM infection was not described. However, several case reports have noted NTM-associated disease in patients receiving infliximab and etanercept (Marie et al., 2005; Mufti et al., 2005; Salvana et al., 2007; Winthrop et al., 2008), and infliximab has been statistically more increased infection ratio of mycobacterium species than etanercept (Wallis et al., 2004). There is less incidence of NTM with Infliximab than with etanercept, because infliximab binds both monomeric and trimeric forms of soluble TNF- α , whereas etanercept only binds the trimeric form. Moreover, etanercept binds less strongly to transmembrane TNF- α than infliximab (Keane, 2005; Wallis et al., 2004).

One reason for the few reports of NTM infections caused by TNF- α blocker administration may relate to the lack of evidence for a latent phase in NTM infections. In addition, NTM disease is generally insidious, occasionally difficult to diagnose, and is not required to be reported to health authorities. Furthermore, NTM infections can persist even after at least 12 months of TNF- α blocker therapy and are therefore often considered to be new infections. The generally lower pathogenicity of NTM species, as compared to *M. tuberculosis*, could further explain the lower frequency of TNF blocker-associated NTM disease (van Ingen et al., 2008). However, the frequency of NTM disease compared with TB reactivation was reported to be 5- to 10-fold higher in patients undergoing therapy with TNF- α blockers (Wallis et al., 2004). As there is no evidence for the existence of a latent phase in NTM disease, screening for NTM before initiating immunosuppressive treatment might be challenging, and is further complicated by the lack of specific tests for the detection of NTM infection. Chest radiography typically only detects diverse and partly species-specific patterns (Griffith et al., 2007); moreover, these features represent active NTM disease and cannot be used to identify early infection. Despite these difficulties, the number of NTM infections has recently exceeded that of TB (Winthrop et al., 2008), which may reflect improvements in the screening for latent TB infection (Arend et al., 2003; Beglinger et al., 2007; Carmona et al., 2005; Centers for Disease Control and Prevention, 2004; Keane & Bresnihan, 2008; Leding et al., 2005).

Among the new drug classes developed for anti-RA therapy, anti-IL-17 and anti-IL-23 antibodies are particularly significant to NTM infections, as they have important roles in all stages of the immune response against mycobacterial infection, from neutrophil recruitment in early phases to granuloma formation and maintenance in later stages (Lubberts, 2008;

McInnes & Liew, 2005). These two agents modify JAK-STAT signaling, which is an essential step in mycobacterial immunity, leading to increased susceptibility to mycobacterial disease in humans (Haverkamp et al., 2006). Metalloproteinase inhibitors are also likely to confer an increased risk of mycobacterial infection (van Ingen et al., 2008). Although NTM infection in patients receiving TNF- α blockers is relatively rare and its diagnosis can be difficult, the presence of infection should be evaluated because TNF- α blockers and new drugs for anti-RA therapy represent notable predisposing factors for potentially serious, even fatal, infections.

In a number of RA patients receiving TNF- α blockers, NTM-PD progressed despite aggressive antimycobacterial treatment (Winthrop et al., 2009). Etanercept therapy has been reported in association with fatal MAC-PD, fatal pulmonary *M. xenopi* infection (Maimon et al., 2007), *M. chelonae* endophthalmitis (Stewart et al., 2006), *M. xenopi* spinal osteomyelitis (Yim et al., 2004), and pulmonary *M. szulgai* infection (van Ingen et al., 2007). Due to the long duration and potential side effects of antibiotics, the treatment of NTM disease is difficult and the outcome is often disappointing (Griffith et al., 2007; Jenkins et al., 2008; van Ingen et al., 2007). Although the ATS recommendations consider active TB infection prior to completing a standard regimen of anti-TB therapy to be a contraindication for treatment with biologic agents, no information is available for NTM disease (Saag et al., 2008). The Japanese College of Rheumatology recommends that TNF- α blockers not be used in patients with active NTM infection, because NTM is resistant to most antimycobacterial drugs. On the other hand, expert opinion is that patients with active NTM disease should receive TNF- α blockers only if they are concomitantly receiving adequate therapy for the NTM disease (Griffith et al., 2007). American College of Rheumatology and European Urban Research Association don't restrict the use of TNF- α blockers in patients the NTM. By contrast, several reports on immune reconstitution inflammatory syndrome (IRIS) have been described for a variety of diseases in HIV patients, including MAC lymphadenitis and pulmonary and central nervous system tuberculosis. IRIS appears to be mediated by a recovering immune system upon the recognition of circulating antigens to which it previously mounted a minimal response (Shelburne & Hamill, 2003). While IRIS to TB associated with infliximab treatment has been described in HIV-uninfected individuals (Belknap et al., 2005; Garcia et al., 2005), no cases of IRIS to MAC have been reported for this subset of patients. However, concurrent low-dose treatment with TNF- α blockers might produce immunological regulation that is beneficial for this group of patients (Garcia et al., 2005), because the disruption of granuloma formation by TNF- α blockers could increase exposure of the bacteria to antimycobacterial drugs, resulting in improved infection outcomes (Wallis, 2005). Whether TNF- α blockers can be safely continued during antimycobacterial therapy remains unclear. It is also not evident when it would be safe to reinstitute anti-TNF- α therapy in NTM-infected patients (Winthrop et al., 2009). Therefore, TNF- α blockers should always be discontinued on diagnosis of NTM infection, but IRIS should be strongly suspected if clinical and radiologic deterioration occur during an appropriate time frame after cessation of these drugs (Salvana et al., 2007).

2.6 Pulmonary manifestations in RA

Extra-articular manifestations of RA include intrathoracic lesions; parenchymal pulmonary disease; interstitial lung disease (fibrosing alveolitis); rheumatoid nodules, cryptogenic organizing pneumonia, bronchiolitis obliterans and bronchiectasis; airway disease; cricoarytenoid arthritis and obstructive airway disease; pleural disease; pleural effusion,

pneumothorax, and pleurisy; vascular disease (pulmonary hypertension and vasculitis), eosinophilic pneumonia, shrinking lung, and pulmonary amyloidosis (Anaya et al., 1995; Ganhar et al., 2007; Mori et al., 2008; Tanaka et al., 2004). It is reported that bronchial and bronchiolar changes, which include bronchiectasis, centrilobular nodules, or tree-in-bud opacities, are the most prevalent lung lesions in RA patients (Akira et al., 1999; Remy-Jardin et al., 1994). Rheumatoid PD, which includes bronchiolitis and bronchiectasis, develops in approximately 10% of RA patients. A genetic susceptibility to the development of bronchiectasis was identified for RA patients (Hillarby et al., 1993), and it has been proposed that the increased susceptibility of RA patients to pulmonary infections coupled with recurrent respiratory tract infections, which triggers immune reaction, may eventually lead to bronchiectasis and bronchiolectasis (Gauhar et al., 2007; Perez et al., 1998). Supporting this speculation, bronchiectasis was detected in HRCT scans in approximately 30% of RA patients, and represented one of the most frequent lung manifestations (Cortet et al., 1995; Hassan et al., 1995; Perez et al., 1998); however, clinically significant bronchiectasis is uncommon in RA, reportedly occurring in only 1%-3% of patients (Bryckaert et al., 1994; Shadick et al., 1994).

Bronchiectasis in RA predominantly involves the lower half of the bronchial tree (Manjunatha et al., 2010) (Fig. 3). Severe bronchiectasis typically occurs in female RA patients (Shadick et al., 1994), and the incidence of bronchiectasis in lifelong-nonsmoking RA patients with no pulmonary symptoms is 25% (Hassan et al., 1995). RA patients with bronchiectasis are 7.3 fold more likely to die during a 5-year follow-up period than the general population, 5.0 fold more likely to die than those with RA alone, and 2.4 fold more likely to die than those with bronchiectasis alone (Awinson et al., 1997). Despite this association with higher mortality, it is reported that the presence of bronchiectasis is not correlated with the severity of RA (Manjinatha et al., 2010). Bronchiectasis associated with RA can precede the development of arthritis, but may also occur during the course of the disease (Gorman et al., 2002). A relatively recent study reported that the most frequent HRCT finding in RA patients was bronchiectasis, which was observed in 41.3% of patients, with clear differences detected in early (diagnosed within 1 year; 33.8%) and longstanding RA patients (duration >3 years; 49.2%) (Mori et al., 2008). An association has also been suggested between connective tissue disorder and susceptibility to NTM (Guide & Holland,

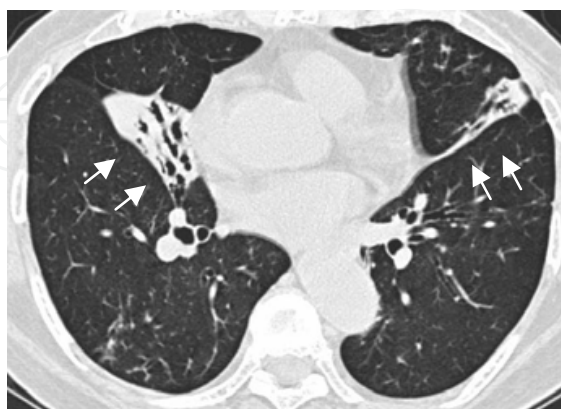


Fig. 3. HRCT image of the lungs of a 72-year-old woman suffering from RA for five years (stage 3, class 2). No NTM were detected in several analysed sputum cultures. The level of anti-GPL core IgA antibodies was negative (0.26 IU/l). Bronchiectasis was seen in the right middle lobe and lingula with infiltration (arrows).

2002). Among RA patients, NTM is more common in women >50 years of age (Gabriel, 2001; Griffith et al., 2007). According to United States Food and Drug Administration (FDA) MedWatch database, among patients with NTM disease receiving TNF- α blockers, the median age was 62 years, 65% were female, and the majority had RA. Notably, NTM infections were associated with all available TNF- α blockers, and MAC species were most commonly implicated as the infecting agents (Winthrop et al., 2009).

3. A new diagnostic tool for MAC-PD using an EIA kit detecting anti-GPL core antigen IgA antibodies

GPLs are the major cell-surface antigens of slowly growing mycobacteria, such as MAC, whereas *M. kansasii* and *M. tuberculosis* complex, and bacilli Calmette-Guerin (BCG) do not have GPLs in their cell walls (Brennan & Nikaido, 1995). The chemical structure of GPL consists of a common GPL core, with the different oligosaccharide (polar GPL) moieties linked at the Thr substituent of the core. There are 31 distinct GPL serotypes, of which the complete structures of 14 have been identified (Aspinall et al., 1995; Brennan & Nikaido, 1995; Fujiwara et al., 2007; Kitada et al., 2005). Kitada et al. (2008) established an EIA kit for the serological diagnosis of MAC-PD that is based on the levels of serum IgA antibody to the GPL core. On examination of the MAC-specific IgG, IgA, and IgM immunoglobulin subclasses, the best results were obtained by the measurement of IgA, with a sensitivity of 92.5% and specificity of 95.1% for the GPL core. The serological testing of GPL core antibody levels could accurately differentiate MAC-PD from pulmonary TB, *M. kansasii*-PD, MAC colonization/contamination, and healthy subjects (Kitada et al., 2008). Furthermore, the GPL core-based EIA for diagnosing MAC disease is not affected by prior vaccination with BCG, because GPLs are not present in *M. tuberculosis* complexes (Brennan & Nikaido, 1995). Kitada et al. (2008) also reported that the levels of GPL core antibody, as measured by the developed EIA kit, in fibrocavitary disease and the nodular bronchiectasis-type of MAC-PD were significantly higher in the latter, although higher seropositivity was detected in fibrocavitary disease patients. Using the developed EIA kit, 15.8% false-negative determinations were made for patients with MAC-PD. Kitada et al. (2008) proposed several possible explanations for the false-negative results: (1) recently diagnosed disease; (2) change of GPL core antigenicity after chemotherapy; or (3) diversity of immune responses to GPL core in individual patients, potentially related to human leukocyte antigen genes.

In recent years, the number of case reports of NTM-PD disease among patients using TNF- α blockers has increased (Maimon et al., 2007; van Ingen et al., 2007; Winthrop et al., 2008). According to recent analysis of NTM infections associated with TNF- α blockers, of 105 confirmed or probable cases, most involved women (65%) and the median age was 63 years (range 20-90 years). Among these cases, *M. avium* was the most common etiologic organism identified (49%), followed by rapidly growing mycobacteria (19%) and *M. marinum* (8%) (Winthrop et al., 2009). As previously described, the diagnosis of MAC-PD is often challenging. Furthermore, bronchiectasis and NTM infection, predominantly MAC, often coexist (Griffith et al., 2007), and it is difficult to distinguish airway involvements due to bronchiectasis or bronchiolitis from those of MAC-PD on chest radiographs or HRCT. Moreover, before initiating TNF- α blockers, further pulmonary testing with sputum is indicated to rule out active NTM disease (van Ingen et al., 2008). However, as sputum cultures are not sufficiently sensitive for the diagnosis of NTM-PD, more invasive methods, such as bronchoalveolar lavage and biopsy, may be required to assess NTM infection (Huang et al., 1999).

Unlike bronchoscopy, the EIA kit developed by Kitada et al. (2008) is a rapid (results within a few hours) and noninvasive assay with high sensitivity and specificity for diagnosing MAC-PD. Therefore, we investigated the usefulness of anti-GPL core IgA antibodies in the diagnosis of MAC-PD in RA patients. Sixty-three RA patients were enrolled: 17 with MAC-PD, including 3 with positive cultures of NTM isolates other than MAC, 16 with pulmonary abnormalities characteristic of NTM, such as bronchiectasis, on CT but undetected in sputum culture, and 30 control subjects with normal chest CT and no respiratory symptoms. The mean levels of antibodies in patients with MAC-PD, abnormal chest CT without NTM, and controls were 1.08 ± 1.42 , 0.04 ± 0.09 , and 0.09 ± 0.12 IU/l, respectively, representing a significantly higher titer of EIA antibody in the MAC-PD group than that in the abnormal chest CT without NTM group ($p=0.02$). Furthermore, the serum antibody levels were significantly higher in the patients with MAC-PD than those with abnormal chest CT without NTM when compared to controls ($p=0.02$). With the cutoff points set at 0.7 IU/l, the sensitivity and specificity of the GPL core IgA antibody between MAC-PD and control RA patients were 43% and 100%, respectively. Using receiver operating characteristic analysis for MAC-PD and control patients, the area under the curve of anti-GPL core IgA antibody titers was significant large ($p<0.005$). GPL core antigen is also useful for the rapid and less invasive serodiagnosis of MAC-PD in RA patients. Representative HRCT images of the lungs of a 32-year-old woman with RA (stage 4, class 2) suffering from sinusitis and respiratory symptoms, including phlegm and cough, are presented in Fig. 4. *M. avium* was detected in the patient's sputum culture despite treatment with ethambutol and high-dose clarithromycin. The level of anti-GPL core IgA antibodies in this patient was correspondingly positive (0.88 IU/l; cutoff value, 0.7 IU/l) (Watanabe et al., 2011). Kitada et al. (2007, 2005) described that the effects of treatment on the EIA titers were limited because anti-GPL core IgA antibody levels did not change with failure of chemotherapy, and there was no conversion to seronegative from seropositive status. However, on monitoring of the patient shown in Fig. 4, we observed that the EIA titer declined gradually and became seronegative after antimycobacterial treatment (Watanabe et al., 2011).

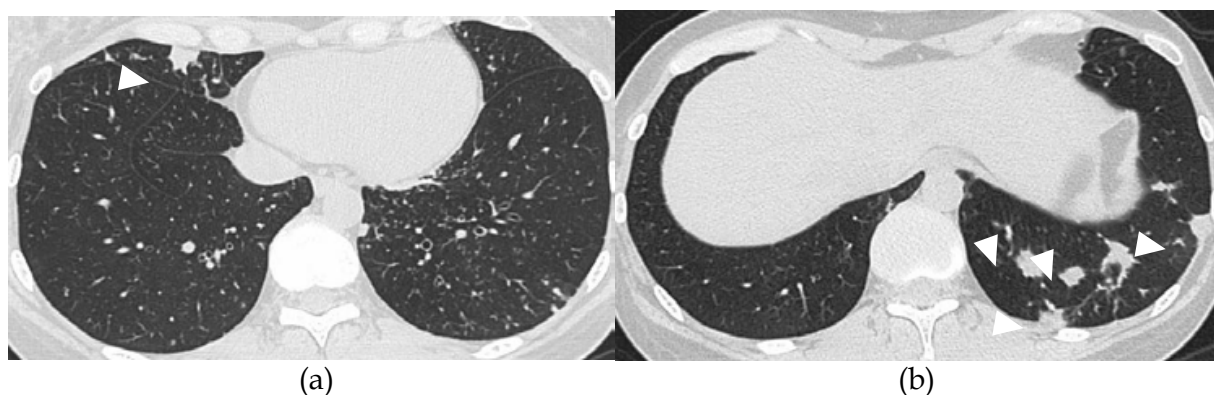


Fig. 4. HRCT images of the lungs of a 32-year-old woman with RA (stage 4, class 2) who had been suffering from sinusitis and respiratory symptoms. *M. avium* was detected in the patient's sputum culture despite of antimycobacterial treatment. Multiple nodules (arrowheads) were seen in the right middle and left lower lobes ((a) and (b)). Centrilobular tree-in-bud opacities with slight bronchiectasis were seen in the left lower lobe (a). EIA results were positive for the level of anti-GPL core IgA antibodies (0.88 IU/l).

4. Conclusion

NTM infection is one of the most important adverse events in RA patients, particularly those receiving TNF- α blockers, as infections can lead to severe or even fatal disease. NTM are associated with several types of illness, including pulmonary manifestations, with bronchiectasis representing the most frequent pulmonary involvement in RA patients. However, RA bronchiectasis is not easily distinguishable from bronchiectasis caused by NTM on HRCT, and the diagnosis of NTM-PD is often difficult due to contamination by ubiquitous environmental NTM isolates. Therefore, less invasive examination methods, in place of bronchoscopy, are needed for the diagnosis of NTM-PD. MAC is the most common pathogen of NTM-PD patients receiving TNF- α blockers. A newly developed EIA method for detecting the GPL core antigen IgA antibodies of MAC was shown to be highly specific, rapid, and have low invasiveness; thus, the EIA kit may be useful as an additional tool for the diagnosis of MAC-PD in RA patients. Although more examinations are needed to evaluate the clinical effectiveness of the EIA kit, it may be useful not only as a diagnostic tool, but also for monitoring the treatment of MAC-PD in RA patients receiving TNF- α blockers. The EIA kit may aid in the determination to restart TNF- α blockers in patients with severe RA and MAC-PD.

5. References

- Akira M, Sakatani M, Hara H. (1999). Thin-section CT findings in rheumatoid arthritis-associated lung disease: CT patterns and their courses. *J Comput Assist Tomogr*, 23, 941-948.
- Albelda SM, Kern JA, Marinelli DL, Miller WT. (1985). Expanding spectrum of pulmonary disease caused by nontuberculous mycobacteria. *Radiology*, 157, 289-296.
- Anaya JM, Diethelm L, Ortiz LA, Gutierrez M, Citera G, Welsh RA, Espinoza LR. (1995). Pulmonary involvement in rheumatoid arthritis. *Semin Arthritis Rheum*, 24, 242-254.
- Arend SM, van Soolingen D, Ottenhoff TH. (2009). Diagnosis and treatment of lung infection with nontuberculous mycobacteria. *Curr Opin Pulm Med*, 15, 201-208.
- Arend SM, Breedveld FC, van Dissel JT. (2003). TNF-alpha blockade and tuberculosis: better look before you leap. *Neth J Med*, 61, 111-119.
- Aspinall GO, Chatterjee D, Brennan PJ. (1995). The variable surface glycolipids of mycobacteria: structures, synthesis of epitopes, and biological properties. *Adv Carbohydr Chem Biochem*, 51, 169-242.
- Barker AF. (2002). Bronchiectasis. *N Engl J Med*, 346, 1383-1393.
- Bean AG, Roach DR, Briscoe H, France MP, Korner H, Sedgwick JD, Britton WJ. (1999). Structural deficiencies in granuloma formation in TNF gene-targeted mice underlie the heightened susceptibility to aerosol Mycobacterium tuberculosis infection, which is not compensated for by lymphotoxin. *J Immunol*, 162, 3504-3511.
- Beglinger C, Dudler J, Mottet C, Nicod L, Seibold F, Villiger PM, Zellweger JP. (2007). Screening for tuberculosis infection before the initiation of an anti-TNF-alpha therapy. *Swiss Med Wkly*, 137, 620-622.
- Belknap R, Reves R, Burman W. Immune reconstitution to Mycobacterium tuberculosis after discontinuing infliximab. (2005). *Int J Tuberc Lung Dis*, 9, 1057-1058.

- Boulman N, Rozenbaum M, Slobodin G, Rosner I. (2006) Mycobacterium fortuitum infection complicating infliximab therapy in rheumatoid arthritis. *Clin Exp Rheumatol*, 24, 723.
- Brennan PJ, Nikaido H. (1995). The envelope of mycobacteria. *Annu Rev Biochem*, 64, 29-63.
- Bryckaert M, Fontenay M, Lioté F, Bellucci S, Carriou R, Tobelem G. (1994). Increased mitogenic activity of scleroderma serum: inhibitory effect of human recombinant interferon-gamma. *Ann Rheum Dis*, 53, 776-779.
- Cappelluti E, Fraire AE, Schaefer OP. (2003). A case of "hot tub lung" due to Mycobacterium avium complex in an immunocompetent host. *Arch Intern Med*, 14, 163, 845-848.
- Carmona L, Gómez-Reino JJ, Rodríguez-Valverde V, Montero D, Pascual-Gómez E, Mola EM, Carreño L, Figueroa M; BIOBADASER Group. (2005) Effectiveness of recommendations to prevent reactivation of latent tuberculosis infection in patients treated with tumor necrosis factor antagonists. *Arthritis Rheum*, 52, 1766-1772.
- Centers for Disease Control and Prevention (CDC). (2004). Tuberculosis associated with blocking agents against tumor necrosis factor- α --California, 2002-2003. *MMWR Morb Mortal Wkly Rep*, 53, 683-686.
- Chalermkulrat W, Gilbey JG, Donohue JF. (2002). Nontuberculous mycobacteria in women, young and old. *Clin Chest Med*, 23, 675-686.
- Chan ED, Kaminska AM, Gill W, Chmura K, Feldman NE, Bai X, Floyd CM, Fulton KE, Huitt GA, Strand MJ, Iseman MD, Shapiro L. (2007). Alpha-1-antitrypsin (AAT) anomalies are associated with lung disease due to rapidly growing mycobacteria and AAT inhibits Mycobacterium abscessus infection of macrophages. *Scand J Infect Dis*, 39, 690-696.
- Christensen EE, Dietz GW, Ahn CH, Chapman JS, Murry RC, Anderson J, Hurst GA. (1981). Initial roentgenographic manifestations of pulmonary Mycobacterium tuberculosis, M kansasii, and M intracellulare infections. *Chest*, 80, 132-136.
- Cook JL. (2010). Nontuberculous mycobacteria: opportunistic environmental pathogens for predisposed hosts. *Br Med Bull*, 96, 45-59.
- Corbett EL, Churchyard GJ, Clayton T, Herselman P, Williams B, Hayes R, Mulder D, De Cock KM. (1999). Risk factors for pulmonary mycobacterial disease in South African gold miners. A case-control study. *Am J Respir Crit Care Med*, 159, 94-99.
- Cortet B, Flipo RM, Rémy-Jardin M, Coquerelle P, Duquesnoy B, Rémy J, Delcambre B. (1995). Use of high resolution computed tomography of the lungs in patients with rheumatoid arthritis. *Ann Rheum Dis*, 54, 815-819.
- Crum NF, Lederman ER, Wallace MR. (2005). Infections associated with tumor necrosis factor- α antagonists. *Medicine (Baltimore)*, 84, 291-302.
- Daley CL, Griffith DE. (2002). Pulmonary disease caused by rapidly growing mycobacteria. *Clin Chest Med*, 23, 623-632.
- Dhillon SS, Watanakunakorn C. (2000). Lady Windermere syndrome: middle lobe bronchiectasis and Mycobacterium avium complex infection due to voluntary cough suppression. *Clin Infect Dis*, 30, 572-575.
- Ehlers S. (2005). Tumor necrosis factor and its blockade in granulomatous infections: differential modes of action of infliximab and etanercept? *Clin Infect Dis*, 41, S199-203.

- Ehlers S, Benini J, Kutsch S, Endres R, Rietschel ET, Pfeffer K. (1999). Fatal granuloma necrosis without exacerbated mycobacterial growth in tumor necrosis factor receptor p55 gene-deficient mice intravenously infected with *Mycobacterium avium*. *Infect Immun*, 67, 3571-3579.
- Ellis SM, Hansell DM. (2002). Imaging of Non-tuberculous (Atypical) Mycobacterial Pulmonary Infection. *Clin Radiol*, 57, 661-669.
- Embil J, Warren P, Yakrus M, Stark R, Corne S, Forrest D, Hershfield E. (1997). Imonary illness associated with exposure to *Mycobacterium-avium* complex in hot tub water. Hypersensitivity pneumonitis or infection? *Chest*, 111, 813-816
- Ergin A, Hascelik G. (2004). Non tuberculous mycobacteria (NTM) in patients with underlying diseases: results obtained by using polymerase chain reaction-restriction enzyme analysis between 1997-2002. *New Microbiol*, 27, 49-53.
- Falkinham JO 3rd. (2002). Nontuberculous mycobacteria in the environment. *Clin Chest Med*, 23, 529-551.
- Falkinham JO 3rd. (1996) Epidemiology of infection by nontuberculous mycobacteria. *Clin Microbiol Rev*, 9, 177-215.
- Field SK, Cowie RL. (2006). Lung disease due to the more common nontuberculous mycobacteria. *Chest*, 129, 1653-1672.
- Fowler SJ, French J, Sreaton NJ, Foweraker J, Condliffe A, Haworth CS, Exley AR, Bilton D. (2006). Nontuberculous mycobacteria in bronchiectasis: Prevalence and patient characteristics. *Eur Respir J*, 28, 1204-1210.
- Fujiwara N, Nakata N, Maeda S, Naka T, Doe M, Yano I, Kobayashi K. (2007). Structural characterization of a specific glycopeptidolipid containing a novel N-acyl-deoxy sugar from mycobacterium intracellulare serotype 7 and genetic analysis of its glycosylation pathway. *J Bacteriol*, 189, 1099-1108.
- Gabriel SE. (2001). The epidemiology of rheumatoid arthritis. *Rheum Dis Clin North Am*, 27, 269-281.
- Garcia Vidal C, Rodríguez Fernández S, Martínez Lacasa J, Salavert M, Vidal R, Rodríguez Carballeira M, Garau J. (2005). Paradoxical response to antituberculous therapy in infliximab-treated patients with disseminated tuberculosis. *Clin Infect Dis*, 40, 756-759.
- Gardam MA, Keystone EC, Menzies R, Manners S, Skamene E, Long R, Vinh DC. (2003). Anti-tumour necrosis factor agents and tuberculosis risk: mechanisms of action and clinical management. *Lancet Infect Dis*, 3, 148-155.
- Gauhar UA, Gaffo AL, Alarcón GS. (2007). Pulmonary manifestations of rheumatoid arthritis. *Semin Respir Crit Care Med*, 28, 430-440.
- Glassroth J. (2008). Pulmonary disease due to nontuberculous mycobacteria. *Chest*, 133, 243-251.
- Goo JM, Im JG. (2002). CT of tuberculosis and nontuberculous mycobacterial infections. *Radiol Clin North Am*, 40, 73-87.
- Gorman JD, Sack KE, Davis JC Jr. (2002) Treatment of ankylosing spondylitis by inhibition of tumor necrosis factor alpha. *Engl J Med*, 346, 1349-1356.
- Griffith DE, (2010). Nontuberculous mycobacterial lung disease. *Curr Opin Infect Dis*, 23, 185-190.
- Griffith DE, Aksamit T, Brown-Elliott BA, Catanzaro A, Daley C, Gordin F, Holland SM, Horsburgh R, Huitt G, Iademarco MF, Iseman M, Olivier K, Ruoss S, von Reyn CF,

- Wallace RJ Jr, Winthrop K; ATS Mycobacterial Diseases Subcommittee; American Thoracic Society; Infectious Disease Society of America. (2007). An official ATS/IDSA statement: diagnosis, treatment, and prevention of nontuberculous mycobacterial diseases. *Am J Respir Crit Care Med*, 2007, 175, 367-416.
- Griffith DE, Brown-Elliott BA, Langsjoen B, Zhang Y, Pan X, Girard W, Nelson K, Caccitolo J, Alvarez J, Shepherd S, Wilson R, Graviss EA, Wallace RJ Jr. (2006). Clinical and molecular analysis of macrolide resistance in Mycobacterium avium complex lung disease. *Am J Respir Crit Care Med*, 174, 928-934.
- Griffith DE, Girard WM, Wallace RJ Jr. (1993) Clinical features of pulmonary disease caused by rapidly growing mycobacteria. An analysis of 154 patients. *Am Rev Respir Dis*, 147, 1271-1278.
- Gubler JG, Salfinger M, von Graevenitz A. (1992). Pseudoepidemic of nontuberculous mycobacteria due to a contaminated bronchoscope cleaning machine. Report of an outbreak and review of the literature. *Chest*, 101, 1245-1249.
- Guide SV, Holland SM. (2002). Host susceptibility factors in mycobacterial infection. Genetics and body morphotype. *Infect Dis Clin North Am*, 16, 163-186.
- Han D, Lee KS, Koh WJ, Yi CA, Kim TS, Kwon OJ. (2003). Radiographic and CT findings of nontuberculous mycobacterial pulmonary infection caused by Mycobacterium abscessus. *Am J Roentgenol*, 181, 513-7.
- Hartman TE, Swensen SJ, Williams DE. (1993). Mycobacterium avium-intracellulare complex: evaluation with CT. *Radiology*, 187, 23-26.
- Hassan WU, Keaney NP, Holland CD, Kelly CA. (1995). High resolution computed tomography of the lung in lifelong non-smoking patients with rheumatoid arthritis. *Ann Rheum Dis*, 54, 308-310.
- Haverkamp MH, van Dissel JT, Holland SM. (2006). Human host genetic factors in nontuberculous mycobacterial infection: lessons from single gene disorders affecting innate and adaptive immunity and lessons from molecular defects in interferon-gamma-dependent signaling. *Microbes Infect*, 8, 1157-1166.
- Haverkort F; Australian Mycobacterium Reference Laboratory Network; Special Interest Group in Mycobacteria within the Australian Society for Microbiology. (2003). National atypical mycobacteria survey, 2000. *Commun Dis Intell*, 27, 180-189.
- Hillarby MC, McMahon MJ, Grennan DM, Cooper RG, Clarkson RW, Davies EJ, Sanders PA, Chattopadhyay C, Swinson D. (1993) HLA associations in subjects with rheumatoid arthritis and bronchiectasis but not with other pulmonary complications of rheumatoid disease. *Br J Rheumatol*, 32, 794-797.
- Hollings NP, Wells AU, Wilson R, Hansell DM. (2002). Comparative appearances of nontuberculous mycobacteria species: a CT study. *Eur Radiol*, 12, 2211-2217.
- Huang JH, Kao PN, Adi V, Ruoss SJ. (1999). Mycobacterium avium-intracellulare pulmonary infection in HIV-negative patients without preexisting lung disease: diagnostic and management limitations. *Chest*, 115, 1033-1040.
- Inderlied CB, Kemper CA, Bermudez LE. (1993). The Mycobacterium avium complex. *Clin Microbiol Rev*, 6, 266-310.
- Iseman MD, Buschman DL, Ackerson LM. (1991). Pectus excavatum and scoliosis. Thoracic anomalies associated with pulmonary disease caused by Mycobacterium avium complex. *Am Rev Respir Dis*, 144, 914-916.


- Jacobs M, Togbe D, Fremond C, Samarina A, Allie N, Botha T, Carlos D, Parida SK, Grivennikov S, Nedospasov S, Monteiro A, Le Bert M, Quesniaux V, Ryffel B. (2007). Tumor necrosis factor is critical to control tuberculosis infection. *Microbes Infect*, 9, 623-628.
- Jarzebowski JA, Young MB. (2008). Nontuberculous mycobacterial infections. *Arch Pathol Lab Med*, 132, 1333-1341.
- Jenkins PA, Campbell IA, Banks J, Gelder CM, Prescott RJ, Smith AP. (2008). Clarithromycin vs ciprofloxacin as adjuncts to rifampicin and ethambutol in treating opportunist mycobacterial lung diseases and an assessment of Mycobacterium vaccae immunotherapy. *Thorax*, 63, 627-34.
- Kahana LM, Kay JM, Yakrus MA, Wasserman S. (1997). Mycobacterium avium complex infection in an immunocompetent young adult related to hot tub exposure. *Chest*, 111, 242-245.
- Keane J, Bresnihan B. (2008). Tuberculosis reactivation during immunosuppressive therapy in rheumatic diseases: diagnostic and therapeutic strategies. *Curr Opin Rheumatol*, 20, 443-449.
- Keane J, Gershon S, Wise RP, Mirabile-Levens E, Kasznica J, Schwieterman WD, Siegel JN, Braun MM. (2001). Tuberculosis associated with infliximab, a tumor necrosis factor alpha-neutralizing agent. *N Engl J Med*, 345, 1098-1104.
- Keane J. (2005). TNF-blocking agents and tuberculosis: new drugs illuminate an old topic. *Rheumatology (Oxford)*, 44, 714-720.
- Khoor A, Leslie KO, Tazelaar HD, Helters RA, Colby TV. (2001). Diffuse pulmonary disease caused by nontuberculous mycobacteria in immunocompetent people (hot tub lung). *Am J Clin Pathol*, 115, 755-762.
- Kim TS, Koh WJ, Han J, Chung MJ, Lee JH, Lee KS, Kwon OJ. (2005). Hypothesis on the evolution of cavitary lesions in nontuberculous mycobacterial pulmonary infection: thin-section CT and histopathologic correlation. *Am J Roentgenol*, 184, 1247-1252.
- Kindler V, Sappino AP, Grau GE, Piguet PF, Vassalli P. (1989). The inducing role of tumor necrosis factor in the development of bactericidal granulomas during BCG infection. *Cell*, 56, 731-740.
- Kitada S, Kobayashi K, Ichiyama S, Takakura S, Sakatani M, Suzuki K, Takashima T, Nagai T, Sakurabayashi I, Ito M, Maekura R; MAC Serodiagnosis Study Group. (2008). Serodiagnosis of Mycobacterium avium-complex pulmonary disease using an enzyme immunoassay kit. *Am J Respir Crit Care Med*, 177, 793-797.
- Kitada S, Maekura R, Toyoshima N, Naka T, Fujiwara N, Kobayashi M, Yano I, Ito M, Kobayashi K. (2005). Use of glycopeptidolipid core antigen for serodiagnosis of mycobacterium avium complex pulmonary disease in immunocompetent patients. *Clin Diagn Lab Immunol*, 12, 44-51.
- Koh WJ, Kwon OJ. (2005) Mycobacterium avium complex lung disease and panhypopituitarism. *Mayo Clin Proc*, 80, 961-962.
- Koh WJ, Lee KS, Kwon OJ, Jeong YJ, Kwak SH, Kim TS. (2005). Bilateral bronchiectasis and bronchiolitis at thin-section CT: diagnostic implications in nontuberculous mycobacterial pulmonary infection. *Radiology*, 235, 282-288.
- Kubo K, Yamazaki Y, Hachiya T, Hayasaka M, Honda T, Hasegawa M, Sone S. (1998). Mycobacterium avium-intracellulare pulmonary infection in patients without known predisposing lung disease. *Lung*, 176, 381-391.

- Ledingham J, Wilkinson C, Deighton C. (2005). British Thoracic Society (BTS) recommendations for assessing risk and managing tuberculosis in patients due to start anti-TNF- α treatments. *Rheumatology (Oxford)*, 44, 1205-1206.
- Lubberts E. (2008). IL-17/Th17 targeting: on the road to prevent chronic destructive arthritis? *Cytokine*, 41, 84-91
- Lynch DA, Simone PM, Fox MA, Bucher BL, Heinig MJ. (1995). CT features of pulmonary Mycobacterium avium complex infection. *J Comput Assist Tomogr*, 19, 353-360.
- Maimon N, Brunton J, Chan AK, Marras TK. (2007). Fatal pulmonary Mycobacterium xenopi in a patient with rheumatoid arthritis receiving etanercept. *Thorax*, 62, 739-740.
- Manjunatha YC, Seith A, Kandpal H, Das CJ. (2010). Rheumatoid arthritis: spectrum of computed tomographic findings in pulmonary diseases. *Curr Probl Diagn Radiol*, 39, 235-46.
- Marie I, Heliot P, Roussel F, Hervé F, Muir JF, Levesque H. (2005). Fatal Mycobacterium peregrinum pneumonia in refractory polymyositis treated with infliximab. *Rheumatology (Oxford)*, 44, 1201-1202.
- Martin-Casabona N, Bahrmand AR, Bennedsen J, Thomsen VO, Curcio M, Fauville-Dufaux M, Feldman K, Havelkova M, Katila ML, Köksalan K, Pereira MF, Rodrigues F, Pfyffer GE, Portaels F, Urgell JR, Rüscher-Gerdes S, Tortoli E, Vincent V, Watt B; Spanish Group for Non-Tuberculosis Mycobacteria. (2004). Non-tuberculous mycobacteria: patterns of isolation. A multi-country retrospective survey. *Int J Tuberc Lung Dis*, 8, 1186-1193.
- Maugein J, Dailloux M, Carbonnelle B, Vincent V, Grosset J; French Mycobacteria Study Group. (2005). Sentinel-site surveillance of Mycobacterium avium complex pulmonary disease. *Eur Respir J*, 26, 1092-1096.
- McGrath EE, Blades Z, McCabe J, Jarry H, Anderson PB. (2010). Nontuberculous mycobacteria and the lung: from suspicion to treatment. *Lung*, 188, 269-282.
- McInnes IB, Liew FY. (2005). Cytokine networks--towards new therapies for rheumatoid arthritis. *Nat Clin Pract Rheumatol*, 1, 31-39.
- Mdluli K, Swanson J, Fischer E, Lee RE, Barry CE 3rd. (1998). Mechanisms involved in the intrinsic isoniazid resistance of Mycobacterium avium. *Mol Microbiol*, 27, 1223-1233.
- Moore EH. (1993). Atypical mycobacterial infection in the lung: CT appearance. *Radiology*, 187, 777-782.
- Mori S, Cho I, Koga Y, Sugimoto M. (2008). Comparison of pulmonary abnormalities on high-resolution computed tomography in patients with early versus longstanding rheumatoid arthritis. *J Rheumatol*, 35, 1513-1521.
- Morita H, Usami I, Torii M, Nakamura A, Kato T, Kutsuna T, Niwa T, Katou K, Itoh M. Isolation of nontuberculous mycobacteria from patients with pneumoconiosis. (2005). *J Infect Chemother*, 11, 89-92.
- Morrissey BM. (2007). Pathogenesis of bronchiectasis. *Clin Chest Med*, 28, 289-296.
- Mufti AH, Toye BW, Mckendry RR, Angel JB. (2005) Mycobacterium abscessus infection after use of tumor necrosis factor alpha inhibitor therapy: case report and review of infectious complications associated with tumor necrosis factor alpha inhibitor use. *Diagn Microbiol Infect Dis*, 53, 233-238.
- Mutlu GM, Mutlu EA, Bellmeyer A, Rubinstein I. (2006). Pulmonary adverse events of anti-tumor necrosis factor-alpha antibody therapy. *Am J Med*, 119, 639-646.

- Obayashi Y, Fujita J, Suemitsu I, Kamei T, Nii M, Takahara J. (1999). Successive follow-up of chest computed tomography in patients with Mycobacterium avium-intracellulare complex. *Respir Med*, 93, 11-15.
- Okubo H, Iwamoto M, Yoshio T, Okazaki H, Kato T, Bandoh M, Minota S. (2005). Rapidly aggravated Mycobacterium avium infection in a patient with rheumatoid arthritis treated with infliximab. *Mod Rheumatol*, 15, 62-64.
- Okumura M, Iwai K, Ogata H, Ueyama M, Kubota M, Aoki M, Kokuto H, Tadokoro E, Uchiyama T, Saotome M, Yoshiyama T, Yoshimori K, Yoshida N, Azuma A, Kudoh S. (2008). Clinical factors on cavitary and nodular bronchiectatic types in pulmonary Mycobacterium avium complex disease. *Intern Med*, 47, 1465-1472.
- Olivier KN. (1998). Nontuberculous mycobacterial pulmonary disease. *Curr Opin Pulm Med*, 4, 148-53.
- Perez T, Remy-Jardin M, Cortet B. (1998). Airways involvement in rheumatoid arthritis: clinical, functional, and HRCT findings. *Am J Respir Crit Care Med*, 157, 1658-1665.
- Pfeffer K, Matsuyama T, Kündig TM, Wakeham A, Kishihara K, Shahinian A, Wiegmann K, Ohashi PS, Krönke M, Mak TW. (1993). Mice deficient for the 55 kd tumor necrosis factor receptor are resistant to endotoxic shock, yet succumb to L. monocytogenes infection. *Cell*, 73, 457-467.
- Piersimoni C, Scarparo C. (2008) Pulmonary infections associated with non-tuberculous mycobacteria in immunocompetent patients. *Lancet Infect Dis*, 8, 323-334.
- Primack SL, Logan PM, Hartman TE, Lee KS, Müller NL. (1995). Pulmonary tuberculosis and Mycobacterium avium-intracellulare: a comparison of CT findings. *Radiology*, 194, 413-417.
- Prince DS, Peterson DD, Steiner RM, Gottlieb JE, Scott R, Israel HL, Figueroa WG, Fish JE. (1989). Infection with Mycobacterium avium complex in patients without predisposing conditions. *N Engl J Med*, 321, 863-868.
- Reich JM, Johnson RE. (1992). Mycobacterium avium complex pulmonary disease presenting as an isolated lingular or middle lobe pattern. The Lady Windermere syndrome. *Chest*, 101, 1605-1609.
- Reich JM, Johnson RE. (1991). Mycobacterium avium complex pulmonary disease. Incidence, presentation, and response to therapy in a community setting. *Am Rev Respir Dis*, 143, 1381-1385.
- Remy-Jardin M, Remy J, Cortet B, Mauri F, Delcambre B. (1994). Lung changes in rheumatoid arthritis: CT findings. *Radiology*, 193, 375-382.
- Saag KG, Teng GG, Patkar NM, Anuntiyo J, Finney C, Curtis JR, Paulus HE, Mudano A, Pisu M, Elkins-Melton M, Outman R, Allison JJ, Suarez Almazor M, Bridges SL Jr, Chatham WW, Hochberg M, MacLean C, Mikuls T, Moreland LW, O'Dell J, Turkiewicz AM, Furst DE; American College of Rheumatology. (2008). American College of Rheumatology 2008 recommendations for the use of nonbiologic and biologic disease-modifying antirheumatic drugs in rheumatoid arthritis. *Arthritis Rheum*, 59, 762-784.
- Salliot C, Dougados M, Gossec L. (2009). Risk of serious infections during rituximab, abatacept and anakinra treatments for rheumatoid arthritis: meta-analyses of randomised placebo-controlled trials. *Ann Rheum Dis*, 68, 25-32.
- Salvana EM, Cooper GS, Salata RA. (2007). Mycobacterium other than tuberculosis (MOTT) infection: an emerging disease in infliximab-treated patients. *J Infect*, 55, 484-7.

- Shadick NA, Fanta CH, Weinblatt ME, O'Donnell W, Coblyn JS. (1994). Bronchiectasis. A late feature of severe rheumatoid arthritis. *Medicine (Baltimore)*, 73, 161-170.
- Shelburne SA 3rd, Hamill RJ. (2003). The immune reconstitution inflammatory syndrome. *AIDS Rev*, 5, 67-79.
- Sonnenberg P, Murray J, Glynn JR, Thomas RG, Godfrey-Faussett P, Shearer S. (2000). Risk factors for pulmonary disease due to culture-positive *M. tuberculosis* or nontuberculous mycobacteria in South African gold miners. *Eur Respir J*, 15, 291-296.
- Stewart MW, Alvarez S, Ginsburg WW, Shetty R, McLain WC, Sleater JP. (2006). Visual recovery following *Mycobacterium chelonae* endophthalmitis. *Ocul Immunol Inflamm*, 14, 181-183.
- Stout JE. (2006). Evaluation and management of patients with pulmonary nontuberculous mycobacterial infections. *Expert Rev Anti Infect Ther*, 4, 981-993.
- Sugita Y, Ishii N, Katsuno M, Yamada R, Nakajima H. (2000). Familial cluster of cutaneous *Mycobacterium avium* infection resulting from use of a circulating, constantly heated bath water system. *Br J Dermatol*, 142, 789-793.
- Swensen SJ, Hartman TE, Williams DE. (1994) Computed tomographic diagnosis of *Mycobacterium avium-intracellulare* complex in patients with bronchiectasis. *Chest*, 105, 49-52.
- Swinson DR, Symmons D, Suresh U, Jones M, Booth J. (1997). Decreased survival in patients with co-existent rheumatoid arthritis and bronchiectasis. *Br J Rheumatol*, 36, 689-691.
- Taiwo B, Glassroth J. (2010). Nontuberculous mycobacterial lung diseases. *Infect Dis Clin North Am*, 24, 769-789.
- Tanaka D, Niwatsukino H, Oyama T, Nakajo M. (2001). Progressing features of atypical mycobacterial infection in the lung on conventional and high resolution CT (HRCT) images. *Radiat Med*, 19, 237-245.
- Tanaka E, Amitani R, Niimi A, Suzuki K, Murayama T, Kuze F. (1997) Yield of computed tomography and bronchoscopy for the diagnosis of *Mycobacterium avium* complex pulmonary disease. *Am J Respir Crit Care Med*, 155, 2041-2046.
- Tanaka N, Kim JS, Newell JD, Brown KK, Cool CD, Meehan R, Emoto T, Matsumoto T, Lynch DA. (2004). Rheumatoid arthritis-related lung diseases: CT findings. *Radiology*, 232, 81-91.
- Teo SK, Lo KL. (1992). Nontuberculous mycobacterial disease of the lungs in Singapore. *Singapore Med J*, 33, 464-466.
- Thomsen VO, Andersen AB, Miørner H. (2002). Incidence and clinical significance of nontuberculous mycobacteria isolated from clinical specimens during a 2-y nationwide survey. *Scand J Infect Dis*, 34, 648-653.
- Tortoli E. (2009). Clinical manifestations of nontuberculous mycobacteria infections. *Clin Microbiol Infect*, 15, 906-910.
- Tortoli E. (2006). The new mycobacteria: an update. *FEMS Immunol Med Microbiol*, 48, 159-178.
- Tureson C, O'Fallon WM, Crowson CS, Gabriel SE, Matteson EL. (2003). Extra-articular disease manifestations in rheumatoid arthritis: incidence trends and risk factors over 46 years. *Ann Rheum Dis*, 62, 722-727.

- van Ingen J, Boeree MJ, Dekhuijzen PN, van Soolingen D. (2008). Mycobacterial disease in patients with rheumatic disease. *Nat Clin Pract Rheumatol*, 4, 649-656.
- van Ingen J, Boeree M, Janssen M, Ullmann E, de Lange W, de Haas P, Dekhuijzen R, van Soolingen D. (2007). Pulmonary Mycobacterium szulgai infection and treatment in a patient receiving anti-tumor necrosis factor therapy. *Nat Clin Pract Rheumatol*, 3, 414-419.
- Wallis RS. (2005). Reconsidering adjuvant immunotherapy for tuberculosis. *Clin Infect Dis*, 41, 201-208.
- Wallis RS, Broder M, Wong J, Beenhouwer D. (2004). Granulomatous infections due to tumor necrosis factor blockade: correction. *Clin Infect Dis*, 39, 1254-1255.
- Wallis RS, Broder MS, Wong JY, Hanson ME, Beenhouwer DO. (2004) Granulomatous infectious diseases associated with tumor necrosis factor antagonists. *Clin Infect Dis*, 38, 1261-1265.
- Watanabe M, Banno S, Sasaki K, Naniwa T, Hayami Y, Ueda R. (2011). Serodiagnosis of Mycobacterium avium-complex pulmonary disease with an enzyme immunoassay kit that detects anti-glycopeptidolipid core antigen IgA antibodies in patients with rheumatoid arthritis. *Mod Rheumatol*, 21, 144-149.
- Wickremasinghe M, Ozerovitch LJ, Davies G, Wodehouse T, Chadwick MV, Abdallah S, Shah P, Wilson R. (2005). Non-tuberculous mycobacteria in patients with bronchiectasis. *Thorax*, 60, 1045-1051.
- Winthrop KL, Chang E, Yamashita S, Iademarco MF, LoBue PA. (2009) Nontuberculous mycobacteria infections and anti-tumor necrosis factor-alpha therapy. *Emerg Infect Dis*, 15, 1556-1561.
- Winthrop KL, Yamashita S, Beekmann SE, Polgreen PM; Infectious Diseases Society of America Emerging Infections Network. (2008). Mycobacterial and other serious infections in patients receiving anti-tumor necrosis factor and other newly approved biologic therapies: case finding through the Emerging Infections Network. *Clin Infect Dis*, 46, 1738-1740.
- Wittram C, Weisbrod GL. (2002) Mycobacterium avium complex lung disease in immunocompetent patients: radiography-CT correlation. *Br J Radiol*, 75, 340-344.
- Witty LA, Tapson VF, Piantadosi CA. (1994) Isolation of mycobacteria in patients with pulmonary alveolar proteinosis. *Medicine (Baltimore)*, 73, 103-109.
- Woodring JH, Vandiviere HM, Melvin IG, Dillon ML. (1987). Roentgenographic features of pulmonary disease caused by atypical mycobacteria. *South Med J*, 80, 1488-1497.
- Yim K, Nazeer SH, Kiska D, Rose FB, Brown D, Cynamon MH. (2004). Recurrent Mycobacterium xenopi infection in a patient with rheumatoid arthritis receiving etanercept. *Scand J Infect Dis*, 36, 150-154.



Rheumatoid Arthritis - Etiology, Consequences and Co-Morbidities

Edited by Dr. Andrew Lemmey

ISBN 978-953-307-847-2

Hard cover, 304 pages

Publisher InTech

Published online 11, January, 2012

Published in print edition January, 2012

The purpose of this book is to provide up-to-date, interesting, and thought-provoking perspectives on various aspects of research into current and potential treatments for rheumatoid arthritis (RA). This book features 16 chapters, with contributions from numerous countries (e.g. UK, USA, Japan, Sweden, Spain, Ireland, Poland, Norway), including chapters from internationally recognized leaders in rheumatology research. It is anticipated that Rheumatoid Arthritis - Etiology, Consequences and Co-Morbidities will provide both a useful reference and source of potential areas of investigation for research scientists working in the field of RA and other inflammatory arthropathies.

How to reference

In order to correctly reference this scholarly work, feel free to copy and paste the following:

Maiko Watanabe and Shogo Banno (2012). Nontuberculous Mycobacterium Infections in Rheumatoid Arthritis Patients, Rheumatoid Arthritis - Etiology, Consequences and Co-Morbidities, Dr. Andrew Lemmey (Ed.), ISBN: 978-953-307-847-2, InTech, Available from: <http://www.intechopen.com/books/rheumatoid-arthritis-etiology-consequences-and-co-morbidities/nontuberculous-mycobacterium-infections-in-rheumatoid-arthritis-patients>

INTECH

open science | open minds

InTech Europe

University Campus STeP Ri
Slavka Krautzeka 83/A
51000 Rijeka, Croatia
Phone: +385 (51) 770 447
Fax: +385 (51) 686 166
www.intechopen.com

InTech China

Unit 405, Office Block, Hotel Equatorial Shanghai
No.65, Yan An Road (West), Shanghai, 200040, China
中国上海市延安西路65号上海国际贵都大饭店办公楼405单元
Phone: +86-21-62489820
Fax: +86-21-62489821

© 2012 The Author(s). Licensee IntechOpen. This is an open access article distributed under the terms of the [Creative Commons Attribution 3.0 License](#), which permits unrestricted use, distribution, and reproduction in any medium, provided the original work is properly cited.

IntechOpen

IntechOpen