

AutoCAD for Quantitative Measurement of Cervical MPR CT Images Reconstructed in ImageViewer Interface

Hou Lisheng, Ruan Dike, Cui Hongpeng and Bai Xuedong
*Orthopaedic Department, Navy General Hospital, Beijing
The People's Republic of China*

1. Introduction

As surgical skills develop in spinal field, transpedicular screw fixation of the lower thoracic, thoracolumbar, and lumbar spines have already been performed successfully, even using freehand technique by trained surgeons. The benefits of transpedicular screw fixation are widely accepted in the thoracolumbar spinal region for very stable fixation effect. Abumi et al first introduced transpedicular screw fixation in the subaxial cervical spinal region in 1991 and reported their initial clinical results in 1994 [1]. Since then, some other spinal surgeons began to accept transpedicular screw fixation in the subaxial cervical region as one choice [5]. But whether this fixation method can be accepted widely as a routine choice has been disputed till now. The main concern comes from the potential violation of the pedicle cortices and following damages to adjacent neurovascular structures [6][12]. To diminish subaxial cervical pedicle (SCP) screw malposition ratio as low as possible and to ensure successful clinical results, the complex morphologic features and projections of subaxial cervical pedicles should be clearly understood. That is, the exact diameter, inclinations at transverse and sagittal plane, cortical thicknesses at different orientations, and cortical thicknesses adjacent to pedicle entrance should be determined before any transpedicular screw fixation was performed, even by experienced surgeons using meticulous surgical techniques[Fig.1]. Although morphologic studies of the cervical spine have been reported as a way to evaluate the feasibility and safety of the technique, many have focused on transverse diameter of the pedicles, which is far from enough [3]. Thorough understanding of the subaxial cervical spinal pedicle anatomy is mandatory to avoid injury to the vertebral artery, spinal cord or a nerve root [8][11][14].

Because of their inherent ability to render bony anatomy in three dimensions, CT scans can provide the best osseous detail of subaxial cervical pedicles. Volumetric CT could reconstruct multiplanar CT images based on raw sequential transaxial CT images [7]. Multiple planar reconstruction (MPR) CT images could provide vivid anatomic data of subaxial cervical pedicles at different planes and different orientations for further detailed study. MPR CT images can be reconstructed using the CT-machine attached Advantage Workstation. If time permitted, quantitative measurement of MPR CT images can be fulfilled using the measurement tools of the CT machine-attached Advantage Workstation. But in clinical practice, large clinical CT scanning tasks are under schedule · the Advantage

Workstation could only fulfil routine MPR reconstruction and measurement work; it is not realistic to reconstruct wanted subaxial cervical MPR CT images and to finish quantitative measurement using the measurement tools of the Workstation at every time (Fig. 2) . Also, one could not expect that a CT-machine operator could reconstruct satisfied MPR CT images and finish relative measurement as a spinal surgeon really needed. If primary MPR CT images are not qualified, reviewing or reconstructing more MPR images based on raw CT data for further observation and quantitative measurement becomes more difficult. One feasible substitute choice is to develop other software which is free of CT-machine and could fulfil reconstructing satisfied MPR CT images and quantitative measurement based on raw transaxial CT images at a free computer.

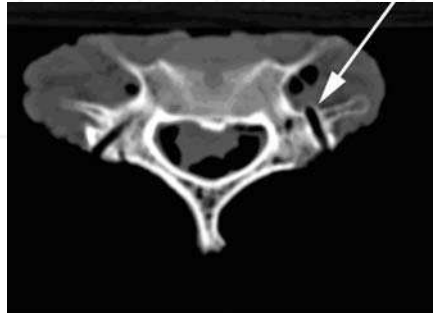


Fig. 1. Lateral wall violation of mispositioned screw trajectory

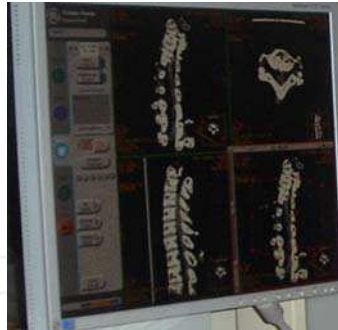

Fig. 2. It is not realistic to finish quantitative measurement using the measurement tools of the CT machine-attached Advantage workstation at every time

To some extent, we found ImageViewer software could fulfil this requirement. The software is one sharestation of Silver picture archiving and communication system (PACS) which was developed by Beijing Silver medical information Technical Corporation Limited of People's Republic of China (webdress: <http://www.minipacs.com>). The software could provide qualified electronic MPR CT images with reference ruler present based on sequential raw transaxial CT images (Fig.3). However this software also has some defects; for example, it could not finish electronic measurements on reconstructed MPR CT images. Later we found this defect could be compensated by AutoCAD software with the help of Adobe Photoshop software.

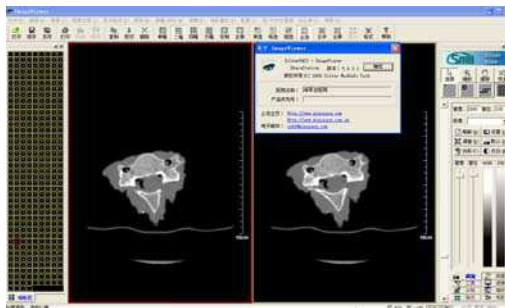


Fig. 3. Raw CT image opened in ImageViewer interface (Chinese Version)

In this chapter we describe the technique of using AutoCAD2010 software to perform quantitative electronic measurement on subaxial cervical MPR CT images which were reconstructed with Imageviewer interface of Silver PACS software at the basis of sequential raw tranaxial CT images. As the morphology of SCP and quantitative anatomical data were got, unsuitable pedicles were rejected; successful subaxial cervical transpedicular screw fixation could be finished.

2. Important

To ensure accuracy of subaxial cervical transpedicular fixation, the pedicle's morphology and orientation must be clearly understood preoperatively. Multiple planar reconstructed (MPR) CT images can provide vivid MPR images for detailed observation (Fig.4). Meanwhile, quantitative electronic measurement of these images can be fulfilled using the measurement tools of the CT machine-attached Advantage Workstation. Theoretically, all needed quantitative data could be easily obtained at Advantage Workstation. But as large routine clinical CT scanning tasks and multiple planar reconstruction works are under schedule every day, it is not realistic to do extra MPR reconstructions and quantitative electronic measurement of subaxial cervical pedicles at Advantage Workstation every time as one spinal surgeon really needs. If there exists some other software which can fulfil the multiple reconstruction work meanwhile fulfil quantitative measurement which is free of CT machine, that would be a good substitute solution method. ImageViewer software is one sharestation of Silver picture archiving and communication system (PACS), it was developed by Beijing Silver medical information Technical Corporation Limited and has been authorized to our hospital. Primarily the software was developed to provide online command dashboard screen observation of raw CT images at remote terminal computers; meanwhile it also could reconstruct qualified electronic MPR CT images with reference ruler present by reformatted method based on sequential raw transaxial CT images (Fig.2). Also the software could finish some primary linear and angular measurement on raw digital images, although not accurate. To our great pity, it could not finish electronic measurements on reconstructed MPR CT images.

To compensate this defect, we used the computer's PrtSc key to capture a snapshot of the computer screen which was exhibiting the electronic MPR CT images with reference ruler present at ImageViewer interface, and pasted it to a new opened file which was created in Adobe Photoshop CS software and used the *crop* tool to crop the needed image region and saved it as in JPG format [2]. The JPG format image was then inserted to opened AutoCAD file as raster image to finish electronic quantitative measurement. By such steps, the morphology of SCP and quantitative anatomical data could be gotten successfully.

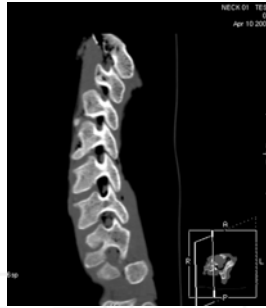

Fig. 4. Reconstructed sagittal CT images at CT machine-attached Advantage Workstation

Based on these data, we fulfilled successful subaxial cervical transpedicular screw fixation manipulation. In this chapter, we introduce the details of using AutoCAD2010 software[3] to perform quantitative electronic measurement on subaxial cervical MPR CT images which were reconstructed with ImageViewer interface of Silver PACS software at the basis of sequential raw transaxial CT images.

As the raster images opened in AutoCAD program were not real digitized images but JPG format ones. The precision is still limited, to some extent. Also, the procedures were tedious. In the near future, we hope new version of ImageViewer software can be developed to fulfil electronic quantitative measurement on MPR CT images.

3. Content

3.1 Getting raw transaxial CT images

Volumetric CT ((GE, LightSpeed 16) scanning was performed on cervical spine samples with the samples on prone position one by one. We made sure the samples' longitudinal axes were parallel to the CT machine's longitudinal axis. The scan length was kept constant as 5-mm thickness. The entire subaxial cervical region was enrolled within the scanning region (Fig. 5).

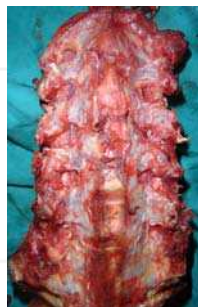

Fig. 5. Cervical spine sample

Sequential raw transaxial CT image data of each sample were then generated by interpolation reconstruction method for a 0.625-mm thickness at 0.625 mm reconstruction intervals and saved as digital imaging and communication in medicine (Dicom) format documents using the CT machine-attached Advantage Workstation software. These image

data could be stored in Disk array machine, so that they could be observed online at a remote terminal computer or downloaded to hard disc of a terminal computer through Picture Archiving and Communication System (PACS)[6]. These data could also be directly burned to a compact disc or saved to a USB (Universal Serial Bus) flash disk. Here chose to burn the data to a compact disc.

3.2 Reconstructing MPR CT images using the post-processing function of ImageViewer software

Installed Imageviewer software to its default location on our personal computer. The software could also be installed to any other location.

(1). Starting ImageViewer

ImageViewer is a very good Windows program, we could make the program window appear on-screen in numerous ways.

1. On the Windows *taskbar*, click *Start*, point to *All Programs*, point to *ImageViewer* button, then click;
2. Open the ImageViewer folder, double-click the ImageViewer program icon
3. During installing process, we chose to create an ImageViewer shortcut icon on our computer desktop. So, double-clicking the shortcut icon also could start the program.

The running ImageViewer program window was shown as Fig.6

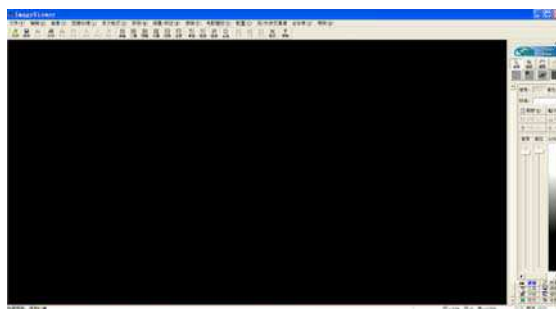


Fig. 6. The ImageViewer Interface Window

The *title bar* locates at the top of the screen, a *menu bar* just below it, a *standard toolbar* is below the *menu bar*, and a floating *integrated toolbox* pane on the right, which are very like those found in Microsoft Office System program window. If you have installed this software, what you see on your screen might not match the graphics in Fig.5 exactly. That depends whether toolbars are chosen *hide* or *show*. The settings could be toggled by clicking their relative buttons on *View menu's* subcommands.

(2). Opening raw sequential CT images

1. On the *Standard toolbar* of the ImageViewer, click the *Open* button. Or press **Ctrl + O** to open the *Open dialog box*.
2. In the *Open dialog box*, navigate to the folder that contains the sequential raw CT images.
3. Chose the sequential images that we want to open, then press **Alt + O**, or click the *Open* button, the chosen images will display (Fig.7). The image numbers displayed in the work area may vary. This depends on what display pattern we chose. Click relative *display settings* buttons on the *standard toolbar*, then the display pattern would change to fulfil our request (Fig. 8).

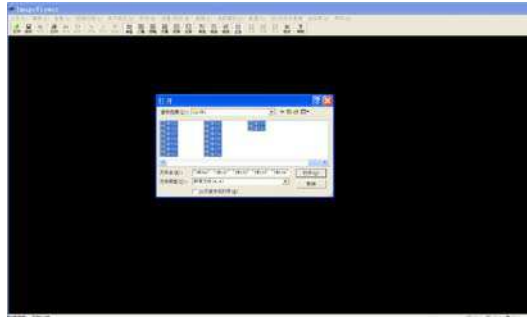


Fig. 7. To navigate to the folder which contains the raw CT images

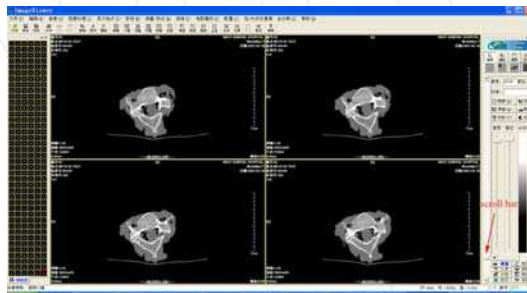


Fig. 8. Raw transaxial CT images opened at ImageViewer interface in sequence (four images in one work area).

Only a few of the images can be displayed on the screen. We could choose to display other images by clicking their relative thumbnails on the left, or by dragging the *Scroll bar* just right to the *work area*.

4. Deleting unnecessary images.

Following observation and identification, delete those raw images which are not belonged to the subaxial cervical spinal region from the folder (Fig.9~10).

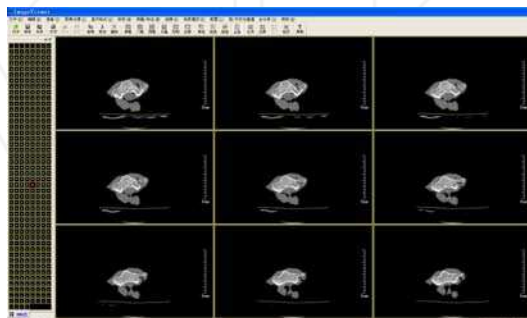


Fig. 9. Proximal transaxial images should be deleted(C1~2 spinal region, nine images in one work area)

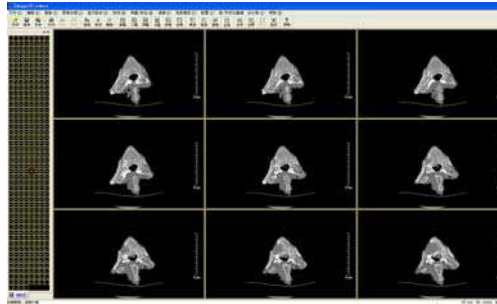


Fig. 10. Distal images should be deleted (upper thoracic spinal region)

5. Reconstructing MPR CT images

Click *delete* button on the *standard* toolbar to delete all the displayed images at the work area (the original images still exist in the folder). Then open all the images which should be included in the reconstruction region from the folder again, then clicked the *coronal/sagittal reconstruction* menu and scroll down to choose *begin reconstructing* icon and click (Fig.11). The MPR CT images with reference ruler then appear (Fig. 12). At this step, the raw axial images are used for guiding as a reference.

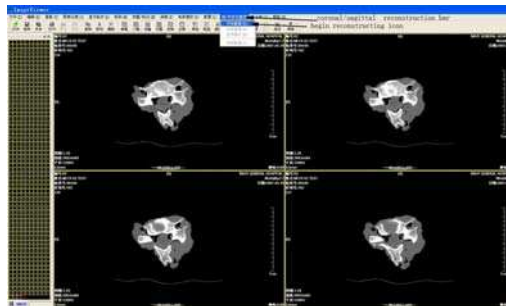


Fig. 11. To click *begin reconstructing* icon

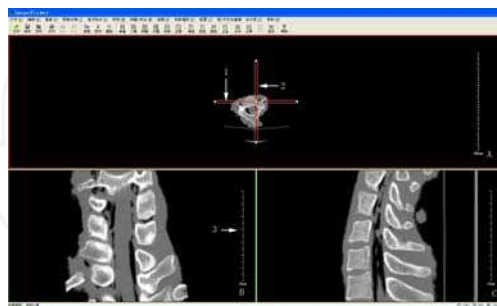


Fig. 12. Reconstructed MPR CT images at ImageViewer interface. A: Raw transverse CT image (act as localizer); B: Reconstructed coronal CT image ;C: Reconstructed sagittal CT image. 1.Localizer indicates coronal reconstructing plane; 2.Localizer indicates sagittal reconstructing plane;3.Reference ruler at coronal reconstructed CT image interface

The raw CT images chosen for reconstruction must be in sequence, neither repeated, nor interrupted images are permitted. Or the reconstruction couldn't be fulfilled.

6. Adjusting required MPR images

Mov the mouse cursor to the raw axial CT image(Fig. 13A), and choose the coronal reconstructing plane localizer (Fig.12,arrow1) then drag the coronal localizer to proper position and inclination. During this process, the reconstructed coronal CT image will change simultaneously. The same can be done to sagittal reconstructing plane localizer (Fig. 13, arrow3). By such process, the real coronal MPR image which was perpendicular to the longitudinal axis of the pedicle and sagittal MPR image which just bisects the pedicle along its longitudinal axis are reconstructed. The lateral cortex is confirmed to be the thinnest (Fig.13-B).

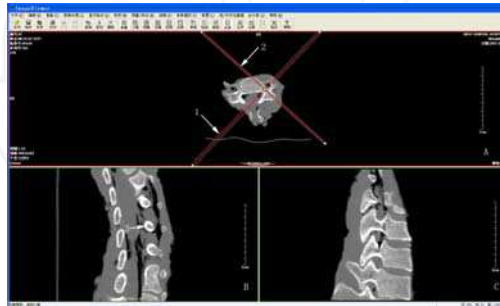


Fig. 13. To drag the localizers to suitable position and angulation to reconstruct satisfied MPR images. A: Raw transverse CT image (acted as localizer); B: Reconstructed required coronal CT image; C: Reconstructed required sagittal CT image. 1.Localizer indicates coronal reconstructing plane;2.Localizer indicates sagittal reconstructing plane.3.Reconstructed coronal image of subaxial cervical pedicle; 4.Reconstructed sagittal image of subaxial cervical pedicle

7. Adjusting the size of MPR images

Select the *zoom* tool from the floating *integrated toolbox* pane on the far right side of the work area, or click the "image" menu and scroll down to choose "zoom" subcommand icon and

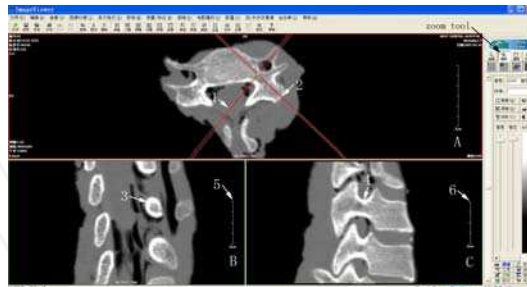


Fig. 14. To Select the zoom tool to magnify the raw CT image, the reconstructed MPR images magnified simultaneously with the reference rulers changing too.A:Magnified raw transaxial CT image;B:Reconstructed coronal CT image(magnified);C: Reconstructed sagittal CT image(magnified). 1.Localizer indicated coronal reconstructing plane;2.Localizer indicated sagittal reconstructing plane;3.Reconstructed coronal image of subaxial cervical pedicle; 4.Reconstructed sagittal image of subaxial cervical pedicle;5.Changed reference ruler at coronal MPR image interface;6.Changed reference ruler at sagittal MPR image.

click. Then move the cursor over the raw transaxial CT image area (Fig.14-A), the cursor would look like a tiny magnifying glass with a plus sign (+) in the center. Presse the left key of the mouse and drag the cursor downwards or rightwards, the raw image can be enlarged. Meanwhile, the reconstructed coronal and sagittal MPR images will enlarge with the reference rulers changing simultaneously. If we drag the cursor upwards or leftwards, the raw and reconstructed images would diminish simultaneously.

8. To reconstruct MPR images from only one vertebral raw transaxial CT images

We could also choose part of sequential raw transaxial CT images which mainly come from only real vertebra, thus the reconstructed MPR images only displayed the proper CT images of one vertebral structure (Fig.15).

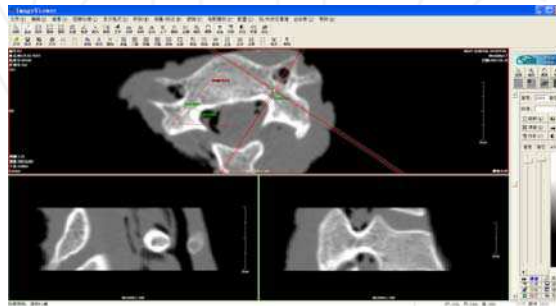


Fig. 15. Reformatted MPR CT imges from sequential raw transaxial CT images of only one cervical vertebra

(3). Simple and rough linear and angular measurement of raw transaxial CT image.

Chose *line* icon at the *measure* toolbar (Tip: we could click *View* button on the *standard* menu and then click the *measure toolbar* subcommand button to show the toolbar if it was hidden). We could finish rough linear measurement at raw transaxial CT image. If we chose *angular* icon, the angular measurement could be finished on raw CT images. But linear or angular measurement could not be fulfilled at reconstructed MPR image (Fig 15). The linear measurement precision is limited as 0mm. Angular measurement precision is 0.0°. Compared to the measurement precision that AutoCAD could provide, the values are rougher.

3.3 Creating .JPG documents of MPR CT images with Adobe Photoshop CS

(1). Capturing a snapshot of the computer screen

First press *Windows Print Screen* Key to capture a snapshot of the computer screen which exhibits the ImageViewer interface with the raw CT and reformatted CT images and copy the snapshot to the clipboard

(2). Creating a new image document with Adobe Photoshop CS.

Firstly, start Adobe Photoshop CS program to open the Photoshop interface, then press **Ctrl+N** to create a new image document. After this, the *New Dialog Box* appears. On the *New dialog box*, choose *resolution* as 300 pixels/inch, *color mode* as RGB color, *background contents* as white, then click *OK*(Fig. 16). The new document work area appears.

Following , press **Ctrl+V**, the snapshot will be pasted to the new created document as a new layer (Fig. 17).

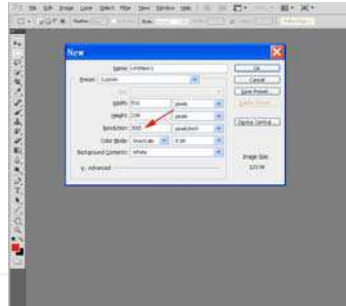


Fig. 16. To create a new document with Adobe Photoshop

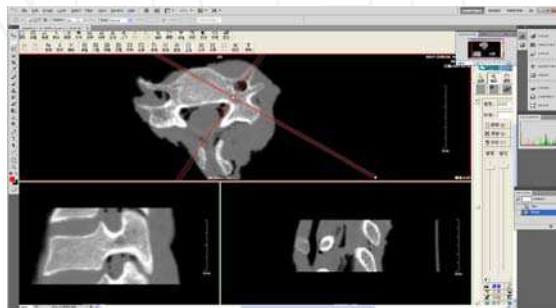


Fig. 17. To paste the snapshot in the new created document opened in Adobe Photoshop

(3). Editing image

Choose *rectangular marquee tool* at the toolbox (locate at the left side of the work area). Then move the cursor over the image window, drag the cursor to draw a rectangle around the required image area and then release the mouse button. An animated dashed line indicates that the area inside it is selected.

Click the *Image* menu and drag down to select the *crop* icon, and then click. Only the selected image is left (Fig. 18).

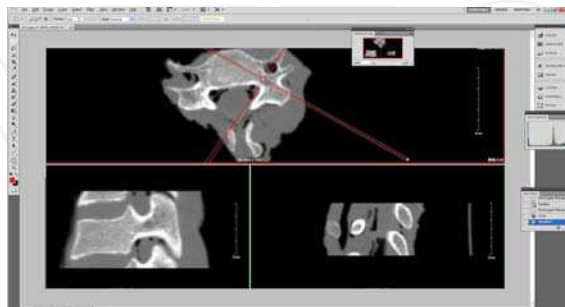


Fig. 18. Only selected area is left after clicking Crop icon

Following, click the *layer* menu and drag down to select the *merge layer* icon to merge the two layers together.

(4). Saving the merged image document as .JPG image

Click the *File* menu and drag down to select *save as* icon, the *Save As* dialog box appears, saved the image as .JPG document to destined folder for further use[3] (Fig.19).

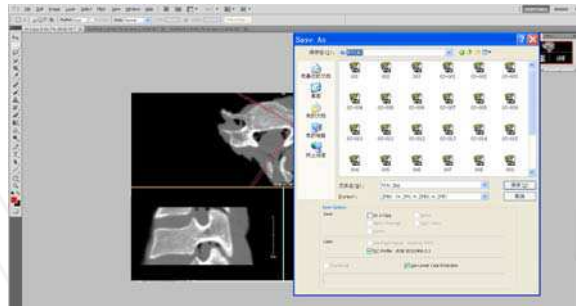


Fig. 19. To save the selected area as .JPG document

3.4 Finishing electronic quantitative measurement of MPR CT images using AutoCAD 2010

(1). Starting AutoCAD 2010

We can select one of the following to start AutoCAD:

1. Double-click the AutoCAD shortcut icon on the desktop.
2. Click the Start button→(All) Programs→Autodesk→AutoCAD 2010→ AutoCAD2010 icon, then clicked.

After this step, the *New Features Workshop* box appears, select the *Maybe Later* option on the left and click *OK* (Fig.20). The AutoCAD program window will appear.

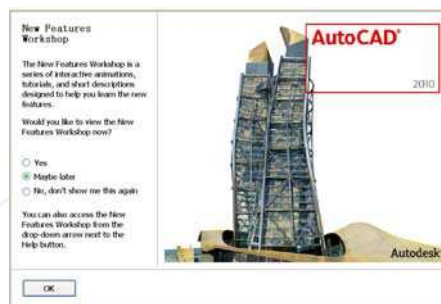


Fig. 20. To select *Maybe later* option when encounter the *New Features Workshop*

(2). (2)Inserting MPR CT image as raster image

We did the followings:

1. On the ribbon, click the *Insert* tab.
2. On the *Reference* panel, click the *attach* button (Fig. 21), the *Select Reference File* box will appear (Fig. 22).

On the "*Select Reference File*" box, navigate to the folder that contains the MPR CT images. Then browse to the raster image file (.JPG format) that we want to attach (the image we want to fulfil quantitative measurement in AutoCAD) and select it, then click *Open* (Fig.22).

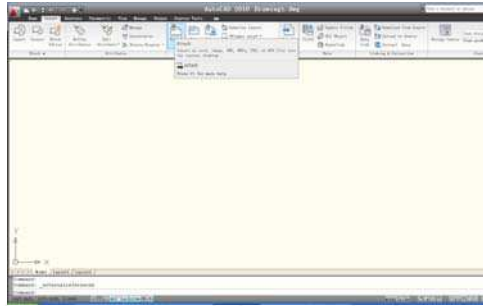

Fig. 21. To access attach command on the reference panel

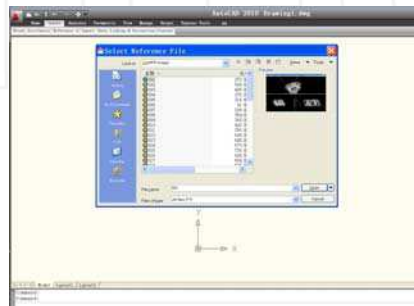


Fig. 22. To choose the image that we wanted to measure

The *Select Image File* dialog box closes, and the *Attach Image* dialog box appears. Click *Details* button to display additional information about the selected image (Fig. 23).

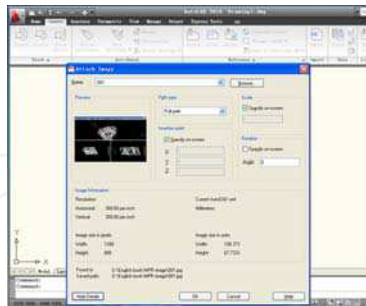


Fig. 23. To attach a raster image reference

The path to and the name of the file we selected appear in the *Found In* and *Saved Path* fields, respectively. The *Name* drop-down list allows us to select a previously attached raster image file, and *Browse* allows us to specify a different raster image file to reference. The *Image Information* area provides feedback on how the image would be scaled when it is inserted. We could also click *Hide Details* button to hide the additional information.

In the *Path Type* area, we specify the path format as full path. In the *Insertion Point* area, choose $\langle 0,0,0 \rangle$, in the *Scale* area, choose $\langle 1 \rangle$, in the *Rotation* area, choose $\langle 0 \rangle$, then press *OK*

button (we could also choose other choices). The selected MPR image appears at AutoCAD work area.

(3). Adjusting the image to proper location and proper magnified extent.

Move the cursor to work area, then right-clicked the mouse to display shortcut menu and chose *zoom* button (Fig.24).

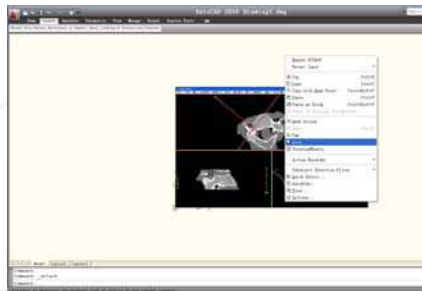


Fig. 24. To choose *zoom* shortcut

We then right-clicked the mouse again to display *zoom* menu shortcut and chose *zoom extents* button, the inserted image fitted the whole window (Fig.25).

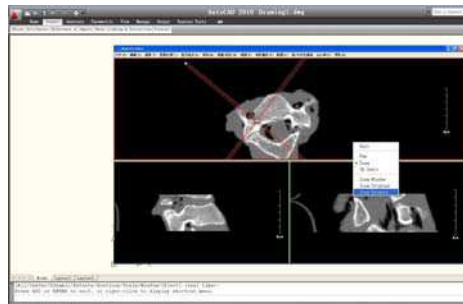


Fig. 25. To choose *zoom extents* to make the image occupy the whole active window area.

Then we moved the portion that we wanted to measure to the center of the window screen and adjusted it to suitable size by using *pan* and *zoom* icons' functions alternatively (Fig.26).

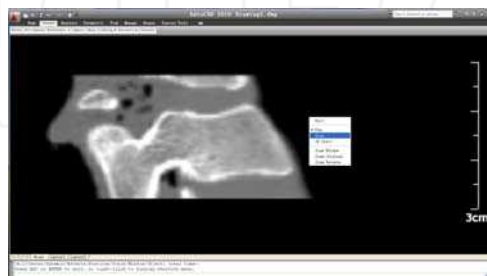


Fig. 26. To move the measured portion to the center of the active window screen by *pan* and *zoom* buttons alternatively.

(4). Adjusting reference factor for accurate measurement

1. On the ribbon, click the *Home* tab.
2. On the *Draw* panel, click the *point* button.
3. Then draw *point* objects at the start point and end point of the reference ruler of the MPR image, respectively. Later, they are chosen as specified node points for the origins of dimensions (Fig .27).

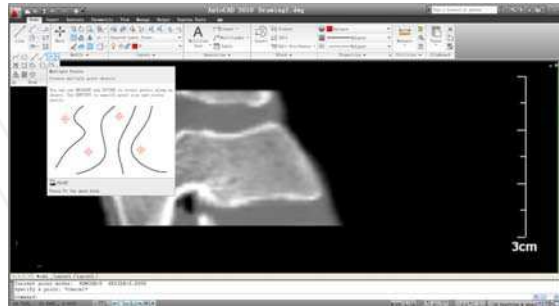


Fig. 27. To draw point objects for the origins of dimensions

4. Toggling the *Object Snaps* on for correct measurement.

Object snaps let one pick a precise point. We use *object snaps* to make sure that the dimensions are created with the correct measurement. *Node* objects are chosen as specified points. Clicking the *Object Snap* button toggles the *Object Snap* on if it is off, then right-click the *Object Snap* (OSNAP) button on the *Status Bar* and toggle the *Node* object snaps on from the shortcut menu (Fig.28).

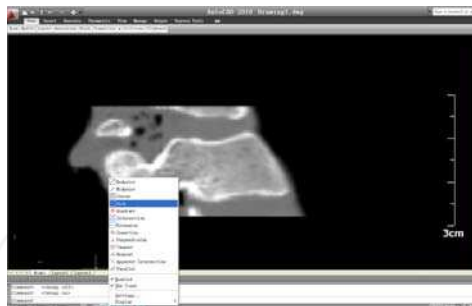


Fig. 28. To turn the *Node* object snap on from the shortcut menu.

5. Creating a new dimension style

Type *dimstyle* on the *command line* to display the *Dimension Style Manager* dialog box, then click *New* button. The *Create New Dimension Style* dialog box is displayed.

In the *New Style Name* text box, enter *reference* as the new name for the dimension style. In the *Start With* drop-down list, select *standard*. After this, click *continue* button. The *New Dimension Style* dialog box then is displayed. Click *OK* button to return to the *Dimension Style Manager* dialog box. Then click *Set Current* button to set the *reference* dimension style to current. Following click *Close* button to close the dialog box. The *reference* dimension style is applied to dimensions we created.

6. Creating a linear dimension

On the ribbon, click the *Annotate* tab. Then on the *Dimensions* panel, click the dimension flyout button and choose *linear* icon (Fig.29).

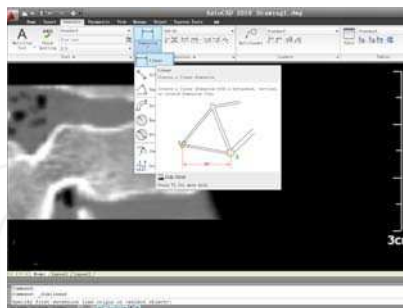


Fig. 29. To choose linear dimension

At the prompt, pick the node which had been drawn at the start location of the reference ruler for the first origin point of the dimension. After this, the prompt *Specify second extension line origin* is displayed. Then move the cursor to the second node which has been drawn at the end point of the reference ruler for the second origin point of the dimension and click. As the prompt *Specify dimension line location* is displayed, pick a point to place the dimension, the linear dimension will display. But the value is not identical to real reference ruler length (Fig.30).

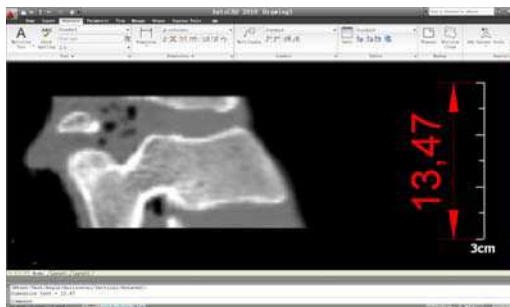


Fig. 30. Original vertical linear dimension is displayed

7. Displaying correct reference value by modifying the dimension style in use.

Type *dimstyle* on the *command* line to display the *Dimension style Manager* dialog box again. In the *Styles list* box, select *reference*, then click *Modify* button to display the *Modify Dimension Style* dialog box. In the *Modify Dimension Style dialog* box, click *Symbols and Arrows* tab, change the *arrow size* to desired size; click *Text* tab, change the text height to desired height; click *Primary Units* tab, specify *Precision* as 0.0, *suffix* as mm, specify *measurement Scale factor* to a proper value, then click *OK* to save the changes to the *reference* dimension style and to close the *Modify Dimension Style* dialog box. Any dimensions using the modified style (*reference*) are automatically updated to reflect the changes. Here when we modify the *measurement Scale factor* to 2.2240, the vertical linear dimension value is identical to the real reference ruler length (30.0mm). By changing other styles proper value, the dimensions created are shown clearly on the computer screen (Fig.31).

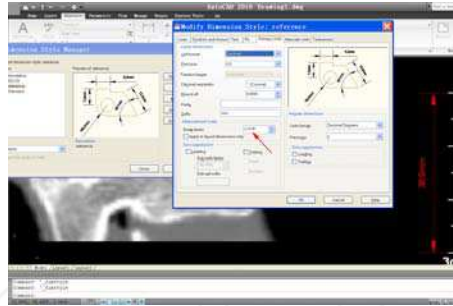

Fig. 31. To adjust *Scale factor* till the vertical linear dimension value changes identical to the reference ruler value the dimensions created can be observed clearly.

(5). Correct electronic quantitative measurement of the MPR CT images

To get correct linear distance values, operate as the followings:

1. On the ribbon, click the *Home* tab.
2. On the *Draw* panel, click the *point* button
3. Draw point objects at the MPR CT image's proper positions to identify the start point and end point for relative linear dimension display.
4. On the *Dimensions* panel, choose the aligned linear dimension button
5. Pick the *start* node and then the *end* node. Then relative aligned distance value displays (Fig.32). The value is just the one we want to get. Here the value's precision is 0.0mm. We could choose to change precision setting on the *Modify Dimension Style* dialog box as we like; Toggling *Object* snaps on and turning on the *Node* object snaps guarantee correct and precise measurement if the positions of point objects are positioned correct. As the start and end nodes are fixed, the aligned linear dimension value is determined identical, no matter what time we do the measurement.

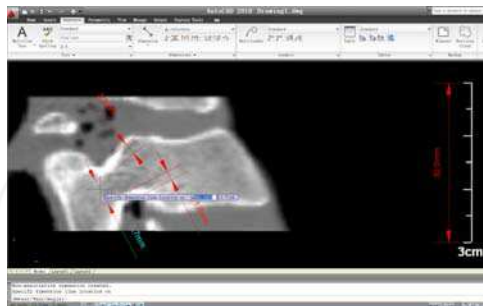


Fig. 32. Electronic quantitative measurement of the MPR sagittal CT image.

The reference ruler length at sagittal image is not identical to that at coronal image. We 'd first made correct reference value on coronal MPR CT image by modifying *scale factor* value at *Primary Units* tab in the *Modify Dimension Style* dialogue box, then repeat the same steps, the electronic quantitative measurement of the coronal CT image could be achieved successfully (Fig. 33).

Chose *Angular Dimension*, then the superior and medial angles of the pedicle can be displayed (Fig.34).

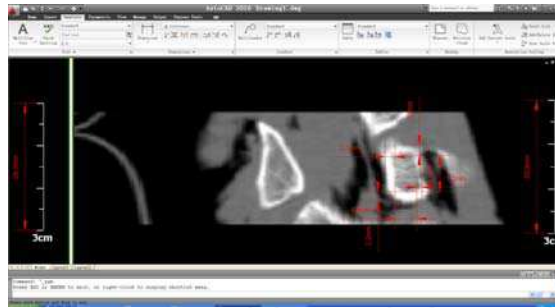


Fig. 33. To finish electronic quantitative measurement of the MPR coronal CT image

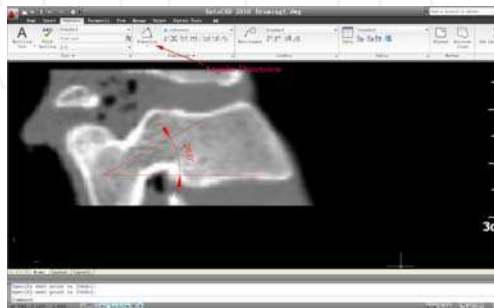


Fig. 34. To finish electronic quantitative angular measurement of the MPR sagittal CT image

We could also make correct electronic quantitative measurement of the raw Transaxial CT images if we are not satisfied with the values measured in ImageViewer software.

Repeat the above-mentioned steps, each pedicle's linear and angular quantitative data could be gotten precisely as desired.

The following table is some linear value data we got in eight subaxial cervical samples.

	MCP	LCP	SCP	ICP	ACL	ACS	ACI	PCT
C3	1.9±0.3 (1.3~2.1)	0.8±0.4 (0.3~1.2)	2.1±0.5 (1.5~2.7)	2.3±0.6 (1.9~3.2)	2.3±0.5 (1.6~2.9)	1.9±0.4 (1.6~2.7)	1.9±0.3 (1.5~2.2)	0.9±0.2 (0.8~1.2)
C4	2.3±0.7 (1.8~3.5)	1.4±0.4 (0.9~2.0)	2.4±0.5 (1.8~2.8)	2.2±0.4 (1.9~2.8)	2.2±0.3 (1.9~2.7)	2.1±0.3 (1.7~2.4)	2.5±0.6 (1.8~3.2)	0.9±0.4 (0.5~1.4)
C5	2.3±0.2 (2~2.6)	1.5±0.3 (1.1~1.8)	2.5±0.8 (1.8~3.6)	2.3±0.6 (1.9~3.3)	2.0±0.3 (1.7~2.5)	1.8±0.7 (1.3~3.3)	2.8±0.6 (1.8~3.8)	1.2±0.4 (0.8~1.8)
C6	1.9±0.2 (1.5~2.2)	1.2±0.2 (0.8~1.3)	2.4±0.6 (2.0~3.6)	2.3±0.5 (1.9~3.1)	1.7±0.2 (1.3~1.9)	1.8±0.3 (1.3~2.0)	2.8±0.4 (2.4~3.5)	1.0±0.3 (0.8~1.4)
C7	2.0±0.5 (1.5~2.8)	0.9±0.3 (0.5~1.3)	2.0±0.3 (1.6~2.5)	2.2±0.4 (1.6~2.7)	1.8±0.2 (1.6~2.2)	1.8±0.3 (1.5~2.2)	2.1±0.4 (1.6~2.5)	0.9±0.3 (0.6~1.3)

* MCP: medial cortex of pedicle. LCP:lateral cortex of pedicle SCP:superior cortex of pedicle. ICP: inferior cortex of pedicle ACL:anterior cortex of lamina ACS:anterior cortex of superior articularis ACI:anterior cortex of inferior articularis PCT posterior cortex of transverse foramen

Table 1. Cortex thickness measurement of subaxial pedicle and its adjacent structures

The results confirmed that the lateral cortex of the subaxial cervical pedicles was significantly thinner than medial, superior, and inferior counterparts. Based on above-mentioned and other relative linear and angular values, we tried some new techniques to perform subaxial cervical transpedicular manipulation by hand. All suitable pedicles were performed successfully (Fig .35).

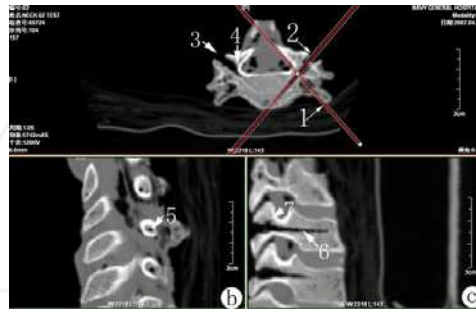


Fig. 35. Successful subaxial transpedicular manipulation

Although it seems tedious and troublesome from the above-mentioned steps description, but if one is familiar with AutoCAD, it is very easy to finish the steps mentioned-above. What we need to do is just translating the MPR image into JPG-format image and inserted it into AutoCAD interface as raster image. Other measurement steps are very simple and easy to do.

4. Conclusion

To make successful transpedicular screw fixation in subaxial cervical spinal region, the anatomical characteristics of subaxial cervical spine must be thoroughly understood. Many previous morphologic studies based on cadaveric specimens and CT images have mainly focused on transverse diameter of the pedicles [15]. Realizing the complex morphologic features of the subaxial cervical pedicles in spatial orientation and vital neurovascular structures adjacent, these studies are far from enough. To get successful subaxial cervical transpedicular screw insertion, surgeons must make in mind the anatomical features in three dimensions clearly. Volumetric CT scanning could reconstruct multiplanar CT images needed at CT-machine attached Advantage Workstation. But it is not realistic to reconstruct wanted subaxial cervical MPR CT images and to finish quantitative measurement using the measurement tools of the Workstation at every time, while a spinal surgeon who is interested in subaxial cervical transpedicular screw insertion study may not allowed to manipulate the Advantage Workstation. Even the surgeon is allowed to manipulate at rare condition, he may not familiar with the sophisticated operating procedures. ImageViewer software is a very good and easy-to-learn Windows program and has been authorized to our hospital. Every terminal computer has been installed this program. The software could reconstruct qualified MPR CT images with reference ruler present based on sequential raw CT images to fulfil primary and qualitative observation. AutoCAD program is developed primary to create accurate 2D and 3D designs, to do much more complex things that were not possible with board drafting, and the new-emerged versions are able to be installed on personal computers, have become into something that we could take on-site with us. AutoCAD program has been introduced into medical field to realize

precise quantitative measurement in recent years [7]. But using AutoCAD to realize quantitative measurement of MPR CT images are rarely reported. By selecting proper MRP CT images reconstructed using ImageViewer program and saving them as .JPG images using Adobe Photoshop program, we got raster images for further quantitative measurement with AutoCAD program. When these images were inserted into opened AutoCAD document, and proper nodes were drawn at special locations of the images, we could get precise linear and angular values, which guaranteed our entrance point and direction determination of transpedicular screw fixation. With these quantitative data in mind, we successfully finished subaxial cervical pedicle screw fixation manipulation on suitable pedicles.

There are two kinds of images: bitmap and vectorgram images [13]. Vectorgram images are essentially presentation of computer programming language based on mathematical expressions, no matter simple or sophisticated, their qualities are not influenced by magnifying or decreasing the image. While the qualities of bitmap images are determined by image size dimensions and resolution. The images in JPG format are belonged to bitmap kind. Realizing JPEG compressed images would produce some artifacts, the visualization of details of MPR CT images inserted in AutoCAD program for quantitative measurement is determined by raw .JPG image size. So determining the specified points for measurement is mainly estimated by the observers, what we introduced here is just the very likelihood estimation of special points' determination. Thus the measurement data got were non-rigid. But we think they are satisfied enough to guide the pedicle screw insertion.

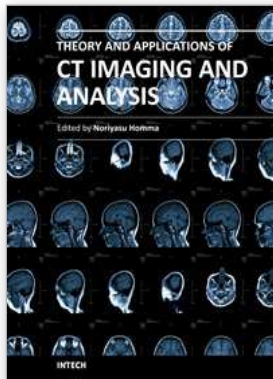
It seems tedious and troublesome from the description above, but if one is familiar with AutoCAD, it is very easy to finish the steps mentioned-above. In fact, what we need to do is just translating the MPR image into JPG-format image and inserted it into AutoCAD interface as raster image. Other measurement steps are very simple and easy to do.

5. References

- [1] Abumi K, Itoh H, Taneichi H, et al. (1994). Transpedicular screw fixation for traumatic lesions of the middle and lower cervical spine: description of the techniques and preliminary report. *J Spinal Disord.* 7(1):19-28.
- [2] Carvalho FB, Gonçalves M, Tanomaru-Filho M.(2007).Evaluation of chronic periapical lesions by digital subtraction radiography by using Adobe Photoshop CS: a technical report. *J Endod.*33(4):493-497.
- [3] Eising EG, Jentzen W, Gorges R,et al.[2007].Economic image compression of output documentation of the most frequent examinations in nuclear medicine. *Acad Radiol.*14(8):967-973.
- [4] Hussein KW, Rajion ZA, Hassan R, et al.(2009). Variations in tooth size and arch dimensions in Malay school children. *Aust Orthod J.* 25(2):163-8.
- [5] Ishikawa Y, Kanemura T, Yoshida G,et al.(2010). Clinical accuracy of three-dimensional fluoroscopy-based computer-assisted cervical pedicle screw placement: a retrospective comparative study of conventional versus computer-assisted cervical pedicle screw placement.*J Neurosurg Spine.* 13(5):606-611.
- [6] Kast E, Mohr K, Richter HP, et al. (2006). Complications of transpedicular screw fixation in the cervical spine. *Eur Spine J.* 15(3):327-334.

- [7] Le AH, Liu B, Huang HK.(2009). Integration of computer-aided diagnosis/detection (CAD) results in a PACS environment using CAD-PACS toolkit and DICOM SR.*Int J Comput Assist Radiol Surg.* 4(4):317-329.
- [8] Minn KW, Hong KY, Lee SW.(2010).Preoperative TRAM free flap volume estimation for breast reconstruction in lean patients. *Ann Plast Surg.*64(4):397-401.
- [9] Miyazaki M, Takita C, Yoshiiwa T,et al.(2010). Morphological analysis of the cervical pedicles, lateral masses, and laminae in developmental canal stenosis.*Spine (Phila Pa 1976).* 2010;35(24):E1381- E1385.
- [10] Reinhold M, Magerl F, Rieger M, et al. (2007). Cervical pedicle screw placement: feasibility and accuracy of two new insertion techniques based on morphometric data.*Eur Spine J.* 16(1):47-56.
- [11] Tan J, Lim Joon D, Fitt G, et al.(2010).The utility of multimodality imaging with CT and MRI in defining rectal tumour volumes for radiotherapy treatment planning: a pilot study.*J Med Imaging Radiat Oncol.*54(6):562-568.
- [12] Tomasino A, Parikh K, Koller H, et al. (2010). The vertebral artery and the cervical pedicle: morphometric analysis of a critical neighborhood.*J Neurosurg Spine.* 13(1):52-60.
- [13] Woo HS, Lee JM.(2009).Using Adobe Acrobat to create high-resolution line art images.*AJR Am J Roentgenol.* 193(2):W112- W117.
- [14] Yukawa Y, Kato F, Yoshihara H, et al. (2006). Cervical pedicle screw fixation in 100 cases of unstable cervical injuries:pedicle axis views obtained using fluoroscopy. *J Neurosurg Spine.* 5(6):488-493
- [15] Yusof MI, Ming LK, Abdullah MS, Yusof AH(2006). Computerized tomographic measurement of the cervical pedicles diameter in a Malaysian population and the feasibility for transpedicular fixation. *Spine (Phila Pa 1976).* 31(8):E221- E224.

INTECH



Theory and Applications of CT Imaging and Analysis

Edited by Prof. Noriyasu Homma

ISBN 978-953-307-234-0

Hard cover, 290 pages

Publisher InTech

Published online 04, April, 2011

Published in print edition April, 2011

The x-ray computed tomography (CT) is well known as a useful imaging method and thus CT images have continually been used for many applications, especially in medical fields. This book discloses recent advances and new ideas in theories and applications for CT imaging and its analysis. The 16 chapters selected in this book cover not only the major topics of CT imaging and analysis in medical fields, but also some advanced applications for forensic and industrial purposes. These chapters propose state-of-the-art approaches and cutting-edge research results.

How to reference

In order to correctly reference this scholarly work, feel free to copy and paste the following:

Hou Lisheng, Ruan Dike, Cui Hongpeng and Bai Xuedong (2011). AutoCAD for Quantitative Measurement of Cervical MPR CT Images Reconstructed in ImageViewer Interface, Theory and Applications of CT Imaging and Analysis, Prof. Noriyasu Homma (Ed.), ISBN: 978-953-307-234-0, InTech, Available from: <http://www.intechopen.com/books/theory-and-applications-of-ct-imaging-and-analysis/autocad-for-quantitative-measurement-of-cervical-mpr-ct-images-reconstructed-in-imageviewer-interfac>

INTECH

open science | open minds

InTech Europe

University Campus STeP Ri
Slavka Krautzeka 83/A
51000 Rijeka, Croatia
Phone: +385 (51) 770 447
Fax: +385 (51) 686 166
www.intechopen.com

InTech China

Unit 405, Office Block, Hotel Equatorial Shanghai
No.65, Yan An Road (West), Shanghai, 200040, China
中国上海市延安西路65号上海国际贵都大饭店办公楼405单元
Phone: +86-21-62489820
Fax: +86-21-62489821