

# Robotic Assisted Laparoscopic Hysterectomy

Khaled Sakhel  
Eastern Virginia Medical School,  
USA

## 1. Introduction

In 1495 Leonardo Da Vinci designed what was to be the first automated humanoid and it is speculated that this was to be for the entertainment of royalty. It is not known whether an actual prototype was ever built. The word robot was first introduced by the Czech writer Karel Capek in his play *Rossum's Universal Robots* (R.U.R) in 1920. The Czech word *robot* means labor or servitude. The play takes place on an island where the robot factory is producing robots to be sold to the world as cheap labor. The robots turn around and try to take over the world and end the human race. Isaac Asimov wrote a sequence of short stories in 1940 on the difficulties that would be faced if autonomous robots populated the Earth. He laid 3 laws of robotics which state "(the first law) A robot may not injure a human being, or through inaction allow a human being to come to harm, (the second law) A robot must obey the orders given it by human beings except where such orders would conflict with First Law and (the third law) A robot must protect its own existence as long as such protection does not conflict with the First and Second Law". As his writings became more intricate and complex, so did the relationship between man and robot. He then felt the need to add another law which was more basic and more important than the first three which he then called the zeroth law "A robot may not injure humanity, or through inaction, allow humanity to come to harm". This gave a broader picture of the laws governing robots.

Robotic technology is now incorporated into our everyday life which can range from the large manufacturing assembly lines to everyday household chores. The field of Medicine is no exception where robotic applications are gaining momentum.

One of the first robotic applications came from the Stanford Artificial Intelligence Lab (SAIL) in 1969. They designed a robotic arm with 6 degrees of freedom (6-dof) all-electric mechanical manipulator exclusively for computer control. The Stanford Arm and SAIL helped to develop the knowledge base which has been applied in essentially all the industrial robots.

The first commercially available robotic system was the ROBODOC which was used for orthopedic surgery. AESOP was designed to allow the surgeon greater control over visualization and to eliminate the need for an assistant holding the scope. The ZEUS robot was then developed which had a two-dimensional imaging system. Intuitive Surgical Inc (Intuitive Surgical Inc, Mountain View, CA) developed the Da Vinci robotic system and the first successful surgery was performed in 1997 in Belgium.

The Da Vinci Robotic system is now also utilized by gynecologists to perform a number of procedures including hysterectomy myomectomy, tubal reversal and sacrocolpopexy as

Source: Robot Surgery, Book edited by: Seung Hyuk Baik,  
ISBN 978-953-7619-77-0, pp. 172, January 2010, INTECH, Croatia, downloaded from SCIYO.COM

well as cancer surgeries. This chapter will discuss the use of robotic technology during hysterectomy procedures for benign conditions.

## 2. Why laparoscopic hysterectomy?

With more than 600,000 procedures performed annually in the US, hysterectomy is by far one of the most common procedures in women's health and the most common in the non-pregnant women. [1] Traditionally this procedure is performed through 3 routes which include abdominal, vaginal and laparoscopic. The abdominal route is considered to be the most invasive while the vaginal route is the least invasive. The laparoscopic approach is considered minimally invasive and sort of in between those two ends of the spectrum.

Even though the vaginal route is considered the least invasive on the patients, still around 65-70% of hysterectomy procedures are performed via the abdominal route.[1] The decision on the route is multifaceted. It includes the anticipated complexity of the surgery, size of the uterus, presence of adhesions, vaginal exposure, concomitant procedures such as oophorectomy and the surgeon's skill level. In addition, vaginal hysterectomy does not allow adequate inspection of the pelvis and abdomen.

It has been over 20 years since Reich performed the first laparoscopic hysterectomy. <sup>2</sup> Since then laparoscopic hysterectomy has undergone many changes and tools have been developed to assist with this procedure. This procedure has gained much attention and popularity. A trend toward higher rate of laparoscopic hysterectomy was observed in the 1990s with an increase from 0.3% to 9.9% and a drop in abdominal hysterectomy rates from 73.6% to 63.0% over a period of 7 years.[1] Vaginal hysterectomy remained stable at around 23-24%. Some of the reasons behind the added interest in the laparoscopic approach include the ability to survey the pelvis and easy access to the infundibulo-pelvic ligaments as compared to the vaginal route, and the potential for benefits of a minimally invasive procedure as compared to the abdominal route. Especially considering that the ovaries are concomitantly removed in 73% of these procedures. [3] When compared to abdominal hysterectomy, the laparoscopic route results in a shorter hospital stay, less abdominal wound morbidity, quicker return to normal daily activity and decreased blood loss, however at the cost of increased surgical time and urinary tract injuries. [4, 5] Similar to Vaginal hysterectomy, this procedure is highly dependent on the skill and experience of the surgeon.

## 3. Why robotic hysterectomy?

The straight laparoscopic hysterectomy is limited by the 2-dimensional view and four degrees of freedom and the most significant recent addition to the laparoscopic armamentarium is the robotic assistance. The Da Vinci Robotic System has three main components: the robotic cart (actual robot with arms), the operating console (which contains the surgeon's hand controls and foot pedals) and the endoscopic stack (or tower). With multiple arms, seven degrees of freedom and 3-dimension high definition magnified image inside the peritoneal cavity, the potential is there to complete the most daunting procedure with ease and precision. The robot will also automatically filter out any tremors in the hand of the surgeon and scale the movements to a smooth single motion. The lack of tactile feedback which the surgeon would have otherwise obtained from the laparoscopic instruments is replaced by visual feedback. Finally the surgeon is seated in an ergonomically comfortable console which makes the prolonged cases more tolerable.

Robot assisted laparoscopic hysterectomy (RALH) has been shown to be safe and effective. [6-11] A recent study by Payne et al comparing straight laparoscopic hysterectomy to RALH, noted that the robotic cohort was associated with significantly less blood loss, decreased hospital stay, but longer operative time. The intra-operative conversion rate to abdominal route from laparoscopic dropped from 9% to 4% when the robot assistance was introduced and there were no post-operative exploratory laparotomy in the robotic cohort as compared to 11% in the straight laparoscopic. [12] In another similar study by Sakhel et al, RALH was associated with less total operative room time, less blood loss and no conversion to laparotomy as compared to 11% conversion rate with straight laparoscopic hysterectomy. [13]

### 3. Preoperative preparations

As with any procedure, the preoperative preparations are of utmost importance and can help make it a success. Some form of mechanical bowel preparation should be used the day before surgery while the patient is on clear liquid diet. Even though strong data to support the practice of mechanical bowel preparation does not exist, [14] we believe this helps to deflate the bowels for visualization and also decrease the risk of contamination should the bowel be injured accidentally. On the other hand, it may be advisable to discuss this with the team who would be performing any bowel repair should you encounter bowel injury.

The patients should also be instructed to refrain from taking anything by mouth past midnight. All patients should be screened for blood thinners and medical conditions that require further workup and management. The need for pneumo-peritoneum and steep Trendelenburg may make some patients poor candidates for laparoscopic procedures. In the preoperative holding area the patients are given antibiotic prophylaxis (2 grams of cefazolin intravenously) and some form of an anti-emetic regimen especially if the patient is to be discharged the same day.

### 4. Patient positioning

After general endotracheal anesthesia is induced, the patient is positioned in the dorsal lithotomy position with the buttock just off the table. The patient must be securely positioned on the OR table with the use of shoulder braces, chest straps, underbody foam "egg-crate" mattress or a combination of those. It is advisable to use stirrups that allow for leg repositioning as this will facilitate adequate visualization of the cervix for the insertion of the uterine manipulator. The arms are padded and tucked in on the side of the patient in the neutral position with the thumb pointing up. Some form of protection of the face may be utilized and this can be in the form of a foam or gel pad. An Oro-gastric tube may be inserted to deflate the stomach especially if a left upper quadrant trocar insertion is contemplated.

### 5. Uterine manipulator

The patient may be placed in some Trendelenburg and the legs may be elevated with the use of the stirrups. An examination under anesthesia is performed to estimate the size and position of the uterus. A speculum is inserted, the cervix is held using a single tooth tenaculum and the uterus is sounded. If the cervix is to be excised with the uterus then a uterine manipulator is a must for successful colpotomy and completion of the surgery. Currently there are 3 commonly used uterine manipulators which have a colpotomy ring. They are the Vcare Uterine

Manipulator (ConMed Corporation, Utica, N.Y.), the Rumi and the Zumi Uterine Manipulators (Cooper Surgical, Trumbull, CT) with a Koh ring and balloon pneumo-occluder attached. The uterine manipulator of choice is inserted into the uterus and the uterine balloon is insufflated. The single tooth tenaculum is removed. The colpotomy ring is placed ensuring that it fits well all around the cervix by a sweep of the index and middle fingers (Fig. 1). The speculum is removed. A Foley catheter is then inserted into the bladder.

## 6. Trocars placement and docking

At this point the Trendelenburg is reversed, the patient is placed in the neutral position and the legs are put down. A pneumo-peritoneum is secured in the usual manner. This can be achieved with a Veress needle, direct umbilical trocar insertion or left upper quadrant trocar insertion. Alternatively an open technique with a Hasson trocar may be used. We prefer the direct insertion with a bladeless trocar that allows visualization of the tip. The first trocar to be inserted is the umbilical trocar. This is a 12mm bladeless to be used for the camera arm and may be placed higher in the midline abdomen to ensure a distance of 10 cm from the fundus of the uterus. The patient is then placed in maximal Trendelenburg. This is a must for procedures that involve the pelvis as this will allow the bowels to migrate into the abdomen for visualization. This should not increase the risk of the patient sliding back down the OR table nor affect oxygenation even in the morbidly obese, if the patient is securely positioned. The left and right 8mm robotic arm trocars are placed 10cm lateral and 3cm inferior to the umbilical trocar under direct laparoscopic visualization. This ensures an arc across the fundus of the uterus. If the 4<sup>th</sup> arm is needed, it is placed 10cm lateral and 3cm inferior to the left robotic trocar. A 10-12mm bladeless surgeon's assistant trocar is placed about 5-7cm superior and midway between the umbilical trocar and the right or left upper robotic trocar (Fig. 2). The robot is then docked (Fig. 3).

## 7. Operative technique

After the docking of the robot is completed, the surgeon may then leave the sterile field and move over to the surgeon console. The surgeon's assistant will then insert the camera and Endowrist instruments of choice into the robotic ports. This is performed under direct vision of the trocar by the robotic camera. Our preferred instruments include the monopolar Hot Shears on the right, the fenestrated bipolar on the left and if the 4<sup>th</sup> arm is needed a Cobra Grasper or a Tenaculum is inserted. A common variation to this set up is to use the PK Dissecting Forceps in place of the bipolar fenestrated while that is used for retraction.

The hysterectomy described is the AAGL type IVE which is defined as a totally laparoscopic removal of the uterus and cervix including vaginal cuff closure. [15]

### Step 1. Survey of the Pelvis

A comprehensive survey of the pelvic and lower abdominal structures is performed. The ureters and identified on either side.

### Step 2. Opening of the broad ligament.

The round ligament is identified, cauterized using the fenestrated bipolar and cut using the monopolar Hot shears. The anterior leaf of the broad ligament is then incised towards the bladder and the vesicouterine reflection (bladder flap) is started. The surgical assistant will either be retracting from above with a tenaculum or using the suction irrigation to provide adequate exposure and removing excess surgical smoke (Fig. 4).

**Step 3.** The ovaries

If the ovaries are to be removed, the infundibulopelvic ligament is then cauterized with bipolar and cut with shears ensuring the safety of the ureter. If the ovaries are to be conserved then the utero-ovarian ligament is cauterized and cut (Fig.5).

**Step 4.** The contra lateral side

In a similar fashion the contra lateral side is secured.

**Step 5.** The Vesico-uterine reflection

At this point a 30° down camera may be used for adequate visualization anteriorly especially if the uterus is enlarged. The anterior leaf of the broad ligament is completely incised creating the vesicouterine reflection anteriorly. The vesicouterine reflection is tented up using the fenestrated bipolar and the bladder is gently dissected off the uterus and cervix using mostly sharp dissection with the shears. This will ensure adequate visualization of the colpotomy ring (Fig. 6).

A few common variations to the above noted steps include starting with the Infundibulopelvic or Utero-ovarian ligament and working caudal toward the round ligament. This ensures adequate visualization of the broad ligament. In addition, other vessel occluding devices may be inserted from the surgeon assistant port for securing pedicles.

**Step 6.** Uterine Vessels

Once the vesico-uterine reflection is completed, the uterine arteries can be skeletonized adequately. This will ensure that the ureters are sufficiently lateral and out of harms way. The uterine arteries can then be coagulated using the bipolar and cut with the shears. It is advisable to begin coagulation at the ascending branch of the uterine artery and move caudal along the cardinal ligaments (Fig. 7).

**Step 7.** Colpotomy

The colpotomy is performed using the monopolar Hot Shears and taken all around. At one point the uterine manipulator will no longer suffice for retraction as the colpotomy progresses. At that point either the 4<sup>th</sup> arm or the surgeon assistant may grasp the uterus and provide tension for completion of the colpotomy. The specimen can be pulled through the incision if it is small enough to pass through vaginal cuff or it can be divided or morcellated first. The uterus can serve as a pneumo-occluder in the vagina or the balloon occluder can be replaced into the vagina (Fig. 8).

**Step 8.** Vaginal cuff closure

Irrigation is performed and any significant bleeding is controlled. Minimal oozing from the vaginal cuff can be controlled with the closure. Excessive cautery should be avoided at the vaginal cuff as this may predispose the patient to cuff dehiscence. The bipolar fenestrated and shears are replaced with needle holders. The vaginal cuff can then be closed with interrupted figure of eight stitches using 2-0 Vicryl incorporating the uterosacral ligaments. The needle is passed in and out of the abdomen by the surgeon assistant. Alternatively, the vaginal cuff can be closed with a running stitch and the use of Lapra-ty clips (Ethicon Endosurgery, Cincinnati, OH) (Fig. 9, 10).

**Step 9.** Repair of the trocar sites

Once the vaginal cuff repair is completed, the pelvis is irrigated and inspected for hemostasis. The instruments are then removed under vision, the robot is undocked, the trocars are removed and the abdomen is deflated. The sites of the trocars are repaired in the usual manner as per the surgeon's preference. The rate of bowel herniation at the 12mm bladeless trocar sites has been reported to be 0.7% [16] and

therefore we prefer to re-approximate the fascia of those sites separately using the Carter-Thomason Closure system XL (Inlet Medical, Eden Prairie, Minnesota) or the EndoClose (Tyco International, Inc. Norwalk, CT).

#### Step 10. Cystoscopy

While the repair of the skin incisions is being performed, the patient is given indigo carmine intravenously. Cystoscopy is then performed to ensure patency of the ureters and the integrity of the bladder. The rate of bladder and ureteral injury during laparoscopic has been reported to be 2.9% and 1.7% respectively. [17] Only one fourth of injuries to the urinary tract are detected by visual inspection. For this purpose a 30° or 70° scope can be used with saline for distention medium.

### 8. Postoperative care

Postoperatively the patient may be placed on a diet of her choice and this can be started immediately after surgery. The Foley catheter may be removed immediately especially if the patient is to be discharged. Even though abdominal trocar wound site infections are rare the patients are advised to keep them clean. The rate of vaginal cuff evisceration is 2.9% for RALH. [18] For this reason we recommend that they refrain from vaginal intercourse for 6-8 weeks. We have found that patients can be discharged the day of the procedure if she is noted to be stable 4-6 hours later or early the next day.

### 9. References:

- [1] Farquhar CM, Steiner CA. Hysterectomy rates in the United States 1990-1997. *Obstet Gynecol* 2002; 99:229.
- [2] Reich H, Decaprio J, McGlynn F. Laparoscopic hysterectomy. *J Gynecol Surg.* 1989; 5:213-216.
- [3] "Hysterectomy". National Women's Health Information Center. 2006-07-01
- [4] Nieboer TE, Johnson N, Lethaby A, Tavender E, Curr E, Garry R, van Voorst S, Mol BW, Kluivers KB. Surgical approach to hysterectomy for benign gynaecologic disease. *Cochrane Database Syst Rev.* 2009 Jul 8;(3):CD003677
- [5] Manolitsas TP, Copeland LJ, Cohn DE, Eaton LA, Fowler JM. Ureteroileoneocystostomy: the use of an ileal segment for ureteral substitution in gynecologic oncology. *Gynecol Oncol.* 2002 Jan; 84(1):110-4.
- [6] Margossian H, Falcone T. Robotically assisted laparoscopic hysterectomy and adnexal surgery. *J Laparosc Adv Surg Tech A.* 2001;11:161-165
- [7] Diaz-Arrastia C, Jurnalov C, Gomez G, Townsend C Jr. Laparoscopic hysterectomy using a computer-enhanced surgical robot. *Surg Endosc.* 2002; 16:1271-1273
- [8] Advincula AP, Reynolds RK. The use of robot-assisted laparoscopic hysterectomy in the patient with a scarred or obliterated anterior cul-de-sac. *JSLS.* 2005;9:287-291
- [9] Beste TM, Nelson KH, Daucher JA. Total laparoscopic hysterectomy utilizing a robotic surgical system. *JSLS.* 2005;9:13-15
- [10] Marchal F, Rauch P, Vandromme J, Laurent I, Lobontiu A, Ahcel B et al. Telerobotic-assisted laparoscopic hysterectomy for benign and oncologic pathologies: initial clinical experience with 30 patients. *Surg endosc.* 2005;19:826-31.
- [11] Fiorentino RP, Zepeda MA, Goldstein BH, John CR, Rettenmaier MA. Pilot study assessing robotic laparoscopic hysterectomy and patient outcomes. *J Minim Invasive Gynecol.* 2006; 13:60-63.

- [12] Payne TN, Dauterive FR. A comparison of total laparoscopic hysterectomy to robotically assisted hysterectomy: surgical outcomes in a community practice. *J Minim Invasive Gynecol.* 2008 May-Jun; 15 (3):286-91.
- [13] Sakhel K, Kirakosyan A, Lukban J, Hines J. Comparison between Robot-Assisted Laparoscopic Hysterectomy and Total Laparoscopic Hysterectomy - A Cohort Study. Presented at the AAGL annual meeting, 38<sup>th</sup> Global Congress, Orlando, November 17<sup>th</sup> 2009.
- [14] Guenaga KF, Matos D, Castro AA, Atallah AN, Wille-Jorgensen P. Mechanical bowel preparation for elective colorectal surgery. *Cochrane Database Syst Rev* 2005 Jan 25;(1):CD001544.
- [15] Olive DL, Parker WH, Cooper JM, Levine RL. The AAGL classification system for laparoscopic hysterectomy. *J Am Assoc Gynecol Laparosc.* 2000;7:9-15
- [16] Chiong E, Hegarty PK, Davis JW, Kamat AM, Pisters LL, Matin SF. Port-site Hernias Occurring After the Use of Bladeless Radially Expanding Trocars. *Urology* October 2009
- [17] Gilmour DT, Das S, Flowerdew G. Rates of urinary tract injury from gynecologic surgery and the role of intraoperative cystoscopy. *Obstet Gynecol.* 2006; 107(6):1366-72.
- [18] Robinson BL, Liao JB, Adams SF, Randall TC. Vaginal Cuff Dehiscence After Robotic Total Laparoscopic Hysterectomy *Obstet Gynecol* 2009;114(2):369-371.

## Figures

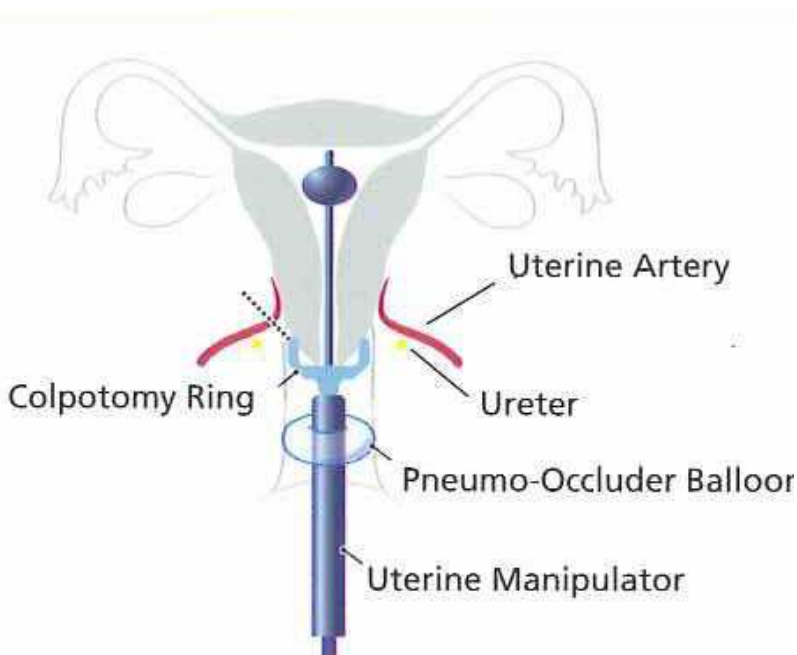


Fig. 1. Uterine Manipulator (Courtesy of Intuitive Surgical)

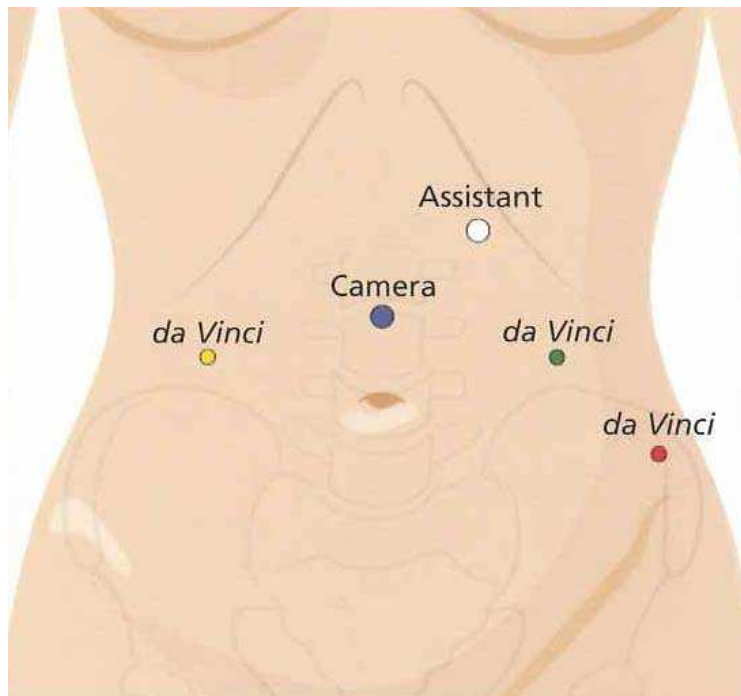


Fig. 2. Port Placement (Courtesy of Intuitive Surgical)




Fig. 3. Da Vinci Robotic System docked (Courtesy of Intuitive Surgical)



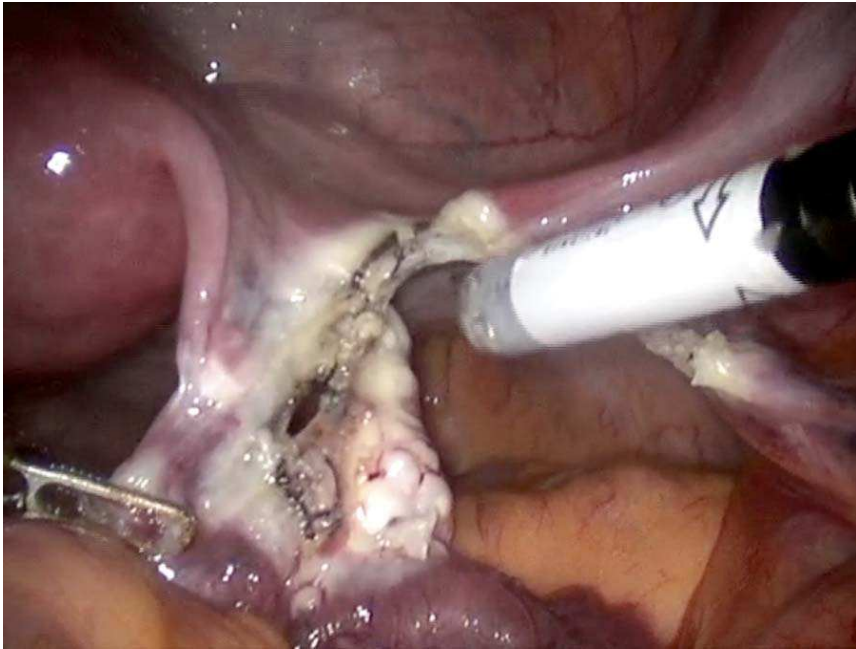


Fig. 4. Securing the round ligament

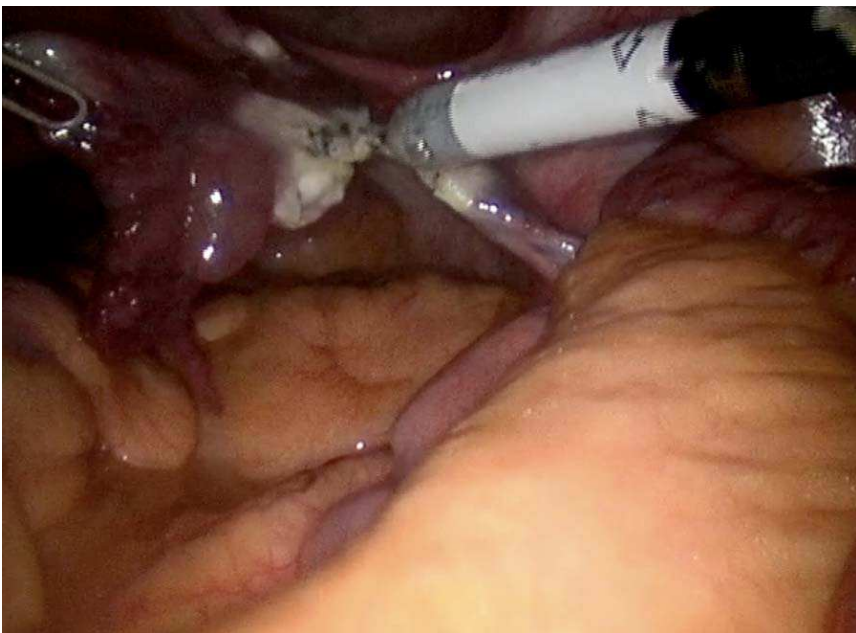

Fig. 5. Securing the infundibulo-pelvic ligament.

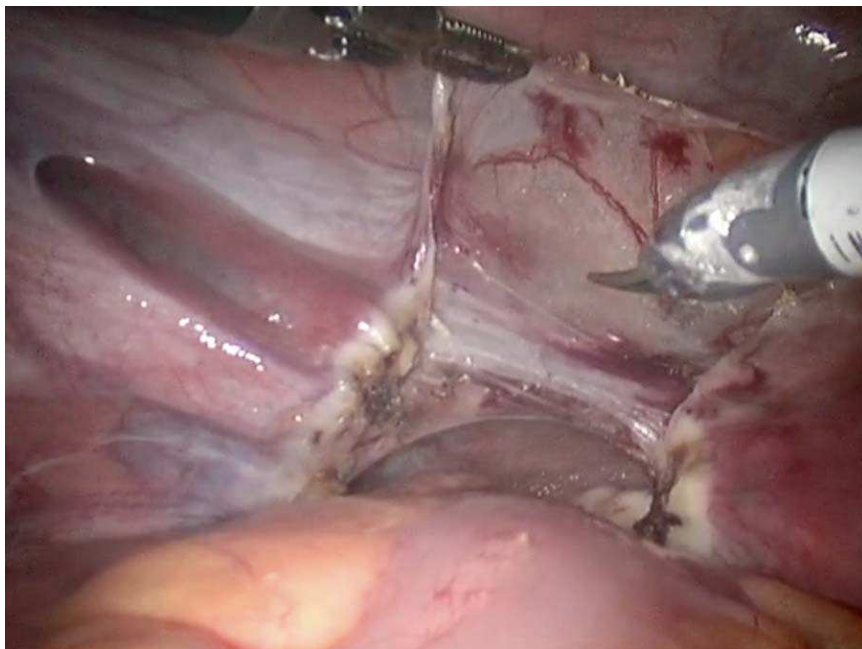


Fig. 6. Opening the broad ligament and developing the vesico-uterine reflection.

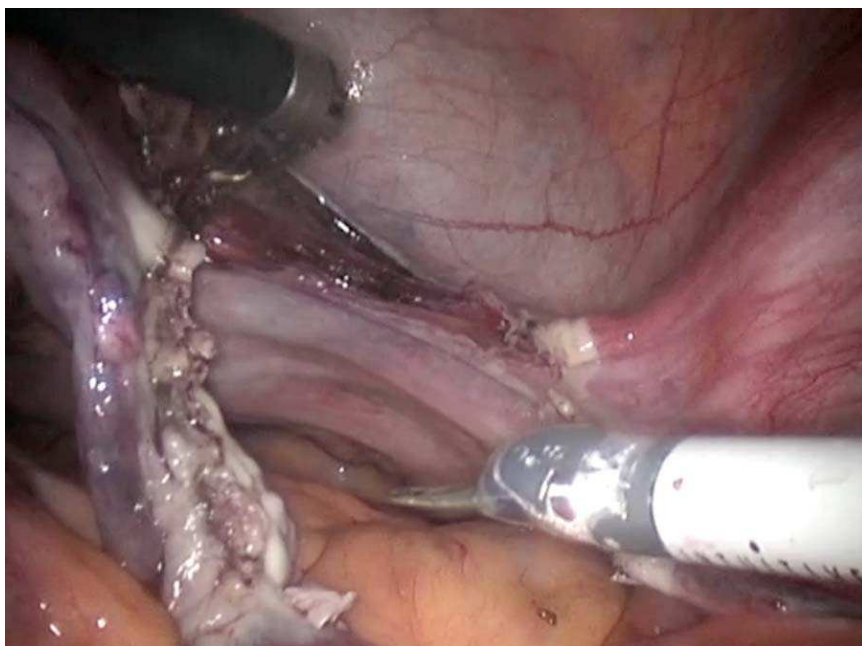

Fig. 7. Securing the ascending branch of the uterine artery

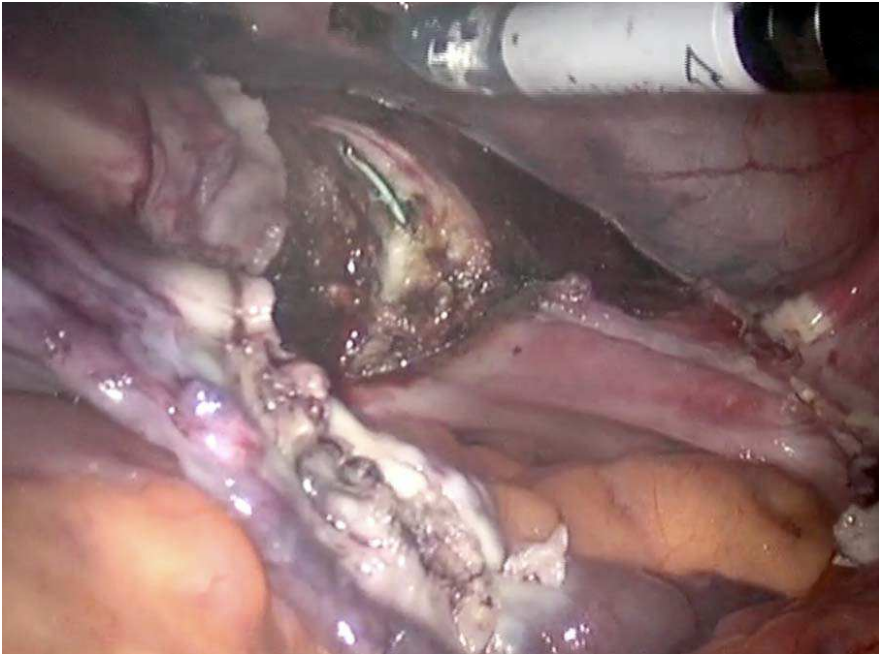


Fig. 8. Performing the colpotomy (green).

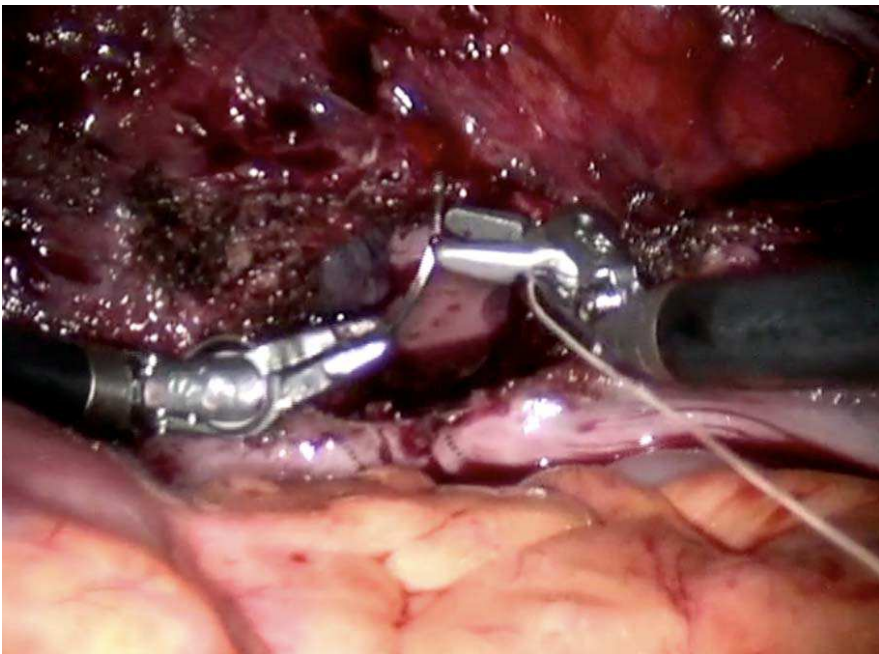


Fig. 9. Vaginal cuff closure.

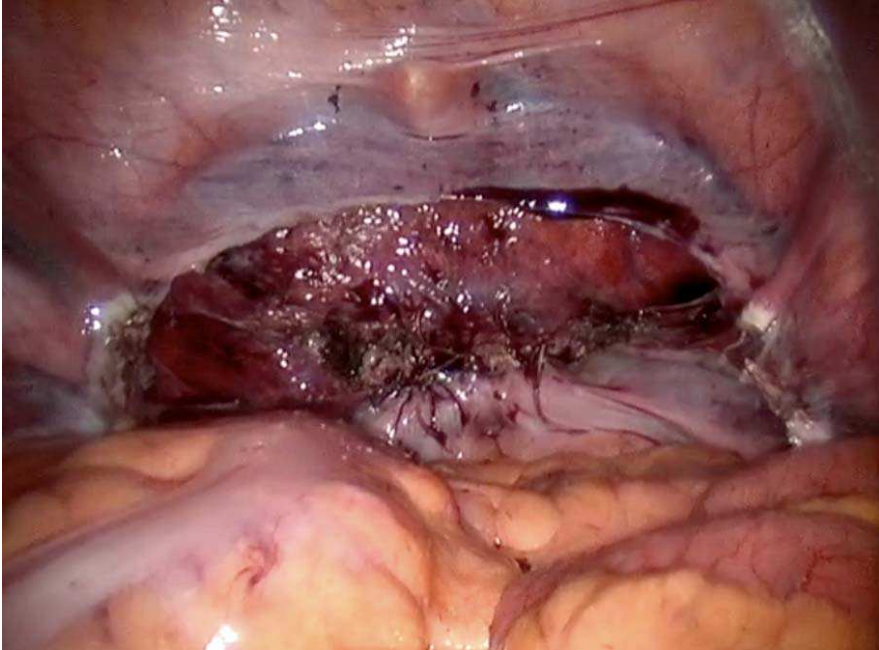


Fig. 10. Completion of the procedure with the vaginal cuff closed.



## **Robot Surgery**

Edited by Seung Hyuk Baik

ISBN 978-953-7619-77-0

Hard cover, 172 pages

**Publisher** InTech

**Published online** 01, January, 2010

**Published in print edition** January, 2010

Robotic surgery is still in the early stages even though robotic assisted surgery is increasing continuously. Thus, exact and careful understanding of robotic surgery is necessary because chaos and confusion exist in the early phase of anything. Especially, the confusion may be increased because the robotic equipment, which is used in surgery, is different from the robotic equipment used in the automobile factory. The robots in the automobile factory just follow a program. However, the robot in surgery has to follow the surgeon's hand motions. I am convinced that this In-Tech Robotic Surgery book will play an essential role in giving some solutions to the chaos and confusion of robotic surgery. The In-Tech Surgery book contains 11 chapters and consists of two main sections. The first section explains general concepts and technological aspects of robotic surgery. The second section explains the details of surgery using a robot for each organ system. I hope that all surgeons who are interested in robotic surgery will find the proper knowledge in this book. Moreover, I hope the book will perform as a basic role to create future prospectives. Unfortunately, this book could not cover all areas of robotic assisted surgery such as robotic assisted gastrectomy and pancreaticoduodenectomy. I expect that future editions will cover many more areas of robotic assisted surgery and it can be facilitated by dedicated readers. Finally, I appreciate all authors who sacrificed their time and effort to write this book. I must thank my wife NaYoung for her support and also acknowledge MiSun Park's efforts in helping to complete the book.

### **How to reference**

In order to correctly reference this scholarly work, feel free to copy and paste the following:

Khaled Sakhel (2010). Robotic Assisted Laparoscopic Hysterectomy, Robot Surgery, Seung Hyuk Baik (Ed.), ISBN: 978-953-7619-77-0, InTech, Available from: <http://www.intechopen.com/books/robot-surgery/robotic-assisted-laparoscopic-hysterectomy>

**INTECH**  
open science | open minds

#### **InTech Europe**

University Campus STeP Ri  
Slavka Krautzeka 83/A  
51000 Rijeka, Croatia  
Phone: +385 (51) 770 447  
Fax: +385 (51) 686 166

#### **InTech China**

Unit 405, Office Block, Hotel Equatorial Shanghai  
No.65, Yan An Road (West), Shanghai, 200040, China  
中国上海市延安西路65号上海国际贵都大饭店办公楼405单元  
Phone: +86-21-62489820  
Fax: +86-21-62489821



© 2010 The Author(s). Licensee IntechOpen. This chapter is distributed under the terms of the [Creative Commons Attribution-NonCommercial-ShareAlike-3.0 License](#), which permits use, distribution and reproduction for non-commercial purposes, provided the original is properly cited and derivative works building on this content are distributed under the same license.