
Percutaneous Suspension Sutures to Change the Nasal Tip

M. B. Des Fernandes

Additional information is available at the end of the chapter

<http://dx.doi.org/10.5772/56249>

1. Introduction

Although a number of procedures have been described for placement of “shaping sutures” during open and closed rhinoplasty, scant attention is given to the possibility of percutaneous placement of sutures without dissection of the skin envelop. Periodically patients will present who want minimal changes to their nose because the tip is too bulky, not well defined and the nose is longer than ideal. Many of these patients have no concerns about the bridge width and do not have a dorsal hump. This is the perfect patient to consider using the operation that will be described.

Many other patients have had an attractive straight nose when they were young and as they have aged, the nose has become coarser, broader and tends to lengthen and lose support from the septum and then droops into becoming a hooked nose. The operation that will be described specifically addresses these changes and with this surprisingly simple operation, the nose can be restored to much closer to the original.

Other patients who have had a corrective rhinoplasty develop a typical “polly-beak” deformity. By elevating and rotating the nasal cartilages one can restore a normal nasal tip projection and a straight bridge.

2. Methods and instruments

The following instruments and materials are required:

1. 11 or 15 blade scalpel
2. 18 gauge (green) needle or a 22 (yellow) spinal needle.
3. Sharp pointed fine scissors
4. Fine dissector (optional)

5. Toothed Adson's forceps.
6. Fine needle holder to tie the knot.
7. Skin hook to free the skin from the buried thread
8. 4/0 or 5/0 non-absorbable suture. This could be an elasticised suture as described by Serdev.

The procedure is usually done in an office setting on an ambulatory patient under simple local anaesthetic usually without the need for any sedation.

The guide-line markings are made on the nose with the patient sitting up to assess the degree of droop of the nose and get an impression of the amount of lift and rotation of the tip of the alar cartilages that will be required to get the ideal result and then to feel how much more the nose may comfortably be lifted to exaggerate the immediate result.

3. Standard markings

1. A dot is placed to the right side of the dorsum of the nose immediately below the osteo-cartilagenous junction of the bridge of the nose, about 4 mm from the midline. This point is chosen so that when the anchoring transfixion suture goes through the cartilaginous septum, the tract will be anterior to the anterior nasal mucosal recess inside the nose.
2. Then a line is drawn on the side of the nose directed towards the lowest part of the columella (see Fig 1).

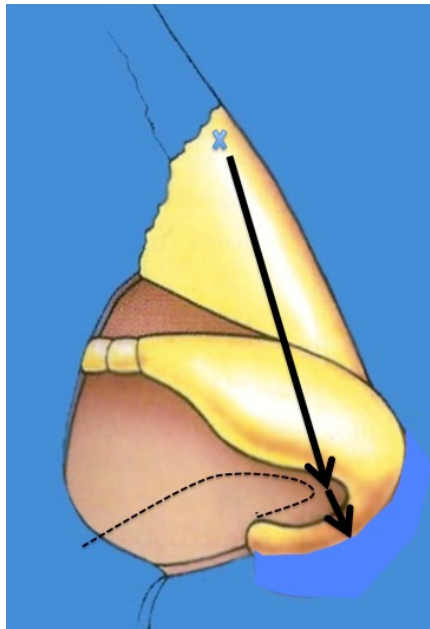


Figure 1. Showing the markings on the lateral side of the nose for the standard nose.

3. The line will traverse the soft triangle of the nostril as it courses towards the lowest part of the columella. Usually this is at the position where the columella changes angle in the “ideal” nose.
4. As one draws this line one has to take into account the shape of the lower lateral alar cartilages. (See Fig 2). Normally as seen from the front in figure 2, the line is straight downwards.




Figure 2. Showing the skin markings for the standard nose

5. However, if the cartilages are bulging and wide then one should deviate the line laterally towards the maximum width as seen from the frontal view. (See Fig 3) Generally if one presses on the lateral alar wings one can determine where this essential point is to apply medial pressure in order to narrow the nose tip. Its worth spending time familiarising yourself with these little details.
6. Then mark the midline of the columella with a vertical 3-4 mm line where the incision will be made. This incision is also dependant on where the columella will be lifted.
7. Similar markings are made on the opposite side.

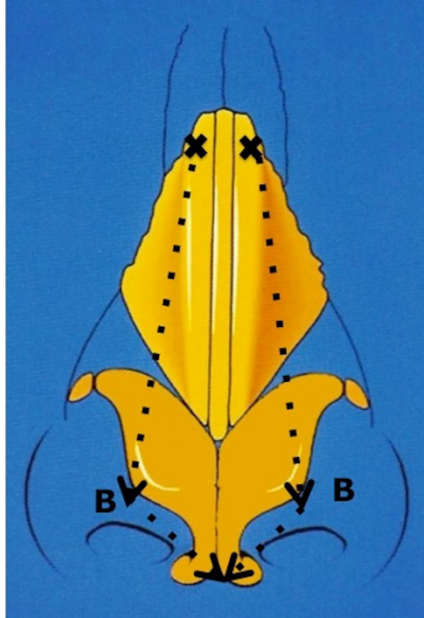


Figure 3. Showing the markings for a nose with broad alar dome cartilages.

4. Anaesthesia

An inferior orbital nerve block should be done first and in some people this gives excellent anaesthesia of the whole nose especially if the local anaesthetic is placed in the inferior orbital foramen. In other people it may be necessary to add specific block to the lateral nasal nerves as well as the nerves at the nasal spine to the columella. By blocking these nerves, anaesthesia is achieved easily and painlessly. It is advisable to check that the septal cartilage is numb by infiltrating across to the other side where the anchors will be placed.

5. Placement of the suspension sutures

1. Two stab incisions need to be made at the points marked X in figures 1 and 2 and then use the sharp pointed scissors to make sure to dissect the skin away from the cartilage that the skin is entirely free of the surrounding deep tissues. These holes should be as small as possible.
2. Make the incision on the columella and then dissect the skin away from the vertical alar cartilages in the area and extend the dissection area across into the “soft triangle” and even to the inferior edge of the lateral lower alar cartilages. By doing this one reduces the possibility of the needle passing into the nose as it is pushed across the “soft triangle” down towards the incision in the columella.
3. Insert the chosen needle perpendicularly through the incision on the right side of the nose

4. Once one reaches the layer just outside the upper lateral cartilage, change direction of the needle and point it down under the guidelines previously marked.
5. One has to distort the nose by pushing it medially and at the same time it is useful to put the Adson's forceps into the columella incision in order to retrieve the needlepoint. Make sure that the needle does not catch any tissue of the columella.
6. The needle is now positioned outside of the nasal cartilages and the non-absorbable thread (4/0 or 5/0) is passed up the needle until it protrudes through the hub at the end of the needle.
7. Pull back the needle until one reaches the entry point on the side of the nose, change direction to be perpendicular again and then push the needle through the septal cartilage to emerge through the opposite incision without catching any of the tissues attached to skin. This is the anchor so one has to be sure that the thread is not too close to the edge of the cartilage. It is easy to avoid the anterior nasal mucosal recess because it does not come into the sharp angle between the nasal septum and the upper lateral cartilages
8. Hold on to the thread and remove the needle. Most people expect that the bevel of the needle will cut the suture as it goes through the septum, but it generally never does. In doing this type of procedure for several thousands of times, the thread has been cut only twice. By this stage we have constructed more than half of the important loop that will eventually narrow, rotate and lift the alar cartilages.
9. The final stage is approached differently. The needle is now carefully inserted into the columella incision taking care not to catch any of the outer skin layer in the soft triangle of the left nostril and then pushed up to the stab incision on the left side of the nose.
10. By using the Adson's forceps one can guide the needle tip out through the stab incision without catching the surrounding soft tissue.
11. The thread is passed through the needle until it emerges from the needle hub before the needle is pulled out.
12. The suspension loop has now been created outside the upper and lower lateral alar cartilages and one can check what the nose looks like as one tightens the threads. The nose tip is lifted and the lower lateral alar cartilages are compressed towards each other medially and narrowed.
13. Examine the inside of the nostrils to be certain that the thread has not been accidentally placed medial to the alar cartilages. If this has been done and has not been detected, then it might cause a chronic infection and pain.
14. It is advisable to make two throws in the same direction so that the knot can be adjusted before the third throw which seals the knot. A double throw is recommended and altogether I recommend about six throws to ensure that the knot never slips. The knot is cut exactly on the knot so that the ends do not later protrude through the skin.
15. Always over-correct. In general it is unlikely that one over-corrects even though the nose tip is rather exaggeratedly lifted. Of course one should not over-correct too excessively. One major advantage of this operation is that it is easy to do and should one not over-correct sufficiently then the procedure is easy to repeat. The same is true should one over-correct.

16. Should you feel that the nose has not been adequately lifted a second suture can be inserted. I do not try and remove the first suture.
17. I suggest taping the nose with micropore for about two days to limit swelling and also to ensure immobility. The nose tip can be rather sensitive for the first few days.
18. Over the next three to six weeks the nose tip will drop down into a stable position. By 8 to 10 weeks one reaches a stable position.

6. Further modifications

In some patients the described procedure makes a difference but one does not achieve the refinement of the nose tip that is desired. In these cases one needs to add extra sutures. Experience has shown that generally these sutures need to be shorter.

1. If the suture designed above will not narrow the nose sufficiently then one needs to add a suture lower down on the nose with more direct pressure on the upper edges of the lower lateral cartilages. (See Figs. 5 and 6)

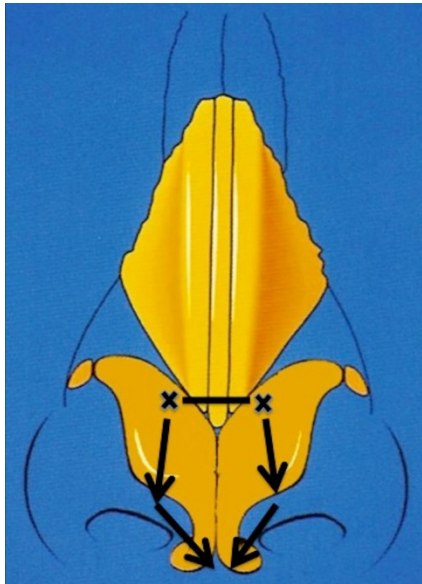


Figure 4. Showing the frontal view of the skin markings where one needs more pressure on the alar wings.

As one creates this suture in much the same way as described above, take care to ensure that the alar cartilages are not lifted anteriorly which will create a ridge on the lower nose instead of maintaining a straight bridge to the tip, or supra-tip bump. This suture is often important for creating a really fine nose tip.. A variant that can be done, depending on the anatomy, is the pass above the lower lateral alar cartilages through the septum and then around them to make a more defined cinched tip (See Fig 6 and 7).

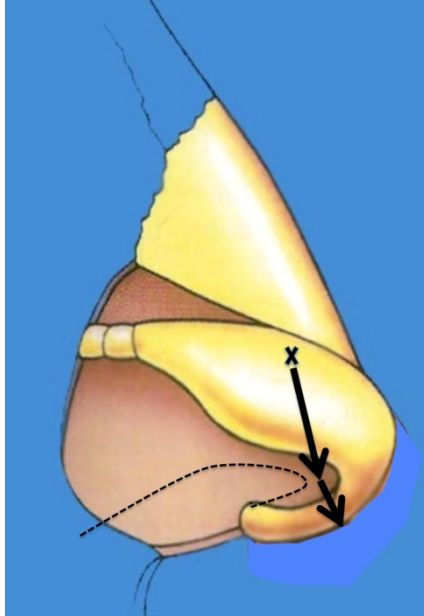


Figure 5. Showing the lateral marking for the shorter suture to compress the alar cartilages more directly.

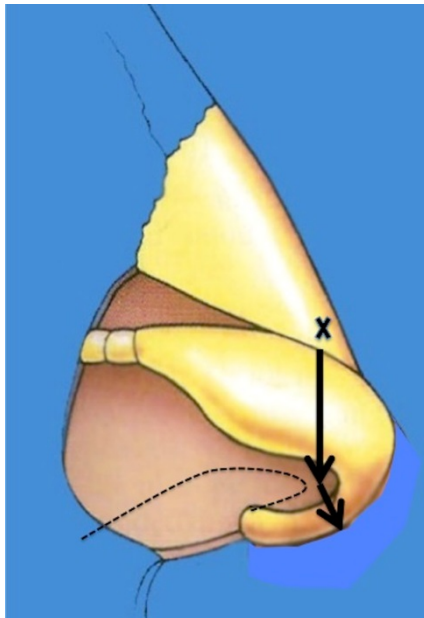


Figure 6. Showing the markings for a more pinched tip with the suture going through the septum only.

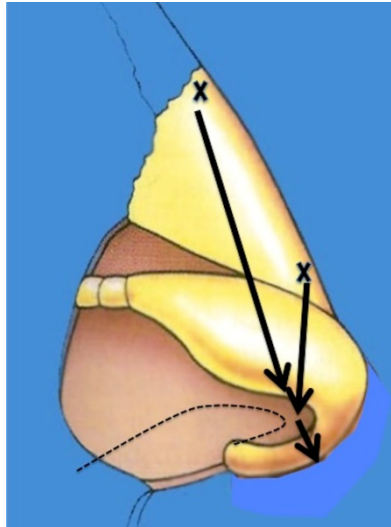


Figure 7. Showing the composite view of both longer and then a shorter cinching suture to the nasal tip.

2. In some cases with very bulky lateral alar wings we need to do a slightly different suture to get better compression. Here it is necessary to make four stab incisions on the alar cartilage in a design that allows more compression on the alar cartilage and compresses the tip as well. (See Fig. 8)




Figure 8. Showing the square suture combination in the upper edge of the medial wing of the lower alar cartilage.

Here we have to be cautious about not entering the nasal cavity. These sutures do not need to be anchored to the septum. I rarely use this suture.

3. In some cases the alar cartilages are not positioned evenly and one cartilage may be lower than the other. In this case the displaced cartilage can be lifted by a loop created in the same fashion as described above but one goes medial to the “normal cartilage so that the one thread of the suspension loop lies in between the alar cartilages and the other part lies exterior to the lower cartilage as shown in figure 9.

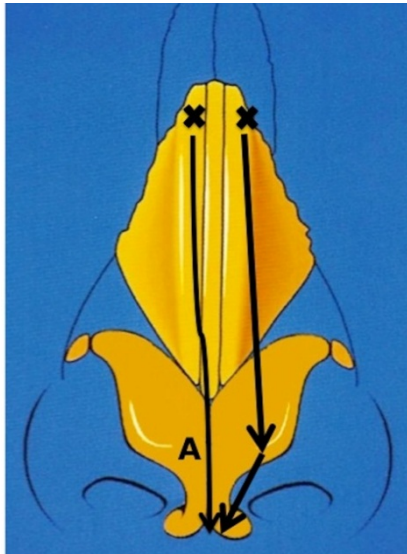


Figure 9. Showing the surface markings of the suture used to pull up the left alar cartilage. It would be the mirror image for the right side.

Tightening the loop will lift the alar cartilage to a matching position and then the suspension suture for both alar cartilages can be positioned. Do not expect that a simple loop will correct this type of asymmetry.

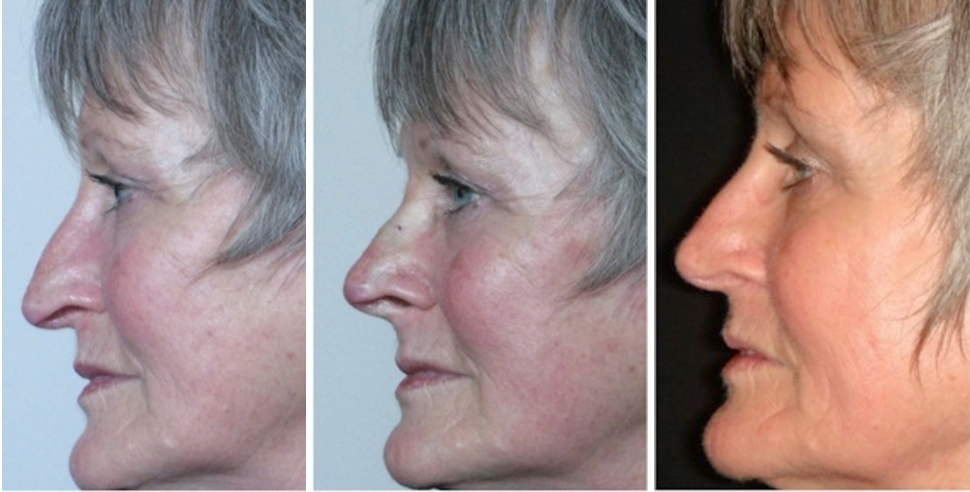4. In cases of excessive bulk of the columella that hangs very low, then one should consider an elliptical excision of mucosa to lift the columella. Suspension sutures alone cannot remedy this situation.

7. Postoperative phase

Initially patients may worry that the tip of the nose has been lifted too much but if sensible exaggeration has been done, the nose takes up a pleasing position very quickly. (see Figures 10 through 1)

For the first four five days the nose looks over-corrected but rapidly changes as the swelling disappears and within a week the patient feels much more confident. By ten weeks. Weeks the nose has settled to very close to the final appearance.

The nose can be rather sensitive to minor trauma and even to kissing but that also settles quite soon. The patients may be aware of the suture for up to six months.



One realises quite quickly if the nose has not been over-corrected sufficiently. Patients should be warned that this is a possibility and that they might need a second minor procedure.

8. The advantages

This is a simple low cost procedure easily done in the office that does not disrupt the alar cartilages and yet shapes them easily. It is rapidly done with little morbidity and the patient can rapidly return to normal social activity. The worst luck is that the nose might need some modification with some extra sutures.

One of the greatest advantages for older people is the improvement in breathing through their nose when the tip has been lifted. Another major advantage for people who have had previous surgery is how easily their nose can be re-fashioned into the nose they hoped for.

9. Summary

A simple technique is always a benefit and this technique of lifting and compressing the nasal tip combines a very simple surgical procedure with rapid results and minimal discomfort. It can be used in old people whose nose tips have dropped and also in patients who have had a previous rhinoplasty. Its simplicity also makes it an inexpensive minimally invasive procedure that is also suitable for many minor nasal deformities.

Author details

M. B. Des Fernandes

The Renaissance Body Science Institute, Cape Town, South Africa.

Department of Plastic Surgery, Groote Schuur Hospital, University of Cape Town, Cape Town, South Africa