

---

# **Correction of Face Involutional Changes by Method of Light Lift Elegance Thread Reinforcement**

---

O. Gaziullina, O. Zhukova and S. Shostak

Additional information is available at the end of the chapter

<http://dx.doi.org/10.5772/50742>

---

## **1. Introduction**

The technology of face rejuvenation with the use of polylactic acid absorbable threads, which appeared a few years ago, has become a follow-up of Aptos polypropylene threads face lift. The techniques of fixation of threads made from absorbable and nonabsorbable material were identical. The only difference was the expected duration of the thread lift effect. [1,2,3,4] It has been histologically confirmed that it is already within the first month that there comes a delicate fibrous capsule around the implanted threads. It coats the threads as a small soft connective tissue cover, creating artificial ligaments which occur to be those face-lift agents that strengthen the effect achieved after the thread introduction. The effect remains for years. [2] Light Lift Elegance threads are absorbed completely within some time by way of hydrolysis. Due to the polylactic acid, they stimulate the activity of fibroblasts, thus activating the mechanism of neocollagenesis. As the result, there has been noted a double effect of absorbable threads usage – consistent mechanical lift effect and tissue revitalization. [6]

These observations have resulted in creation of a special thread reinforcement technique - Light Lift Elegance. It is indeed an elegant method of atonic skin transfer which leads to consistent skin graft lifting. This technique can also be used by dermatologists and cosmetologists who would like to offer their patients more effective procedures.

## **2. Materials**

Light Lift Elegance threads are thin threads with micro cogs throughout the length which directed towards each other. It allows to fix the skin graft using a special fixation technique and to hold the tissue in this position until a new collagen framework is formed. Thus, the main feature of these threads is their structure. It is the cogs directed to the middle part of

the threads that allow to lift the overstretched atonic skin and to achieve the effect of consistent skin graft lift.

### **3. Methods**

The method of Light Lift Elegance thread fixation, i.e. reinforcement, is used for correction of the involuntional changes of the middle third and lower third of the face, submandibular area, neck, low neck, inner shoulder surface, thighs, abdomen, and patellar areas. Since our main task is to strengthen the surface tissues of the body, the threads should be placed along the lines of the natural skin stretching. Possible schemes of Aptos Elegans thread fixation coincide with the lines of Langer (C.R. Langer, 1819-1887, German anatomist) – relative lines on the skin surface, indicating the direction of its maximum distensibility and corresponding to the location of fascicles of collagen fibers.

Fixation depth, the degree of thread tension and tissue transfer criterion

Thin and delicate threads LL Elegance perform two functions – creation of subdermal frame and skin revitalization. Therefore, the depth of the threads plantation should correspond to their main purpose. It should be done subdermally but contouring is to be avoided. The threads have small cogs from the end of the thread to its middle, which allows to shrink the tissue a little, thus making the skin graft smaller. If one retracts the skin a little at the moment of the thread plantation, the cogs will help to fix it in this position and create a strong connective frame around the thread. The skin surface tends to become plicated after the thread fixation. This effect wears off within a week. It is undesirable to create strong overstretchings and visible tucks. [1]

### **4. Fixation technique**

Infiltration anesthesia is used after taking pictures, marking, skin aseptic cleaning, and draping. It contains 2% Lidocaine, Marcaine or Ultracaine 1:2000000, adrenaline 0.1% -0.1 ml and 5% NaCO<sub>2</sub> as a buffered solution used for relieving pain during anesthetics administration, equal infiltration and hydro undermining of tissues. The threads are fixed in sequence in accordance with the marking. While inserting a thread one can be guided by the Arcus zygomaticus projection and while taking it out – by the Corpus mandibular projection. [1]

The ends of the threads are cut off after their fixation. The remaining ends are being placed subdermally and massaged gently. The skin over the place of the thread plantation can be stretched a little to eliminate the excessive folding. [1]

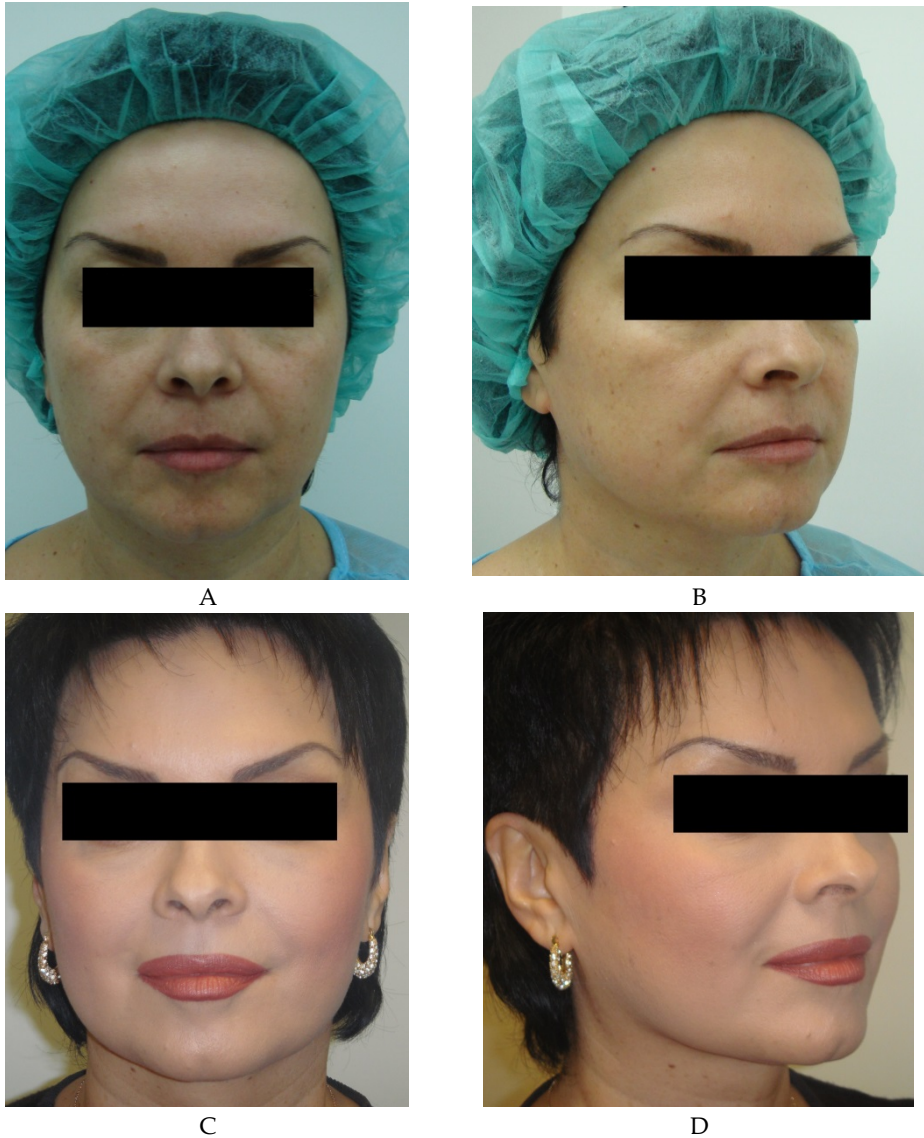### **5. The selection of patients**

What categories of patients fit for this delicate method of thread lift?

First of all, it is patients with initial manifestations of age-related changes that cannot be corrected with the help of modern hardware-based and injection techniques. LL Elegance

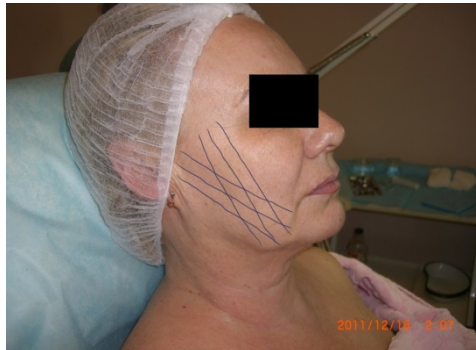can be applied both as a mono-method and also in a combination with a wide range of modern cosmetic treatment.

Patients with atonic, rugulose skin with manifestations of photoaging can also improve their appearance using this method. L.L. Elegance works perfectly in combination with hyaluronic acid fillers, peelings, and botulinum toxin.

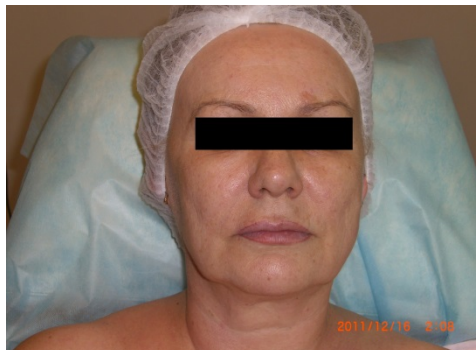

**Figure 1.** Patient N. 49 years old. Photo (A;B.) Before threads plantation. Photo (C;D.) Here is a correction of the middle third and lower third of the face. 1 month later.

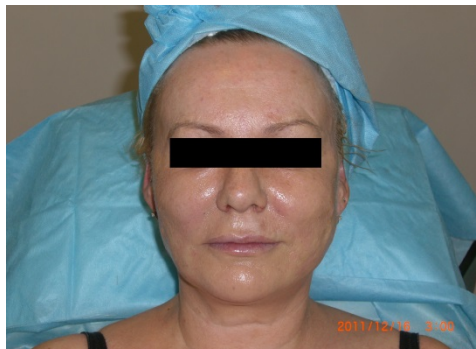Patients with face sebaceous disproportion, gravitational ptosis of subcutaneous fat, hyperextension of the collagen fibers and the formation of deep wrinkles should use a combination of several methods of thread correction. In this case, it is recommended to use a combination of methods of zone, deep lift by Thread 2 G, Needle2G, Spring threads, and methods of the surface subdermal plantation of LL Elegance threads.



A

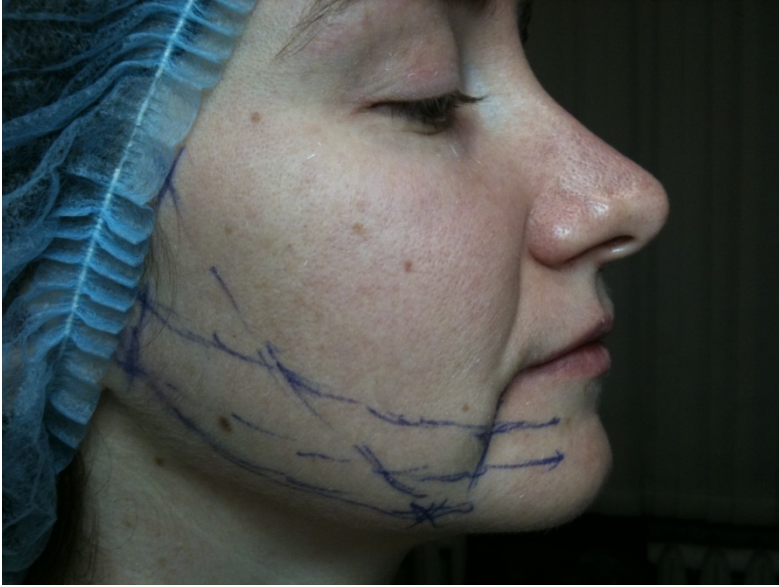

B

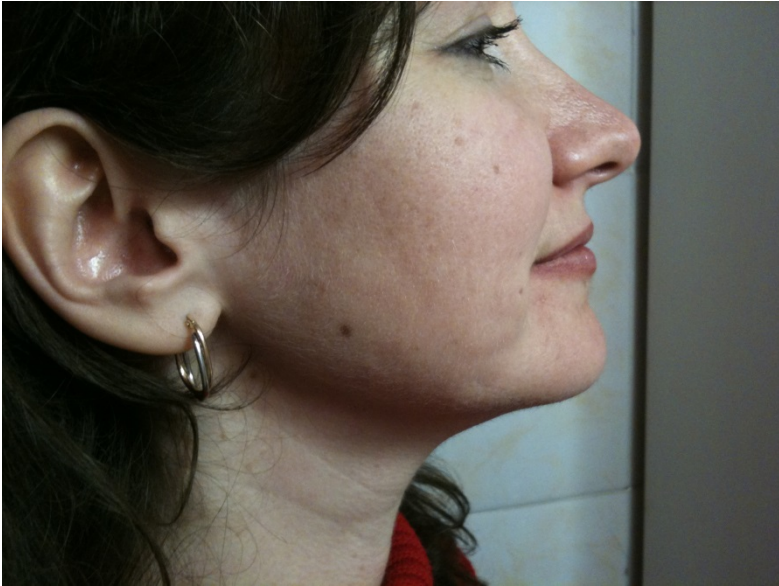

C

**Figure 2.** Patient K. 58 years old. Photo (A;B.) Before threads plantation. Photo (C.) Here is a correction of the middle third and lower third of the face. This is a result just after operation.



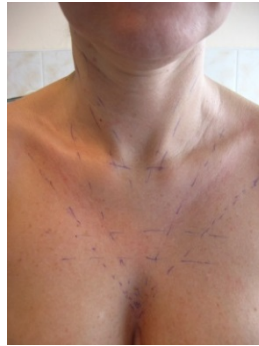A



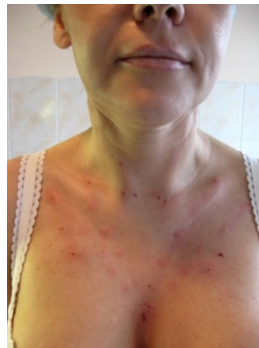B

**Figure 3.** Patient M. 45 years old.  
Photo (A.) Before threads plantation.  
Photo (B.) Here is a correction of the lower third of the face 3 weeks after plantation.

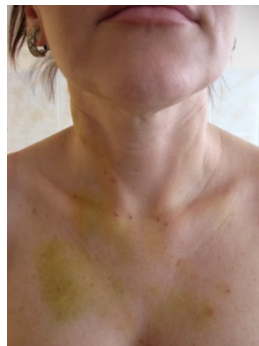
It would be good to focus on the method of complex correction of submandibular and neck areas with an excess of soft tissues in these areas. It is recommended to reduce fatty tissue using a mechanical or chemical (mesolipolysis) way. Then follows the insertion of a hammock in the submandibular area and the use of reinforcement of the neck area for a simultaneous fixation of tissues in these areas.



A



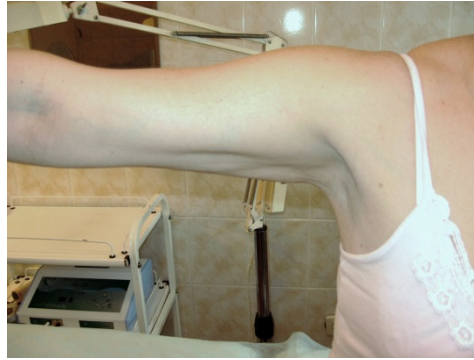B



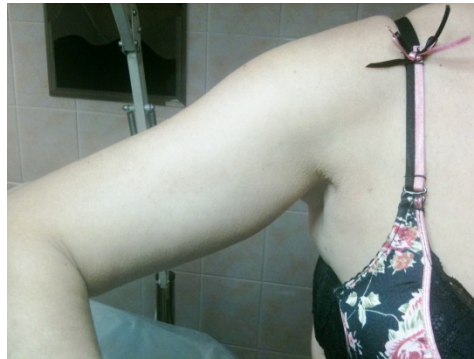C

**Figure 4.** Patient S. 48 years old. Photo (A.) Before threads plantation. Photo (B.) Here is a correction of the neck and lower neck area. The result is just after operation. Photo (C.) This is a result of threads plantation 6 days later.

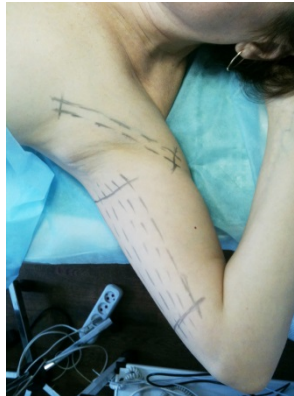




A



B

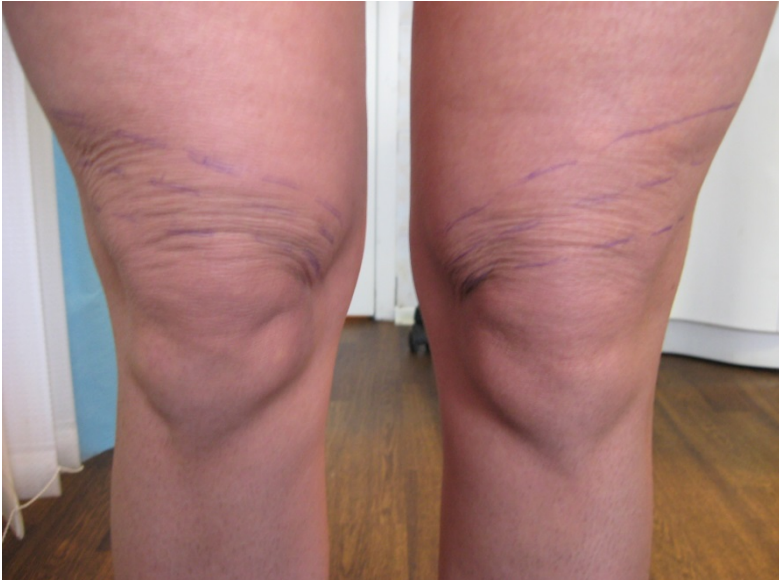

C

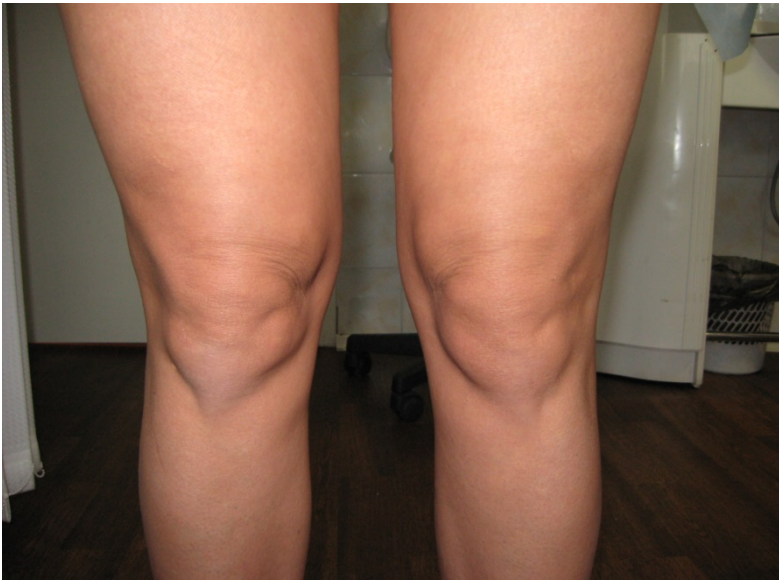**Figure 5.** Patient S. 48 years old. Photo (A; B.) Before threads plantation. Photo (C.)The sketch of threads plantation in inner shoulder surface.

When using Light Lift Elegance method, the patients should be selected among those with signs of sclerosis and skin and subdermal tissue sagging. It is recommended to consider all

the variants of lipodystrophy (especially in the initial phase) because thinning of the surface investing tissues (and consequently the flabbiness) is always the main symptom.



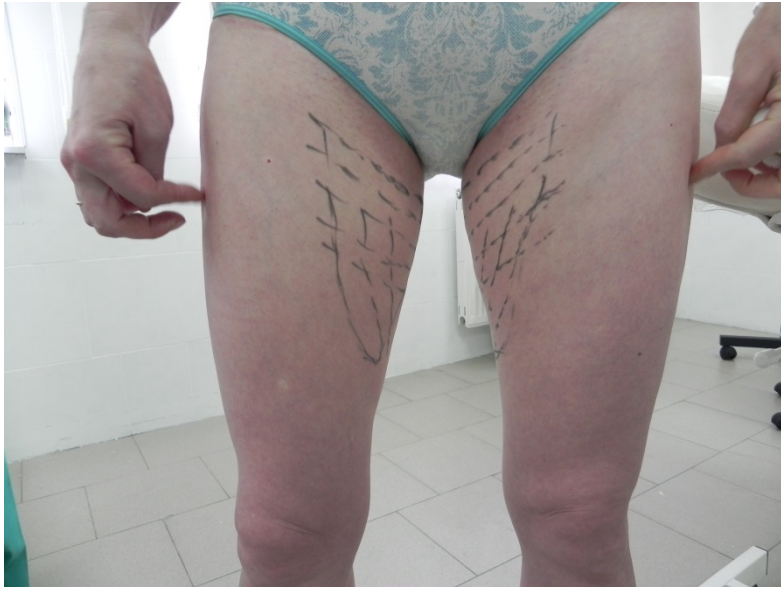A



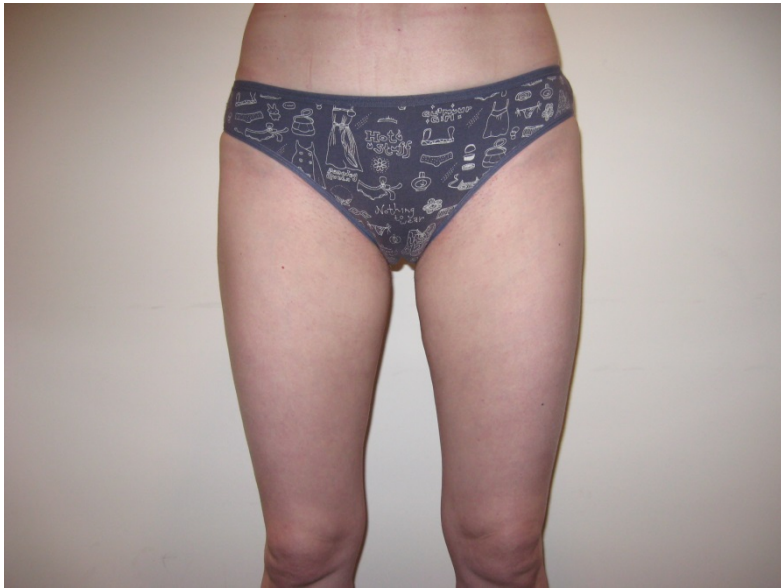B

**Figure 6.** Patient B. 42 years old.  
Photo (A.) Before threads plantation.  
Photo (B.) Patient 2 months after correction of patellar areas.





A



B

**Figure 7.** Patient L. 49 years old.  
Photo (A.) Before threads plantation.  
Photo (B.) Patient 2 months after correction of thighs areas.

## 6. Complications

- Hematoma, swellings, painfulness;
- Threads contouring connected with the surface plantation;
- Inflammation around the thread;
- Disruption of the threads;
- Thread exposure on the skin surface;
- Temporary paresthesia.

All complications are to be treated in accordance with the cause of their formation.

## Author details

O. Gaziullina, O. Zhukova and S. Shostak

*Clinic of Aesthetic Medicine and Laser Cosmetology "Time of Beauty",  
People's Friendship University of Russia, Clinic of Aesthetic Medicine "Total Charm",  
Ufa, Moscow, Russia*

## 7. References

- [1] M.A.Sulamanidze, G.M.Sulamanidze, I.S.Vozdvizhenskiy, K.M.Sulamanidze, A.A. Kadzhaya. New Method of Elastic Thread Face Lift // *Aesthetic Medicine*. – Volume IX-N3, October 2, 2010.
- [2] Skuba N.D., Adamyan A.A., Sulamanidze M.A., Husnutdinova Z.R. Morphological foundation of face skin reinforcement by «Aptos» threads. // *The annals of plastic, reconstructive and esthetic surgery*. – 2002. - №3. – P. 19-26.
- [3] Sulamanidze M.A., Sulamanidze G.M. Hyposthenic, aged face. New treatment // *Thes.II Congress of esthetic and plastic surgery*. – M., 1998. – P.15.
- [4] Sulamanidze M.A., Sulamanidze G.M «Aptos» methods: the past, the present and the future // *Vestnik of esthetic medicine*. – 2007. – Vol.6, №3. – P. 23-32
- [5] Sulamanidze M.A., Fournier P.F., Paikidze T.G., Sulamanidze G.M. Removal of facial soft tissue phtosis with special threads.//*Dermatol. Surgery*. – 2002, May. - № 28. – P.367-371.
- [6] Sulamanidze M., Sulamanidze G. Aptos Suture Lifting Methods. 10 Years of Experience // *Clinics in Plast. Surgery*. – 2009, April. – Vol. 36, № 2. – P. 281-306.