

---

# Spinal Arteriovenous Lesions

---

Benjamin Brown, Chiazio Amene, Shihao Zhang,  
Sudheer Ambekar, Hugo Cuellar and  
Bharat Guthikonda

Additional information is available at the end of the chapter

<http://dx.doi.org/10.5772/56731>

---

## 1. Introduction

Spinal arteriovenous lesions represent a heterogeneous set of pathologic entities. As our general understanding of these lesions has evolved, so have the classification systems clinicians use to describe them. Historically, the most common classification of arteriovenous fistulas (AVF) has been the Type I-IV classification. More recently these lesions have been described from an anatomical and physiologic perspective.

This text will use the most recent categorizations by Spetzler, et al in 2002 [15]. Table 1 provides an overview of the spinal arteriovenous lesions discussed in this chapter and can be used as a quick reference for comparison.

## 2. Extradural arteriovenous fistulae

### 2.1. Anatomy/etiology/classification

The extradural arteriovenous fistulae represent an abnormal connection between an epidural artery and the epidural venous plexus, otherwise known as Batson's plexus [2]. This connection produces engorgement of the epidural plexus and subsequent mass effect upon the thecal sac and spinal cord within [10]. Venous drainage can be confined to the epidural space or may reflux into the perimedullary veins [28]. These fistulae occur more commonly in the thoracic and lumbar spine than the cervical spine. The cause of these lesions is unknown, though both post-surgical and post-traumatic lesions have been documented [18, 26-27]. These have been referred to as epidural fistulas in previous classification schemes and are not included in the

	Extradural	Dorsal Intradural	Ventral Intradural	Intramedullary	Extradural-Intradural	Conus Medullaris
<b>Pathophysiology</b>	Compression, venous congestion, vascular steal	Venous congestion	Compression, hemorrhage, vascular steal	Compression, vascular steal, hemorrhage	Compression, vascular steal, hemorrhage	Compression, vascular steal, hemorrhage
<b>Presentation</b>	Myelopathy	Myelopathy	Myelopathy	Pain, acute myelopathy	Pain, myelopathy	Myelopathy, radiculopathy
<b>Flow</b>	High	Low	High	High	High	Variable
<b>Nidus</b>	Extradural artery and vein	Radicular artery to medullary vein at root sleeve	Pial surface	Spinal cord parenchyma	Diffuse: Extradural, <u>intradural</u> , parenchymal, muscle, bone	Multiple feeders from anterior and posterior spinal arteries
<b>Alternate Nomenclature</b>	Epidural fistulas	Type IA, Spinal <u>dural</u> AVF, Dural AVF	Type IV, anterior <u>intradural</u> AVF, or <u>Perimedullary</u> AVF	Type II, Classic AVM, or <u>Glomus</u>	Type III, Metameric, or Juvenile	None

**Table 1.** Overview of Spinal Arteriovenous Lesions

Type I-IV dural AVF classification. Rangel-Castilla et al proposed subdividing extradural arteriovenous fistulae into three types: A, B1, and B2. Type A fistulae have at least one intradural draining vein, while types B1 and B2 have purely extradural drainage. Type B1 has mass effect on the thecal sac, while in type B2 there is no mass effect by the distended epidural veins [28].

## 2.2. Clinical manifestation

Due to their rarity, it is difficult to provide epidemiological data on extradural arteriovenous fistulae. Case reports suggest their average age of presentation to be in the seventh decade of life [27-28]. Clinically, they result in a progressive myelopathy [15]. This is thought to be secondary to direct mass effect from engorged veins as well as intramedullary venous hypertension secondary to poor outflow [2]. The constellation of symptoms varies based on the location of lesion. Patients may experience a compressive radiculopathy or myelopathy. Venous hypertension may also lead to progressive myelopathy in a manner similar to dural AVF. Vascular steal is thought to play less of a role because these shunts do not involve afferents with associated arterial supply to the spinal cord [23].

## 2.3. Imaging

MRI examination reveals a picture identical to spinal dural AVF. There will be swelling in the parenchyma of the cord identified by T2 hyperintensity within the cord. Serpentine structures around the surface of the cord may be noted as T2 “flow-voids.” Additionally there may be dural enhancement on T1 weighted imaging with contrast. Formal angiography remains the “gold standard” and will best delineate the anatomy of each individual extradural AVF.

## **2.4. Treatment**

These lesions rarely require open surgery and are treated very effectively by endovascular procedures [15]. Most commonly the use of liquid embolic such as Onyx is used to arrest flow within the fistula. Rarely open microsurgery can be used when vascular access to a given lesion is not possible. Partial obliteration of these lesions may allow for the remaining AVF to recruit new blood vessels and recur, thus treatment aims to completely obliterate the lesion.

## **2.5. Outcomes**

Due to the rarity of these lesions, reliable outcome data is not available. However, treatment usually halts and often reverses progression of symptoms.

## **3. Intradural AVFs**

These can be divided into two types: Dorsal intradural AVFs and Ventral intradural AVFs.

## **4. Dorsal intradural AVFs**

### **4.1. Anatomy/epidemiology**

Dorsal intradural AVFs correspond to the classic 'Type I' lesions in the original nomenclature. They are the most common type of spinal AVF, making up about 70% of all spinal AV malformations [9]. There is a male predominance, approximately 5:1, and it is usually diagnosed in the 5th to 6th decades of life [5]. They are most commonly found in the thoracic and thoracolumbar regions (greater than 80%) [5, 9, 33], with approximately 2% in the cervical spine and 4% in the sacral region [5].

Dorsal intradural AVFs are formed by a pathologic connection between one or more radiculomeningeal arteries and the venous outflow. The radiculomeningeal artery supplies the corresponding nerve root and meninges but not necessarily the spinal cord parenchyma. The shunt is located intradurally at the level of the dural sleeve surrounding the nerve root and drains into the venous system [2]. They characteristically have slow flow [15] and may be grouped into 2 subtypes. Subtype A involves a single feeding artery while Subtype B involves multiple feeders that converge into a single fistula, still on the intradural side of the nerve root. Venous outflow obstruction appears to be a hallmark of this type of lesion and may contribute to the formation of the shunt. This type of AVF is acquired and is theorized to result from traumatic injury, infection, or prior surgery; although often, the causative agent is never identified.

### **4.2. Pathophysiology**

The pathology seen in spinal AVF was first described in 1926 by Foix and Alajouanine [30]. They described a progressive subacute necrotizing myelopathy, now known as Foix-Alajoua-

nine syndrome, and found evidence of vascular obstruction, spinal cord necrosis and tortuous and dilated vasculature on the surface of the spinal cord. The actual etiology of the noted pathology was not cemented until Aminoff and Logue proposed that spinal cord ischemia secondary to venous congestion or hypertension was the underlying cause. The venous hypertension results in arterialization of the coronal venous plexus [15] which in turn leads to a decreased pressure gradient between the artery and vein and, therefore, decreases drainage of the spinal cord. This results in progressive venous congestion and edema of the spinal cord parenchyma with progressive symptoms.

### 4.3. Clinical manifestation

Aminoff et al. also characterized the clinical presentation of their patients with spinal AVF. They noted a gradual progression of symptoms; additionally, they noted that in approximately 50% of cases, spinal AVF led to severe disability [32]. Early symptoms of dorsal intradural AVF are often non-specific which may lead to delay in diagnosis. The end result is a progressive myelopathy. Lower extremity weakness is the most common initial presenting symptom, seen in about 50% of cases [24], although patients often reported milder symptoms months to years prior to presentation. Other symptoms seen at presentation, in order of descending frequency, include gait disturbance, paresthesias, back pain and bladder or sexual dysfunction [24]. This type of SDAVF rarely presents with hemorrhage. Patients are often graded clinically based on the Aminoff-Logue Scale (ALS) (Table 2)

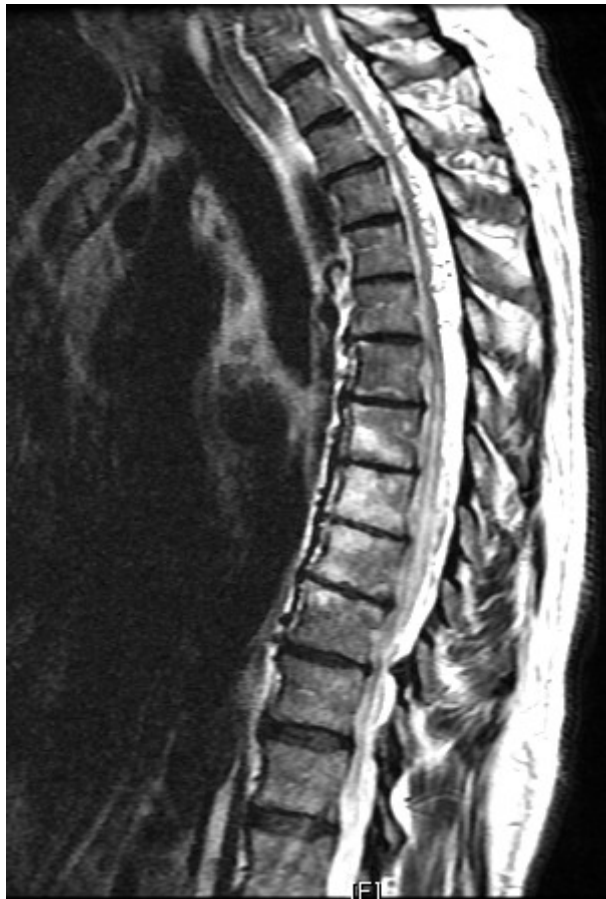	<b>Score</b>
<b>Gait</b>	
Some leg weakness, but able to walk unaided	1
Restricted exercise tolerance	2
Requires a cane to walk	3
Requires 2 canes or crutches to walk	4
Requires a wheelchair, unable to stand	5
<b>Micturation</b>	
Normal	0
Hesitancy, urgency, frequency, altered sensation, but continent	1
Occasional urinary incontinence or retention	2
Total incontinence or persistent retention	3
<b>Bowel</b>	
Mild constipation	1
Occasional incontinence or persistent constipation	2
Persistent incontinence	3

**Table 2.** Aminoff-Logue Scale

## 4.4. Imaging

### 4.4.1. MRI

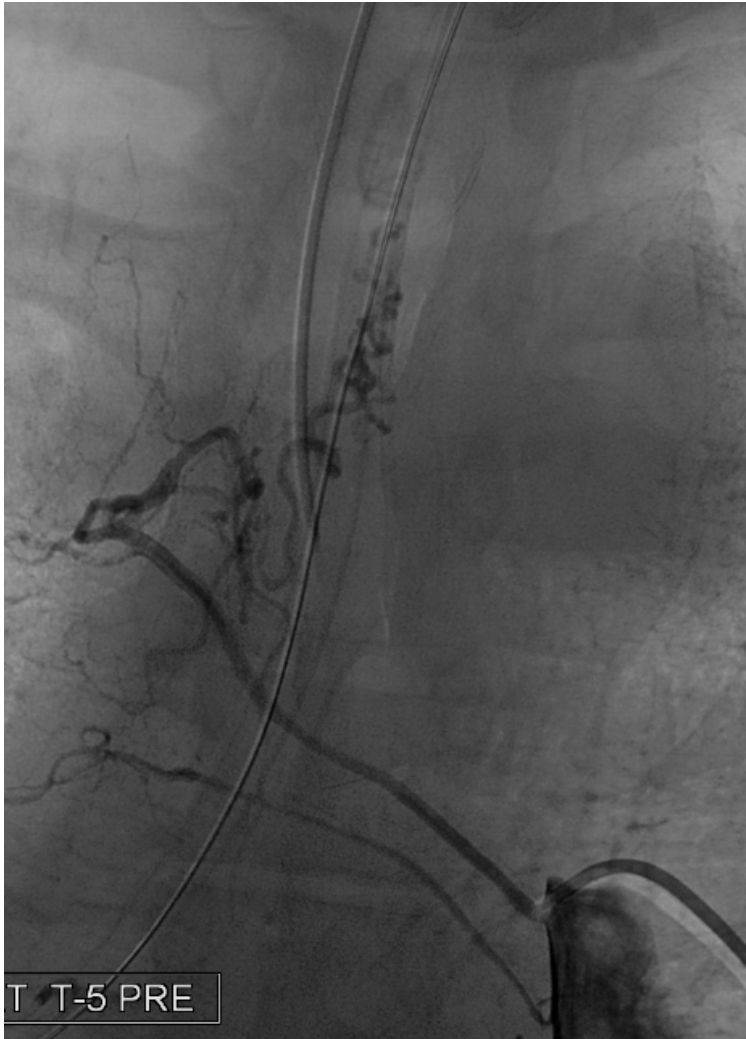MRI is the initial image modality used in the evaluation of suspected dorsal intradural AVFs. MRI often reveals increased signal intensity at the center of the cord on T2-weighted images which corresponds to cord edema and which may span several levels. Dorsal intradural flow voids may be present and are more evident on T2-weighted images or contrast-enhanced T1-weighted images. With the advancement in MRI technology, MRA can more reliably identify the location of the fistula though spinal angiography remains the gold standard [8, 25]. (Figure 1)



**Figure 1.** T2 Sagittal MRI showing tortuous vasculature on the dorsal aspect of the spinal cord and signal change within the cord representing edema.

4.4.2. *Selective Spinal Angiography (SSA)*

Even with the advances in MR imaging and angiography, catheter angiography remains the gold standard for diagnosis of dorsal intradural AVFs. It also provides an opportunity for possible endovascular treatment (discussed below). SSA reveals tortuous dilated vessels that may span many levels and also the characteristic slow-flow pattern produced by the feeding dorsal radiculomeningeal artery (Figure 2).



**Figure 2.** Spinal angiogram showing a dorsal intradural SDAVF filling from the right at T5

While SSA is still considered superior to other modes for diagnosis, it is not without potential complications. It often requires selective catheterization of many spinal feeders to determine the main feeding artery which results in lengthy procedures with extensive exposure to ionizing radiation and potential nephrotoxic levels of contrast agent [8]. Also due to the length of the procedures, it is often done with general anesthesia which presents its own complications. There have also been reports of neurologic injury caused by catheterization of spinal arteries.

## **4.5. Treatment**

Secondary to the progressive nature of this disease, definitive and prompt treatment is required to halt the process.

### *4.5.1. Microsurgery*

Historically, intradural dorsal AVFs were thought to be posterior angiomas and surgical treatment involved the stripping of dorsal perimedullary veins. This often resulted in worsening of neurologic function. It was discovered that instead, treating the intradural arterialized vein at the nerve root was the appropriate course of action. Therefore, surgery involves performing a hemilaminectomy, opening the dura, and following the dorsal radiculomeningeal artery as it heads towards the dorsal nerve root and ligating the artery-vein connection by coagulation or clipping. Surgery has been shown to be associated with very low morbidity (2%), with complete occlusion achieved in >98% of cases [17].

### *4.5.2. Endovascular*

The recent advances in endovascular techniques have provided an alternative to surgical treatment of SDAVFs. It is less invasive, and may be performed at the same time as the diagnostic angiogram. Early endovascular endeavors utilized polyvinyl alcohol particulates to achieve obliteration of the fistula. However, this was complicated by high recanalization rates [19]. More recently, endovascular surgeons utilize liquid embolics like N-butylcyanoacrylate (NBCA) and Onyx. In some cases, embolization has been used as an adjunct to surgical resection. Embolization is contraindicated in cases where a spinal cord artery (radiculomedullary artery) arises from the same pedicle as the feeder. Attempts with endovascular treatment in these cases may result in either inadequate embolization or spinal cord ischemia if the medullary artery is occluded [5-6]. Embolization, even with liquid embolics, is still associated with high recurrence rates—up to 54% in the literature [17].

## **4.6. Outcomes**

Prognosis after treatment directly correlates with duration and severity of pre-operative symptoms (6, 8, 31). Otherwise, there has been an inconsistency in the literature regarding prognosis after treatment. Clinical improvement of the motor function ranges from 25% to 100% [4, 31].

## 5. Ventral intradural AVFs

### 5.1. Anatomy/epidemiology:

These lesions correspond to 'Type IV' lesions in the classic categorization. In the literature, they are also referred to as perimedullary AVFs or fistulous arteriovenous malformations (AVMs). They are extremely rare, with only a few cases reported in the literature [14]. They occur in a younger population, with mean age in the 20's and 30's and no sex predilection [13-14]. They are also more prevalent at the conus medullaris and cauda equina [14].

Ventral intradural AVFs originate from the anterior spinal artery [14, 15]. The fistulous connection lies completely outside the cord parenchyma and pia matter in the subarachnoid space ventral to the cord at the midline. Blood flow through these AVFs is rapid and they may have flow-related aneurysms and venous hypertension [15]. In contrast to the dorsal types, ventral intradural AVFs may present as congenital lesions, but there is evidence supporting an acquired etiology to these lesions. They can be further subdivided into 3 distinct types based on feeding vessel size, shunt volume and drainage pattern [11, 15].

Type A – Small with a single feeder and low shunt volume. The feeding artery and draining vein are not significantly dilated. Hemodynamic features are similar to dorsal intradural AVFs.

Type B – These are of an intermediate size with a major feeder from anterior spinal artery as well as smaller feeders at the level of the fistula.

Type C – These are giant lesions with multi-pediculated and massively dilated venous channels and large shunt volumes. Hemodynamic features are similar to intramedullary AVMs.

### 5.2. Pathophysiology

Ventral intradural AVFs were first described by Djindjian in 1977 [12] and later classified as Type IV by Heros in 1986 [3]. They originate from the anterior spinal artery, with a direct fistulous connection to the engorged venous drainage system. There are no capillaries between the artery and the venous network. The pathology is similar to dorsal intradural AVFs with venous hypertension a common finding. However, the cause of the venous hypertension appears to be more from vascular steal and mechanical compression [15] than from slow flow and venous congestion. Secondary to the higher flow rate through these AVFs, hemorrhage is more common and occurs in about 20-40% of cases [13-14].

### 5.3. Clinical manifestation

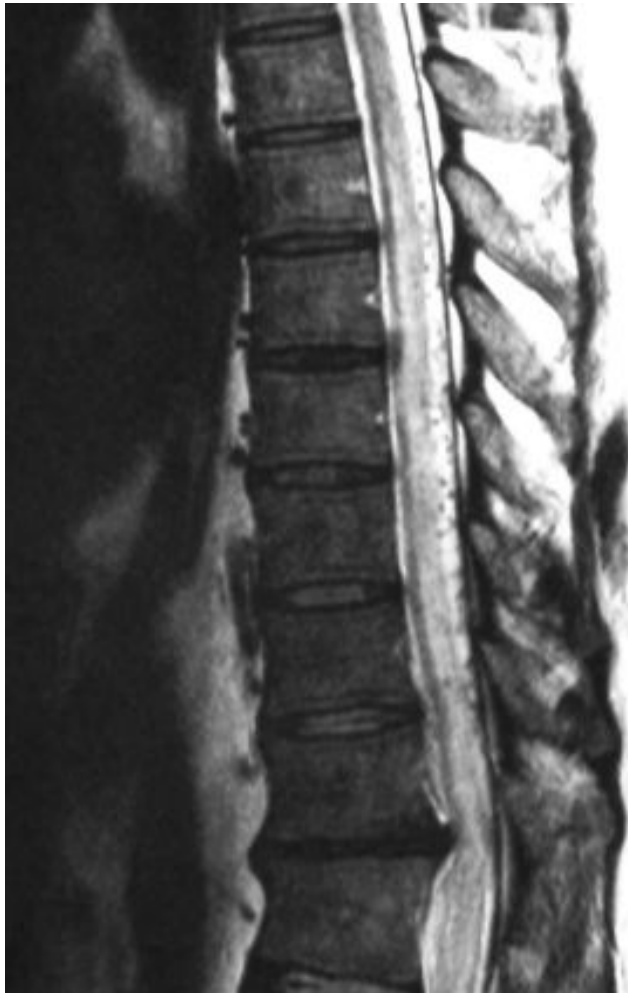As opposed to the dorsal AVFs, symptoms are thought to be produced by vascular steal and mechanical compression from engorged veins or by subarachnoid or intraparenchymal hemorrhage. Symptoms are usually progressive in nature, with myelopathy the most common finding. Cases in which a patient may have an acute presentation or an acute exacerbation of baseline symptoms are usually a result of hemorrhage.



## 5.4. Imaging

### 5.4.1. MRI

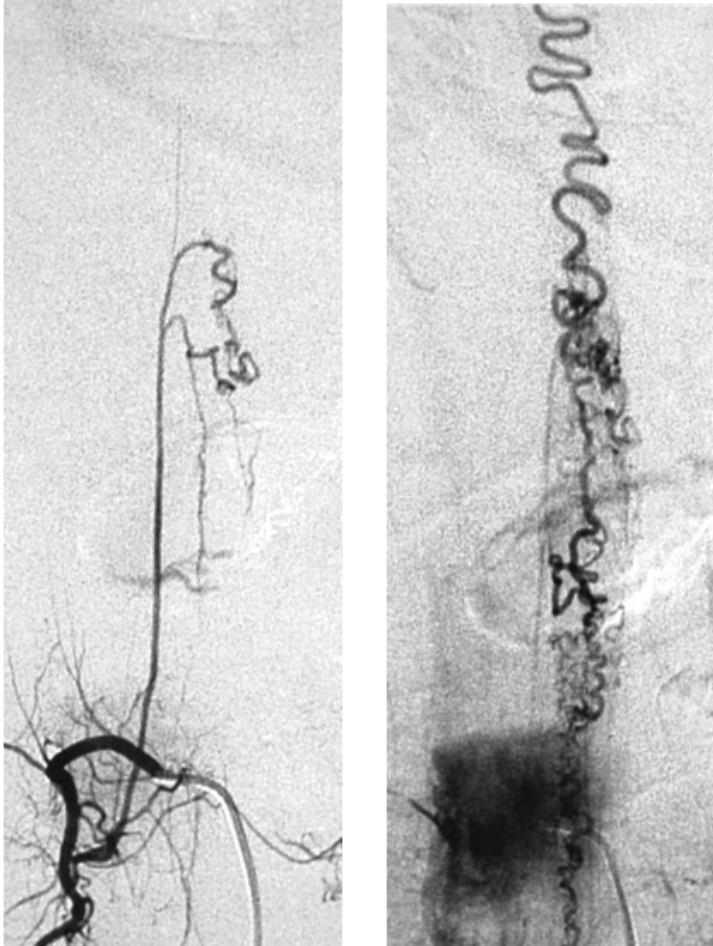
MR Imaging is often the initial image modality used to diagnose ventral intradural AVFs. Like their dorsal counterparts, T2 prolongation in the parenchyma may be noted with flow voids on the ventral aspect of the cord or thecal sac. However, it is difficult to determine the type of AVF or differentiate between the subtypes of ventral AVFs and spinal angiography remains the standard for diagnosis. (Figure 3)



**Figure 3.** T2 Sagittal MRI showing hyperintensity within the spinal cord indicating edema

5.4.2. SSA

Catheterization of the anterior spinal artery cements the diagnosis of ventral intradural AVFs. (Figure 4)



**Figure 4.** Spinal angiography showing an AVF fed by an anterior spinal artery at the thoracic level. Delayed images show the perispinal venous drainage of the fistula.

**5.5. Treatment**

Treatment modality depends on the subtype of the ventral intradural AVFs. Types A and B are often treated surgically, while Type C lesions are almost always treated via endovascular embolization [13-15].

### 5.5.1. Microsurgery

Surgery is the treatment of choice for Types A and B ventral intradural AVFs. This is feasible when they are located at the conus or cauda equina but may prove difficult in higher lesions and necessitate an anterior or anterolateral approach for treatment [14]. The target for surgery is the fistulous connection. Care must be taken to preserve the patency of the anterior spinal artery [2].

### 5.5.2. Endovascular

Endovascular embolization is often of limited use in these lesions due to the involvement of the anterior spinal artery, which is difficult to catheterize and navigate. For Type C lesions, however, endovascular treatment via embolization or detachable balloon occlusion appears to be the only safe course of action secondary to the large size of the lesion and easy catheterization of the severely dilated anterior spinal artery [2, 13-14].

## 5.6. Outcomes

Treatment usually results in stabilization of symptoms. Secondary to the paucity of these cases in the literature, definitive prognostic figures are not available.

## 6. Extradural-intradural arteriovenous malformations

Extradural-Intradural Arteriovenous Malformation is rare and very complex. It has been called type III, metameric, or juvenile AVM. It contains an intramedullary nidus which may take up the entire spinal canal at the occupied level. It could involve bony, extradural, intradural, and intramedullary tissue. This is a high-flow system with multiple feeding and draining vessels. The cause of this malformation is thought to be a problem with embryogenesis [2, 15, 37].

### 6.1. Clinical manifestations

Adolescents and young adults are the most affected by this type of AVM. Patients usually present with pain or progressive myelopathic symptoms from spinal cord compression, venous hypertension, or vascular steal. Intramedullary or subarachnoid hemorrhage could also lead to meningismus or acute pain [15, 37]. While only 35% of patients present with hemorrhage, over 50% have multiple hemorrhage at the time of diagnosis.

### 6.2. Imaging

MRI is the modality of choice when determining the location of the AVM. Flow voids can be seen on T1 weighted imaging. On T2 weighted imaging, hyperintensity and cord expansion are noted, which may be associated with venous hypertension. Appearance of subarachnoid or intraparenchymal bleeding on MRI varies depending on whether it is acute or chronic blood. In extradural-intradural AVM, the extension of the vessels into the paraspinal tissue can be found on MRI [2, 15, 37].

### 6.3. Treatment

The goal for treating extradural-intradural AVM is no different than any other type of AVM—obliteration of the nidus without causing damage to the spinal cord. However, treatment is very difficult and involves a multidisciplinary approach. A common strategy is to embolize the multiple feeding arteries followed by resecting the nidus if possible. Complete resection without neurological deficits is extremely difficult [15, 20, 37].

### 6.4. Outcome

Many cases of extradural-intradural AVM are inoperable. There are only a few case reports that relate successful resection of nidus with pre-operative embolization. No long term outcome data is available for this disorder [20].

## 7. Intramedullary AVM's

### 7.1. Anatomy and etiology

A spinal intramedullary AVM is formed by multiple abnormal vessels constituting a nidus with a feeding artery and a draining vein. These lesions were classified as type II (glomus) AVMs in the earlier classification by Anson and Spetzler [11] and as intramedullary AVMs in a later classification [15]. The nidus may be entirely intramedullary in location, intra and extramedullary or may be located in the region of conus medullaris. The intramedullary AVMs resemble the intracranial AVMs closely, in that they are located within the parenchyma and have distinct multiple feeding arteries from either the anterior or posterior spinal arteries and draining veins. These lesions are most often located in the cervico-thoracic area. Another distinct feature of the intramedullary AVMs is the association with spinal aneurysms. About 20-40% of spinal intramedullary AVMs are associated with aneurysms and their presence is associated with increased risk of bleeding [7, 20].

### 7.2. Types

Djindjian and colleagues suggested classifying them into types based on the volume of spinal cord involved. They divided the AVMs into type I-normal volume, type II-enlarged volume and type III-intra and extramedullary AVM [12]. However, they are more simply classified by Spetzler into compact and diffuse forms [15]. The compact forms were earlier classified as glomus type and the diffuse forms were classified as juvenile AVMs. The juvenile AVMs form a distinct sub-group in that they have an embryological basis for their location. They usually arise from single or multiple somites, are usually both intra and extradural and may involve soft tissue and bone in addition to the spinal cord parenchyma. Most often they are diffuse and do not have a nidus. They may also be a manifestation of a syndromic complex such as the metameric angiomatosis (Cobb's syndrome), disseminated angiodysplasia (Osler-Weber-Rendu syndrome), Klippel-Trenaunay syndrome, or Parkes-Weber syndrome.

### 7.3. Clinical manifestations

Patients usually present in the first three decades of life, most commonly in the third decade. Hemorrhage is seen in up to 50% of patients. About 25% patients present with motor and sensory symptoms. The risk of re-bleeding in patients presenting with hemorrhage is 10% at one month and 40% at one year [22]. No sex predilection is seen in the adult population, but in childhood boys are more likely to be affected than girls. Non-hemorrhagic manifestations include back pain, radicular pain, motor/sensory deficits, sexual disturbance, sphincter disturbances and bruit. Conus AVMs, due to their location present most often with radicular pain, and involvement of the cauda equina.

Five factors contribute to the spectrum of clinical manifestations in patients with spinal AVMs.

**Hemorrhage:** Up to 50% of patients present with subarachnoid hemorrhage or acute medullary syndrome. These patients may present with moderate to severe backache and sudden neurologic deficit. The clinical course is often consists of progressive neurologic deficit with repeated hemorrhage. Sometimes, the patient may relate the onset of symptoms to a trivial trauma which may not be related to the neurological deficit. Spinal aneurysms located on the feeding arteries or draining veins may rupture causing acute onset neurologic deficits and/or low backache. Intracranial subarachnoid hemorrhage has also been reported due to spinal vascular malformation [21, 29].

**Venous hypertension:** As in intracranial AVMs, the arterialized veins have dysplastic walls and are not capable of handling high blood pressure. The resulting venous hypertension either leads to rupture of these vessels and hemorrhage or causes venous congestion and ischemia of the surrounding neural tissue due to pressure effect. Symptoms may be positional with maneuvers such as squatting or raising the leg above heart level causing increased venous congestion and exacerbation of symptoms.

**Venous thrombosis:** Thrombosis due to venous congestion is seen predominantly in low flow AVMs. Partial or complete thrombosis causes venous hypertension and predisposes to ischemic damage of surrounding parenchyma and hemorrhage.

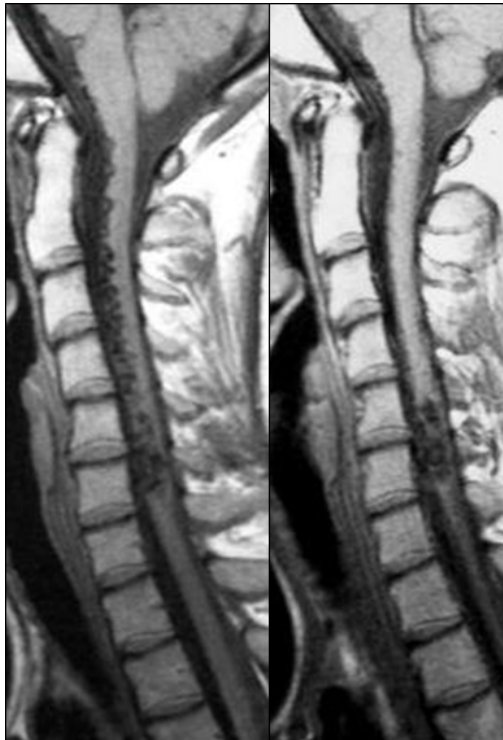**Vascular steal:** The phenomenon of vascular steal due to high blood flow is seen in high-flow AVMs. The AVM vessels are dysplastic and do not respond to regulatory signals. With limited ability to vasoconstrict, more blood is diverted to the AVM and the surrounding normal tissue suffers ischemic damage.

**Mechanical compression:** The bulky arterialized veins can cause compression of the surrounding parenchyma leading to progressive neurologic deficits. Depending upon the level where the spinal cord and nerve root are compressed, the patient may present with a combination of myelopathy and radiculopathy.

### 7.4. Imaging

A high index of suspicion is required to diagnose the lesions. Magnetic resonance imaging (MRI) and magnetic resonance angiography (MRA) are the first choice of investigation although angiography is the gold standard for definitive diagnosis and characterization of

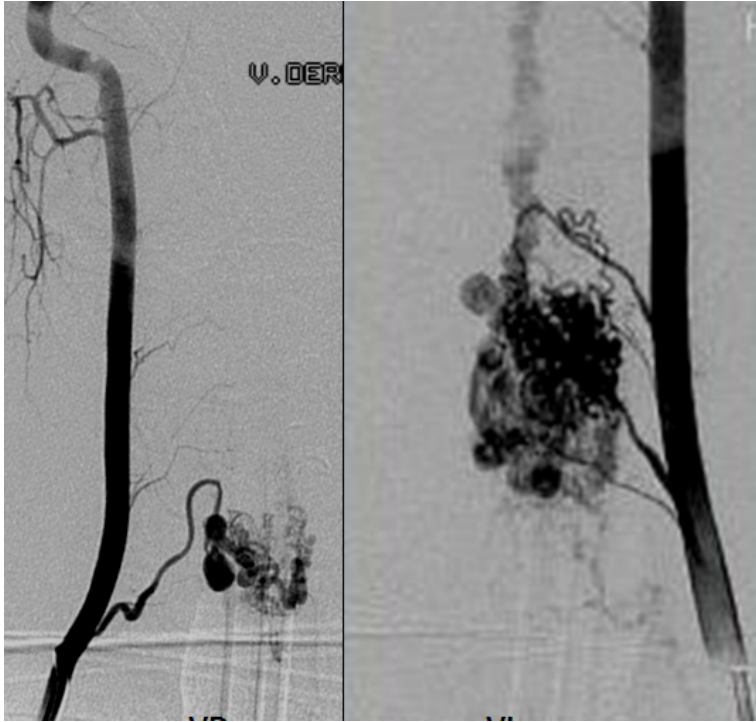
these lesions. MR features suggestive of vascular malformations include a serpentine pattern of low signal on T1 and T2WI (flow in dilated tortuous vessels of the arterialized coronal venous plexus), scalloped appearance on T1WI (Arterialized pial veins may focally indent the cord surface) and spinal cord signal changes due to venous congestion, myelomalacia, infarction and hemorrhage. MRA is increasingly being used for the diagnosis, localization and characterization of spinal AVMs. Mull et al reported identification of the feeding artery in 10 out of 11 patients with intradural spinal AVMs [8]. The limitations of MRA are difficulty in detection of multiple feeding vessels, low sensitivity for detection of spinal aneurysms, and inability to offer therapy in the same sitting. (Figure 5)



**Figure 5.** T1 Sagittal MRI showing serpentine “low signal” within the parenchyma of the cervical spinal cord

Digital subtraction angiography is the gold standard for diagnosis and characterization of spinal AVMs. It also offers the opportunity to treat these lesions in the same sitting. All the segmental arteries are individually catheterized on both sides to avoid missing silent lesions. The vertebral artery, thyrocervical trunk, costocervical trunk, intercostal arteries, lumbar intersegmental arteries, internal iliac arteries and sacral arteries should be visualized during the procedure. Important information to be sought on DSA includes (1) Location of AVF/AVM, feeding pedicle (2) side and site of AVF/AVM (left/right, dorsal/ventral) (3) type of fistula

(dural / epidural / perimedullary) (4) location of anterior spinal and posterior spinal arteries in relation to the lesion. (Figure 6)



**Figure 6.** Spinal angiogram revealing an intramedullary AVF supplied by the vertebral artery

### 7.5. Treatment

The first successful surgery for spinal AVM was carried out by Elsberg in 1912. The goal of treatment is total obliteration or complete excision of the lesion. However, in some cases of juvenile AVMs, the risks associated with treatment outweigh the potential benefits from treatment. In these cases, observation may be the best choice.

There are three modalities for treatment of spinal AVMs (1) surgery (2) endovascular and (3) stereotactic radiosurgery. In some cases a combination of two modalities may have to be employed to tackle the lesion.

Surgical excision remains the gold standard for the treatment of spinal AVMs. The general neurosurgical principles involved in the excision of intracranial AVMs apply. For intramedullary lesions, a midline myelotomy is performed and the nidus is dissected carefully all around. The feeder arteries are interrupted first followed by the draining veins in the end. Juvenile AVMs are the most difficult to treat as they extend over several spinal cord segments,

have multiple feeding vessels and do not have well-defined margins. Use of intraoperative SSEP and MEP monitoring, wide laminectomy and adequate exposure helps in minimizing traction and damage to the spinal cord parenchyma. Fusion may be required in a few cases if instability is caused due to facet removal.

Endovascular therapy is used either primarily or to shrink the lesion to help in surgery. Selective catheterization of feeder arteries rather than the segmental artery helps in preventing ischemia of the normal parenchyma that the segmental artery may supply. Provocative testing of radicular arteries may be undertaken via the administration of lidocaine. If corresponding deficits are noted, embolizing the corresponding feeder may not be safe. Various embolic materials that have been used include polyvinyl alcohol particles, sponge particles, balloon occlusion, liquid embolic agents such as N-butyl cyanoacrylate (NBCA), ethylene vinyl alcohol copolymer, Onyx and finally the Guglielmi Detachable Coils (GDC). Factors favoring successful endovascular occlusion include normal anterior spinal artery separate from the nidus, short distance between the feeders and the nidus, and high flow through the lesion. Occlusion of the nidus may lead to edema of the surrounding parenchyma and neurological deterioration. This is often a self-limiting condition and the patient recovers in a few weeks. Use of corticosteroids in this period may be helpful.

Although stereotactic radiosurgery (SRS) is one of the established modalities of treatment for intracranial vascular malformations, its role in the treatment of spinal vascular malformations remains investigational. Several articles have been published describing the efficacy of SRS. In one study, the authors observed significant reduction in volumes at a mean follow-up period of 27.9 months [16]. The authors concluded that long term angiographic outcome of patients is required before any treatment recommendation is made [16].

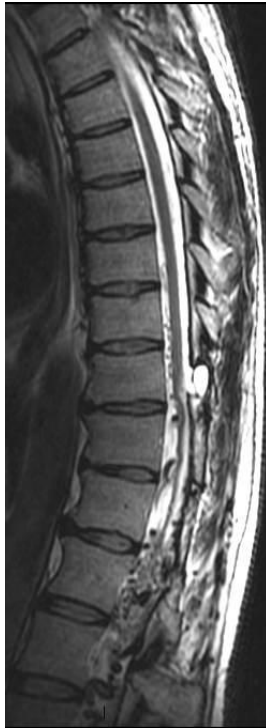## 7.6. Outcome

Spetzler et al noted 68% improvement among the 27 patients who underwent surgery for spinal intramedullary AVMs and 35% improvement in patients with conus AVMs. Endovascular therapy results in successful embolization of about 63% of spinal intramedullary AVMs [1].

## 8. Conus medullaris AVMs

This subset of intramedullary AVMs was proposed by Spetzler in 2002 and consists of lesions at the conus medullaris with multiple feeding arteries, multiple niduses and complex venous drainage. They have multiple direct arteriovenous shunts that derive from the anterior and posterior spinal arteries and have diffuse niduses that are usually extramedullary and pial based. An intramedullary component may also be present. Because of the special location of these lesions, patients may present with both upper and lower motor neuron symptoms. (Figure 7)





**Figure 7.** T2 Sagittal MRI showing tortuous vessels at the level of the conus in a male presenting with severe cauda equina syndrome.

## 9. Conclusion

Spinal arteriovenous lesions are a rare and diverse group of lesions that can pose challenges for clinicians both in diagnosis and treatment. Preoperative workup with quality imaging including MRI and angiogram is necessary to delineate the vascular anatomy as well as the effect on the spinal cord parenchyma. With this knowledge the proper open, endovascular, or combined treatment can be selected.

## Author details

Benjamin Brown, Chiazio Amene, Shihao Zhang, Sudheer Ambekar, Hugo Cuellar and Bharat Guthikonda

LSU Health – Shreveport, LA, USA

## References

- [1] Biondi A, Merland JJ, Hodes JE, Pruvo JP, Reizine D. Aneurysms of spinal arteries associated with intramedullary arteriovenous malformations. I. Angiographic and clinical aspects. *AJNR Am J Neuroradiol.* 1992;13(3):913–922.
- [2] Kim LJ, Spetzler RF. Classification and surgical management of spinal arteriovenous lesions: arteriovenous fistulae and arteriovenous malformations. *Neurosurgery.* 2006;59(5 Suppl 3):S195–201; discussion S3–13.
- [3] Heros RC, Debrun GM, Ojemann RG, Lasjaunias PL, Naessens PJ. Direct spinal arteriovenous fistula: a new type of spinal AVM. Case report. *J. Neurosurg.* 1986;64(1):134–139.
- [4] Symon L, Kuyama H, Kendall B. Dural arteriovenous malformations of the spine. Clinical features and surgical results in 55 cases. *J. Neurosurg.* 1984;60(2):238–247.
- [5] Jellema K, Tijssen CC, van Gijn J. Spinal dural arteriovenous fistulas: a congestive myelopathy that initially mimics a peripheral nerve disorder. *Brain.* 2006;129(Pt 12):3150–3164.
- [6] Niimi Y, Berenstein A, Setton A, Neophytides A. Embolization of spinal dural arteriovenous fistulae: results and follow-up. *Neurosurgery.* 1997;40(4):675–682; discussion 682–683.
- [7] Biondi A, Merland JJ, Reizine D, et al. Embolization with particles in thoracic intramedullary arteriovenous malformations: long-term angiographic and clinical results. *Radiology.* 1990;177(3):651–658.
- [8] Mull M, Nijenhuis RJ, Backes WH, et al. Value and limitations of contrast-enhanced MR angiography in spinal arteriovenous malformations and dural arteriovenous fistulas. *AJNR Am J Neuroradiol.* 2007;28(7):1249–1258.
- [9] Krings T, Thron AK, Geibprasert S, et al. Endovascular management of spinal vascular malformations. *Neurosurg Rev.* 2010;33(1):1–9.
- [10] Asai J, Hayashi T, Fujimoto T, Suzuki R. Exclusively epidural arteriovenous fistula in the cervical spine with spinal cord symptoms: case report. *Neurosurgery.* 2001;48(6):1372–1375; discussion 1375–1376.
- [11] Anson JA, Spetzler RF. Interventional neuroradiology for spinal pathology. *Clin Neurosurg.* 1992;39:388–417.
- [12] Djindjian M, Djindjian R, Rey A, Hurth M, Houdart R. Intradural extramedullary spinal arterio-venous malformations fed by the anterior spinal artery. *Surg Neurol.* 1977;8(2):85–93.

- [13] Mourier KL, Gobin YP, George B, Lot G, Merland JJ. Intradural perimedullary arteriovenous fistulae: results of surgical and endovascular treatment in a series of 35 cases. *Neurosurgery*. 1993;32(6):885–891; discussion 891.
- [14] Barrow DL, Colohan AR, Dawson R. Intradural perimedullary arteriovenous fistulas (type IV spinal cord arteriovenous malformations). *J. Neurosurg*. 1994;81(2):221–229.
- [15] Spetzler RF, Detwiler PW, Riina HA, Porter RW. Modified classification of spinal cord vascular lesions. *J. Neurosurg*. 2002;96(2 Suppl):145–156.
- [16] Sinclair J, Chang SD, Gibbs IC, Adler JR Jr. Multisession CyberKnife radiosurgery for intramedullary spinal cord arteriovenous malformations. *Neurosurgery*. 2006;58(6):1081–1089; discussion 1081–1089.
- [17] Steinmetz MP, Chow MM, Krishnaney AA, et al. Outcome after the treatment of spinal dural arteriovenous fistulae: a contemporary single-institution series and meta-analysis. *Neurosurgery*. 2004;55(1):77–87; discussion 87–88.
- [18] Gjertsen O, Nakstad PH, Pedersen H, Dahlberg D. Percutaneous intravertebral body embolization of a traumatic spinal epidural arteriovenous fistula with secondary perimedullary venous reflux. A case report. *Interv Neuroradiol*. 2010;16(1):97–102.
- [19] Hall WA, Oldfield EH, Doppman JL. Recanalization of spinal arteriovenous malformations following embolization. *J. Neurosurg*. 1989;70(5):714–720.
- [20] Rosenblum B, Oldfield EH, Doppman JL, Di Chiro G. Spinal arteriovenous malformations: a comparison of dural arteriovenous fistulas and intradural AVM's in 81 patients. *J. Neurosurg*. 1987;67(6):795–802.
- [21] van Beijnum J, Straver DCG, Rinkel GJE, Klijn CJM. Spinal arteriovenous shunts presenting as intracranial subarachnoid haemorrhage. *J. Neurol*. 2007;254(8):1044–1051.
- [22] da Costa L, Dehdashti AR, terBrugge KG. Spinal cord vascular shunts: spinal cord vascular malformations and dural arteriovenous fistulas. *Neurosurg Focus*. 2009;26(1):E6.
- [23] Hurst RW, Kenyon LC, Lavi E, Raps EC, Marcotte P. Spinal dural arteriovenous fistula The pathology of venous hypertensive myelopathy. *Neurology*. 1995;45(7):1309–1313.
- [24] Narvid J, Hetts SW, Larsen D, et al. Spinal dural arteriovenous fistulae: clinical features and long-term results. *Neurosurgery*. 2008;62(1):159–166; discussion 166–167.
- [25] Bowen BC, Fraser K, Kochan JP, et al. Spinal dural arteriovenous fistulas: evaluation with MR angiography. *AJNR Am J Neuroradiol*. 1995;16(10):2029–2043.
- [26] Khaldi A, Hacein-Bey L, Oigitano TC. Spinal epidural arteriovenous fistula with late onset perimedullary venous hypertension after lumbar surgery: case report and discussion of the pathophysiology. *Spine*. 2009;34(21):E775–779.

- [27] Silva N Jr, Januel AC, Tall P, Cognard C. Spinal epidural arteriovenous fistulas associated with progressive myelopathy. Report of four cases. *J Neurosurg Spine*. 2007;6(6):552–558.
- [28] Rangel-Castilla L, Holman PJ, Krishna C, et al. Spinal extradural arteriovenous fistulas: a clinical and radiological description of different types and their novel treatment with Onyx. *J Neurosurg Spine*. 2011;15(5):541–549.
- [29] Germans MR, Pennings FA, Sprengers MES, Vandertop WP. Spinal vascular malformations in non-perimesencephalic subarachnoid hemorrhage. *J. Neurol*. 2008;255(12):1910–1915.
- [30] Hirayama K, Foix C, Alajouanine T. [Subacute necrotic myelitis (Foix-Alajouanine disease) 1]. *Shinkei Kenkyu No Shimpo*. 1970;14(1):208–225.
- [31] Cecchi PC, Musumeci A, Faccioli F, Bricolo A. Surgical treatment of spinal dural arterio-venous fistulae: long-term results and analysis of prognostic factors. *Acta Neurochir (Wien)*. 2008;150(6):563–570.
- [32] Aminoff MJ, Logue V. The prognosis of patients with spinal vascular malformations. *Brain*. 1974;97(1):211–218.
- [33] Aminoff MJ, Barnard RO, Logue V. The pathophysiology of spinal vascular malformations. *J. Neurol. Sci*. 1974;23(2):255–263.
- [34] Ropper AE, Gross BA, Du R. Surgical treatment of Type I spinal dural arteriovenous fistulas. *Neurosurg Focus*. 2012;32(5):E3.
- [35] Patsalides A, Santillan A, Knopman J, et al. Endovascular management of spinal dural arteriovenous fistulas. *J Neurointerv Surg*. 2011;3(1):80–84.
- [36] Nichols DA, Rufenacht DA, Jack CR Jr, Forbes GS. Embolization of spinal dural arteriovenous fistula with polyvinyl alcohol particles: experience in 14 patients. *AJNR Am J Neuroradiol*. 1992;13(3):933–940.
- [37] Clarke MJ, Krauss WE, Pichelmann, MA. Spinal Vascular Malformations. In: The textbook of spinal surgery. 3<sup>rd</sup> Edition. Philadelphia: Lippincott Williams and Wilkins; 2011. p. 1544-1552.