

---

# FDG- PET Imaging in Neurodegenerative Brain Diseases

---

L. K. Teune, A. L. Bartels and K. L. Leenders

Additional information is available at the end of the chapter

<http://dx.doi.org/10.5772/56505>

---

## 1. Introduction

### 1.1. Cerebral glucose metabolism

Increases and decreases of synaptic activity in the brain are accompanied by proportional changes in capillary perfusion and local glucose consumption. These changes in glucose consumption are the effect of changed activity or density of the afferent nerve terminals in that region. Loss of neurons may result in decreased glucose consumption in distant brain regions by deafferentiation, while also increased regional glucose consumption by increased activation of afferent neurons can occur. The PET tracer [<sup>18</sup>F]fluorodeoxyglucose (FDG) allows the measurement of glucose consumption. FDG is a glucose analog with physiological aspects almost identical to glucose. It is transported from the blood to the brain by a carrier-mediated diffusion mechanism. FDG and glucose are phosphorylated by hexokinase as the first step of the glycolytic process. FDG differs from glucose in that a hydrogen atom replaced the hydroxyl group at the second carbon atom of the molecule. Glucose is then phosphorylated to glucose-6-PO<sub>4</sub>, and continues along the glycolytic pathway for energy production. However, FDG is phosphorylated to FDG-6-PO<sub>4</sub>, which is not a substrate for further metabolism and trapped in tissues. As glucose is the only source of energy for the brain it reflects the neuronal integrity of underlying brain pathology. Since FDG is a competitive substrate with glucose for both transport and phosphorylation, it is important for tracer uptake to avoid high blood glucose levels during an FDG-PET scan in subjects with diabetes.

In neurodegenerative brain diseases, specific brain regions degenerate and specific patterns of metabolic brain activity develop. This happens before clear structural changes can be detected with imaging techniques.

Measurement of glucose consumption with FDG PET imaging thus allows us to identify disease-specific cerebral metabolic brain patterns in several neurodegenerative brain diseases at an early disease stage. Since the first FDG PET study in man in 1979 (Reivich, et al. 1979)

regional differences in cerebral glucose metabolism have been reported in various neurodegenerative brain diseases including parkinsonian syndromes.

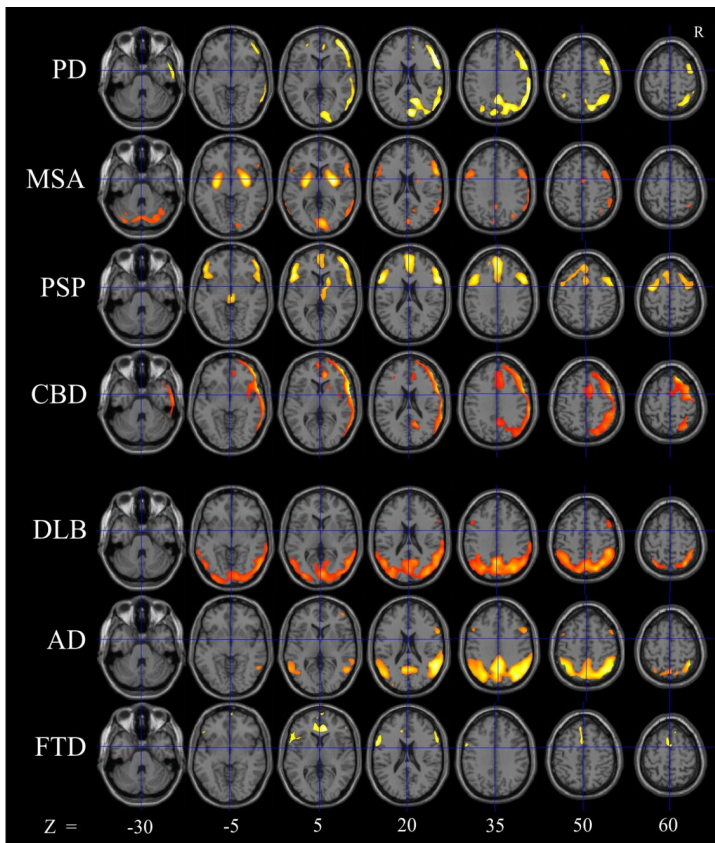
## 2. Disease-specific metabolic brain patterns: Methods

Univariate methods like voxel-based statistical parametric mapping (SPM) analyses have been used to identify group differences between patients with neurodegenerative brain diseases and controls. (Eckert, et al. 2005, Juh, et al. 2004, Yong, et al. 2007).

At the University Medical Center Groningen, The Netherlands we have performed a retrospective study (Teune, et al. 2010) selecting typical patients with 7 different neurodegenerative brain diseases who had had a clinical FDG brain scan at a time point when their diagnosis was not sure yet. These patients developed in the following years the mentioned typical disease states. Images of each of the seven patient groups were separately compared to controls using a two-sample t test. At those early scans, already typical differences between patient - and control groups were found for each disease.

However, Scaled Subprofile modelling/principal component analysis (SSM/PCA), a multivariate method, not only identifies group differences, but is also able to identify relationships in relatively increased and decreased metabolic activity between different brain regions in combined samples of patients and control scans (Eidelberg. 2009, Moeller, et al. 1987). Covariance analysis techniques are considered appropriate methods to explore network activity. In the SSM, a threshold of the whole-brain maximum can be applied to remove out-of-brain voxels, followed by a log transformation. A threshold of 35% is used by the Eidelberg research group resulting in a mask of mainly grey matter (Spetsieris and Eidelberg. 2010). After removing between-subject and between-region averages, a principal component analysis (PCA) can be applied. PCA transforms a set of correlated variables into a new set of orthogonal uncorrelated variables that are called the principal components. Voxels participating in each principal component (PC) may have either a positive or a negative loading. The loadings express the covariance structure (i.e. the strength of the interaction) between the voxels that participate in the PC. They are ordered in terms of the variability they represent. That is, the first principal components represents for a single dimension (variable) the greatest amount of variability in the original dataset. Each succeeding orthogonal component accounts for as much of the remaining variability as possible. They can be very helpful in determining how many of the components are really significant and how much the data can be reduced.

In most studies, the components that together describe at least 50% of the variance are used for further analysis, but this is an arbitrary limit. To identify a covariance pattern that best discriminates a patient group from a control group, each subject's expression of the selected principal components with the lowest AIC (Akaike information criterion) value (Akaike. 1974) are entered into a stepwise regression procedure. This regression results in a linear combination of the PCs that best discriminated the two groups and is designated as the disease-specific metabolic covariance pattern.



**Figure 1.** Typical cerebral metabolic patterns in neurodegenerative brain diseases. SPM (t) maps of decreased metabolic activity were overlaid on a T1 MR template thresholded at  $P < 0.001$  with cluster cutoff of 20 voxels. Patient groups are indicated on the vertical axis and on the horizontal axis, seven transversal slices through the brain are shown. PD = Parkinson's disease: decreased metabolic activity in the contralateral to the most affected body side parieto-occipital and frontal regions; MSA = multiple system atrophy: decreased metabolic activity in bilateral putamen and cerebellum; PSP = progressive supranuclear palsy: decreased metabolic activity in the prefrontal cortex, caudate nucleus, thalamus and mesencephalon; CBD = corticobasal degeneration: decreased metabolic activity in the contralateral to the most affected body side cortical regions; DLB = dementia with Lewy bodies: decreased metabolic activity in the occipital and parieto-temporal regions. AD = Alzheimer's Disease: decreased metabolic activity in the angular gyrus and other parieto-temporal regions including precuneus extending to the posterior- and middle cingulate gyrus. FTD = frontotemporal dementia: decreased metabolic activity in the superior and inferior frontal gyrus, anterior cingulate gyrus, SMA, sensorimotor area and middle temporal gyrus. Adapted from: Teune et al. (2010) Typical cerebral metabolic patterns in neurodegenerative brain diseases. *Movement Disorders*. 2010;25:2395-404.

Important for its use in clinical practice is that this metabolic covariance pattern can then be applied to individual patients to test whether they express the pattern or not. Every voxel value in a subject scan is multiplied by the corresponding voxel weight in the covariance pattern, with a subsequent summation over the whole brain volume. The resulting subject score captures to what extent a subject expresses the covariance pattern.

### 3. Disease-specific metabolic brain patterns in patients with parkinsonism

#### 3.1. Parkinson's disease

Parkinson's disease (PD) is characterized by bradykinesia, rigidity, sometimes rest tremor and postural instability. A disturbed  $\alpha$ -synuclein protein forming so-called Lewy bodies seems to play a causal role, which was a reason to designate PD as a  $\alpha$ -synucleinopathy. The main pathophysiological changes result from degeneration of catecholaminergic, especially dopaminergic cells in brainstem regions.

A characteristic metabolic covariance pattern has been identified in PD patients (PD-related pattern, PDRP) showing regionally relatively increased metabolism in the globus pallidus and putamen, thalamus, pons and cerebellum and relatively decreased metabolism in the lateral frontal, premotor and parietal association areas (Ma, et al. 2007). Network expression in PD patients also increases linearly with disease progression (Huang, et al. 2007b). Tang et al. tried to study network changes in the PD-related motor pattern before symptom onset by studying 15 hemiparkinsonian patients and focusing mainly on the "presymptomatic" hemisphere. They conclude that abnormal PDRP activity antecedes the appearance of motor signs by approximately 2 years (Tang, et al. 2010a). However, this needs to be proven in future research in true presymptomatic patients.

#### 3.2. Parkinson's disease and metabolic brain patterns related to specific symptoms

In addition to motor symptoms, cognitive dysfunction is also common in PD, especially executive and visuospatial dysfunction. FDG-PET studies have been performed to study these specific symptoms and their relations with neural network pathophysiology. The Eidelberg research group has shown PD subclassifications related to specific symptoms. Network analysis with the SSM/PCA approach detected a significant covariance pattern in non-demented PD patients that correlated with memory and executive functioning tasks. The expression of this PD-related cognitive pattern (PDCP) in individual patients correlated with severity of cognitive dysfunction (Huang, et al. 2007a).

Alterations in neuropsychological test results in advanced PD were found to correlate with decreases in glucose metabolism in the dorsolateral prefrontal cortex (DLPFC), lateral orbitofrontal cortex (LOFC) ventral and dorsal cingulum (v/dACC) and in Broca area (Kalbe, et al. 2009). In the study of Kalbe et al, PD patients with deep brain stimulation in the subthalamic nucleus (STN-DBS) showed cognitive decline that correlated with decrease in glucose metabolism in these areas. In another study in STN-DBS treated patients, STN DBS was found to activate glucose metabolism in the frontal limbic and associative territory (Hilker, et al. 2004). Interestingly, cortical areas that show hypometabolism in patients with depression (Mayberg HS. 1994) are similar to the regions that show restored glucose metabolism after STN DBS. This finding agrees with the clinical observation that PD-related depression tends to improve after STN DBS.

Mure et al. identified a spatial covariance pattern associated with Parkinson tremor which was characterized by covarying increases in the cerebellum/dentate nucleus and primary cortex and to a minor degree in the caudate/putamen (Mure, et al. 2011).

Hallucinations in PD have been related to relative frontal hypermetabolism compared to PD patients without hallucinations (Nagano-Saito, et al. 2004). However, another study showed hypometabolism in occipitotemporoparietal regions in PD patients with hallucinations, sparing the occipital pole, while no significant increase in regional glucose metabolism was detected (Boecker, et al. 2007). Interestingly, in patients with dementia with Lewy bodies (DLB), who also suffer from hallucinations, glucose metabolism was also decreased in occipitoparietal regions, however without sparing of the occipital pole (see DLB section).

### 3.3. Multiple system atrophy

Multiple system atrophy is a sporadic neurodegenerative brain disease which affects both men and women and generally starts in the sixth decade of life. The main clinical features are parkinsonism, autonomic failure, cerebellar ataxia, and pyramidal signs in any combination. However, two major motor presentations can be distinguished. Parkinsonian features predominate in 80% of patients (MSA-P subtype) and cerebellar ataxia is the main motor feature in 20% of patients (MSA-C subtype) ((Gilman, et al. 2008, Wenning, et al. 1997)

In MSA-P the striatonigral system is the main site of pathology but less severe degeneration can be widespread and normally includes the olivopontocerebellar system. In MSA-C pathological changes are mainly seen in the olivopontocerebellar system and involvement of striatum and substantia nigra are less severe (Wenning, et al. 1997). The discovery of glial cytoplasmic inclusions in MSA brains highlighted the unique glial pathology as biological hallmark of the disease. Their distribution selectively involves basal ganglia, supplementary and primary motor cortex, the reticular formation and pontocerebellar system. Glial cytoplasmic inclusions contain besides classical cytoskeletal antigens also  $\alpha$ -synuclein, which is a presynaptic protein present in Lewy Bodies, and this accumulation seems to play a central part not only in MSA but also in other  $\alpha$ -synucleinopathies such as PD and DLB.

Disease-related metabolic patterns were also present in MSA consisting of hypometabolism in putamen and cerebellum in MSA (Eckert, et al. 2008). Poston et al. found that differences in expression of the MSA-related pattern correlated with clinical disability (Poston, et al. 2012).

### 3.4. Progressive supranuclear palsy

The clinical picture of progressive supranuclear palsy (PSP) has been first described by Steele, Richardson and Olszewski (Steele JC, Richardson J, Olszewski J. 1964) and is characterized by progressive parkinsonism, early gait and balance impairment, vertical gaze palsy and more profound frontal cognitive disturbances. PSP is one of several neurodegenerative diseases characterised by accumulation of hyperphosphorylated tau (tauopathy), forming abnormal filamentous inclusions in neurons and glia in the precentral and postcentral cortical areas but also in the thalamus, subthalamic nucleus, red nucleus and substantia nigra. Other neurodegenerative brain diseases which show disturbances in tau protein handling are corticobasal

degeneration (CBD) and frontotemporal dementia (FTD) but there is also overlap in pathology with Alzheimer's disease (AD).

However the metabolic brain patterns in these tauopathies are quite different. The covariance pattern of PSP consists of decreased metabolism in the prefrontal cortex, frontal eye fields, caudate nuclei, medial thalamus and upper brainstem (Eckert, et al. 2008). Brain stem atrophy and atrophy of the medial frontal cortical regions have also been reported in histopathological studies (Hauw, et al. 1994).

### **3.5. Corticobasal degeneration**

The most striking features of patients with corticobasal degeneration (CBD) include marked asymmetrical parkinsonism and apraxia but also postural instability, limb dystonia, cortical sensory loss, dementia and the alien limb phenomenon. CBD is one of the tauopathies and clinical diagnosis is complicated by both the variability of presentation of true CBD and the syndromes that look alike but are caused by other tauopathies with parkinsonism like PSP or FTD (Josephs, et al. 2006). However with functional neuroimaging a clear distinction can be made. In CBD a typical pattern of hypometabolism is seen in cortical regions contralateral to the affected body side, including parieto-temporal regions, prefrontal cortex and motor cortex. Furthermore, a decrease can be found in the contralateral caudate nucleus, putamen and thalamus (Eckert, et al. 2005, Teune, et al. 2010). No covariance pattern has been described using the SSM/PCA technique in CBD.

## **4. Disease-specific metabolic brain patterns in the differential diagnosis of individual patients with parkinsonism**

Interestingly, Tang and co-workers studied the potential role of FDG PET in the individual diagnosis of 167 patients who had parkinsonian features but uncertain clinical diagnosis (Tang, et al. 2010b) After FDG PET imaging, patients were assessed by blinded movement disorders specialists for a mean of 2.6 years before a final clinical diagnosis was made (gold standard). SSM/PCA analysis can quantify the expression of an obtained covariance pattern in each subject which allows assessing the expression of a given pattern on a single case basis. Using this automated image-based classification procedure and the previously defined disease related covariance patterns in PD, MSA and PSP, individual patients were differentiated with high specificity.

However, blinded, prospective imaging studies (ideally involving multiple centers, a larger validation group, repeat imaging, and more extensive post-mortem confirmation) are needed to establish the accuracy and precision of this pattern-based categorisation procedure. These studies are currently undertaken.

For routine clinical practice, this knowledge of disease specific patterns of regional metabolic activity in neurodegenerative brain diseases can be a valuable aid in the differential diagnosis of individual patients, especially at an early disease stage.



## 5. Disease-specific metabolic brain patterns in dementia

### 5.1. Alzheimer's disease

Alzheimer's disease (AD) is a progressive neurodegenerative brain disease accounting for 50-60% of cases of dementia. AD is characterized by a severe decline in episodic memory together with general cognitive symptoms such as impaired judgement, decision making and orientation (McKhann, et al. 1984). A correct clinical diagnosis can be difficult, especially in early disease stages or in patients with for example comorbid depression, high education or young age (Bohnen, et al. 2012). FDG-PET imaging can be used to assist in the differential diagnosis, because for different dementia syndromes, a separate pattern of hypometabolism can be found. In Alzheimer's disease (AD), decline of FDG uptake in posterior cingulate, temporoparietal and prefrontal association cortex was related to dementia severity (Herholz, et al. 2002). Foster et al used visual interpretation of an automated three-dimensional stereotactic surface projection technique of patients with AD and FTD. They showed that visual interpretation of FDG-PET scans after training is more reliable and accurate in distinguishing FTD from AD than clinical methods alone (Foster, et al. 2007).

Although multivariate analytical techniques might identify diagnostic patterns that are not captured by univariate methods, they have rarely been used to study neural correlates of Alzheimer's Disease or cognitive impairment. Because cognitive processes are the result of integrated activity in networks rather than activity of any one area in isolation, functional connectivity can be better captured by multivariate methods. A study from Habeck et al. examined the efficacy of multivariate and univariate analytical methods and concluded that multivariate analysis might be more sensitive than univariate analysis for the diagnosis of early Alzheimer's disease (Habeck, et al. 2008).

Scarmeas et al. were the first to derive an AD related covariance pattern using  $H_2^{15}O$  to measure brain perfusion (Scarmeas, et al. 2004). It consisted of relatively increased perfusion in the bilateral insula, lingual gyri and cuneus with bilaterally decreased flow in bilateral inferior parietal lobule and cingulate in AD patients. However, using this PET tracer they found a sensitivity of 76-94% and a specificity of 63-81% with considerable overlap in pattern expression among AD patients and controls. Therefore they concluded that the derived  $H_2^{15}O$  pattern cannot be used as a sufficient diagnostic test in clinical settings. Specific FDG covariance patterns to distinguish early AD-related cognitive decline using multivariate methods have yet to be specified.

### 5.2. Frontotemporal dementia

Frontotemporal dementia (FTD) is one of the neurodegenerative diseases commonly mistaken for AD. FTD patients do not have a true amnesic syndrome but can present with either gradual and progressive changes in behaviour, or gradual and progressive language dysfunction. Gross examination of the post-mortem brain from a patient with FTD usually reveals frontal or temporal lobar atrophy or both, but the distribution or severity of brain atrophy are not specific for a particular neurodegenerative brain disease. Jeong et al. and Diehl-Schmid et al.

analysed FDG-PET scans of FTD patients on a voxel-by-voxel basis using Statistical Parametric Mapping (SPM). They found hypometabolism depending on disease stage in the frontal lobe, parietal and temporal cortices (Diehl-Schmid, et al. 2007, Jeong, et al. 2005).

### 5.3. Dementia with Lewy Bodies

The clinical overlap of dementia and parkinsonism is highlighted in Dementia with Lewy Bodies (DLB). These patients show besides dementia extrapyramidal motor symptoms and marked neuropsychiatric disturbances including visual hallucinations, depression, variability in arousal and attention (McKeith, 2006). Consistent observation of a metabolic reduction in the medial occipital cortex in DLB patients (Minoshima, et al. 2001, Teune, et al. 2010) using FDG-PET imaging suggests the use of FDG-PET in the differential diagnosis of AD and DLB and of PD and DLB. Minoshima et al. found that the presence of occipital hypometabolism distinguished DLB from AD with 90% sensitivity and 80% specificity when using post-mortem diagnosis as the gold standard diagnosis (Minoshima, et al. 2001).

## 6. Disease-specific metabolic brain patterns in hyperkinetic movement disorders

### 6.1. Huntington's disease

Huntington's disease (HD) is characterized by progressive dementia and chorea, starting around 30-40 years of age. HD is caused by a dominantly inherited CAG repeat expansion mutation that generates lengthening of the protein huntingtin, with size-dependent neurotoxicity. Several PET studies have shown hypometabolism in the caudate nucleus, both in symptomatic and asymptomatic mutation carriers (Grafton, et al. 1992) (Antonini A., et al. 1996) In asymptomatic carriers, metabolic decreases were also significantly associated with the CAG repeat number (Antonini A., et al. 1996). Furthermore, it was found that FDG uptake in the caudate nucleus provided a predictive measure for time of onset of the disease, in addition to the mutation size (Ciarmiello A., et al. 2012).

Another study applied network analysis of FDG-PET scans in presymptomatic mutation carriers (Feigin, et al. 2001). They found a HD related metabolic covariance pattern (HDRP) characterized by caudate and putamenal hypometabolism, but also including mediotemporal reductions as well as relative increases in occipital regions. Disturbances of these striatotemporal projections may underlie aspects of the psychiatric and cognitive abnormalities that occur in the earliest stages of HD, before the onset of motor signs (Cummings JL. 1995).

### 6.2. Dystonia

Dystonia is a movement disorder characterized by involuntary, sustained muscle contractions causing twisting movements and abnormal postures. The most common forms of primary torsion dystonia (PTD) are DYT1 and DYT6, both caused by autosomal inherited mutations with a reduced penetrance.



Functional neuroimaging techniques have been applied in different dystonic disorders including primary generalized dystonia, mainly DYT1 and DYT6 and dopa-responsive dystonia, as well as focal dystonic syndromes such as torticollis, writer's cramp and blepharospasm. A common finding is abnormality of the basal ganglia, cerebellum and associated outflow pathways to sensorimotor cortex and other regions involved with motor performance. However, controversial results have been found in imaging dystonias, partly attributed to methodological differences but also to the heterogeneity of the dystonias. Using the SSM/PCA approach a reproducible pattern of abnormal regional glucose utilization in two independent cohorts of DYT1 carriers have been found (Eidelberg D. 1998)(Trost M., et al. 2002).

This torsion-dystonia related metabolic pattern is characterized by increases in the posterior putamen/globus pallidus, cerebellum and SMA. Interestingly, also in clinically non-manifesting mutation carriers this pattern was found, suggesting a cerebral "vulnerability to develop dystonia" network change. Also in manifesting and non-manifesting DYT 6 carriers abnormal network activity has been identified. A difference between DYT1 and DYT6 metabolic patterns can be seen in the putamen, where glucose metabolism is increased in DYT1 and decreased in DYT6, possibly do to cell loss in DYT6. Furthermore, the cerebellum shows increased activity in DYT1 and normal activity in DYT6 (Carbon M., et al. 2004).

The TDRP network is not expressed in patients with Dopa-responsive dystonia (DRD) (Trost M., et al. 2002).

DRD is characterized by an early onset of dystonic symptoms and later appearance of parkinsonian symptoms. A defining feature is a marked and sustained response to low doses of levodopa, suggesting that the lesion may be functional in the presynaptic dopaminergic system rather than anatomical. The DRD related metabolic pattern is characterized by relative increases in the dorsal midbrain, cerebellar vermis, and SMA, associated with covarying decreases in putamen, lateral premotor and motor cortical regions (Asanuma, et al. 2005b). This DRD related pattern is not apparent in DYT 1 and 6 carriers supporting the hypothesis that the pathophysiology of DRD differs from that of other forms of dystonia. They also found that the Parkinson-related metabolic pattern is not apparent in DRD patients. Thus FDG-PET can be useful to distinguish PD related dystonia from dopa-responsive dystonia with parkinsonism (Asanuma, et al. 2005a).

### 6.3. Gilles de la Tourette

Tourette syndrome is characterized by the presence of chronic motor and vocal tics that develop before the age of 18. Comorbid behavioural abnormalities are common in Tourette syndrome, most notably obsessive-compulsive disorder and attention deficit/hyperactivity disorder (Lebowitz, et al. 2012). The neurophysiology remains poorly understood with varying and inconsistent neuropathological and neuroimaging findings, possibly due to the clinical heterogeneity of the disorder. Pourfar et al. identified a Tourette syndrome related pattern characterized by reduced metabolic activity of the striatum and orbitofrontal cortex associated with relatively increased metabolic activity in the premotor cortex and cerebellum. A second metabolic brain pattern was found in patients with Tourette syndrome and obsessive com-

pulsive disorder characterized by reduced activity in the anterior cingulate and dorsolateral prefrontal cortex and relative increases in primary motor cortex and precuneus. Subject expression correlated with symptom severity. These findings suggest that the different clinical manifestations of the Tourette syndrome are associated with different abnormal brain networks (Pourfar, et al. 2011).

## 7. Conclusion

FDG-PET imaging is increasingly available for routine clinical practice and has remained the only available radiotracer to detect accurately and reliably the cerebral glucose metabolism. As glucose is the only source of energy for the brain it reflects the energy needs of underlying brain neuronal systems. The SSM/PCA method can identify relationships in relatively increased and decreased metabolic activity between different brain regions in combined samples of patients and controls. The expression of an obtained covariance pattern can be quantified in an individual patient and this resulting subject score captures to what extent a patient expresses the covariance patterns. The disease-related metabolic brain patterns can therefore be a valuable aid in the early differential diagnosis of individual patients with neurodegenerative brain diseases.

## Author details

L. K. Teune, A. L. Bartels<sup>\*</sup> and K. L. Leenders

<sup>\*</sup>Address all correspondence to: a.l.bartels@umcg.nl

Department of Neurology, University Medical Center Groningen, The Netherlands

## References

- [1] Akaike, H. A new look at the statistical model identification. *A New Look at the Statistical Model Identification* (1974). , 1974, 716-23.
- [2] Antonini, A, Leenders, K. L, Spiegel, R, Meier, D, Vontobel, P, Weigell-weber, M, et al. Striatal glucose metabolism and dopamine D2 receptor binding in asymptomatic gene carriers and patients with huntington's disease. (1996).
- [3] Asanuma, K, Carbon-correll, M, & Eidelberg, D. Neuroimaging in human dystonia. (2005a).
- [4] Asanuma, K, Ma, Y, Huang, C, Carbon-correll, M, Edwards, C, Raymond, D, et al. The metabolic pathology of dopa-responsive dystonia. (2005b).

- [5] Boecker, H, Ceballos-baumann, A. O, Volk, D, Conrad, B, Forstl, H, & Haussermann, P. Metabolic alterations in patients with parkinson disease and visual hallucinations. *Arch Neurol* (2007). , 64, 984-8.
- [6] Bohnen, N. I. Djang DSW, Herholz K, Anzai Y, Minoshima S. Effectiveness and safety of 18F-FDG PET in the evaluation of dementia: A review of the recent literature. *Journal of Nuclear Medicine* (2012). , 53, 59-71.
- [7] Carbon, M, Trost, M, Ghilardi, M. F, & Eidelberg, D. Abnormal brain networks in primary torsion dystonia. (2004).
- [8] Ciarmiello, A, Giovacchini, G, Orobello, S, Bruselli, L, Elifani, F, & Squitieri, F. F-FDG PET uptake in the pre-huntington disease caudate affects the time-to-onset independently of CAG expansion size. (2012).
- [9] Cummings, J. L. Behavioral and psychiatric symptoms associated with huntington's disease. (1995).
- [10] Diehl-schmid, J, Grimmer, T, Drzezga, A, Bornschein, S, Riemenschneider, M, Forstl, H, et al. Decline of cerebral glucose metabolism in frontotemporal dementia: A longitudinal 18F-FDG-PET-study. *Neurobiol Aging* (2007). , 28, 42-50.
- [11] Eckert, T, Barnes, A, Dhawan, V, Frucht, S, Gordon, M. F, Feigin, A. S, et al. FDG PET in the differential diagnosis of parkinsonian disorders. *Neuroimage* (2005). , 26, 912-21.
- [12] Eckert, T, Tang, C, Ma, Y, Brown, N, Lin, T, Frucht, S, et al. Abnormal metabolic networks in atypical parkinsonism. *Mov Disord* (2008).
- [13] Eidelberg, D. Abnormal brain networks in DYT1 dystonia. (1998).
- [14] Eidelberg, D. Metabolic brain networks in neurodegenerative disorders: A functional imaging approach. *Trends Neurosci* (2009). , 32, 548-57.
- [15] Feigin, A, Leenders, K. L, Moeller, J. R, Missimer, J, Kuenig, G, Spetsieris, P, et al. Metabolic network abnormalities in early huntington's disease: An [(18)F]FDG PET study. *J Nucl Med* (2001). , 42, 1591-5.
- [16] Foster, N. L, Heidebrink, J. L, Clark, C. M, Jagust, W. J, Arnold, S. E, Barbas, N. R, et al. FDG-PET improves accuracy in distinguishing frontotemporal dementia and alzheimer's disease. *Brain* (2007). , 130, 2616-35.
- [17] Gilman, S, Wenning, G. K, Low, P. A, Brooks, D. J, Mathias, C. J, Trojanowski, J. Q, et al. Second consensus statement on the diagnosis of multiple system atrophy. *Neurology* (2008). , 71, 670-6.
- [18] Grafton, S. T, Mazziotta, J. C, & Pahl, J. J. St George-Hyslop P, Haines JL, Gusella J, et al. Serial changes of cerebral glucose metabolism and caudate size in persons at risk for huntington's disease. (1992).

- [19] Habeck, C, Foster, N. L, Pernecky, R, Kurz, A, Alexopoulos, P, Koeppe, R. A, et al. Multivariate and univariate neuroimaging biomarkers of alzheimer's disease. *Neuroimage* (2008). , 40, 1503-15.
- [20] Hauw, J. J, Daniel, S. E, Dickson, D, Horoupian, D. S, Jellinger, K, Lantos, P. L, et al. Preliminary NINDS neuropathologic criteria for steele-richardson-olszewski syndrome (progressive supranuclear palsy). *Neurology* (1994). , 44, 2015-9.
- [21] Herholz, K, Salmon, E, Perani, D, Baron, J. C, Holthoff, V, Frolich, L, et al. Discrimination between alzheimer dementia and controls by automated analysis of multicenter FDG PET. *Neuroimage* (2002). , 17, 302-16.
- [22] Hilker, R, Voges, J, Weisenbach, S, Kalbe, E, Burghaus, L, Ghaemi, M, et al. Subthalamic nucleus stimulation restores glucose metabolism in associative and limbic cortices and in cerebellum: Evidence from a FDG-PET study in advanced parkinson's disease. *J Cereb Blood Flow Metab* (2004). , 24, 7-16.
- [23] Huang, C, Eidelberg, D, Habeck, C, Moeller, J, Svensson, L, Tarabula, T, et al. Imaging markers of mild cognitive impairment: Multivariate analysis of CBF SPECT. *Neurobiol Aging* (2007a). , 28, 1062-9.
- [24] Huang, C, Tang, C, Feigin, A, Lesser, M, Ma, Y, Pourfar, M, et al. Changes in network activity with the progression of parkinson's disease. *Brain* (2007b). , 130, 1834-46.
- [25] Jeong, Y, Cho, S. S, Park, J. M, Kang, S. J, Lee, J. S, Kang, E, et al. F-FDG PET findings in frontotemporal dementia: An SPM analysis of 29 patients. *J Nucl Med* (2005). , 46, 233-9.
- [26] Josephs, K. A, Petersen, R. C, Knopman, D. S, Boeve, B. F, Whitwell, J. L, Duffy, J. R, et al. Clinicopathologic analysis of frontotemporal and corticobasal degenerations and PSP. *Neurology* (2006). , 66, 41-8.
- [27] Juh, R, Kim, J, Moon, D, Choe, B, & Suh, T. Different metabolic patterns analysis of parkinsonism on the 18F-FDG PET. *Eur J Radiol* (2004). , 51, 223-33.
- [28] Kalbe, E, Voges, J, Weber, T, Haarer, M, Baudrexel, S, Klein, J. C, et al. Frontal FDG-PET activity correlates with cognitive outcome after STN-DBS in parkinson disease. *Neurology* (2009). , 72, 42-9.
- [29] Lebowitz, E. R, Motlagh, M. G, Katsovich, L, King, R. A, Lombroso, P. J, Grantz, H, et al. Tourette syndrome in youth with and without obsessive compulsive disorder and attention deficit hyperactivity disorder. (2012).
- [30] Ma, Y, Tang, C, Spetsieris, P. G, Dhawan, V, & Eidelberg, D. Abnormal metabolic network activity in parkinson's disease: Test-retest reproducibility. *Journal of cerebral blood flow and metabolism : official journal of the International Society of Cerebral Blood Flow and Metabolism* (2007). , 27, 597-605.
- [31] Mayberg, H. S. Frontal lobe dysfunction in secondary depression. (1994).

- [32] Mckeith, I. G. Consensus guidelines for the clinical and pathologic diagnosis of dementia with lewy bodies (DLB): Report of the consortium on DLB international workshop. *J Alzheimers Dis* (2006). , 9, 417-23.
- [33] Mckhann, G, Drachman, D, Folstein, M, Katzman, R, Price, D, & Stadlan, E. M. Clinical diagnosis of alzheimer's disease: Report of the NINCDS-ADRDA work group under the auspices of department of health and human services task force on alzheimer's disease 35. *Neurology* (1984). , 34, 939-44.
- [34] Minoshima, S, Foster, N. L, Sima, A. A, Frey, K. A, Albin, R. L, & Kuhl, D. E. Alzheimer's disease versus dementia with lewy bodies: Cerebral metabolic distinction with autopsy confirmation. *Ann Neurol* (2001). , 50, 358-65.
- [35] Moeller, J. R, Strother, S. C, Sidtis, J. J, & Rottenberg, D. A. Scaled subprofile model: A statistical approach to the analysis of functional patterns in positron emission tomographic data. *J Cereb Blood Flow Metab* (1987). , 7, 649-58.
- [36] Mure, H, Hirano, S, Tang, C. C, Isaias, I. U, Antonini, A, Ma, Y, et al. Parkinson's disease tremor-related metabolic network: Characterization, progression, and treatment effects. *Neuroimage* (2011). , 54, 1244-53.
- [37] Nagano-saito, A, Washimi, Y, Arahata, Y, Iwai, K, Kawatsu, S, Ito, K, et al. Visual hallucination in parkinson's disease with FDG PET. *Mov Disord* (2004). , 19, 801-6.
- [38] Poston, K. L, Tang, C. C, Eckert, T, Dhawan, V, Frucht, S, Vonsattel, J, et al. Network correlates of disease severity in multiple system atrophy. *Neurology* (2012). , 78, 1237-44.
- [39] Pourfar, M, Feigin, A, Tang, C. C, Carbon-correll, M, Bussa, M, Budman, C, et al. Abnormal metabolic brain networks in tourette syndrome. *Neurology* (2011). , 76, 944-52.
- [40] Reivich, M, Kuhl, D, Wolf, A, Greenberg, J, Phelps, M, Ido, T, et al. The [18F]fluorodeoxyglucose method for the measurement of local cerebral glucose utilization in man. *Circ Res* (1979). , 44, 127-37.
- [41] Scarmeas, N, Habeck, C. G, Zarahn, E, Anderson, K. E, Park, A, Hilton, J, et al. Covariance PET patterns in early alzheimer's disease and subjects with cognitive impairment but no dementia: Utility in group discrimination and correlations with functional performance. *Neuroimage* (2004). , 23, 35-45.
- [42] Spetsieris, P. G, & Eidelberg, D. Scaled subprofile modeling of resting state imaging data in parkinson's disease: Methodological issues. *Neuroimage* (2010).
- [43] Steele, J. C, Richardson, J, & Olszewski, J. Progressive supranuclear palsy: A heterogeneous degeneration involving the brain stem, basal ganglia and cerebellum with vertical gaze and pseudobulbar palsy, nuchal dystonia and dementia. *Archives of Neurology* (1964). , 10, 333-59.

- [44] Tang, C. C, Poston, K. L, Dhawan, V, & Eidelberg, D. Abnormalities in metabolic network activity precede the onset of motor symptoms in parkinson's disease. *J Neurosci* (2010a). , 30, 1049-56.
- [45] Tang, C. C, Poston, K. L, Eckert, T, Feigin, A, Frucht, S, Gudesblatt, M, et al. Differential diagnosis of parkinsonism: A metabolic imaging study using pattern analysis. *Lancet Neurol* (2010b). , 9, 149-58.
- [46] Teune, L. K, Bartels, A. L, De Jong, B. M, Willemsen, A. T, Eshuis, S. A, De Vries, J. J, et al. Typical cerebral metabolic patterns in neurodegenerative brain diseases. *Mov Disord* (2010). , 25, 2395-404.
- [47] Trost, M, Carbon, M, Edwards, C, Ma, Y, Raymond, D, Mentis, M. J, et al. Primary dystonia: Is abnormal functional brain architecture linked to genotype? (2002).
- [48] Wenning, G. K, & Tison, F. Ben Shlomo Y, Daniel SE, Quinn NP. Multiple system atrophy: A review of 203 pathologically proven cases. *Mov Disord* (1997). , 12, 133-47.
- [49] Yong, S. W, Yoon, J. K, An, Y. S, & Lee, P. H. A comparison of cerebral glucose metabolism in parkinson's disease, parkinson's disease dementia and dementia with lewy bodies. *Eur J Neurol* (2007). , 14, 1357-62.