Chapter 17

Reconstruction of Mandibular Defects

Maiolino Thomaz Fonseca Oliveira,
Flaviana Soares Rocha, Jonas Dantas Batista,
Sylvio Luiz Costa de Moraes and
Darceny Zanetta-Barbosa

Additional information is available at the end of the chapter

http://dx.doi.org/10.5772/52104

1. Introduction

Surgical reconstruction of mandibular bone defects is a routine procedure for rehabilitation of patients with deformities caused by trauma, infection or tumor resection. The mandible plays a major role in masticatory and phonetic functions, supporting the teeth and defining the contour of the lower third of the face. Therefore, mandibular discontinuity produces severe cosmetic and functional deformities, including loss of support for suprahyoid muscles and subsequent airway reduction. Reconstruction of these severe defects is mandatory for restoring the patient's quality of life. Surgical techniques have improved considerably in the last decade, but reconstruction of large bone defects of the mandible still pose a great challenge in maxillofacial rehabilitation. Several things can be done to optimize the surgery; the use of prototyping modeling for instance provides a better assessment of the bone defect and pre-contouring of the fixation plates, reducing operating time. The choice of the most suitable titanium plate system is critical to the success of the procedure. Mandibular defects with loss of continuity require more robust (load bearing) systems supporting mandibular function. Many studies consider the use of plates and screws temporary treatment due to the large number of complications such as fracture of plates and screws, plate exposure and infection. Thus, the use of grafts both in the first operation or in a two-stage procedure ensures a more predictable result.

Bone grafts are widely used in reconstructive surgery of the mandible. Incorporation of the bone graft restores continuity, shape, and strength of the jaw to near normal function. Installation of dental implants in the grafted areas is important to restore masticatory function and maintain bone graft volume. Autogenous bone is the best choice for major reconstructions due to lack of rejection, and the presence of viable osteogenic cells that increase bone

INTECH
open science | open minds

© 2013 Oliveira et al.; licensee InTech. This is an open access article distributed under the terms of the Creative Commons Attribution License (http://creativecommons.org/licenses/by/3.0), which permits unrestricted use, distribution, and reproduction in any medium, provided the original work is properly cited.

formation and incorporation at the graft site. The use of a vascularized graft is a good choice because it increases the success of the treatment. However, this technique is not available in all medical centers. Autogenous free bone (non-vascularized) is still the most used graft, even in major reconstructions [1]. The high vascularity of the soft tissues in the oral cavity has allowed the use of free bone graft in the repair of oral cavity defects; but larger grafts increase the risk of bone resorption or failure of graft take. Hyperbaric oxygen therapy is currently being used to optimize bone healing. This procedure increases bone cellular activity and capillary ingrowth, inducing new bone formation and accelerating bone healing. The aim of this chapter is to present our experience with a series of patients with extensive mandibular defects where the use of autogenous free bone grafts along with hyperbaric oxygen therapy as an important adjuvant was beneficial to the outcome.This chapter also presents other alternatives for mandibular reconstruction.

2. Defect evaluation

In mandibular reconstruction, the restoration of bone continuity is not the only criteria for success. The ultimate goals constituting success is attaining near normal morphology and appropriate relation to the opposing jaw, adequate bone height and width, good facial contour and support for overlying soft tissue structures and restoration of jaw of function.

Bony reconstruction planning begins with evaluation of the patient's anatomy in order to define the full extent of the existing defect (both bone and soft tissues) and select the best reconstruction technique for each particular case. The size of the defect will define the magnitude of the reconstruction [2,3]. Some defects may not need to be restored to original size and shape. Loss of a significant portion of a mandibular ramus, for example, may be adequately managed by providing continuity from the condyle to the body of the mandible without restoring the coronoid process.

The quantity and quality of the soft tissues are both important when choosing the reconstructive method. The complete closure of the soft tissue without tension is essential for success. If the tissue is inadequate in quantity, the use of horizontal incisions in the periosteum must be used to guarantee tissue flexibility when needed. This ensures good (tension-free) repair, minimizes postoperative discomfort and reduces dehiscence (one of the most commonly observed complications after grafting in the oral cavity).

On the other hand, if the quantity of soft tissue is adequate but the quality is poor, the reconstruction will be compromised or limited. Tissue with extensive scarring provides a poor host bed for any grafting procedure. When considering the use of non-vascularized bone grafts, the ideal soft and hard tissue bed should have enough bulk, vascularity, and cellularity in order to permit bone graft incorporation. In several cases, tissue loss, scar contracture, and previous irradiation will hamper secondary reconstruction. In this setting, the use of hyperbaric oxygenation should always be considered, because it promotes vascularization and angiogenesis.

Preoperative radiographic evaluation of patients undergoing reconstructive bone surgery aims to evaluate the nature and extent of the lesion and provide the surgeon with anatomic mapping of important structures. Also, follow-up examinations to confirm healing and to

discover complications at an early stage are paramount. The selection of the most appropriate imaging method in each case must take into account the diagnostic capability and cost-effectiveness. Radiographic analysis, computed tomography with three-dimensional (3D) images and magnetic resonance can provide important information. With the development of rapid prototyping methods, such as stereolithography, fused deposition modeling and selective laser sintering, 3D reconstruction based on biomodels have become indispensible tools both for mandibular resection and bony reconstruction.

The use of 3D biomodels, may help delineate the osteotomy area, improving the accuracy of marginal resection. Pre-modeling of reconstruction plates according to the mandibular anatomy is also facilitated. At the time of the secondary reconstruction, the individual plate gives the surgeon a clear direction where the bone should be ideally placed. Another important possibility with these models is the reproduction of the anatomy of the resected area based on mirror imaging of the contralateral side of the mandible. This procedure guides the surgeon as to where to cut the bone graft in the donor area and enhance visualization of the points to be remodeled in the graft prior to fixation to reproduce the new mandible.

3. Reconstruction plates

Mandibular reconstruction plates and screws (2.4 System) are the most widely used devices for mandibular reconstruction; however 2.0 plates can be used in selected cases. With the conventional fixation technique, the tightening of the screws presses the plate against the bone (load sharing). This pressure generates friction, which may contribute to resorption of the grafted bone. However, with the locking systems (load bearing), additional threads within the screw head allows the plate to be anchored to the intraosseous screw instead of being compressed onto the bone. This reduces interference to the bone blood supply underlying the plate, prevents bone pressure necrosis and decreases the potential for plate failure at the screw-bone interface. These plates and screws provide an excellent rigid frame construction with high mechanical stability which is extremely useful in bone grafting (Figures 1-6).

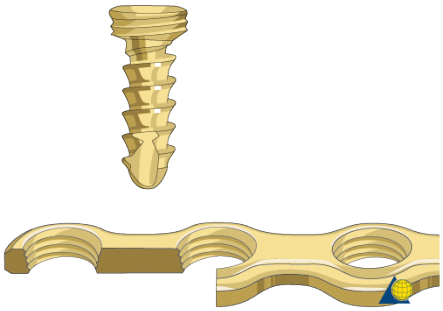

Figure 1. The locking plate has a corresponding threaded plate hole. Copyright by AO Foundation, Switzerland. Source: AO Surgery Reference, www.aosurgery.org.

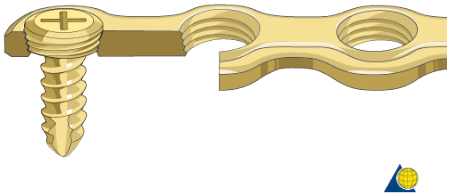

Figure 2. During insertion the locking head screw engages and locks into the threaded plate hole. Copyright by AO Foundation, Switzerland. Source: AO Surgery Reference, www.aosurgery.org.

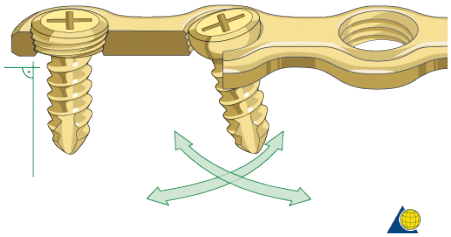

Figure 3. If necessary the threaded plate hole also accepts nonlocking screws, which permit greater angulation. Copyright by AO Foundation, Switzerland. Source: AO Surgery Reference, www.aosurgery.org.

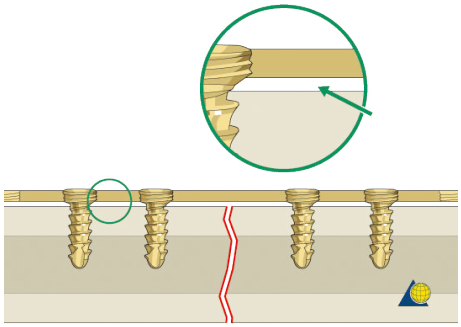

Figure 4. With the locking head screws engaged in the plate, the plate is not pressed onto the bone. This reduces interference to the blood supply to the bone underlying the plate. Copyright by AO Foundation, Switzerland. Source: AO Surgery Reference, www.aosurgery.org.

Reconstruction plates are usually shaped before the mandibular resection and applied afterwards. By bending these plates and placing drill holes in the proximal and distal mandible segments before complete mandibular resection, the surgeon can more confidently maintain the proper occlusion and relationships of the remaining mandibular segments after removal of the involved bone. Even in edentulous cases, this planning maintains a more natural con-

tour and good joint function. With the currently available low-profile locking reconstruction plates, the contoured plate can closely approximate the natural mandibular projection without sacrificing durability and strength, even when used in conjunction with bone grafts. If, however, there is involvement of the buccal cortex of the mandible, direct plate contouring to the bone is not always possible. In these cases, removal of the buccal part of the lesion to allow plate positioning before complete resection is a possible option with satisfactory results. Post-resection freehand plate contouring and fixation is another possibility, however it is difficult, presumes the need of inter-maxillary fixation (IMF) and often yields suboptimal symmetry.

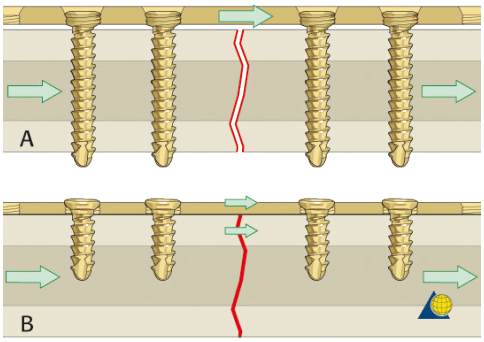

Figure 5. Loading forces are transmitted directly from the bone to the screws, then onto the plate, across the gap and again through the screws into the bone. Friction between plate and bone is not necessary for stability. The plate and screws provide adequate rigidity and do not depend on the underlying bone (load bearing osteosynthesis) when using a locking reconstruction plate 2.4. Copyright by AO Foundation, Switzerland. Source: AO Surgery Reference, www.aosurgery.org.

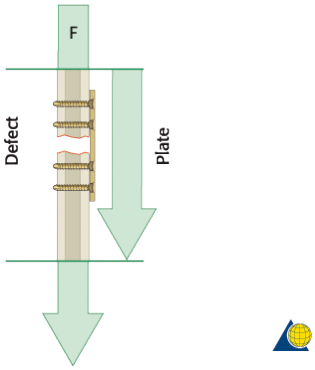

Figure 6. In load-bearing fixation the plate assumes 100% of the functional loads. Copyright by AO Foundation, Switzerland. Source: AO Surgery Reference, www.aosurgery.org.

It is important to understand the appropriate possibilities for bone graft fixation. In our experience, adequate internal fixation using reconstruction locking plates and, subsequently, free autogenous bone grafts seem to be most satisfactory.

4. Free bone grafting

During harvesting, tissue connections between the bone graft and surrounding tissues are transected. In the recipient site, the bone must be revitalized mainly via tissue ingrowth, although it is known that many cells within free bone grafts are able to survive after transplantation. The revitalization goes along with a process of initial remodeling and bone resorption, which is associated with bone volume loss. The amount of resorption depends on many factors, such as the quality of the bone (cortical, cancellous), bone graft fixation to surrounding bone, biomechanical properties (functional loading), the dimensions of the bone graft (it takes longer to revitalize large bone grafts, and therefore, usually they show greater percentage of bone loss) and tissue qualities at the recipient site (vascularization). The amount of bone formed is directly proportional to the number of viable osteogenic cells transferred. The next phase involves revascularization, remodeling, and reorganization of the previously formed bone by osteoblasts and osteoclasts.

Non-vascularized autogenous bone grafts can be harvested from the patient's calvarium, rib, ilium, tibia or fibula [4]. They can be successfully used for reconstruction of small to medium size mandibular defects with favorable prognosis. However, in large mandibular defects, bone reconstruction is still challenging.

Cancellous bone grafts, consisting of medullary bone and bone marrow, contain the highest percentage of viable cells. These grafts become rapidly vascularized due to their particulate structure and large surface area. In contrast, cortical grafts consisting of lamellar bone, provides more resistance to the graft. Cortico-cancellous bone grafts contain both cortical and underlying cancellous bone providing both viable cells and necessary strength for bridging discontinuous defects. The combination of particulate cortical bone and cancellous marrow provides the best potential for osteogenesis.

Bone harvesting should always be performed with sharp instruments under abundant irrigation, and the surgical time must be as short as possible to minimize tissue necrosis and preserve cell viability [5]. The same principles are required during the bone adaptation in the recipient site. The lack of adaptation of the bone block onto the recipient site and the presence of gaps can generate fibrous tissue interposition, which can be avoided with filling the gap with particulate autogenous bone, platelet rich plasma (PRP) or biomaterials.

The recipient site preparation should facilitate the subsequent adaptation of the graft and also expose the bone marrow, favoring revascularization, since the vessels from the periosteum were compromised when it was displaced. The cortical bone in the recipient site can be perforated or even removed with drills to enable contact of the marrow spaces of the graft [6].

Graft fixation is essential to allow its revascularization and incorporation. Movement of the bone block during the healing period results in fibrous tissue between the graft and the recipient site or graft resorption [5,6]. The fixation screws can be used in a passive or compressive manner, however, in the latter case, excessive compression must always be avoided. In cases of mandibular reconstruction decortication is extremely important before the placement of the grafts to support revascularization and facilitate the graft adaptation.

5. Hyperbaric oxygen therapy

The hyperbaric oxygen (HBO) is a therapeutic modality performed within devices called pressurized containers, in which the patient breathes pure oxygen at a high pressure. The HBO promotes an increase in the amount of dissolved oxygen in the blood due to increased pressure inside the chamber, aiding tissue oxygenation [7] (Figure 7).

Figure 7. Patient in an HBO chamber during a hyperbaric oxygen therapy session.

For years, conventional medicine thought of HBO only as a treatment for decompression sickness and air embolism. However, the use of HBO is becoming increasingly common in general practice. HBO has already been used in the treatment of carbon monoxide poisoning, cerebral arterial gas syndrome, decompression sickness, osteoradionecrosis and clostridial gas gangrene. It is also beneficial to improve the healing of a variety of compromised or hypoxic wounds including diabetic ulcers, radiation-induced tissue damage, gangrene, and necrotizing anaerobic bacterial infections [8].

Complications of HBO can be due to either O_2 toxicity or barotrauma. O_2 toxicity is due to formation of superoxide, OH- and H_2O_2. Signs and symptoms of O_2 toxicity mainly involve respiratory system and central nervous system with symptoms like anxiety, nausea, vomiting, seizures, vertigo and decreased level of consciousness. Patients also show respiratory discomfort ranging from dry cough and substernal pain to pulmonary edema and fibrosis [7].

HBO is contraindicated in a patient with pneumothorax due to increased risk of gas embolism. It is also contraindicated in epileptics, hyperthermia and acidosis due to increased risk of seizures. Chronic obstructive pulmonary disease, malignant tumors, pregnancy, claustrophobia, hereditary spherocytosis and optic neuritis are other relative contraindications for the use of HBO therapy [9].

Following maxillofacial trauma there is a vascular disruption which leads to the formation of a hypoxic zone. While hypoxia is necessary to stimulate angiogenesis and revascularization, extended hypoxia will blunt the healing process. HBO may be used to aid in the healing of these compromised wounds by increasing oxygen diffusion from the capillaries to tissues [10]. The available oxygen also has bacteriostatic and bactericidal activites, enhances the phagocytic capacity of white blood cells and promotes differentiation of fibroblasts by interfering with the synthesis of collagen. Important biological events such as angiogenesis and osteogenesis are also stimulated by HBO [11], improving tissue repair and increasing the overall success of reconstruction procedures.

The stimulation of osteogenesis by HBO has been reported in animal experiments and clinical cases. In 1996, Sawai et al. conducted a study to evaluate the effect of hyperbaric oxygen therapy on autogenous free bone grafts transplanted from iliac crest to the mandibles of rabbits and the results indicate that HBO accelerates the union of autogenous free bone grafts [12]. Other studies also demonstrated that HBO elevates alkaline phosphatase activity, a marker of bone formation, in rats following mandibular osteotomy [13], increased osteoblastic activity and angiogenesis in irradiated mandibles undergoing distraction [14] and increased vascular endothelial growth factor expression during bone healing [15].

5.1. A hyperbaric oxygen protocol in mandibular reconstructions

The following treatment steps are included in these sessions: 10 minutes of ventilation to fill the chamber with 100% oxygen, 10 to 15 minutes of diving (0.06 to 0.12 kgf/cm^2 in 1 minute), the patients are exposed to 2.4 ATA (Atmosphere Absolute) pressure for 90 minutes, 10 minutes of re-surfacing and 10 minutes of air ventilation. HBO is given every day and the treatment starts 10 days before bony reconstruction and continues for another 40 days after the surgical procedure.

http://dx.doi.org/10.5772/52104

6. Clinical cases

Figure 8. Patient with ossifying fibroma in the right side of the mandible. Extra and intra oral appearance.

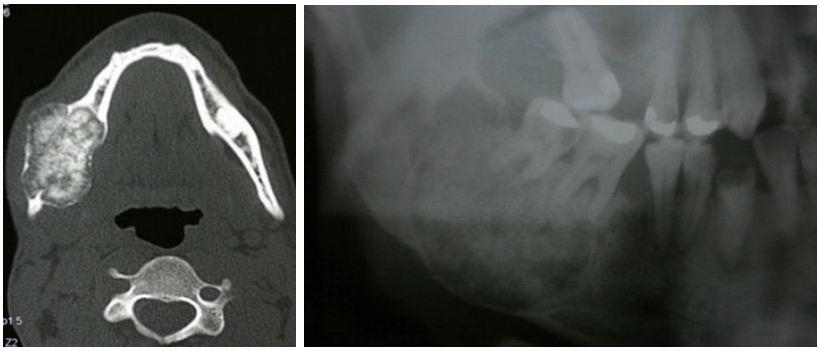

Figure 9. Computed Tomography and panoramic images revealing the lesion area.

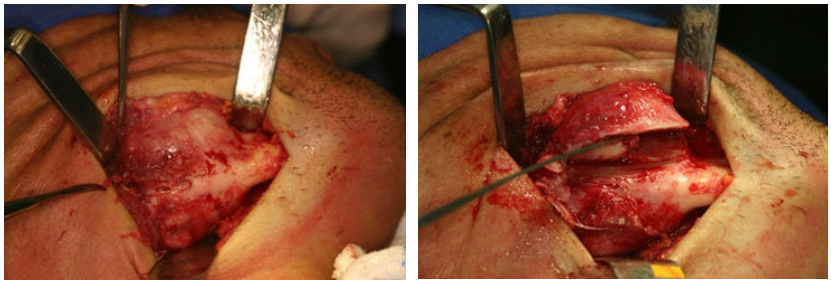

Figure 10. Part of the lesion was removed to permit reconstruction plate modeling maintaining mandibular contour.

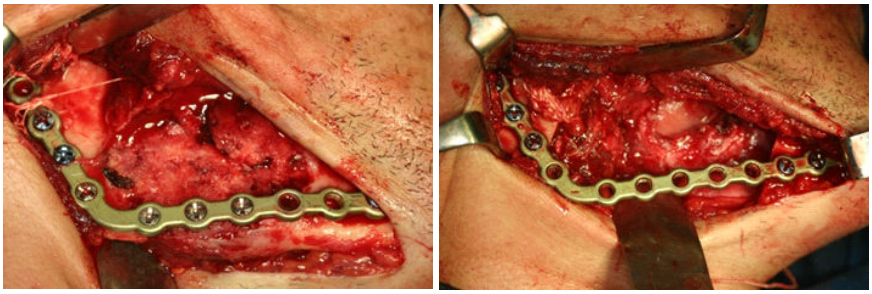

Figure 11. Reconstruction plate installation prior and after complete removal of the lesion. This preserves dental occlusion and condylar position.

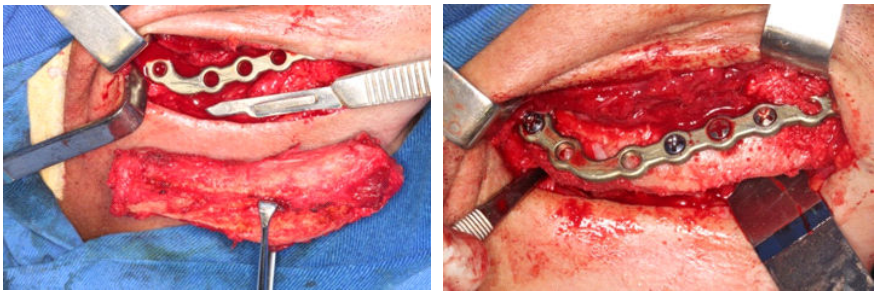

Figure 12. Mandibular reconstruction with free iliac bone 6 months after resection.

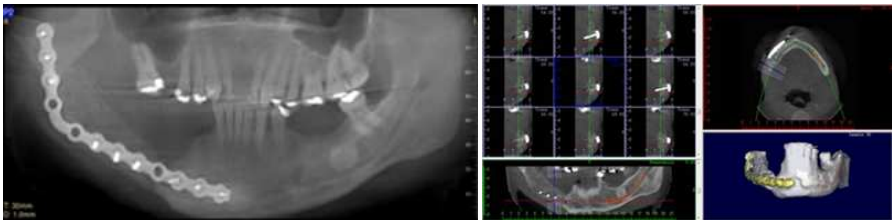

Figure 13. Computed Tomography images 8 months after bony reconstruction revealing the maintenance of bone graft volume. The next step is implant installation for final oral rehabilitation.

Figure 14. Extra-oral image 8 months after bony reconstruction showing preserved mandibular contour and facial symmetry.

6.1. Clinical case

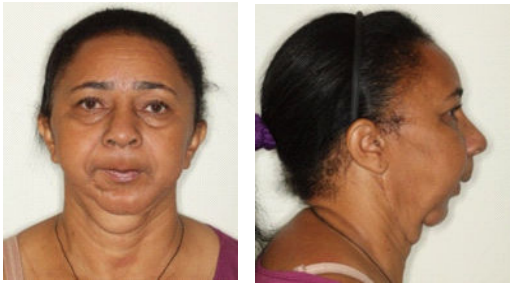

Figure 15. Patient sought treatment for mandibular reconstruction 5 years after undergoing surgery for removal of an ossifying fibroma. There was a significant impairment of the symmetry of the face and backward positioning of the soft tissues of the lower face ("Andy Gump" deformity).

Figure 16. Intraoral image showing the soft tissue condition. There was difficulty in mouth opening.

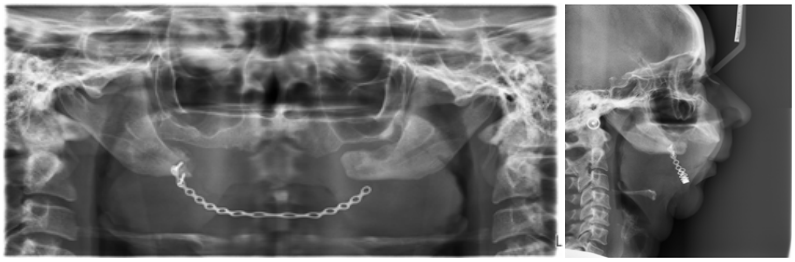

Figure 17. Radiographic images revealing failure of the fixation system and major deficiency in lower face position.

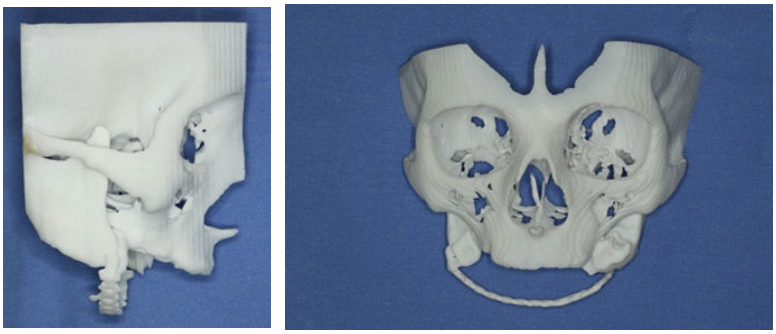

Figure 18. biomodels constructed to better understand the case and assist planning mandibular reconstruction.

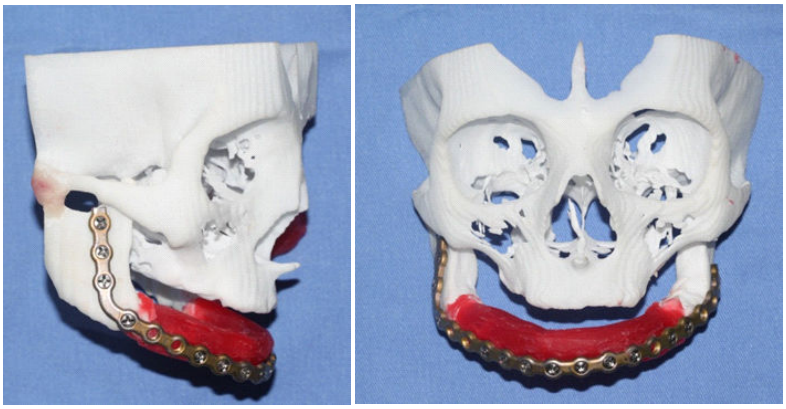

Figure 19. The 2.4 reconstruction plate was previously modeled to facilitate the surgery procedure and reduce operation time.

http://dx.doi.org/10.5772/52104

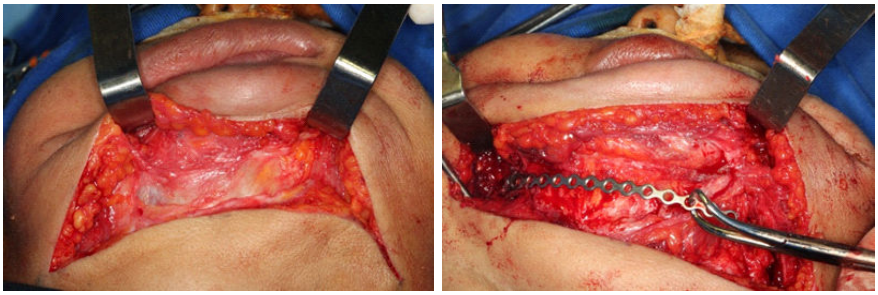

Figure 20. After the surgical approach, the 2.0 miniplate was removed and the bone segments located.

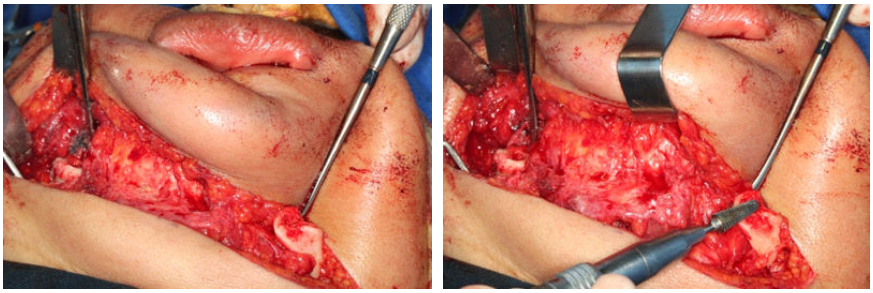

Figure 21. Refreshing the bone margins is important to enhance bone graft take.

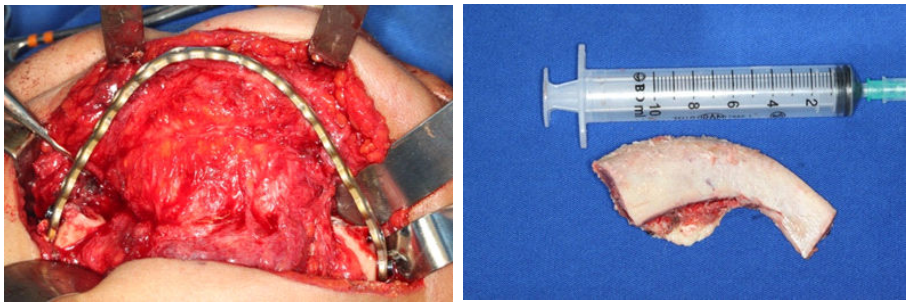

Figure 22. The locking plate was installed and the iliac crest bone was removed.

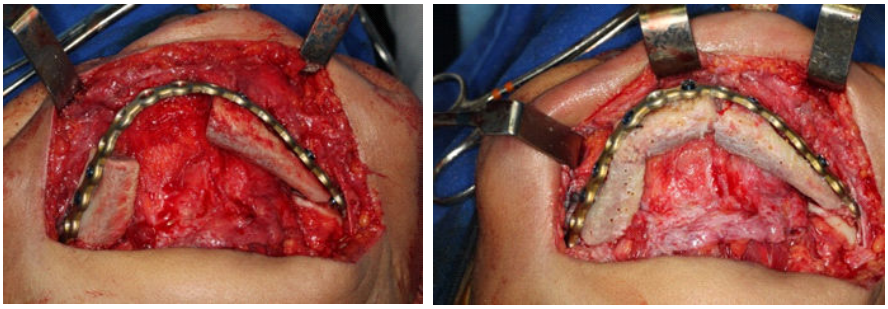

Figure 23. Positioned and fixed bone blocks. In this case the locking plate supports the full load.

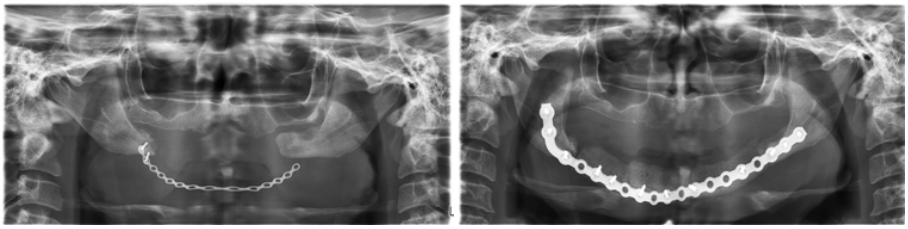

Figure 24. Pre and post-operative images of mandibular reconstruction.

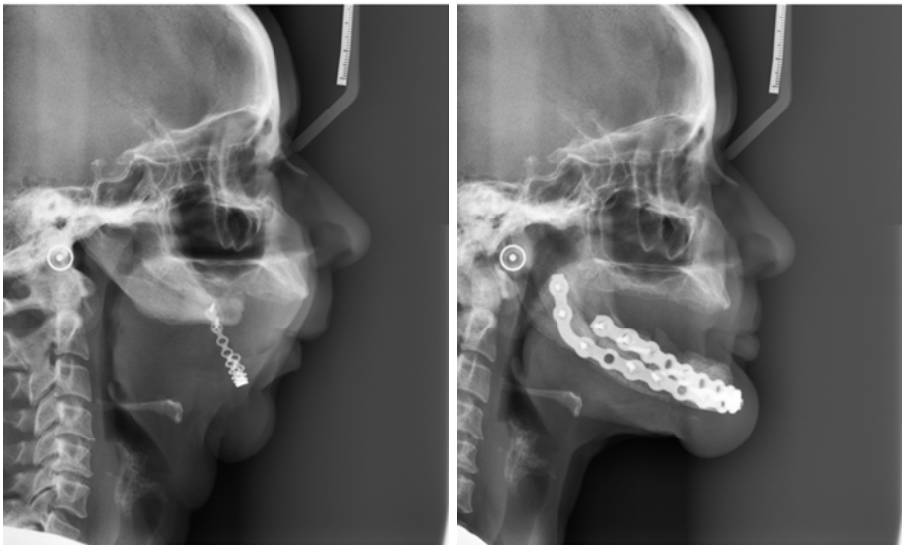

Figure 25. Pre and post-operative profile imagesof mandibular reconstruction.

Figure 26. Postoperative appearance after mandibular reconstruction with preserved contour of the mandible and face.

7. Clinical case

Figure 27. The patient was diagnosed with ameloblastoma in the left mandibular body. The panoramic radiograph shows an extensive multilocular lesion and resorption of tooth roots.

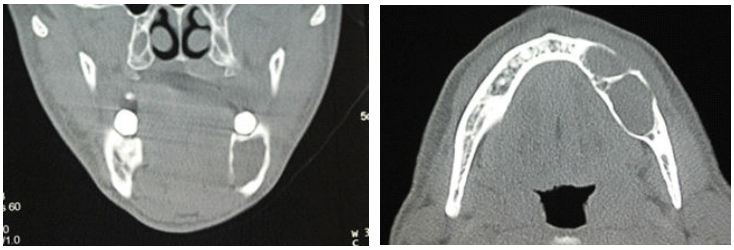

Figure 28. Computed Tomography images are important to define the extent of the affected area.

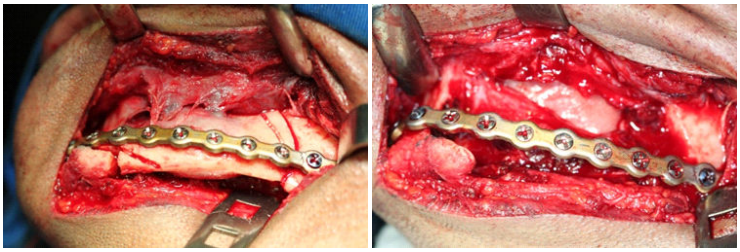

Figure 29. Installation of the 2.4 reconstruction plate before and after complete remove the lesion. These preserves dental occlusion and condylar position.

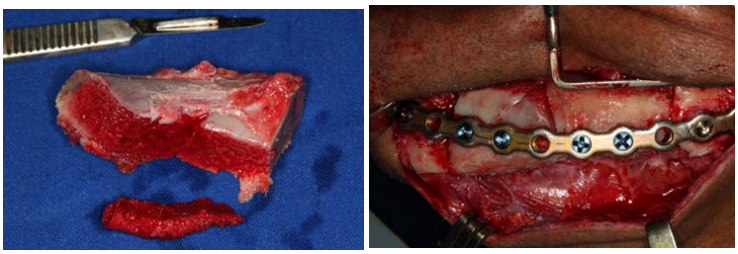

Figure 30. Mandibular reconstruction with iliac free bone 9 months after the resection.

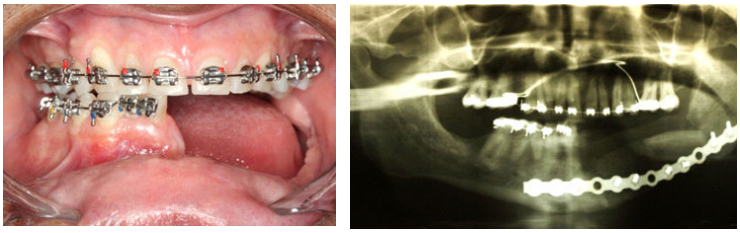

Figure 31. Intraoral examination evidenced good quality of soft tissue.Orthodontic brackets are installed to prevent extrusion of the upper teeth.Panoramic image 6 months after mandibular bony reconstruction demonstrating bone volume maintenance.

http://dx.doi.org/10.5772/52104

Figure 32. Postoperative appearance after mandibular reconstruction with preserved contour of the mandible and face.

7.1. Clinical case

Figure 33. The patient was diagnosed with ameloblastoma in left mandibular body. The panoramic radiograph shows an extensive multilocular lesion and resorption of tooth roots.

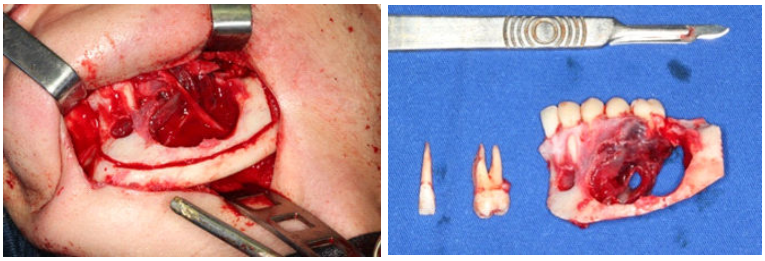

Figure 34. Marginal mandibular resection preserving the mandible basis.

Figure 35. Installation of the 2.4 locking reconstruction plate. The presence of plate protects the jaw of a possible fracture.

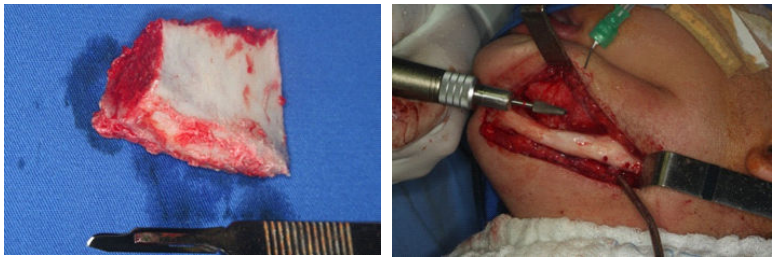

Figure 36. Mandibular bony reconstruction 8 months after resection. The receptor site of the graft should be prepared by removing part of the bone cortex. This favors the incorporation of the graft.

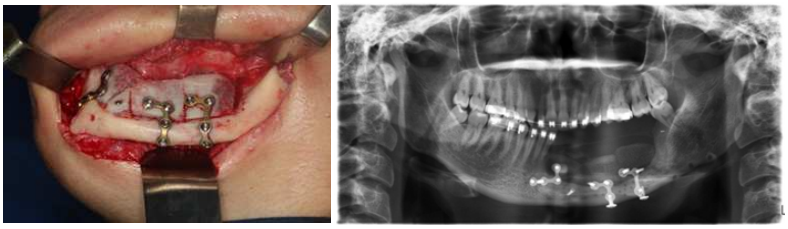

Figure 37. In this case, the reconstruction plate was removed and the bone blocks were fixed using 2.0 miniplates. The use of miniplates provided a better fit and positioning of the blocks.

Figure 38. Postoperative appearance after mandibular reconstruction with preserved contour of the mandible and face. Intraoral examination evidenced good quality of soft tissue. Orthodontic brackets are installed to prevent extrusion of the upper teeth.

Author details

Maiolino Thomaz Fonseca Oliveira[1], Flaviana Soares Rocha[1], Jonas Dantas Batista[1], Sylvio Luiz Costa de Moraes[2] and Darceny Zanetta-Barbosa[1]

1 Department of Oral and Maxillofacial Surgery and Implantology – School of Dentistry - Federal University of Uberlândia – UFU, Brazil

2 Head, Clinic for Cranio-Maxillofacial Surgery at Hospital São Francisco. Director of Facial Reconstruction Center – RECONFACE. Faculty AO-Foundation

References

[1] Pogrel MA, Podlesh S, Anthony JP, Alexander J. A comparison of vascularised and nonvascularized bone grafts for reconstruction of mandibular continuity defects. J Oral Maxillofac Surg. 1997 Nov;55(11):1200-6.

[2] Bernstein S, Cooke J, Fotek P, Wang HL. Vertical bone augmentation: where are we now? Implant Dent. 2006 Sep;15(3):219-28. Review.

[3] McAllister BS, Haghighat K. Bone augmentation techniques. J Periodontol. 2007 Mar; 78(3):377-96.

[4] Weibull L, Widmark G, Ivanoff CJ, Borg E, Rasmusson L. Morbidity after chin bone harvesting--a retrospective long-term follow-up study. Clin Implant Dent Relat Res. 2009 Jun;11(2):149-57. Epub 2008 Jul 24.

[5] Cypher TJ, Grossman JP. Biological principles of bone graft healing. J Foot Ankle Surg. 1996 Sep-Oct;35(5):413-7.

[6] Buser D, Dula K, Hirt HP, Schenk RK. Lateral ridge augmentation using autografts and barrier membranes: a clinical study with 40 partially edentulous patients. J Oral Maxillofac Surg. 1996 Apr;54(4):420-32; discussion 432-3.

[7] Brazilian Society of Hyperbaric Medicine (SBMH), 2010.

[8] DESOLA J, CRESPO A, GARCIA A et al: Indicaciones y Contraindicaciones de la Oxigenoterapia Hiperbarica. Nº 1260, 5- 11 de Junho de JANO/Medicina, 1998;LIV.

[9] Fernandes TD. [Hyperbaric medicine]. Acta Med Port. 2009 Jul-Aug;22(4):323-34. Epub 2009 Aug 10. Review. Portuguese.

[10] Feldmeier JJ. Hyperbaric oxygen for delayed radiation injuries. Undersea Hyperb Med. 2004 Spring; 31(1):133-45.

[11] Jacobson AS, Buchbinder D, Hu K, Urken ML. Paradigm shifts in the management of osteoradionecrosis of the mandible. Oral Oncol. 2010 Nov;46(11):795-801. Epub 2010 Sep 16. Review.

[12] Sawai T, Niimi A, Takahashi H, Ueda M. Histologic study of the effect of hyperbaric oxygen therapy on autogenous free bone grafts. J Oral Maxillofac Surg. 1996 Aug; 54(8):975-81.

[13] Nilsson LP. Effects of hyperbaric oxygen treatment on bone healing. An experimental study in the rat mandible and the rabbit tibia. Swed Dent J 1989;64(1):1-33.

[14] Muhonen A, Haaparanta M, Gronroos T, Bergman J, Knuuti J, Hinkka S, et al. Osteoblastic activity and neoangiogenesis in distracted bone of irradiated rabbit mandible with or without hyperbaric oxygen treatment. Int J Oral Maxillofacial Surg 2004;33(2):173-8.

[15] Fok TC, Jan A, Peel SA, Evans AW, Clokie CM, Sándor GK. Hyperbaric oxygen results in increased vascular endothelial growth factor (VEGF) protein expression in rabbit calvarial critical-sized defects. Oral Surg Oral Med Oral Pathol Oral Radiol Endod. 2008 Apr;105(4):417-22.