
Post-Therapeutic Follow-Up and Early Detection of Recurrence in Hepatocellular Carcinoma

Simona Ioanițescu, L. Micu, Mariana Mihăilă and
R. Badea

Additional information is available at the end of the chapter

<http://dx.doi.org/10.5772/55778>

1. Introduction

Hepatocellular carcinoma (HCC) represents the fifth cause of death due to cancer in the world. Approximately half a million new cases are recorded globally each year [1,2].

The most important risk factors include chronic infection with hepatitis B or hepatitis C viruses, alcoholic liver disease and nonalcoholic fatty liver disease. Less frequent causes of HCC are haemochromatosis, Wilson's disease and autoimmune hepatitis.

The early diagnosis of HCC relies on careful follow-up of patients with increased risk of developing the disease, in accordance with the AASLD and EASL-EORTC guidelines from 2010 and 2012, respectively.

Current treatment of HCC is based on the updated Barcelona algorithm [3]. According to this algorithm, therapeutic options for HCC are divided into curative treatments (resection, liver transplantation and radiofrequency/percutaneous ethanol injection) for HCC in very early stage or early stage (A), transarterial chemoembolization (TACE) for intermediate stage (B) HCC, sorafenib for advanced stage (C) HCC and best supportive care for terminal stage (D) HCC. The following therapies should be applied depending on the stage of HCC:

- stage 0 (PST 0, Child-Pugh A) represents very early stage (0) HCC, with a single tumor < 2 cm or carcinoma *in situ*. When portal pressure/bilirubin are normal, resection is indicated. In case portal pressure/bilirubin are increased, liver transplantation is the therapy of choice in the absence of important comorbidities, or RFA in case of associated diseases.
- Stage A-C (PST 0-2, Child-Pugh A-B) is classified into early stage (A) (single or 3 nodules ≤ 3 cm, PS 0), intermediate stage (B) (multinodular, PS 0) and advanced stage (C) (Portal

invasion, N1, M1, PS 1-2). For early stage (A) HCC, in case of a single nodule the same algorithm applies as for very early stage (0) HCC; in case of 3 nodules ≤ 3 cm, liver transplantation or RFA should be performed, depending on the absence or presence of associated diseases. For intermediate stage (B) HCC transarterial chemoembolization (TACE) is advised, while for advanced stage (C) HCC sorafenib is indicated.

- Stage D (PST > 2, Child-Pugh C) represents terminal stage (D) and only benefits from best supportive care [3].
- Currently, the 5-year survival rate after surgical resection and transplant is of 70-80%, and of 70% after local ablative procedures [4-7].

The post-therapeutic follow-up and early detection of recurrences represent an important problem in the management of patients with HCC.

2. Definition of therapeutic response to therapy and methods for its evaluation

HCC presents several therapeutic peculiarities that must be taken into account when monitoring therapy. Studies have shown that HCC is associated in over 90% of cases with chronic liver disease of viral etiology [8]. In approximately 80% of cases the tumor develops in a previously cirrhotic liver, characterized by disruption of the lobular architecture of the liver and nodular reorganization of the hepatic parenchyma [9]. Malignant transformation is more frequent in cirrhotic livers, with a frequency of 80-90% being noted in autopsy-based studies [10, 11], while 59-94% of newly diagnosed nodules in cirrhosis are histologically proven to be malignant [11-13].

Carcinogenesis is a multistep and multicentric process, the evolution from regenerative nodule to dysplastic nodule to HCC taking place in different phases of the progression of liver cirrhosis; therefore it is possible to simultaneously present regenerative nodules, nodules with different degrees of dysplasia and even early-stage HCC, alongside a nodule or nodules already diagnosed as HCC. Changes in the intranodular vascularization lie at the heart of carcinogenesis, consisting in a chaotic and explosive development of arterial neovascularization with a gradual decrease to disappearance of portal vascularization [14]. Changes in intratumoral vascularization are specific to HCC and allow for its imaging-based diagnosis [15].

Treatment of HCC is complex, and according to the staging of the tumor, therapies can be radical or palliative, local, loco-regional or systemic.

Different criteria for evaluating efficiency of HCC therapy have been investigated over the years.

The first criteria used for monitoring oncological therapies were those based only on measurement of tumor dimensions, namely unidimensional – RECIST criteria (Response Evaluation Criteria in Solid Tumours), modified RECIST 1.1, and bidimensional – WHO (World Health

Organization) criteria. However it was later shown that the degree of necrosis induced by therapy does not necessarily correlate with tumoral dimensions, and measurement of only tumor diameters is not sufficient for evaluating response to therapy.

In 2001, the European Association for the Study of the Liver (EASL) introduced evaluation of tumoral necrosis induced by therapy as a criterion for assessing response to therapy, by using contrast-enhanced dynamic imaging techniques.

The American Association for the Study of Liver Diseases (AASLD) later endorsed this criterion and introduced it in the *AASLD practice guideline on the management of HCC*, published in 2005.

In 2008, a group of experts determined a series of additions and changes to the RECIST criteria, useful both in clinical practice and in complex studies of new targeted therapies. These amendments were published in the „AASLD-JNCI (Journal of the National Cancer Institute) guideline“ as the mRECIST (modified RECIST) criteria. These criteria have been endorsed and are currently recommended by the European Association for the Study of the Liver (EASL) and by the European Organization for Research and Treatment of Cancer (EORTC) in the first common guideline, „EASL-EORTC Clinical Practice Guidelines: Management of hepatocellular carcinoma“ published in 2012.

According to these guidelines, post-therapeutic evaluation of patients with cirrhosis and HCC is based exclusively on contrast-enhanced dynamic imaging criteria. The recommended techniques are contrast-enhanced spiral CT scan or contrast-enhanced MRI. Other imaging techniques, such as angiography, contrast-enhanced ultrasound and PET-CT, are appreciated as “controversial” [3]. It is worth mentioning that their role is analyzed especially in positive diagnosis of HCC more than in post-therapeutic monitoring.

CT and MRI have the advantage of being easier to standardize. Ultrasonography, even using second-generation contrast media, remains an operator-dependent method and requires specialists with training and experience in this field.

CT scan allows for performing very thin slices. Standard practice is represented by successive slices with a thickness of 5 mm and a reconstruction interval of 5 mm, therefore making possible identification of lesions with a minimal diameter of 1 cm. The lesions are measured either in the arterial phase or in the portal-venous phase, when we have a maximal contrast from the normal parenchyma and when the margins of the lesion are clearly delineated [16].

The protocol for post-therapeutic monitoring includes a mandatory initial imaging examination less than 4 weeks before the start of treatment considered as a baseline exam. On this occasion the lesions are divided into measurable and non-measurable. Measurable lesions are lesions that can be correctly measured in at least one dimension, which are reproducible and measurable at later examinations, and that are larger than 1 cm. Target lesions are selected from these measurable lesions [16].

The RECIST 1.1 criteria evaluate therapeutic response by measuring the sum of the maximal diameters of the target lesion (in total 5 lesions, maximum 2 per organ), the remaining lesions being considered as non-target. A change compared to the RECIST criteria is the fact that

enlarged lymph nodes are considered to be target, distinct from the hepatic target lesions and are considered pathological if the short axis is ≥ 15 mm. Lymph nodes ≥ 10 - < 15 mm are considered to be non-target, while lymph nodes < 10 mm non-pathological. Evaluation of global response in the RECIST 1.1 criteria include analysis both of target lesions and of non-target lesions [17].

Compared to the RECIST 1.1 criteria, the mRECIST criteria measure the maximum diameter of the viable segment (which captures contrast media) of the tumor. In order to be considered a target lesion, the hyperenhancing area must be measurable (at least 1 cm), clearly delineated and reproducible at later examinations.

It is important to note that infiltrative HCC must be considered as a non-target lesion when its contour is not well delineated and does not allow precise repeated measurements during further examinations. Furthermore, previously treated tumors can be considered as target lesions only if the intralesional hyperenhancing area is measurable, being clearly delineated, if it measures at least 1 cm and is reproducible at further examinations [16].

According to the mRECIST criteria adopted by EASL in the EASL-EORTC Practice Guidelines, the following definitions should be used:

- complete response (CR) for target lesions is defined as "disappearance of any intratumoral arterial enhancement in all target lesions";
- partial response (PR): "at least a 30% decrease in the sum of the diameters of viable (enhancement in the arterial phase) target lesions, taking as reference the baseline sum of the diameters of target lesions";
- stable disease (SD): "any case that does not qualify for either PR or PD";
- progressive disease (PD): "any increase of at least 20% in the sum of diameters of viable (enhancing) target lesions, taking as reference the smallest sum of the diameters of viable target lesions recorded since treatment started" [3].

In case of non-target lesions, the following definitions apply:

- CR represents "disappearance of any intratumoral arterial enhancement in all non-target lesions";
- incomplete response (IR) or SD: "persistence of intratumoral arterial enhancement in one or more non-target lesions";
- PD: "appearance of one or more new lesions and/or unequivocal progression of existing non-target lesions" [3,16]

Moreover, the mRECIST criteria include a series of special recommendations related to portal vein thrombosis, periportal adenopathies, presence of pleural effusions and/or ascites. Thus, malignant thrombosis of the portal vein must be considered as a non-measurable lesion, due to the difficulties in providing an exact measurement and in later repeating the measurements. Periportal reactive lymph nodes are frequently encountered in viral liver disease. They are considered malignant only when the short axis of the lymph nodes measure more than 20 mm.

Ascites and pleural effusions rarely develop as complications in the evolution of HCC due to the fact that peritoneal carcinomatosis is rare, but appear frequently as markers of the worsening of liver cirrhosis. This is the reason for which experts insist, in the new mRECIST criteria, on cytohistological confirmation of the neoplastic nature of pleural effusions and especially of ascites when they appear or progress during treatment, and when the liver lesions do not meet the criteria for progressive disease [16; 18].

Another aspect that is analyzed is represented by defining hepatic lesions appearing during therapy or post-therapy as malignant and thus recording disease progression. The difficulty derives from the heterogenous and nodular aspect of the cirrhotic hepatic parenchyma, in which we can simultaneously encounter regenerative nodules and nodules with different degrees of dysplasia, as well as changes in the vascularization dynamics of these nodules during the process of carcinogenesis. All these details explain the difficulties in diagnosing early-stage HCC. Respecting the diagnostic criteria for HCC endorsed by the EASL and AASLD guidelines, experts have introduced the following recommendations related to disease progression in the mRECIST criteria:

- a newly discovered nodule is considered to be HCC if it measures over 1 cm and presents a vascular pattern typical for HCC;
- a nodule larger than 1 cm and with atypical vascular pattern is considered to be HCC if progression of its dimensions of at least 1 cm is recorded during further measurements;
- assessment of global therapeutic response takes into account target lesions, non-target lesions and development of new lesions. Any newly-discovered lesion with a pattern typical for HCC is considered to be a marker of disease progression regardless of the evolution of the target and non-target lesions. If the lesion has atypical features, it is considered to be unclear and inconclusive for recording disease progression at that time;
- disease progression can be recorded retrospectively if a newly discovered nodule, which did not initially meet the diagnostic criteria for HCC, gains typical vascular aspects during evolution [16].

Monitoring of global therapeutic response and of disease progression has generated over time a series of controversies. The possibility for retrospectively analyzing newly discovered liver masses during disease evolution represents an important element that has been introduced in therapeutic guidelines. This element takes into account the particularities of the natural evolution of the disease.

Another problem underlined by the groups of experts addresses the difficulty of assessing therapeutic response to local and loco-regional therapies, as well as when it would be correct to record disease progression.

EASL-EORTC Clinical Practice Guidelines recommend that "Assessment of response in HCC should be based on the mRECIST criteria (recommendation 2B)", and "Dynamic CT or MRI are recommended tools to assess response one month after resection, loco-regional or systemic therapies (recommendation 1A)" [3].

The mRECIST criteria are useful in case of radiotherapy or systemic therapies, but are not as useful when treatment strictly addresses one mass or a group of masses, while the natural evolution of disease continues in the remaining hepatic parenchyma.

The Liver Cancer Study Group of Japan aimed to determine criteria for distinctly assessing local, loco-regional and systemic therapies - criteria which should be useful and applicable in clinical practice. The recommendations, known as RECICL (Response Evaluation Criteria in Cancer of the Liver), are applicable especially for local and loco-regional therapies (TACE), but also for radiotherapy or systemic therapies, in combination with the WHO and RECIST criteria. These criteria, first published in 1994, were revised and completed in 2004 and 2009.

The main concept of the 2004 RECICL (and the difference from the RECIST and WHO criteria) was the analysis only of the treated mass, excluding the appearance of new lesions from the assessment of the direct therapeutic effect on the previously treated lesion by local or loco-regional therapies. Experts affirm that in case of loco-regional therapies, the appearance of new intrahepatic lesions in another area than that subjected to treatment should not necessarily be considered as progressive disease. However, in global evaluation, the appearance of new lesions is regarded as progressive disease, and new lesions are described separately [19].

The evaluation criteria are mainly imaging based, including both dimensional variations of the tumor and the assessment of the therapeutically induced degree of necrosis. The Japanese experts consider that measurement of tumoral dimensions in two axes (the first being the maximum diameter of the tumor and the second being perpendicular on the first) is more exact than measuring only the maximum diameter of the tumor, as is recommended by the RECIST criteria. A maximum of 5 target lesions are chosen for global evaluation of therapy when more than 5 lesions are present, but CR is defined as "100% tumor-necrotizing effect or 100% tumor size reduction rate" of all hepatic lesions, target or non-target, as opposed to the RECIST criteria, which define CR as "disappearance of all target lesions". In order to evaluate the direct therapeutic effect on the target lesion, each nodule is analyzed separately when multiple intrahepatic nodules are present [19].

The definitions of PR and PD also differ according to the criteria used for assessing response. Thus, RECICL regards PR as "tumor-necrotizing effect or tumor size reduction rate between 50% and < 100%", while the RECIST criteria define PR as "30% or greater reduction of target lesions". PD is defined in the RECICL criteria as "≥ 25% enlargement of the tumor regardless of the necrotizing effect or appearance of a new lesion", as opposed to the RECIST criteria where PD is considered a "≥ 20% increase or appearance of a new lesion" [19].

New lesions are classified by the Japanese authors into:

- intrahepatic solitary lesion (within or outside the treatment area);
- intrahepatic multiple lesions (within or outside the treatment area); or
- vascular invasion (the portal vein, hepatic vein, bile duct)/extrahepatic spread [19].

This classification was adopted in order to allow for a better appreciation of prognosis; thus, prognosis is more reserved when the new lesions are more disseminated.

It is important to note here the imaging aspects of CR, residual tumor and recurrence. The imaging of a complete therapeutic response is represented by the presence of non-enhanced areas on contrast examination which signify complete tumoral necrosis, with a safety rim around the tumor. In order to assess the efficiency of therapy, it is mandatory to compare the diameter of the tumor before therapy with that of the ablation zone. It is worth noting that in order to assess the CR of the treated nodule, the non-enhanced area must surpass or at least be equal to the tumoral dimensions, the two situations being classified separately (figure 1 a and b) [19].

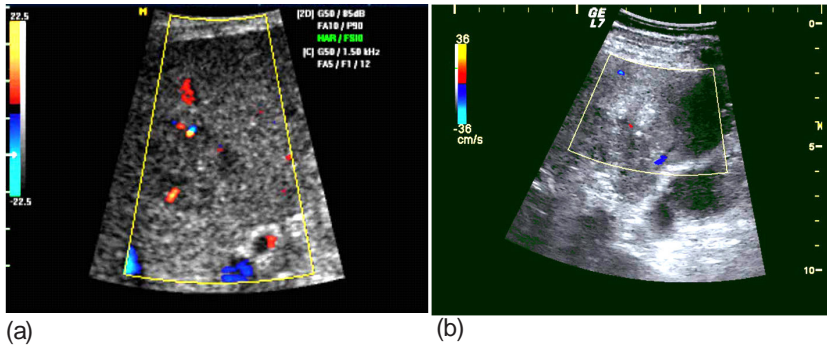


Figure 1. a. HCC before therapy. 2D ultrasound and color Doppler examination. b. Same case, standard ultrasound and color Doppler examination after RFA. We remark that the dimensions of the post-RFA lesion are larger than the dimensions of the initial tumor.

In case of incomplete ablation, diameter of the tumor remains unchanged, and the residual tumoral tissue shows a non-regular outline and poorly delineated internal margins located at the periphery of the tumor. At contrast-enhanced CT or CEUS examinations its behavior is identical to that of the initial tumor (figure 2).

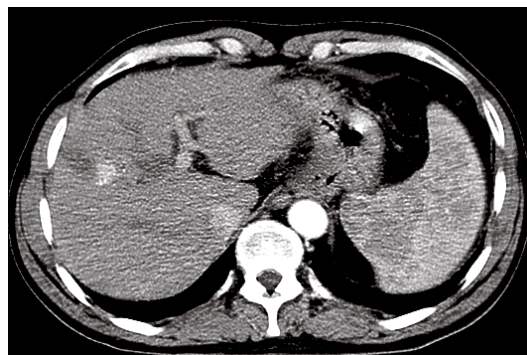


Figure 2. Partial response after RFA. CE-CT image, arterial phase. We remark residual tumoral tissue in the profound portion of the lesion.

Recurrences are defined as reappearance of intralesional areas at the tumor periphery with behaviour similar to HCC (hyperenhancing in the arterial phase and wash-out in the portal and parenchymal phases on contrast exams) at a certain time after the procedure. Especially in cases of HCC treated by percutaneous ethanol injection (PEI), the presence of hyperenhancing septa or vessels inside the tumor have been noted [20]. The increase of tumor size occurs later than changes in intralesional vascularization and serological markers; therefore early diagnosis of recurrences is based mainly on contrast-enhanced dynamic imaging examinations.

A new element also appears in assessing therapeutically-induced tumoral necrosis. It is known that post-TACE intralesional presence of lipiodol prevents contrast-enhanced examination of the nodule, especially the assessment of contrast enhancement of the lesion in the arterial phase. Lipiodol appears intensely hyperechoic at ultrasound examination with important posterior attenuation, which decreases visibility (figure 3).

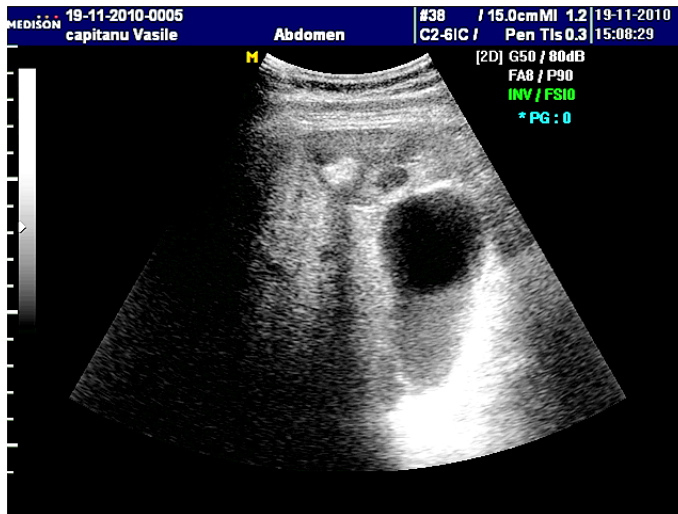


Figure 3. Baseline ultrasound examination 48 hours after TACE. Examination is hampered by the diffuse presence of lipiodol inside the liver. We remark lipiodol concentrated inside the lesion, intensely hyperechoic, with posterior shadow.

At CT examination lipiodol appears intensely hyperechoic inside the lesion, preventing contrast-enhanced examination. Lipiodol may persist months or even years inside the lesion (figure 4a and b). Studies have histologically demonstrated that when lipiodol is present inside the lesion and the dimensions of the tumor do not increase, the tumor is completely necrosed [21]. It is considered that a homogenous and dense presence of lipiodol inside the lesion one month after therapy represents a sign of intratumoral necrosis [19].

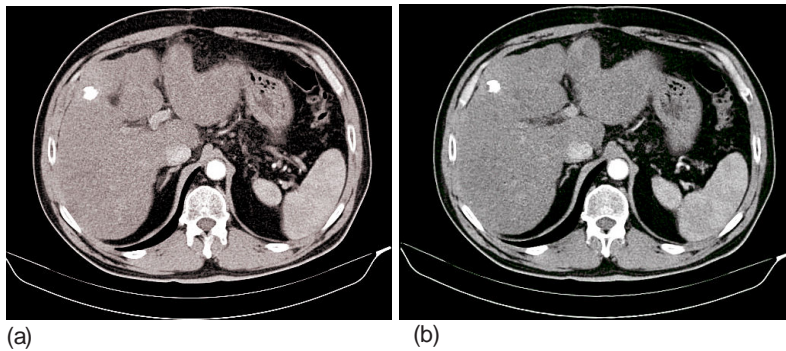


Figure 4. a. Lipiodol present inside the lesion one month after TACE. CT examination. We remark the hyperechoic, homogenous, dense aspect of the lipiodol concentrated inside the lesion. b. The same case, follow-up 3 months after treatment. We remark the persistence of lipiodol inside the lesion and a discrete decrease of tumor dimensions.

According to the recommendations of the Japanese experts, evaluation of the direct effects of treatment on the target mass (treatment effect – TE) requires the following steps [19]:

1. Tumoral necrosis and the reduction rate of the dimensions of the nodule are calculated based on the decrease in the dimensions and disappearance of nodule hypervascularization at contrast-enhanced CT examination. It is important to note that the experts accept the use of other contrast-enhanced imaging techniques such as contrast-enhanced MRI and/or contrast-enhanced ultrasound (CEUS) during follow-up as an alternative to CT scan.
2. The percentage of tumoral necrosis obtained through therapy is calculated.
3. The reduction rate of the tumor dimensions is calculated.
4. When multiple lesions are present, TE is individually determined for each lesion.

The Japanese experts classify TE as:

- TE4 when the tumor-necrotising effect is 100% or the tumor size reduction rate is 100%.
- In case of ethanol injection therapy, microwave coagulation therapy and radiofrequency ablation, TE4 is divided into TE4a (100% necrotized tumor) when the necrotized area is larger than the original nodule and TE4b when the necrotized area has the same size as the original nodule. This situation is also noted as 100% necrotized tumor, but separately classified because the risk of recurrence is higher than in TE4a cases.
- In TACE, the tendency of reduction of tumor size, without tumor enhancement on CE-CT (contrast-enhanced CT) scan, and denser uniform accumulation of lipiodol over time than just after TACE when lipiodol is used, is classified as TE4.
- TE3 defines the cases when tumor-necrotizing effect or tumor size reduction rate is between 50% and < 100%
- TE2 defines effects other than TE3 and TE1, and

- TE1 when the tumor appears enlarged by > 25% regardless of the necrotizing effect [19].

The biological marker for monitoring recurrence after any of the therapeutic procedures was, until recently, only AFP (α -fetoprotein). The specificity of AFP is high when levels are over 200 ng/ml, but with sensitivity not higher than 22% [3].

Several markers have currently been introduced in an attempt to increase the possibility of detecting primary HCC or recurrence after a curative or palliative therapeutic measure as early as possible. Of these markers, it is worth mentioning γ des-carboxi prothrombin (DPC), also known as prothrombin induced by absence of vitamin K (PIVKA). Recent clinical studies that used DPC in the detection of HCC have shown higher sensitivity and specificity compared to AFP [22].

In the global evaluation of the therapeutic effect, the Japanese experts also take into account, in the RECICL criteria, tumoral markers (α -fetoprotein, (AFP, AFP-L3) and PIVKA-II (protein induced by vitamin K absence or antagonist) or DCP (des-gamma-carboxy-prothrombin). The importance of these markers is not necessarily given by their serum levels, but more by their variations under the influence of therapy. Thus, experts consider that the lowest concentration obtained 3 months after therapy is considered to be the reference value for global evaluation of therapy, with any other increase in serum concentrations of these markers being considered an alarm signal highlighting the risk of recurrence. It is noteworthy that the *EASL-EORTC Clinical Practice Guidelines: Management of hepatocellular carcinoma* state that "accurate tumor biomarkers for early detection need to be developed" and that „Data available with tested biomarkers (i.e. AFP, AFP-L3 and DCP) show that these tests are suboptimal for routine clinical practice (evidence 2D; recommendation 2B)", while "Use of changes in serum levels of biomarkers for the assessment of response (i.e. AFP levels) is under investigation" [3].

Another debated problem is the optimal moment for evaluating the effects of therapy. In case of evaluating local therapies (PEI, RFA or microwave coagulation therapy), effects may be assessed immediately after therapy. In case of loco-regional therapies (transcatheter arterial chemoembolization with or without lipiodol or transcatheter arterial embolization), the optimal moment for assessing therapeutic effects is considered to be after at least one month. The Japanese experts consider that global therapeutic response is at a maximum within 3 months after treatment, while in case of radiotherapy optimal evaluation is at 6 months after therapy. They recommend the use of RECIST and WHO criteria for evaluating systemic therapy and radiotherapy, including molecular targeted agents, in combination with the RECICL criteria [19].

Regarding post-therapeutic follow-up for detection of recurrence, *EASL-EORTC Clinical Practice Guidelines* recommend the use of a contrast-enhanced imaging examination "every 3 months during the first year, and every 6 months thereafter to complete at least two years. Afterwards, regular ultrasound is recommended every 6 months. Assessment of time to progression is recommended with CT and/or MRI every 6-8 weeks" [3].

According to the *EASL* guidelines, post-therapeutic follow-up by abdominal ultrasound must be performed by qualified individuals every 3-4 months after surgical resection or after local ablative therapies (evidence 3D; recommendation 2B). [23,24]

Contrast-enhanced spiral CT scan remains the imaging technique of choice for monitoring HCC treatment, since it offers an overview of tumoral extension and is not limited by abdominal feature or liver steatosis [25]. The main problem in follow-up by CT scan is represented by the irradiation associated with repeated monitoring procedures and by renal toxicity of iodized contrast media.

MRI examination with gadolinium presents the advantage of the absence of irradiation and of increased sensitivity and specificity in detecting intratumoral vascularization, especially in small tumors [26]. The procedure is not as easily accessible, MRI machines usually being found in tertiary centers of diagnosis and treatment. The problem of contrast-enhanced renal toxicity remains for this technique as well.

2D ultrasound examination has a low efficiency in assessing effects of therapy in HCC because it is not capable of differentiating viable tumoral tissue from post-therapeutic tumoral necrosis. It also has a limited role in detecting new lesions and in assessing the development of potential complications of local or loco-regional treatment immediately or early after the procedure. Similarly, its role in the evaluation of disease progression (portal vein thrombosis) is limited. Doppler ultrasound may sometimes identify intratumoral vascularization, but the absence of Doppler signal does not exclude the presence of viable tumoral tissue. The introduction of contrast-enhanced ultrasound (CEUS) represented an important advance, due to its capability of identifying intralesional microcirculation; CEUS has proven its efficiency in post-therapeutic follow-up as an alternative to contrast-enhanced CT or MRI. CEUS examination presents the advantage of dynamic examination, of lack of irradiation and of the possibility of repeating as often as necessary during follow-up. Second generation contrast media used in Europe are eliminated from the body through respiration, thus avoiding hepatic and renal toxicity. However, CEUS examination presents the same limits as the ultrasound method in general (operator/equipment dependent; limitations imposed by the ultrasound window, as well as post-therapeutic steatosis which appears in oncological patients and hampers profound visibility). For these reasons CEUS will not be able to totally replace the other imaging techniques.

Although in the *EASL-EORTC Clinical Practice Guidelines: Management of hepatocellular carcinoma* the roles of CEUS and angiography are considered controversial, and PET-CT "not accurate" [3], these aspects only refer to early diagnosis of HCC. The indications of CEUS are defined by the European Federation of Societies for Ultrasound in Medicine and Biology (EFSUMB) in the "*Guidelines and good clinical practice recommendations for contrast enhanced ultrasound (CEUS) – update 2008*". The "*Update 2012*" reaches a consensus between World Federations of Ultrasound in Medicine and Biology (WFUMB) and European Federations of Ultrasound in Medicine and Biology (EFSUMB) in cooperation with representatives of other important international ultrasound societies (AFSUMB, AIUM, ASUM, FLAUS and ICUS). The Guidelines focus on its pre-, intra- and post-therapeutic role in ablative therapies for HCC, while follow-up of systemic therapies is currently regarded as an unvalidated indication. This is despite its efficiency being shown in large clinical studies [27,28]. Therefore, CEUS is recommended before treatment in addition to contrast-enhanced CT and/or MRI, but cannot exclude these examinations, which remain the examinations of choice for the diagnosis of HCC.

Another indication for CEUS is in ultrasound guiding of ablative procedures, helping to position the needle inside the tumor when it is incompletely or poorly delineated at standard ultrasound. During the same examination CEUS allows an immediate evaluation of therapeutic response and guidance for immediate retreatment of the residual tumoral areas. The last indication is in evaluating tumoral recurrence when contrast-enhanced CT or MRI are contraindicated or inconclusive, and it is considered that CEUS can be used in protocols for post-therapeutic follow-up in association with CE-CT and CE-MRI, which remain the indications of choice for post-therapeutic follow-up, its diagnostic accuracy being equivalent to that of CE-CT or MRI [29]. Moreover, ultrasound examination 24 hours after the procedure, including CEUS, identifies not only lesion characteristics, but also potential post-interventional complications (for example bleeding).

In case of ablative procedures, CEUS examination shows a central non-enhancing area which presents a peripheral ring of homogenous hyper-enhancement determined by post-procedure inflammation. At 24 hours after the procedure, the peripheral inflammatory ring becomes thinner, the necrotic area appears larger compared to the previous examination, and the eventual residual tumor appears more evident.

The sensitivity of CT and CEUS in assessing therapeutic efficiency is however low in the first days after the procedure, especially due to post-lesional hyperemia; for this reason a contrast-enhanced imaging control is necessary one month after ablation in order to confirm the results of treatment [30]. In case of therapeutic success, further follow-up is performed according to the EASL-EORTC Clinical Practice Guidelines recommendations every 3 months by using a contrast-enhanced imaging technique (figures 5-7).

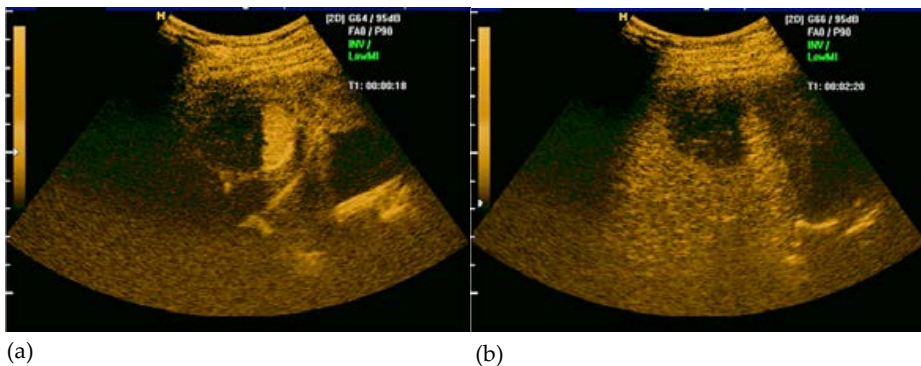


Figure 5. Incomplete RFA, CEUS exam performed 3 months after therapy. Note the hyperenhancing excentric area with irregular internal contour in the arterial phase (left image) and with pronounced wash-out in the portal venous phase (right image).

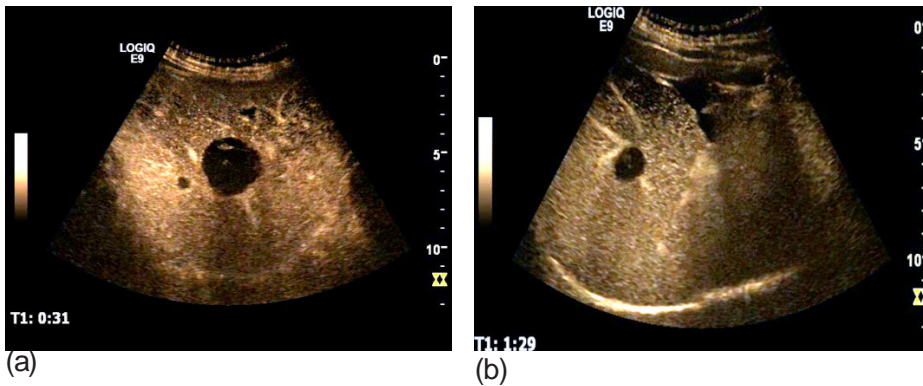


Figure 6. a. The same case, complete response after re-treatment (RFA), CEUS examination. We remark a regular internal contour of the non-enhancing area, without peripheral enhancement of the contrast media. b. The same case, a second nodule, complete response after re-treatment (RFA), CEUS examination.

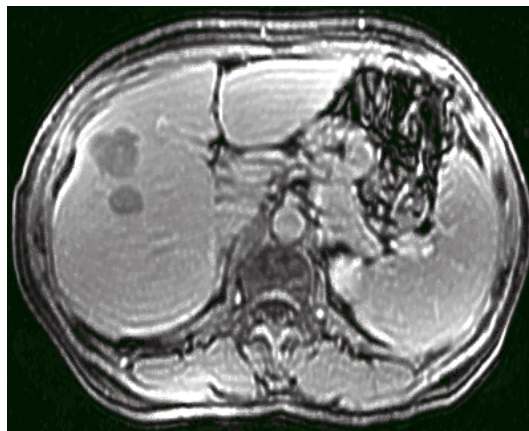


Figure 7. The same case, complete response after re-treatment (RFA) of both nodules. CE-MRI image.

A randomized study showed that recurrence at 2 years after RFA was significantly lower than after percutaneous ethanol injection. However, recurrence after RFA occurs more frequently and earlier when compared with surgical resection. Recurrence is also more frequent in case of percutaneous RFA compared to RFA through open or laparoscopic surgery, and when lesions are larger than 3 cm [31].

Transarterial chemoembolization (TACE) is based on the fact that HCC vascularization is predominantly arterial, while the remaining hepatic parenchyma has a dual nutritive vascularization (predominantly portal). For this reason TACE is effective only in lesions with hyperenhancement in the arterial phase. In cases of TACE procedures with lipiodol, immediate

evaluation, as well as evaluation in the first days post-procedure, are inappropriate using CT and CEUS. Although CE-MRI is not influenced by the presence of lipiodol, it remains a costly and difficult to access method. Lipiodol may persist for months inside the lesion, and this is why assessment of therapeutic efficiency is currently done by indirectly evaluating fixation of lipiodol inside the lesion by CT without contrast media [32]. The EASL-EORTC Clinical Practice Guidelines recommend the same follow-up timing as in ablative procedures (figures 8a and b).

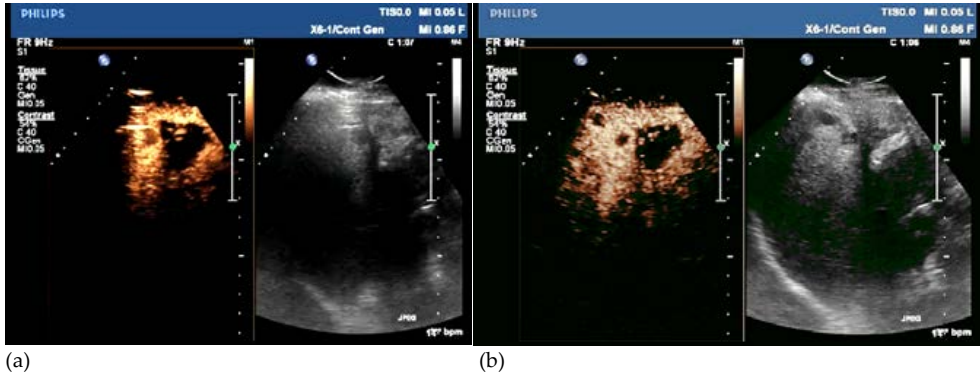

Figure 8. a. Partial response after RFA and TACE. We remark the irregular, internal contour and contrast enhancement at the periphery of the lesion. b. The same case. After loco-regional therapy we also note complete necrosis of two satellite nodules of the initial tumor.

The role of ultrasound assessment is limited in the first days after the procedure and should be used only to assess for complications of the procedure. On the other hand, CEUS may play an important role during follow-up in monitoring dysplastic nodules in order to detect the moment when changes occur in arterial vascularization, facilitating therapeutic intervention as soon as possible [33].

Systemic therapies are indicated in advanced stages of hepatic tumors, when no more efficient therapeutic options remain. In addition to the recommendations for follow-up of the EASL-EORTC Clinical Practice Guidelines, CEUS has provided a significant benefit, being used in ample clinical studies to quantify intratumoral perfusion (figures 9 and 10) [34,35].

Surgical resection represents the treatment of choice for patients with a single hepatic lesion and with well conserved liver function. Recurrence rate is over 70% at 5 years and is mainly due to dissemination of the primary tumor. The appearance of new tumors near the scar of the primary tumor is considered having origin in restant tumoral cells and noted as recurrence. The most important predictors of recurrence are appearance of other tumors near the scar of the primary tumor and vascular microinvasion [36]. The EASL-EORTC Clinical Practice Guidelines recommend the same follow-up timing after resection. No increased benefit using CEUS was noted.

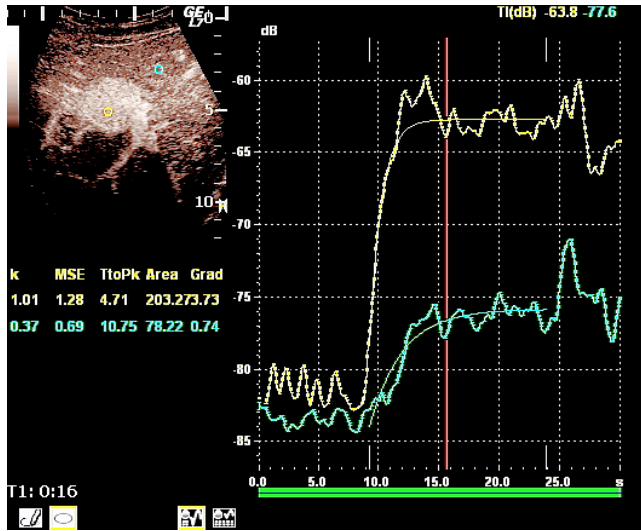


Figure 9. Quantitative analysis (time-intensity curve - TIC) of tumor vascularization before systemic therapy.

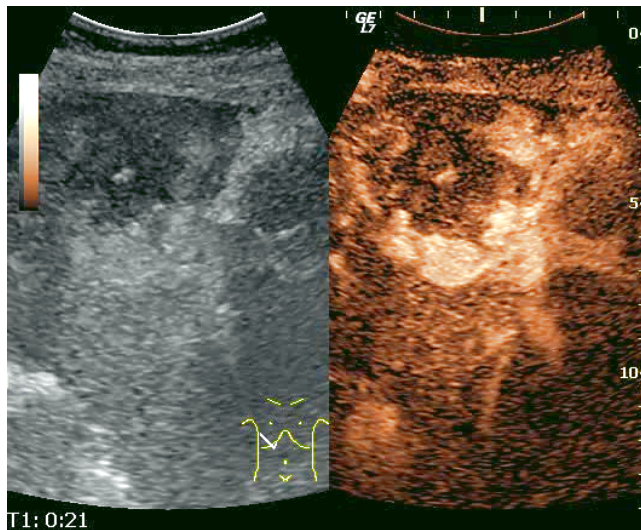


Figure 10. Therapeutic induced necrosis after Sorafenib therapy. CEUS examination, arterial phase.

3. Conclusions

Hepatocellular carcinoma is one of the most frequent malignant tumors, and its incidence is rising. HCC develops in most cases in patients with chronic liver disease, usually of viral etiology,

and malignant transformation is more frequent in the cirrhotic liver. Therefore, strict follow-up of patients with liver cirrhosis is recommended in order to diagnose HCC as early as possible.

Carcinogenesis is a complex, multistep and multicentric process. Changes in the intratumoral vascularization are specific to HCC and allow for its imaging-based diagnosis. Several therapeutic options are available, depending on the stage of the tumor. Thus, surgical resection or local therapies are recommended in early stages, while loco-regional and systemic therapies or radiotherapy are indicated for intermediate and advanced stages.

A very important role is played by post-therapeutic follow-up, which includes complex criteria for assessing both the direct effect of therapy on the tumoral nodule (tumoral necrosis induced by treatment and variations of tumor dimensions) as well as global therapeutic response (appearance of complications of HCC or of liver cirrhosis and development of new tumoral nodules) – the mRECIST and RECICL criteria.

The imaging techniques of choice for the early diagnosis of recurrences are represented by contrast-enhanced CT and contrast-enhanced MRI. CEUS represents a viable alternative for post-therapeutic follow-up, because it has a diagnostic accuracy similar to that of the other two techniques and has the advantages of lack of irradiation and lack of hepatic and renal toxicity; however CEUS cannot replace the two other techniques. CEUS is recommended to be used in post-therapeutic follow-up together with CE-CT and CE-MRI.

Although the role of serum tumoral markers in the diagnosis of HCC is considered to be “suboptimal” while their variations during evolution are “under investigation”, they are still used in current clinical practice, especially for post-therapeutic follow-up.

Author details

Simona Ioanițescu¹, L. Micu¹, Mariana Mihăilă¹ and R. Badea²

1 Center of Internal Medicine, Fundeni Clinical Institute, Bucharest, Romania

2 Ultrasound Dept., Institute of Gastroenterology and Hepatology, Univ. of Medicine & Pharmacy “Iuliu Hațieganu” Cluj-Napoca, Romania

References

- [1] Ferlay J, Bray F, Pisani P, Parkin DM. GLOBOCAN 2000: cancer incidence, mortality and prevalence worldwide, version 1.0. International Agency for Research on Cancer CancerBase no. 5. Lyon, France: IARC Press, 2001.
- [2] Surveillance, Epidemiology, and End Results (SEER) Program. SEER*Stat database: incidence – SEER 9 Regs research data, Nov 2009 Sub (1973-2007). Bethesda, MD: National Cancer Institute, April 2010.

- [3] European Association for the Study of the Liver and European Organisation for Research and Treatment of Cancer. EASL-EORTC Clinical Practice Guidelines: management of hepatocellular carcinoma," *Journal of Hepatology*, vol 56, pp. 908-943, 2012.
- [4] Takayama T, Makuuchi M, Hirohashi S, Sakamoto M, Yamamoto J, Shimada K, et al. Early hepatocellular carcinoma as an entity with a high rate of surgical cure. *Hepatology* 1998;28:1241–1246.
- [5] Roayaie S, Blume IN, Thung SN, Guido M, Fiel MI, Hiotis S, et al. A system of classifying microvascular invasion to predict outcome after resection in patients with hepatocellular carcinoma. *Gastroenterology* 2009;137:850–855.
- [6] Roayaie S, Llovet JM, Obeidat K, Labow D, Sposito C, Pellegrinelli A, et al. Hepatic resection for hepatocellular carcinoma < 2 cm in diameter. *Hepatology*, in press.
- [7] Livraghi T, Meloi F, Di Stasi M, Rolle E, Solbiati L, Tinelli C, et al. Sustained complete response and complications rates after radiofrequency ablation of very early hepatocellular carcinoma in cirrhosis: is resection still the treatment of choice? *Hepatology* 2008;47:82–89.
- [8] Shiratoli Y, Shiina S, Imamura M, et al: Characteristic difference of hepatocellular carcinoma between hepatitis B- and C-viral infection in Japan. *Hepatology* 1995;22:1027–1033.
- [9] Llovet JM, Burroughs A, Bruix J. Hepatocellular carcinoma. *Lancet* 2003;362:1907–1917.
- [10] Fattovich G, Stroffolini T, Zagni I, Donato F. Hepatocellular carcinoma in cirrhosis: incidence and risk factors. *Gastroenterology* 2004; 127: S35-S50
- [11] Andreana L, Isgrò G, Pleguezuelo M, Germani G, Burroughs A. Surveillance and diagnosis of hepatocellular carcinoma in patients with cirrhosis. *World J Hepatol* 2009 October 31; 1(1): 48-61
- [12] Burrel M, Llovet JM, Ayuso C, Iglesias C, Sala M, Miquel R, Caralt T, Ayuso JR, Sole M, Sanchez M, Bru C, Bruix J. MRI angiography is superior to helical CT for detection of HCC prior to liver transplantation: an explant correlation. *Hepatology* 2003;38:1034-1042
- [13] Caturelli E, Bartolucci F, Biasini E, Vigliotti ML, Andriulli A, Siena DA, Attino V, Bisceglia M. Diagnosis of liver nodules observed in chronic liver disease patients during ultrasound screening for early detection of hepatocellular carcinoma. *Am J Gastroenterol* 2002; 97: 397-405
- [14] Matsui O. Imaging of multistep human hepatocarcinogenesis by CT during intra-arterial contrast injection. *Intervirology* 2004;47:271-276.
- [15] Lencioni R, Piscaglia F, Bolondi L. Contrast-enhanced ultrasound in the diagnosis of hepatocellular carcinoma. *Journal of Hepatology* (2008);48:848–857

- [16] Lencioni R, Llovet J.M. Modified RECIST (mRECIST) Assessment for Hepatocellular Carcinoma. *Semin Liver Dis* 2010;30:52-60
- [17] Eisenhauer E.A, Therasse P, Bogaerts J, Schwartz L.H, Sargent D, Ford R, Dancey J, Arbuck S, Gwyther S, Mooney M, Rubinstein L, Shankar L, Dodd L, Kaplan R, Lacombe D, Verweij J. New response evaluation criteria in solid tumours: Revised RECIST guideline (version 1.1). *EJC* (2009); 45:228–247. doi:10.1016/j.ejca.2008.10.026
- [18] D’Amico G, Garcia-Tsao G, Pagliaro L. Natural history and prognostic indicators of survival in cirrhosis: a systematic review of 118 studies. *J Hepatol* 2006;44(1):217–231
- [19] Kudo M, Kubo S, Takayasu K, Sakamoto M, Tanaka M, Ikai I, Furuse J, Nakamura K, Makuuchi M. Response evaluation criteria in cancer of the liver (RECICL) proposed by the Liver Cancer Study Group of Japan (2009 Revised Version). *Hepatology Research* 2010;40:686-692 DOI: 10.1111/j.1872-034x.2010.00674.x
- [20] Sparchez Z; Radu P; Zaharia T; Kacso G; Grigorescu I; Botis G; Badea R. Usefulness of contrast enhanced ultrasound guidance in percutaneous biopsies of liver tumors. *JGLD* 2011;20(2):191 - 196.
- [21] Takayasu K, Arii S, Matsuo N et al. Comparison of CT findings with resected specimens after chemoembolization with iodized oil for hepatocellular carcinoma. *Am J Roentgenol* 2000; 175: 699–704.
- [22] Carr B.I, Wang Z, Wei G. Differential effects of vitamin K1 on AFP and DPC levels in patients with unresectable HCC and HCC cell lines. *Digestive Disease and Sciences* 2011;56(6):1876-1883.
- [23] Bruix J, Sherman M, Llovet JM, Beaugrand M, Lencioni R, Burroughs AK, et al. EASL Panel of Experts on HCC. Clinical management of hepatocellular carcinoma. Conclusions of the Barcelona-2000 EASL conference. European Association for the Study of the Liver. *J Hepatol* 2001;35:421–430.
- [24] National Cancer Institute. PDQ_ levels of evidence for adult and pediatric cancer treatment studies. Bethesda, MD: National Cancer Institute. Date last modified 26/August/2010. <<http://cancer.gov/cancertopics/pdq/levelsevidence-adult-treatment/healthprofessional/>>; 2011 [accessed 01.03.11].
- [25] Bartolozzi C, Cioni D, Donati F, Granai G, Lencioni R. Imaging evaluation of tumor response. In: Bartolozzi C, Lencioni R, editors. *Liver malignancies. Diagnostic and interventional radiology*, 1st ed. Berlin: Springer-Verlag, 1999. pp. 467–487.
- [26] Dromain C, de Baere T, Elias D, et al. Hepatic tumors treated with percutaneous radiofrequency ablation: CT and MR imaging follow up. *Radiology* 2002; 223: 255-262.
- [27] Claudon, M, Cosgrove, D, Albrecht, T, Bolondi, L, Bosio, M, Calliada, F, Correas, J-M, Darge, K, Dietrich, C, D’Onofrio, M, Evans, D. H, Filice, C, Greiner, L, Jäger, K, de Jong, N, Leen, E, Lencioni, R, Lindsell, D, Martegani, A, Meairs, S, Nolsøe, C, Piscaglia, F, Ricci, P, Seidel, G, Skjoldbye, B, Solbiati, L, Thorelius, L, Tranquart, F, We-

- skott, H-P, Whittingham, T. Guidelines and Good Clinical Practice Recommendations for Contrast Enhanced Ultrasound (CEUS) - update 2008. *Ultraschall Med* (2008). , 29, 28-44.
- [28] Claudon M, Dietrich CF., Choi BI, Cosgrove DO, Kudo M, Nolsøe CP, Piscaglia F, Wilson SR, Barr RG, Chammass MC, Chaubal NG, Chen M-H, Clevert DA, Correas JM, Ding H, Forsberg F, Fowlkes JB, RN Gibson, Goldberg BB, Lassau N, Leen E. L. S, Mattrey R. F, Moriyasu F, Solbiati L, Weskott H-P, Xu H-X. Guidelines and Good Clinical Practice Recommendations for Contrast Enhanced Ultrasound (CEUS) in the Liver – Update 2012. A WFUMB-EFSUMB initiative in cooperation with representatives of AFSUMB, AIUM, ASUM, FLAUS and ICUS. *Ultraschall in Med* 2012; DOI: 10.1055/s-0032-1325499.
- [29] Frieser M, et al. Efficacy of Contrast-Enhanced US versus CT or MRI for the Therapeutic Control of Percutaneous Radiofrequency Ablation in the Case of Hepatic Malignancies. *Ultraschall in Med*. Published online 2011. ISSN: 0172-4614.
- [30] Nicolau C, Vilana R, Bianchi L, Brú C. Early-stage hepatocellular carcinoma: the high accuracy of real-time contrast-enhanced ultrasonography in the assessment of response to percutaneous treatment. *Eur Radiol* 2007; 17(Suppl 6): F80-88.
- [31] Khan KN, Yattsuhashi H, Yamasaki K, Inouc O, Koga M, et al. Prospective analysis of risk factors for early intrahepatic recurrence of hepatocellular carcinoma following ethanol injection. *J Hepatol*. 2000; 32: 269-278.
- [32] Maruyama H, Yoshikawa M, Yokosuka O. Current role of ultrasound for the management of hepatocellular carcinoma. *World J Gastroenterol* 2008; 14: 1710-1719
- [33] Badea R, Ioanimescu S. Ultrasound Imaging of Liver Tumors – Current Clinical Applications. In: "Liver Tumors". Alexander Julianov (ed.). InTech, Rijeca, Croatia, 2012, pp. 75 – 102. <http://www.intechopen.com/books/liver-tumors/ultrasound-imaging-of-liver-tumors-current-clinical-applications> (accessed 5.09.2012)
- [34] Yoshida K, Hirokawa T, Moriyasu F, Liu L, Liu G-J, Yamada M, Imai Y. Arterial-phase contrast-enhanced ultrasonography for evaluating anti-angiogenesis treatment: A pilot study. *World J Gastroenterol* 2011 February 28; 17(8): 1045-1050. doi: 10.3748/wjg.v17.i8.1045.
- [35] Lassau N, Chami L, Chebil M, Benatsou B, Bidault S, Girard E, Abboud G, Roche A. Dynamic Contrast-Enhanced Ultrasonography (DCE-US) and Anti-angiogenic Treatments. *Discov Med* 11(56):18-24, January 2011.
- [36] Bruix J, Sherman M. Management of hepatocellular carcinoma. *Hepatology* 2005;42: 1208–1236.

