

---

# Oral Manifestations of HIV

---

G.A. Agbelusi, O.M. Eweka, K.A. Òmezudike and M. Okoh

Additional information is available at the end of the chapter

<http://dx.doi.org/10.5772/52941>

---

## 1. Introduction

Human Immunodeficiency Virus (HIV) was first reported in USA. In June and July of 1981, the CDC published two reports on clusters of young homosexual men who developed opportunistic infections that were chiefly detected in several immunodeficient individuals (CDC, 1993).

Acquired Immunodeficiency Syndrome (AIDS) is a complex of symptoms and infections caused by the HIV virus as it impacts the immune system. It is an acquired infection, not hereditary. AIDS since its appearance in 1981 has spread to become a major cause of premature death and so far a cure has not yet been found. The diagnosis of HIV/AIDS requires a positive HIV antibody test or evidence of HIV infection and the appearance of some very specific conditions/diseases (CDC, 1993).

AIDS is a global pandemic, 33.4 million people are currently living with the disease worldwide, and it has killed an estimated 2.4 million people, including 330,000 children (UNAIDS, 2010). Over three-quarters of these deaths occurred in Sub-Saharan Africa, retarding economic growth and destroying human capital. South Africa has the largest population of HIV patients in the world, followed by Nigeria and India (McNeil, 2007).

Oral lesions have been reported to be early clinical features of HIV infection (Greenspan et al., 1992). These lesions are often indicators of immune suppression and can be used for early testing, diagnosis and management of patients with HIV/AIDS. Oral lesions contribute to patients' morbidity, affecting the psychological and economic functioning of the individual and community (Kaminu et al., 2002).

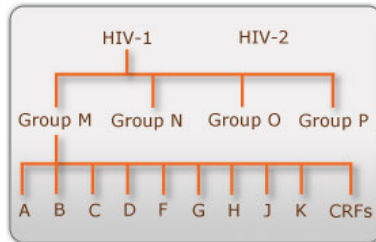
The overall prevalence of oral manifestations of HIV infection has changed since the advent of Highly Active Anti-Retroviral Therapy (HAART). Several Studies have shown reduction in prevalence of herpes labialis and periodontal diseases along with other lesions to more

than 30% after the institution of HAART (Ceballos-Salobrena et al., 1997), and in HIV-associated opportunistic infections (Septowitz, 1998).

## 2. Literature review

HIV has two primary strains: HIV-1 and HIV-2. HIV-1 is found throughout the world. HIV-2 is found primarily in West Africa, where the virus may have been in circulation since the 1960s–1970s (Beaupre et al., 2006).

Both HIV-1 and HIV-2 have several subtypes. The strains of HIV-1 can be classified into four groups: the "major" group M, the "outlier" group O and two new groups, N and P. These four groups may represent four separate introductions of simian immunodeficiency virus into humans. Within group M there are known to be at least nine genetically distinct subtypes (or clades) of HIV-1. These are subtypes A, B, C, D, F, G, H, J and K (Lihana et al., 2009).



**Scheme 1.**

### 2.1. Pathophysiology

Human Immunodeficiency Virus (HIV) mainly affects white blood cells called T-lymphocytes (T-cells) by attaching to a protein on the cell surface called CD4 (Cluster of differentiation 4), it is also expressed on the surface of monocytes, macrophages, and dendritic cells (Miceli, 1993).

HIV gains entry into the body through the blood or mucosal surfaces. The virus establishes itself within the lymphoid tissue, where it replicates and makes itself available to the cells of the immune system (such as T-Lymphocytes, monocytes and macrophages).

The hallmark of HIV disease is the progressive loss of CD4<sup>+</sup> lymphocytes. Without intervention, an average of 60 to 80 cells/mm<sup>3</sup> is lost every year; this loss is highly variable and occurs in periods of stability and rapid decline. The level of metabolic and mitotic activity of the host CD4 cell is believed to be a factor in the rate at which the disease progresses in individual patients.

With progressive CD4 lymphocyte depletion, immunosuppression becomes increasingly more severe with the emergence of pre-AIDS opportunistic infections. Once the CD4 lym-

phocyte count falls below 200 cells per ml and the ratio of helper and suppressor cells is reversed, a diagnosis of AIDS is made.

### **3. Oral manifestations of HIV**

#### **3.1. Significance of oral lesions of HIV**

Oral lesions have been reported to be early clinical features of HIV infection (Greenspan et al., 1992). They are multiple and varied, and are occasionally the first sign that patients harbour the virus. Studies have estimated that more than 90% of persons with HIV infection will have at least one oral manifestation during the course of their disease (Weinert et al., 1996). These lesions may be present in up to 50% of people with HIV infection and in up to 80% of those with a diagnosis of AIDS (Palmer et al., 1996). In cases where a person's HIV status is unknown the lesions provide a strong indication of the presence of HIV infection (Maeve et al., 2005).

Some of these lesions may have a predictive value, warning of a progression from HIV seropositivity to clinically manifest as AIDS. They are often indicators of immune suppression and can be used for early testing, diagnosis and management of patients with HIV/AIDS (Scully et al., 1991; Arendorf et al., 1998; Agbelusi and Wright, 2005). Oral lesions in HIV may serve as markers for immune deterioration and disease progression and may also indicate poor prognosis (Adurogbangba et al., 2004).

They can therefore be used as an entry or end-point in therapy and vaccine trials and can be determinants of opportunistic infection and anti-HIV therapy, staging and classification systems

Oral lesions contribute to patients' morbidity, affecting the psychological and economic functioning of the individual and community (Kaminu et al., 2002). The pain of oral lesions can lead to increased morbidity. In cases like herpes zoster of the trigeminal nerve or facial nerve palsy facial aesthetics may be compromised. Some of the oral lesions have a fatal outcome e.g. Kaposi's sarcoma. Therefore, it is important to perform oral examinations routinely in the dental and medical settings (Patel et al., 2003), in those affected with HIV and patients at risk of the disease (Maeve et al., 2005).

Predisposing factors to expression of oral lesions of AIDS include CD4 counts less than 200 cells/mm<sup>3</sup>, viral load greater than 3000 copies/ml, xerostomia, poor oral hygiene and smoking (Greenspan et al., 2001).

#### **3.2. Epidemiology of oral lesions of HIV**

Several studies done worldwide showed varying reports of oral lesions from 40% to 93% (Mirowski et al., 1998; Ramirez – Amardor et al., 1998; Ranganathan et al., 2000; Matee et al., 2000; Campisi et al., 2002). The prevalence of oral lesions seen in a German study showed 39% (Schmidt- Westhausen et al., 1997), in South Africa, 73% was reported by Kaminu and Naidoo (2002). Nigerian reports also showed a prevalence of 36.4% - 84% in various studies done in

the different geopolitical zones. (Onunu et al., 2002, Anteyi et al., 2003, Wright et al., 2005; Taiwo et al., 2005; Taiwo et al., 2006; Arotiba et al., 2006; Adedigba et al., 2008).

All studies carried out showed presence of oral lesions as a manifestation of HIV/AIDS infection.

### **3.3. Importance of oral lesions of HIV for the dental profession**

The overall growth of the global AIDS epidemic appears to have stabilized, the annual number of new HIV infections has been steadily declining since the late 1990s and there are fewer AIDS-related deaths due to the significant scale up of antiretroviral therapy over the past few years. Although the number of new infections has been falling, levels of new infections overall are still high, and with significant reductions in mortality, the number of people living with HIV (PLWA) worldwide has increased (UNAIDS, 2010). This increase in the number of PLWA translates to the fact that the likelihood of an oral health care worker particularly the dentist treating a PLWA in high incidence areas is almost certain, therefore the dental team needs to be more involved in the prevention of spread and care of infected persons.

It is also important to note that the clinical problem of HIV infection poses one of the greatest challenges to Health Care Workers all over the world.

Some oral lesions of HIV/AIDS are ulcerative and painful, and so compromise the patients' ability to eat and swallow, subsequently leading to malnutrition and emaciation which worsens the already immunocompromized state. Hence prompt and early treatment of lesions is required.

The mode of spread of HIV also poses special danger to HCW particularly the dentist who works in an environment contaminated with blood, saliva and other body fluids and has close contact with his patients.

The dentist may possibly be the first health care provider to diagnose the condition from a high index of suspicion and results of diagnostic investigations prompted by the head/neck and oral manifestations (Agbelusi and Wright, 2005). Dentists should have a good knowledge of oral lesions in HIV/AIDS and be able to recognize and accurately diagnose such lesions. Early treatment of oral lesions is also necessary to reduce morbidity and mortality in HIV-infected patients. The need to maintain oral health to prevent complications like microbial infections which may be fatal in these patients cannot be over-emphasized.

Currently, viral load and CD<sub>4</sub> status determination are used to initiate and monitor a patient's treatment. Diagnostic tests such as these place a greater responsibility on the dental practice team as they need to be aware of drug changes, new drugs and appropriate management of such patients. Some of the antiviral drugs may also have oral lesions as side effects.

### **3.4. Classification of oral lesions of HIV**

Oral mucosal lesions are part of the clinical criteria in a number of HIV/AIDS classification systems currently in use. This classification can be based on the etiological factors or the strength of association. EC-Clearinghouse on Oral Problems Related to HIV Infection and

WHO Collaboration centre on oral manifestations of the Human Immunodeficiency Virus uses strength of association of Oral lesions with HIV infection as basis for classification (ECC/WHO, 1993)

---

GROUP 1: Lesions Strongly Associated with HIV infection:

Candidiasis:

Pseudomembraneous candidiasis

Erythematous candidiasis

Angular cheilitis

Hairy leukoplakia

Kaposi's sarcoma

Non- Hodgkins lymphoma

Periodontal diseases

Linear gingival erythema (LGE)

Necrotizing (ulcerative) gingivitis (NUG)

Necrotizing (ulcerative) Periodontitis (NUP)

GROUP 2: Lesions Less Commonly Associated with HIV Infection

Bacterial infections

Mycobacterium avium intra-cellulare

Mycobacterium tuberculosis

Melanotic hyperpigmentation

Necrotic (ulcerative) stomatitis

Salivary gland diseases

Xerostomia due to decreased salivary flow rate

Unilateral or Bilateral swelling of major salivary glands

Thrombocytopaenic purpura

Ulceration NOS ( Not-otherwise specified)

Viral infections:

Herpes simplex virus

Human papilloma virus (HPV)

Condyloma acuminatum

Focal epithelial hyperplasia

Verruca vulgaris

Varicella zoster

Herpes zoster

---

### 3.5. Clinical characteristics and diagnosis of oral lesions of HIV

#### 3.5.1. Oral candidiasis

This is the most common intra-oral lesion seen among HIV infected individuals. In African studies, the prevalence ranged from 15% to more than 80% in HIV+ adults. The most common organism involved with the presentation of candidiasis is *Candida albicans*. The pres-

ence of oral *Candida* was associated with a *CD4* count of  $<200$  cells/microl, cigarette smoking and heroine/methadone use (Greenspan et al., 2000). The most common organism involved with the presentation of candidiasis is *Candida albicans*, but other non-*albicans* species, such as *C. glabrata*, *C. tropicalis*, *C. krusei* and *C. dubliniensis* can also cause the disease.

There are 3 frequently observed forms of oral candidiasis:

- Pseudomembraneous candidiasis
- Erythematous candidiasis
- Angular Cheilitis

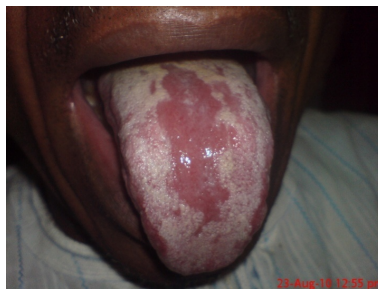#### 3.5.1.1. Pseudomembraneous candidiasis

It appears as creamy white curd-like plaques on the buccal mucosa, tongue and other oral mucosal surfaces (palate, lips etc.) that can be wiped away, leaving a red or bleeding underlying surface. The plaques consist of a mixture of fungal hyphae, desquamated epithelium, and inflammatory cells. These plaques can appear anywhere on the oral and pharyngeal mucosa.

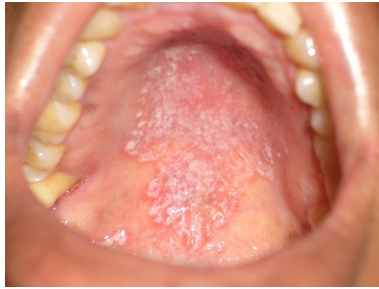**Diagnosis:** In most clinical conditions, the presumptive diagnosis of oral candidiasis is made based on the typical clinical appearance. In this situation, the presumptive diagnosis is strengthened if the patient responds to an empirical trial of anti-fungal therapy.

When the clinical diagnosis of oral candidiasis is not clear, the diagnosis can be confirmed by obtaining a direct smear and performing either a *Potassium Hydroxide* (KOH) wet mount or a *Gram's stain* (Greenspan et al., 1992). The KOH wet mount typically shows presence of yeasts or pseudo-hyphae, and the gram stain shows gram- positive staining organisms that are much larger than bacteria. Obtaining oral fungal cultures is generally reserved for situations when patients do not respond to therapy and anti-fungal resistance is suspected.

The pseudomembraneous variant was associated with severe immune suppression in several studies where these clinical parameters were available (Schoidt et al., 1990; Tukutuku et al., 1990; Hodgson, 1997; Ranganathan et al., 2000). As with other causes of oral candidiasis, recurrences are common if the underlying problem persists.



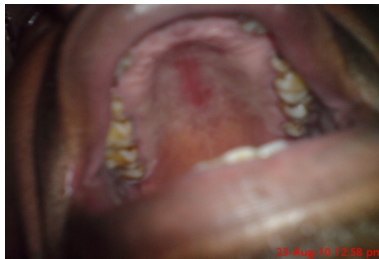**Figure 1.** Pseudomembraneous and erythematous candidiasis on the dorsum of the tongue



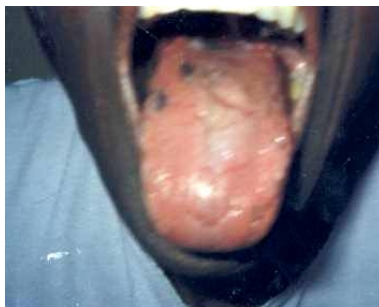**Figure 2.** Pseudomembranous candidiasis on the palate

### 3.5.1.2. *Erythematous candidiasis*

This appears as a red lesion commonly located on the palate, dorsum of the tongue (as areas of depapillation) and buccal mucosa. The lesions tend to be symptomatic with patients complaining of burning mouth and change of taste, most frequently while eating salty or spicy foods or drinking acidic beverages.



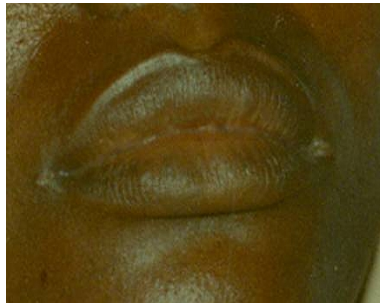**Figure 3.** Erythematous candidiasis on the palate



**Figure 4.** Erythematous candidiasis on the tongue and angular cheilitis on the lips.

### 3.5.1.3. Angular cheilitis

Presents as fissures or linear ulcers at the corners (commissures) of the mouth and often associated with small white plaques, could be unilateral or bilateral. It can occur with or without the presence of erythematous candidiasis or pseudomembranous candidiasis. Angular cheilitis can also exist for an extensive period of time if left untreated.



**Figure 5.** Angular cheilitis

### 3.5.2. Periodontal diseases

Since the first descriptions of the HIV in 1981, a considerable number of researches have focused on the periodontal changes specifically associated with HIV infection. Earlier reports included unusual and severe forms of periodontal disease in HIV-infected individuals, particularly among homosexual males. These lesions ranged from severe gingivitis to advanced, painful periodontitis characterized by spontaneous bleeding, bone exposure and frequently bone sequestration followed by the exfoliation of several teeth (Silverman et al., 1986; Winkler et al., 1988). An increased incidence of acute necrotizing ulcerative gingivitis (ANUG) was also reported in HIV-seropositive patients (Schiodt & Pindborg, 1987; Gornitsky & Pekovie, 1987).

HIV-associated periodontal diseases were initially classified into four broad categories: HIV-associated gingivitis (HIV-G) (Winkler et al., 1988), HIV-associated periodontitis (HIV-P), ANUG and necrotizing stomatitis (NS) (Greenspan et al., 1990). Later classifications proposed that the term 'HIV-associated' be dropped in relation to periodontal disease because the conditions were also seen in non-HIV infected populations (Smith et al., 1993).

HIV-G is now known as linear gingival erythema (LGE), while HIV-P is referred to as necrotizing ulcerative periodontitis (NUP). Currently, the spectrum of periodontal diseases associated with HIV includes linear gingival erythema, necrotizing diseases (NUG and NUP), and exacerbated chronic periodontitis. LGE, necrotizing ulcerative gingivitis (NUG) and NUP are classified under lesions strongly associated with HIV infection ((ECC/WHO, 1993; Armitage, 1999; Winkler et al., 1988). The exacerbated periodontitis described in HIV infected patients is however not clinically distinguishable from that occurring in non-HIV-infected populations (Robinson et al., 2002).



Periodontal diseases associated with HIV infection along with some other oral lesions have important diagnostic values as they may alert the dentist to the presence of HIV infection (ECC/WHO,1993; Robinson et al., 2002). Their prognostic significance is due to their ability to predict a deteriorating immune status and progression from HIV to AIDS (Robinson et al., 1998; Soubry et al., 1995; Glick et al., 1994a; Glick et al., 1994b). Soubry et al (1995) evaluated 224 people with necrotizing periodontal disease. Overall, 81% were found to be HIV positive. When compared with the general population in their environment, the HIV prevalence was only 30% which was much lower.

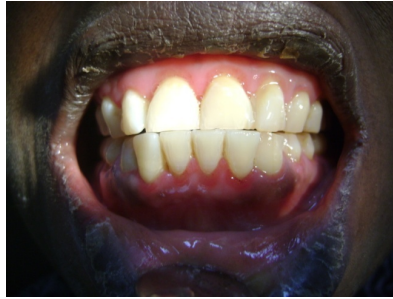### 3.5.2.1. *Linear gingival erythema*

This periodontal lesion presents as a persistent, distinct, intense, fiery red band extending 2-3mm apically from the free gingival margin. The erythema may be limited to the marginal tissue, the attached gingiva in a punctate or diffuse form, or could extend into the alveolar mucosa. These erythematous changes are usually generalized but may be confined to few teeth. Unlike conventional marginal gingivitis, the associated teeth usually have little or no plaque formation (Narani & Epstein, 2001) thus regarded as a non-plaque induced gingivitis, particularly as the degree of erythema is disproportionately intense to the amount of plaque seen (Holmstrup & Westergaard, 1998). The gingiva bleeds easily on tooth brushing or gentle probing or even spontaneously in some cases (Robinson et al., 2002). No ulceration is however present. LGE is commonly first seen earlier in the course of HIV infection and may or may not serve as a precursor to necrotizing ulcerative periodontitis (Glick & Holmstrup, 2000).

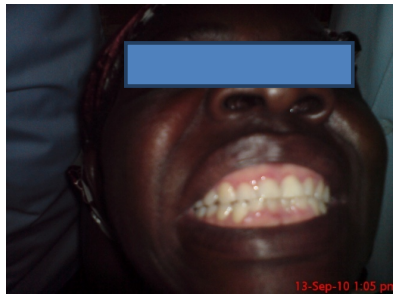
Studies have revealed a microbiota comprising *Candida albicans*, *Porphyromonas gingivalis*, *Prevotella intermedia*, *Actinobacillus actinomycetemcomitans*, *Fusobacterium nucleatum* and *Campylobacter rectus* (Murray et al., 1989; Murray et al., 1991). This microflora is consistent with that of conventional periodontitis. The *Candida* species isolated from some LGE lesions, suggests its possible aetiologic role (Lamster et al., 1994; Velegraiki et al., 1999; Grbic et al., 1995). LGE has been classified under 'Gingival diseases of fungal origin', a separate periodontal disease entity at the 1999 International workshop for a Classification of Periodontal diseases and conditions (Armitage, 1999).

The use of tobacco has been reported to affect the extent of gingival banding which is measured by the number of affected sites (Swango et al., 1991). The relationship of LGE to severe immune suppression is variable. This condition may (Ceballos et al., 1996; Holmes et al., 2002) or may not be associated with CD4 counts < 200 cells/mm<sup>3</sup> (Grbic et al., 1995; Davoodi et al., 2010).

A major clinical hallmark of LGE is its non-responsiveness to conventional scaling and root planing. The differential diagnosis is conventional chronic gingivitis, a plaque-induced gingival condition which responds to conventional periodontal therapy.



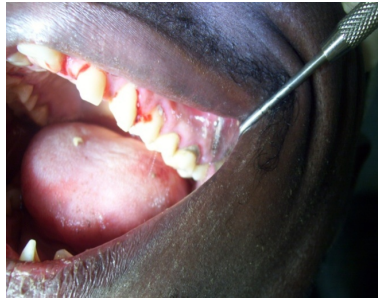**Figure 6.** Linear gingival erythema



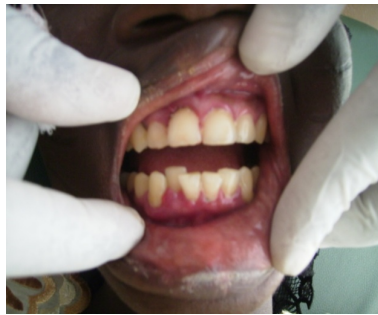**Figure 7.** Linear gingival erythema in an anaemic patient

### 3.5.2.2. *Necrotizing ulcerative gingivitis*

Necrotizing ulcerative gingivitis (NUG) is defined using the presumptive diagnostic criterion (ECC/WHO, 1993) as the destruction of one or more interdental papillae. In the acute stage of the disease, ulceration, necrosis and sloughing may be accompanied by hemorrhage and a characteristic fetor. The affected gingiva may be extremely painful or asymptomatic (Robinson et al., 1998). The anterior and lower teeth are often affected (Robinson et al., 1998). The gingival ulceration may be limited to single tooth or extend to several areas of the jaws. The clinical description of NUG is only limited to lesions involving the gingiva without any loss of periodontal attachment. NUG in HIV-associated lesions represents the same spectrum of acute necrotizing ulcerative gingivitis (ANUG) seen in patients without HIV infection but in HIV-infected individuals it progresses more rapidly (Winkler and Murray, 1987). Some of the organisms isolated from NUG lesions include *Borrelia*, gram-positive cocci,  $\beta$ -hemolytic streptococci and *Candida albicans* (Reichart et al., 1987). NUG has been associated with depleted CD4 lymphocyte counts in some studies (Ceballos et al., 1996). However, others have failed to establish this association (Barr et al., 1992).



**Figure 8.** Necrotizing ulcerative gingivitis

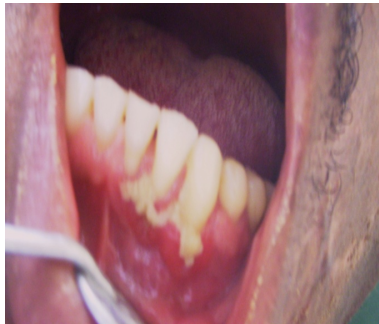

**Figure 9.** Necrotizing ulcerative gingivitis

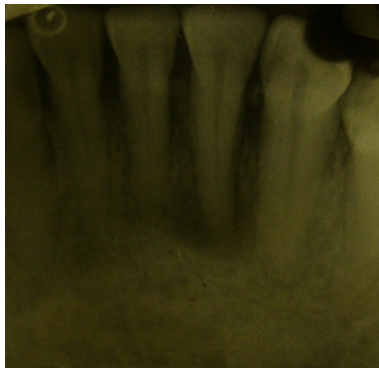
### 3.5.2.3. *Necrotizing ulcerative periodontitis*

Necrotizing ulcerative periodontitis (NUP) may be an extension of NUG in HIV infected individuals. It is characterized by soft tissue loss resulting from ulceration or necrosis with rapid destruction of the periodontal attachment and interproximal bone (EC-WHO 93, Winkler & Robertson, 1992). Initially, the lesion manifests with severe, deep-seated jaw pain, interproximal necrosis and cratering. This severe pain is however not a consistent feature (Robinson et al., 1998; Masouredis et al., 1992). The bone may then be exposed, with subsequent necrosis and sequestration, resulting in loosening of the teeth (Umezudike et al., 2011a). There is thus radiographic evidence of bone loss. Few teeth are affected in most cases in either the premolar or molar region, but the lesion may be more generalized in severe NUP cases. A characteristic fetor oris is usually present. Deep pockets are not a characteristic feature of NUP because of the extensive gingival necrosis which often coincides with loss of alveolar bone. The lesion may bleed on probing with 50% of sites bleeding spontaneously (Winkler & Robertson, 1992). Most studies report a similar microbial component in both NUP lesions associated with HIV and conventional chronic periodontitis (Glick et al., 1994b; Murray et al., 1989; Murray et al., 1991). Human herpes-viruses such as cytomegalovirus

have however been identified in some NUP lesions (Slot, 2004). Homosexuals and bisexual men appear to have a higher incidence of NUP compared to other cohorts of HIV positive individuals (Glick et al., 1994b). Several studies reveal an association between NUP and HIV progression (Masouredis et al., 1992; Winkler et al., 1988). NUP has also been reported to be one of the strongest predictors of severe immune suppression, characterized by low CD4 lymphocyte counts (Glick et al., 1994a; Glick et al., 1994b). Patients with NUP may however, have CD4 counts above 200 cells/mm<sup>3</sup>, indicating that other factors such as high viral loads may be associated (Umezudike et al., 2011a).



**Figure 10.** Necrotizing ulcerative periodontitis with sequestrum,

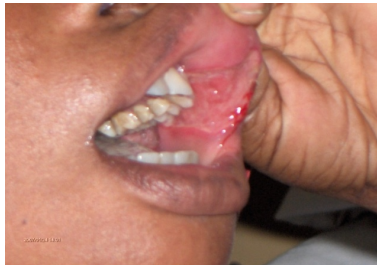

**Figure 11.** Radiograph of NUP showing extensive bone loss around 22.

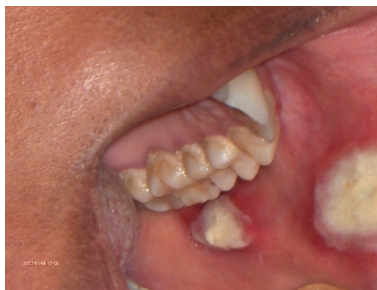#### 3.5.2.4. *Necrotizing ulcerative stomatitis*

This is a rare condition in HIV positive patients. It is characterized by a localized, acutely painful rapidly destructive lesion which is ulcerative and necrotic. The lesion may extend from the gingiva into the adjacent oral mucosa, resulting in extensive destruction of the underlying soft tissues and osseous tissues. It may occur as a separate condition or be an exten-

sion of NUP. The condition may lead to extensive denudation and eventual sequestration of bone (Williams et al., 1990). The condition is often associated with severe immune suppression with low CD4 lymphocyte counts. This condition is similar to the cancrum oris (noma) a rare destructive condition described in nutritionally deprived individuals particularly children in Africa which progresses from ANUG (Osuji, 1990). Studies carried out by various individuals all around Nigeria did not show the presence of the disease, though the condition was seen in Lagos University Teaching Hospital in a previously undiagnosed HIV seropositive patient (Agbelusi and Eweka, 2011).



**Figure 12.** Necrotizing ulcerative stomatitis

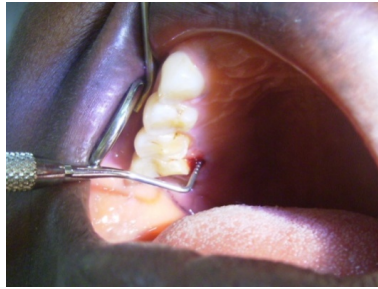


**Figure 13.** Necrotizing ulcerative stomatitis

### 3.5.2.5. *Chronic periodontitis with an increased rate of attachment loss*

Rapid periodontal pocket formation has been reported in HIV infection in some controlled studies (Barr et al., 1992; Yeung et al., 1993; Robinson et al., 1996; Ndiaye et al., 1997; Ranganathan et al., 2007; Umeizudike et al., 2011b). Although, this is not a consistent finding (Scheutz et al., 1997). This accelerated periodontal attachment loss reported in HIV infected individuals could be the result of severe episodes of NUP. The clinical presentation of gingivitis and chronic periodontitis in HIV-positive individuals is the same as that occurring in non HIV infected populations. It is characterized by the rapid destruction of the periodontal tissues characterized by rapid pocket formation and attachment loss. Radiographic features

with evidence of alveolar bone loss are evident. The risk factors for periodontitis in HIV positive patients include age, smoking pack-years, high viral load, *Fusobacterium nucleatum*, *Prevotella intermedia*, *Actinobacillus actinomycetemcomitans*, neutrophil elastase and  $\beta$ -glucuronidase (Alpagot et al., 2004).



**Figure 14.** Deep periodontal pocket around tooth 16.

### 3.5.3. Oral Hairy Leukoplakia: (OHL)

This lesion usually presents as asymptomatic, white, vertical, corrugated, hair-like projections on the lateral borders of the tongue (bilaterally or unilaterally). It can spread to the dorsum of the tongue and on the ventral aspect to the floor of the mouth and occasionally on the adjacent buccal mucosa, when seen in these areas it is smooth and velvety not hair-like. Unlike candidiasis the lesion cannot be wiped off the mucosal surface (ECC/WHO, 1993).

OHL was seen and investigated in 1981 by Greenspan et al., who published the initial report of its existence among homosexual men in San Francisco in 1984 (Greenspan et al., 1984).

It is slightly less common in women than in men, and it is also rare in children. In HIV positive persons OHL heralds more rapid progressions of AIDS (Greenspan et al., 1984; Glick et al., 1994; Lifson et al., 1994).

The incidence of OHL is reported to be 20% in CDC II individuals, increasing as CD4 count falls and patient's clinical condition deteriorates (Glick et al., 1994; Lifson et al., 1994). It also appears during the late latency stages of HIV infection. Although the studies carried out by Greenspan et al in 2000, showed that the presence of OHL was not related to CD4 count but was associated with high viral load.

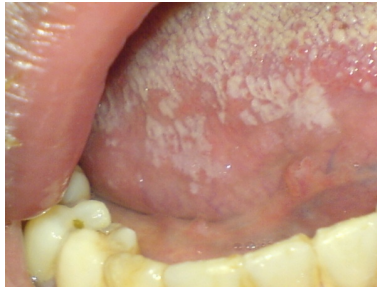OHL prevalence rates ranged from 0% amongst Tanzanians (Schiodt et al., 1990) to 20% in Cape Town (Arendorf et al., 1998).

Although originally postulated to be pathognomonic for HIV infection, this lesion has subsequently been reported in other immune deficiency states as well as in immunocompetent individuals (Sirois, 1998) e.g. among organ or bone marrow recipients and those receiving long-term steroid therapy (King et al., 1994).

The frequency of OHL is about 20% in those with otherwise symptom- free HIV infection and increases as the CD4 count falls and the clinical condition deteriorates (Aragues et al., 1990; Feigel et al., 1991; Glick et al., 1994; Lifson et al., 1994).

Considerable research have provided a body of evidence that the *Epstein Barr virus (EBV)* is the likely cause of this lesion, which should probably now be renamed according to its aetiology as "*EBV Leukoplakia*" (Greenspan et al., 1984; Iain et al., 2000).

Histologic features of OHL shows surface corrugation, thickening of the prickle- cell layer (acanthosis) with groups or layers of ballooning cells similar to koilocytes, absence of atypia and other features of dysplasia, lack of inflammatory cells infiltration in the epithelium or adjoining connective tissues (Greenspan et al., 1984). These features are not pathognomic of OHL. Evidence of presence of EBV is required for definitive diagnosis of OHL, although presumptive diagnosis can be made on clinical appearance alone and non-response to anti-fungal drugs. (ECC/WHO, 1993).



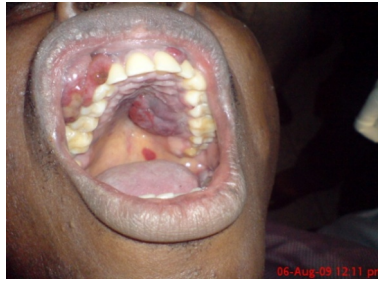**Figure 15.** Hairy leukoplakia

#### 3.5.4. *Kaposi's sarcoma*

This is the most common malignancy encountered in HIV/AIDS patients (Iain et al., 2000). Kaposi's sarcoma-associated herpes virus (KSHV)/Human Herpes Virus-8 (HHV-8) is the causative agent of the endothelial cell-derived tumour Kaposi's sarcoma (Sturzl et al., 2009). The lesions are commonly seen in homosexual men. The lesions are characterized by reddish, bluish or purple, single or multiple macules or nodules. These are seen on the palate or gingivae and may ulcerate, gingival involvement may lead to underlying bone destruction and tooth mobility (Iain et al., 1992). Twenty two percent of the lesions are present intraorally, with 45% of patients presenting with both skin and oral lesions (Tappero et al., 1993).

Biopsy is essential for a definitive diagnosis. It is considered pathognomonic of HIV infections.

There is evidence that oral Kaposi's sarcoma lesions are associated with patients who have lower CD4 counts than those with the skin lesions alone. (Iain et al., 2000)



**Figure 16.** Kaposi's sarcoma on the palate and gingiva

### 3.5.5. *Non- Hodgkin's Lymphoma (NHL)*

This is an uncommon feature of HIV disease. It is however, the second most common malignancy in this condition, with 4% of patients developing NHL during the course of their disease (Iain et al., 2000).

NHL of the oral cavity accounts for 3% of all malignant lymphomas, which tends to occur extranodally (Epstein et al., 1992).

Characteristically, oral tumours involve the fauces and gingivae but atypically may involve other sites such as the tongue (Borring et al., 1985).

It often clinically presents as a rapidly enlarging mass with associated bony destruction. Though the presentation varies, the pathogenesis of NHL remains obscure, but there has been much interest in the role of the Epstein Barr virus, with 50% of AIDS related tumours demonstrating EBV genomes and also aetiologic role of Human Herpes Virus-8 (HHV-8) (Boshoff et al., 1997). Survival rates are low and biopsy is essential for definitive diagnosis.

### 3.5.6. *Oral ulcers*

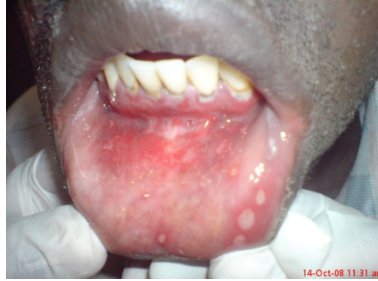Around 50% of AIDS patients present with oral ulcerations during the course of their disease. Recurrent aphthous ulcers (RAU) can be classified as **Minor aphthous Ulcers (MiAU) and Major Aphthous ulcers (MjAU)**.

**MiAU:** Occur in non-keratinized mucosa and their frequency in AIDS patients is not any different from that in the general population. RAU have a prolonged course in AIDS patients as well as being more painful and difficult to treat. These ulcers are shallow in appearance, about 2-5mm in diameter, are generally covered with a whitish pseudomembrane and surrounded by an erythematous halo.

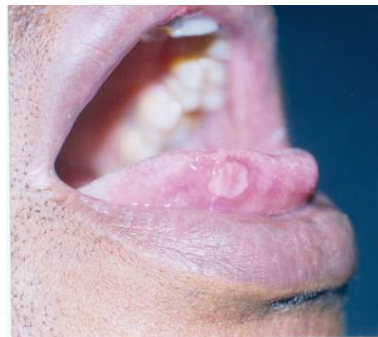**MjAU:** Are generally seen in AIDS patients with severe immunodepression (median CD4 T-lymphocyte count 100 cells/mm<sup>3</sup> or below) (Ramos-Gomez, 1997). These larger ulcers develop generally on the lateral border of the tongue, soft palate, floor of the mouth, buccal mucosa and oropharynx (occurring on both keratinized and non-keratinized surfaces). They are crater-like in appearance with elevated borders and covered with a white-yellowish



pseudomembrane, measuring over 1cm in diameter. These lesions are very painful and may persist for months causing difficulty in swallowing and impairment of speech and mastication. Generally, an erythematous halo can be seen surrounding the ulcer and may be accompanied by regional lymphadenopathy.



**Figure 17.** Minor aphthous ulcers.



**Figure 18.** Major aphthous ulcer.

### 3.5.7. Salivary gland diseases

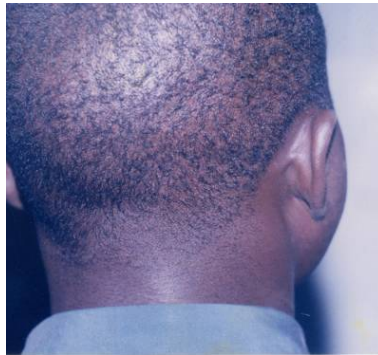Salivary gland diseases such as enlargement of the major salivary glands and xerostomia, was reported to be high in Northern Africa and Thailand (Nittayananta and Chungpanich, 1997). Malnutrition, especially in Northern Africa may play a role.

Enlargement of the salivary glands due to infiltration by CD8 lymphocytes is seen in both adult and paediatric HIV infection (Schoidt et al., 1989). Some of these glands undergo cystic change, and such benign lymphoepithelial cysts occasionally cause pain. The cause of HIV-related salivary gland diseases is unclear, for no etiological agents have been identified. It can represent a relatively beneficial host CD8 response - Diffuse Infiltrative Lymphocytosis Syndrome (DILS) (Itescu et al., 1990), the lymphocytes may be anti- HIV CD8 cells. No evi-

dence of Epstein-Barr virus or cytomegalovirus has been found in biopsies of salivary gland (Soberman et al., 1991) One report describes an association between HIV-SGD and HLA-DR5 and HLA-B35 cell-surface antigen (Schiodt et al.,1989).

Adults and children with salivary glands enlargement seem to experience slower progression of HIV disease (Katz et al., 1993).

Oral Mucoceles and ranulas are recently discovered to be oral manifestations of HIV infection. Several reports are considering it as initial symptoms and early manifestations of HIV infection (Syebele et al., 2010; Kamulegeya et al., 2012).



**Figure 19.** Salivary gland swelling

#### 3.5.7.1. Xerostomia

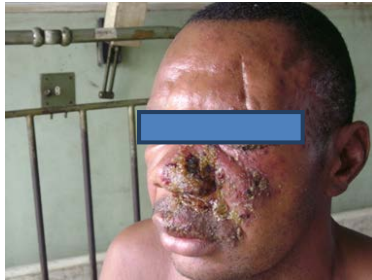This may be associated with the salivary gland enlargement but is also a common consequence of medications used by this population. Cytomegalovirus (CMV) has been demonstrated in the salivary gland of xerostomic patients (Greenspan et al., 1992). Symptomatic relief may be provided by salivary stimulants such as sugarless chewing gums or saliva substitutes. Prevention of dental caries in people with xerostomia is extremely important, and the use of topical fluoride gels and rinses should be encouraged (Greenspan et al., 1996). In addition, management of xerostomia will improve oral comfort, the quality of speech and use of any prostheses (Narani et al., 2001).

#### 3.5.7.2. Herpes virus infections

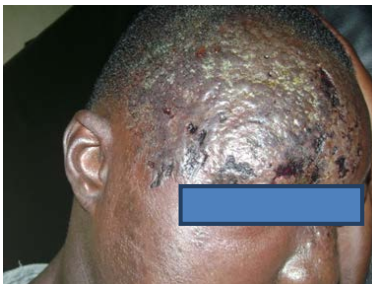Varicella zoster (VZV) is a herpesvirus, and, like other herpesviruses, it causes both primary and recurrent infection and remains latent in neurons present in sensory ganglia. VZV is responsible for two major clinical infections of humans: chickenpox (varicella) and shingles (herpes zoster [HZ]) (Greenburg et al., 2003 ).

Herpes zoster may indicate a poor prognosis of HIV infection (Scully et al., 1991). This can be an early complication of AIDS, where it is five times more common than HIV-negative

persons, and potentially lethal (Cawson et al., 2002). Varicella-zoster may present with a prodrome of dental pain, preceding oral and unilateral vesicles on an erythematous base then appear in clusters, chiefly along the course of the nerve, giving the characteristic clinical picture of single dermatome involvement. Some lesions spread by viremia occur outside the dermatome. The vesicles turn to scabs in 1 week, and healing takes place in 2 to 3 weeks and condition can be life threatening in HIV disease.



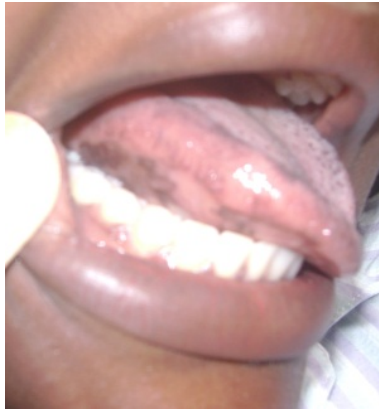
**Figure 20.** Herpes zoster of the left maxillary branch and the right occipital branch of the trigeminal nerve



**Figure 21.** Herpes zoster of the left maxillary branch and the right occipital branch of the trigeminal nerve.

### 3.5.7.3. *Melanotic hyperpigmentation*

Brownish or brown black macular oral hyperpigmentation, typically associated with intra-leukocytic melanin or pigment in the basal cell layer or lamina propria, with premature melanosomes has been described in HIV-infected patients (Langford et al., 1989; Porter et al., 1990). Often the cause is unknown, but identified causes include Zidovudine (AZT), Clofazimine, ketoconazole and hypoadrenocorticism as a result of adrenal *Mycobacterium avium intracellulare* infection (Porter et al., 1990). Usually does not respond to HAART.



**Figure 22.** Melanotic hyperpigmentation

### **3.6. Management of oral lesions of HIV**

#### *3.6.1. Candidiasis*

Treatment may be topical (using lozenges or mouth rinses) or systemic depending on the severity of the disease and other associated underlying conditions e.g. Diabetes, liver disease, xerostomia etc.

#### **Topical:**

1. Chlorhexidine (0.2%) mouth wash
2. Lozenges: e.g. Nystatin (Mycostatin) 100,000 i.u; Clotrimazole (Mycelex) 1%
3. Adhesive tablets: Miconazole 10mg
4. Miconazole oral gel- X2% daily
5. Suspension: e.g. Amphotericin B (0.5-1mg), Nystatin (100,000 i.u)

Topical treatments are preferred because they limit systemic absorption, but the effectiveness depends entirely on patient compliance. Topical medications require that the patient hold medications in the mouth for 20 to 30 minutes.

Clotrimazole is an effective topical treatment (one oral troche [10-mg tablet]) when dissolved in the mouth five times daily. Used less frequently, one vaginal troche can be dissolved in the mouth daily.

Nystatin preparations include a suspension, a vaginal tablet, and an oral pastille. Regimens are nystatin tablets (one tablet, 100,000 units, dissolved in the mouth three times a day), or nystatin oral pastille (available as a 200,000 unit oral pastille, one or two pastilles dissolved slowly in the mouth five times a day). Nystatin suspension has a high sugar content and

cannot be held in the mouth long enough to be effective. Topical creams and ointments containing nystatin, ketoconazole, or clotrimazole may be useful in treating angular cheilitis. For patients with initial and recurring oropharyngeal candidiasis, a topical agent is generally recommended, provided the patient has a CD4 count greater than 50 cells/mm<sup>3</sup> and no oesophageal involvement.

Another therapeutic choice is Amphotericin B (0.1 mg/ml). Five to 10 ml of oral solution is used as a rinse and then expectorated three to four times daily (Greenspan, 1998).

**Systemic:** Fluconazole 150mg daily (Diflucan) for 2 weeks or more

- Miconazole 250mg daily for 2 weeks or more
- Ketoconazole 200mg daily (Sporanox), for 2 weeks or more
- Itraconazole 100mg daily, for 2 weeks or more

Ketoconazole (Nizoral) is a 200 mg tablet taken with food once daily. Patient compliance is usually good. Careful monitoring of liver function is necessary for long-term use because of reported side effects, including hepatotoxicity. Lack of efficacy of ketoconazole may occur because of poor absorption in those with an abnormally high gastric pH.

Fluconazole (Diflucan) is a triazole antifungal agent effective in treating candidiasis (100-mg tablet taken once daily for 2 weeks (Just-Nubling et al., 1991).

Itraconazole (100 mg capsules) may be used for the treatment of oral candidiasis (200 mg daily orally for 14 days. Salivary levels of itraconazole are maintained for several hours after administration (Smith et al., 1991).

The recommendation to avoid systemic anti-fungal therapies in this setting is based on evidence that widespread use of systemic azoles is strongly linked with the development of drug-resistant candidiasis. Patients with concurrent oesophageal involvement or a CD4 count less than 50 cells/mm<sup>3</sup> should receive a systemic oral azole.

Ketoconazole, fluconazole, and itraconazole may interact with other medications including rifampicin, phenytoin, cyclosporin A, terfenadine, digoxin, coumarin-like medications, and oral hypoglycemic medications.

### 3.6.2. *Linear gingival erythema*

The treatment protocol for LGE is similar to that of conventional marginal gingivitis and consists of scaling and polishing of the affected sites and thorough root planing using chlorhexidine solution as an irrigant (Murray, 1994). Povidone-iodine (10%) solution may be beneficial for the irrigation because of its anaesthetic and antiseptic effects. According to Murray (1994), the rationale for scaling is to prevent the lesion from progressing to NUP, the more severe form. Typically, the patients are given oral hygiene instructions to achieve good home care, placed on chlorhexidine mouthrinses twice daily, re-assessed 2 to 3 weeks after the initial therapeutic phase, and further recalled every 3 months.

Non-responsive lesions could signal a possible candidal co-infection which may need to be treated concomitantly with topical antifungal rinses or systemic antifungal tablets such as fluconazole for 7 to 10 days (Murray, 1994). This has been shown to reduce the erythema associated with LGE. It must be borne in mind that LGE may still be refractory to treatment, hence, patient should be monitored closely for any signs of severe necrotizing periodontal conditions. The lesion has sometimes been known to undergo spontaneous remission for reasons yet unknown.

### 3.6.3. *Necrotizing ulcerative gingivitis*

The NUG lesion should be debrided thoroughly under topical anaesthesia to remove tissue slough, plaque and necrotic soft tissue in the initial phase of treatment. Irrigation should be done frequently with hydrogen peroxide or povidone iodine which is particularly advantageous because of its topical anaesthetic effect (Grassi et al., 1988). This should be accompanied by daily or alternate day visits for further debridement of affected areas for the first week with the gradual introduction of home plaque control measures to reinforce good oral hygiene. This initial phase of treatment is followed by scaling and thorough root planing if indicated. Systemic antibiotics such as metronidazole may be prescribed in severe cases of tissue loss or associated systemic effects. Topical chlorhexidine gluconate 0.12% mouthwash is prescribed. Patients are reassessed 1 month after resolution of the acute phase to determine if further therapy is needed. Most of the lesions may resolve within a week (Robinson et al., 1998).

### 3.6.4. *Necrotizing ulcerative periodontitis*

The treatment of NUP involves the gentle debridement of the affected lesions, followed by sub-gingival scaling and root planing, irrigation with chlorhexidine gluconate (Grassi et al., 1988; Umeizudike et al., 2011a) or povidone-iodine. Oral hygiene instructions should be emphasized alongside the home use of twice daily antimicrobial mouth-rinses such as 0.12% or 0.2% chlorhexidine gluconate. In severe NUP cases, systemic metronidazole 500mg loading dose and 250 mg four times daily for 5-7 days is the drug of choice. It has been shown to reduce acute pain and promote rapid healing. Metronidazole should be prescribed with caution in patients with liver alteration or history of hepatitis (Winkler & Robertson, 1992). Alternatively, penicillin may be prescribed. However, it should be used with caution to avoid the proliferation of opportunistic infections such as candidiasis. Appropriate topical or systemic antifungal treatment may be used for patients who have concurrent oral candidiasis (Holmstrup & Samaranayake, 1990). There is a need to follow up these patients after the initial phase of therapy to ensure adequate plaque control and reduce the incidence of delayed healing and continued rapid destruction (Winkler & Robertson, 1992). Oral hygiene aids such as interproximal brushes may be necessary to achieve better plaque control. Sequestra should be removed if present to facilitate wound healing (Umeizudike et al., 2011a) and may not always require antibiotic coverage (Robinson, 1991).

### 3.6.5. *Necrotizing ulcerative stomatitis*

The principles of the treatment are similar to that of necrotizing ulcerative periodontitis. It should begin with gross scaling to remove visible plaque and debridement of necrotic soft tissue. Povidone-iodine may be used for irrigation. Systemic metronidazole and chlorhexidine mouthrinses should be prescribed. Necrotic bone should be removed if present to promote wound healing (Williams et al., 1990).

### 3.6.6. *Chronic periodontitis with an increased rate of attachment loss*

This should include conservative, non-surgical periodontal therapy which basically consists of scaling and polishing of all teeth, sub-gingival scaling and root planing of affected teeth. Detailed oral hygiene instructions should be given to the patient in order to achieve effective plaque control. This should include the use of 0.2% chlorhexidine mouthwashes twice daily at home. The overall health status of the patient, the degree of immune suppression, extent of periodontal attachment loss and patient's ability to perform effective oral hygiene are all the factors that should be taken into consideration when planning for elective periodontal surgical procedures and implant placement. The hematological profile of patients may be required prior to these surgical procedures to monitor their overall health status. Periodontal maintenance recalls should be instituted at 2-3 monthly intervals initially, and later to 6 monthly intervals. Dentists should be ready to advise patients and provide dental treatments in a relaxed and calm atmosphere to minimize the patients stress and anxiety, as these HIV positive patients are prone to psychological problems (Asher et al. 1993).

In summary, it should be noted that the treatment of periodontal diseases associated with HIV should have some basic components (Winkler & Robertson, 1992).

1. Extensive debridement of necrotic tissues.
2. Antimicrobial therapy (local and systemic)
3. Immediate follow up phase
4. Regular long-term maintenance

### 3.6.7. *Oral Hairy Leukoplakia (OHL)*

**OHL** is usually symptomless; complaints about the discomfort and appearance sometimes justify treatment (Barr, 1995). The lesions respond to high doses of acyclovir, ganciclovir, and also podophyllin and retinoin. Treatment is usually not indicated, but improved with antiretroviral therapy e.g. AZT, Ganciclovir, acyclovir or descyclovir. Hairy leukoplakia recurs after discontinuation of therapy (Scully et al., 1992).

### 3.6.8. *Kaposi's sarcoma*

Treatment of oral kaposi's sarcoma is directed towards control of spread and palliation, for aesthetic reasons, pain or functional impairment. It is by radiotherapy or chemotherapy such as Vinblastin. Radiation therapy may be indicated for large, multiple lesions (Green-

span et al., 1984). A single dose of 800 cGy or an equivalent fractionated dose is frequently used and produces a good response. Other local therapy may involve excision of exophytic lesions or intra-lesional injection of vinblastin (Iain et al., 2000).

### 3.6.9. Oral ulcers

Topical steroids can be effective in the treatment of MiAU and MjAU:

- i. Fluocinonide gel 0.05% with Orabase - apply to ulcers four times daily.
- ii. Clobetasol 0.05% in Orabase – apply 3-4 times daily.
- iii. Dexamethasone elixir 0.5mg/ml – rinse with 20ml four times daily
- iv. Triamcinolone in Orabase – apply 3-4 times daily.

Ulcers are reevaluated after one week. If there is no improvement, alternative treatment should be considered, including systemic steroids e.g. Prednisolone.

Alternative forms of treatment have included **intralesional** injection with **Triamcinolone acetoneide**.

Supportive therapy is necessary to aid healing of the ulcers, this includes:

- Vitamin B complex i tds
- Tabs Folic acid i daily
- Tabs Vitamin C 300mg tds
- Xylocaine gel to relieve pain and Chlorhexidine mouth wash.

### 3.6.10. Salivary gland diseases

No treatment is indicated for the salivary gland enlargement, although large cystic glands are sometimes removed surgically for cosmetic purposes. Radiation therapy has also been used to reduce the swelling.

### 3.6.11. Xerostomia

The management of xerostomia involves the use of both saliva substitutes and saliva stimulants. Patients with little or no responsive salivary gland tissue will need saliva substitutes. A properly balanced artificial saliva should be of neutral pH and contain electrolytes, including fluoride, to correspond to the composition of saliva.

Gustatory stimuli such as sugarless sweets containing citric and malic acid, chemically induce saliva production. Care must be taken that the acidic content does not result in the dissolution of tooth enamel. Controlled studies have shown that pilocarpine is an effective stimulus to saliva production (Greenspan et al., 1987; Rieke et al., 1995), side effects, mainly the result of generalised parasympathetic stimulation, are the most common reason to discontinue treatment.



There have been a number of studies that have shown that chewing gum increases salivary flow from patients with xerostomia of varying aetiology (Risheim et al., 1993). In some xerostomic patients, the initial stimulated salivary flow rate while chewing sugar free gum is seven times greater than the unstimulated flow rate. Chewing sugar free gum has been shown to be one of the most preferred treatments for xerostomia (Bjornstrom et al., 1990).

### 3.6.12. *Herpes zoster*

Management should be directed toward shortening the course of the disease, preventing post-herpetic neuralgia in patients over 50 years of age, and preventing dissemination in immunocompromised patients. Acyclovir or the newer antiherpes drugs valacyclovir or famciclovir accelerate healing and reduce acute pain, but they do not reduce the incidence of postherpetic neuralgia. The newer drugs have greater bioavailability and are more effective in the treatment of HZ. Supportive therapy, antibiotics and analgesics are also recommended.

- Tabs Acyclovir 200-400mg 5x daily for 1 week

### 3.7. Oral lesions and relationship with CD4 count and viral load

The hallmark of HIV disease is the progressive loss of CD4+ lymphocytes. Without intervention, an average of 60 to 80 cells/mm<sup>3</sup> is lost every year; this loss is highly variable and occurs in periods of stability and rapid decline. High viral load is also considered to be one of the main indicators of the progression of HIV-induced immunosuppression. Several studies have shown that the higher the viral load, the quicker the progression to AIDS.

The CD4 count and viral load measure the progression of the HIV disease. Several studies have shown high prevalence of oral lesions in patients with low CD4 count, <200 cells/mm<sup>3</sup> and high viral load: >55,000 copies/ml. CD4 count < 200 cells/mm<sup>3</sup> is used as criterion for initiating HAART, which is consistent with the guidelines for initiating HAART treatment by WHO (2003).

Presence of multiple lesions in infected HIV patients is also associated with severe immunosuppression and AIDS.

### 3.8. Oral lesions and response to HAART

The goals of HAART should be maximal and durable viral suppression. The aim is preservation and restoration of the immune system at minimal cost to the patient. This should improve the quality of life through ease of use of their regimen with minimal side-effects to enhance optimum adherence. This should translate into a reduction of HIV-related morbidity including oral manifestations. Reduction of viral burden will prevent progressive immunodeficiency, decrease the risk of the emergence of resistant viruses and possibly decrease the risk of viral transmission (Fauci et al., 2000).

It has been shown in various studies that the prevalence of HIV-related oral lesions reduces significantly with HAART. The reported percentage decrease varied from 10% in a USA

study on 570 patients (Patton et al., 2000) to 50% in a Mexican study on selected 1000 HIV patients over a period of 12 years (Ramírez-Amador et al., 2003).

In a Spanish study on 154 subjects, Ceballos-Salobrena et al (2000) showed a 30% reduction of oral lesions, while Tappuni and Fleming (2001) reported a reduction of 24% in a study on 284 patients in the United Kingdom. Some looked at a particular oral manifestation (Cauda et al., 1999) as opposed to a range of oral lesions (Ceballos-Salobrena et al., 2000; Tappuni and Fleming, 2001; Eyson et al., 2002; Ramírez-Amador et al., 2003).

Studies examining the effect of HAART on the prevalence of individual oral manifestations mainly reported on oral candidiasis, oral hairy leukoplakia, HIV-related periodontal diseases, Kaposi's sarcoma (KS), oral papilloma, and HIV-related salivary gland disease showed reduction in the prevalence (Patton et al., 2000; Schmidt-Westhausen et al., 2000; Tappuni et al., 2001).

Oral candidiasis (OC) has been shown to be one of the most common oral lesions in HIV patients. With the advent of HAART, most studies reported a decrease in the prevalence of Oral Candidiasis. In a study on 93 patients, 7% of patients on protease inhibitors (PI) had Oral Candidiasis, compared with 36% in non-PI-treated patients (Cauda et al., 1999). Schmidt-Westhausen et al (2000) detected Oral Candidiasis in 10/103 (9.7%) of their study subjects who had been on HAART for 4 weeks and in none after 6 months' therapy (n = 61). Tappuni and Fleming (2000) reported that the prevalence of Oral Candidiasis was about 50% less in patients on therapy (n = 89) compared with drug-naïve patients (n = 195). Conversely, Patton et al (2000) found no significant difference in the prevalence of Oral Candidiasis with the use of Protease Inhibitors (n = 507). In the same study, the prevalence of oral hairy leukoplakia (OHL) was found to decrease with therapy (Patton et al., 2000), in agreement with reports from other studies (Tappuni and Fleming, 2001).

The prevalence of HIV-associated periodontal diseases was reported to decrease significantly in an American cohort, from 4.8% to 1.7% with HAART (Patton et al., 2000), in concordance with findings in other studies (Ceballos-Salobrena et al., 2000; Tappuni and Fleming, 2001).

Kaposi's Sarcoma (KS) is one of the oral manifestations that is strongly associated with HIV, although its prevalence is quite low in this group (Ceballos-Salobrena et al., 2000). Studies from the USA (Patton et al., 2000) and Mexico (Ramírez-Amador et al., 2003) found no significant change in the occurrence of Kaposi Sarcoma with HAART.

Unlike most other oral manifestations of HIV, studies from the USA and the United Kingdom(UK) described an increase in the prevalence of oral warts with HAART (Patton et al., 2000; Greenwood et al., 2002), which may reach statistical significance (Greenspan et al., 2001). Others looking at a different population (Mexicans) reported similar detection rates of oral warts, papillomas, condylomas and focal epithelial hyperplasia in HIV-positive subjects on HAART compared with those not on therapy (Ramírez-Amador et al., 2003).

Other lesions that are showing a trend of rising prevalence include HIV-related salivary gland disease (Patton et al., 2000). However, this was not supported by other studies (Ramírez-Amador et al., 2003). Studies from industrialized world report a decreased frequency of

HIV-related oral manifestations of 10–50% following the introduction of HAART (Hodgson et al., 2006).

## Author details

G.A. Agbelusi<sup>1</sup>, O.M. Eweka<sup>1</sup>, K.A. Ûmeizudike<sup>1</sup> and M. Okoh<sup>2</sup>

1 Faculty of Dental Sciences, College of Medicine, University of Lagos, Lagos State, Nigeria

2 School of Dental Sciences, College of Medicine, University of Benin, Edo State, Nigeria

## References

- [1] Adedigba MA, Ogunbodede EO, Jeboda SO, Naidoo S (2008): Patterns of oral manifestation of HIV/AIDS among 225 Nigerian patients. *Oral Dis.* 4: 314-316.
- [2] Adurogbangba MI, Aderinokun GA, Odaibo GN, Olaleye OD, Lawoyin TO (2004): Oro-facial lesions and CD4 counts in an adult population in Oyo state, Nigeria. *Oral Dis.* 10: 319-326.
- [3] Agbelusi GA, Eweka OM (2011). Necrotising Stomatitis as a presenting symptom of HIV. *Scrip.org/journal/OJST.* 1:1-4.
- [4] Agbelusi GA, Wright AA (2005): Oral lesions as indicators of HIV infection among routine dental patients in Lagos, Nigeria. *Oral Dis;* 11: 370-373
- [5] Alpagot T, Duzgunes N, Wolff LF, Lee A (2004): Risk factors for periodontitis in HIV positive patients. *J Periodont Res;* 39: 149-157.
- [6] Anteyi KO, Thacher TD, Yohanna S, Idoko JI( 2003): Oral manifestation of HIV/ AIDS in Nigerian patients. *Int. J. AIDS;* 14: 395-398.
- [7] Aragues M, Sanchez Perez J, Fraga J, Burgos E, Noguerado A, Garciadiez A (1990): Hairy Leukoplakia : a clinical histopathological and ultrastructural study in 33 patients. *Clin Exp Dermatol ;* 15:335-339.
- [8] Arendorf TM; Bredekamp B, Cloete CAC (1998): Oral manifestations of HIV infection in 600 South African patients. *J. Oral Pathol Med.* 27: 179-189.
- [9] Armitage GC(1999): Development of a classification system for periodontal diseases and conditions. *Ann Periodontol;* 4:1-6.
- [10] Arotiba JT, Arowojolu MO, Fasola AO, Denloye OO, Obiechina AE (2006): Oral manifestation of HIV/AIDS. *Afr J Med Med Sci.;*(35): 13-18.
- [11] Asher RS, McDowell JD, Winquist H. (1993): HIV-related neuropsychiatric changes: concerns for dental professionals. *J Am Dent Assoc* 124:80.

- [12] Barr C, Lopez MR, Rua-Dobles A (1992): Periodontal changes by HIV serostatus in a cohort of homosexual and bisexual men. *J Clin Periodontol* 19: 794-801.
- [13] Bjornstrom M, Axell T, Birkhed D (1990) Comparison between saliva stimulants and saliva substitutes from patients using symptoms related to dry mouth. A multi-centre study. *Swed Dent J.* 14: 153-161 Boring CC, Brynes RK, Chan WC (1985): Increase in high grade lymphomas in young men. *Lancet*; 1: 857-859.
- [14] Boring CC, Brynes RK, Chan WC (1985): Increase in high grade lymphomas in young men. *Lancet*; 1: 857-859.
- [15] Boshoff C, Whitby D, Talbot S (1997): Aetiology of AIDS- related kaposi's sarcoma and lymphoma. *Oral Dis.* 3: S129-132.
- [16] Campisi G, Pizzo G, Mancuso S, Margiotta V (2002): Gender differences in HIV-related oral lesions: an Italian study. *Oral Surg Oral Med Oral Pathol*; 93 (3): 281-286.
- [17] Cauda R, Tacconelli E, Tumbarello M, Morace G, De Bernadis et al (1999): Role of protease inhibitor in preventing recurrent oral candidosis in patients with HIV infection: a prospective case- control study. *J AIDS*; 21: 20-25
- [18] Ceballos-Salobrena A, Aguirre-Urizar JM, Bagan-Sebastian JV (1996): Oral manifestations associated with human immunodeficiency virus infection in a Spanish population. *J Oral Pathol Med*: 25: 523-526.
- [19] Ceballos-salobrena A, Gactan-Cepeda L A, Ceballos-Garcia L, Lezamz- Del Nalle D (1997): Oral lesions in HIV/AIDS patients undergoing Highly Active Anti-Retroviral Treatment including protease- inhibitors: a new face of oral AIDS. *Oral Dis*; 3 suppl 1: S46-50
- [20] Centers for Disease Control and Prevention (1993): Revised classification system for HIV infection and expanded surveillance case definition for AIDS among adolescents and adults . *MMWR Recomm Rep.* 41:1-19.
- [21] Davoodi P, Hamian M, Nourbaksh R, Motamayel FA (2010): Oral Manifestations Related To CD4 Lymphocyte Count in HIV-Positive Patients. *J Dent Res Dent Clin Dent Prospect*; 4(4):115-119.
- [22] EC-Clearinghouse on oral Problems Related to HIV Infection and WHO Collaboration center on oral manifestations of the immunodeficiency Virus (ECC/WHO) (1993): Classification and diagnostic criteria for oral lesions in HIV infection. *J Oral Pathol Med* 22:289-291.
- [23] Epstein JB, Silverman S (1992): Head and neck malignancies associated with HIV infection. *Oral Surg. Oral Med. Oral Pathol*; 73: 193-300.
- [24] Eyeson JD, Tenant-Flowers M, Cooper DJ, Johnson NW, Warnakulasuriya KA (2002): Oral manifestations of an HIV positive cohort in the era of highly active anti-retroviral therapy (HAART) in South London. *J Oral Pathol Med* 31:169-174.

- [25] Fauci AS, Bartlett JG, Goosby EP (2000): Guidelines for the use of antiretroviral agents in HIV-1 infected adults and adolescents. Panel on clinical practices for treatment of HIV infection conveyed by the department of health and Human services and the Henry J Kaiser foundation.
- [26] Feigel D W, Katz MH, Greenspan D (1991): The prevalence of oral lesions in HIV- infected homosexual and bisexual men: three San-Fransisco epidemiological cohorts . AIDS; 5: 519-525.
- [27] Glick M, Muzyka BC, Lurie D, Salkin LM (1994): Necrotising Ulcerative Periodontitis : a marker for immune deterioration and a predictor for the diagnosis of AIDS. J. Periodontol. 65: 393-397.
- [28] Gornitsky M. Pekovie D (1987): Involvement of human immunodeficiency virus (HIV) in gingival of patients with AIDS. Adv Exp Med Biol ;216: 553-62.
- [29] Grassi M, Williams CA, Winkler JR et al (1988): Management of HIV-associated periodontal diseases. In Robertson, PB & GJS, ed. Perspectives on Oral Manifestations of AIDS. PSG Publishing Co., Inc., Littleton, pp. 119-130.
- [30] Grbic FT, Mitchelle-Lewis DA, Fine JB (1995): The relationship of candidosis to LGE in HIV- infected homosexual men and parenteral drug users. J. Periodontol. 66: 30-37.
- [31] Greenburg MS, Glick M (2003): ulcerative, vesicular and bullous lesions, Burket's oral Medicine. Diagnosis and treatment, 10th edition. 50-84.
- [32] Greenspan D, Greenspan JS, Conant M, Peterson V, Silverman S, De Sonza Y (1984): Oral Hairy Leukoplakia in male homosexuals: evidence of association with both papilloma virus and a herpes group virus. Lancet 831-834.
- [33] Greenspan D, Daniels TE (1987): Effectiveness of pilocarpine from postradiation xerostomia. Cancer. 59: 1123-1125
- [34] Greenspan D, Greenspan JS, Schiodt M, Pindborg JJ. (1990.):In: AIDS and the mouth. Copenhagen: Munksgaard.
- [35] Greenspan D, Greenspan JS (1996): HIV- related oral disease. The Lancet; 348: 729-733.
- [36] Greenspan JS, Barr CE, Sciubba JJ, Winkler J R (1992): Oral manifestations of HIV infection. Oral Surg Oral Med Oral Pathol; 73: 142-144.
- [37] Greenspan D (1998): Oral manifestation of HIV. HIV InSite Knowledge Base Chapter
- [38] Greenspan D, Canchola AJ, MacPhail LA, Cheikh B, Greenspan JS (2001): Effect of highly active antiretroviral therapy on frequency of oral warts. Lancet 357:1411-1412.
- [39] Greenwood I, Zakrzewska JM, Robinson PG (2002): Changes in the prevalence of HIV-associated mucosal disease at a dedicated clinic over 7 years. Oral Dis 8:90-94.

- [40] Hodgson TA, Greenspan D, Greenspan JS (2006): Oral lesions of HIV diseases and HAART in industrialized countries. *Adv. Dent. Res* 19:57- 62.
- [41] Holmes HK, Stephen LX (2002): Oral lesions of HIV infection in developing countries. *Oral Disease*; 8(2): 40-43.
- [42] Holmstrup P, Westergaard J (1998): HIV infection and periodontal diseases. *Periodontology* 2000; (18): 37-46.
- [43] Iain LC, Hamburger J(2000): The significance of oral health in HIV disease. *Sex Trans infection*; 76: 236-243.
- [44] Itescu S, Brancato L, Buxbaum J (1990): A diffuse infiltrative CD8 lymphocytosis syndrome in HIV infection: A host immune response associated with HLA-DR5. *Ann Intern Med.* 112: 3-10.
- [45] Just-Nubling G, Gentschew G, Meissner K (1991): Fluconazole prophylaxis of recurrent oral candidiasis in HIV-positive patients. *Eur J Clin Microbiol Infect Dis*;10: 917-21.
- [46] Kaminu HN, Naidoo S (2002): Oral HIV lesions and oral health behavior of HIV-Positive patients attending the Queen Elizabeth II Hospital, *SADJ* 57:479.
- [47] Katz MH, Mastrucci MT, Leggott PJ, Westenhouse J, Greenspan JS, Scott GB (1993): Prognostic significance of oral lesions in children with perinatally acquired HIV infection. *Am J Dis Child* 147 (1): 45-48.
- [48] King GN, Healy CM, Glover MT (1994): Prevalence and risk factors associated with hairy Leukoplakia, erythematous candidiasis and gingival hyperplasia in renal transplant recipients. *OralSurg Oral Med Oral Pathol*; 78:18-26.
- [49] Lamster IB, Begg MD, Mitchell-Lewis D, et al (1994): Oral manifestations of HIV infection in homosexual men and intravenous drug users, *Oral Surg Oral Med Oral Pathol*; 78: 163.
- [50] Lifson AR, Hilton JF, Westenhouse JL (1994): Time from HIV seroconversion to oral candidiasis or Hairy Leukoplakia among homosexual and Bisexual men enrolled in three prospective cohorts. *J AIDS*; 8: 73- 79.
- [51] Lihana RW, Khamadi SA , Lwembe RM, Kinyua JG, Muriuki JK et al (2009): HIV-1 subtype and viral tropism determination for evaluating antiretroviral therapy options: an analysis of archived Kenyan blood samples. *BMC Infect. Dis*; 9:215-217.
- [52] Maeve MC, Greenspan J, Challacombe SJ (2005). Oral lesions in infection with HIV. *Bulletin of the World Health Organisation.* 83: 700-706.
- [53] Masouredis CM, Katz MH, Greenspan D, Herrera C, Hollander H, Greenspan JS, Winkler JR (1992): Prevalence of HIV-associated periodontitis and gingivitis in HIV-infected patients attending an AIDS clinic. *J Acquir Immune Defic Syndr* 5: 479-483.

- [54] Matee M, Scheutz F, Moshy J. (2000): Occurrence of oral lesions in relation to clinical and immunological status among HIV-infected adult Tanzanians. *Oral Dis*; 6: 106-111.
- [55] Mckaig RG, Patton LL, Thomas JC, Strauss RP, Slade GD. (2000): Factors associated with periodontitis in an HIV infected southeast USA study. *Oral dis*. 6: 158-165.
- [56] McNeil DG Jr (2007): "U.N. agency to say it overstated extent of HIV cases by millions". *New York Times*.
- [57] Miceli MC, Parnes JR (1993): "Role of CD4 and CD8 in T cell activation and differentiation". *Adv. Immunol*. 53: 59-122.
- [58] Mirowski GW, Hilton JF, Greenspan D, Canchola AJ, MacPhail LA, Maurer T, Berger TG, Greenspan JS. (1998): Association of cutaneous and oral diseases in HIV – infected men. *Oral Dis*. (1): 16-21.
- [59] Murray PA, Grassi M, Winkler JR (1989):. The microbiology of HIV associated periodontal lesions. *J Clin Periodontol* 16: 636-642.
- [60] Murray PA, Winkler JR, Peros WJ, French CK, Lippke JA (1991). DNA probe detection of periodontal pathogens in HIV-associated periodontal lesions. *Oral Microbiol Immunol*: 6: 3440.
- [61] Murray PA. (1994): Periodontal diseases in patients infected by human immunodeficiency virus. *Periodontology* 2000. (6): 50-67.
- [62] Narani N, Epstein JB (2001): classifications of oral lesions in HIV infection. *J clin Periodontol* ; 28: 137-145.
- [63] Ndiaye CF, Critchlow CW, Leggot PJ, Kiviati NB, Ndoye I, Robertson PB, Georgas KN (1997): Periodontal status of HIV-1 and HIV-2 seropositive and HIV seronegative female commercial sex workers in Senegal. *J Periodontol*; 68: 827-831. *West Afr J Med*; 21: 9-11.
- [64] Nittayananta W, Chungpanich S(1997): Oral lesions in a group of Thai people with AIDS. *Oral Dis*. 3:41-56.
- [65] Onunu A N, Obueke N (2002): HIV- related oral diseases in Benin city,
- [66] Osuji OO (1990): Necrotizing ulcerative gingivitis and cancrum oris in Ibadan, Nigeria. *J Periodontol*; 61: 769-772.
- [67] Palmer GD, Robinson PG, Challacombe SJ, Birnbaum W, Croser D, Erridge PL et al. (1996): Aetiological factors for oral manifestation of HIV infection. *Oral Dis*. 2: 193-197.
- [68] Patton LL, McKaig R, Strauss R, Rogers D, Eron JJ Jnr. (2000): Changing prevalence of oral manifestations of human immuno-deficiency virus in the era of protease inhibitor therapy. *Oral Surg Oral Med Oral Pathol Oral Radiol Endod* 89:299-304.

- [69] Ramírez-Amador V, Esquivel-Pedraza L, Sierra-Madero J, Ponce-de-Leon S (1998): Oral manifestations of HIV infection by gender and transmission category in Mexico City. *J Oral Pathol Med* 27 (3): 135-140.
- [70] Ramírez-Amador V, Esquivel-Pedraza L, Sierra-Madero J, Anaya-Saavedra G, Gonzalez-Ramírez I, Ponce-de-Leon S (2003): The changing clinical spectrum of human immunodeficiency virus (HIV)-related oral lesions in 1,000 consecutive patients: a 12-year study in a referral center in Mexico. *Medicine (Balt)* 82:39-50.
- [71] Ramos-Gomez FJ (1997): Oral aspects of HIV disease in children. *Oral Dis.* 3: S31-35.
- [72] Ranganathan K, Reddy BV, Kumarasamy N, Solomon S, Viswanathan R et al. (2000) Oral lesions and conditions associated with human immunodeficiency virus infection in 300 South Indian patients. *Oral Diseases.* 6: 152-157.
- [73] Ranganathan K, Magesh KT, Kumarasamy N, Solomon S, Viswanathan R, Johnson NW (2007): Greater severity and extent of periodontal breakdown in 136 south Indian human immunodeficiency virus seropositive patients than in normal controls: A comparative study using community periodontal index of treatment needs. *Indian J Dent Res.* 18(2): 55-59.
- [74] Reichart PA, Gelderblom HR, Becker J, Kuntz A. (1987): AIDS and the oral cavity. The HIV-infection: virology, etiology, origin, immunology, precautions and clinical observations in 110 patients. *Int J Oral Maxillofac Surg*; 16: 129-153.
- [75] Rieke JW, Hafermann MD, Johnson JT (1995): Oral pilocarpine for radiation-induced xerostomia: integrated efficacy and safety results from two prospective randomized clinical trials. *Int J Rad Onc Biol Phys.* 31: 661-669
- [76] Riley C, London JP, Burmester JA (1992): Periodontal health in 200 HIV positive patients. *J. Oral pathol. Med.* 21: 124-127.
- [77] Risheim H, Arneberg P (1993) Salivary stimulation by chewing gum and lozenges from rheumatic patients using xerostomia. *Scand J Dent Res.* 181: 40-43
- [78] Robinson PG, Sheiham A, Challacombe SJ, Wren MWD, Zakrzewska JM (1998): Gingival Ulceration in HIV infection. A case series and case control study *J Clin Periodontol*; 25: 260-267.
- [79] Robinson PG, Adegboye A, Rowland RW, Yeung S, Johnson NW (2002): Periodontal diseases and HIV infection. *Oral Diseases* 8(2): 144-150.
- [80] Scheutz F, Matee MIN, Andsager L, Holm AM, Moshi J et al. (1997): Is there an association between periodontal condition and HIV infection? *J Clin Periodontol*; 24: 580-587.
- [81] Schiodt M, Pindborg JJ (1987): AIDS and the oral cavity. Epidemiology and clinical oral manifestations of HIV infection: a review. *Int. J of Oral Maxillofacial surg.*; 16: 1-14.



- [82] Schiodt M, BakilanaPB, Haza FR (1990): Oral candidiasis and hairy leukoplakia correlate with HIV infection. *Oral Surg Oral Med Oral Pathol* 69:591-596.
- [83] Schmidt- Westhausen AM, Priepe F, Bergman FJ, Riechart PA (2000): Decline in the rate of Oral opportunistic infections following introduction of HAART. *J. Oral Pathol /Med*; 29: 336-341.
- [84] Scully C, McCarthy G (1992): Management of oral health in persons with HIV infection. *Oral Surg Oral Med Oral Pathol*; 73: 215-225.
- [85] Septowitz KA (1998): Effect of HAART on natural history of AIDS- related opportunistic disorders. *Lancet* 351: 228-230.
- [86] Silverman S Jr, Migliorati CA, Lozada-Nur F, Greenspan D, Conant MA (1986): Oral findings in people with or at high risk for AIDS: a study of 375 homosexual males. *J Am Dent Assoc*; 112: 187-192.
- [87] Sirois DA (1998): Oral Manifestation of HIV disease. 65:322-332
- [88] Slots J (2004): Update on human cytomegalovirus in destructive periodontal diseases. *Oral Microbiol Immunol*; 19:217.
- [89] Smith DE, Midgley J, Allan M (1991): Itraconazole versus ketaconazole in the treatment of oral and oesophageal candidiasis in patients infected with HIV. *AIDS*; 5:1367-71.
- [90] Smith GLF, Felix DH, Wray D (1993): Current classification of HIV-associated periodontal diseases. *Br Dent J*; 174: 102-105.
- [91] Soberman N, Leonidas JC, Berdon WE, (1991): Parotid enlargement in children seropositive for human immunodeficiency virus: imaging findings. *AJR*;157: 553-6.
- [92] Soubry R, Taelman H, Banyangiliki V et al (1995): Necrotising periodontal disease in HIV-1 infected patients: a 4 year study. In: Greenspan JS, Greenspan D, eds. *Oral manifestations of HIV infection*. Quintessence Publishing Co, Inc., Chicago,; 60-67.
- [93] Sturzl M, Konrad A, Alkharsah KR, Jochmann R, Mathias T et al (2009): The contribution of systems biology and reverse genetics to the understanding of kaposi's sarcoma-associated herpes virus pathogenesis in endothelial cells. *Thomb. Haematol*; 102: 1117-1134.
- [94] Swango PA, Kleinman DV, Konzelman JL(1991): HIV and periodontal Health: a study of military personnel with HIV J. *Am Dent Assoc*. 122 (8): 49-54.
- [95] Taiwo O, Okeke EN, Jalo PH, Danfillo IS (2006): Oral manifestation of HIV in Plateau state indigenes, Nigeria. *West Afr. J. Med.* (1): 32-37.
- [96] Taiwo O, Okeke EN, Otoh EC, Danfillo IS (2005): Prevalence of HIV- related oral lesions in Nigerian women. *Nig J. Med*; 14: 132-136.
- [97] Tappero JW, Conant MA, Wolfe SF (1993): Kaposi's sarcoma. *J Am Acad. Dermatol*; 28: 371-395.

- [98] Tappuni AR, Fleming GJ (2001): The effect of antiretroviral therapy on the prevalence of oral manifestations in HIV-infected patients: a UK study. *Oral Surg Oral Med Oral Pathol Oral Radiol Endod* 92:623–628.
- [99] Tukutuku K, Muyembe – Tamfum L, Kayembe K (1990): Oral manifestation of AIDS in a heterosexual population in a Zaire hospital. *J Oral Pathol Med* 19: 232-234.
- [100] Umezudike KA, Savage KO, Ayanbadejo PO, Akanmu AS (2011a) Severe presentation of Necrotizing Ulcerative Periodontitis in a Nigerian HIV Positive Patient- A Case report. *Med Princ Pract.* 20:374-376.
- [101] Umezudike KA, Savage KO, Ayanbadejo PO, Akanmu AS (2011b): Greater severity of periodontitis among HIV Positive Patients in Nigeria. *J Dent Res* 90 (Spec Iss B) 152991 AMER, [www.dentalresearch.org](http://www.dentalresearch.org)
- [102] UNAIDS: Joint United Nations Programme on HIV/AIDS (2010): Epidemiologic fact sheet on HIV and AIDS. [www.UNAIDS.org](http://www.UNAIDS.org)
- [103] Velegraki A, Nicolatou O, Theodoridou M et al (1999): Paediatric AIDS-related linear gingival erythema; a form of erythematous candidiasis? *J Oral Pathol Med*; 28: 178.
- [104] Weinert M, Grimes RM, Lynch DP (1996): Oral manifestation of HIV infection. *J Dent* 125; 6:485-496.
- [105] Williams CA, Winkler JR, Grassi M, Murray PA. (1990): HIV-associated periodontitis complicated by necrotizing stomatitis. *Oral Surg Oral Med Oral Pathol Oral Radiol Endod* 69:351-355.
- [106] Winkler JR, Murray PA (1987): A potential intra-oral expression of AIDS may be rapidly progressive periodontitis. *Journal of the California Dental Association*; 15:20
- [107] Winkler JR, Grassi M, Murray PA (1988): Clinical description and aetiology of HIV-associated periodontal disease. In: *Oral manifestations of AIDS. Proceedings of 1st. international symposium on oral manifestations.* AIDS eds. Robertson PB and Greenspan JS. 49-70.
- [108] Winkler JR, Robertson PB (1992): Periodontal diseases associated with HIV infection *Oral Med Oral Pathol*; 73: 145-150..
- [109] Wright AA, Agbelusi GA (2005): Group II and III lesions in HIV positive Nigerians attending the general Hospital Lagos, Nigeria. *Odonto- Stomatologie Tropicale*; 112: 19- 23.
- [110] Yeung SCH, Stewart GJ, Cooper DA, Sindhusake D (1993): Progression of periodontal disease in HIV seropositive patients. *J. Periodontol*; 64: 651-657.