

---

# Ventricular Arrhythmias and Myocardial Revascularization

---

Rainer Moosdorf

Additional information is available at the end of the chapter

<http://dx.doi.org/10.5772/54694>

---

## 1. Introduction

Ventricular arrhythmias are closely associated with myocardial ischemia and its sequelae. Acute ischemia frequently leads to ventricular fibrillation (Vfib) and to sudden cardiac death. As well, chronic ischemia, if presented as ischemic cardiomyopathy with restricted left ventricular function, is prone to the risk of Vfib. In contrast, scar formation after myocardial infarction leads to reentry circuits as an origin of ventricular tachycardia (Vt).

## 2. Pathophysiology

One of the typical complications of acute myocardial ischemia respectively myocardial infarction is ventricular fibrillation. Ischemic cells lose their membrane stability and a compound of such ischemic cells may cause electrical instability. Revascularization, if in time, restores cellular function and leads to electrical restabilization. One has to be aware however, that the so called reperfusion injury in the early phase after revascularization may also cause ventricular arrhythmias.

Chronic ischemia with a significant reduction of left ventricular function, the so called ischemic cardiomyopathy, is also prone to ventricular fibrillation and also in these patients revascularization may lead to a risk reduction by an improvement of the myocardial function and left ventricular ejection fraction.

If a myocardial infarction has happened, tissue is irreversibly damaged and replaced by scar. The center of this postinfarct scar is homogenous, but the border zone to vital myocardium is not linear but shows irregular interdigitations between the two tissues. Within this inhomogenous

borderzone, reentry circuits may induce ventricular tachycardia, which is not influenced by reperfusion(1).

### **3. Surgical treatment options**

If a myocardial infarction has led to a scar, no matter to what extent, reentry circuits may be induced and lead to VT's. Early surgical treatments were performed in cases of major scars, so called ventricular aneurysms, which were resected (2,3) and within the same procedure, deep encircling incisions of different extent should isolate the electrically unstable border zone from the remaining ventricle (4,5). With the introduction of electrophysiological investigations, the origin of such reentry circuits along the border zone was localized and an endocardial resection of this focus performed (6,7,8,9,10,11). However recurrent VT's were observed frequently after these procedures, oftentimes different from the primary clinical and also electrophysiological presentation. Experimental studies could demonstrate epicardial sites as origins of these recurrences, which could of course not be reached by endocardial resections (12).

### **4. Mapping guided laser photocoagulation**

The search for different treatment options finally led to the introduction of laser energy into this type of cardiac surgery (13,14,15,16,17,18,19). Using a conventional Nd-Yag laser and a gas cooled fiber for energy transmission, deep photocoagulations of the diseased tissue can be performed. Tissue is not removed or ablated in the original sense, but the structural integrity of the laser area remains intact. This deep photocoagulation creates a homogenous kind of scar and stops the reentry circuit. This kind of treatment is not limited to the endocardium but can also be applied to the epicardial surface after an electrophysiological mapping.

Consequently, mapping was no longer limited to the endocardium after resection of an aneurysm, but was extended to the epicardial surface during the same procedure (18). By this combination, recurrences could be significantly reduced.

Moreover, in cases of only small scar areas and without an aneurysm as access to the left ventricle, our group, together with the pioneering group of Svenson and Selle, performed the first cases of sole epicardial ablation, so to avoid a ventricular incision and further myocardial damage (20). Even with deep laser lesions, this limited access can of course not reach certain regions of the myocardium, especially the septum and the papillary muscles but we could still eliminate significant numbers of VT's in this special cohort of patients and avoid the implantation of an ICD.

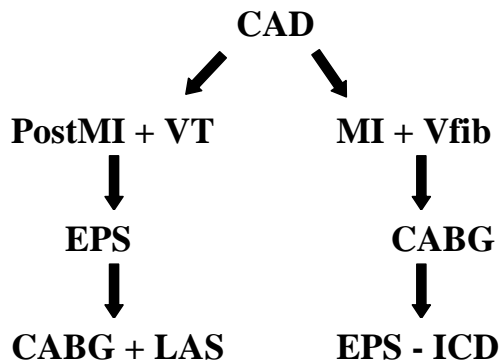
### **5. Treatment algorithm for patients with coronary artery disease and ventricular arrhythmias**

Patients with coronary artery disease and an indication for surgical revascularization, who also have experienced Vfib, receive coronary bypassgrafting alone. After surgery, the decision

for an ICD depends on the standardized criteria like reduced ejection fraction, incomplete revascularization or recurrent Vfib. In case of doubt, an electrophysiological investigation should be considered.

Patients with coronary artery disease and a status post infarct, who have experienced already a VT, are scheduled for a combined procedure of bypass grafting and VT-surgery. If the VT is documented in the charts, no further testing is necessary. If a reliable record is missing, an electrophysiological testing should be performed. The lack of major scar or an aneurysm is no exclusion criterion, in these cases a sole epicardial procedure is scheduled and the patient has to be informed about the lower cure rate because of the limited access.

Anyway, a sole revascularization with or without aneurysm resection, is an incomplete therapeutic approach. Patients, who need a surgical revascularization and/or an aneurysm resection and ventricular restoration, should also be offered a curative therapy of their ventricular arrhythmia. Without a directed ablation, a disappearance of the VT can not be expected and the implantation of an ICD is only palliative! Surgery should be curative if ever possible.



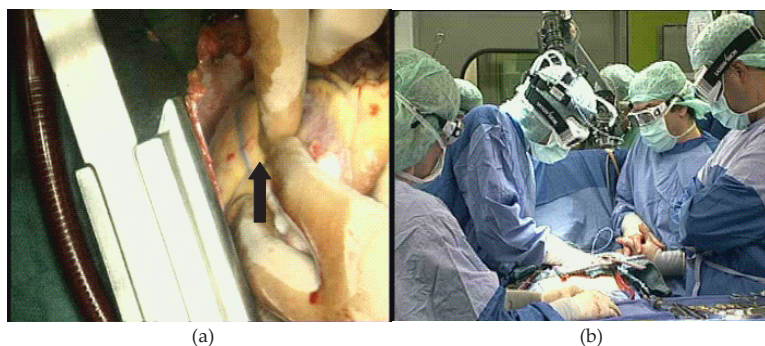**Figure 1.** Treatment algorithm (CAD:coronary artery disease, MI:myocardial infarction, EPS:electrophysiological study, CABG:coronary artery bypass grafting, LAS:laser arrhythmia surgery, ICD implantable cardioverter defibrillator)

## 6. The surgical procedure

The procedure is performed via a median sternotomy and after establishing extracorporeal circulation and placing pacing wires on the surface of the right ventricle, the left ventricle is opened through the aneurysm and blood is evacuated by a vent, which is inserted via the right upper pulmonary vein as usual. It is important however to maintain a sufficiently high flow of the extracorporeal circulation to keep the aortic valve closed and to avoid an air embolism. After inspection of the ventricular cave and definition of the resection lines, the VT is induced with the epicardial electrodes and mapping is performed with a small finger electrode.

Whenever a typical early potential is detected by the electrophysiologist, lasing is performed with the gas cooled fiber kept at a distance of approximately 5mm away from the tissue. So a sufficiently deep lesion can be created without removal of tissue and destruction of the structural integrity of the myocardium. Laser application is terminated after the VT stops and sinus rhythm reoccures. This procedure is repeated on the endo- and afterwards on the epicardium, until no further VT is inducible. After that, surgery is continued in the normal fashion with the definitive aneurysm resection, ventricular restoration and bypass surgery.

If no aneurysm is present, the ventricle is generally not opened but mapping guided laser photocoagulation only performed epicardially. If in these cases no further epicardial focus can be mapped but a VT, mostly different to the initial clinical recording, is still inducible, the procedure must be terminated without complete cure, as already described above. According to our very strict protocol, all these patients receive an ICD in a second intervention.



**Figure 2.** Intraoperative mapping with a small fingerprobe (a) and laser photocoagulation with protective goggles (b)

## 7. Postoperative protocol

Postoperatively, no antiarrhythmic drugs are given, except the standard medication with a beta-blocker. Before discharge, every patient is submitted to a final electrophysiological investigation with an aggressive stimulation protocol to induce an arrhythmia. The photocoagulation is only considered successful, if no ventricular arrhythmia can be induced including VT's different from the initial one or even Vfib. Patients with any type of inducible arrhythmia get an ICD before being discharged.

## 8. Results

Depending of course on the number of foci mapped and photocoagulated, the operative procedure is prolonged for about half an hour. The heart is not arrested during this time, so

that the arrhythmia surgery does not add to the ischemic time. In our hands, the risk of the procedure is not significantly increased. Table 2 shows the results of the initial 32 patients treated consecutively by our group at the University Hospitals Bonn and Marburg (17,20).

	Total (n=32)	Endo + Epi (n=20)	Epi (n=12)
Intraop. VT-term.	29	19	10
Postop. Ind. VT	5	1	4 (3)
Recurrent VT	5	0	5 (4)
ICD	6	0	6
Mortality (30 days)	3(9%)	2(10%)	1(8%)

**Table 1.** Results of 32 patients treated consecutively because of VT and severe coronary artery disease

One has to keep in mind, that all patients being treated endo- and epicardially for their VT were primarily referred because of severe coronary artery disease and large ventricular aneurysms, resulting in a severely reduced left ventricular function prior to surgery, so that the mortality is in accordance with the predicted mortality of this high risk group alone.

Among the group with sole epicardial photocoagulation, around 40% still had inducible VT's during the postoperative electrophysiological examination. Most of them were not identical with the initial clinical one. However, according to our protocol, they were registered as non successful and received an ICD. Still, 60 % of those formerly not curatively treatable patients could remain without ICD and among the remaining 40% with ICD's, shocks could be avoided or kept very rare, so that this limited access approach is also worth while being pursued.

## 9. Summary and message

In contrast to Vfib, Vt is in the vast majority of cases associated with a clearly defined patho-anatomical substrate, an inhomogenous interdentation of scar and vital myocardium in the border zone of a postinfarct scar, which is not affected by revascularization, but has to be addressed separately.

Revascularization alone will not lead to termination of Vt's, nor will sole resection of scar or an aneurysm be curative either, as the inhomogenous borderzone remains unaffected and may still trigger reentry circuits, which may be located subendocardially as well as subepicardially.

As a consequence, any patient with a documented VT and an indication for surgical revascularization and / or a ventricular restoration should also be submitted to an intraoperative VT ablation and be referred to specialized centers. A surgical intervention should always aim at curative result and ICD is very effective but is palliative!

## Author details

Rainer Moosdorf\*

Department for Cardiovascular Surgery, University Hospital Marburg, Marburg, Germany

## References

- [1] De Bakker, J. M, Coronel, R, Tasseron, S, Wilde, A. A, Opthof, T, Janse, M. J, Van Capelle, F. J, Becker, A. E, & Jambroes, G. Ventricular tachycardia in the infarcted, Langendorff-perfused human heart: role of the arrangement of surviving cardiac fibers. *J Am Coll Cardiol*, (1990). , 1594-607.
- [2] Welch, T. G, Fontana, M. E, & Vasco, J. S. Aneurysmectomy for recurrent ventricular tachyarrhythmias. *Am Heart J*, (1973). , 685-88.
- [3] Arnulf, G. Resistance and tolerance of myocardium in ischemia: experimental results. *J Cardiovasc Surg (Torino)*, (1975). , 218-27.
- [4] Guiraudon, G, Fontain, G, Frank, R, Escande, G, Etievent, P, Vignes, R, Mattei, M. F, Cabrol, C, & Cabrol, A. Circular exclusion ventriculotomy. Surgical treatment of ventricular tachycardia following myocardial infarction. *Arch Mal Coeur Vaiss*, (1978). , 1255-62.
- [5] Schulte, H. D, Bircks, W, Ostermeyer, J, & Seipel, I. Surgery of life-threatening ventricular tachyarrhythmias associated with ventricular aneurysm. *Thorac Cardiovasc Surg*, (1979). , 124-27.
- [6] Josphson, ME, & Horowitz, . . Recurrent sustained ventricular tachycardia. 2. Endocardial mapping. *Circulation*, 1978, 57(3); 440-47
- [7] Ostermeyer, J, Breithart, G, Kolvenbach, R, Borggreffe, M, Seipel, L, Schulte, H. D, & Bircks, W. The surgical treatment of ventricular tachycardias. Simple aneurysmectomy versus electrophysiologically guided procedures. *J Thorac Cardiovasc Surg*, (1982). , 704-15.
- [8] Gallagher, J. J, Oldham, H. N, Wallace, A. G, Peter, R. H, & Kasell, J. Ventricular aneurysm with ventricular tachycardia. Report of a case with epicardial mapping and successful resection. *Am J Cardiol* (1975). , 696-700.
- [9] Fontain, G, Guiraudon, G, Frank, R, Gerbaux, A, Cousteau, J. P, Barrillon, A, Gay, J, Cabrol, C, & Facquet, J. Epicardial cartography and surgical treatment by simple ventriculotomy of certain resistant reentry ventricular tachycardias, *Arch Mal Coeur Vaiss*, (1975). , 113-24.

- [10] Cox, J. L, Gallagher, J. J, & Ungerleider, R. M. Encircling endocardial ventriculotomy for refractory ischemic ventricular tachycardia. IV. Clinical indication, surgical technique, mechanism of action, and results. *J Thorac Cardiovasc Surg*, (1982). , 865-72.
- [11] Fontain, G, Guiraudon, G, Frank, R, Vedel, J, Cabrol, C, & Grosogeat, Y. The concept of reentry in the surgical treatment of ventricular tachycardia. *Ann Med Interne (Paris)*, (1978). , 413-17.
- [12] Littmann, L, Svenson, R. H, Gallagher, J. J, Selle, J. G, Zimmern, S. H, Fedor, J. M, & Colavita, P. G. Functional role of the epicardium in postinfarction ventricular tachycardia. Observations derived from computerized epicardial activation mapping, entrainment and epicardial laser photoablation. *Circulation* (1991). , 1577-91.
- [13] Littmann, L, Svenson, R. H, Gallagher, J. J, & Selle, J. G. High grade entrance and exit block in an area of healed myocardial infarction associated with ventricular tachycardia with successful laser photoablation of the anatomic substrate. *Am J Cardiol*, (1989). , 122-24.
- [14] Cox, J. L. Laser photoablation for the treatment of refractory ventricular tachycardia and endocardial fibroelastosis. *Ann Thorac Surg*, (1985). , 199-200.
- [15] Mesnildrey, P, Laborde, F, Beloucif, F, Mavolini, P, & Piwnica, A. Ventricular tachycardia of ischemic origin. Surgical treatment by encircling thermo- exclusion using the Nd-Yag laser. *Presse Med*, (1986). , 531-34.
- [16] Svenson, R. H, Gallagher, J. J, Selle, J. G, Zimmern, S. H, Fedor, J. M, & Robicsek, F. Neodymium:Yag laser photocoagulation: a successful new map guided technique for the intraoperative ablation of ventricular tachycardia, *Circulation*, (1987). , 1319-28.
- [17] Moosdorf, R, Pfeiffer, D, Schneider, C, & Jung, W. Intraoperative laser photocoagulation of ventricular tachycardia. *Am Heart J*, (1994). pt2); , 1133-38.
- [18] Svenson, R. H, Littmann, L, Gallagher, J. J, Selle, J. G, Zimmern, S. H, Fedor, J. M, & Colavita, P. G. Termination of ventricular tachycardia with epicardial laser photocoagulation: a clinical comparison with patients undergoing successful endocardial photocoagulation alone. *J Am Coll Cardiol*, (1990). , 163-70.
- [19] Isner JmEstes NA, Payne DD, Rastegar H, Clarke RH, Cleveland RJ. Laser assisted endocardiotomy for refractory ventricular tachyarrhythmias. *Clin Cardiol* (1987). , 201-4.
- [20] Pfeiffer, D, Moosdorf, R, Svenson, R. H, Littmann, L, Grimm, W, Kirchhoff, P. G, & Lüderitz, B. Epicardial Neodymium:Yag laser photocoagulation of ventricular tachycardia without ventriculotomy in patients after myocardial infarction. *Circulation*, (1996). , 3221-25.

