
Imaging in Kidney Transplantation

Valdair Francisco Muglia, Sara Reis Teixeira,
Elen Almeida Romão, Marcelo Ferreira Cassini,
Murilo Ferreira de Andrade, Mery Kato,
Maria Estela Papini Nardin and Silvio Tucci Jr

Additional information is available at the end of the chapter

<http://dx.doi.org/10.5772/55074>

1. Introduction

At the end-stage of renal failure, the best option for treatment is kidney transplantation, before starting any form of dialysis. The scarcity of organs from cadaveric donors and the comorbidity of the receptors patients, delay this treatment from being routinely performed prior to dialysis. Living-donor kidney transplantation can meet this objective perfectly, since it does not depend on waiting lists imposed by cadaveric donation [1]. In recent years, the expansion of genetically unrelated living donation has facilitated living-donor kidney transplantation as spouses, distant relatives, and even good friends have increased the pool of potential living donors. The living-donor transplants offer better survival than those of cadaveric-donor transplants, despite of HLA compatibility [2, 3].

For cadaver's donors, cause of brain death, age, plasma levels of creatinine and hemodynamic stability are the main factors for evaluating a potential donor. In contradistinction, the imaging methods constitute the initial assessment of the living donor in the kidney transplantation, with special attention to the kidneys (size, structure, lithiasis, arterial blood flow) and pelvis anatomy. The abdominal Color Doppler ultrasound, computed tomography (CT), selective kidney arteriography and Magnetic Resonance (MR) with three-dimensional reconstruction and excretory phase study provide an anatomical assessment of the arterial vascularization (identification of the main artery, accessory or aberrant arteries or early divisions) of the venous system (number, situation, size and anatomic abnormalities) and the kidney parenchyma with the variations of collecting duct system, helping to choose the most appropriate organ to be removed [4, 5].

In the postoperative phase, many kinds of images methods (ultrasound, scintigraphy, CT and MR) may help in early diagnosis of complications, as described below. In this chapter we review the usual image evaluation techniques in kidney transplantation.

2. Imaging methods

2.1. Ultrasonography

Ultrasonography (US) is the first choice for evaluating kidney allograft either in acute, immediate post-transplantation period or in the long-term follow-up [6, 7]. US is non-invasive, innocuous and due to its availability has a key role when assessing complications of any nature in renal transplants. As the transplanted kidney usually lies in a superficial position in the iliac fossa, it is possible to use high-frequency transducers enabling images of high spatial resolution. In addition, the ability of Color Doppler (CD) and Power Doppler (PD) to investigate blood flow helps to make the diagnosis of the most common functional complications as rejection acute tubular necrosis [8, 9].

2.2. Magnetic resonance imaging

When additional imaging is required, generally because the sonographic findings were indeterminate, Magnetic Resonance Imaging (MRI) emerges as the problem-solving method in kidney transplantation [10, 11]. MRI has several advantages when compared to Computed Tomography (CT); it has no ionizing radiation and the main contraindication to this method is the use of cardiac pacemakers. MRI has the highest contrast resolution among all imaging methods and is able to produce angiographic images (MR angiography) without the use of contrast media. And, when necessary the contrast media for MRI, Gadolinium-based salts, are safer than iodinated contrast media used in CT [12, 13]. In addition, the MRI technique to study the collecting system based on T2-weighted images, MR urography, has been used as an alternative to intravenous urography (IVU) and CT [14].

After initial concern about the possible relation between gadolinium salts and Systemic Nephrogenic Fibrosis [15, 16], there is a consensus that some Gadolinium-based contrast media (GBCM), more stable, may be used in patients with depressed renal function, as long as recommendations regarding type and doses of contrast media were respected [17, 18]. The only absolute contraindication that still persists for GBCM is patients in a regular scheme of peritoneal dialysis [18].

2.3. Computed Tomography

Computed Tomography (CT) is scarcely used to evaluate kidney transplants, because MRI covers all the possible indications for CT, without ionizing radiation and the use of nephrotoxic contrast media [19]. Although CT angiography has great spatial resolution, this technique should be avoided whenever possible, due to the potential nephrotoxicity of iodinated

contrast. CT will play a major role for evaluation potential donors for living transplantation as will be described later on in this chapter [20].

2.4. Digital Subtraction Angiography

Digital Subtraction Angiography (DSA) was commonly used to investigate vascular complications, e.g. renal artery transplant stenosis, suspected by US and is still considered the gold standard for such diagnoses [7, 21]. However, nowadays, with the possibility of using non-invasive methods with high accuracy for diagnosing vascular complications, such as MR angiography, DSA is practically reserved for therapeutic purposes only. The ability to guide minimally invasive procedures, as angioplasty and stenting of vascular stenosis makes DSA the ideal method to assess post-transplant patients avoiding more aggressive surgical procedures [21].

3. Radionuclides imaging

Functional imaging methods based on nuclear medicine, such as the dynamic renal study which use glomerular filtration agents and tubular secretion agents, are useful and routinely used tools for evaluation of renal transplants. Glomerular agents (^{99m}Tc -DTPA) are considered to be ideal ones, since glomerular filtration is defined as the main reflex of renal function and their mechanism of extraction occur through the process of ultrafiltration driven by Starling forces in the glomeruli. The most important regulatory mechanisms in glomerular filtration are renal blood flow and the peripheral vascular resistance of afferent and efferent glomerular arterioles. The normal distribution of these renal agents is intravascular, and they are elimi-




Figure 1. DTPA renal scintigraphy. Phase of preserved arterial blood flow.

nated by the renal parenchyma and excreted through the urinary pathways. The acquisition protocol involves the capture of sequential images within a short time interval immediately after the venous administration of the glomerular agent, providing information about renal perfusion (Figure 1), and of sequential images over a more prolonged period of time in order to obtain information about glomerular filtration and urine formation (Figure 2A). Semiquantitative analysis is performed based on the curves of the radioisotope renogram. These curves are obtained by drawing areas of interest in the kidneys and then tracing time count curves (Figure 2B).

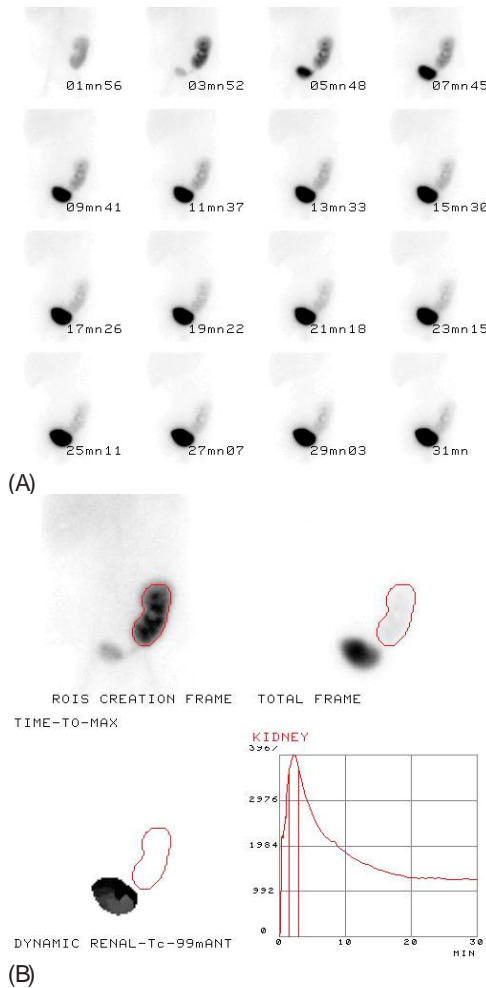


Figure 2. (A) and (B): ^{99m}Tc-DTPA renal scintigraphy. Normal functional phase and renographic curve.

4. Post-transplant evaluation

4.1. Normal

Imaging methods are frequently used in patients with kidney transplantation, even when clinical parameters and laboratorial tests indicate a good evolution. As US is very sensitive, innocuous, and largely available, most of centers for renal transplantation include, at least, one US exam in the immediate post-transplant period to detect possible subtle complications that otherwise could remain undetected until more severe symptoms [6, 22]. As mentioned early, US is performed with high frequency transducers, using scanners with Color and Power Doppler techniques.

The appearance of transplant kidney is quite similar to the native ones. But, in the immediate post-transplant period a mild dilatation of collecting system is expected due to hipotony (Figure 3), and edema in ureteral anastomosis [22]. A detailed examination is performed and, not rarely, incidental findings as kidney stones, cysts or small angiomyolipomas may be detected in first post-surgical examination. Besides, a careful search for perinephric collections is performed and CD and PD used for evaluation of vascular anastomosis. The renal transplant artery is usually anastomosed to the donor external iliac artery in an end-to-side way. Occasionally, the artery may be anastomosed in an end-to-end way to the internal iliac artery. The donor renal vein is anastomosed in an end-to-side way to the donor's external iliac vein [23].

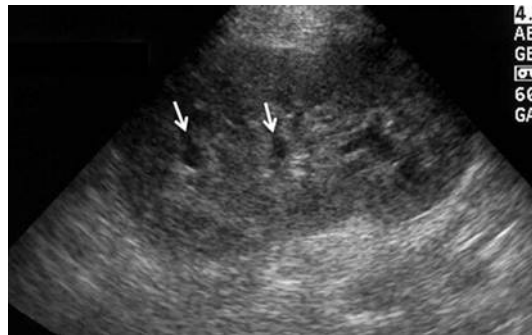


Figure 3. Normal sonographic appearance of a renal allograft in the immediate post-transplant period. Notice the mild dilatation of calyceal system (arrows).

5. Complications

Complications related to the graft following a renal transplant can be didactically divided into medical complications (MC), urological complications (UC) including fluid collections (FC), and vascular complications (VC). Neoplasms (NEO), and recurrent native renal disease are

also complications that can occur but in minor incidence. The most common complications of renal transplantation are discussed below and listed in Table 1.

5.1. Medical complications

In the early post-transplant period, delayed graft function (DGF) occurs when the decline of the serum creatinine concentration is slower than wanted. The most common medical complications (MC) related to DGF are acute tubular necrosis (ATN), drug toxicity (mainly caused by calcineurin inhibitors - CNI), and rejection. In general, imaging tools in evaluating MC following renal transplantation are non-specific [24-26]. The major role of imaging in this setting is to exclude urologic, collections, and/or vascular complications. To date, quantitative criteria for the diagnosis of acute graft dysfunction with MR renography or nuclear medicine have not been adequately standardized. Promising techniques, especially using quantitative and functional MRI are objects of interest in this field [14, 27, 28].

5.1.1. Acute Tubular Necrosis (ATN)

ATN is the most common cause of DGF, defined as need for dialysis in the first week following transplantation. It is related to the cold ischemic time [29] and infrequently seen in patients whose transplants are from living donors [30, 31]. ATN occurs in the first days following transplantation, even in the first hours. Renal function usually recovers within 1-2 weeks, but can last abnormal up to 3 months [19, 31].

There is no imaging specific pattern for the diagnosis of ATN [10, 32]. Images can be completely normal depending on the severity of injury [33-35]. US can reveal swollen and globular kidneys, with increasing corticomedullary differentiation (CMD) [26]. The cortex is brightly echogenic, swollen, rendering medullary pyramids very prominent and compressing fat in the renal sinus. An elevated Resistance Index (RI > 0,80) measured in the intra-renal arteries is considered to be a non-specific marker of graft dysfunction, seen on both, ATN and rejection [8, 32, 36-40]. Serial measurements of RI and Pulsatile index (PI) combined with clinical and biochemical information is useful in monitoring the patient [31, 39]. At MRI, CMD tends to be preserved [41]. Dynamic functional MRI and perfusion show slightly delayed medullary enhancement, and markedly impaired contrast excretion [42, 43]. CT demonstrates decreased graft enhancement, eventually with no contrast media excretion [19].

With radionuclide imaging (iodine-131 orthoiodohippurate and Tc-99m MAG3), the most conspicuous findings are delayed transit with delayed time to maximal activity (T-max), delayed time from maximum to one-half maximal activity (T-1/2), and a high 20 to 3 minute ratio. On sequential images, marked parenchymal retention is seen [44, 45]. (Figure 4).

5.1.2. Rejection

Rejection can be classified according to the period of appearance as hyperacute (occurring within minutes), acute (occurring within days to weeks), late acute (occurring after 3 months), or chronic (occurring months to years after transplantation) [46]. When hyperacute rejection happens, graft dysfunction is usually irreversible. The humoral reaction of the patient leads

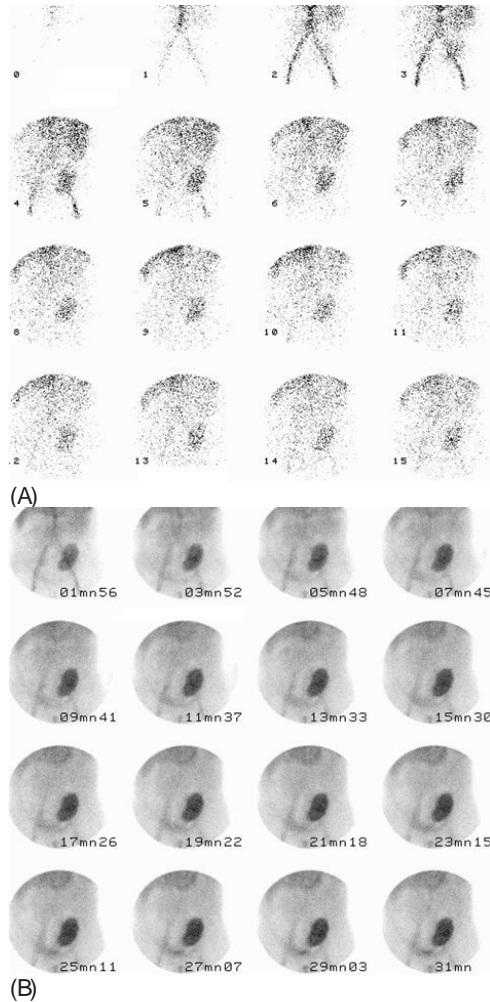


Figure 4. (A) and (B): ^{99m}Tc -DTPA renal scintigraphy. Postoperative period of 48 hours. Preserved arterial blood flow and glomerular function deficit, with minor urine formation during the study.

to a severe vascular lesion and to cortical necrosis. Imaging does not play any role. Absence of perfusion will be seen in Doppler, angiography or scintigrams [10]. Accelerated acute rejection occurs within the first week. The imaging features are the same as of acute rejection (AR). Cortical nephrocalcinosis may be seen in rejected transplants left in situ [10, 47].

Currently, the overall risk of acute rejection within 1 year after transplantation is less than 15% [46]. AR can be divided in acute-antibody mediated rejection and T-cell-mediated rejection. Acute-antibody mediated rejection is characterized by a rapid graft dysfunction due to inflammation. T-cell-mediated rejection can also present as an increasing creatinine level and

diminished urinary output. Fever and graft tenderness now rarely occur. As mentioned before, imaging in AR is non-specific. Imaging findings superpose with other conditions such as ATN, drug nephrotoxicity, UC, and VC. The sonographic features are similar to those described for ATN [10, 33]. They include renal enlargement, heterogeneity of renal cortex, loss, increase or decrease of CMD, hypoechogenicity of renal pyramids, cortex and sinus, thickening of renal cortex and thickening of the walls of collecting system (figure 5). Although both ATN and AR cause PI and RI rise on Doppler US, the likelihood of AR is greater with high values [31]. An elevated RI ($>0,9$) is highly suggestive of AR, but is not specific [32, 36-38, 48, 49]. A PI of more than 1.5 is used in some centers for helping diagnosing rejection. Radionuclide studies show decreased renal perfusion and function [45, 50]. If the isotope study is normal in early post-operative phase and becomes abnormal subsequently, acute rejection can be diagnosed. MR findings are variable and include various degrees of swelling, globular morphology with indistinct margins of the graft, decrease or loss of the CMD are common findings [10, 14, 19, 28, 31]. Perfusion abnormalities are seen in contrast enhanced scans with marked decreased cortex and medulla enhancement, prolonged arterial phase, poor wash-out and patchy nephrogram [10, 14, 24, 28] (Figure 6).

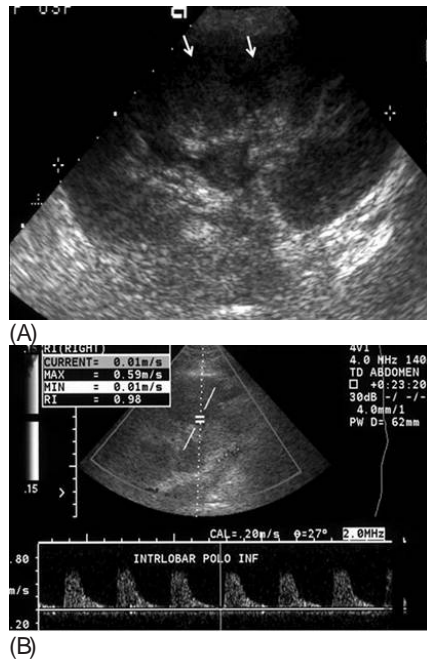


Figure 5. (A) Acute rejection, longitudinal scan. The cortex is swollen, extending into the renal sinus and compressing the fat. Medullary pyramids are prominent (arrows), indicative of an increase in cortical echogenicity. (B) Spectral Doppler shows a RI $> 0,90$ highly suggestive of AR.

Chronic rejection (CR) occurs after at least 3 months to years after transplantation. It happens due to an insufficient immunosuppression to control residual antigraft lymphocytes

and antibodies. It presents as a progressive decline in renal function [46] and may be difficult to diagnose by a non-invasive techniques. RI measurements are not reliable for this diagnosis [24, 38, 40]. Initially, the graft is enlarged and shows increased cortical thickness, which later changes to a thin cortex and mild hydronephrosis on both US, CT, and MRI [19, 50] [28, 33]. A diminished uptake of radiopharmaceuticals and also a normal parenchymal transit with absent or minimal cortical retention is seen in scintigraphy studies. In advanced stages, parenchymal retention of radiotracers is present [45].

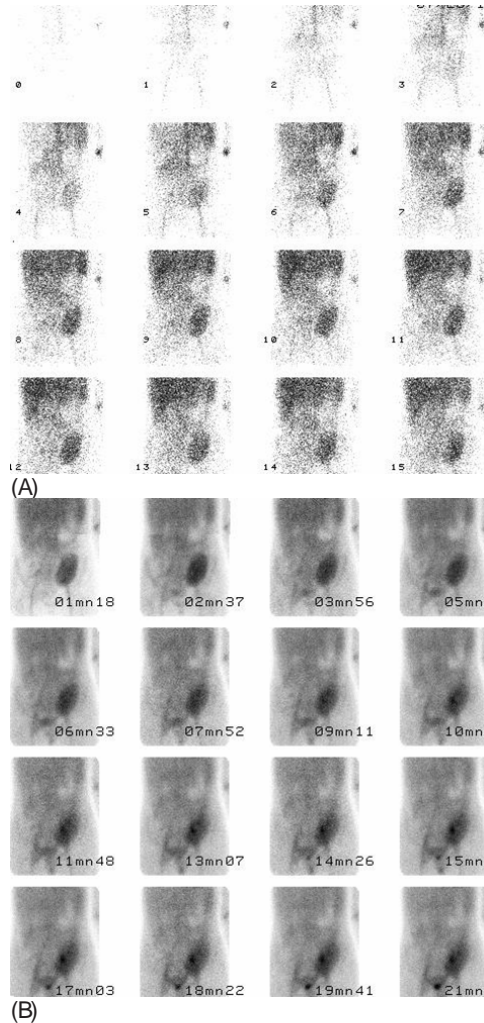


Figure 6. (A) and (B): ^{99m}Tc -DTPA renal scintigraphy. Two week follow up. Depressed arterial blood flow of a discrete degree and glomerular function deficit of moderate degree

5.1.3. Calcineurin Inhibitors (CNI) nephrotoxicity

CNI can cause renal vasoconstriction with ischemia. CNI toxicity is caused by afferent arteriolar vasoconstriction followed by a decrease in glomerular perfusion pressure and also by a tubulointerstitial injury independently from its vascular effects [51]. These physiological effects are similar between cyclosporine and tacrolimus. Monitoring the CNI serum levels is important to prevent the occurrence of nephrotoxicity and, on the other hand, to achieve the appropriate immunosuppression. Moreover, nephrotoxicity of these drugs not related to their serum levels are described [52, 53].

When DGF occurs many experts prefer do not use CNI due to their possible detrimental effects in the ischemic damaged kidneys [54]. When creatinine level stabilizes without complete renal function recovery or when renal function deterioration occurs, a renal biopsy should be performed. Currently, no clinical findings are specific enough to differentiate allograft rejection from CNI nephrotoxicity. Imaging findings are also non-specific and superimposed with the other parenchymal complications. Cyclosporine toxicity may produce an enlarged kidney with increased cortical echogenicity and prominent medullary pyramids. On radio-nuclide images, acute cyclosporine toxicity resembles mild acute rejection, with depressed effective renal plasma flow and parenchymal retention [22, 45] Loss of the corticomedullary differentiation can be seen on MRI [55]. Findings should be correlated with cyclosporine levels. Sustained increasing in RI values (Figure 7), without a morphologic cause such as hydronephrosis, is indicative of graft dysfunction, but it's non-specific and may be caused by acute or chronic rejection, ATN, or cyclosporine toxicity [56].

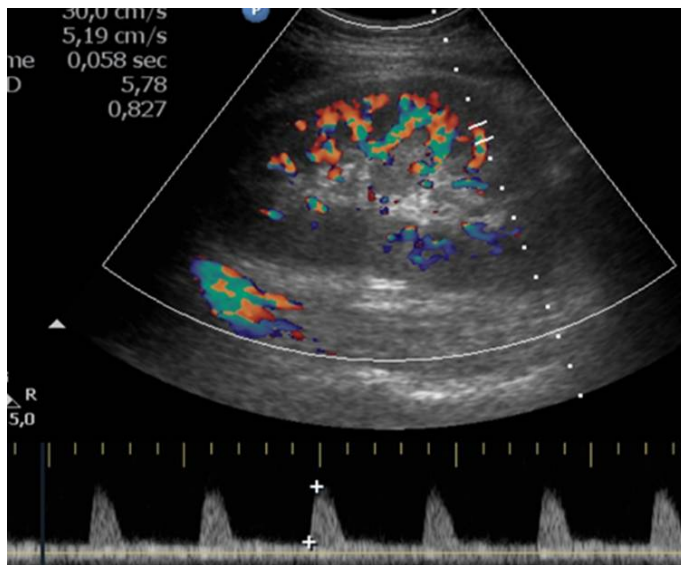


Figure 7. CNI toxicity. Spectral doppler evaluation with a mild elevation of RI.

To date, no imaging or laboratory test has been found accurate enough to discriminate the parenchymal causes of graft dysfunction and renal biopsy remains as the gold standard [22, 49, 50, 57].

5.2. Urological complications

The clinical setting of most UCs is that of a decrease in graft function. Because many of the complications are treatable, it is extremely important to make an early diagnosis and separate from rejection or ATN. The first reports concerning renal transplantation showed a prevalence of UC varying from 10% to 25%, with a mortality rate ranging from 20% to 30%. Nowadays, due to advances in immunosuppressive therapy combined with careful surgical technique the incidence of UC decreased, ranging from 1% to 8% [58, 59]. The majority of the UC are seen during the first month to six months after transplant. Ureteric obstruction and urine leak are the most common [22, 60].

5.2.1. Obstructive uropathy

The major causes of ureteral obstruction are ureteral ischemia, edema at the uretero-vesical anastomotic site, infection, extrinsic compression of the ureter by fluid collections, and ureteral kinking. Other relatively rare causes are stones, papillary necrosis, clots, fungi, pelvic fibrosis, and herniation of the ureter [61]. Early-onset obstruction of the ureter is secondary to kinks, clots, edema, inflammation, or a tight submucosal tunnel. Percutaneous treatment is the best treatment option. Late-onset obstruction is caused by fibrosis, ischemia, or periureteral masses or may be secondary to rejection [19]. The transplanted ureter is relatively prone to ischemia due to limited blood supply [22, 24, 50, 58]. A large majority of the ureteral strictures occur in the distal third of the ureter, usually secondary to ischemia [22, 58].

Sonography shows dilated renal pelvis and calyces and is useful to determine the site of ureteral obstruction (Figure 8). This is a nonspecific finding because it is also seen in cases of diminished ureteral tonus resulted from denervation of the transplant [62], mild dilated collecting system in rejection, vesico-ureteral reflux, and secondary to overdistended bladder. In the later condition, it's important to repeat the US with an empty bladder.

When highly echogenic, weakly shadowing masses are present in the collecting system, fungus balls should be considered, whereas low-level echoes may suggest pyonephrosis or hemonephrosis [63]. Other abnormalities of the collecting system include calculi and urothelial tumors. In some cases of acute obstruction an increased RI and PI may be present, however, again they are nonspecific findings [37, 64].

At Nuclear Medicine, in patients with early partial obstruction, good perfusion and prompt uptake of the radiotracer may be seen; however, in patients with functionally significant hydronephrosis, radioactivity is retained in the collecting system. Delayed images are useful for differentiating an obstructed ureter from a dilated but unobstructed ureter, since a non-obstructed system shows clearance into the bladder. Diuretic renography and conventional

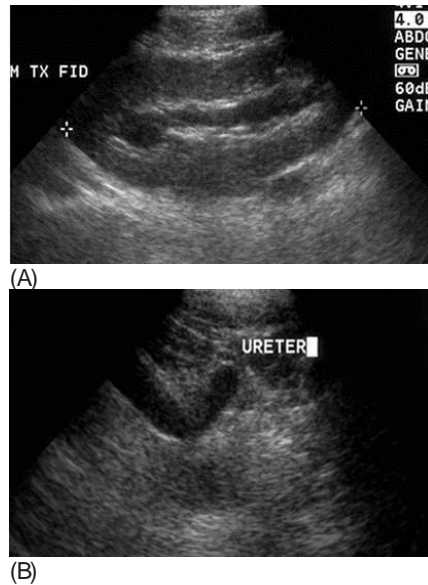


Figure 8. (A) and (B) - Mild hydronephrosis presumably, secondary to a tight submucosal tunnel.

clearance times can be used in the assessment of urinary tract patency [65]. The anterograde urography usually depicts the site of obstruction. The combination of normal results from the Whitaker test and anterograde pyelography virtually excludes the presence of obstruction [66]. If necessary, MDCT allows accurate imaging of the entire course of ureteral and periureteral diseases.

In pyelonephritis, diffuse thickening of the urothelium in the renal pelvis and proximal ureter may be seen, but it's also seen in rejection. At MRI, an absent renal fat sinus and decrease in corticomedullary differentiation, along with striated nephrogram and multiple nonenhancing, round foci in the transplant renal parenchyma are the most frequent signs [43, 67].

Renal stones may either form in the transplant kidney or be incidentally carried from the donor kidney. Because the kidney and ureter are denervated, these patients do not present with a typical colic pain. The incidence and risk factors for calculus are the same as for a native kidney [10], in some reports ranging from 0,4% to 1,0% [68]. Lithiasis can lead to further complications such as obstruction or infection. Small stones are missed in plain films, since the transplant kidney overlies iliac bone. Unenhanced MDCT is the gold standard as can detect virtually 100% of stones.

Occasionally, gas may be seen in the collecting system, usually introduced from external sources, such as catheter or occasionally from needle biopsy or, very rarely, from emphysematous pyelonephritis. Evaluation of the collecting system and bladder may also show an abnormal position or condition of the stent.

5.2.2. *Perirenal collections*

In the early post transplant period, it is common to see fluid collections around the kidney in up to 50% cases. Common post-transplant fluid collections include urinome, hematoma, seroma, lymphocele, and abscess [33, 58, 62]. Rarely, they lead to a graft dysfunction or a collecting system obstruction.

US is very useful to assess the presence and size of perinephric fluid collections; however, it is not very specific for further differentiation among different types of content. The post-transplant time interval may suggest the nature of collections. Fluid collections seen in the immediate postoperative period are usually hematomas or seromas [50]. All fluid collection are identified with US and although solid echoes or septations may suggest specific diagnosis, correlation with clinical findings helps to restrict differential diagnosis, occasionally puncture with biochemical analysis of the fluid are required to final diagnosis

5.2.2.1. *Urinome / urinary leak*

Urinome occurs in up to 6% of transplant recipients [69] in the first weeks post-transplantation. It is believed to be caused by disruption of the vesicoureteric anastomosis or ischemic injury of the distal ureter [24]. It is normally preceded by increased abdominal pain, reduction in urine volumes and sometimes, urine leakage from the wound.

US is essential in the evaluation of perirenal collections, including urinomes. It is the modality of choice for diagnosis and guiding puncture. A cystogram may show leakage from the bladder and an isotope scan is often helpful. These collections are expected to show increased activity on radionuclide MAG-3 (Tc99 mercaptoacetyltriglycine) scans while other fluid collections usually result in photopenic defects [33] (Figure 9). The appearance on US is of a homogeneous anechoic collection, with thin walls, usually without echoes (Figure 10). CT and MRI show a clear fluid collection. Diagnostic aspiration may be required to confirm the nature of the collection. A communication between the fluid collection and urinary tract is required for final diagnosis.

5.2.2.2. *Hematoma*

Hematomas are seen mostly in the early post operative period. The overall incidence of significant postoperative hematomas from renal transplant varies from 4 to 8% [70, 71]. They have a complex appearance, poorly defined wall with internal echoes (Figure 11 A and B). Clots and debris appear as dense areas in unenhanced CT scans. Ultrasound and CT define the collection, but differentiation from abscess is difficult. Radionuclide scans demonstrate photopenic collection adjacent to the kidney, which do not fill up in delayed images. MRI signal depends on the stage of hematoma. Aspiration and imaging guided drainage are performed.




Figure 9. Anomalous accumulation of the glomerular agent (^{99m}Tc -DTPA) above the renal pole compatible with a urinoma. ^{99m}Tc -DTPA image showing accumulation of activity (arrow) outside the area of the kidney, ureter and bladder indicating urinary leakage.

5.2.2.3. Abscess

Abscess can be a complication of surgery, pyelonephritis or secondary to infections, urinomas, hematomas or lymphoceles. It can occur any time during the post transplant period. The appearance is the same as a hematoma, i.e. a complex collection. Parenchymal abscess manifests as a well defined hypochoic mass on US, and nonenhancing, hypoattenuating collection on CT. On MR, it can show high signal intensity on DWI and peripheral enhancement after contrast media.

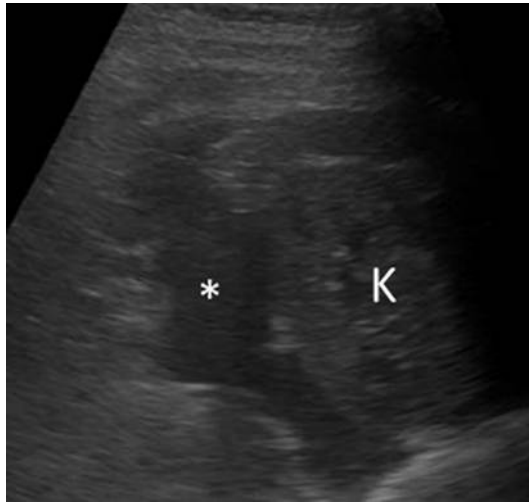

Figure 10. Urinoma. Gray-scale US shows a simple fluid collection around the kidney, anechoic (*). The biochemical analysis of the fluid after puncture revealed a high creatinine level.

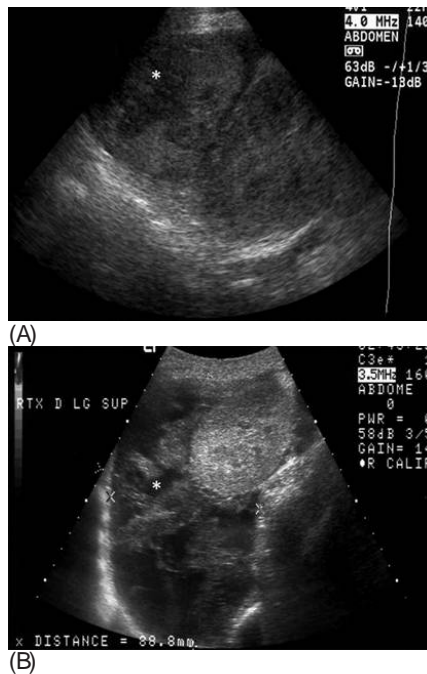

Figure 11. (A) Recent hematoma. Longitudinal US scan shows a complex, hyperechoic mass (*) around the graft. (B) Organizing hematoma. A complex collection (*) around the graft with hiper- and hypoechoic areas.

5.2.2.4. Lymphocele

Lymphoceles are lymph collection from the iliac lymphatic vessels of recipient or graft hilum that accumulates between the transplanted kidney and bladder. It results from surgical disruption of lymphatics and usually occur 4 to 8 weeks following transplantation [62, 70-72]. Usually these are small in size and asymptomatic; however, when large can cause hydro-nephrosis or lower extremity edema and may require drainage [33]. US shows an anechoic collection with fine septa within it, usually inferior to the region between the kidney and bladder (figure 12). Scintigraphy demonstrates a photopenic area which does not fill up with tracer on delayed images [73]. CT shows well defined round or oval collection of 0–20 HU. On MR images, an homogeneous and often minimal complex collection is depicted.

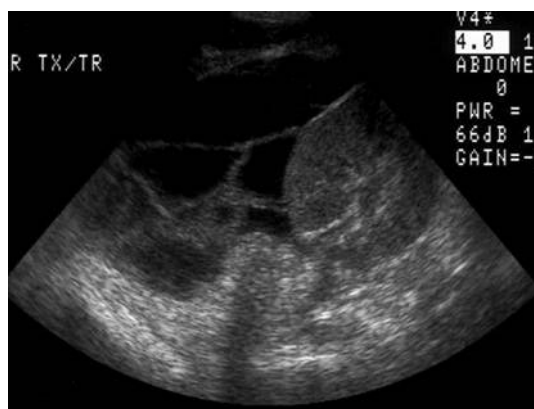

Figure 12. A minimal complex fluid collection around the graft extending to the pelvis, with fine septa, consistent with a lymphocele.

5.2.3. Vesicoureteral reflux

It seems to have a greater incidence in patients whom extravesical cystoureteral anastomosis was performed. However the clinical relevance is still not established, with a slightly increase in risk of infection. Cysto-uretrogram can easily make this diagnosis. Many technical modifications has been proposed to reduce the vesicoureteral reflux and urine leakage like modified Lich-Gregoir technic [74].

6. Other urological complications

- Ureteral necrosis: more common in the distal ureter and caused by a tight submucosal tunnel or vascular ischemia or rejection. It is a cause of urinary leak and is common in the first 6 months [75].

- Torsion: an extremely rare complication, more common in peritoneal location. It refers to rotation of the kidney transplant graft around its vascular pedicle resulting in vascular compromise and infarction [76]. On images the graft is with abnormal axis, enlarged, hypoechoic and with poor enhancement [77].
- Rupture: a rare complication of uncertain etiology. Biopsy, acute rejection, ATN, vascular occlusion, trauma, rejection, and renal cell cancer development are proposed etiologies [78-80]. Sonographic findings are extrarenal and subcapsular collections, laceration or hematomas within the perinephric space [79]. CT shows dense clot and perinephric collection. Radionuclide scans show photopenic defect. MR shows clots and an hemorrhagic perirenal collection.

6.1. Vascular complications

Vascular complications (VC) after renal transplantation are the most frequent type following urological complications, seen in less than 10% [81]. Early VC includes renal artery or vein thrombosis, lesions to the iliac vessels and cortical necrosis. Delayed complications mainly include renal artery stenosis, arteriovenous fistula and rarely pseudo-aneurysm. They have a high associated morbidity and mortality. Although DSA remains the gold standard for vascular complications, US with Doppler is the screening method for assessing blood supply of a kidney graft [49, 82]. MRI with angiography (MRA) has been used more often to confirm US diagnosis of vascular abnormalities in renal transplants [31]. With this combination, radionuclides are scarcely used to evaluate graft vascular complications.

6.1.1. Early vascular complications

Usually occurs in the first week post transplantation. Renal artery and vein thrombosis are generally related to the position of the graft, to a long vessel, to surgical techniques (anastomosis of the arteries), or to compression, e.g. hematoma compressing the renal vein. Renal vein thrombosis can also be secondary to extent of a thrombus in the iliac vein.

Arterial thrombosis is rare in the early transplant period. US and MRI show complete absence of flow in the main transplant renal artery and intrarenal arteries, no flow in the parenchyma with CD or PD (Figure. 13), and no parenchymal perfusion detectable at MRI. MRI can also demonstrate absence of renal artery enhancement. Occlusion of a lobar artery or a pedicle artery leads to a focal well-defined area of infarct, which consequences are dependent to the extension of this area [25]. In the ischemic area, the renal cortex has appearance of a wedge-based hypoechoic mass with echogenic walls, and no signal on CD [31]. MRI can better delimitate the zone of infarct. MRI and CT show a non-enhancing area with enhancing capsule. Scintigraphy may also be used to confirm arterial occlusion (Figure 14).

Renal vein thrombosis is a frequent cause of loss of the renal graft, occurring in 4-6% of the transplants in adults [83]. It's a difficult diagnosis because it begins in the venules within the renal parenchyma, and initially, large veins remain normal [84]. Characteristic features of renal vein thrombosis include a dilated transplanted renal vein containing a thrombus with absent venous flow (Figure 15); lack of venous outflow that causes a very high resistance to arterial

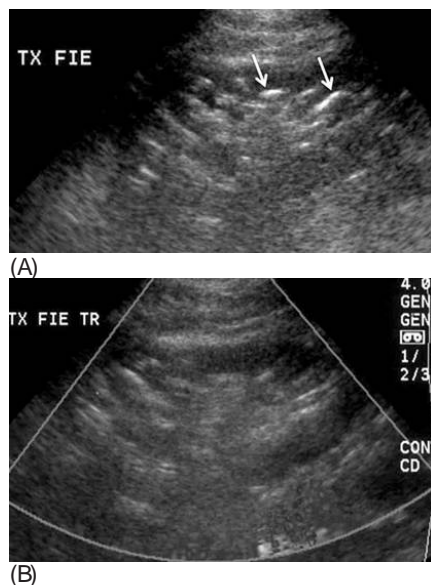


Figure 13. Acute renal artery thrombosis. (A) Gray-scale US shows gas within the collecting system (arrows). (B) Absence of signal at PD.

inflow; there may be no diastolic flow ($RI = 1$) or even diastolic flow reversal (Figure 16) [84]; absence of venous signals in the graft at CD or PD; decrease in the arterial sign at CD of the peripheral arteries [25]. These are non-specific findings, also present in ATN and rejection. Clinical and biochemical findings should take them apart. MRI can demonstrate the extent of the thrombus, but they must not delay the surgical approach.

6.1.2. Vascular thrombosis — Artery / vein

Lesions to the iliac or renal allograft vessels may occur during the transplantation and are associated with multiple arteries donors, anatomic variations, recipients atheromatosis, thrombophilia, obesity and other chronic diseases. They can lead to a non viable graft. Artery dissections, perforation, pseudoaneurysms, and thrombosis are the most common type of these complications [25]. Sonographic evaluation of such these lesions in the immediate post-transplant period may be limited and MRI/MRA might be necessary.

Cortical necrosis is extremely rare but severe. It can be secondary to a long cold ischemic time or rejection. Diagnosis is difficult because in the initial phase, arteries and veins remain patent. US can show a globular and heterogeneous graft with decrease in the CD sign of the cortical arteries. RI is elevated and progresses to absence of diastolic flow. Focal, patchy or diffuse zones of necrosis are better demonstrated by MRI. Biopsy is necessary to exclude rejection [25].

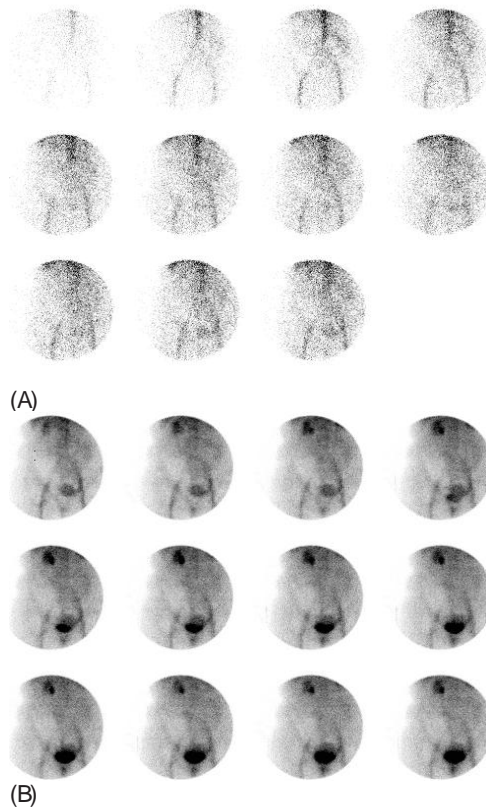


Figure 14. A and B: ^{99m}Tc -DTPA renal scintigraphy. Photopenic area in the left iliac fossa. Absence of arterial blood flow and of glomerular filtration in the transplanted kidney. Radionuclide angioscintigraphy performed with ^{99m}Tc -DTPA. The photon deficiency and no uptake of radioactivity at the site of the graft indicate non-viability.

6.2. Late vascular complications

Renal artery stenosis (RAS) is the most common VC. Stenosis can occur within a few months, most often caused by trauma to the donor's or recipient's vessel during clamping, or it may be delayed for few years, in which case atherosclerosis is usually the cause [84]. Kinking of the renal artery may cause a similar clinical condition, leading to an erroneous suspicion of RAS.

The patency of the renal artery should be performed in patients with severe hypertension refractory to medical therapy or with hypertension combined with either an audible bruit or unexplained graft dysfunction [50]. It usually occurs in the anastomosis or in the proximal donor artery, related to the surgery technique, media and intima injuries, and atherosclerosis, both from the donor or the recipient. They can occur in a short or long segment, multifocal or unifocal involvement. Flow disturbances resulting from a tight anastomosis are most readily detected in the site of the anastomosis.

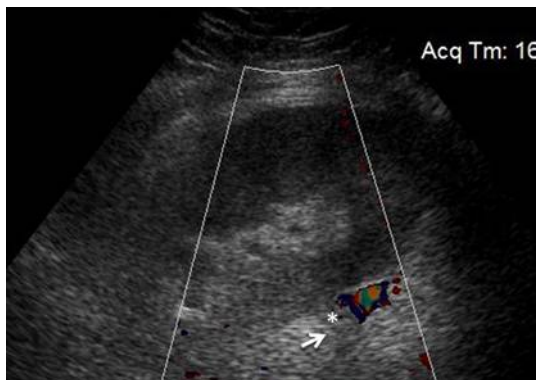


Figure 15. Renal vein thrombosis. The enlarged, occluded vein (arrow) is seen at the hilum, with a thrombus within (*).

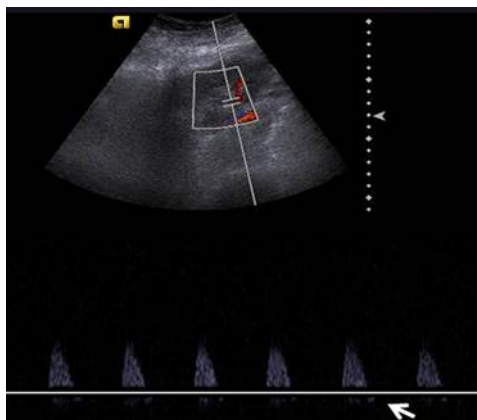


Figure 16. A reversal diastolic flow (arrow) and raising of the PSV in the interlobar artery as an indirect sign of renal vein thrombosis.

The Doppler criteria to diagnosis renal artery stenosis include: 1- high-velocity flow greater than 2 m/s measured in the renal artery (Figure 17A); 2- the ratio peak velocity in the transplant artery / peak velocity in the iliac artery close to the anastomosis higher than 2 (PVS RA/IA > 2); 3- velocity gradient between stenotic and pre-stenotic segments of more than 2:1; 4- marked distal turbulence [85, 86]. US with Doppler of the intra-renal arteries for detecting proximal artery stenosis shows a tardus parvus waveform; prolonged acceleration time, > 0.07 seconds (Figure 17B); diminished acceleration index (<3.0 m/s²); decreased RI (<0,56); and loss of a normal early systolic compliance peak [85]. When US is inconclusive for RAS, MRA (preferable) and CT angiography may define the site and the degree of stenosis. The stenosis can also be confirmed by angiography, which also provides a good estimate of the vessel extent and helps in the planning of percutaneous transluminal angioplasty (Figure 18).

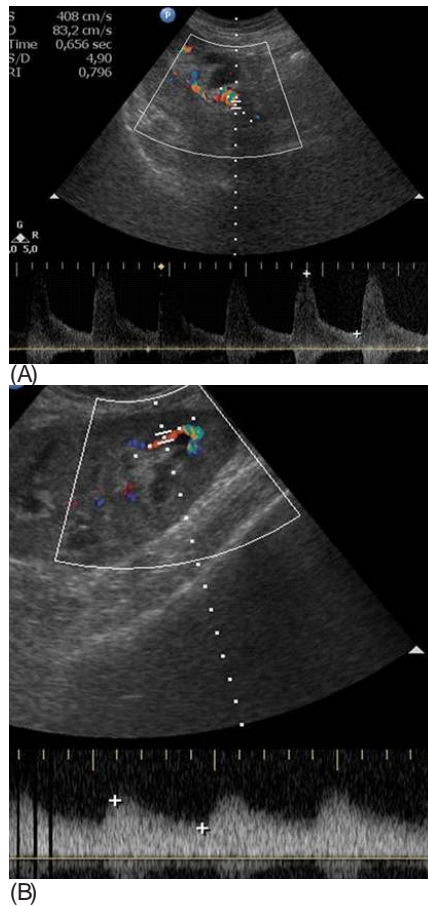


Figure 17. RAS. (A) Color-Doppler shows a focal stenosis near renal hilum with marked increase in PSV (4.0 m/s). (B) There is a tardus parvus waveform and a decreased RI at spectral Doppler.

Arteriovenous fistula (AVF) normally occurs secondary to transplant biopsy, with an incidence of 1-18% [84, 87]. Small lesions may resolve spontaneously; if not, they can be successfully treated with percutaneous embolization. They are usually asymptomatic, but can manifest with hypertension, hematuria, and graft dysfunction. Doppler US is the modality of choice for diagnosis. Focal high-velocity, low-impedance intrarenal arterial flow might suggest an arteriovenous fistula. An intense focus of high-velocity turbulent flow that is seen as a multicolored focus, persisting even with high pulse repetition frequency (or Doppler scale) at CDUS is also suspect. MRI and CT are used when US cannot define the vascular nature of the lesion. Visualization of a round abnormality in the renal parenchyma that enhances similar to the aorta at arterial-phase on MRI with an abnormal early venous drainage adjacent to the lesion is diagnostic for AVF [19]. DSA remains as the gold standard for such diagnosis and is also the method of choice for therapeutic (Figure 19).

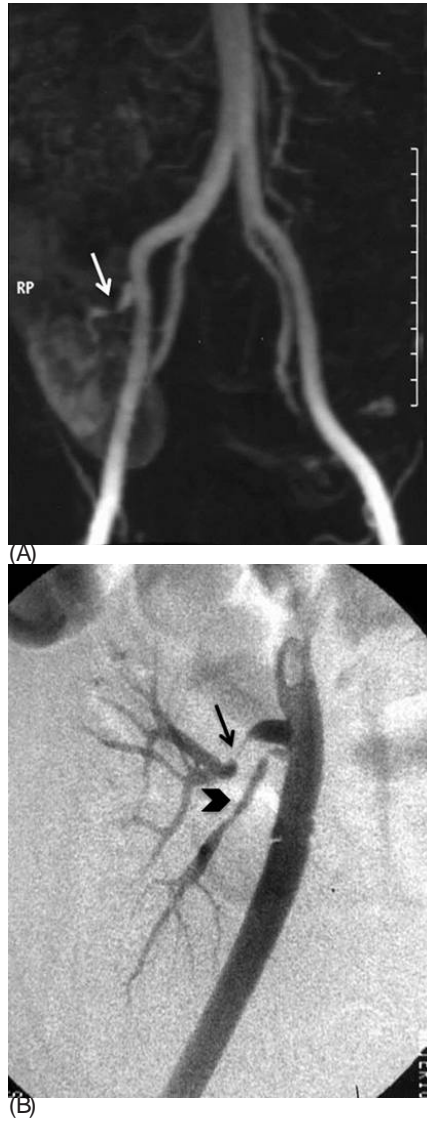


Figure 18. (A): MRA reconstructed with MIP nicely demonstrates the renal artery stenosis (arrow). (B): DSA of a different case showing multifocal stenosis in the renal artery (arrows) and a long segmental stenosis in the polar artery (arrowhead).

In general, pseudoaneurysms develop secondary to biopsy injury. Most of them resolve spontaneously within the first two months. However, if there were progressive enlargement, an unusual size (> 2 cm in diameter) or loss of renal function, intervention will be required [31]. US shows a simple or complex cyst. CD shows the to-and-fro yin and yang pattern seen in

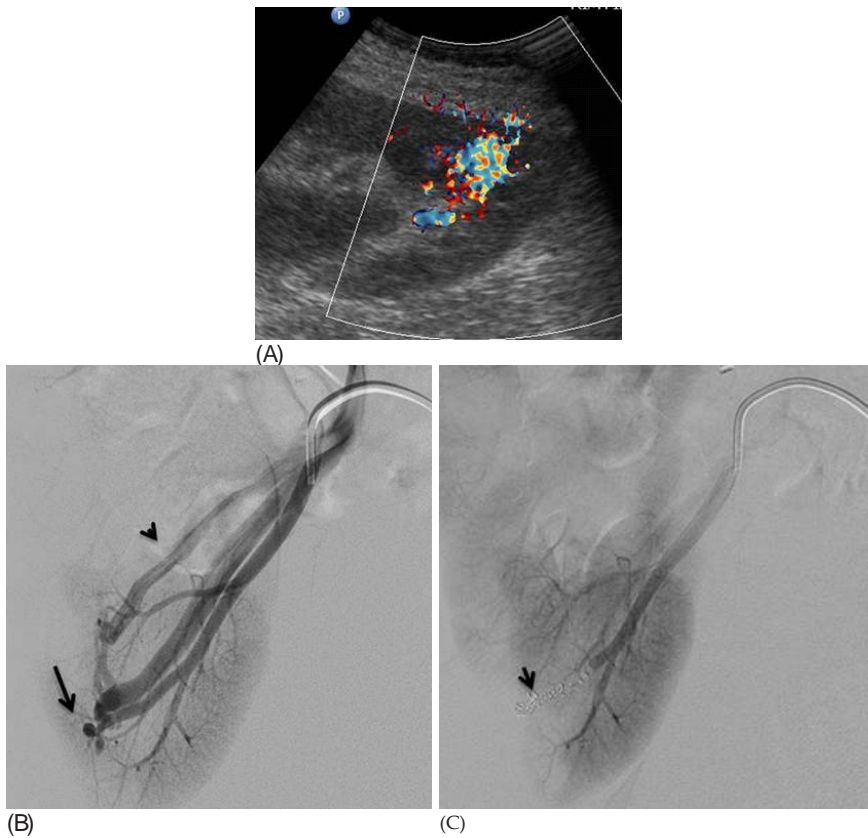


Figure 19. arteriovenous fistula. (A) US CD shows a vascular structure with troubling flow. (B) DSA pre- treatment showing a distal communication (arrow) between arterial and venous system with early drainage (arrowhead). (C) Af- ter coil placement (arrow) the AV fistula is no longer seen.

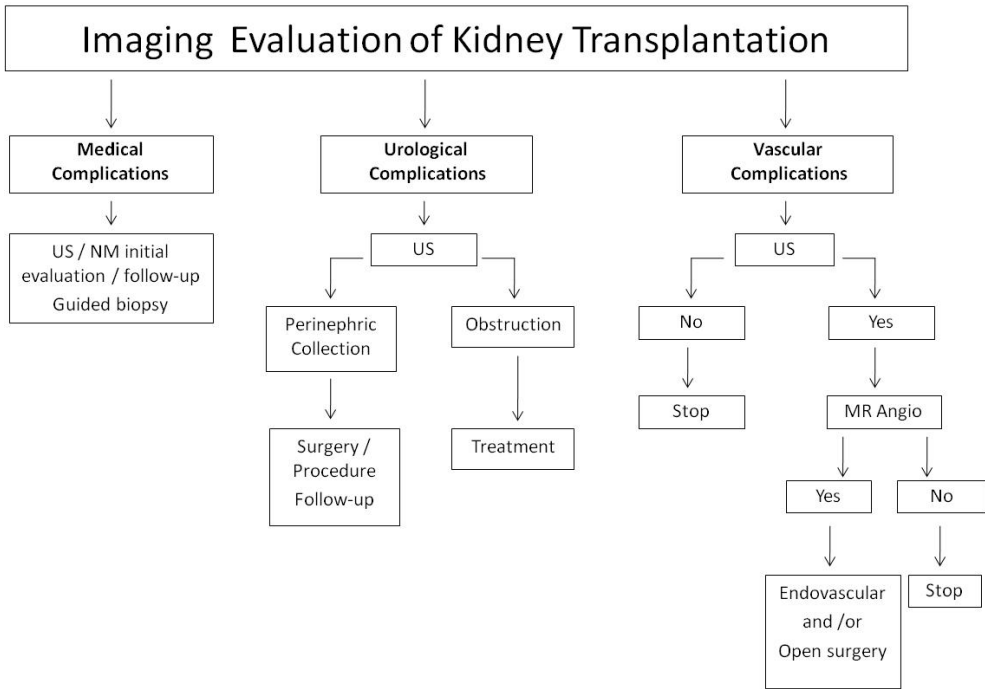
other sites of pseudoaneurysms. Extrarenal arterial pseudoaneurysm following renal trans-plantation is extremely rare.

Figure 20 shows an algorithm for initial evaluation of complications after kidney transplan- tation.

7. Other complications following renal transplantation

7.1. Malignancy after kidney transplantation

It is a known fact that patients submitted to renal replacement therapy, whether dialysis or transplantation, are at higher risk for cancer [88]. Among neoplasias, urologic tumors are about 4 to 5 times more frequent among renal transplant recipients and their characteristics differ



Algorithm for imaging evaluation of complications after kidney transplantation
 NM – nuclear medicine
 US – ultra sound

Figure 20. Algorithm for initial evaluation of kidney transplantation.

from those of tumors occurring in the general population. These neoplasias show three different presentations: de novo occurrence in the recipient, recurrence of a preexisting malignant neoplasia, or transfer of a malignant neoplasia together with the renal graft [89].

With increasing donor age, the use of marginal donors and the increased survival of renal grafts, malignant genitourinary neoplasms have become more common. Thus, post-renal transplant vigilance is important in order to obtain an early diagnosis and to institute appropriate treatment (Figure 21).

The imaging methods used for diagnostic confirmation are those cited earlier and their use varies according to the symptoms presented by the patient.

7.2. Disease recurrence

Disease recurrence in the graft has a greater prevalence in children than in adults, thereby increasing patient morbidity, graft loss and, sometimes, mortality rates. Indeed, the current overall graft loss is mainly due to primary glomerulonephritis (70–80%) and inherited metabolic diseases [7, 90-95]. It depends on the primary disease before transplantation. The

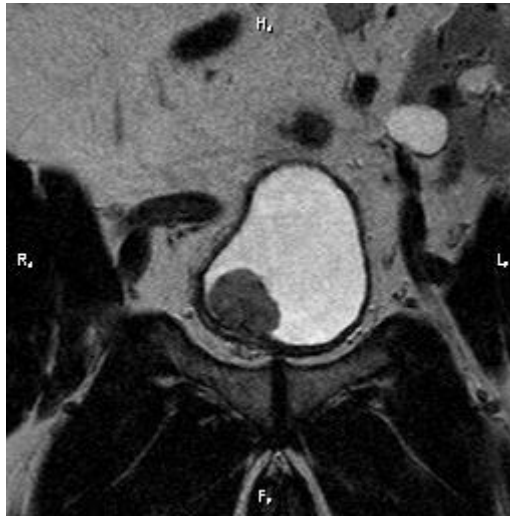

Figure 21. Vesical neoplasia in patient with renal allograft. A mass is seen in the bladder floor (arrow). Transplant kidney (TK) is in left inguinal fossa.

presentation of recurrence includes early massive proteinuria and sometimes graft failure and arterial hypertension [96]. Imaging has no specific pattern in these situations, and mainly plays a role in guiding biopsy.

7.3. End-stage disease

Nonfunctional renal grafts are often left in situ. As in chronic native renal parenchymal chronic disease the grafts are usually small, and can have fatty replacement, hydronephrosis, infarcts, hemorrhage, and calcifications [19].

7.4. Renal focal lesions

Focal lesions are seen as a less common complication after transplantation. Besides parenchymal abscess, and focal infarction, these may be secondary to recent surgery such as focal contusion or postbiopsy intrarenal hematoma. Focal lesions may be miscarried in surveillance [33].

8. Donors' evaluation

The number of people waiting for transplantation using cadaveric organs is usually very expressive, worldwide. Therefore kidney transplantation from living donors is becoming more and more frequent. Living donor kidney recipients have a significant increase in graft survival compared to deceased donor recipients. A living donor transplant has the advantage not to require a waiting list and can be performed in a preemptive manner (before the beginning of

dialysis treatment). There is also evidence that patients who receive a preemptive transplant have a longer graft survival than patients who remain on dialysis before the transplant. In the past, only genetically related individuals were considered to be potential donors; however, the use of unrelated kidney donors is increasing and the recipients of these kidneys have a better graft survival than recipients of deceased kidney donors [97, 98].

The organ donor candidate must be an adult with the ability to decide, should have an affective relationship with the recipient and be free from coercion. He should be healthy from both a medical and psychic viewpoint and should be informed about the risks and benefits of donation [99].

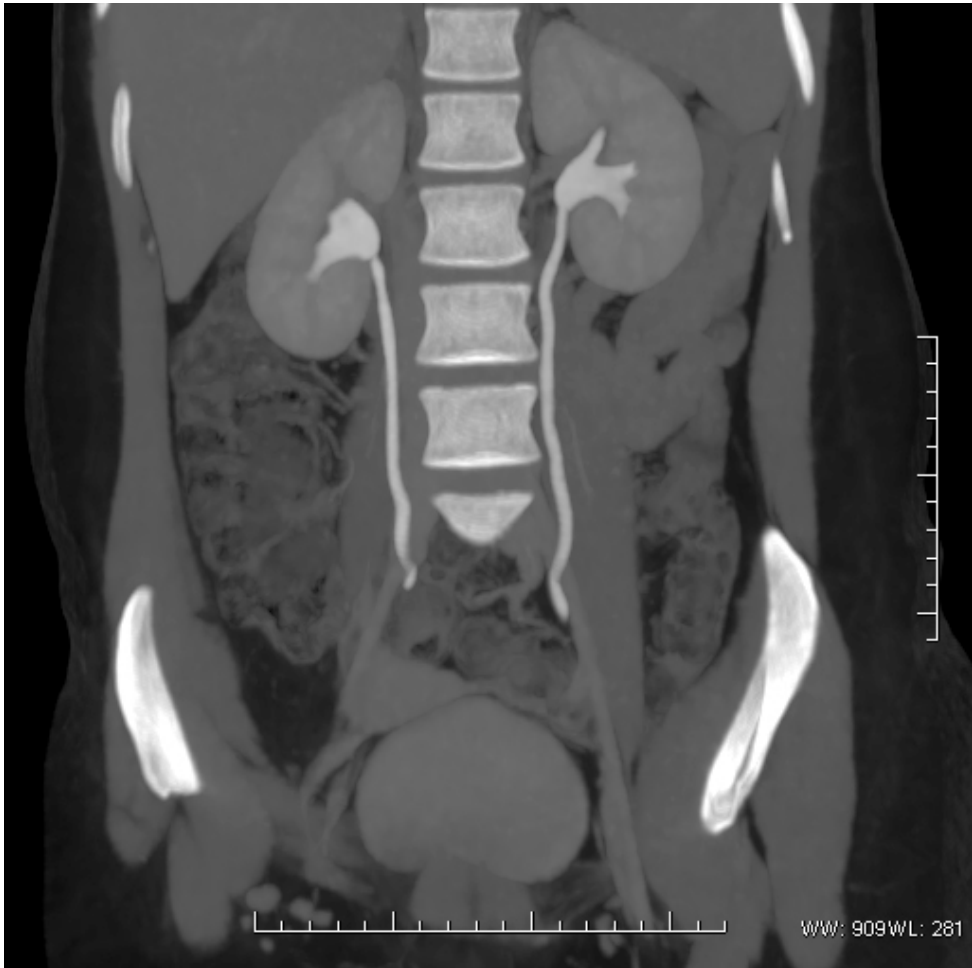

Figure 22. Split-bolus CT-Urography with MIP reconstruction allows evaluation of pelvicaliceal system and ureters fully distended, as well as renal parenchyma, in a potential kidney-donor.

The systematic evaluation of a living donor includes socioeconomic and psychological assessment, medical history and physical examination complemented with laboratory tests and imaging exams.

The evaluation of renal anatomy, mainly the vascular details of a living organ, is absolutely crucial, before removing it, surgically [18]. When living donors are considered, possible aortic and/or renal arterial, venous anatomical variants and/or congenital malformations are key factors to decide if a relative could be a potential donor, and moreover, which kidney will be removed, left or right. In addition, a detailed evaluation of collecting system and ureters may be obtained and may abbreviate decisions [82].

In the past, to obtain all the information required, urologist and nephrologists used to order at least 3 exams: 1- Intravenous urography (IVU) for evaluation of collecting system; 2- voiding cystourethrogram to detect a silent vesicoureteral reflux and its consequences to the kidneys and; 3- abdominal angiography to evaluate aorta and renal arteries. Nowadays, although there is a considerable variation of protocols for potential donors, all this information can be derived from only one technique, multidetector CT (MDCT). The fast scanners recently available allow timing-specific images, in other words it's possible to obtain early images, in the arterial phase, to depict arterial anatomy in detail and, later on, do another scanning during venous phase and later on, on excretory phase to depict pelvicaliceal system and ureters [15]. MDCT is reported to be as accurate as DSA for detecting supranumerary and polar arteries, as well as venous anatomical variations as circumaortic veins, double veins and so on. Some authors, in order to reduce ionizing radiation dose, suggest that the last (excretory) phase, could be replaced by a abdominal plain film, taking advantage of the contrast media in the collecting system and bladder, simulating an late film in IVU (Figure 22).

Voiding cystourethrogram (VCU) was commonly used for evaluating of living donors, however, several studies have shown that no clinically relevant information is provided for this examination in the great majority of cases. So, VCU is no longer used in most of individuals who are candidates for kidney donation [83].

Author details

Valdair Francisco Muglia¹, Sara Reis Teixeira¹, Elen Almeida Romão²,
Marcelo Ferreira Cassini³, Murilo Ferreira de Andrade³, Mery Kato⁴,
Maria Estela Papini Nardin¹ and Silvio Tucci Jr³

1 Department of Internal Medicine, Division of Radiology, University of Sao Paulo, Faculty of Medicine of Ribeirao Preto, Ribeirao Preto – SP, Brazil

2 Division of Nephrology, University of Sao Paulo, Faculty of Medicine of Ribeirao Preto, Ribeirao Preto – SP, Brazil

3 Division of Urology, University of Sao Paulo, Faculty of Medicine of Ribeirao Preto, Ribeirao Preto – SP, Brazil

4 Section of Nuclear Medicine, University of Sao Paulo, Faculty of Medicine of Ribeirao Preto, Ribeirao Preto – SP, Brazil

References

- [1] Cecka, J. M. Kidney transplantation in the United States. *Clin Transpl.* (2008). , 2008, 1-18.
- [2] Foss, A, Leivestad, T, Brekke, I. B, Fauchald, P, Bentdal, O, Lien, B, et al. Unrelated living donors in 141 kidney transplantations: a one-center study. *Transplantation.* (1998). Jul 15;, 66(1), 49-52.
- [3] Collaborative Transplant Study (CTS)cited May (2010). Available from: www.ctstransplant.org/public/graphics/sample.shtml.
- [4] Gluecker, T. M, Mayr, M, Schwarz, J, Bilecen, D, Voegelé, T, Steiger, J, et al. Comparison of CT angiography with MR angiography in the preoperative assessment of living kidney donors. *Transplantation.* (2008). Nov 15;, 86(9), 1249-56.
- [5] Turkvatan, A, Akinci, S, Yildiz, S, Olcer, T, & Cumhuri, T. Multidetector computed tomography for preoperative evaluation of vascular anatomy in living renal donors. *Surg Radiol Anat.* (2009). Apr;, 31(4), 227-35.
- [6] Friedewald, S. M, Molmenti, E. P, Friedewald, J. J, Dejong, M. R, & Hamper, U. M. Vascular and nonvascular complications of renal transplants: sonographic evaluation and correlation with other imaging modalities, surgery, and pathology. *J Clin Ultrasound.* [Review]. (2005). Mar-Apr;, 33(3), 127-39.
- [7] Nankivell, B. J. Kuypers DRJ. Diagnosis and prevention of chronic kidney allograft loss. *The Lancet.* (2011). , 378(9800), 1428-37.
- [8] Radermacher, J, Mengel, M, Ellis, S, Stucht, S, Hiss, M, Schwarz, A, et al. The renal arterial resistance index and renal allograft survival. *N Engl J Med.* [Research Support, Non-U.S. Gov't]. (2003). Jul 10;, 349(2), 115-24.
- [9] Chow, L, Sommer, F. G, Huang, J, & Li, K. C. Power Doppler imaging and resistance index measurement in the evaluation of acute renal transplant rejection. *J Clin Ultrasound.* [Evaluation Studies]. (2001). Nov-Dec;, 29(9), 483-90.
- [10] Rajiah, P, Lim, Y. Y, & Taylor, P. Renal transplant imaging and complications. *Abdom Imaging.* [Review]. (2006). Nov-Dec;, 31(6), 735-46.
- [11] Sharfuddin, A. Imaging evaluation of kidney transplant recipients. *Semin Nephrol.* [Review]. (2011). May;, 31(3), 259-71.
- [12] Haustein, J, Niendorf, H. P, Krestin, G, Louton, T, Schuhmann-giampieri, G, Clauss, W, et al. Renal tolerance of gadolinium-DTPA/dimeglumine in patients with chronic renal failure. *Invest Radiol.* [Clinical Trial]. (1992). Feb;, 27(2), 153-6.
- [13] Liu, X, Berg, N, Sheehan, J, Bi, X, Weale, P, Jerecic, R, et al. Renal transplant: nonenhanced renal MR angiography with magnetization-prepared steady-state free precession. *Radiology.* (2009). May;, 251(2), 535-42.

- [14] Kalb, B, Martin, D. R, Salman, K, Sharma, P, Votaw, J, & Larsen, C. Kidney transplantation: structural and functional evaluation using MR Nephro-Urography. *J Magn Reson Imaging*. [Review]. (2008). Oct;, 28(4), 805-22.
- [15] Marckmann, P, Skov, L, Rossen, K, Dupont, A, Damholt, M. B, Heaf, J. G, et al. Nephrogenic systemic fibrosis: suspected causative role of gadodiamide used for contrast-enhanced magnetic resonance imaging. *J Am Soc Nephrol*. (2006). Sep;, 17(9), 2359-62.
- [16] Grobner, T. Gadolinium--a specific trigger for the development of nephrogenic fibrosing dermopathy and nephrogenic systemic fibrosis? *Nephrol Dial Transplant*. (2006). Apr;, 21(4), 1104-8.
- [17] Wang, Y, Alkasab, T. K, Narin, O, Nazarian, R. M, Kaewlai, R, Kay, J, et al. Incidence of nephrogenic systemic fibrosis after adoption of restrictive gadolinium-based contrast agent guidelines. *Radiology*. (2011). Jul;, 260(1), 105-11.
- [18] Stacul, F, Van Der Molen, A. J, Reimer, P, Webb, J. A, Thomsen, H. S, Morcos, S. K, et al. Contrast induced nephropathy: updated ESUR Contrast Media Safety Committee guidelines. *Eur Radiol*. [Review]. (2011). Dec;, 21(12), 2527-41.
- [19] Sebastia, C, Quiroga, S, Boye, R, Cantarell, C, Fernandez-planas, M, & Alvarez, A. Helical CT in renal transplantation: normal findings and early and late complications. *Radiographics*. [Review]. (2001). Sep-Oct;, 21(5), 1103-17.
- [20] Chen, C. H, Shu, K. H, Cheng, C. H, Wu, M. J, Yu, T. M, Chuang, Y. W, et al. Imaging evaluation of kidney using multidetector computerized tomography in living-related renal transplantation. *Transplant Proc*. (2012). Jan;, 44(1), 7-10.
- [21] Hagen, G, Wadstrom, J, Magnusson, M, & Magnusson, A. Outcome after percutaneous transluminal angioplasty of arterial stenosis in renal transplant patients. *Acta Radiol*. [Research Support, Non-U.S. Gov't]. (2009). Apr;, 50(3), 270-5.
- [22] Irshad, A, Ackerman, S. J, Campbell, A. S, & Anis, M. An Overview of Renal Transplantation: Current Practice and Use of Ultrasound. *Seminars in Ultrasound, CT, and MRI*. (2009). , 30(4), 298-314.
- [23] Kalble, T, Lucan, M, Nicita, G, & Sells, R. Burgos Revilla FJ, Wiesel M. EAU guidelines on renal transplantation. *Eur Urol*. [Consensus Development Conference Guideline Practice Guideline Review]. (2005). Feb;, 47(2), 156-66.
- [24] Auriol, J. Urological and medical complications of renal transplant]. *J Radiol*. [Review]. (2011). Apr;, 92(4), 336-42.
- [25] Ardelean, A, Mandry, D, & Claudon, M. Vascular complications following renal transplantation: diagnostic evaluation]. *J Radiol*. [Case Reports Review]. (2011). Apr;, 92(4), 343-57.
- [26] Hricak, H, Terrier, F, & Demas, B. E. Renal allografts: evaluation by MR imaging. *Radiology*. (1986). May;, 159(2), 435-41.

- [27] Yamamoto, A, Zhang, J. L, Rusinek, H, Chandarana, H, Vivier, P. H, Babb, J. S, et al. Quantitative evaluation of acute renal transplant dysfunction with low-dose three-dimensional MR renography. *Radiology*. [Clinical Trial In Vitro Research Support, Non-U.S. Gov't]. (2011). Sep;; 260(3), 781-9.
- [28] Kalb, B, Votaw, J. R, Salman, K, Sharma, P, & Martin, D. R. Magnetic resonance nephrourography: current and developing techniques. *Radiol Clin North Am*. [Research Support, Non-U.S. Gov't Review]. (2008). Jan;v., 46(1), 11-24.
- [29] Isoniemi, H. M, Krogerus, L, Von Willebrand, E, Taskinen, E, Ahonen, J, & Hayry, P. Histopathological findings in well-functioning, long-term renal allografts. *Kidney Int*. [Clinical Trial Randomized Controlled Trial Research Support, Non-U.S. Gov't]. (1992). Jan;; 41(1), 155-60.
- [30] Shoskes, D. A, & Halloran, P. F. Delayed graft function in renal transplantation: etiology, management and long-term significance. *J Urol*. [Research Support, Non-U.S. Gov't Review]. (1996). Jun;; 155(6), 1831-40.
- [31] Park, S. B, Kim, J. K, & Cho, K. S. Complications of renal transplantation: ultrasonographic evaluation. *J Ultrasound Med*. [Review]. (2007). May;; 26(5), 615-33.
- [32] Neill, O, & Baumgarten, W C. DA. Ultrasonography in renal transplantation. *Am J Kidney Dis*. [Review]. (2002). Apr;; 39(4), 663-78.
- [33] Irshad, A, Ackerman, S, Sosnouski, D, Anis, M, Chavin, K, & Baliga, P. A review of sonographic evaluation of renal transplant complications. *Curr Probl Diagn Radiol*. [Review]. (2008). Mar-Apr;; 37(2), 67-79.
- [34] Swobodnik, W. L, Spohn, B. E, Wechsler, J. G, Schusdziarra, V, Blum, S, Franz, H. E, et al. Real-time ultrasound evaluation of renal transplant failure during the early post-operative period. *Ultrasound Med Biol*. [Comparative Study]. (1986). Feb;; 12(2), 97-105.
- [35] Griffin, J. F, Short, C. D, Lawler, W, Mallick, N. P, & Johnson, R. W. Diagnosis of disease in renal allografts: correlation between ultrasound and histology. *Clin Radiol*. [Comparative Study]. (1986). Jan;; 37(1), 59-62.
- [36] Grant, E. G, & Perrella, R. R. Wishing won't make it so: duplex Doppler sonography in the evaluation of renal transplant dysfunction. *AJR Am J Roentgenol*. [Comment]. (1990). Sep;; 155(3), 538-9.
- [37] Perrella, R. R, Duerinckx, A. J, Tessler, F. N, Danovitch, G. M, Wilkinson, A, Gonzalez, S, et al. Evaluation of renal transplant dysfunction by duplex Doppler sonography: a prospective study and review of the literature. *Am J Kidney Dis*. [Review]. (1990). Jun;; 15(6), 544-50.
- [38] Schwenger, V, Hinkel, U. P, Nahm, A. M, Morath, C, & Zeier, M. Color doppler ultrasonography in the diagnostic evaluation of renal allografts. *Nephron Clin Pract*. [Review]. (2006). c, 107-12.

- [39] Zimmerman, P R. N, & Schiepers, C. Diagnostic imaging in kidney transplantation. In: GM D, editor. Handbook of kidney transplantation. 4th ed: Philadelphia: Lippincott Williams & Wilkins; (2005). , 347-368.
- [40] Jimenez, C, Lopez, M. O, Gonzalez, E, & Selgas, R. Ultrasonography in kidney transplantation: values and new developments. *Transplant Rev (Orlando)*. [Review]. (2009). Oct;, 23(4), 209-13.
- [41] Neimatallah, M. A, Dong, Q, Schoenberg, S. O, Cho, K. J, & Prince, M. R. Magnetic resonance imaging in renal transplantation. *J Magn Reson Imaging*. [Research Support, Non-U.S. Gov't]. (1999). Sep;, 10(3), 357-68.
- [42] Huang, A. J, Lee, V. S, & Rusinek, H. Functional renal MR imaging. *Magn Reson Imaging Clin N Am*. [Review]. (2004). Aug;vi., 12(3), 469-86.
- [43] Fang, Y. C, & Siegelman, E. S. Complications of renal transplantation: MR findings. *J Comput Assist Tomogr*. [Review]. (2001). Nov-Dec;, 25(6), 836-42.
- [44] Dubovsky, E. V, Russell, C. D, Bischof-delaloye, A, Bubeck, B, Chaiwatanarat, T, Hilson, A. J, et al. Report of the Radionuclides in Nephrourology Committee for evaluation of transplanted kidney (review of techniques). *Semin Nucl Med*. [Review]. (1999). Apr;, 29(2), 175-88.
- [45] Dubovsky, E. V, Russell, C. D, & Erbas, B. Radionuclide evaluation of renal transplants. *Semin Nucl Med*. [Review]. (1995). Jan;, 25(1), 49-59.
- [46] Nankivell, B. J, & Alexander, S. I. Rejection of the kidney allograft. *N Engl J Med*. Oct 7;, 363(15), 1451-62.
- [47] Elsayes, K. M, Menias, C. O, Willatt, J, Azar, S, Harvin, H. J, & Platt, J. F. Imaging of renal transplant: utility and spectrum of diagnostic findings. *Curr Probl Diagn Radiol*. [Review]. (2011). May-Jun;, 40(3), 127-39.
- [48] Dupont, P. J, Dooldeniya, M, Cook, T, & Warrens, A. N. Role of duplex Doppler sonography in diagnosis of acute allograft dysfunction-time to stop measuring the resistive index? *Transpl Int*. [Comparative Study]. (2003). Sep;, 16(9), 648-52.
- [49] Baxter, G. M. Ultrasound of renal transplantation. *Clin Radiol*. [Review]. (2001). Oct;, 56(10), 802-18.
- [50] Brown, E. D, Chen, M. Y, Wolfman, N. T, Ott, D. J, & Watson, N. E. Jr. Complications of renal transplantation: evaluation with US and radionuclide imaging. *Radiographics*. [Review]. (2000). May-Jun;, 20(3), 607-22.
- [51] Benigni, A, Bruzzi, I, Mister, M, Azzollini, N, Gaspari, F, Perico, N, et al. Nature and mediators of renal lesions in kidney transplant patients given cyclosporine for more than one year. *Kidney Int*. (1999). Feb;, 55(2), 674-85.
- [52] Scott, L. J, Mckeage, K, Keam, S. J, & Plosker, G. L. Tacrolimus: a further update of its use in the management of organ transplantation. *Drugs*. (2003). , 63(12), 1247-97.

- [53] Seron, D, & Moreso, F. Preservation of renal function during maintenance therapy with cyclosporine. *Transplant Proc.* (2004). Mar;36(2 Suppl):257S-60S.
- [54] Kanazi, G, Stowe, N, Steinmuller, D, Hwieh, H. H, & Novick, A. C. Effect of cyclosporine upon the function of ischemically damaged kidneys in the rat. *Transplantation.* (1986). Jun;, 41(6), 782-4.
- [55] Ali, M. G, Coakley, F. V, Hricak, H, & Bretan, P. N. Complex posttransplantation abnormalities of renal allografts: evaluation with MR imaging. *Radiology.* (1999). Apr;, 211(1), 95-100.
- [56] Browne, R. F, & Tuite, D. J. Imaging of the renal transplant: comparison of MRI with duplex sonography. *Abdom Imaging.* (2006). Jul-Aug;, 31(4), 461-82.
- [57] Baxter, G. M. Imaging in renal transplantation. *Ultrasound Q.* [Review]. (2003). Sep;, 19(3), 123-38.
- [58] Akbar, S. A, Jafri, S. Z, Amendola, M. A, Madrazo, B. L, Salem, R, & Bis, K. G. Complications of renal transplantation. *Radiographics.* [Review]. (2005). Sep-Oct;, 25(5), 1335-56.
- [59] Kocak, T, Nane, I, Ander, H, Ziyilan, O, Oktar, T, & Ozsoy, C. Urological and surgical complications in 362 consecutive living related donor kidney transplantations. *Urol Int.* (2004). , 72(3), 252-6.
- [60] Azhar, R. A, Hassanain, M, Aljiffry, M, Aldousari, S, Cabrera, T, Andonian, S, et al. Successful salvage of kidney allografts threatened by ureteral stricture using pyelovesical bypass. *Am J Transplant.* Jun;, 10(6), 1414-9.
- [61] Mukha, R. P, Devasia, A, & Thomas, E. M. Ureteral herniation with intermittent obstructive uropathy in a renal allograft recipient. *Urol J.* [Case Reports]. (2011). Spring; 8(2):98.
- [62] Pozniak, M. A, & Dodd, G. D. rd, Kelcz F. Ultrasonographic evaluation of renal transplantation. *Radiol Clin North Am.* [Review]. (1992). Sep;, 30(5), 1053-66.
- [63] Tublin, M. E, & Dodd, G. D. rd. Sonography of renal transplantation. *Radiol Clin North Am.* [Review]. (1995). May;, 33(3), 447-59.
- [64] Tublin, M. E, Bude, R. O, & Platt, J. F. Review. The resistive index in renal Doppler sonography: where do we stand? *AJR Am J Roentgenol.* [Review]. (2003). Apr;, 180(4), 885-92.
- [65] Tripathi, M, Chandrashekar, N, Phom, H, Gupta, D. K, Bajpai, M, Bal, C, et al. Evaluation of dilated upper renal tracts by technetium-99m ethylenedicysteine F+O diuresis renography in infants and children. *Ann Nucl Med.* [Clinical Trial Controlled Clinical Trial]. (2004). Dec;, 18(8), 681-7.
- [66] Sperling, H, Becker, G, Heemann, U, Lummen, G, Philipp, T, & Rubben, H. The Whitaker test, a useful tool in renal grafts? *Urology.* (2000). Jul;, 56(1), 49-52.

- [67] Winsett, M. Z, Amparo, E. G, Fawcett, H. D, Kumar, R, & Johnson, R. F. Jr., Bedi DG, et al. Renal transplant dysfunction: MR evaluation. *AJR Am J Roentgenol*. [Research Support, Non-U.S. Gov't]. (1988). Feb,; 150(2), 319-23.
- [68] Stravodimos, K. G, Adamis, S, Tyrirtzis, S, Georgios, Z, & Constantinides, C. A. Renal transplant lithiasis: analysis of our series and review of the literature. *J Endourol*. [Review]. (2012). Jan,; 26(1), 38-44.
- [69] Cranston, D. Urological complications after renal transplantation. *J R Soc Med*. (1996). Suppl 29:22.
- [70] Silver, T. M, Campbell, D, Wicks, J. D, Lorber, M. I, Surace, P, & Turcotte, J. Peritransplant fluid collections. Ultrasound evaluation and clinical significance. *Radiology*. (1981). Jan,; 138(1), 145-51.
- [71] Yap, R, Madrazo, B, Oh, H. K, & Dienst, S. G. Perirenal fluid collection after renal transplant. *Am Surg*. (1981). Jul,; 47(7), 287-90.
- [72] Khauli, R. B, Stoff, J. S, Lovewell, T, Ghavamian, R, & Baker, S. Post-transplant lymphoceles: a critical look into the risk factors, pathophysiology and management. *J Urol*. (1993). Jul,; 150(1), 22-6.
- [73] Kumar, R. Bharathi Dasan J, Choudhury S, Guleria S, Padhy AK, Malhotra A. Scintigraphic patterns of lymphocele in post-renal transplant. *Nucl Med Commun*. (2003). May,; 24(5), 531-5.
- [74] Campos Freire J, de Goes GM, de Campos Freire JG. Extravesical ureteral implantation in kidney transplantation. *Urology*. (1974). Mar,; 3(3), 304-8.
- [75] Browne, R. F, & Tuite, D. J. Imaging of the renal transplant: comparison of MRI with duplex sonography. *Abdom Imaging*. [Comparative Study Review]. (2006). Jul-Aug,; 31(4), 461-82.
- [76] Lucewicz, A, Isaacs, A, Allen, R. D, Lam, V. W, Angelides, S, & Pleass, H. C. Torsion of intraperitoneal kidney transplant. *ANZ J Surg*. (2011). May 10.
- [77] Wong-you-cheong, J. J, Grumbach, K, Krebs, T. L, Pace, M. E, Daly, B, Chow, C. C, et al. Torsion of intraperitoneal renal transplants: imaging appearances. *AJR Am J Roentgenol*. (1998). Nov,; 171(5), 1355-9.
- [78] Millwala, F. N, Abraham, G, Shroff, S, Soundarajan, P, Rao, R, & Kuruvilla, S. Spontaneous renal allograft rupture in a cohort of renal transplant recipients: a tertiary care experience. *Transplant Proc*. [Case Reports]. (2000). Nov,; 32(7), 1912-3.
- [79] Beek, F. J, Bax, N. M, Donckerwolcke, R, & Van Leeuwen, M. S. Sonographic findings in spontaneous renal transplant rupture. *Pediatr Radiol*. [Case Reports]. (1992). , 22(4), 313-4.
- [80] Rahatzad, M, Henderson, S. C, & Boren, G. S. Ultrasound appearance of spontaneous rupture of renal transplant. *J Urol*. [Case Reports]. (1981). Oct,; 126(4), 535-6.

- [81] Hohnke, C, Abendroth, D, Schleibner, S, & Land, W. Vascular complications in 1,200 kidney transplantations. *Transplant Proc.* [Review]. (1987). Oct;, 19(5), 3691-2.
- [82] Lebkowska, U, Malyszko, J, Lebkowski, W, Brzosko, S, Kowalewski, R, Lebkowski, T, et al. The predictive value of arterial renal blood flow parameters in renal graft survival. *Transplant Proc.* (2007). Nov;, 39(9), 2727-9.
- [83] Gao, J, Ng, A, Shih, G, Goldstein, M, Kapur, S, Wang, J, et al. Intrarenal color duplex ultrasonography: a window to vascular complications of renal transplants. *J Ultrasound Med.* (2007). Oct;, 26(10), 1403-18.
- [84] Cosgrove, D. O, & Chan, K. E. Renal transplants: what ultrasound can and cannot do. *Ultrasound Q.* [Review]. (2008). Jun;quiz 141-2., 24(2), 77-87.
- [85] Taylor, K. J, Morse, S. S, Rigsby, C. M, Bia, M, & Schiff, M. Vascular complications in renal allografts: detection with duplex Doppler US. *Radiology.* [Case Reports]. (1987). Jan;162(1 Pt 1):31-8.
- [86] Snider, J. F, Hunter, D. W, Moradian, G. P, Castaneda-zuniga, W. R, & Letourneau, J. G. Transplant renal artery stenosis: evaluation with duplex sonography. *Radiology.* (1989). Sep;172(3 Pt 2):1027-30.
- [87] Grenier, N, Claudon, M, Trillaud, H, Douws, C, & Levantal, O. Noninvasive radiology of vascular complications in renal transplantation. *Eur Radiol.* (1997). , 7(3), 385-91.
- [88] Stewart, J. H, Vajdic, C. M, Van Leeuwen, M. T, Amin, J, Webster, A. C, Chapman, J. R, et al. The pattern of excess cancer in dialysis and transplantation. *Nephrol Dial Transplant.* (2009). Oct;, 24(10), 3225-31.
- [89] Melchior, S, Franzaring, L, Shardan, A, Schwenke, C, Plumpe, A, Schnell, R, et al. Urological de novo malignancy after kidney transplantation: a case for the urologist. *J Urol.* Feb;, 185(2), 428-32.
- [90] Cochat, P, Fargue, S, Mestrallet, G, Jungraithmayr, T, Koch-nogueira, P, Ranchin, B, et al. Disease recurrence in paediatric renal transplantation. *Pediatr Nephrol.* [Review]. (2009). Nov;, 24(11), 2097-108.
- [91] Moroni, G, Tantardini, F, Gallelli, B, Quaglini, S, Banfi, G, Poli, F, et al. The long-term prognosis of renal transplantation in patients with lupus nephritis. *Am J Kidney Dis.* [Comparative Study Research Support, Non-U.S. Gov't]. (2005). May;, 45(5), 903-11.
- [92] Ozdemir, B. H, Ozdemir, F. N, Demirhan, B, Turan, M, & Haberal, M. Renal transplantation in amyloidosis: effects of HLA matching and donor type on recurrence of primary disease. *Transplant Int.* (2004). Jun;, 17(5), 241-6.
- [93] Seikaly, M. G. Recurrence of primary disease in children after renal transplantation: an evidence-based update. *Pediatr Transplant.* [Review]. (2004). Apr;, 8(2), 113-9.
- [94] Ivanyi, B. A primer on recurrent and de novo glomerulonephritis in renal allografts. *Nat Clin Pract Nephrol.* [Review]. (2008). Aug;, 4(8), 446-57.

- [95] Briganti, E. M, Russ, G. R, Mcneil, J. J, Atkins, R. C, & Chadban, S. J. Risk of renal allograft loss from recurrent glomerulonephritis. *N Engl J Med.* [Comparative Study]. (2002). Jul 11;, 347(2), 103-9.
- [96] Newstead, C. G. Recurrent disease in renal transplants. *Nephrol Dial Transplant.* [Review]. (2003). Aug;18 Suppl 6:vi, 68-74.
- [97] Spital, A. Increasing the pool of transplantable kidneys through unrelated living donors and living donor paired exchanges. *Semin Dial.* (2005). Nov-Dec;, 18(6), 469-73.
- [98] Meier-kriesche, H. U, Port, F. K, Ojo, A. O, Rudich, S. M, Hanson, J. A, Cibrik, D. M, et al. Effect of waiting time on renal transplant outcome. *Kidney Int.* (2000). Sep;, 58(3), 1311-7.
- [99] Israni, A. K, Halpern, S. D, Zink, S, Sidhwani, S. A, & Caplan, A. Incentive models to increase living kidney donation: encouraging without coercing. *Am J Transplant.* (2005). Jan;, 5(1), 15-20.

