

Endophthalmitis, Prevention and Treatment

Elvis Ojaimi and David T. Wong

*University of Toronto, Vitreoretinal Department, St Michael's Hospital
Canada*

1. Introduction

Endophthalmitis is a devastating eye condition that can lead to permanent visual loss or even loss of the eye. It can occur from an immune mediated response to an antigen (sterile endophthalmitis) or most commonly from an infectious cause. Infectious endophthalmitis can be classified broadly into endogenous and exogenous. Endogenous endophthalmitis occurs from hematological spread in the setting of bacteremia or fungemia and is seen in the setting of immunosuppression, intravenous drug use, chronic indwelling urinary catheterization or remote infection. Exogenous endophthalmitis refers to an intraocular infection caused by the introduction of organisms from the external environment. This can occur in the setting of trauma (traumatic endophthalmitis) or surgery (acute & chronic postoperative endophthalmitis, filtering bleb-associated, intravitreal injections and secondary to extension of infection). Acute postoperative endophthalmitis can occur following any surgery that involves penetration of the eye including cataract, glaucoma, corneal and vitrectomy surgery. Endophthalmitis has also been reported in external ocular surgeries such as strabismus and scleral buckle surgery. These are probably associated with inadvertent perforation, infected explant material, and intraocular spread of external pathogens. Table 1 describes a classification for endophthalmitis. This chapter will be limited to exogenous endophthalmitis.

Endophthalmitis	
Exogenous	Endogenous
Acute onset postoperative <ul style="list-style-type: none"> • Cataract surgery • Glaucoma filtering surgery (penetrating) • Penetrating keratoplasty • Vitrectomy surgery • External ocular surgery (rarely) 	
Delayed (chronic) onset postoperative Posttraumatic Filtering bleb-associated Other: <ul style="list-style-type: none"> • Intravitreal injections • Infectious spread from keratitis or scleritis 	

Table 1. Endophthalmitis categories

2. Epidemiology

2.1 Exogenous endophthalmitis

2.1.1 Cataract surgery

The incidence of endophthalmitis following cataract surgery was described in a recent review as ranging from <0.05% to >0.3%.¹ In our study we reported a rate of suspected endophthalmitis of 0.14% from more than 440,000 cataract surgeries in Ontario, Canada over a 4 year period.² In Europe, the results of a recent, large, randomized multicentre study of antibacterial prophylaxis revealed an incidence of endophthalmitis ranging from 0.049% to as high as 0.345% seen in the control group.³ In an article by West et al.⁴, a 5% sampling of Medicare beneficiary data files revealed an increase in the rate of endophthalmitis from the time period 1994–1997 when compared with 1998–2001. The pooled rate over the entire 8-year period (which corresponds to the rise in clear corneal cataract surgery) was also high at 2.15 per 1000 surgeries (0.2%). Taban et al.⁵ performed a systematic review of the English literature and concluded that endophthalmitis rates were rising. Using a regression analysis model and excluding case reports, the authors found the rate of pooled endophthalmitis to be 0.265% from 2000 to 2003. Rates as high as 0.49% were also described in a study from Dublin.⁶

The rate of chronic post-operative endophthalmitis is less clear but less common than the acute type.

2.1.2 Glaucoma surgery

Bleb-associated endophthalmitis has been classified into early onset and late (delayed) onset, with 4 weeks after surgery being the arbitrary cut-off.⁷ Rates of endophthalmitis following non-augmented trabeculectomy surgery have been reported to occur between 0.2 – 1.5%.⁷ The rate increases significantly with intraoperative 5-FU or MMC. A recent US based retrospective study, utilizing the US medicare database reported the rate of endophthalmitis to be between 0.3-0.7% following trabeculectomy surgery.⁸ For glaucoma drainage devices, the study found an endophthalmitis rate of 2.0%.⁸ The rate of endophthalmitis following non penetrating glaucoma surgery is probably rare, with one case reported in the literature.⁹

2.1.3 Vitreoretinal procedures

2.1.3.1 Vitrectomy surgery

Internationally published rates of endophthalmitis for 20G vitrectomy range from 0.018% to 0.07%.¹⁰⁻¹² The incidence of endophthalmitis following 23G vitrectomy in the UK has been estimated at around 0.04%.¹² A higher rate of endophthalmitis has been suggested for 25G vitrectomy. However, in a recent meta-analysis the evidence was found to be tentative.¹³ The reported increase in risk of postoperative endophthalmitis after 25G was due to mainly two studies. Kunimoto et al¹⁴ identified 7 cases of endophthalmitis among 3103 25-gauge PPV surgeries (0.23%, or roughly 1 in 400), and Scott et al¹⁵ identified 11 cases in 1307 PPV surgeries (0.84%, or 1 in 119). In each series, this incidence was significantly higher than that observed after 20-gauge PPV during the same period among the same group of vitreoretinal surgeons. Most of the postoperative endophthalmitis cases that were reported involved both straight incision technique and were left fluid-filled at the end of the case.¹³

2.1.3.2 Intravitreal injections

Retrospective reports of eyes receiving triamcinolone indicate a per-injection endophthalmitis risk between zero and 0.87%.¹⁶ There was one case of endophthalmitis out of 3159 injections of triamcinolone (0.03%) performed in the SCORE and DRCR.net trials.¹⁶ Interestingly, in the DRCR.net trials 3 cases of endophthalmitis from 3226 receiving intravitreal Ranibizumab were reported.

ANCHOR and MARINA studies demonstrated a low rate of endophthalmitis in eyes receiving intravitreal Ranibizumab. At 2 years there were only three cases of endophthalmitis out of 5921 injections (0.05%) in ANCHOR. MARINA and the pivotal trial for pegaptanib (VISION) each reported a 0.05% per-injection rate of presumed endophthalmitis. The PACORES Trial utilized Bevacizumab and reported a higher incidence of 0.16%, whereas other large, retrospective trials reported rates ranging from a 0.019–0.07%.¹⁶

Immunocompromised patients may be at greater risk of developing endophthalmitis. Data from several studies suggest a 0.11% per-injection risk associated with intravitreal antivirals.¹⁶

2.1.4 Other

In a systematic review of the literature, the overall pooled estimate (1972–2002) of the incidence of acute endophthalmitis after penetrating keratoplasty (PK) was 0.382% based on 90,549 PK's. The rate of endophthalmitis from 1972 to 1999 was 0.392%, whereas the rate from 2000 to 2003 was 0.200%, representing an almost 2-fold decrease in the incidence.¹⁷

After sustaining open globe injury, the chance of developing endophthalmitis is estimated to be approximately 7% with studies ranging between 0% and 13%. Injuries including intraocular foreign bodies may have higher rates of endophthalmitis, ranging from 11% to 30%, highest in a study of rural penetrating trauma.¹⁸

2.2 Endogenous endophthalmitis

This infection occurs when microorganisms in the bloodstream cross the blood-ocular barrier to infect the intraocular tissues. It is relatively rare, accounting for only 2–8% of endophthalmitis cases and these patients usually have underlying diseases such as diabetes, human immunodeficiency virus infection, intravenous drug abuse, renal failure on dialysis, cardiac disease, malignancy, immunosuppressive therapy, or indwelling catheters that predispose them to infection.¹⁸

3. Clinical

3.1 History and symptoms

Acute postoperative endophthalmitis refers to infectious endophthalmitis that occurs shortly after ocular surgery or intravitreal injection. Patients usually present within 1–2 weeks of surgery and often within a few days. A history of complicated cataract surgery, including posterior capsular rupture may be identified. Symptoms of acute post-operative endophthalmitis include pain, visual loss, eye redness and swollen eyelid. Almost all subjects had symptoms in the Endophthalmitis Vitrectomy Study (EVS), with 94.3% of patients reporting blurred vision, 82.1% reporting red eye, 74.3% reporting pain, and 34.5% reporting a swollen lid.¹⁹

Chronic postoperative endophthalmitis is characterized by insidious inflammation occurring usually weeks to months after intraocular surgery. It consists of recurrent

episodes of low-grade inflammation and pain may or may not be present. It may rarely be precipitated by YAG-laser capsulotomy. Patients may describe visual symptoms including progressive visual loss and floaters. Inflammation may initially respond to steroids but usually recurs following steroid taper.

Endophthalmitis following bleb-surgery can occur in the early postoperative period, but occurs more often months to years after filter surgery. One recent large study showed a mean time between glaucoma filtering surgery and endophthalmitis of 19.1 months, with a range of 3 days to 9 years.²⁰ A history of anti-metabolite use is relevant because these can promote a thin, cystic bleb that becomes vulnerable to infection and leakage. Presentation is similar to acute postoperative endophthalmitis and is usually with redness, reduced vision and pain.

Diagnosing posttraumatic endophthalmitis immediately after the ruptured globe injury can be difficult because of trauma-induced inflammation and the disruption of normal anatomy. Traumatic endophthalmitis may occur within a few days or up to several weeks between injury and onset. Symptoms include decreasing vision, increasing pain, or a greater than expected degree of pain. The course of posttraumatic endophthalmitis can be affected by factors including, the type of injury, the presence or absence of an intraocular foreign body (IOFB) and the time between injury and treatment.

3.2 Signs

Table 2 outlines the signs of endophthalmitis according to classification. Common signs of acute postoperative endophthalmitis include decreased visual acuity, lid swelling, conjunctival and corneal edema, anterior chamber cells and fibrin, hypopyon, vitreous inflammation, retinitis, and blunting of red reflex.¹⁸ Retinal periphlebitis may be an early sign. Bleb-associated endophthalmitis has similar features. It is characterized by sudden intraocular inflammation in an eye that has been quiet for months or years following filtering surgery. Bleb purulence is noted in most patients, with an appearance of a milky white bleb. In the absence of vitritis and hypopyon, the term blebitis is given. This tends to respond to conservative measures with fortified topical antibiotics and systemic therapy. Endophthalmitis following intravitreal injections also follows a similar course to acute postoperative endophthalmitis. However, distinction from sterile endophthalmitis is sometimes possible. This may represent inflammation resulting from reaction to the drug, components of the drug vehicle, or sterile microbial toxins in the formulation. Additionally, triamcinolone acetonide crystals can migrate into the anterior chamber and mimic a hypopyon.¹⁸ Gravity induced shifting of this material may distinguish it from a true hypopyon, as well as the absence of anterior chamber flare or fibrin.

Delayed (chronic) endophthalmitis can occur in the early postoperative period but usually manifests weeks to months after surgery, with a chronic low grade inflammation that is initially responsive to topical steroids but rebounds following taper. There is usually the absence of a hypopyon. The uveitis may be granulomatous with large keratic precipitates on the cornea or precipitates on the intraocular lens. A white intracapsular plaque is commonly observed with *Propionibacterium* infection, often associated with retained lens particles and sequestration of organisms. The plaques can also be seen less frequently with other bacteria and fungal infections. Stringy white infiltrates and “fluff balls” or “pearls-on-a-string” near the capsular remnant are characteristic but not pathognomonic of fungal infection. Vitreous cellular reaction is usually mild, but dense, diffuse vitritis can be seen in some infections, notably with *S* epidermidis.¹⁸

Acute postoperative endophthalmitis

- Reduced visual acuity (<5/200 in 86%*)
- Afferent papillary defect (11.7%*)
- Lid edema
- Conjunctival injection and swelling
- Conjunctival discharge (+/- purulent)
- Corneal edema
- Anterior chamber inflammation – cells, flare, fibrin, hypopyon
- Vitreous inflammation – anterior vitreous cells, haze (unable to see retinal vessel 79.1%*)
- Signs of intraocular surgery
- +/- signs of complicated cataract surgery– wound leak, abscess, vitreous incarceration etc.
- Retinal and choroidal involvement
- Signs of extraocular extension in advanced cases

Delayed (chronic) postoperative endophthalmitis

- Low-grade anterior chamber inflammation (granulomatous)
- +/- mutton-fat keratic precipitates
- Vitritis (common)
- Fibrin, hypopyon
- Enlarging capsular plaque (may require maximal dilation or even gonioscopy to visualize)
- Signs that may suggest fungal cause – persistent corneal edema, a corneal infiltrate, a mass in the iris or ciliary body, necrotizing scleritis, “pearls -on-a-string” in the anterior chamber, paradoxical worsening of the inflammatory course after steroid therapy

Filtering bleb-associated endophthalmitis

- White milky bleb containing pus
- Severe anterior chamber inflammation +/- hypopyon
- Vitritis

Posttraumatic endophthalmitis

- Intraocular foreign body
- Lid edema & Chemosis
- Greater than expected anterior chamber cell inflammation, fibrinoid response
- Hypopyon
- Vitritis, vitreous opacification
- Retinal involvement if the view allows – retinitis, vasculitis
- Extension of exudate from a wound
- Purulence

Intravitreal injection

- Similar to acute postoperative endophthalmitis
- Differentiate from sterile endophthalmitis (Triamcinolone acetonide crystals in the anterior chamber, gravity-induced shifting of material, absence of anterior chamber flare or fibrin)

Extension from infection

- Corneal abscess or infective scleritis
-

* Endophthalmitis Vitrectomy Study Table.1 Baseline characteristics by treatment group¹⁹

Table 2. Signs of exogenous endophthalmitis

4. Etiology

Endophthalmitis type	%
Acute postoperative endophthalmitis¹⁹	
Gram positive coagulase negative growth	46.9 (67% of positive cultures)
Other gram positive growth	15.5 (22.4% of positive cultures)
Gram negative growth	4.1 (5.8% of positive cultures)
Polymicrobial	2.9
No growth	30.7
Chronic postoperative endophthalmitis¹⁸	
Propionibacterium species	63
Staph epidermidis	16
Candida parapsilosis	16
Corynebacterium species	5
Other: Actinomyces, Nocardia, Achromobacter, Cephalosporium, Acremonium, Paecilomyces, and Aspergillus species	
Filtering bleb-associated endophthalmitis²²	80% positive culture (several cases had more than one species of strep or staph)
Streptococcus species	41 % of positive culture
Staphylococcus species	28 % of positive culture
Enterococcus species	23 % of positive culture
Gram negative	
Post traumatic endophthalmitis	
Gram positive organisms	~75 (~20% due to Bacillus)
Gram negative organisms	
Fungal	
Intravitreal injection	
Similar to acute postoperative with coagulase-negative staphylococcus	
Other: Streptobacillus parasanguis, Mycobacterium chelonae, Streptobacillus species	

Table 3. Causative organisms

4.1 Organisms

Table 3 outlines the organisms involved in exogenous endophthalmitis. Gram-positive bacteria cause the majority of exogenous endophthalmitis cases. Coagulase-negative staphylococcal isolates are the most common cause of postoperative endophthalmitis cases. Other species involved include *Staphylococcus aureus*, streptococci, enterococci, and Gram-positive rods such as *Bacillus*. Gram-negative bacteria were isolated from a relatively low number of post-operative endophthalmitis cases. According to the Endophthalmitis Vitrectomy Study (EVS), around 69% had culture positive result, and of those around 70% were gram-positive coagulase negative organisms and only 2.2% enterococcus species. The literature suggests that the spectrum of organisms may be shifting with the introduction of prophylactic antibiotics. Enterococcus spp. were found to cause 25.3% of all cases of endophthalmitis, suggesting an increased proportion of cases of enterococcal endophthalmitis. This relative increase in the proportion of endophthalmitis cases due to Enterococcus spp. was attributed to the introduction of intracameral cefuroxime as a means of anti-bacterial prophylaxis. Although intracameral cefuroxime was quite effective in reducing the overall number of endophthalmitis infections, enterococci are relatively resistant to cefuroxime.¹

Both Gram-positive and Gram-negative organisms can cause post-traumatic endophthalmitis. Polymicrobial infections and fungal infections also have been reported. Gram-positive organisms constitute the majority of pathogens in post-traumatic endophthalmitis. Among Gram-positive microbes, *Staphylococcus epidermidis* is isolated most commonly. Although *Bacillus cereus* may not be as common as *Staphylococcus epidermidis*, it is relatively frequently associated with IOFBs and is associated with a very poor visual prognosis. The incidence of post-traumatic endophthalmitis caused by *Pseudomonas* species as the only isolate ranges from 0% to 23.1%²¹

The spectrum of causative organisms associated with bleb-associated endophthalmitis has been reported to differ from that of acute-onset endophthalmitis after cataract surgery. The more virulent streptococcal species and gram-negative organisms are more common causes of delayed-onset bleb-associated endophthalmitis. In a study at Bascom Palmer Eye Institute between 1996 and 2001, streptococcal species and gram-negative organisms, followed by staphylococcal species were found to be the commonest organisms. Gram-negative organisms and *Haemophilus influenzae* are also commonly isolated.²²

The spectrum of organisms isolated in chronic postoperative endophthalmitis is quite different to other categories of exogenous endophthalmitis, with *Propionibacterium* species accounting for the majority of cases and fungal organisms comprising a significant proportion. A review of endophthalmitis cases presenting more than 4 weeks after cataract surgery found 63% *Propionibacterium* species, 16% *S epidermidis*, 16% *Candida parapsilosis*, and 5% *Corynebacterium* species.¹⁸

5. Differential diagnosis

5.1 Retained lens fragment

Retention of lens cortex or nucleus may cause significant intraocular inflammation in an acute or chronic setting. Operative details from the cataract surgeon and visualizing the fragments may aid in differentiating this condition from endophthalmitis.

5.2 TASS, toxic anterior segment syndrome

This condition is due to marked inflammation due to noninfectious substances that enter the eye, such as bacterial toxins, preservatives, cleaning compounds or intraocular solutions. This condition can sometimes be differentiated from endophthalmitis by its rapid onset (within 12-24hrs following surgery or intravitreal injection), lack of pain or redness, diffuse corneal edema and lack of isolated organisms by gram stain or culture.

6. Prevention

6.1 Risk factors

The risk of developing acute postoperative endophthalmitis is associated with a number of factors such as the presence of eyelid or conjunctival disease, the patient's general condition including, diabetes, skin disease, the use of immunosuppressive drugs, the type of intraocular surgery performed, and intraoperative complications. Table 4 outlines risk factors associated with endophthalmitis according to the category.

Endophthalmitis category	Risk factors
Acute postoperative endophthalmitis	<p>Preoperative Age, diabetes, chronic bacterial blepharitis, active conjunctivitis, lacrimal drainage system obstruction, eyelid pathology such as ectropion</p> <p>Operative Wound abnormalities, vitreous loss, prolonged surgery, contaminated irrigation solutions, polypropylene haptics</p> <p>Postoperative Wound leak, vitreous incarceration, contaminated eye drops</p>
Chronic postoperative endophthalmitis	Unclear
Traumatic endophthalmitis	Retained IOFB, lens rupture, delayed timing of primary repair, age greater than 50 years, female gender, large wound size, location of wound, ocular tissue prolapse, placement of primary intraocular lens (IOL), and rural locale
Bleb-associated endophthalmitis	Antimetabolites (5-FU, MMC), inferior bleb location, tube exposure after conjunctival erosion in drainage devices, younger age in drainage devices, blepharitis, diabetes, limbus-based conjunctival flaps, silk conjunctival sutures, early postoperative complications and bleb manipulation from revision or needling

Table 4. Risk factors for endophthalmitis

Traumatic endophthalmitis has been associated with retained IOFB, lens rupture, delayed timing of primary repair, age greater than 50 years, placement of primary intraocular lens (IOL), and rural locale. The composition of IOFB may play a role with infection, with non-metallic objects having a higher risk of infection. These foreign bodies may be contaminated with infectious material and intuitively, may increase the risk of infection. Treatment delay has been shown to be an important factor in the development of post-traumatic endophthalmitis. Delayed primary repair, especially more than 24 hours, is considered to be a risk factor for post-traumatic endophthalmitis in the absence of an IOFB. Contaminated injuries can be significant risk factors for the development of infection. For example, penetrating globe injuries by a cat claw, contaminated utensils, or injuries sustained during dental procedures are all considered highly contaminated. Also, the likelihood of injury with a contaminated object is increased in rural settings where trauma frequently occurs after farm-related accidents. The increased risk of infection with organic matter may be due to an increased microbial inoculum, greater extent of injury, and possibly more virulent organisms that may be resistant to antibiotics.

Bleb-associated endophthalmitis has been associated with antimetabolites (5-FU, MMC), inferior bleb location, tube exposure after conjunctival erosion in drainage devices, younger age in drainage devices, blepharitis, diabetes, limbus-based conjunctival flaps, silk conjunctival sutures, early postoperative complications and bleb manipulation from revision or needling. In a study at Bascom Palmer, potential risk factors and clinical features among the study population included history of bleb leak, bleb manipulations (needling, compression sutures, laser suture lysis, bleb revision, and autologous blood injection), bleb defects, inferior bleb location, and nasolacrimal duct obstruction.²²

6.2 Prophylaxis

6.2.1 Pre-operative

Treatment of local ocular factors, such as blepharitis, conjunctivitis, eyelid pathology (ectropion or entropion) and nasolacrimal duct obstruction is imperative before elective intraocular surgery. Systemic risk factors such as diabetes and immunosuppression should be optimized. Figure 1 is an outline of one approach for prophylaxis against endophthalmitis following cataract surgery.

The low incidence of endophthalmitis makes the study of risk factors and preventative measures difficult. Pre-operative application of topical antibiotics is becoming common practice in the USA and Canada. In a recent survey of Canadian ophthalmologists we found preoperative topical antibiotics were routinely used by 78% of respondents.²³ There are studies that suggest the use of preoperative late-generation fluoroquinolones decreases the incidence of infection,²⁴ but at this stage there are no large, prospective, randomized controlled trials that demonstrate this. Despite the lack of level I evidence, pre-operative topical antibiotics probably have a role. They have been shown to decrease bacterial load and penetrate the anterior chamber to achieve significant intraocular concentration.

In terms of prophylaxis for traumatic endophthalmitis, prophylactic perioperative systemic antibiotics are commonly administered for ruptured globes, but no prospective evidence for its benefit has been established. Despite this it is common practice to give systemic antibiotics either broad spectrum intravenous or oral.

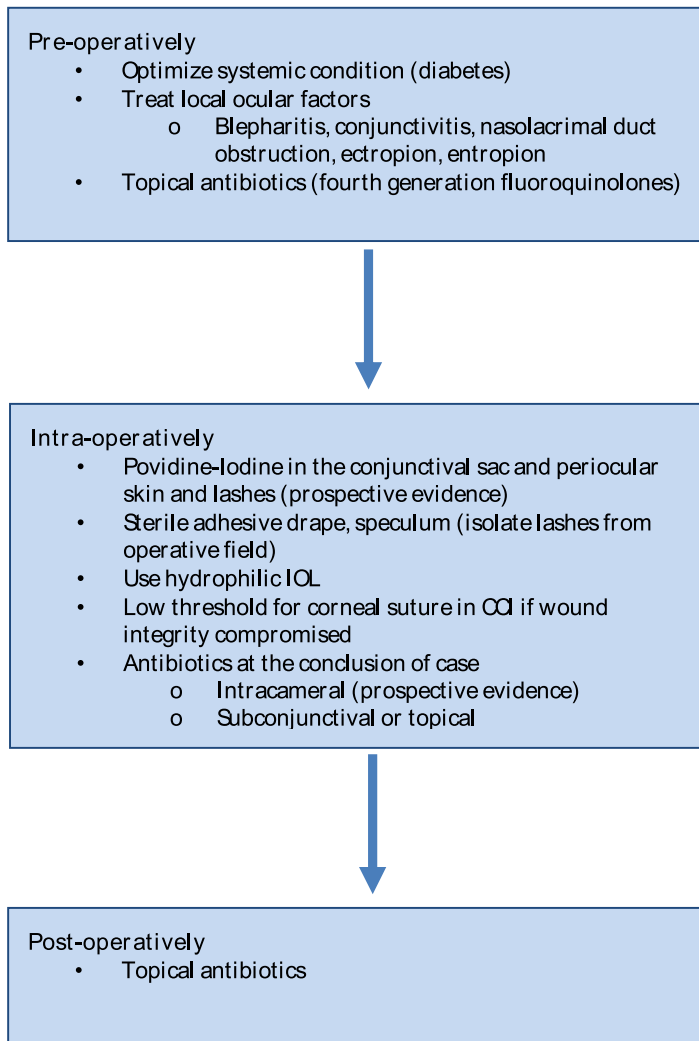


Fig. 1. Guide for prophylaxis against acute postoperative endophthalmitis following cataract surgery

6.2.2 Intraoperative

A review of the literature by Ciulla et al. supported the role of Povidine-Iodine in prophylaxis against endophthalmitis.²⁵ Povidine-Iodine as a prophylactic technique has been demonstrated to reduce the risk of endophthalmitis in a prospective study. Instillation of Povidine-Iodine should be instilled into the conjunctival sac and incorporate the lashes and surrounding periocular skin within the surgical field. Cutting of the eyelashes is not considered necessary, however, modern drapes with a speculum should exclude lashes from the surgical field.

The European Society of Cataract and Refractive Surgery conducted the first prospective, randomized, multicentre clinical trial concerning antibacterial prophylaxis of postoperative endophthalmitis.³ They investigated the use of intracameral antibiotics (cefuroxime 1 mg /0.1 cc) following phacoemulsification. In the absence of cefuroxime administration there was a 5- to 6-fold increased risk for endophthalmitis, which was in line with retrospective results reported from Sweden. In addition to the administration of intracameral cefuroxime at the time of surgery, other factors in that study that were associated with a reduction in the risk for endophthalmitis were the use of acrylic material for the IOL optic and the choice of scleral tunnel as the site of incision. It is conceivable that hydrophilic polymer surfaces may be useful in avoiding the development of bacterial colonies by possibly inhibiting or delaying bacterial colonization. Well-constructed clear corneal incisions are necessary to prevent microleaks and the risk of intraocular contamination. To eliminate these risks, a single interrupted 10-0 nylon suture should be applied across an incision where the structural integrity is in question.

Other drugs are also being investigated for intracameral use, including fluoroquinolones, and some centres utilize Vancomycin.²⁶ Caution needs to be taken when using these drugs for prophylaxis because of the potential for resistant strains, which can become problematic in the treatment of established cases. There is evidence in the literature to suggest a change in the spectrum of pathogens that cause postoperative endophthalmitis and growing resistance to certain prophylactic antibiotics.²⁷ There are also other issues with intracameral antibiotics including, dosing errors and potential toxicity.

Some ophthalmologists utilize intraoperative subconjunctival antibiotics but the evidence is tentative. There are reports that demonstrate a reduced incidence of endophthalmitis with subconjunctival antibiotics. Experimental models have shown adequate anterior chamber concentrations following the administration possibly making it a valid prophylactic option. Antibiotic soaked collagen shields placed in the eye at the conclusion of surgery are also utilized but the evidence is limited at this stage.

Intravitreal antibiotic administration in the setting of trauma is controversial. Some authors advocate this in all cases of penetrating eye injuries, while others recommend it in the presence of risk factors.²¹ Suggested regimen includes Vancomycin 1mg/0.1cc and Ceftazidime 2.25mg/0.1cc.

6.2.3 Post-operative

The use of topical antibiotics postoperatively is common practice despite limited evidence. Topical antibiotics such as the fourth generation fluoroquinolones have good penetration and can achieve therapeutic concentrations in the anterior chamber. However, these concentrations are not achieved in the vitreous cavity. It has been suggested that post-operative antibiotics may be more appropriately used in high dose and short duration to reduce the risk of emergent resistant strains.

7. Management

7.1 Workup & treatment of acute postoperative endophthalmitis

Figure 2 outlines a management algorithm for suspected acute postoperative endophthalmitis. In the early stage, a diagnosis of endophthalmitis can be difficult to make because signs can be mild. Close observation (every 6 hrs) is recommended for a patient presenting with symptoms suggestive of endophthalmitis but not enough signs to confirm because inflammatory signs can escalate rapidly. In patients with signs suggestive of endophthalmitis, including significant anterior chamber and vitreous inflammation, +/- hypopyon and reduced visual acuity, urgent management is required. Visual acuity should be obtained to determine whether VA \geq HM or PL, as this would influence treatment. A thorough ocular examination must be performed and post-operative complications such as wound leak should be detected. An ultrasound should be done if the view precludes a good posterior segment examination. Retinal and/or choroidal detachment can be ruled out, and signs such as vitreous opacities and/or chorioretinal thickening (severe cases) provide further support for a diagnosis of endophthalmitis.

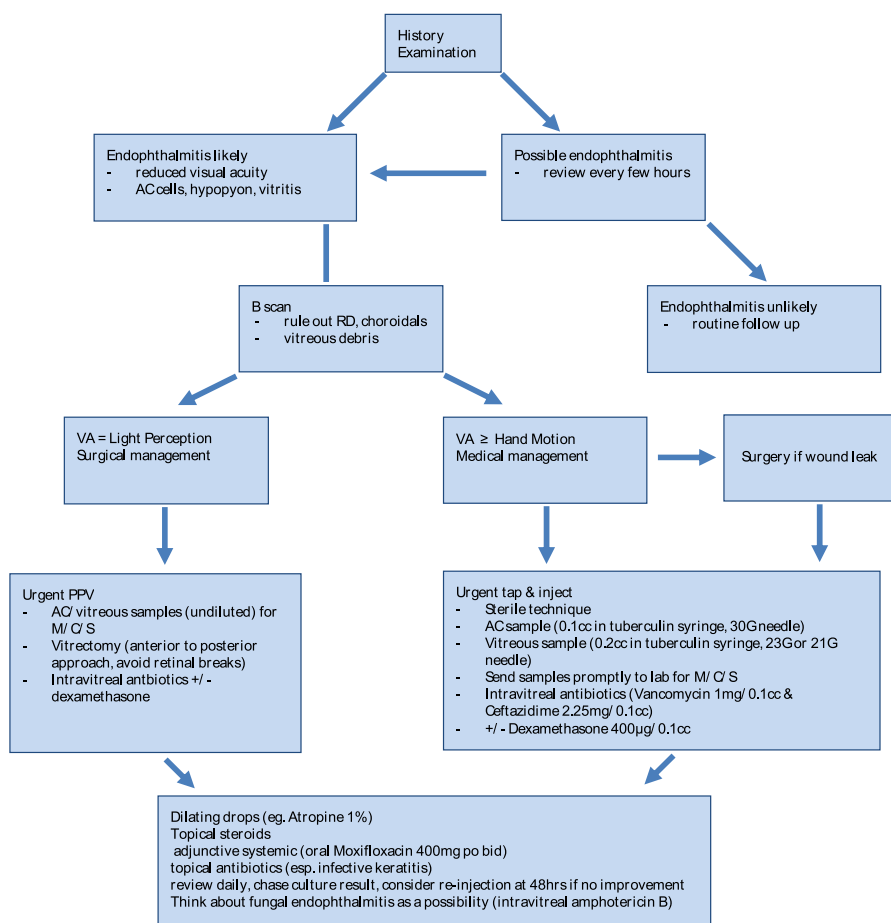


Fig. 2. Management algorithm in acute postoperative cataract endophthalmitis

The EVS addressed the relative efficacy of immediate PPV versus vitreous tap in the treatment of postoperative endophthalmitis. Patients presenting with light perception only visual acuity had a threefold-improved chance of obtaining 20/40 vision after immediate vitrectomy (33%) compared to vitreous tap or biopsy (11%). There was a 56% chance of obtaining 20/100 or better vision after immediate PPV compared to 30% chance after vitreous tap or biopsy. In patients presenting with vision of hand motions or better, there was no significant difference between the two treatment groups in final visual acuity. Based on the EVS, aqueous and vitreous samples can be obtained at the time of PPV, if it is indicated. It is worth mentioning that the EVS excluded patients presenting with no light perception visual acuity or significant opacification of the anterior chamber to the point of obscuring iris tissue, so that more virulent organisms may have been excluded. Also, the EVS studied endophthalmitis in post cataract surgery, and these results may not apply to other intraocular surgeries.

An anterior chamber tap, vitreous tap and intravitreal antibiotic injection should be done aseptically. Povidine-iodine, surgical drape, lid speculum, and an operating microscope may be used. A 30-gauge needle attached to a 1cc tuberculin syringe is inserted through the limbus into the anterior chamber and an aqueous specimen is aspirated without collapsing the anterior chamber. A quantity of approximately 0.1 cc can usually be obtained. Outside the operating room, a vitreous specimen may be obtained either by vitreous needle tap (23G or 21G in a non-vitrectomized eye) or by vitreous biopsy with a cutting/aspirating probe such as The Intrector® portable vitrectomy instrument (Insight Instruments, Inc.). A dry vitreous specimen can be obtained with the cutter in the operating room (before the infusion is turned on). Samples should be obtained for Gram stain, culture (aerobic, anaerobic, and fungal), as well as antibiotic sensitivities. Culture inoculation by the surgeon or the laboratory within minutes of obtaining specimens is ideal to maximize recovery of organisms. Anaerobic cultures should be kept for at least 14 days to recover slow-growing species (for example, *P. acnes*) and fungal cultures should be kept for several weeks. There may be a role for PCR in the detection of fastidious organisms.

Current recommendations for empirical therapy are vancomycin 1.0 mg/0.1cc and ceftazidime 2.25 mg/ 0.1cc. Amikacin 400 µg/0.1cc can be considered in exchange for ceftazidime in β-lactam sensitive patients. Retinal toxicity is a potential complication of intravitreal antibiotic therapy. Toxicity has not been studied well for most antibiotics and it is possible that toxicity may develop with repeat injections. Most studies have been in animal models and application to humans may not be ideal. Gentamicin retinal toxicity is a well-known phenomenon, with macular infarction described even with lower doses (0.1mg). Retinal toxicity is less common but also reported with amikacin. Intravitreal ceftazidime appears safer than aminoglycosides, but it can cause retinal toxicity when given at doses higher than the recommended 2.25 mg/0.1 cc. A study in squirrel monkeys (vitreous cavity volume of 1/5th to 1/7th the human volume) showed retinal toxicity with a ceftazidime dose of 10 mg in 0.1cc and no retinal toxicity with 2.25mg.²⁸ The dose of intravitreal antibiotic is particularly relevant in eyes that have had an air-fluid exchange or patients that have silicone oil or gas filled eyes, so that dose adjustment should be considered.^{29,30} Vancomycin has been nontoxic in intravitreal doses up to 2mg in pigmented rabbits.³¹ The role of fourth generation fluoroquinolones as intravitreal therapy remains unclear and optimal dosage in the human eye is not known. Experimental data suggests a Moxifloxacin dose of ≤160ug/0.1cc is probably safe.³²

The major limitation of intraocular antimicrobials is the short duration of action. Reinjection should be considered if the infection fails to stabilize or improve more than 48 hours after the first injection. Based on consensus view, the EVS protocol recommended reinjection if the infection was worsening at 36 – 60 hours after initial injection. The rationale for reinjection is based on the observation of rapid half-life elimination of some intravitreal antibiotics in animal eyes.^{33,34} In addition, 48 hours after treatment, culture results become available. If cultured organisms are likely to be resistant to the initially injected antibiotics and the infection is not improving, alternative antibiotics could be used.

Most antimicrobials penetrate the vitreous cavity poorly after intravenous injection because of the blood-eye barrier. The EVS showed no difference in visual acuity or media clarity with or without intravenous antibiotics when given in addition to intravitreal antibiotics. These results led many physicians to avoid intravenous antibiotics in post-operative endophthalmitis. However, recent evidence demonstrates the intraocular penetration of oral moxifloxacin and gatifloxacin.^{35,36} Ninety percent minimal inhibitory concentrations (MIC90) were achieved after two 400 mg oral doses against many Gram-positive and Gram-negative pathogens implicated in postoperative endophthalmitis. Given their favorable characteristics of broad coverage, good tolerability, and ease of oral administration, these agents are promising adjunct therapies for all forms of exogenous endophthalmitis.

Currently, there is no consensus regarding the use of intraocular steroids in the management of endophthalmitis. There are theoretical advantages including modulation of the host inflammatory response to minimize ocular damage. Some retinal physicians advocate systemic steroids. The EVS used oral steroids, but the benefit was not evaluated. An advantage was found with systemic steroids in a retrospective study compared to only topical or no steroids.³⁷ Das et al evaluated the efficacy of intravitreal dexamethasone in the management of exogenous endophthalmitis and reported an early reduction in inflammation, but with no influence on final visual outcome.³⁸ In another prospective, randomized trial of 29 patients with endophthalmitis after cataract surgery, Gan et al showed a trend towards better visual acuity with adjuvant intravitreal dexamethasone. In contrast, a retrospective study found patients that received intravitreal corticosteroids had a reduced likelihood of achieving a 3-line improvement in visual acuity.³⁹ At this stage, the use of intravitreal dexamethasone and timing is dependent upon surgeon preference.

Topical antibiotic therapy is indicated when there is concurrent infective keratitis. Dilating drops such as atropine 1% bid are beneficial to minimize posterior synechiae and reduce ciliary spasm.

7.2 Surgical approach

Figure 3 outlines an approach to vitrectomy surgery in endophthalmitis. If the patients systemic condition allows, general anesthesia may be the anesthetic of choice because obtaining adequate local anesthesia for an inflamed painful eye can be difficult. Following the application of povidine-iodine solution, draping and lid speculum, the corneal or scleral wound should be closed with 10-0 nylon suture. An attempt should be made to aspirate anterior chamber fluid (around 0.1cc) with a 30G needle and 1cc tuberculin syringe. An infusion cannula (25G or 23G or 20G 6mm) is inserted pars plana if the view allows. If anterior segment opacity precludes view of the infusion cannula, an anterior chamber maintainer can be utilized initially. The infusion is kept off to allow for an undiluted vitreous sample, which is obtained with manual aspiration of a tuberculin syringe

connected to a 3-way stopcock, connected to the aspiration tubing of vitrectomy probe. Both samples are either sent quickly to the microbiology laboratory for urgent gram stain, culture and sensitivities or the material is plated directly onto blood agar, chocolate agar, Sauboraud's media, thioglycolate broth and placed on two glass slides for Gram and Giemsa stains.

- Consider general anesthesia
- Prep & drape
- Suture the corneal wound with a 10-0 nylon
- Insert 3 ports (25 or 23G) pars plana & place plugs
- Anterior chamber tap (27 or 30G needle, tuberculin syringe)
- Place the infusion line in the anterior chamber when the view is very poor, but keep the infusion off. Alternatively consider a 20G 6mm infusion line pars plana
- Vitreous sample (undiluted) – connect cutter/aspiration line to a 3-way stop cock connected to a tuberculin syringe and manually aspirate 0.2-0.3cc of vitreous fluid
- Send anterior chamber and vitreous samples for urgent M/C/S or inoculate onto appropriate plates and slides
- Methodical approach from anterior to posterior
- Clear anterior chamber of fibrin/inflammatory debris/membrane using cutter/aspiration via a limbal approach
- Switch the infusion to pars plana port once the view allows to confirm position
- Consider endoscopic approach in the presence of a very poor view if available
- Core vitrectomy
- Peripheral vitrectomy if visualization allows
- Measures to avoid retinal breaks
 - Refrain from inducing PVD or shaving the vitreous base if the retina is necrotic and severely inflamed
- No air-fluid exchange is done unless indicated
- Check sclerotomies & ensure sealed
- Inject intravitreal antibiotics ceftazidime 2.25mg/0.1cc and vancomycin 1mg/0.1cc
 - Consider reducing the antibiotic dose in gas/air filled eyes or silicone oil filled eyes to reduce the risk of retinal toxicity. Especially for ceftazidime.
- Consider intravitreal dexamethasone 400µg/0.1cc

Fig. 3. Surgical approach in acute post-operative (cataract surgery) endophthalmitis

Infusion is then started and the anterior chamber is cleared to enable visualization. This includes careful removal of membranes and avoiding trauma to the iris with resultant hyphema. A core vitrectomy is then performed and the vitrectomy is carried posteriorly. Attempts were made to clear $\geq 50\%$ of the vitreous with no aim of inducing a posterior vitreous detachment in the EVS to avoid secondary complications.¹⁹ Aggressive removal of vitreous in the vicinity of inflamed and necrotic retina has the potential risk of creating retinal tears and detachment. Eyes with a posterior vitreous detachment allow for a more complete vitrectomy. These eyes may have inflammatory debris over the posterior pole that can be gently aspirated. In situations where visibility is too poor to adequately define posterior vitreous, attempts to clear reformed anterior chamber debris/membrane should be performed. Membranes can also develop on the posterior aspect of the intraocular lens and this should be cleared. If the opacity precludes adequate view following core vitrectomy, the procedure can be discontinued rather than risk retinal/choroidal trauma with the cutter. Intraoperative complications in this setting include retinal breaks and hemorrhage as well as choroidal hemorrhage, which can be devastating. Retinal breaks can be treated with laser photocoagulation or cryotherapy and gas or silicone oil tamponade. However, this poses dosing issues when injecting intravitreal antibiotics. One step to avoid choroidal hemorrhage includes maintaining a steady intraocular pressure during surgery. If this complication develops, the bottle height should be raised to occlude the source, but in severe cases it can lead to loss of the eye. Intravitreal antibiotics should be injected pars plana at the conclusion of the case, once the sclerotomy sites are sealed. Modification in the dose of ceftazidime may be required in eyes with gas or oil fill to account for the reduction in vitreous fluid. Intravitreal dexamethasone is optional and given at the surgeons discretion.

Kuhn and Gini recommended an approach not based on presenting acuity alone, but on the overall clinical picture and course.^{40,41} In the presence of a poor reflex or absent retinal detail at presentation, or no improvement within 24 h of initial conservative therapy with intravitreal injections, PPV was offered to the patient. Their vitrectomy technique differed significantly from that of the EVS. They defined a 'complete' PPV as that starting at the anterior segment and working posterior which included, utilizing temporary keratoprosthesis if necessary, evacuating the AC of fibrin and cellular material, and then working purposely posterior towards the retina with engagement and removal of the posterior hyaloids and irrigation of any macular hypopyon and debris. Conservative shaving of the vitreous base was recommended depending on limitations in visualization. Silicone oil was an option for necrotic or detached retina or those otherwise having multiple tears. In their non-randomized consecutive series of 47 patients, 91% achieved a visual acuity of 20/40 or better compared to 53% in the EVS. In this limited report, no retinal detachments developed (8.3% EVS), there were no lost eyes from phthisis, and no additional PPV was required. The authors base these positive results on advances in vitrector technology and the development of wide-angle viewing systems since the EVS. The development of the endoscope in vitrectomy surgery has likewise increased the amount of patients, previously excluded by the EVS inclusion criteria, to more aggressive management.⁴²

7.3 Treatment in other causes of exogenous endophthalmitis

Application of the EVS to traumatic endophthalmitis may not be appropriate because of differences in organisms and potential for concurrent posterior injury with trauma. In severe cases, vitrectomy should be strongly considered to clear infected vitreous and

manage coexisting injury including vitreous hemorrhage and retinal breaks. However, significant challenges are encountered due to altered anatomy and visualization difficulties.

Vancomycin (1 mg/0.1 cc) has been the treatment of choice for bacterial infection, with broad coverage of Gram-positive bacteria implicated in chronic postoperative endophthalmitis.⁴³ If fungi are implicated, intravitreal amphotericin B (5-10 µg/0.1 mL) should be considered. Voriconazole or miconazole can be considered if organisms are resistant to amphotericin B. PPV is often advocated for treatment of chronic postoperative endophthalmitis. Removal of vitreous infiltrates with total capsulectomy, intravitreal antibiotic and intraocular lens removal or exchange has the lowest recurrence rate.⁴³ Even with these interventions, recurrent inflammation may still occur. The effectiveness of orally administered fourth-generation quinolones, such as gatifloxacin and moxifloxacin, may obviate the need for such aggressive procedures in the future.

- Insert infusion line infero-temporal 3.5mm from the limbus
- Create superonasal and superotemporal transconjunctival scleral tunnel sclerotomies for the light pipe and vitrector
- Create a limbal paracentesis and inject viscoelastic into the bag and anterior chamber
- Place iris hooks to allow better visualization of the zonular apparatus
- Create a superior corneal wound
- Rotate the IOL out of the bag
- Cut the optic of the foldable IOL with an intraocular scissors about $\frac{3}{4}$ of its length and remove in one piece
- Insert an intraocular forceps through the clear corneal incision between the sutures to grasp the anterior capsule and stretch it to expose the zonules
- Use the vitrector through the pars plana cannula to cut the zonules 360°
- The entire capsular bag is then removed with the intraocular forceps and sent for gram stain and inoculation onto bacterial and fungal media
 - At least 2 medias for anaerobic culture should be used
- Suture the corneal wound
- Perform core vitrectomy
- Posterior hyaloid detachment, vitreous base shaving and aspiration of deposits can be carried out
- Aspirate remaining viscoelastic
- Inject intravitreal Vancomycin 1mg/0.1cc

Fig. 4. Technique for vitrectomy in eyes with chronic endophthalmitis and a foldable acrylic IOL

Many retinal surgeons extrapolate from EVS data and apply this to the treatment of bleb-associated endophthalmitis. However, this may not be appropriate and a lower threshold for PPV may be warranted given the more virulent organisms involved. However, insertion of sclerotomies should be away from the infected bleb. Also, intensive fortified topical antibiotics should be utilized where blebitis is also present.

Our future challenges will be staying ahead of the constant evolution of bacterial resistance. Bacteria have survived the primordial soup at the dawn of life and somewhere in the bacterial plasmids are the genetic codes to all forms of antibiotics that we may develop. Despite the power of bacterial evolution, future advancements in antibiotic pharmacology, surgical and prophylactic techniques will be necessary to keep us one step ahead.

8. References

- [1] Fintelmann RE, Naseri A. Prophylaxis of postoperative endophthalmitis following cataract surgery. Current status and future directions. *Drugs* 2010;70(11):1395-1409
- [2] Hatch WV, Cernat G, Wong D et al. Risk Factors for Acute Endophthalmitis after Cataract Surgery: A population-based Study. *Ophthalmology* 2009;116:425-430
- [3] Endophthalmitis Study Group, European Society of Cataract & Refractive Surgeons. Prophylaxis of postoperative endophthalmitis following cataract surgery: results of the ESCRS multicenter study and identification of risk factors. *J Cataract Refract Surg* 2007 Jun; 33 (6): 978-88c
- [4] West ES, Behrens A, McDonnell PJ, et al. The incidence of endophthalmitis after cataract surgery among the U.S. Medicare population increased between 1994 and 2001. *Ophthalmology* 2005; 112:1388-1394.
- [5] Taban M, Behrens A, Newcomb RL, et al. Acute endophthalmitis following cataract surgery: a systematic review of the literature. *Arch Ophthalmol* 2005 May; 123 (5): 613-20
- [6] Khan RI, Kennedy S, Barry P. Incidence of presumed postoperative endophthalmitis in Dublin for a 5-year period (1997-2001). *J Cataract Refract Surg* 2005; 31:1575-1581.
- [7] Ang GS, Varga Z, Shaarawy. Postoperative infection in penetrating versus non-penetrating glaucoma surgery. *Br J Ophthalmol* 2010;94:1571-1576
- [8] Stein JD, Ruiz D Jr, Belsky D, et al. Longitudinal rates of postoperative adverse outcomes after glaucoma surgery among medicare beneficiaries 1994 to 2005. *Ophthalmology* 2008;115:1109e1116.e7.
- [9] Chiselita D, Danielescu C. Postoperative endophthalmitis after non-penetrating deep sclerectomy. *Oftalmologia* 2010;54(1):36-40
- [10] Kunimoto DY, Kaiser RS, Wills Eye Retina Service. Incidence of endophthalmitis after 20- and 25-gauge vitrectomy. *Ophthalmology* 2007; 114(12): 2133-2137
- [11] Cohen SM, Flynn Jr HW, Murray TG, Smiddy WE. Endophthalmitis after pars plana vitrectomy. The Postvitrectomy Endophthalmitis Study Group. *Ophthalmology* 1995; 102: 705-712
- [12] Patel KC, Rahman R. Incidence of post-operative endophthalmitis following 23-gauge transconjunctival sutureless vitrectomy in the United Kingdom: a survey. *Eye* 2011 [epub ahead of print]
- [13] Bahrani HM, Fazelat AA, Thomas M et al. Endophthalmitis in the Era of Small Gauge Transconjunctival Sutureless Vitrectomy-MetaAnalysis and Review of Literature. *Sem Ophthalmol* 2010;25(5-6):275-282
- [14] Kunimoto DY, Kaiser RS, Wills Eye Retina Service. Incidence of endophthalmitis after 20- and 25-gauge vitrectomy. *Ophthalmology* 2007;114:2133-7
- [15] Scott IU, Flynn HW Jr, Dev S, et al. Endophthalmitis after 25-gauge and 20-gauge pars plana vitrectomy: incidence and outcomes. *Retina* 2008;28:138-42

- [16] Sampat KM, Garg SJ. Complications of intravitreal injections. *Curr Opin Ophthalmol* 2010;21(3):178-183
- [17] Taban M, Behrens A, Newcomb RL et al. Incidence of Acute Endophthalmitis Following Penetrating Keratoplasty – A Systematic Review. *Arch Ophthalmol* 2005;123:605-609
- [18] Lemley CA, Han DP. Endophthalmitis: a review of current evaluation and management. *Retina* 2007;27(6):662-680
- [19] Endophthalmitis Vitrectomy Study Group. Results of the Endophthalmitis Vitrectomy Study. A randomized trial of immediate vitrectomy and of intravenous antibiotics for the treatment of postoperative bacterial endophthalmitis. *Arch Ophthalmol* 1995;113:1479-1496
- [20] Busbee BG, Recchia FM, Kaiser R, et al. Bleb-associated endophthalmitis: clinical characteristics and visual out-comes. *Ophthalmology* 2004;111:1495-1503
- [21] Bhagat N, Nagori S, Zarbin M. Post-traumatic Infectious Endophthalmitis. *Surv Ophthalmol* 2011.[Epub ahead of print]
- [22] Song A, Scott IU, Flynn HW et al. Delayed-onset Bleb-associated endophthalmitis. Clinical Features and Visual Acuity Outcomes. *Ophthalmology* 2002;109:985-991
- [23] Hammoudi DS, Abdolell M, Wong DT. Patterns of perioperative prophylaxis for cataract surgery in Canada. *Can J ophthalmol* 2007;42:681-8
- [24] DeCroos FC, Afshari NA. Perioperative antibiotics and anti-inflammatory agents in cataract surgery. *Curr Opin Ophthalmol* 2008;19:22-26
- [25] Ciulla TA, Starr MB, Masket S. bacterial endophthalmitis prophylaxis for cataract surgery: an evidence-based update. *Ophthalmology* 2002;109:13-24
- [26] Anijeet DR, Palimar P, Peckar CO. Intracameral vancomycin following cataract surgery: An eleven year study. *Clin Ophthalmol* 2010;4:321-326
- [27] Recchia FM, Busbee BG, Pearlman RB et al. Changing trends in the microbiologic aspects of postcataract endophthalmitis. *Arch Ophthalmol* 2005;123:341-346
- [28] Campochiaro PA, Green WR. Toxicity of intravitreal ceftazidime in primate retina. *Arch Ophthalmol* 1992;110:1625-9
- [29] Hegazy HM, Kivilcim M, Peyman GA et al. Evaluation of toxicity of intravitreal ceftazidime, vancomycin, and ganciclovir in a silicone oil-filled eye. *Retina* 1999;19:553-7
- [30] Mieler WF, Glazer LC, Bennett SR et al. favourable outcome of traumatic endophthalmitis with associated retinal breaks or detachment. *Can J Ophthalmol* 1992;27:348-52
- [31] Pflugfelder SC, Hernandez E, Fliesler S et al. Intravitreal vancomycin. Retinal toxicity, clearance, and interaction with gentamicin. *Arch Ophthalmol* 1987;105:831-7
- [32] Thompson AM. Ocular toxicity of fluoroquinolones. *Clin Experiment Ophthalmol* 2007;35:566-77
- [33] Aguilar HE, Meredith TA, el-Massry A et al. Vancomycin levels after intravitreal injection. Effects of inflammation and surgery. *Retina* 1995;15:428-32
- [34] Barza M, Lynch E, Baum JL. Pharmacokinetics of newer cephalosporins after subconjunctival and intravitreal injection in rabbits. *Arch Ophthalmol* 1993;111:121-5
- [35] Hariprasad SM, Mieler WF, Holz ER. Vitreous and aqueous penetration of orally administered gatifloxacin in humans. *Arch Ophthalmol* 2003;121:345-350

-
- [36] Hariprasad SM, Shah GK, Mieler WF, et al. Vitreous and aqueous penetration of orally administered moxifloxacin in humans. *Arch Ophthalmol* 2006;124:178-182
- [37] Koul S, Phillipson BT, Phillipson A. Visual outcome of endophthalmitis in Sweden. *Acta Ophthalmol (Copenh)* 1989;67:504-9
- [38] Das T, Jalali S, Gothwal VK et al. Intravitreal dexamethasone in exogenous bacterial endophthalmitis: results of a prospective randomized study. *Br J Ophthalmol* 1999;83:1050-5
- [39] Shah GK, Stein JD, Sharma S et al. Visual outcomes following the use of intravitreal steroids in the treatment of postoperative endophthalmitis. *Ophthalmology* 2000;107:486-9
- [40] Kuhn F, Gini G. Vitrectomy for endophthalmitis. *Ophthalmology* 2006;113:714
- [41] Kuhn F, Gini G. Ten years after...are findings of the Endophthalmitis Vitrectomy Study still relevant today? *Graefes Arch Clin Exp Ophthalmol* 2005;243:1197-9
- [42] De Smet MD, Carlborg EA. Managing severe endophthalmitis with the use of an endoscope. *Retina* 2005;25:976-80
- [43] Deramo VA, Ting TD. Treatment of propionibacterium acnes endophthalmitis. *Curr Opin Ophthalmol* 2001;12:225-9