

---

# Sentinel Lymph Node Biopsy for Melanoma and Surgical Approach to Lymph Node Metastasis

---

Yasuhiro Nakamura and Fujio Otsuka

Additional information is available at the end of the chapter

<http://dx.doi.org/10.5772/53625>

---

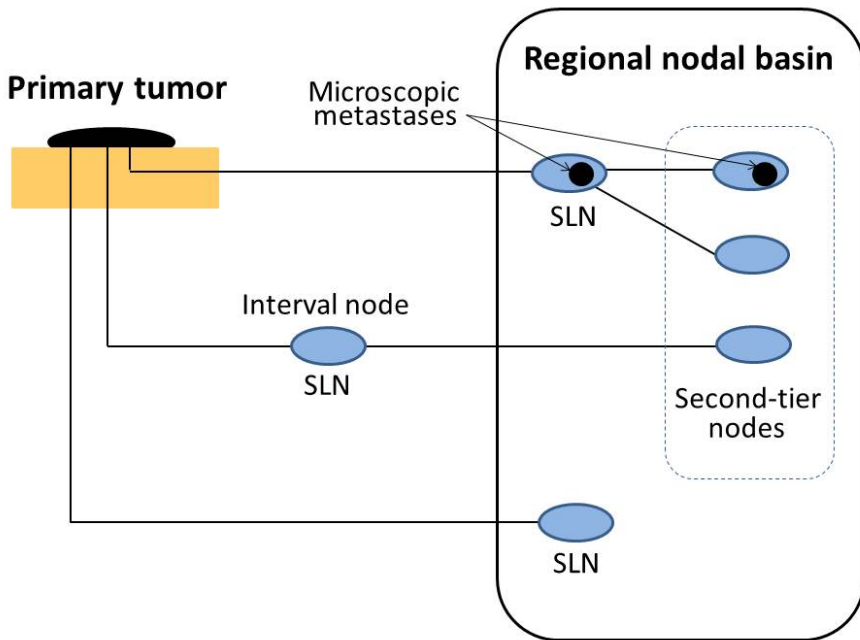
## 1. Introduction

The surgical approach to cutaneous melanoma patients with clinically uninvolved regional lymph nodes has been controversial. Although most patients with melanoma have no clinically palpable nodal disease at the time of presentation, some patients whose primary tumor increases in thickness, has ulceration, and shows a high mitotic rate histologically harbor clinically undetectable regional lymph node metastasis[1].

While some authors have advocated wide excision of the primary tumor with elective lymph node dissection (ELND), others had recommended excision of the primary site alone and therapeutic lymph node dissection (TLND) only when clinical nodal disease is present. ELND is based on the concept that metastasis arises by passage of the tumor from the primary to the regional lymph nodes and distant sites, in which case early LND will prevent this metastatic progression. In contrast, TLND, which is a "watch and wait" approach, suggests that regional lymph node metastases are markers for disease progression and that hematogenous distant metastases could occur without lymph node metastasis. Four randomized prospective studies comparing ELND with TLND were reported[2-5]. The earlier 2 studies conducted in the 1970s demonstrated no overall survival advantage for ELND[2, 3]. Accordingly, ELND was once contested and largely abandoned. Thereafter, the latter 2 studies conducted in the 1990s suggested the tendency, albeit statistically insignificant, that patients with early regional metastases may benefit from ELND[4, 5]. However, in most melanoma patients with no clinical nodal disease, microscopic nodal disease is absent at presentation. These patients cannot benefit from ELND; if ELND were to be performed, they would suffer from the cost, time, and morbidity of an unnecessary operation.

With respect to this controversy surrounding ELND, the technique of lymphatic mapping and sentinel lymph node biopsy (SLNB) was introduced as a minimally invasive method for

detection of microscopic regional lymph node metastases in the early 1990s[6]. Lymphatic mapping is based on the concept that the lymphatic drainage from the skin to the regional lymph node basins runs in an orderly, stepwise fashion. These lymphatic drainage patterns would be the same as the dissemination of melanoma through the lymphatic system and therefore predict the routes of metastatic spread of melanoma cells to the regional lymph nodes (Fig. 1). Morton et al. first reported the details of the SLN technique using intradermal blue dye injection around the primary site and reported that the SLN identification rate was 82% among 237 patients[6], which was considered a high identification rate at that time. In the early 1990s, several authors evaluated this concept by performing synchronous ELND at the time of SLNB[7-9]. A “false-negative” SLN was defined as microscopic metastasis in a non-SLN despite the SLN showing no metastasis. These studies indicated that 5.8% of patients had a false-negative SLN. In addition, Gershenwald et al. reported that only 4.1% (10/243) of patients with a histologically negative SLN developed a nodal recurrence in the previously mapped basin during a follow-up period of over 3 years[10]. This low false-negative rate supported the SLN concept described above.



**Figure 1. Lymphatic drainage from a primary tumor to sentinel lymph nodes.** A sentinel node is sometimes located between the primary tumor and the regional nodal basins, in which case it is called an interval (unusual, in-transit, ectopic) node. If the SLN has microscopic nodal metastasis, some of the second-tier nodes may also have metastasis.

## 2. Technical advances in SLNB

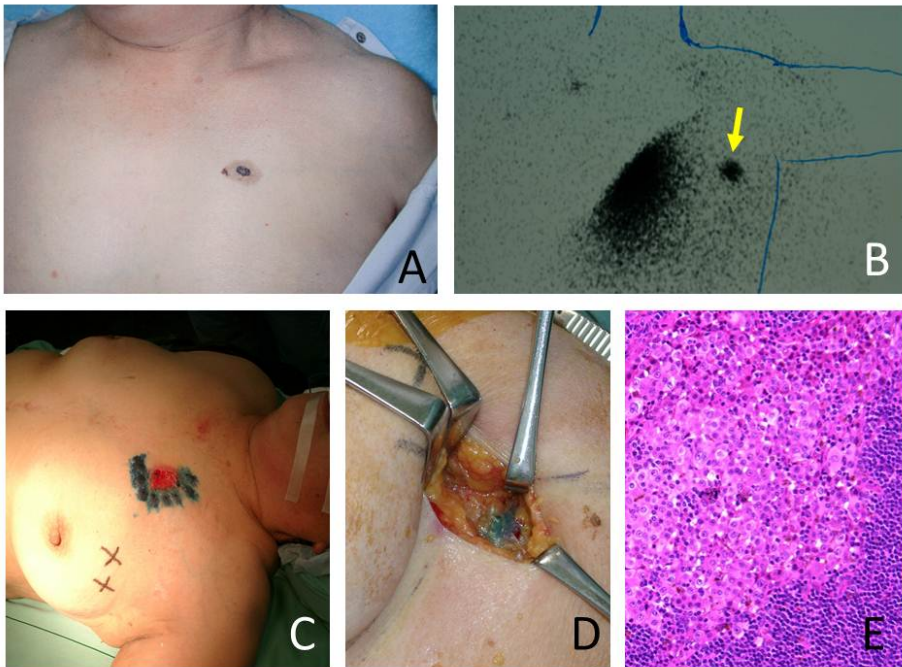
Although the initial SLN identification rate using blue dye injections alone was approximately 82%[6], the advent of lymphoscintigraphy and the intraoperative hand-held gamma probe drastically improved the SLN identification rate. Studies comparing blue dye injection alone with combined techniques using blue dye, lymphoscintigraphy, and an intraoperative hand-held gamma probe showed a significant increase in SLN identification of up to 99% with the combined techniques[11, 12], which has come to be recognized as the standard technique of SLNB (Fig. 2). This combined technique also enables the surgeon to identify the interval (unusual, in-transit, ectopic) nodes located outside the named regional nodal basins (Fig. 3)[13-17]. The rate of interval SLN identification is reported to be approximately 5% to 10%, and the rate of microscopic metastasis in the interval nodes is approximately the same as that in the SLN in the regional nodal basins[14].

However, SLNB in the head and neck has particular problems because the lymphatic drainage in the head and neck is much more complex than those in the axillary and inguinal regions. Furthermore, the cervical and parotid lymph nodes are smaller and located in sites that are not easily accessible, for example in the parotid gland, through which the facial nerve passes [18, 19]. In addition, it is sometimes difficult to detect the lymphatic drainage and SLN with lymphoscintigraphy because the SLN is often close to the highly radioactive site where the tracer was injected, the so-called shine-through phenomenon[18, 19]. In addition, in some cases the naked eye cannot confirm that an SLN has been dyed blue even after injection of the blue dye because of the short staining period for blue dye in cervical SLNs resulting from the rapid and complex cervical lymphatic flow[19]. In our experience too, over half of the SLNs did not show any blue staining. Furthermore, some authors reported a high false-negative rate of up to 44%, which leads to increased morbidity[20-22]. This high rate may be caused by partially obstructed lymphatic vessels that do not allow for smooth flow of nanocolloids with a size of 6 to 12 nm[23]. Although several authors have reported a high identification rate in SLNB for head and neck melanoma[24-26], the identification rate of SLNs for the standard technique in the cervical region is generally less than that in the inguinal or axillary regions. In the MSLT-I trial reported by Morton et al., the SLN identification rate in the cervical region (84.5%) was clearly lower than that in the inguinal (99.3%) or axillary regions (96.6%)[18].

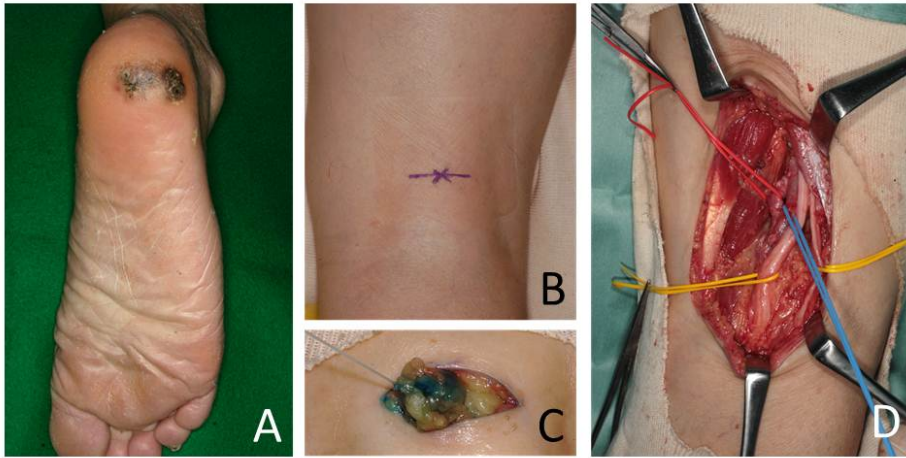
Several studies on the SLNB technique using indocyanine green (ICG) injection in skin cancer patients have demonstrated high SLN detection and identification rates, although these studies involved mainly axillary and inguinal SLNBs and only a small number of cervical SLNBs[23, 27-29]. ICG is a diagnostic reagent used in various examinations such as examination for cardiac output or hepatic function and retinal angiography. It has a size of only 2.1 nm, binds with albumin, and generates a peak wavelength of 840 nm near-infrared fluorescence when excited with 765-nm light[30]. Using a near-infrared camera intraoperatively, it is possible to observe the ICG as a subcutaneous lymphatic flow as well as SLNs in the fluorescence images after intradermal injection of ICG around the primary tumor. (Fig. 4) In our experience, the mean and median numbers of SLNs per basin were higher in the ICG

group than in the standard-technique group. The small size of ICG allows a smooth flow along the lymphatic vessels. It may lead to detection of SLNs not detectable by lymphoscintigraphy (Fig. 4C, D) owing to poor flow of the radioactive tracer and may reduce the false-negative rate. Indeed, Stoffels et al. reported that 2 of 11 additional SLNs that were only identified by the ICG technique showed microscopic metastasis[23].

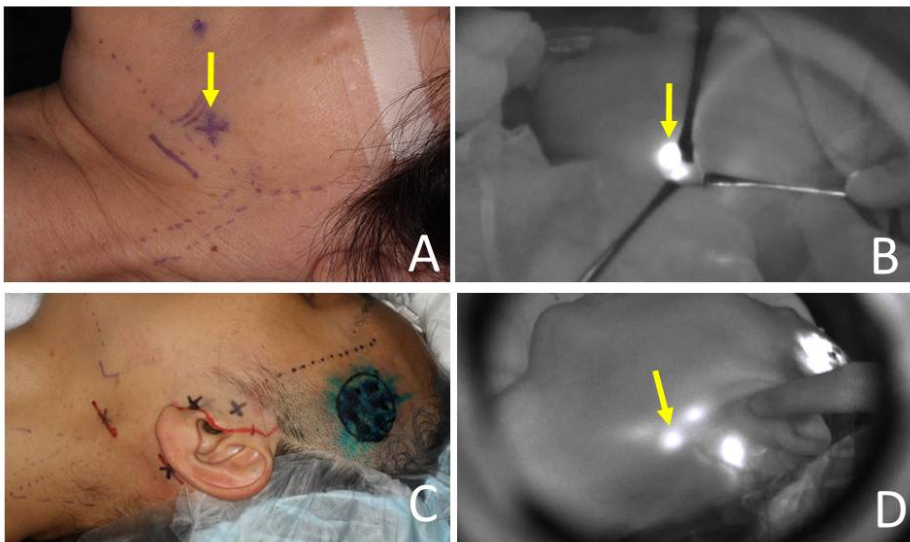
In addition, the recently introduced hybrid single-photon emission computed tomography with computed tomography (SPECT/CT) can visualize the exact anatomic location of the SLN and second-tier nodes, which would be of great help in identifying the SLN, especially those in the head and neck region[31, 32], as well as the interval nodes.



**Figure 2. The technique of lymphatic mapping and sentinel lymph node biopsy (SLNB).** (A) Primary melanoma on the left chest. (B) Lymphoscintigraphy shows accumulation of  $^{99}\text{Tc}$ -tin colloid which was intradermally injected around the primary tumor in the left axilla (arrow). (C) Intradermal injection of 2% isosulfan blue injection around the primary site. (D) The exploration of the location of SLN using a hand-held gamma-probe and identification of a blue-stained SLN. (E) Histopathologic detection of microscopic nodal metastasis.



**Figure 3. Detection of interval SLN.** (A) Primary melanoma on the right heel. (B) Lymphoscintigraphy revealed accumulation in the right popliteal fossa. (C) Radioactive and blue-stained popliteal node, which had microscopic metastasis. (D) Popliteal lymph node dissection was performed.



**Figure 4. SLNB using ICG.** (A) SLNB for melanoma of the nose. The X mark on the left mandible indicates accumulation of radioisotope (arrow). (B) A fluorescent submandibular SLN is visible through the incision using the near-infrared camera (arrow). (C) SLNB for melanoma of the left temporal region. The X marks indicate accumulation of radioisotope. (D) An additional fluorescent SLN (arrow), which was not detected by lymphoscintigraphy, is observed through the overlying skin.

### 3. Does SLNB-guided early lymph node dissection improve survival rate?

Whether patients who undergo complete lymph node dissection (CLND) after confirmation of a positive SLN have a better prognosis than patients who undergo TLND after occurrence of clinical nodal disease is controversial. The results of retrospective studies that compared survival after CLND for a positive SLN with survival after TLND for clinical nodal disease remain controversial. Several retrospective studies, including a multicentric study and a matched control study, demonstrated a significant survival benefit for patients who underwent CLND for a positive SLN[33, 34]. In addition, a survival benefit was also demonstrated for patients whose primary tumor thickness was between 1 mm and 4 mm and who underwent CLND for a positive SLN[35]. In contrast, other retrospective studies demonstrated no significant difference in overall survival between patients who underwent CLND for a positive SLN and those who underwent TLND for clinical nodal disease[36, 37].

The third interim analysis of the Multicenter Selective Lymphadenectomy Trial 1 (MLST-1), the only randomized control trial with available results, failed to demonstrate a 5-year survival advantage for the SLNB group when compared with the observation group and only a disease-free survival benefit for the SLNB group[38]. In a subgroup analysis, patients who underwent CLND for a positive SLN showed an improvement in 5-year survival of about 20% when compared with patients who underwent TLND after nodal observation and subsequently occurring clinical nodal disease (72.3% vs 52.4%;  $P=0.004$ ). The nodal recurrence was lower in patients who had a negative SLN (4.0%) than in those who had a positive SLN but were observed without early CLND (15.6%). From these results, the authors concluded that microscopic metastasis would develop within the lymph nodes and that early LND may lead to accurate staging and survival improvement.

However, whether SLNB and/or CLND would be a therapeutic procedure remains unclear, and several authors have questioned this conclusion from the results of the MLST-1. First, they claim that it was inappropriate to conclude that early CLND would improve survival because this result was based on a postrandomization subgroup analysis[39]. Second, they question whether all microscopic metastases will develop into clinical nodal disease. That is, some microscopic metastases may show indolent behavior and not develop into clinical nodal disease for a long time. In that case, comparison of the nodal recurrence rate between the 2 arms described above is an inappropriate analysis[37]. As a result, all that is currently clear is that SLNB can provide staging information that predicts prognosis and may impact clinical management.

## 4. Complete lymph node dissection

### 4.1. The role of complete lymph node dissection

The therapeutic value of CLND and appropriate selection of patients for CLND remain questionable. The role of CLND in patients with positive SLNs is also a clinically important

question because only 10% to 25% of patients with positive SLNs will have additional microscopic metastasis in non-SLNs[40-42], which means that approximately 80% of patients with positive SLNs may be spared CLND. Several authors categorized the SLN as several variables and tried to find a reliable indicator of non-SLN status[43, 44]. However, it remains unclear what size of microscopic metastasis of the SLN or which histopathologic location of metastasis in the SLN, such as subcapsular, parenchymal, multifocal, and extensive, would be a reliable indicator of non-SLN status[44].

The choice of the extent of CLND is ultimately decided by the individual surgeon. Few specific recommendations are available in the published guidelines, with the common description being "a thorough dissection" and reports of low levels of evidence supporting the appropriate surgical extent of CLND of the cervical, axillary, and inguinal regions[45-47].

## 5. Neck dissection

### 5.1. Extent of dissection and regional recurrence rate

The purpose of neck dissection is to control regional disease; it has little impact on overall survival. However, the extent of neck dissection is still controversial and various extents of neck dissection have been advocated by several authors. Radical neck dissection (RND) including removal of level I-V (Fig. 5A) and nonlymphatic tissue such as the sternocleidomastoid muscle, the internal jugular vein, and the spinal accessory nerve has been the gold standard for neck dissection for melanoma[48]. Despite extensive areas of dissection, O'Brien et al. reported that regional control with RND was unsatisfactory, with regional recurrence of 28% in patients with all nodal disease and of 34% in patients with clinical nodal disease[48].

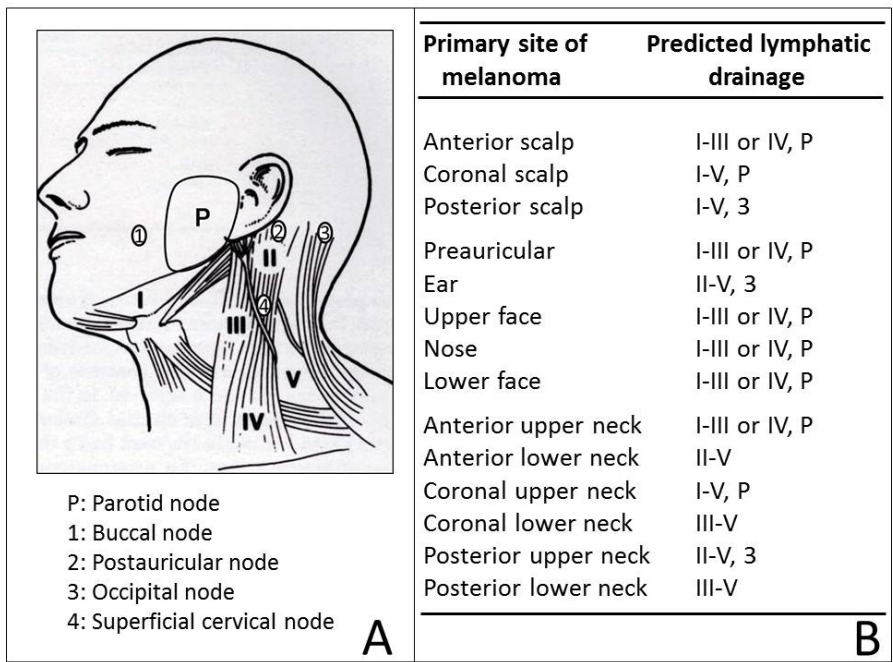
Generally, RND is associated with significant morbidity. Therefore, some authors have considered modified RND (MRND) or functional neck dissection including preservation of any or all of the sternocleidomastoid muscle, the internal jugular vein, and the spinal accessory nerve[49, 50]. In studies of patients with clinical nodal disease, several authors demonstrated that regional recurrence rates were 14-32% after RND, 0% after MRND, and 23% to 29% after selective neck dissection (SND), which is not statistically significant among the groups[51-53]. Byers also reported a 16% recurrence rate after MRND[54]. From these studies, MRND has been advocated even in the setting of clinical nodal disease.

In addition, as an even more selective approach, the lymphatic drainage patterns of head and neck melanoma have been described by O'Brien et al. based on a consecutive series of over 270 neck dissections and parotidectomies (Fig. 5B)[52]. As described above, although several authors reported relatively high regional recurrence rates of 23% to 29% after SND, these studies include clinical N2-N3 (multiple involved nodes) disease, which will have a higher risk of recurrence than N1 disease[51, 52]. In a study of 37 consecutive patients with clinically N1 neck disease reported by White et al., 6 patients underwent RND, 24, MRND, and 7, SND. None of the 3 groups had any cases of local recurrence during a mean follow-up of 46 months[55], indicating that SND may be an alternative to RND or MRND for the clinically N1 neck in melanoma[55].

Furthermore, the appropriate extent of dissection is also unclear in patients with positive SLNs. Pu et al. reported 23 consecutive patients with positive SLNs who underwent MRND or superficial parotidectomy. Of those patients, 21 (91.3%) had no additional positive non-SLNs and only 2 (8.7 %) had 1 additional positive non-SLN[56]. No patient developed a regional local recurrence during a mean follow-up period of 23.7 months. The low prevalence of additional positive non-SLNs in MRND specimens suggests that when microscopic SLN metastasis exists, nodal disease is confined to the SLN alone in most patients [56] and SND may be selected.

As for parotid gland nodes, patients with clinically palpable parotid nodes have a 28% to 58% risk of microscopic metastasis in the cervical nodes[57-59]. Although neck dissection should be included when clinical parotid disease is present, the need to treat the parotid nodes when clinical nodal disease of the neck is present is controversial. In such cases, many surgeons selectively perform superficial parotidectomy combined with a neck dissection based on O'Brien's lymphatic map (Fig. 5B) or the protocol of the individual institute[60].

However, the lymphatic drainage in the head and neck is generally complex and 8% to 43% of patients have unexpected drainage patterns in the occipital, postauricular, and contralateral nodes (Fig. 5A).[26, 61-64] Therefore, SND should be tailored to the individual patient according to the location of the SLN and second-tier nodes.



**Figure 5.** A) Lymphatic anatomy of the head and neck showing the 5 major lymph node levels and superficial nodes (B) Predicted lymphatic drainage and extent of neck dissection recommended by O'Brien et al.



## 5.2. Complication rate and technical variables

Significant complications associated with radical neck dissection may include injury to the facial and spinal accessory nerves, chylous fistula, and skin flap necrosis[65]. Although it is generally accepted that the rate of morbidity is reduced by MRND and further reduced by SND, detailed complication rates in the treatment of melanoma have not been reported. According to the literature, neck dissection and parotidectomy is usually safe when appropriately planned preoperatively and when performed by well-experienced surgeons.

Technical variables mainly include skin incisions. Commonly used incisions are single Y, T, or double Y-type incisions, which provide optimal exposure of the entire neck. However, the edge of the flap sometimes has a poor blood supply and breakdown can result in the exposure of the major vessels. The three-point suture line gives a high incidence of postoperative scar contracture[66, 67]. The Mcfee incision was designed to eliminate the three-point exposure line, giving a good cosmetic result. However, the exposure is difficult, particularly in a short fat neck, and excessive traction of the skin flaps can result in damaging of the skin edges[67]. Large, single incisions such as the curtain flap, apron flap, U-flap, and Hockey stick incision offer a good blood supply and most of the scar lies within the relaxed skin tension lines of the neck[68]. Each incision should be selected appropriately according to the extent of the neck dissection.

## 6. Axillary lymph node dissection

### 6.1. Extent of dissection and regional recurrence

Axillary LND for patients with melanoma is performed for local control and staging[69]; the therapeutic value is still unclear. The axillary nodes are divided into level I, II, and III nodes. Level I nodes are lateral to the lateral edge of the pectoralis minor muscle. Level II nodes are between the medial and lateral edges of the pectoralis minor muscle. Level III nodes are medial to the medial edge of the pectoralis minor muscle, in the apex of the axilla. The generally recommended extent of dissection is from level I to III nodes because of the various drainage patterns in the second-tier nodes as well as the potentially increased risk of recurrence with a lesser dissection[70, 71]. Several authors recommended a more extensive dissection including the supraaxillary fat pad because approximately 14% of patients will have metastatic nodes in this area[69, 72]. In contrast, several authors have questioned whether a level III dissection is necessary in all melanoma patients with a positive SLN and advocated that level III dissection should be included only when suspicious nodes are present in this level [73-75]. Namm et al. also advocated that level I and II dissection should be performed for positive-SLN patients because of the low regional recurrence rate and low postoperative morbidity and concluded that level III dissection is not necessary for regional control in patients with microscopic metastasis[76].

As for the regional recurrence rate, unfortunately, most studies grouped together all of the dissected levels. Several authors reported a 10% to 19% regional recurrence rate during

about a 30-month median follow-up[77-79]; however, in all 3 of those studies, the extent of dissection was not documented. Veenstra et al. reported a 4% regional recurrence rate and documented which levels were included when axillary LND was performed; however, they did not tease out the axillary recurrence rate specifically[80]. In the case of level I and II dissection for patients with a positive SLN, a low recurrence rate of 4% during a median follow-up of approximately 39-month was reported[76].

## 6.2. Complication rate and technical variables

Wrightson et al. reported a 19.9% complication rate among 262 patients undergoing axillary LND, most of which was thought to be level I-III dissection, for a positive SLN[81]. Several authors reported a complication rate of 14% to 21% for wound infection and of 19% to 36% for lymphocele when performing level I-III dissections[82, 83]. In contrast, Numm et al. reported that postoperative complications occurred in 11% of patients, with infectious complications in 8% when performing level I and II dissection. However, comparative studies of level I-II dissection with and level I-III dissection have not been published. Although the definition of lymphedema varies among studies, a long-term lymphedema rate was reported to be 1% to 12%[72, 75, 81].

Evidence of an optimal surgical technique for axillary LND has not been shown. As technical modifications, 2 incisions are mainly used. One is a transverse incision from the lateral edge of the pectoralis major muscle to the border of the latissimus dorsi muscle, and the other is an extended incision following the contour of the pectoralis major into the axillary apex and then down the medial arm[72, 84]. However, these incision variables would not affect the complication rate. Lawton et al. advocated preservation of the pectoralis major, the interpectoral, and the latissimus dorsi fascia during axillary LND to try to reduce lymphedema[84]. Over 110 elective and therapeutic fascia-preserving axillary LNDs developed a 5% incidence of long-term lymphedema, which is the same as or slightly lower than the incidence rates reported by the studies [72, 75, 81] described above. Optimal surgical exposure for level III dissection sometimes requires transection of the pectoralis minor muscle, and several authors suggested routine en bloc dissection of the pectoralis minor for TLND[16, 72, 75]. The long thoracic and thoracodorsal nerves are routinely preserved, although the intercostobrachial nerves are often sacrificed in TLND[73, 75]. As a result, no modifications clearly improve the complication rate, and only the extent of dissection impacts the complication rate.

## 7. Ilioinguinal lymph node dissection

### 7.1. Extent of dissection and regional recurrence rate

The dissection areas subject to most controversy are inguinal LND alone or ilioinguinal LND (inguinal LND + iliac/obturator (pelvic) LND). When iliac or obturator node involvement is suspected clinically or radiologically, additional pelvic LND is generally

recommended[74, 85-87]. For patients with clinically palpable nodal disease in the inguinal region alone, additional pelvic LND has not been widely accepted because of the lack of overall survival advantage[88, 89]. However, some authors advocated ilioinguinal LND because the rate of pelvic lymph node involvement in patients with palpable inguinal disease is 27% to 52%[87-92]. In a study of predictive factors for pelvic nodal status, Strobbe et al. reported that the Cloquet node has a limited sensitivity of 65% to predict involvement of the pelvic nodes and that the negative predictive value is 78%. In patients with clinical inguinal nodal disease, a tumor-positive Cloquet node had a 69% risk (positive predictive value) of additional positive nodes[91]. They also showed that the number of positive nodes in the inguinal region is not a reliable predictive factor for the pelvic nodal status, with a sensitivity of 41% and a negative predictive value of 78%[91].

Furthermore, the extent of dissection is more controversial in positive inguinal SLN patients. Van der Ploeg et al. reported that there is no lymphatic drainage to the inferior lateral zone, which is just lateral to the femoral artery and inferior to the level of saphenofemoral junction in the inguinal area, in patients with a positive SLN and advocated that this area need not be included in LND for such patients[93]. Pelvic nodes also seem unlikely to be involved when an inguinal SLN shows only microscopic metastasis[94, 95]. Several authors reported that 9% to 17 % of patients with a positive inguinal SLN also have positive pelvic nodes when ilioinguinal LND is performed[96-98]. In addition, a study evaluating lymphatic flow using lymphoscintigraphy and/or SPECT/CT demonstrated that over 50% of patients with a positive SLN showed second-tier nodal drainage to the pelvic nodes[93]. This study suggests that a selective pelvic LND based on the location of the second-tier nodes may be appropriate in positive SLN patients[93, 99].

As for the regional recurrence rate, published recurrence rates after inguinal or ilioinguinal LND for patients with clinical nodal disease is 0% to 33.6% (inguinal LND: 11.7%-13%; ilioinguinal LND: 0%-17.9%)[74, 85-89]. Sterne et al. reported that patients with palpable nodal disease who underwent inguinal LND alone had a regional recurrence rate of 12.5% (2 of 16 patients), whereas for those who underwent ilioinguinal LND, it was 0% (0 of 25 patients) [85]. Pearlman et al. reported a modification of inguinal LND that does not violate the femoral sheath. However, a 16% rate of regional recurrence was reported[100].

## **7.2. Complication rate and technical variables**

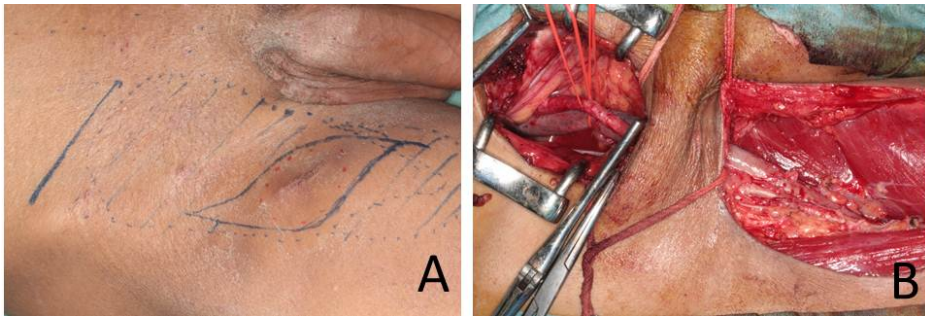
In the field of urology, classical inguinal LND has traditionally been associated with an 80% to 100% risk of surgical morbidity[101]. In the treatment of melanoma, several authors reported that 20% to 77% of patients who underwent inguinal LND had postoperative morbidity such as skin necrosis and wound dehiscence (7%-55%), wound infection (5%-15%), lymphocele/seroma (2%-46%), and lymphedema (5%-64%).[102] Although concerns have been raised about the potential for increased morbidity in patients undergoing an additional pelvic LND[87, 103], the addition of pelvic LND to inguinal LND did not significantly increase the risk for postoperative wound complication[87, 101, 104, 105]. However, lymphedema was more common after inguinal LND alone in some studies, although 1 study

specifically evaluating the incidence of lymphedema found no difference between the 2 procedures[87, 106, 107]. The lack of consensus about the complications of additional pelvic LND may suggest that when clinically indicated, concern about increased morbidity should not be a reason to avoid ilioinguinal LND, although patients may suffer from the operating time and cost.

The commonly described technical variables of ilioinguinal LND include different type of skin incision, thick skin flap, preservation of the large saphenous vein, transposition of the sartorius muscle over the femoral vessels, continuity dissection with division of the inguinal ligament, and trimming of the skin edges at the time of closure[108].

Several skin incisions are used: a Lazy-S incision from just medial to the anterior superior iliac spine to the inferior margin of the femoral triangle, paired oblique incisions (Fig. 6A), or an oblique/transverse incision above the inguinal crease with a longitudinal incision below and a skin bridge between[73, 84, 100]. Lazy-S incision provides optimal exposure and less subcutaneous lymphatic disruption[108]. In contrast, paired oblique incisions or an oblique/transverse incision can avoid an incision in the inguinal crease to reduce skin necrosis and wound dehiscence[84]. Recently, however, Spillane et al. reported minimal-access 3- to 6-cm-long paired incisions above and below the inguinal ligament, which showed no significant difference in wound and lymphedema complications[109]. A thick skin flap elevated at the level of the Scarpa fascia may improve skin necrosis and wound dehiscence rates; however, a 26% to 34% rate of skin necrosis and wound infection was reported[84, 100]. The preservation of the saphenous vein and the sartorius transposition flap for vessel coverage were designed to improve lymphedema rates, with no incidence of lymphedema[100]. When performing ilioinguinal LND, technical variables include a continuity dissection by dividing the inguinal ligament or an abdominal wall incision above and parallel to the inguinal ligament (Fig. 6B) to expose the retroperitoneal space[73, 84, 86]. Although advantages of inguinal ligament division include optimal exposure and possible continuity dissection, the main disadvantage is possible long-term abdominal wall weakness that may lead to abdominal incisional hernia. As another modification, Lawton et al. advocated fascia-preserving ilioinguinal LND, which is similar to the modified axillary dissection described above in the section on axillary LND, and the long-term lymphedema rate was 14%. Video-assisted endoscopic inguinal LND is currently investigated as a minimally invasive and less morbid approach but is not widely used[110, 111].

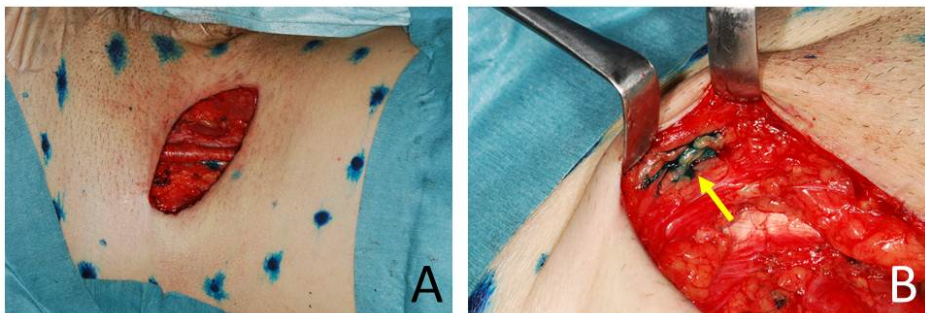
Despite such modifications, a comparative study reported by Sabel et al. demonstrated no significant difference in wound and lymphedema complications between modified inguinal LND (incision avoiding the inguinal crease, saphenous vein preservation, or sartorius transposition) and conventional inguinal LND[107]. However, although insignificant, saphenous vein preservation decreased the lymphedema rate from 30% to 13% and the wound complication rate from 20% to 7%. An incision avoiding the inguinal crease also decreased the wound complication rate from 21% to 9%, which is also statistically insignificant. Thus, these modifications seem to offer promise in decreasing morbidity.



**Figure 6.** Ilioinguinal LND using paired incisions. (A) Incision lines. The incision below the inguinal crease is fusiform to include the skin overlying the metastatic node. (B) Operating field after dissection. The abdominal wall was incised parallel to the inguinal ligament, which was preserved under the bipedicle flap.

As another procedure in an attempt to decrease lymphocele, Nakamura et al. reported a simple method using intraoperative injection of isosulfan blue during inguinal LND without modifications to identify leakage from an injured lymphatic vessels for the prevention of lymphocele (Fig. 7)[112]. There was no incidence of lymphocele in the isosulfan blue injection group and the lymphatic drainage output from the inguinal region was clearly less, leading to early removal of the suction catheter.

Despite many technical variables, it is difficult to evaluate each technique because of the different study designs, variable definitions of complications, and different patient populations. Multicenter, randomized prospective trials with a standardized definition of complications are required in the future.



**Figure 7.** Intraoperative injection of blue dye during inguinal LND for detection of injured lymphatic vessels. (A) Intra-cutaneous injection of isosulfan blue around the right inguinal region just after inguinal LND. (B) Blue-staining lymphatic leak (arrow) in the surgical field, which was ligated.

## 8. Adjuvant radiation therapy

Regional recurrence occurs in 20% to 50% of patients after TLND. High-risk factors associated with regional recurrence include a cervical lymph node basin, large lymph nodes, multiple positive lymph nodes, and extracapsular extension[113]. Patients with such risk factors are appropriate candidates for adjuvant radiation therapy, and several nonrandomized studies have demonstrated that adjuvant radiation therapy after CLND for patients with regional nodal disease can reduce the risk of regional recurrence to between 5% and 20% [114-118]. In a prospective phase II study by the Trans Tasman Radiation Oncology Group (TROG Study 96.06) of adjuvant radiation therapy after CLND for patients with regional nodal disease, the regional control rate was 91%[118].

Although adjuvant radiation therapy can be effective in achieving regional control after TLND, it increases chronic lymphedema, particularly in the inguinal region, which is the major morbidity associated with TLND[119].

## 9. Conclusions

The surgical approach to regional lymph node metastasis of cutaneous melanoma is challenging. SLNB allows accurate staging of nodal status and prediction of prognosis. A positive SLN should be treated with CLND for regional control. However, the impact on SLNB on overall survival remains unclear, and the appropriate surgical extent of CLND in the cervical, axillary, and inguinal regions is also debated. More research is required to provide evidence-based guidelines for surgeons about the extent of LND and to investigate the factors that may lead to a more patient-tailored approach.

## Acknowledgements

We thank Ms F. Miyamasu, associate professor of the Medical English Communications Center, University of Tsukuba, for expert English revision.

This work was partly supported by the National Cancer Center Research and Development Fund (23-A-22), and the Japanese Association of Dermatologic Surgery.

## Author details

Yasuhiro Nakamura\* and Fujio Otsuka

\*Address all correspondence to: ynakamura3@yahoo.co.jp

Department of Dermatology, Faculty of Medicine, University of Tsukuba, Tsukuba, Japan

## References

- [1] Balch CM, Soong SJ, Gershenwald JE et al. Prognostic factors analysis of 17,600 melanoma patients: validation of the American Joint Committee on Cancer melanoma staging system. *J Clin Oncol* 2001; 19: 3622-34.
- [2] Sim FH, Taylor WF, Pritchard DJ, Soule EH. Lymphadenectomy in the management of stage I malignant melanoma: a prospective randomized study. *Mayo Clin Proc* 1986; 61: 697-705.
- [3] Veronesi U, Adamus J, Bandiera DC et al. Inefficacy of immediate node dissection in stage I melanoma of the limbs. *N Engl J Med* 1977; 297: 627-30.
- [4] Cascinelli N, Morabito A, Santinami M, MacKie RM, Belli F. Immediate or delayed dissection of regional nodes in patients with melanoma of the trunk: a randomised trial. WHO Melanoma Programme. *Lancet* 1998; 351: 793-6.
- [5] Balch CM, Soong S, Ross MI et al. Long-term results of a multi-institutional randomized trial comparing prognostic factors and surgical results for intermediate thickness melanomas (1.0 to 4.0 mm). Intergroup Melanoma Surgical Trial. *Ann Surg Oncol* 2000; 7: 87-97.
- [6] Morton DL, Wen DR, Wong JH et al. Technical details of intraoperative lymphatic mapping for early stage melanoma. *Arch Surg* 1992; 127: 392-9.
- [7] Ross MI, Reintgen D, Balch CM. Selective lymphadenectomy: emerging role for lymphatic mapping and sentinel node biopsy in the management of early stage melanoma. *Semin Surg Oncol* 1993; 9: 219-23.
- [8] Reintgen D, Cruse CW, Wells K et al. The orderly progression of melanoma nodal metastases. *Ann Surg* 1994; 220: 759-67.
- [9] Thompson JF, McCarthy WH, Bosch CM et al. Sentinel lymph node status as an indicator of the presence of metastatic melanoma in regional lymph nodes. *Melanoma Res* 1995; 5: 255-60.
- [10] Gershenwald JE, Colome MI, Lee JE et al. Patterns of recurrence following a negative sentinel lymph node biopsy in 243 patients with stage I or II melanoma. *J Clin Oncol* 1998; 16: 2253-60.
- [11] Kapteijn BA, Nieweg OE, Liem I et al. Localizing the sentinel node in cutaneous melanoma: gamma probe detection versus blue dye. *Ann Surg Oncol* 1997; 4: 156-60.
- [12] Gershenwald JE, Tseng CH, Thompson W et al. Improved sentinel lymph node localization in patients with primary melanoma with the use of radiolabeled colloid. *Surgery* 1998; 124: 203-10.
- [13] Uren RF, Howman-Giles R, Thompson JF et al. Lymphoscintigraphy to identify sentinel lymph nodes in patients with melanoma. *Melanoma Res* 1994; 4: 395-9.

- [14] Sumner WE, 3rd, Ross MI, Mansfield PF et al. Implications of lymphatic drainage to unusual sentinel lymph node sites in patients with primary cutaneous melanoma. *Cancer* 2002; 95: 354-60.
- [15] Thompson JF, Uren RF, Shaw HM et al. Location of sentinel lymph nodes in patients with cutaneous melanoma: new insights into lymphatic anatomy. *J Am Coll Surg* 1999; 189: 195-204.
- [16] Uren RF, Howman-Giles R, Thompson JF et al. Interval nodes: the forgotten sentinel nodes in patients with melanoma. *Arch Surg* 2000; 135: 1168-72.
- [17] Uren RF, Thompson JF, Howman-Giles R. Sentinel nodes. Interval nodes, lymphatic lakes, and accurate sentinel node identification. *Clin Nucl Med* 2000; 25: 234-6.
- [18] Morton DL, Cochran AJ, Thompson JF et al. Sentinel node biopsy for early-stage melanoma: accuracy and morbidity in MSLT-I, an international multicenter trial. *Ann Surg* 2005; 242: 302-11; discussion 11-3.
- [19] Hayashi T, Furukawa H, Oyama A et al. Sentinel lymph node biopsy using real-time fluorescence navigation with indocyanine green in cutaneous head and neck/lip mucosa melanomas. *Head Neck* 2012; 34: 758-61.
- [20] Thomas JM. Sentinel lymph node biopsy in malignant melanoma. *BMJ* 2008; 336: 902-3.
- [21] Veenstra HJ, Wouters MW, Kroon BB, Olmos RA, Nieweg OE. Less false-negative sentinel node procedures in melanoma patients with experience and proper collaboration. *J Surg Oncol* 2011; 104: 454-7.
- [22] Thomas JM. Caution with sentinel node biopsy in cutaneous melanoma. *Br J Surg* 2006; 93: 129-30.
- [23] Stoffels I, von der Stuck H, Boy C et al. Indocyanine green fluorescence-guided sentinel lymph node biopsy in dermato-oncology. *J Dtsch Dermatol Ges* 2012; 10: 51-7.
- [24] Wagner JD, Park HM, Coleman JJ, 3rd, Love C, Hayes JT. Cervical sentinel lymph node biopsy for melanomas of the head and neck and upper thorax. *Arch Otolaryngol Head Neck Surg* 2000; 126: 313-21.
- [25] Chao C, Wong SL, Edwards MJ et al. Sentinel lymph node biopsy for head and neck melanomas. *Ann Surg Oncol* 2003; 10: 21-6.
- [26] Fincher TR, O'Brien JC, McCarty TM et al. Patterns of drainage and recurrence following sentinel lymph node biopsy for cutaneous melanoma of the head and neck. *Arch Otolaryngol Head Neck Surg* 2004; 130: 844-8.
- [27] Namikawa K, Yamazaki N. Sentinel lymph node biopsy guided by indocyanine green fluorescence for cutaneous melanoma. *Eur J Dermatol* 2011; 21: 184-90.



- [28] Fujisawa Y, Nakamura Y, Kawachi Y, Otsuka F. A custom-made, low-cost intraoperative fluorescence navigation system with indocyanine green for sentinel lymph node biopsy in skin cancer. *Dermatology* 2011; 222: 261-8.
- [29] Polom K, Murawa D, Rho YS, Spychala A, Murawa P. Skin melanoma sentinel lymph node biopsy using real-time fluorescence navigation with indocyanine green and indocyanine green with human serum albumin. *Br J Dermatol* 2012; 166: 682-3.
- [30] Benson RC, Kues HA. Fluorescence properties of indocyanine green as related to angiography. *Phys Med Biol* 1978; 23: 159-63.
- [31] Uren RF. SPECT/CT Lymphoscintigraphy to locate the sentinel lymph node in patients with melanoma. *Ann Surg Oncol* 2009; 16: 1459-60.
- [32] Vermeeren L, van der Ploeg IM, Olmos RA et al. SPECT/CT for preoperative sentinel node localization. *J Surg Oncol* 2010; 101: 184-90.
- [33] Morton DL, Hoon DS, Cochran AJ et al. Lymphatic mapping and sentinel lymphadenectomy for early-stage melanoma: therapeutic utility and implications of nodal microanatomy and molecular staging for improving the accuracy of detection of nodal micrometastases. *Ann Surg* 2003; 238: 538-49; discussion 49-50.
- [34] Kretschmer L, Hilgers R, Mohrle M et al. Patients with lymphatic metastasis of cutaneous malignant melanoma benefit from sentinel lymphonodectomy and early excision of their nodal disease. *Eur J Cancer* 2004; 40: 212-8.
- [35] Nowecki ZI, Rutkowski P, Michej W. The survival benefit to patients with positive sentinel node melanoma after completion lymph node dissection may be limited to the subgroup with a primary lesion Breslow thickness greater than 1.0 and less than or equal to 4 mm (pT2-pT3). *Ann Surg Oncol* 2008; 15: 2223-34.
- [36] Pasquali S, Mocellin S. The anticancer face of interferon alpha (IFN-alpha): from biology to clinical results, with a focus on melanoma. *Curr Med Chem* 2010; 17: 3327-36.
- [37] van Akkooy AC, Bouwhuis MG, de Wilt JH, Kliffen M, Schmitz PI, Eggermont AM. Multivariable analysis comparing outcome after sentinel node biopsy or therapeutic lymph node dissection in patients with melanoma. *Br J Surg* 2007; 94: 1293-9.
- [38] Morton DL, Thompson JF, Cochran AJ et al. Sentinel-node biopsy or nodal observation in melanoma. *N Engl J Med* 2006; 355: 1307-17.
- [39] Ross MI, Gershenwald JE. How should we view the results of the Multicenter Selective Lymphadenectomy Trial-1 (MSLT-1)? *Ann Surg Oncol* 2008; 15: 670-3.
- [40] Govindarajan A, Ghazarian DM, McCready DR, Leong WL. Histological features of melanoma sentinel lymph node metastases associated with status of the completion lymphadenectomy and rate of subsequent relapse. *Ann Surg Oncol* 2007; 14: 906-12.
- [41] Gershenwald JE, Andtbacka RH, Prieto VG et al. Microscopic tumor burden in sentinel lymph nodes predicts synchronous nonsentinel lymph node involvement in patients with melanoma. *J Clin Oncol* 2008; 26: 4296-303.

- [42] Vuylsteke RJ, Borgstein PJ, van Leeuwen PA et al. Sentinel lymph node tumor load: an independent predictor of additional lymph node involvement and survival in melanoma. *Ann Surg Oncol* 2005; 12: 440-8.
- [43] Francischetto T, Spector N, Neto Rezende JF et al. Influence of sentinel lymph node tumor burden on survival in melanoma. *Ann Surg Oncol* 2010; 17: 1152-8.
- [44] van der Ploeg AP, van Akkooi AC, Schmitz PI, Koljenovic S, Verhoef C, Eggermont AM. EORTC Melanoma Group sentinel node protocol identifies high rate of submicrometastases according to Rotterdam Criteria. *Eur J Cancer* 2010; 46: 2414-21.
- [45] Marsden JR, Newton-Bishop JA, Burrows L et al. Revised U.K. guidelines for the management of cutaneous melanoma 2010. *Br J Dermatol* 2010; 163: 238-56.
- [46] Garbe C, Peris K, Hauschild A et al. Diagnosis and treatment of melanoma: European consensus-based interdisciplinary guideline. *Eur J Cancer* 2010; 46: 270-83.
- [47] Gershenwald JE, Ross MI. Sentinel-lymph-node biopsy for cutaneous melanoma. *N Engl J Med* 2011; 364: 1738-45.
- [48] O'Brien CJ, Gianoutsos MP, Morgan MJ. Neck dissection for cutaneous malignant melanoma. *World J Surg* 1992; 16: 222-6.
- [49] Calearo CV, Teatini G. Functional neck dissection. Anatomical grounds, surgical technique, clinical observations. *Ann Otol Rhinol Laryngol* 1983; 92: 215-22.
- [50] O'Brien CJ, Coates AS, Petersen-Schaefer K et al. Experience with 998 cutaneous melanomas of the head and neck over 30 years. *Am J Surg* 1991; 162: 310-4.
- [51] Turkula LD, Woods JE. Limited or selective nodal dissection for malignant melanoma of the head and neck. *Am J Surg* 1984; 148: 446-8.
- [52] O'Brien CJ, Petersen-Schaefer K, Ruark D, Coates AS, Menzie SJ, Harrison RI. Radical, modified, and selective neck dissection for cutaneous malignant melanoma. *Head Neck* 1995; 17: 232-41.
- [53] Jonk A, Strobbe LJ, Kroon BB et al. Cervical lymph-node metastasis from cutaneous melanoma of the head and neck: a search for prognostic factors. *Eur J Surg Oncol* 1998; 24: 298-302.
- [54] Byers RM. The role of modified neck dissection in the treatment of cutaneous melanoma of the head and neck. *Arch Surg* 1986; 121: 1338-41.
- [55] White N, Yap LH, Srivastava S. Lymphadenectomy for melanoma in the clinically N1 neck: radical, modified radical, or selective? *J Craniofac Surg* 2009; 20: 385-8.
- [56] Pu LL, Wells KE, Cruse CW, Shons AR, Reintgen DS. Prevalence of additional positive lymph nodes in complete lymphadenectomy specimens after positive sentinel lymphadenectomy findings for early-stage melanoma of the head and neck. *Plast Reconstr Surg* 2003; 112: 43-9.

- [57] O'Brien CJ, McNeil EB, McMahon JD, Pathak I, Lauer CS. Incidence of cervical node involvement in metastatic cutaneous malignancy involving the parotid gland. *Head Neck* 2001; 23: 744-8.
- [58] Caldwell CB, Spiro RH. The role of parotidectomy in the treatment of cutaneous head and neck melanoma. *Am J Surg* 1988; 156: 318-22.
- [59] Barr LC, Skene AI, Fish S, Thomas JM. Superficial parotidectomy in the treatment of cutaneous melanoma of the head and neck. *Br J Surg* 1994; 81: 64-5.
- [60] Klop WM, Veenstra HJ, Vermeeren L, Nieweg OE, Balm AJ, Lohuis PJ. Assessment of lymphatic drainage patterns and implications for the extent of neck dissection in head and neck melanoma patients. *J Surg Oncol* 2011; 103: 756-60.
- [61] O'Brien CJ, Uren RF, Thompson JF et al. Prediction of potential metastatic sites in cutaneous head and neck melanoma using lymphoscintigraphy. *Am J Surg* 1995; 170: 461-6.
- [62] Pathak I, O'Brien CJ, Petersen-Schaeffer K et al. Do nodal metastases from cutaneous melanoma of the head and neck follow a clinically predictable pattern? *Head Neck* 2001; 23: 785-90.
- [63] Lin D, Franc BL, Kashani-Sabet M, Singer MI. Lymphatic drainage patterns of head and neck cutaneous melanoma observed on lymphoscintigraphy and sentinel lymph node biopsy. *Head Neck* 2006; 28: 249-55.
- [64] Reynolds HM, Smith NP, Uren RF, Thompson JF, Dunbar PR. Three-dimensional visualization of skin lymphatic drainage patterns of the head and neck. *Head Neck* 2009; 31: 1316-25.
- [65] Leong SP. Role of selective sentinel lymph node dissection in head and neck melanoma. *J Surg Oncol* 2011; 104: 361-8.
- [66] Attie JN. A single transverse incision for radical neck dissection. *Surgery* 1957; 41: 498-502.
- [67] Macfee WF. Transverse incisions for neck dissection. *Ann Surg* 1960; 151: 279-84.
- [68] Dancey AL, Srivastava S. Experience with the modified hockey stick incision for block dissection of neck. *J Plast Reconstr Aesthet Surg* 2006; 59: 1276-9.
- [69] Balch CM. Axillary lymph node dissection: differences in goals and techniques when treating melanoma and breast cancer. *Surgery* 1990; 108: 118-9.
- [70] Garbe C, Hauschild A, Volkenandt M et al. Evidence-based and interdisciplinary consensus-based German guidelines: systemic medical treatment of melanoma in the adjuvant and palliative setting. *Melanoma Res* 2008; 18: 152-60.
- [71] Essner R. Surgical treatment of malignant melanoma. *Surg Clin North Am* 2003; 83: 109-56.

- [72] Karakousis CP, Hena MA, Emrich LJ, Driscoll DL. Axillary node dissection in malignant melanoma: results and complications. *Surgery* 1990; 108: 10-7.
- [73] Karakousis CP. Therapeutic node dissections in malignant melanoma. *Ann Surg Oncol* 1998; 5: 473-82.
- [74] Meyer T, Merkel S, Gohl J, Hohenberger W. Lymph node dissection for clinically evident lymph node metastases of malignant melanoma. *Eur J Surg Oncol* 2002; 28: 424-30.
- [75] Serpell JW, Carne PW, Bailey M. Radical lymph node dissection for melanoma. *ANZ J Surg* 2003; 73: 294-9.
- [76] Namm JP, Chang AE, Cimmino VM, Rees RS, Johnson TM, Sabel MS. Is a level III dissection necessary for a positive sentinel lymph node in melanoma? *J Surg Oncol* 2012; 105: 225-8.
- [77] Gershenwald JE, Berman RS, Porter G, Mansfield PF, Lee JE, Ross MI. Regional nodal basin control is not compromised by previous sentinel lymph node biopsy in patients with melanoma. *Ann Surg Oncol* 2000; 7: 226-31.
- [78] Clary BM, Brady MS, Lewis JJ, Coit DG. Sentinel lymph node biopsy in the management of patients with primary cutaneous melanoma: review of a large single-institutional experience with an emphasis on recurrence. *Ann Surg* 2001; 233: 250-8.
- [79] Leiter U, Buettner PG, Bohnenberger K et al. Sentinel lymph node dissection in primary melanoma reduces subsequent regional lymph node metastasis as well as distant metastasis after nodal involvement. *Ann Surg Oncol* 2010; 17: 129-37.
- [80] Veenstra HJ, van der Ploeg IM, Wouters MW, Kroon BB, Nieweg OE. Reevaluation of the locoregional recurrence rate in melanoma patients with a positive sentinel node compared to patients with palpable nodal involvement. *Ann Surg Oncol* 2010; 17: 521-6.
- [81] Wrightson WR, Wong SL, Edwards MJ et al. Complications associated with sentinel lymph node biopsy for melanoma. *Ann Surg Oncol* 2003; 10: 676-80.
- [82] Kretschmer L, Thoms KM, Peeters S, Haenssle H, Bertsch HP, Emmert S. Postoperative morbidity of lymph node excision for cutaneous melanoma-sentinel lymphonectomy versus complete regional lymph node dissection. *Melanoma Res* 2008; 18: 16-21.
- [83] de Vries M, Vonkeman WG, van Ginkel RJ, Hoekstra HJ. Morbidity after axillary sentinel lymph node biopsy in patients with cutaneous melanoma. *Eur J Surg Oncol* 2005; 31: 778-83.
- [84] Lawton G, Rasque H, Ariyan S. Preservation of muscle fascia to decrease lymphedema after complete axillary and ilioinguinofemoral lymphadenectomy for melanoma. *J Am Coll Surg* 2002; 195: 339-51.

- [85] Sterne GD, Murray DS, Grimley RP. Ilioinguinal block dissection for malignant melanoma. *Br J Surg* 1995; 82: 1057-9.
- [86] Strobbe LJ, Jonk A, Hart AA, Nieweg OE, Kroon BB. Positive iliac and obturator nodes in melanoma: survival and prognostic factors. *Ann Surg Oncol* 1999; 6: 255-62.
- [87] Hughes TM, A'Hern RP, Thomas JM. Prognosis and surgical management of patients with palpable inguinal lymph node metastases from melanoma. *Br J Surg* 2000; 87: 892-901.
- [88] Mann GB, Coit DG. Does the extent of operation influence the prognosis in patients with melanoma metastatic to inguinal nodes? *Ann Surg Oncol* 1999; 6: 263-71.
- [89] Kretschmer L, Neumann C, Preusser KP, Marsch WC. Superficial inguinal and radical ilioinguinal lymph node dissection in patients with palpable melanoma metastases to the groin--an analysis of survival and local recurrence. *Acta Oncol* 2001; 40: 72-8.
- [90] Shen P, Conforti AM, Essner R, Cochran AJ, Turner RR, Morton DL. Is the node of Cloquet the sentinel node for the iliac/obturator node group? *Cancer J* 2000; 6: 93-7.
- [91] Strobbe LJ, Jonk A, Hart AA et al. The value of Cloquet's node in predicting melanoma nodal metastases in the pelvic lymph node basin. *Ann Surg Oncol* 2001; 8: 209-14.
- [92] Allan CP, Hayes AJ, Thomas JM. Ilioinguinal lymph node dissection for palpable metastatic melanoma to the groin. *ANZ J Surg* 2008; 78: 982-6.
- [93] van der Ploeg IM, Kroon BB, Valdes Olmos RA, Nieweg OE. Evaluation of lymphatic drainage patterns to the groin and implications for the extent of groin dissection in melanoma patients. *Ann Surg Oncol* 2009; 16: 2994-9.
- [94] Jansen L, Nieweg OE, Peterse JL, Hoefnagel CA, Olmos RA, Kroon BB. Reliability of sentinel lymph node biopsy for staging melanoma. *Br J Surg* 2000; 87: 484-9.
- [95] Estourgie SH, Nieweg OE, Valdes Olmos RA, Hoefnagel CA, Kroon BB. Review and evaluation of sentinel node procedures in 250 melanoma patients with a median follow-up of 6 years. *Ann Surg Oncol* 2003; 10: 681-8.
- [96] Santinami M, Carbone A, Crippa F et al. Radical dissection after positive groin sentinel biopsy in melanoma patients: rate of further positive nodes. *Melanoma Res* 2009; 19: 112-8.
- [97] Spillane AJ, Haydu L, McMillan W, Stretch JR, Thompson JF. Quality assurance parameters and predictors of outcome for ilioinguinal and inguinal dissection in a contemporary melanoma patient population. *Ann Surg Oncol* 2011; 18: 2521-8.
- [98] Chu CK, Delman KA, Carlson GW, Hestley AC, Murray DR. Inguinopelvic lymphadenectomy following positive inguinal sentinel lymph node biopsy in melanoma: true frequency of synchronous pelvic metastases. *Ann Surg Oncol* 2011; 18: 3309-15.

- [99] van der Ploeg IM, Valdes Olmos RA, Kroon BB, Nieweg OE. Tumor-positive sentinel node biopsy of the groin in clinically node-negative melanoma patients: superficial or superficial and deep lymph node dissection? *Ann Surg Oncol* 2008; 15: 1485-91.
- [100] Pearlman NW, Robinson WA, Dreiling LK, McIntyre RC, Jr., Gonzales R. Modified ilioinguinal node dissection for metastatic melanoma. *Am J Surg* 1995; 170: 647-9; discussion 9-50.
- [101] Spiess PE, Hernandez MS, Pettaway CA. Contemporary inguinal lymph node dissection: minimizing complications. *World J Urol* 2009; 27: 205-12.
- [102] Chang SB, Askew RL, Xing Y et al. Prospective assessment of postoperative complications and associated costs following inguinal lymph node dissection (ILND) in melanoma patients. *Ann Surg Oncol* 2010; 17: 2764-72.
- [103] Hughes TM, Thomas JM. Combined inguinal and pelvic lymph node dissection for stage III melanoma. *Br J Surg* 1999; 86: 1493-8.
- [104] Ravi R. Morbidity following groin dissection for penile carcinoma. *Br J Urol* 1993; 72: 941-5.
- [105] Karakousis CP, Driscoll DL. Groin dissection in malignant melanoma. *Br J Surg* 1994; 81: 1771-4.
- [106] Beitsch P, Balch C. Operative morbidity and risk factor assessment in melanoma patients undergoing inguinal lymph node dissection. *Am J Surg* 1992; 164: 462-5; discussion 5-6.
- [107] Sabel MS, Griffith KA, Arora A et al. Inguinal node dissection for melanoma in the era of sentinel lymph node biopsy. *Surgery* 2007; 141: 728-35.
- [108] Karakousis CP. Therapeutic node dissections in malignant melanoma. *Semin Surg Oncol* 1998; 14: 291-301.
- [109] Spillane AJ, Tucker M, Pasquali S. A pilot study reporting outcomes for melanoma patients of a minimal access ilio-inguinal dissection technique based on two incisions. *Ann Surg Oncol* 2011; 18: 970-6.
- [110] Delman KA, Kooby DA, Rizzo M, Ogan K, Master V. Initial experience with video-scopic inguinal lymphadenectomy. *Ann Surg Oncol* 2011; 18: 977-82.
- [111] Ising IM, Bembenek A, Gutzmer R, Kockerling F, Moesta KT. Enhanced postoperative lymphatic staging of malignant melanoma by endoscopically assisted ilioinguinal dissection. *Langenbecks Arch Surg* 2012; 397: 429-36.
- [112] Nakamura Y, Fujisawa Y, Maruyama H, Furuta J, Kawachi Y, Otsuka F. Intraoperative mapping with isosulfan blue of lymphatic leakage during inguinal lymph node dissection (ILND) for skin cancer for the prevention of postoperative lymphocele. *J Surg Oncol* 2011; 104: 657-60.

- [113] Lee RJ, Gibbs JF, Proulx GM, Kollmorgen DR, Jia C, Kraybill WG. Nodal basin recurrence following lymph node dissection for melanoma: implications for adjuvant radiotherapy. *Int J Radiat Oncol Biol Phys* 2000; 46: 467-74.
- [114] Ballo MT, Strom EA, Zagars GK et al. Adjuvant irradiation for axillary metastases from malignant melanoma. *Int J Radiat Oncol Biol Phys* 2002; 52: 964-72.
- [115] Ballo MT, Bonnen MD, Garden AS et al. Adjuvant irradiation for cervical lymph node metastases from melanoma. *Cancer* 2003; 97: 1789-96.
- [116] Ballo MT, Zagars GK, Gershenwald JE et al. A critical assessment of adjuvant radiotherapy for inguinal lymph node metastases from melanoma. *Ann Surg Oncol* 2004; 11: 1079-84.
- [117] Ballo MT, Ross MI, Cormier JN et al. Combined-modality therapy for patients with regional nodal metastases from melanoma. *Int J Radiat Oncol Biol Phys* 2006; 64: 106-13.
- [118] Burmeister BH, Mark Smithers B, Burmeister E et al. A prospective phase II study of adjuvant postoperative radiation therapy following nodal surgery in malignant melanoma-Trans Tasman Radiation Oncology Group (TROG) Study 96.06. *Radiother Oncol* 2006; 81: 136-42.
- [119] Agrawal S, Kane JM, 3rd, Guadagnolo BA, Kraybill WG, Ballo MT. The benefits of adjuvant radiation therapy after therapeutic lymphadenectomy for clinically advanced, high-risk, lymph node-metastatic melanoma. *Cancer* 2009; 115: 5836-44.

