
Transplant Renal Artery Stenosis

Taqi Toufeeq Khan and Mirza Anzar Baig

Additional information is available at the end of the chapter

<http://dx.doi.org/10.5772/50396>

1. Introduction

Transplant renal artery stenosis (TRAS) is an increasingly recognized, potentially reversible complication of kidney transplantation. It has become an important curable cause of hypertension, graft dysfunction and graft loss in kidney recipients. The incidence varies from 1% to 23%[1] and can be attributed to several factors, first, the absence of the definition of hemodynamically significant TRAS, hence, the reported stenosis ranges widely from 50% to 90% [2-5]. Second, the ready availability of noninvasive screening modalities, such as color Doppler ultrasonography (DUS) and magnetic resonance angiography (MRA), may have led to an increase in the number of suspected cases and third, the intensity with which diagnosis and screening is pursued [1]. The vast majority of cases present between 3 months to 2 years after transplantation but can also present earlier or later [6]. The usual presentation is worsening or new onset hypertension and /or graft dysfunction in the absence of rejection, drug toxicity, ureteric obstruction and infection. Several etiologic mechanisms have been proposed for TRAS, acute rejection [7], suture technique, atherosclerotic arterial disease in the donor or recipient, arterial trauma during organ procurement or transplant, cytomegalovirus (CMV) [8, 9], deceased donor transplants, prolonged cold ischemia and arterial kinking because of a longer renal artery [1,11]. Angiography remains the gold standard for diagnosis and planning appropriate therapy [1]. Percutaneous transluminal balloon angioplasty (PTA) is the preferred initial mode of therapy since it is minimally invasive, safe and effective, with success rates reported between 20% and 88%[1, 12,]. Post PTA recurrence prompted the primary placement of endovascular stents to maintain long term patency [13]. Surgical repair of TRAS is technically challenging due to the dense scar tissue around the allograft, it can result in graft loss and may be indicated in cases where PTA has either failed or is not an option [6]. The hypothesis of downstream effects of renal ischemia and hypoperfusion are introduced for the first time in an attempt to explain its association with ureteric stenosis [14].

2. Etiology

There are 3 main lesions seen in TRAS: the common variety is at or close to the anastomosis, another is a localized lesion, which can be proximal or distal to the anastomosis and lastly, diffuse or multiple stenoses.

2.1. Surgical technique and perfusion

The early presentation of TRAS is suggestive of a technical reason, late presentations especially after many years suggests progression of recipient atherosclerosis. The most common cause of stenosis is related to poor technique and usually located at the site of anastomosis, especially in end to end anastomoses [8, 12] when arteries with unequal diameters are approximated. Other technical reasons that may result in TRAS are: the damage to the intima caused by application of vascular clamps, the healing of which would result in stenosis, the degree of stenosis depending on the degree of initial intimal damage.

Torsion of the allograft at the time of final placement [11] at the time of closure of the incision can lead to kinking that can cause turbulent flow and simulate TRAS [1]. In cases where the renal artery is longer than the vein, kinking and knuckling of the artery is unavoidable because the vein is shorter and prevents a smooth contour. This is especially true in deceased donor right kidney allograft that is without the contiguous inferior vena cava needed for renal vein augmentation to match the length of the right renal artery [11]. This problem is compounded if the renal artery has early bifurcation and cannot be shortened to match the vein because multiple arterial anastomoses would then be required (Fig 1).

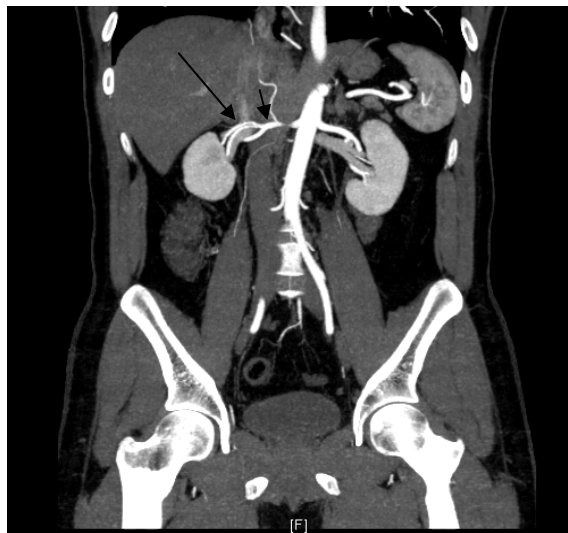

Figure 1. Early bifurcation of the right renal artery . One stump of the renal artery is possible only when it is divided proximal to its bifurcation (short arrow) , rendering it twice the length of the vein (long arrow) that can cause kinking.

Another aspect of technique involves damage to the renal artery at the time of allograft recovery. Rough handling and stretching of the artery can result in intimal injury and dissection, and arteries always need to be handled with great care because success of the entire transplant depends on this arterial inflow. TRAS is allegedly more common in deceased donor transplantation, because of an inherent longer cold ischemia associated with the procedure [12], and not intimal injury. The reason intimal injury is unlikely is because the cannula used for cold perfusion is placed in the aorta, at a distance from the renal arteries, and the renal artery orifices remain untouched. Theoretically at least, intimal injury is more likely in live donor allograft perfusion because the perfusion cannulae are placed directly within the renal artery lumen and have the potential for injury, especially in smaller arteries where an intravenous plastic cannula may be required, and the tip of this plastic cannula can injure the intima if care is not exercised.

2.2. Acute cellular rejection (ACR)

Wong et al found a significantly higher incidence of ACR in their TRAS group compared to controls (0.67 vs 0.35 episodes per patient) with significantly poorer patient and graft survival [7]. Acute rejection was also found to occur more frequently in patients with TRAS (48%) compared to the non TRAS group (27%), although the difference was insignificant [9]. In another paper, 7 of 17 patients with acute rejection also developed TRAS [12]. We also reported our only case of TRAS in a deceased donor recipient, who presented with worsening of hypertension and graft dysfunction, 4 weeks after an episode of ACR [15]. Perfusion injury to the renal artery in this donor was unlikely because the perfusion cannula was placed in the aorta, at a distance from the origin of the renal arteries. Twenty percent of pediatric enbloc and 7% of adult transplants developed TRAS in a study from Spain but the authors found no association between ACR and TRAS in their cohort of 367 pediatric enbloc and adult single kidney transplants over a 13-year period. Interestingly, they found nearly 46% of TRAS lesions proximal to the anastomosis resulting from recipient atherosclerosis [16]. The hypothesis that immune mediated intimal injury was the major factor in the development of TRAS [7] has never been proven and there is no strong definitive evidence that acute rejection causes TRAS. There appears to be only a weak association or perhaps a coincidental finding.

2.3. CMV infection

Pouria et al found CMV infection significantly more in patients with TRAS than controls (36 vs 12) and claim that CMV contributes to the development of a stenosis [8]. In another paper, the same group reported an increased incidence of ACR in their TRAS cases but deny the CMV association with steroid therapy for ACR [7]. Their hypothesis is that CMV induced arterial injury in immune suppressed patients is via local infection and the mitogenic actions of viral gene products within the arterial wall [8]. It is hypothesized that healing that follows this intimal damage causes fibrosis and leads to stenosis of the artery. CMV was also associated with TRAS in a French study, and in their multivariate analysis, only CMV and delayed graft function were significantly and independently associated with TRAS and poor long term outcome [9].

2.4. Progression of recipient atherosclerosis

As more older and diabetic patients become kidney recipients, there is increased risk of peripheral vascular disease and reduced blood flow to the lower limb. These are patients who should be examined for a bruit because of proximal stenoses in the common iliac artery or the aorta. In a Spanish study, Marques et al found 46% of stenoses were caused by recipient atherosclerosis that caused symptoms of TRAS and these stenotic lesions were proximal to the anastomoses [16]. These lesions can limit arterial flow to the allograft and behave like TRAS (pseudo TRAS) and may simultaneously also have signs and symptoms of lower limb ischemia [17, 18]. Progression of atherosclerosis in these cases can result in stenosis, either at the anastomosis or more diffusely. Stenoses that cause symptoms later or many years after transplant is suggestive of recipient atherosclerotic disease that may involve either the renal artery, or more proximally, the external iliac, common iliac or the infrarenal aorta.

2.5. Calcineurin toxicity

Nodular hyaline deposits in the media of afferent arterioles (arteriolar hyalinosis) are commonly considered irreversible changes, and also regarded as a hallmark of CNI nephrotoxicity. These are characterized by the replacement of necrotic smooth muscle cells by focal or circular lumpy protein (hyaline) deposits at the periphery of the wall of afferent arterioles. Eventually, these nodular hyaline deposits become sufficiently large to cause narrowing of the vascular lumen resulting in stenosis that can cause hypoperfusion, ischemia and TRAS like symptoms [19].

3. Pathogenesis

The most common site for a TRAS lesion is close to the arterial anastomosis, but these may also be located at a distance from it. The number of stenoses depends on the etiology, they can be single or several, affecting different sites along the artery which is suggestive of varied times and causes or it may uniformly involve the whole vessel. The anastomotic stenoses are generally related to technique, may also be related to trauma to arteries during recovery of the allograft or the application of clamps at the time of anastomosis. Poor surgical technique can also result in narrowing of the neo ostium especially when end to end union is attempted, especially where there is disparity in the diameter of opposing lumens. These would present early after surgery because the reason is mechanical [6].

Intimal injury caused by rough handling and stretching of the artery can be either small intimal flaps or dissections that would heal as a scar or hyperplasia, resulting in narrowing. Late stenoses, those which present several years after transplantation are suggestive of progression of atherosclerosis and can involve the allograft artery or its proximal inflow [5]. Diffuse stenoses discovered late can be the result of immune mediated endothelial damage because the histology resembles vascular rejection. There is no clear evidence that rejection is the primary insult that over time results in a stenotic lesion.

Prolonged cold ischemia in deceased donor transplantation may cause arterial injury that heals with fibrosis and causes narrowing, TRAS is less common in live donor transplantation because the cold ischemia is much shorter.

Mechanical narrowing of the renal artery by kinking produces the same effect as a stenosis by reducing inflow and causing ischemia. This is observed when the artery is longer than the vein, usually in right kidneys. In right kidneys from deceased donors, the absence of a contiguous inferior vena cava prevents augmentation of the vein to match the longer renal artery and causes kinking if the discrepancy is not corrected. The kinking may be difficult to correct without further surgery, it is thus imperative that attention be paid to any discrepancy in vascular lengths.

4. Pathophysiology

Hypertension caused by TRAS is the clinical equivalent of the experiments carried out by Goldblatt in the 1930s [18]. He took the approach of experimentally compromising renal arterial blood flow by placing a clamp on the main renal artery. He got the idea from pathologists that intrarenal sclerosis of arteries and arterioles were commonly found at autopsy in patients dying with hypertension. Recognizing that no experimental procedure existed for creating the vascular pathology seen in human hypertensive kidneys, he reasoned that if impaired renal blood flow was the fundamental cause, this could be mimicked by constricting the main renal artery.

Silver clips were set for varying degrees of constriction and placed on the renal artery of dogs. Goldblatt observed that minimal occlusion of the main renal artery was sufficient to induce a rise in blood pressure within 24 to 72 hours. In control experiments constriction of the splenic or femoral arteries did not result in elevated blood pressure. Once hypertension was established, removal of the clip resulted in return of blood pressure to normal levels, a finding suggesting that the ischemic kidney maintained the elevated blood pressure. In some experiments, instead of removing the clip, the clipped kidney was removed. This resulted in a return of blood pressure to normal levels. Subsequently placing a clip on the main renal artery of the remaining kidney resulted in reelevation of blood pressure. In Goldblatt's early studies, hypertension in most animals lasted from 4 to 6 weeks and then blood pressures returned to normal levels, even though the clamps were still in place. Goldblatt noticed that the return to normal blood pressure was associated with conspicuous development of collateral arterial circulation to the kidney, particularly through the renal capsule. In subsequent experiments he decapsulated the kidney and enclosed it in a membrane to prevent revascularization. When the renal artery of such animals was constricted, hypertension occurred and persisted.

Goldblatt's one kidney, one clip (1K1C) model is where a clip is applied to one renal artery and the contralateral kidney is removed. The transplanted kidney, unlike the clipped kidney is denervated and ischemia fails to elicit sympathetic activation. In the ischemic 1K1C model, this single kidney responds with activation of renin angiotensin system, sodium

retention and increase in the extracellular volume. The increased volume improves renal perfusion which inhibits the RAS. In this new milieu, hypertension is sustained by the expanded volume and renin levels remain normal or low.

In animal experiments, a decrease in kidney perfusion is observed only after the renal artery lumen is narrowed by more than 50% [20]. Similar findings are reported in humans during angiography, the renal vascular resistance increases to levels which impair perfusion only after arterial lumen is narrowed by 50% [21]. When the renal perfusion pressure drops by at least 15mmHg as a result of TRAS, severe hypertension and renal failure ensue, becoming irreversible if left untreated.

Glomerular filtration rate (GFR) is generally not affected, even though the perfusion pressure is low because intracapillary pressure is sustained by increasing the postglomerular resistance which increases the filtration fraction. There is a critical period during which revascularization can be successful, however, if the ischemia becomes chronic, restoring renal blood flow at this time usually will not result in improvement because of the chronic changes. When revascularization is performed before these changes, the postglomerular resistance is reduced with prompt diuresis and improvement in hypertension [22]. This has clinical implications, because prolonged renal ischemia causes irreversible changes, every effort must be made to restore kidney perfusion in a timely manner after diagnosis to prevent such permanent damage and renal failure. An indication of these permanent changes may be reflected by the intrarenal resistive indices (RIs) on DUS, and RIs over 0.8 reflect such structural changes that will prevent any functional recovery following revascularization. A clinical study was undertaken in transplant recipients by Radermacher et al to assess whether RIs over 0.8 reflected structural changes and predicted early graft loss and death [23]. They showed that significantly more patients with RIs over 0.8 had lower creatinine clearance, required dialysis and died, than patients with RIs less than 0.8 ($P < 0.001$ for all comparisons). This effectively means that if any transplant recipient with TRAS has RIs over 0.8, the chances of revascularization are not enough to warrant invasive treatment. Initially in TRAS, the intrarenal RIs are less than 0.55, however, if untreated, the associated hypertension results in arteriosclerosis, fibrosis and kidney atrophy with an increase in RIs. Presence of RIs between 0.55 and 0.8 suggests that permanent structural changes have not occurred and that revascularization can be successful.

5. Clinical presentation

Worsening or de novo hypertension is the usual initial presentation, in some cases, there may be an increased requirement of anti hypertensive medication. Renal hypoperfusion activates the renin angiotensin system (RAS) with resulting fluid retention, which with hypertension can cause edema, congestive cardiac failure or recurrent pulmonary edema. Patients can also remain asymptomatic except for hypertension. Injudicious diuretic therapy or addition of angiotensin converting enzyme inhibitors or angiotensin receptor blockers to the anti hypertensive regime can cause acute deterioration in renal function or renal failure.

A bruit may be heard over the graft in some cases, although not specific for TRAS because the stenosis can involve any artery proximal to the anastomosis. Renal dysfunction in the absence of rejection, ureteric obstruction and infection is not observed until a critical stenosis is reached, and there is much debate about this critical degree of stenosis or when does a stenosis become 'significant'. Objectively, stenosis of the transplant renal artery only achieves significance once there is evidence of renal impairment, because it indicates a level of renal hypoperfusion or ischemia that is unable to sustain adequate renal function.

6. Differential diagnosis

Any condition that causes hypertension and graft dysfunction must be included in the list of differential diagnosis. During the early period following transplantation, calcineurin inhibitor (CNI) levels are highest, and toxicity can induce reversible hemodynamic changes that mimic those observed in TRAS. This is the result of an increase in resistance at the site of afferent arteriole that causes glomerular hypoperfusion, increased FF, sodium and water retention and hypertension. Chronic CNI toxicity will produce irreversible vascular changes with graft failure [24]. TRAS must be differentiated from proximal aortic or iliac stenosis associated with recipient atherosclerosis, that may have progressed as a consequence of treatment with CNIs and steroids. In these cases, a bruit may be audible below the umbilicus. Other considerations are hypertension as a result of native atrophic kidneys and as a consequence of chronic rejection.

6.1. Diagnosis – Laboratory tests

Plasma renin. Lower levels may be observed in TRAS because the fluid retention and volume expansion that causes hypertension may not fully activate the RAS.

Increased levels may be secondary to diuretic therapy or in some cases of acute rejection.

Serum potassium may be elevated with high CNI levels.

6.2. Isotope scanning

Isotope renal scanning had good sensitivity (75%) but the poor specificity (67%) made it unpopular [25]. Scintigraphy using Captopril [26] was useful in evaluating segmental arteries but Losartan scintigraphy [27] was considered an improvement, but is rarely used now.

6.3. DUS

This is an excellent modality for diagnosis and follow-up for TRAS. Its many advantages are that it is non-invasive, inexpensive, has good sensitivity (87-94%) and specificity (86-100%), can be performed at the bedside, can evaluate hemodynamic significance, grading and localization of stenoses and assess revascularization. The information derived from this depends heavily on the experience and skill of the person operating the machine. Two types of

data are necessary for evaluation of a stenosis, the peak systolic velocity (PSV) at the site of stenosis, and the intra renal RIs. At times, PSV may not be obtainable by DUS but scans carried out during microbubble infusion can quantify total and regional renal blood flow [28].

6.4. Extra renal doppler

This is a scan of the renal artery from the anastomosis to the hilum of the kidney and PSV is measured along its entire course. At the site of a stenosis, there is an increase in PSV of $>2\text{m/sec}$. The advantages are a high accuracy in ascertaining the severity of stenosis with the ability to localize the site of stenosis. The main disadvantage is that it is operator dependent, it is also time consuming because it requires an angle of interrogation parallel to the course of the artery.

6.5. Intra renal doppler

This analyzes the Doppler signal in the intrarenal arteries distal to the stenosis. The normal intrarenal spectral waveform has a sharp systolic rise, a gradual reduction in velocity of flow in late systole, and, low velocity forward flow throughout diastole (Fig 2).

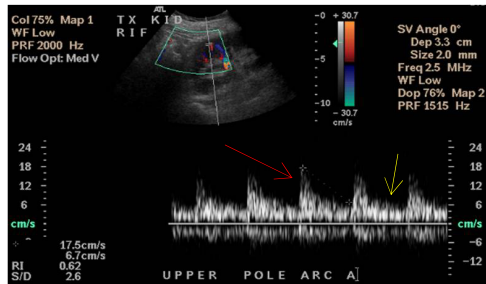


Figure 2. Normal intrarenal waveform, note the sharp systolic upstroke (red arrow), a gradual reduction in velocity and low velocity flow during diastole (yellow arrow).

The parvus tardus waveform is considered diagnostic of a proximal stenosis, and is a small amplitude waveform with a prolonged systolic rise or prolongation of the acceleration time (Fig 3) [29].

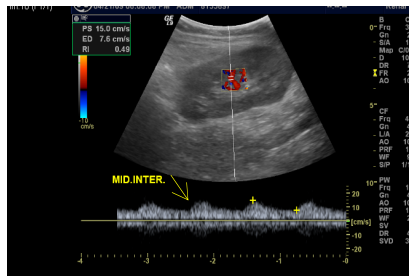


Figure 3. Intrarenal parvus tardus waveform, note the low amplitude and slow systolic rise waveform (yellow arrow) with RI of 0.49.

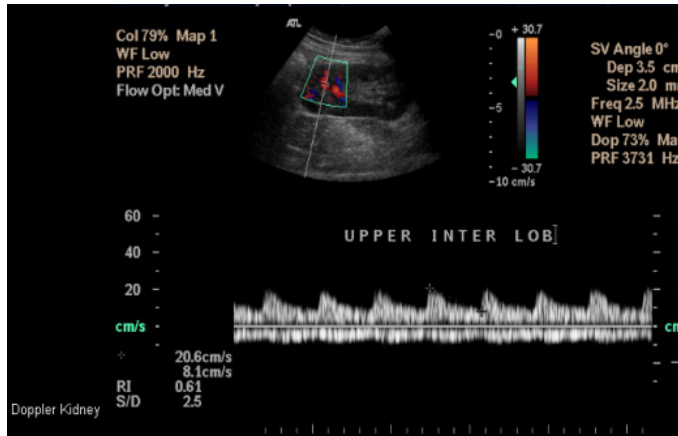


Figure 4. Post revascularization intrarenal Doppler. Normal waveform is seen confirming successful restoration of blood flow.

It must be remembered that this waveform can be produced by a stenosis at any point proximal to the artery studied. This Doppler scan is not as operator dependent as the extra renal Doppler and also cannot localize the site of stenosis.

In cases of TRAS, RIs in the intrarenal arteries are reduced because it is distal to the stenosis and subject to reduced blood flow. An RI of <0.55 is considered diagnostic of TRAS along with the parvus tardus waveform, both reflecting reduced blood flow [30].

6.6. Spiral computerized tomography

Provides three- dimensional imaging of the vascular anatomy and the images are superior to conventional angiography. It requires less contrast medium and does not require arterial access. Unlike angiography, it cannot be used for angioplasty.

6.7. MRA

This imaging modality has a sensitivity of 67-100% and specificity of 75-100%, but is expensive with limited availability. There is no radiation involved and the contrast used is not nephrotoxic [31].

6.8. Angiography

This is the gold standard for diagnosis of TRAS and provides a road map that is helpful in planning treatment. Besides confirming the diagnosis and localizing the site of stenosis, it provides immediate access for PTA and placement of a stent and the outcome can be confirmed right away with another angiography (Fig 4, 5). Carbon dioxide can be used as negative contrast in cases with renal impairment to provide images comparable to standard angiography [32].

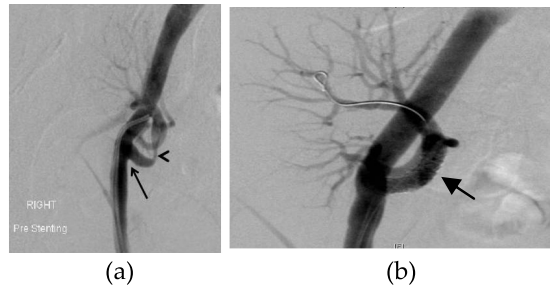


Figure 5. (a)Angiography showing allograft renal artery stenosis (arrowhead) away from site of anastomosis (arrow). (b)Post stenting angiography showing the stent in place (arrow).

7. Treatment

7.1. Conservative treatment

This is indicated when renal function is at baseline values and intrarenal RIs are >0.55 on Doppler. This suggests that renal blood flow is adequate and the stenosis is not hemodynamically significant. In such patients, the treatment of hypertension should include low dose angiotensin converting enzyme inhibitors (ACEi) and serum potassium and creatinine checked in 7-10 days. A 30% increase in serum creatinine from the baseline in cases of TRAS indicates decreased intravascular volume, low albumin or decreased cardiac output. An increase in serum potassium should be treated with exchange resins. Long term treatment should be considered if low dose ACEi are tolerated and replaced with longer acting agents. This will also help in reducing cardiovascular complications. TRAS should be monitored by Doppler at least every 6 months for evidence of progression of the stenosis by comparing the new RI and PSV values with previous ones.

7.2. Angioplasty and stenting

Before the onset of renal impairment, it can be implied that the amount of blood flow possible through the stenosis is enough to maintain normal renal function. When the stenosis becomes hemodynamically significant with evidence of renal hypoperfusion, an angiogram should be carried out to confirm the diagnosis, followed by an angioplasty to dilate the stenosis and stenting, an option that is gaining popularity. PTA is the preferred initial mode of therapy for TRAS. It is minimally invasive and safe with a reported success rate of 70-90% [33]. The variable success rate for PTA may be related to the location and length of the stenosis, and the best results have been reported when the lesions are short, linear and not at the site of anastomosis [1]. When used in anastomotic lesions, PTA alone has a low success rate with an increased risk of complications, but better results are reported when PTA is combined with stenting [34]. In cases where the artery is kinked, PTA is ineffective because the kink is related to the disparity in length of artery and vein and the kink will return once the balloon is withdrawn. After PTA alone, the short term recurrence rate of up to 30% is a major disadvantage, this risk of recurrence can however be

significantly reduced when PTA and stenting are carried out during the same procedure [35]. The low recurrence rates with primary stenting has prompted radiologists to consider stenting during the first PTA. Hung Su reported on 9 cases of TRAS treated with primary stenting after PTA without any evidence of any recurrence after a 4 year follow-up [13]. A novel development to reduce stent occlusion was the introduction of stents that release agents like rapamycin and enoxaparin locally to inhibit intimal hyperplasia [36].

8. Surgery

Indications for surgery include stenoses at the anastomotic site, kinks, severe stenosis inaccessible to PTA, failed PTA and recurrent lesions. Access to the renal arteries can be technically challenging because of scar tissue and adhesions, and serious complications can develop, including graft loss [6]. The success and minimal invasiveness of PTA and stenting has relegated surgery to the position of a salvage procedure when no other options are available. Surgical reconstruction of the transplant renal artery using preserved, blood type-matched, cadaveric donor iliac artery grafts appears promising. In a study from Wisconsin, patients treated with surgical reconstruction, hemodynamically significant TRAS lesions were noted at or within 1 to 2 mm of the anastomosis in 13 patients, in the middle of the renal artery in 4, and secondary to a kink in 2 patients. Surgical treatment was undertaken in seven patients following unsuccessful PTA. Two patients also had aneurysms of the iliac artery. Reconstruction using cadaveric iliac artery was successful in 19 of 21 (90%) patients, and only 1 these patients (4.8%) failed due to recurrence, with a median follow-up of 42 months. Graft loss secondary to TRAS occurred in only two patients. The authors claim not to have seen any long-term complications related to cadaveric iliac artery grafts [37].

9. Defining significant stenosis

After being diagnosed with TRAS on DUS, it is important to know which patients need regular monitoring and which patients require an angiogram and treatment? The lack of such a definition of significant TRAS needs to be addressed and should include both refractory hypertension and importantly, graft dysfunction (in the absence of rejection, obstruction and infection). If TRAS is causing significant ischemia and hypoperfusion, it should cause graft dysfunction. Calculating the degree of stenosis as a percentage is subjective and prone to inaccuracies and reminiscent of the classification of Mirizzi syndrome that was based on the percentage of bile duct diameter affected by stenosis [38]. The increased availability of DUS has increased the diagnosis of TRAS by 12.4% but by only 2.4% in patients already suspected of having TRAS based on the presence of refractory hypertension and renal impairment, highlighting the importance of clinical diagnosis [7]. This increase in suspected cases include those in whom the stenosis is not significant, because their renal function is normal and need only regular monitoring and follow-up like all transplant recipients. The question that needs an answer is, would an angiogram be carried out on a recipient with refractory hypertension or Doppler findings of TRAS without graft dysfunction? The advent of renal impairment on top of refractory hypertension

indicates that the present renal blood flow is not enough to maintain normal renal function and should be labeled as significant. When this point is reached, serious consideration should be given to invasive diagnosis and appropriate treatment. We feel that graft dysfunction should be considered mandatory for the diagnosis of TRAS.

An interesting issue not discussed in the literature is regarding the other effects of ischemia resulting from TRAS? This ischemia, we feel, is the crux of the matter, greater the hypoperfusion, less the blood flow to the kidney. The only proximal blood supply of the ureter is derived from the renal artery in the hilum, which is usually distal to the TRAS lesion. It can be hypothesized that this ischemia will affect that part of the ureter that is furthest from the hilum. It is somewhat surprising that no downstream complications (appropriately termed) of allograft ischemia have been reported except from our center [14].

10. Conclusions

Worsening hypertension is suggestive of TRAS, significant stenosis and ischemia result in graft dysfunction. Early diagnosis is crucial because prompt treatment can restore perfusion, prevent graft loss and cardiovascular complications. DUS is easily available and is accurate, with documentation of PSVs, RIs and parvus tardus waveforms. It can confirm revascularization and monitor renal perfusion as part of follow-up. PTA and primary stenting remain the treatment of choice, while the failures and recurrences can be treated surgically. Incidence of long standing TRAS must be reduced because it causes irreversible structural changes reflected by intrarenal RIs of >0.8 , when successful revascularization is unlikely.

Author details

Taqi Toufееq Khan and Mirza Anzar Baig

Section of renal Transplant Surgery,

Department of Nephrology and Transplantation, Riyadh Military Hospital, Saudi Arabia

Acknowledgement

Figures 2-5 with permission from CHIRURGICA, Edizioni Minerva medica-Torino.

11. References

- [1] Fervenza FC, Lafayette RA, Alfrey EJ, Petersen J. Renal artery stenosis in kidney transplantation. *Am J Kid Dis* 1998;31:142-148.
- [2] Faenza A, Spolaora R, Poggioli G, Selleri et al. Renal artery stenosis after renal transplantation. *Kidney Int Suppl* 1983;14:S54-S59.
- [3] Lo CY, Cheng IK, Tso WK, Mak KO. Percutaneous transluminal angioplasty for transplant renal artery stenosis. *Trans Proc* 1996;28:1468-1469.

- [4] Lacombe M. arterial stenosis complicating renal allotransplantation in man. A study of 38 cases. *Ann Surg* 1975;181:283-288.
- [5] Becker BN, Odorico JS, Becker YT, Leversen G et al. Peripheral vascular disease and renal transplant artery stenosis: reappraisal of transplant renovascular disease. *Clin Transplant* 1999;13:349-355.
- [6] Roberts JP, Ascher NL, Fryd DS, Hunter DW et al. Transplant renal artery stenosis. *Transplantation* 1989;48:580-583.
- [7] Wong W, Fynn SP, Higgins RM, Walters H et al. Transplant renal artery stenosis in 77 patients- does it have an immunological cause? *Transplantation* 1996;61:215-219.
- [8] Pouria S, State OI, Wong W, Hendry BM. CMV infection is associated with transplant renal artery stenosis. *QJM* 1998;91:185-189.
- [9] Audarda V, Matignona M, Hemeryb F, Snanoudjc R et al. Risk Factors and Long-Term Outcome of Transplant Renal Artery Stenosis in Adult Recipients After Treatment by Percutaneous Transluminal Angioplasty. *Am J Transpl* 2006;6:95-99.
- [10] Gray DWR. Graft renal artery stenosis in the transplanted kidney. *Transplant Rev* 1994; 8:15-21.
- [11] Khan T, Baig MA, Zahid R, Mousa D. Right renal vein augmentation in deceased donor kidney transplantation: importance of the contiguous inferior vena cava. *Urotoday Int J* 2010;3(6): doi:10.3834/uij.1944-784.2010.12.08.
- [12] Patel NH, Jindal RM, Wilkin T, et al. Renal artery stenosis in renal artery allografts: Retrospective study of predisposing factors and outcomes after percutaneous transluminal angioplasty. *Radiology* 2001;219:663-667.
- [13] Khan T, Baig MA. Distal ureteric obstruction resulting from transplant renal artery stenosis: A case report. *Urotoday Int J* 2011 April;4(2):art 21. doi:10.3834/uij.1944-5784.2011.04.03.
- [14] Khan T, Baig MA. Primary endoluminal stenting for transplant renal artery stenosis: A case report. *CHIRURGIA* 2011;24:1-2.
- [15] Bruno S, Remuzzi G, Ruggenenti P. Transplant renal artery stenosis. *J AM Soc Nephrol* 2004;15:134-141.
- [16] Marques M, Prats D, Fructuoso AS, Naranjo P et al. incidence of renal artery stenosis in pediatric enbloc and adult single kidney transplants. *Transplantation* 2001;71:164-166.
- [17] Aslam S, Salifu MO, Ghali H, Markell MS et al. common iliac artery stenosis presenting as renal allograft dysfunction in two diabetic recipients. *Transplantation* 2001;71:814-817.
- [18] Goldblatt H, Lynch J, Hanzal RF, Summerville WW. Studies on experimental hypertension: 1. the production of persistent elevation of systolic blood pressure by means of renal ischemia. *J Exp Med* 1934;59:347-379.
- [19] Mihatsch MJ, Kyo M, Morozumi K, Yamaguchi Y et al. the side effects of cyclosporine-A and tacrolimus. *Clin Nephrol* 1998;46:356-363.
- [20] Imanishi M, Akabane S, Takamiya M, Kawamura M et al. Critical degree of renal arterial ischemia that causes hypertension in dogs. *Angiology* 1992;43:833-842.
- [21] Bruno S, Ferrari S, Remuzzi G, Ruggenenti P. Doppler ultrasound in post transplant renal artery stenosis: a reliable tool for assessing effectiveness of revascularization.? *Transplantation* 2003;76:147-153.

- [22] Liard JF, Peters G. Mechanism of fall of blood pressure after unclamping in rats with Goldblatt hypertension. *Experientia* 1980;26:743-745.
- [23] Radermacher J, Mengel M, Ellis S, Stucht S et al. The renal artery resistance index and renal allograft survival. *N Engl J Med* 2003; 349:115-124.
- [24] Sawaya B, Provenzano R, Kupin L, Venkat KK. Cyclosporine induced renal microangiopathy. *Am J Kid Dis* 1988;12:534-537.
- [25] Erley CM, Duda SH, Wakat J-P, Sokler M et al. Non invasive procedures for diagnosis of renovascular hypertension in renal transplant recipients: A prospective analysis. *Transplantation* 1992; 54:863-867.
- [26] Mousa D, Hamilton D, Hassan A, Al-Sulaiman M et al. The diagnosis of segmental transplant renal artery stenosis by Captopril renography. *J Nucl Med* 1999;24:504-505.
- [27] Fuster D, Marco MP, Setoain FJ, Oppenheimer F et al. A case of renal artery stenosis after transplantation: can Losartan be more accurate than Captopril renography? *Clin Nucl Med* 1998;23:731-734.
- [28] Wei K, Le E, Bin JP, Coggins M et al. Quantification of renal blood flow with contrast enhanced ultrasound. *J Am Coll Cardiol* 2001;37:1135-1140.
- [29] Stavros AT, Parker SH, Yakes WF et al. Segmental stenoses of the renal artery: pattern recognition of tardus and parvus abnormalities with duplex sonography. *Radiology* 1992;184:487-492.
- [30] Ardalan MR, Tarzamani MK, Shoja MM. A correlation between direct and indirect Doppler ultrasonographic measures in transplant renal artery stenosis. *Transplant Proc* 2007;39:1436-1438.
- [31] Vasbinder GBC, Nelemans PJ, Kessels AGH, Kroon AA et al. Diagnostic tests for renal artery stenosis in patients suspected of having renovascular hypertension. *Ann Int Med* 2001;135:401-411.
- [32] Moresco KP, Patel NH, Namyslowski J, Shah H et al. Carbon dioxide angiography of the transplanted kidney: technical considerations and imaging findings. *Am J Roentgenol* 1998;9:1271-1276.
- [33] Greenstein S, Verstanding A, McLean G, Dafoe DC et al. Percutaneous transluminal angioplasty. *Transplantation* 1987;43:29-32.
- [34] Chiu TY, Leu HB, Wu TC, Chen JW et al. Endovascular stenting treatment for drug refractory hypertension due to ostial stenosis of transplant renal artery. *J Chin med Assoc* 2004;67:189-192.
- [35] Leertrouwer TC, Gussenhoven EJ, Bosch JL, van Jaarsveld BC et al. Stent placement for renal artery stenosis: where do we stand? A meta analysis. *Radiology* 2000;216:78-85.
- [36] Keisz RS, Buszman P, Martin JL, Deutsch E et al. Local delivery of enoxaparin to decrease re stenosis after stenting: results of initial multicenter trial: Polish-American local Lovenox NIR assessment study (The Polonia study). *Circulation* 2001;103:26-31.
- [37] Shames BD, Odorico JS, D'Allessandro AM, Pirsch JD et al. Surgical repair of transplant renal artery stenosis with preserved cadaveric iliac artery grafts. *Ann Surg* 2003;237:116-122.
- [38] Toufeeq Khan TF, Sherazi ZA, Muniandy S, Hayat FZ. Mirizzi syndrome: a simplified surgical approach and classification. *Sing Med J* 1999;40:1781-173.