
Real-Time Tissue Elastography and Transient Elastography for Evaluation of Hepatic Fibrosis

Hiroyasu Morikawa

Additional information is available at the end of the chapter

<http://dx.doi.org/10.5772/52695>

1. Introduction

Liver fibrosis develops as a sequel of chronic liver injury of various etiologies, including viral infection, immunological reaction, and toxic and metabolic insults, and is characterized by the accumulation of extracellular matrix (ECM) components produced by fibroblast-like cells including activated stellate cells and myofibroblasts in the hepatic parenchyma. Hepatic fibrosis progresses towards cirrhosis, an end-stage liver injury, leading to hepatic failure, hepatocellular carcinoma, and finally death. Hepatitis C virus (HCV) infection is the most common cause of liver fibrosis. HCV infects approximately 170 million individuals worldwide according to a report from the

World Health Organization [1]. Liver biopsy has been considered the 'gold standard' method for the evaluation of liver fibrosis in chronic hepatitis C [2]. However, liver biopsy has some limitations, including its invasiveness, risk of complications, sampling error, variability in histopathological interpretation, and the reluctance of patients to subject to repeated examinations [3-11]. Because of these disadvantages, there is a growing shift in clinical practice to utilize or develop 'non-invasive' methodologies to evaluate the stage of liver fibrosis. In particular, liver stiffness measurement by Vibration-Controlled Transient Elastography (Fibroscan) has become established as an important modality. Recently we and other investigator reported the usefulness of real-time tissue elastography (RTE) for noninvasive, visual assessment of liver stiffness in patients with chronic hepatitis C [12,13]. RTE is a method integrated in a sonography machine and developed in Japan for the visual assessment of tissue elasticity, based on a Combined Autocorrelation Method that calculates rapidly the relative hardness of tissue from the degree of tissue distortion and which displays this information as a color image [14]. This technology has already been proved to be diagnostically

valuable in the breast cancer [15]. We show here the additional value of RTE, in comparison to Fibroscan patients with chronic liver disease.

2. Principle of elastography imaging

The two major categories of non-invasive hepatic elasticity imaging are dynamic elastography techniques, such as Fibroscan, and static elastography techniques, such as RTE. At present the dynamic elastography techniques have the advantage of allowing a quantitative imaging and better resolution than the static elastography techniques. These techniques require more complex equipment for the generation mode and imaging modalities. Ultrasound and magnetic resonance imaging are the major imaging modalities. The dynamic elastography techniques may be divided into two groups, based on the method of generating the shear wave: remote generation using radiation force and mechanical vibration. Of the static elastography techniques, real time tissue elastography developed by Hitachi Medical is most advanced ultrasound technique and can reveal tissue distortion using the heart beat and pulsing of the aorta. Several elastography techniques are summarized in Table 1.

	Principle	Mode of generation	Imaging modality
Real-time Tissue Elastography (RTE)	Tissue distortion	Pulsing of the aorta	Ultrasound
Vibration-Controlled Transient Elastography (VCTE, Fibroscan)	Propagating shear wave	Mechanical vibration	Ultrasound
Acoustic Radiation Force Impulse (ARFI)	Propagating shear wave	Radiation force	Ultrasound
Magnetic Resonance Elastography (MRE)	Propagating shear wave	Mechanical vibration	Magnetic resonance imaging
Supersonic Shear Imaging (SSI)	Propagating shear wave	Radiation force	Ultrasound

Table 1. Elastography techniques for measurement of liver stiffness.

3. Real time tissue elastography

The principle underlining RTE is shown in Figure 1A, which illustrates this as a spring model [16]. When a spring is compressed, the displacement in each section of the spring depends on its stiffness: a soft spring compresses more than a hard spring. The strain distribution can be measured by differentiating the spatial displacement at each location. Although the tissue displacement usually is generated by manual compression and relaxation of the probe in practice, we were able to improve the acquisition of RTE images representing the distortion of liver tissue as a result of the beating of the heart or pulsing of the abdominal aorta.

RTE is carried out using a high quality ultrasound system (Hitachi AlokaMedical, Chiba, Japan). The software uses a complex algorithm to process in a very short time all the data coming from the lesion as radiofrequency impulses and to minimize the artifacts due to lateral dislocations, allowing accurate measurement of the degree of tissue distortion. We used the Hitachi EUB-8500 and EUP-L52 Linear probe (3–7 MHz; Hitachi AlokaMedical) for RTE.

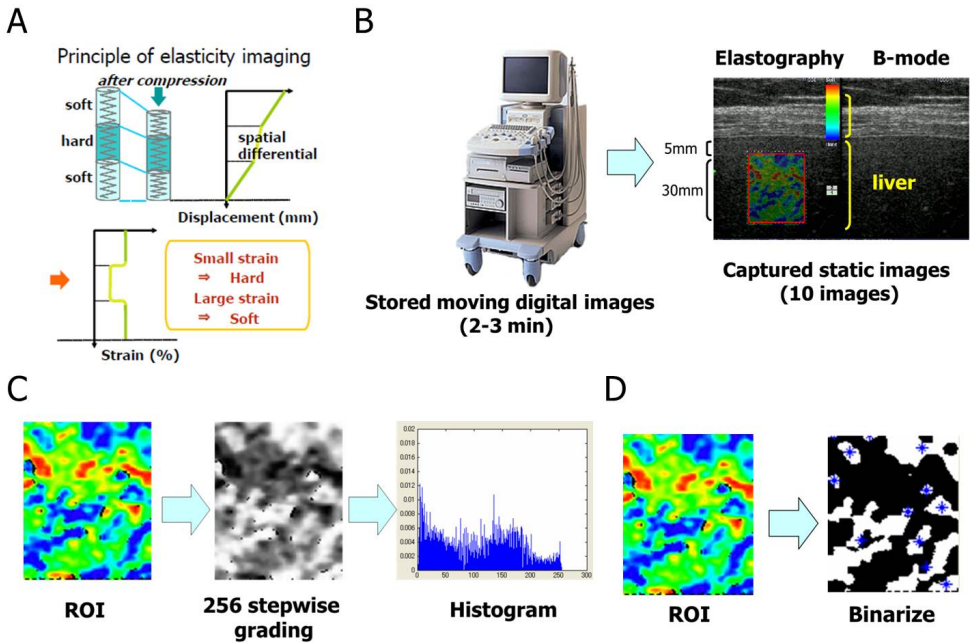


Figure 1. The principle and procedure of image analyses for real-time tissue elastography. (A) When a spring is compressed, displacement in each section of the spring depends on the stiffness of that part of the spring: a soft section compresses more than a hard section. The strain distribution can be measured by differentiating the spatial displacement at each location. (B) The ROI was fixed to a rectangle of approximately 20-30 mm length x 20 mm breadth with a 400–600 mm² area located 5-10 mm below the surface of the liver. left; RTE image, right; B-mode image. (C-D) The color-coded images from the ROI of the RTE were analyzed by the software *Elasto_ver1.5.1*. The colors ranged from blue to red indicating the relative gradients from hardness to softness. The Mean and Standard deviation were calculated by a histogram, which was generated by 256 stepwise grading derived from the color image. The Area and Complexity were calculated from the binary image. Area was derived from the percentage of white regions (asterisks, i.e. hard area). Complexity was calculated as $\text{asperiphery}^2/\text{Area}$. Median value of the data were recorded as representative of RTE parameters.

This system is currently commercially available for the diagnosis of mammary neoplasm. Patients were examined in a supine position with the right arm elevated above the head, and were instructed to hold their breath. The examination was performed on the right lobe of the liver through the intercostal space, and liver biopsy and Fibroscan also were performed at the same site. The RTE equipment displays two images simultaneously; one shows the regions of interest (ROI) as a colored area and the other indicates the conventional

B-mode image (Fig. 1B). We chose an area where the tissue was free from large vessels and near the biopsy point. The measurement was fixed to a rectangle 30 mm in length and 20 mm in breadth located 5-10 mm below the surface of the liver (Fig. 1B). The color in the ROI was graded from blue (representing hard areas) to red (representing soft areas, Fig. 1B). We stored the RTE images for 2- 3min as moving digital images (Fig. 1B) and ten static images were captured at random from the moving images by the observer using AVI2JPG v6.10 converter software (Novo, Tokyo, Japan) and analyzed on a personal computer using the novel software *Elasto_ver 1.5.1*, which was developed and donated by Hitachi Medical. Numerical values of pixels were from 0 to 255 (256 stepwise grading) according to color mapping from blue (0) to red (255), and a histogram of the distribution was generated (Fig. 1C). The scale ranged from red for components with the greatest strain (i.e., the softest components) to blue for those with no strain (i.e., the hardest components). Green indicated average strain in the ROI, and therefore intact liver tissue was displayed as a diffuse homogeneous green pattern. An appearance of unevenness in the color pattern was considered to reflect a change in the liver stiffness. For quantification, all pixel data in the colored image were transferred into a histogram and binary image (Fig. 1C, D).

4. Vibration-controlled transient elastography (Fibroscan)

Fibroscan, which has been developed for the measurement of liver stiffness, is currently considered to reflect the degree of liver fibrosis directly and better than other methods. FibroScan502 was developed by ECOSENS (Paris, France) to evaluate liver fibrosis noninvasively in a short examination period by measuring the propagation of low frequency signals of a mechanical shear wave running through the liver tissue. Fibroscan measures liver stiffness in a volume that approximates a cylinder 10-mm wide and 40-mm in length between 25 and 65 mm below the skin surface. This volume is at least 100 times greater than that obtained by liver biopsy and is therefore considered to be far more representative of the condition of the hepatic parenchyma [17-21]. The results that were obtained from ten valid measurements with a success rate of at least 60% and an interquartile range under 30% were considered successful. Failure was defined as when fewer than ten valid measurements were obtained. The median of 10 valid measurements was expressed in kilopascals (kPa) and regarded as the liver stiffness of a given subject.

Reports in 2005 from Castera et al. and Ziol et al. were pioneering; the liver stiffness measurements could be useful for assessing the presence of significant fibrosis (F2-4) and for suggesting the presence of cirrhosis in cohorts of patients with chronic hepatitis C. The AUROCs ranged from 0.79 to 0.83 for the prediction of F2-4 and were over 0.95 for the identification of cirrhosis [22, 23]. Moreover, reproducibility of Fibroscan has been shown to be excellent for both interobserver and intraobserver agreement with an intraclass correlation coefficient of 0.98 [24, 25]. Friedrich-Rust et al. [26] assessed the overall performance of TE for the diagnosis of liver fibrosis by a meta-analysis that included fifty articles; the mean AUROCs for the diagnosis of significant fibrosis, severe fibrosis, and cirrhosis were 0.84, 0.89, and 0.94, respectively. A recent report from Degos et al. [27] of a multicenter prospective study reported that the

AUROC for the diagnosis of significant fibrosis and cirrhosis were 0.76 and 0.90, respectively. Table 2 shows concisely the diagnostic accuracy of Fibroscan. The limitations of this method also have been discussed; intraobserver agreement is influenced by variables, such as body mass index (particularly when <28 kg/m²), hepatic steatosis, and flares of transaminases [17,23].

Study	Patients (n)	Prognosis	Cutoff (kPa)	Sen	Spe	PPV	NPV	AUC
Catera et al. 2005	n=183, CHC	≥F2	7.1	67%	89%	95%	48%	0.83
		Cirrhosis	12.5	87%	91%	77%	95%	0.95
Zioi et al. 2005	n=251, CHC	≥F2	8.6	56%	91%	88%	56%	0.79
		Cirrhosis	14.6	86%	96%	78%	97%	0.97
Friedrich-Rust et al. 2008	50 studies, liver disease	≥F2						0.84
		Cirrhosis						0.94
Degos et al. 2010	n=1307, viral hepatitis	≥F2	5.2	90%	34%	64%	72%	0.76
		Cirrhosis	12.9	70%	90%	53%	95%	0.79

Sen, Sensitivity; Spe, Specificity; PPV, Positive Predictive Value; NPV, Negative Predictive Value; AUC, Area Under the Receiver-Operator-Characteristic curve; CHC, chronic hepatitis C.

Table 2. Diagnostic accuracies of transient elastography

5. Acoustic Radiation Force Impulse (ARFI) and Magnetic Resonance Elastography (MRE)

The technology applied most recent is acoustic radiation force impulse (ARFI) imaging. ARFI imaging permits evaluation of the elastic properties of a region of interest during real-time B-mode conventional hepatic US examination. Results are expressed in meters per second and the region of interest can be chosen using ultrasound guidance, there by avoiding large blood vessels and the ribs. Previous reports have indicated that the diagnostic power of ARFI imaging for the staging of liver fibrosis is the same as that of Fibroscan [28, 29].

New technological advances have been made in the clinical application of MRI such as diffusion-weighted MRI and MRI elastography. The former measures the apparent diffusion coefficient of water and the parameter is dependent on the tissue structure [30]. The latter measures the propagation characteristic of the shear waves from an acoustic driver within the liver. Although MRI elastography has been shown to be superior to APRI and Fibroscan for determining the stage of fibrosis in patients with various underlying liver diseases [31], it cannot be performed on an iron-overloaded liver because of noise. In addition, MRI takes longer and costs more than the ultrasound-based elastographic examinations.

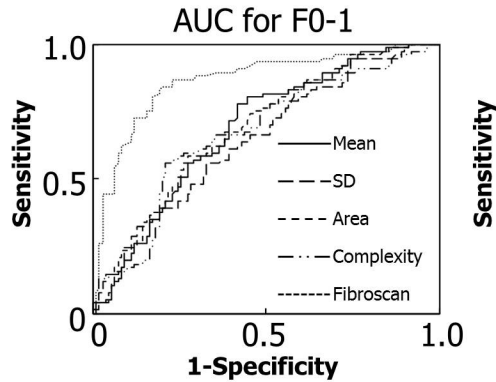
6. Our results

Patients: Two hundred and one patients with chronic hepatitis received liver biopsy and Fibroscan examination within one week after RTE procedure in the Department of Hepatology, Osaka City University Hospital between 2007 and 2010. Etiologies of chronic liver diseases were hepatitis C virus (CHC; n=129, 64.2 %), hepatitis B virus infection (n=13, 6.5 %), non-alcohol steatohepatitis (n=30, 14.9 %), and others (n=29, 14.4 %). Liver fibrosis was evaluated according to the METAVIR score. Table 3 shows the characteristics of the patients who received these examinations.

Sex: male/ female	89/112
Age	55±13 y (21-80)*
BMI (kg/m ²)	22.7±3.5 (14.1-33.2)*
Fibrosis stage(METAVIR Score)	
F0	16
F1	98
F2	33
F3	27
F4	27
Etiology	
HCV	129
NASH	30
HBV	13
Autoimmune hepatitis	9
Primary biliary cirrhosis	6
Others	14
BMI, body mass index.	

Table 3. Characteristics of the patients

Results: Histological and laparoscopic examination: 16 (8 %) patients were classified as F0, 98 (49 %) as F1, 33 (16 %) as F2, 27 (13 %) as F3, and 27 (13 %) as F4 (cirrhosis). RTE was performed successfully on all patients but Fibroscan measurements could not be obtained for 14 patients (7.0 %) because of obesity and liver atrophy. The Mean decreased in proportion to the increase of fibrosis score (Jonckheere–Terpstra test, $p < 0.0001$). SD, Area, Complexity, and Fibroscan increased in proportion to the increase of fibrosis score (Jonckheere–Terpstra test, $p < 0.0001$).



	Cut-off	AUC	Sensitivity [%]	Specificity [%]
Mean	105.6	0.69	62.3	63.1
SD	63.7	0.65	61.0	61.0
Area	31.3	0.69	62.3	65.5
Complexity	25.3	0.67	64.9	65.5
Fibroscan	10.1	0.87	84.4	80.0

Figure 2. Receiver operating characteristic curves of each parameter obtained by RTE and Fibroscan for F0-1.

Table 4 shows linear regression analysis of the values obtained by RTE compared to the liver stiffness values obtained by Fibroscan. Although simple regression analyses indicated that Mean, SD, Area, and Complexity were all significantly correlated with liver stiffness measured by Fibroscan, the *r* value did not indicate a high correlation.

Mean	$r=0.458$
SD	$r=0.377$
Area	$r=0.487$
Complexity	$r=0.451$
$p<0.001$	

Table 4. Correlation between fibroscan and the image features of RTE

The area under the receiver operating characteristic curve (AUC) for stage F0-1 were 0.69, 0.65, 0.69, 0.67, and 0.87 for Mean, SD, Area, Complexity, and Fibroscan, respectively (Fig 2). The AUC for stage F0-2 were 0.79, 0.70, 0.77, 0.73, and 0.87 for Mean, SD, Area, Complexity, and Fibroscan, respectively (Fig 3). The AUC for cirrhosis (F4) were 0.78, 0.68, 0.77, 0.76, and 0.84 for each of respective values (Fig 4).

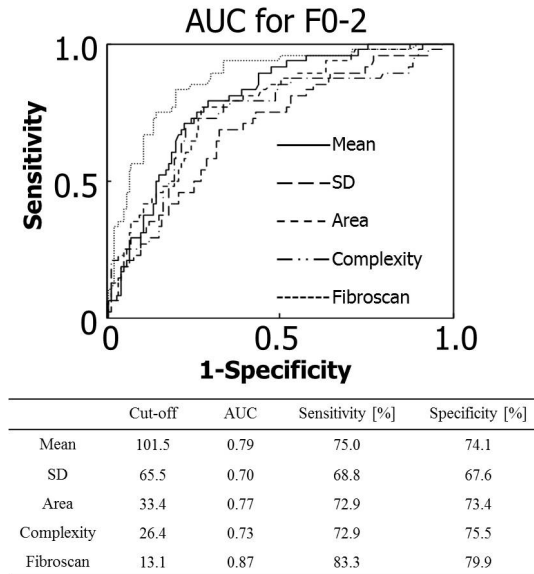


Figure 3. Receiver operating characteristic curves of each parameter obtained by RTE and Fibroscan for F0-2.

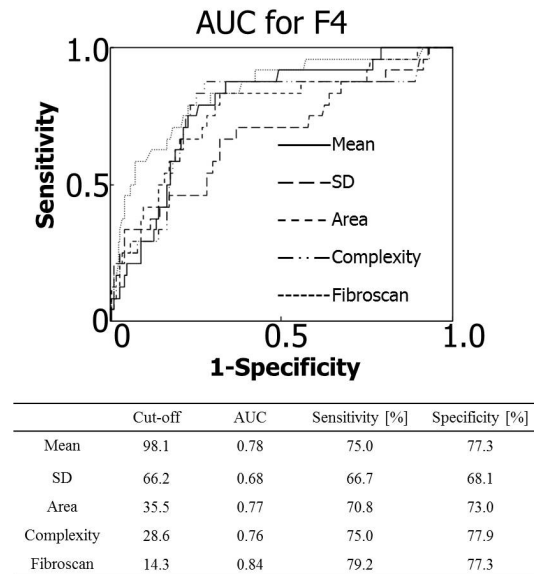


Figure 4. Receiver operating characteristic curves of each parameter obtained by RTE and Fibroscan for F4.

7. Further research

Although our results showed that RTE was inferior to Fibroscan in determining the early stage of liver fibrosis (Fig 2 and 3), Figure 4 indicated that the performance of RTE compares favorably with that of Fibroscan for detecting liver cirrhosis in patients with chronic hepatitis. Unfortunately the best method for the analysis and quantification of RTE remains unclear, but this may be determined by future multicenter studies using larger patient cohorts and the combination of these parameters will enable improvement of the accuracy of assessing hepatic fibrosis.

Fibroscan has been reported to have several limitations and disadvantages in evaluating patients with obesity and ascites. In fact, in our study, we evaluated successfully all patients with RTE, while Fibroscan measurements could not be obtained for fourteen patients because of obesity and liver atrophy (data not shown).

In the future, a combination of imaging modalities and serological parameters or of different imaging modalities will improve further the accuracy in differentiating fibrosis stages. Interestingly, Castera et al. reported that the best results were achieved by a combination of Fibroscan and the Fibro Test [22]. Although ARFI, the most recent technology, Fibroscan, and MRE are all based on shear wave propagation, RTE is constructed by an original theory which is based on tissue distortion. The best diagnostic accuracy will be obtained by combining the RTE elasticity score with shear wave propagation.

8. Conclusion

We have described a static elastography technique, RTE, for the “noninvasive” visual assessment of liver stiffness. Although RTE was inferior to Fibroscan in determining the early stage of liver fibrosis, the performance of RTE compares favorably with that of Fibroscan when detecting liver cirrhosis in patients with chronic liver disease. We suggest that RTE could also be used as a routine imaging method to evaluate the degree of liver fibrosis in patients with other liver diseases. Future studies of larger patient cohorts will be necessary for the validation of RTE analysis, and the combination of RTE with other clinical values including dynamic elastography techniques (i.e. Fibroscan, ARFI and MRE) and serum biomarkers will enable improvement of the accuracy of assessing hepatic fibrosis.

Acknowledgments

We thank Ms. Akiko Tonomura and Mr. Junji Warabino, Hitachi AlokaMedical Co., for the technical support for RTE. Hiroyasu Morikawa was supported by a research grant from the Cannon Foundation (2011-12).

Author details

Hiroyasu Morikawa

Department of Hepatology, Graduate School of Medicine, Osaka City University, Osaka, Japan

References

- [1] Global surveillance and control of hepatitis C. Report of a WHO Consultation organized in collaboration with the Viral Hepatitis Prevention Board, Antwerp, Belgium. *J Viral Hepat.* 1999;6:35–47.
- [2] Bravo AA, Sheth SG, Chopra S. Liver biopsy. *N Engl J Med.* 2001;344:495–500.
- [3] Sporea I, Popescu A, Sirli R. Why, who and how should perform liver biopsy in chronic liver diseases. *World J Gastroenterol.* 2008;14:3396–402.
- [4] Castera L, Negre I, Samii K, Buffet C. Pain experienced during percutaneous liver biopsy. *Hepatology.* 1999;30:1529–30.
- [5] Castera L, Negre I, Samii K, Buffet C. Patient administered nitrous oxide/oxygen inhalation provides safe and effective analgesia for percutaneous liver biopsy: a randomized placebo controlled trial. *Am J Gastroenterol.* 2001;96:1553–7.
- [6] Piccinino F, Sagnelli E, Pasquale G, Giusti G. Complications following percutaneous liver biopsy. A multicentre retrospective study on 68, 276 biopsies. *J Hepatol.* 1986;2:165–73.
- [7] Bedossa P, Darge`re D, Paradis V. Sampling variability of liver fibrosis in chronic hepatitis C. *Hepatology.* 2003;38:1449–57.
- [8] Regev A, Berho M, Jeffers LJ, Milikowski C, Molina EG, Pylsopoulos NT, et al. Sampling error and intraobserver variation in liver biopsy in patients with chronic HCV infection. *Am J Gastroenterol.* 2002;97:2614–8.
- [9] Rousselet MC, Michalak S, Dupre F, Croue A, Bedossa P, SaintAndre JP, et al. Sources of variability in histological scoring of chronic viral hepatitis. *Hepatology.* 2005;41:257–64.
- [10] Bedossa P, Carrat F. Liver biopsy: the best, not the gold standard. *J Hepatol.* 2009;50:1–3.
- [11] Cadranel JF, Rufat P, Degos F. Practices of liver biopsy in France: results of a prospective nationwide survey. For the Group of Epidemiology of the French Association for the Study of the Liver (AFEF). *Hepatology.* 2000;32:477–81.

- [12] Morikawa H, Fukuda K, Kobayashi S, Fujii H, Iwai S, Enomoto M, et al. Real-time tissue elastography as a tool for the noninvasive assessment of liver stiffness in patients with chronic hepatitis C. *J Gastroenterol*. 2011;46:350–8.
- [13] Koizumi Y, Hirooka M, Kisaka Y, Konishi I, Abe M, Murakami H, et al. Liver fibrosis in patients with chronic hepatitis C: noninvasive diagnosis by means of real-time tissue elastography—establishment of the method for measurement. *Radiology*. 2011;258:610–7.
- [14] Shiina T, Nitta N, Ueno E, Bamber JC. Real time tissue elasticity imaging using the combined autocorrelation method. *J Med Ultrason*. 2002;29:119–28.
- [15] Itoh A, Ueno E, Tohno E, Kamma H, Takahashi H, Shiina T, et al. Breast disease: clinical application of US elastography for diagnosis. *Radiology*. 2006;239:341–50.
- [16] Ophir J, Céspedes I, Ponnekanti H, Yazdi Y, Li X. (1991) Elastography: a quantitative method for imaging the elasticity of biological tissues. *Ultrason Imaging*. 1991;13:111–34.
- [17] Pinzani M, Vizzutti F, Arena U, Marra F. Technology insight: noninvasive assessment of liver fibrosis by biochemical scores and elastography. *Nat Clin Pract Gastroenterol-Hepatol*. 2008;5:95–106.
- [18] Sandrin L, Tanter M, Gennisson JL, Catheline S, Fink M. Shear elasticity probe for soft tissues with 1D transient elastography. *IEEE Trans Ultrason Ferroelectr Freq Control*. 2002;49:436–46.
- [19] Ganne-Carrie N, Ziol M, de Ledinghen V, Douvin C, Marcellin P, Castera L, et al. Accuracy of liver stiffness measurement for the diagnosis of cirrhosis in patients with chronic liver diseases. *Hepatology*. 2006;44:1511–7.
- [20] Yeh WC, Li PC, Jeng YM, Hsu HC, Kuo PL, Li ML, et al. Elastic modulus measurements of human liver and correlation with pathology. *Ultrasound Med Biol*. 2002;28:467–74.
- [21] Sandrin L, Fourquet B, Hasquenoph JM, Yon S, Fournier C, Mal F, et al. Transient elastography: a new noninvasive method for assessment of hepatic fibrosis. *Ultrasound Med Biol*. 2003;29: 1705–13.
- [22] Castera L, Vergniol J, Foucher J, Le Bail B, Chanteloup E, Haaser M, et al. Prospective comparison of transient elastography, Fibrotest, APRI, and liver biopsy for the assessment of fibrosis in chronic hepatitis C. *Gastroenterology*. 2005;128:343–50.
- [23] Ziol M, Handra-Luca A, Kettaneh A, Christidis C, Mal F, Kazemi F, et al. Noninvasive assessment of liver fibrosis by measurement of stiffness in patients with chronic hepatitis C. *Hepatology*. 2005;41:48–54.
- [24] Fraquelli M, Rigamonti C, Casazza G, Conte D, Donato MF, Ronchi G, et al. Reproducibility of transient elastography in the evaluation of liver fibrosis in patients with chronic liver disease. *Gut*. 2007;56:968–73.

- [25] Boursier J, Konate A, Guilluy M, Gorea G, Sawadogo A, Quemener E, et al. Learning curve and interobserver reproducibility evaluation of liver stiffness measurement by transient elastography. *Eur J Gastroenterol Hepatol*. 2008;20:693–701.
- [26] Friedrich-Rust M, Ong MF, Martens S, Sarrazin C, Bojunga J, Zeuzem S, et al. Performance of transient elastography for the staging of liver fibrosis: a meta-analysis. *Gastroenterology*. 2008;134:960–74.
- [27] Degos F, Perez P, Roche B, Mahmoudi A, Asselineau J, Voitot H, et al. Diagnostic accuracy of FibroScan and comparison to liver fibrosis biomarkers in chronic viral hepatitis: a multicenter prospective study (the FIBROSTIC study). *J Hepatol*. 2010;53:1013–21.
- [28] Friedrich-Rust M, Wunder K, Kriener S, Sotoudeh F, Richter S, Bojunga J, et al. Liver fibrosis in viral hepatitis: noninvasive assessment with acoustic radiation force impulse imaging versus transient elastography. *Radiology*. 2009;252:595–604.
- [29] Yoneda M, Suzuki K, Kato S, Fujita K, Nozaki Y, Hosono K, et al. Nonalcoholic fatty liver disease: US-based acoustic radiation force impulse elastography. *Radiology*. 2010;256:640–7.
- [30] Lewin M, Poujol-Robert A, Boelle PY, Wendum D, Lasnier E, Viallon M, et al. Diffusion-weighted magnetic resonance imaging for the assessment of fibrosis in chronic hepatitis C. *Hepatology*. 2007;46:658–65.
- [31] Huwart L, Sempoux C, Vicaut E, Salameh N, Annet L, Danse E, et al. Magnetic resonance elastography for the noninvasive staging of liver fibrosis. *Gastroenterology*. 2008;135:32–40.