Chapter 13

Application of Diode Laser in Oral and Maxillofacial Surgery

Dragana Gabrić Pandurić, Ivona Bago,
Irina Filipović Zore, Mato Sušić, Davor Katanec,
Aleksandar Milenović and Vanja Vučićević Boras

Additional information is available at the end of the chapter

http://dx.doi.org/10.5772/52404

1. Introduction

The application of light for processing materials was first described by Arristophanes in his comedy "The clouds" 423 B.C. In the 2500 years that passed until the laser was invented, light had been used both for processing material and for medical purposes in various ways. But only the laser has paved the path for widespread therapeutic use of optical radiation [1]. In 1917, Albert Einstein put forward a theory of "stimulated emission" stating that photons could "stimulate" the emission of another photon that would possess identical properties to the first [2]. The early developments of laser research started from the USA and Soviet Union in 1958. Townes and Schawlow worked to establish the principles that led to the development of the LASER (Light Amplification by Stimulated Emission of Radiation) [3, 4]. In 1960, Theodore Maiman demonstrated the first practical laser with a ruby crystal stimulated by a flashlamp and mirrors to amplify the lasing action. The beam had a deep red colour with a wavelength of 694nm [5]. When Maiman discovered the laser effect it was very difficult for him to have this discovery published in a renowned journal because no one seemed to be aware of its significance. Since the presentation of the first laser, many more materials have been discovered that are capable of producing laser light. Due to the physical particularities of the laser effect, it was not long until the wide array of possible applications were realized. It took several decades to develop reliable, appropriately designed lasers for routine use in medicine and as well as other applications [1, 6]. To understand the applications of laser surgery, it is necessary to know the fundamental principles of laser light. Laser is a special light source because in general it has higher power and a better beam quality and coherency in comparison with the other light sources. Unlike other light sources, lasers emit

coherent, monochromatic, and collimated electromagnetic radiation, with high intensity, displaying a high optical power per unit area for a given amount of energy as compared to broadband light sources. These characteristics endow the laser with unique applications. Of course, there are specific features inherent to each type of a particular laser such as the spot size, wavelength, or radiance that is important to the specific kind of application intended [4, 7]. The most common surgical lasers emit wavelengths in the infrared (IR) part of the spectrum: the Nd:YAG (λ=1,064nm), the Er:YAG (λ=2.94μm), and the CO_2 laser (λ=10.6 and 9.6μm). Within the visible portion of the electromagnetic spectrum, argon lasers emit light between 458 and 515nm, and excimer lasers are located in the ultraviolet part of the spectrum (100 to 400nm). Diode lasers emit wavelengths of 670 to 1551nm. For surgical indications, the later seem to be of increasing interest [7]. Up until now, most of the high-power lasers operated in the near IR or far IR range and there are excimer lasers that have considerable power in the UV range. Thus, there is still a gap in the middle range of the spectrum which motivated development of laser systems for the UV/VIS region of the electromagnetic spectrum [4].

For therapeutic purposes, the laser-tissue interaction mechanisms are mainly determined by two parameters, namely the laser exposure time on the tissue and the effective power density taking into account the tissue-specific absorption [1]. Whether a particular laser source is suited for biomedical purposes, either diagnostic and/or therapeutic, depends on the indication, the aforementioned excitation and de-excitation mechanisms and the extent of laser-tissue interactions. In short, laser-tissue effects and interactions depend on the interplay of irradiation parameters such as wavelength or wavelength band of the particular laser source, physical properties of the tissue irradiated with the particular wavelength, irradiance or pulse energy, continuous wave (cw) or pulsed irradiation, laser beam size on the tissue, irradiation duration or laser pulse length, repetition rate and any changes in the physical properties of the tissue as a result of laser irradiation with the parameters mentioned above [8]. Monochromaticity and high optical power are the most important properties when considering the interaction of laser light with tissue for medical applications [9]. When laser light is delivered to the tissues, or any surface, a number of specific interactions can occur. When laser energy hits a target tissue, it may be transmitted, reflected, absorbed or scattered. If a laser beam can be transmitted through a material there will be little or no absorption and therefore little or no thermal effects. The depth of transmission into tissues depends upon the tissue type, laser wavelength and laser fluence. A laser beam that is not transmitted through a material is absorbed, and as the tissue or materials absorb the laser beam, heat energy is produced which can cause thermal damage to the tissue. In order to achieve a biologic effect, the energy must be absorbed. Selective absorption is the key to the majority of laser treatments, which "target" a particular wavelength for a particular site. By choosing a wavelength of light that is preferentially absorbed by the component of tissue, it is possible to target only the chosen structure and leave surrounding tissues relatively unaffected [6, 9]. Each tissue has specific absorption characteristics based on its composition and chromophore content. The principal chromophores present in mammalian tissue are haemoglobin, melanin, wa-

http://dx.doi.org/10.5772/52404

ter and protein. Infrared light is absorbed primarily by water, while visible and ultraviolet light are primarily absorbed by hemoglobin and melanin, respectively. As wavelength decreases toward the violet and ultraviolet part of the spectrum, scatter or absorption from covalent bonds in protein limits penetration depth in this range. In order to target a specific tissue, one should select a wavelength which is strongly absorbed by chromophores present in that tissue. Most medical laser applications depend on the absorption of laser light to heat the target tissue. To prevent undesirable thermal injury to adjacent tissue, light can be applied in suitably timed pulses related to the size of the target structure according to the principle of selective photothermolysis. The proper pulse width for targeting a structure will be in this range; larger structures will be best treated with a longer pulse, and smaller structures by shorter pulses. Too long a pulse may cause adjacent structures to sustain thermal injuries; too short a pulse may cause insufficient energy to be delivered to the tissue in order to elicit a biologic effect on the target [9]. It can be concluded that with proper selection of the wavelength, exposure time and intensity of the laser, the biologic effect on the target tissue can be optimized and undesirable collateral effects on adjacent tissues can be minimized. By selecting the appropriate wavelength and pulse width, and properly delivering the applied energy, one can achieve a selective effect on the target tissue. There are five interaction mechanisms associated with the use of lasers in biomedicine:

1. *Optical effect* i.e. fluorescence spectroscopy for cancer screening, optical coherence tomography (OCT) for high-resolution imaging
2. *Photomechanical effect* (photoacustic) ie. for laser lithotripsy, removal of tattoos and certain pigmented lesions
3. *Photochemical effect* i.e. photodynamic therapy (PDT), chemical reaction stimulation, composite resin polymerization
4. *Photothermal effect* i.e. laser resurfacing, treatment of vascular lesions, laser hair removal
5. *Photobiostimulative and photobiomodulative effect* i.e. low level laser therapy (LLLT), laser acupuncture, collagen remodeling for aged skin, anti-inflammatory treatments, blue light therapy for acne treatments, accelerated wound healing [8-12].

Whether a laser system is suitable for incisions, vaporization, or coagulation is determined by the wavelength, the energy fluence, the optical characteristics of the tissues, and how the laser is operated. In continuous mode, the laser provides a constant and stable delivery of energy. Lasers within the ultraviolet region (100 to 380nm) are able to ionize tissues, a process known as photochemical desorption. Lasers of longer wavelengths, especially those within the infrared part of the spectrum (700 to 10,000nm), cause significant tissue heating. Most of the surgical lasers are embedded in this group and comprise thermal lasers. The light of these lasers is rapidly converted to thermal energy causing denaturation of proteins, decomposition of tissue, microexplosion of cell water and charring [1, 5, 7, 13-15].

2. Laser applications in OMF surgery

More than in any other dental specialty, lasers have played an integral role in the practice of OMF surgery. Lasers and rapidly becoming the standard of care for many procedures performed by oral and maxillofacial surgeons. The reason for this transition is due to the fact that many procedures can be executed more efficiently and with less morbidity using lasers as compared to a scalpel, electrocautery or high frequency devices. Because many of these procedures are routine for the practicing surgeon, the laser is merely used as a better tool to facilitate the same goals; the transition to laser surgery by most OMF surgeons has been gradual and relatively simple. Many new procedures have been developed specifically to take advantage of the unique properties of the laser or can be done only via a laser; because there is no analogous procedure using conventional surgical instruments. On the other hand, there are procedures that although possible with other modalities, have become popular to perform using the laser because of its inherent advantages. Early lasers were bulky and historically used for major cases in operating theaters; but today, access to small, portable, office-based lasers with improved intraoral delivery systems have made it possible to treat even minor routine procedures in the clinic [13-16].

2.1. Advantages

There are many advantages to the use of lasers in OMF surgery. The advantages of laser surgery include: hemostasis and excellent field visibility, precision, enhanced infection control and elimination of bacteremia, lack of mechanical tissue trauma, reduced postoperative pain and edema, reduced scarring and tissue shrinkage, microsurgical capabilities, less instruments at the site of operation, asepsis due to non-contact tissue ablation and prevention of tumor seeding [1, 15]. The hemostatic nature of the laser is of great value in OMF surgery. It allows surgery to be performed more precisely and accurately because of increased visibility of the surgical site. This characteristic is particulary useful in cases of hemangioma or removal of inflamed epulis fissurata, or any procedure involving incision of the tongue, soft palate, or tonsillar pillars. Decreased postoperative swelling is characteristic of lasers and allows increased safety when performing surgery within the airway and increases the range of surgery that can be performed safely without fear of airway compromise. This effect allows the surgeon to perform many procedures in an office or outpatient facility that previously would have required hospitalization for airway observation, postoperative nursing care, and parenteral pain management. The improvement of tissue healing and scarring is due to a combination of decreased collateral tissue damage, less traumatic surgery, more precise control of the depth of tissue damage, and fewer myofibroblasts in laser wounds [13, 15]. When lasers are used intraorally, wounds generally heal with minimal scar formation and soft, pliable residual tissue. Because of this improved healing (along with the hemostasis), intraoral wounds can often be left unsutured (another distinct advantage). Decreased postoperative pain is often noted with the use of lasers for surgery. The physiology of this effect is still unknown but probably relates to decreased tissue trauma and an alteration of neural transmission. This aspect has enabled surgeons to perform many procedures on an outpatient basis, with patients returning to work within 1 day or even immediately in many

http://dx.doi.org/10.5772/52404

cases. Hollow wave-guide technology and fiberoptics make the laser accessible to almost any area in the oral cavity, even those that would be difficult or impossible to reach with other therapeutical modalities [15]. Despite many advantages, there are disadvantages that must be carefully weighed before choosing the laser for patient treatment. As mentioned previously, healing from laser surgery is usually excellent, with decreased scarring and increased function; however, the speed of healing is usually prolonged when compared with other types of wounds. This healing delay is undoubtedly due to the sealing of blood vessels and lymphatics. Typical intraoral healing takes 2 to 3 weeks for wounds that would normally take 7 to 10 days, and this must be taken into account when considering suture removal (when used) and obtaining informed patient consent [13-15]. None of the lasers can treat all tissue conditions (due to different wavelengths), but a variety of lasers can be useful for various conditions. Different wavelength lasers are used for various indications by taking advantage of their physical properties.

2.2. Laser types

Carbon dioxide (CO_2) lasers continue to be a major instrument for soft tissue surgery for excellent affinity to water-based tissues. The wavelength of 10,600nm is readily absorbed by water thus, it will not penetrate far into tissues (0.1-0.23mm) without repeated or prolonged use making it ideal for superficial lesions and resurfacing of the skin. It is also used for removal of the sialoliths.

Nd:YAG lasers (1064nm) are used for hair removal, in addition for removal of tattoos and pigmented lesions if q-switched. Nd:YAG and Ho:YAG (2.12μm) are frequently used in bone and cartilage ablation.

Ho:YAG lasers are used for adhesions and foreign body removal while treating joint irregularities and performing discectomy of the perforated disk.

Er:YAG lasers (2.94μm) have become the most popular lasers for treatment of hard tissues, teeth and bone. Frequency doubled Nd:YAG or KTP laser (532nm) is strongly absorbed by haemoglobin, melanin and other similar pigments being used for treatment of telangiectasia and keloid scars if q-switched.

Alexandrite lasers (720-800nm) are used for hair removal and tattoo removal, if q-switched, as are the ruby laser (694nm) and dye laser (400-1000nm).

Argon (488, 514nm) and krypton lasers (531nm) are readily absorbed by hemoglobin, melanin and other similar pigmentation and are useful in the treatment of the port-wine stains. Argon, KTP, Nd:YAG and diode lasers are used to treat oral soft and/or vascular lesions by ablation, incision, excision or coagulation. The excimer laser (UV outputs) are absorbed by proteins, and mostly used in ophthalmic surgery [6, 15-17].

2.3. Laser osteotomy

Experimental laser osteotomies were performed *in vitro* and *in vivo* with use of different wavelengths including excimer lasers, Er:YAG, CO_2 and Ho:YAG lasers. The laser light

emitted by Er:YAG and CO_2 lasers are well absorbed by water. The wavelength of the Er:YAG laser, moreover, is also well absorbed by hydroxyapatite, and of the CO_2 laser is highly absorbed by collagen. Therefore, these wavelengths seem to play an increasingly important role in OMF surgery [7]. Light microscopy, histologic sections and SEM revealed no charring, but a very thin basophilic zone next to the cut surface, while cutting the trabecular structures resulted in coagulation zone [17-22].

2.4. Benigin oral lesions

For soft tissue surgery several wavelengths including Er:YAG, CO_2, Nd:YAG and diode lasers were investigated over the past years. Excision of benign lesions, such as fibroma, papilloma, mucocele, gingival lesions, benign salivary glands lesions, salivary stones, epulis fissurata, tongue lesions and hyperplastic tissue excisions, are well documented in the literature. Removal of these lesions using lasers is minimally invasive and can make the surgery less extensive, and may reduce the need for general anesthesia or in-patient hospital care, resulting in the lowered overall costs [4, 5, 15, 23].

2.5. Premalignant lesions of the oral mucosa

According to the literature, malignant transformation of premalignancies such as oral leukoplakia and oral lichen planus occurs in up to 28% of these lesions. Surgery of these lesions is mostly performed conventionally, but using laser for the removal of the premalignancies has been proven very effective being associated with recurrence rates of less then 20%. It allows precise excision, together with some of the underlying connective tissue. The heat generated reaches the deeper-lying cells and, consequently, renders very low recurrence rates. However, a delay in healing caused by the thermal laser energy is an encumbrance for the patient. As an alternative to the scalpel, the CO_2 laser has been used for more then 25 years. In recent studies, very low recurrence rates were observed with the Nd:YAG and diode lasers when treating above mentioned lesions, probably due their deep penetration of the light through the tissue [4-7, 13-16].

2.6. Selected malignant lesions

In selected patients with oral squamous cell carcinoma, as part of overall oncological management, lasers play a role in excision of the lesion, while thermal laser energy was supposed to be of value in cancer surgery, as it was assumed that thermal laser energy may seal arteries, veins and lymphatic vessels. However, advantages of laser surgery seem to be more attributable to technical handling during surgery than to oncologic parameters [4, 5, 13].

2.7. Fluorescence spectroscopy and photodynamic therapy (PDT)

Laser-induced fluorescence (LIF) spectroscopy is a non-invasive technique that has been used in various fields to differentiate tissues, and therefore might be an important tool for cancer diagnostics. Differentiation of benign and malignant tissues using this method is possible with a sensitivity above 80%. It has been shown that PDT can optimize conventional

surgery in cases of squamous cell carcinoma using a new photosensitizer meta-tetrahydroxyphenylchlorine (m-THPC). Intraoperative fluorescence-guided resection followed by PDT seem to be highly promising in improving the radicality of tumor resection combined with a conventional therapeutic approach [7, 24].

2.8. Esthetic and plastic indications

Lasers have been used for more than 25 years in cosmetic surgery of the face. Superficial vascular and pigmented lesions are most commonly treated with use of argon laser. Nd:YAG laser is used for treatment of deep vascular lesions and tumors. CO_2 laser is indicated for vaporization of exophytic lesions. One of the more common procedures performed with laser is cosmetic skin resurfacing by removing the surface layer of the epidermis and superficial papillary dermis, conctracting the dermal collagen, and allowing the skin to reepithelialize in a more uniform manner. The advantage of the laser surgery in cases of esthetic and plastic surgery is based on hemostasis, decreased scarring and decreased postoperative disability [13, 15, 24].

2.9. Surgical indications in children

In cranio-maxillofacial surgery, laser therapy is indicated in the treatment of congenital vascular malformations, such as hemangiomas or naevi flammei which are treated by argon, Nd:YAG or dye lasers. Moreover, use of the CO_2 laser was shown to be effective in cleft surgery of infants [13, 24].

2.10. Temporomandibular joint laser-assisted surgery

Arthroscopic surgery has become the treatment of choice for internal derangements of the temporomandibular joint using Er:YAG, CO_2 and Ho:YAG lasers. Using this technique procedures such as discectomy, discoplasty, synovectomy, hemostasis, posterior attachment contraction, and eminectomy can be performed on an outpatient basis through two incisions less than 2mm each [13, 15].

2.11. Dental implantology

The clinical use of lasers in modern oral implantology may be indicated in the different phases of the treatment. Lasers may be useful in pre-implant treatments when mucogingival surgery is required [24]. The most important indication of laser treatment in implantology is application in the peri-implant soft tissues, as well as decontamination of the implant surfaces in order to treat peri-implant bony defects and rehabilitate failing implants [7, 24-29]. However, apparently not all laser systems available in dentistry are of value in this regard. Nd:YAG laser can dramatically change the implant surfaces and cause melting of the implant microdesign. Better results were seen with the use of a CO_2 laser, which is not able to modify the implant surface, the temperature changes are clinically acceptable and the bacteria reduction is significant. Moreover, of potential interest is the clinical use of the diode laser, which is not able to change the implant surface and has excellent properties for incision,

excision and coagulation of the soft tissues. Recently, PDT with toluidine blue plus diode laser light was used for treatment of peri-implant diseases [24-31]. There are several confirming reports in the literature in which lasers have been used for implant site preparation [32-35]. Lasers are useful tool in the second phase of implant surgery [25, 36]. Laser irradiation has a biostimulating effect on osteoblasts, which may be used for promoting the osseointegration process of dental implants and healing of the bone defect after augmentation procedures [37-39].

2.12. Laser hemostasis

In modern societies, there is an increasing number of older patients, especially who take anticoagulant drugs. Over the past years, lasers haemostatic properties have been established. Due to deeper penetration in soft tissues, Nd:YAG and diode laser have been very effective. To reduce the thermal effect, pulsed lasers are used. Optical characteristics of blood result in scaterring and dispersion of laser light, thereby reducing the adverse effects on bony tissue [7, 31]. There are basically three photothermal techniques for laser use within the oral cavity and on the face: incisional and excisional procedures, ablation and vaporization procedures, and hemostasis. Incisional and excisional procedures are common in cases of soft tissue laser surgery using the laser device essentially as a light scalpel to make relatively deep, thin cuts such as one would do with a scalpel blade. This technique allows the surgeon to perform almost any intraoral procedure that would normally be done with conventional technique, such as incisional and excisional biopsy, lesion removal, or incision for flap access. The main advantages are bloodless surgical field and the reduced need for suturing. Tissue ablation or vaporization is used for removal of the superficial part of the tissue but generally over a fairly large area, as well as for the bone removal. The most common examples are leukoplakias, dysplasias, papillary hyperplasia, and osteotomies. In contrast to incisional procedures in which is spot size is kept small by locating the laser at its focal length; vaporization is accomplished by using larger spot sizes. This technique allows removal of a surface lesion in layers of a few hundred microns to 1-2mm at a time. Visualization of tissue anatomy is excellent, owing to the hemostasis, and the layers are identified easiliy. By removing only the epithelium less damage is done to the underlying tissues, and the risk of inadvertent damage to an underlying nerve, duct, or blood vessel is minimal. Any superficial tissue removal without the need for histologic examination can be treated using this technique. Finally, even in cases in which other modalities of treatment have been used, the laser can be used as a hemostatic tool to stop bleeding in the field and to allow for similar postoperative wound management. The cause of this effect is not coagulation of blood, but rather the contraction of the vascular wall collagen. The contraction results in constriction of the vessels and hemostasis. The technique is very useful for removal of vascular lesions in the oral and maxillofacial region [13-15]. Once these three techniques are understood, the surgeon has to decide which technique would be best for treatment of the lesion most appropriately, taking into account the laser parameters, such as power, time, and spot size to best affect the target with the least collateral damage.

http://dx.doi.org/10.5772/52404

3. Application of diode laser for soft tissue surgery

Diode lasers have a diversity of applications in the medical field. Small and compact, they can be "stacked" to produce considerable output powers. The active material is a semi-conducting crystal, usually gallium arsenide (GaAs) or similar compounds. The precise wavelength depends upon the material used in the semiconductor layers. The beam from the diode laser is usually more divergent than that of the other lasers, requiring additional optics to produce a collimated output beam. Beams can be in continuous wave or pulsed. The advantage of diode systems is their compactness, high efficiency and reliability. Some lasers devices use low power visible diode lasers instead of helium-neon (HeNe) lasers for aiming beams [6]. The diode laser is good for excising benign soft tissue lesions. Blood vessels smaller than 0.5mm in diameter are sealed spontaneously, allowing excellent visibility and precision when dissecting through the tissue planes. There is minimal cellular damage adjacent to the plane of excision. This facilitates good wound healing, and it also means that the specimen can be removed without distorsion, enabling the pathologist to provide an accurate histological diagnosis. Even large laser wounds heal with good functional results and minimal scar [15, 40]. Because of the many uncontrollable factors that determine the depth of effect of the laser into any particular tissue and the three clinician-controlled parameters (power, time and spot size), it is impossible to generalize specific laser parameters for any individual lesion. It is more important to consider each use as a unique circumstance and to adjust the parameters to provide the best results on the target, in the most controllable manner, with the least lateral thermal damage. Using typical spot sizes of 0.1 to 0.5mm, a power of 4 to 10W, is usually a good level to initiate treatment for most intraoral lesions [15]. Where the target tissue can tolerate a wider zone of coagulation necrosis, such as incisions in oral mucosa, a continuous wave may be used. At higher power densities the surgeon will have to work rapidly to minimize unwanted thermal damage. Charring will inevitably occur in inverse relationship to incisional speed [13]. Laser excision is most desirable for any solid, exophytic-type lesion because of the improved visibility and precise control of tissue removal. The laser surgery technique is lesion independent, but any lesion or tissue requiring excision and incision treated use the same basic method. It is important for the surgeon to choose when to use this technique appropriately. Once the appropriate depth has been reached, excision can be performed by grasping the tissue with the forceps, applying slight traction, and horizontally undermining the tissue in the same fashion with the laser still in focused mode [15]. Traction and countertraction of tissue with sponges, forceps, or sutures will facilitate precise surgery just as it does for conventional techniques. The target tissue should be examined to see if the desired depth is reached. As with a scalpel, several passes may be necessary to achieve this [13]. The pathologist should be informed of the use of the laser for the surgery. Wounds produced by the diode laser behave in a different manner than those produced by the scalpel. Closure of incisions and excisions performed with the laser is often at the discretion of the surgeon. Because bleeding and scarring usually are minimized, and postoperative pain does not seem to be related to closure, sutures are absolutely required only for cosmetics, when leaving the wound to granulate slowly would present an unacceptable cosmetic situation [15]. There is minimal damage to adjacent tissue and a coagulum of denatured protein forms on the surface. No dressing is required, and the

lasered area can be left exsposed in the mouth. Skin grafting is not necessary, even for large areas. The acute inflammatory reaction is delayed and minimal; few myofibroblasts are present, and there is little wound contraction. Only small amounts of collagen are laid down, resulting in little scarring or restriction in movement of the soft tissues. However, epithelial regeneration is delayed, and the wounds take a longer time to re-epithelialize [13, 40]. The diode laser offers a minimally invasive technique and can make the surgery less extensive, reduce the need for general anesthesia or hospital stay and lower the overall costs. For these reasons, it is becoming more widely popular [13, 15, 40].

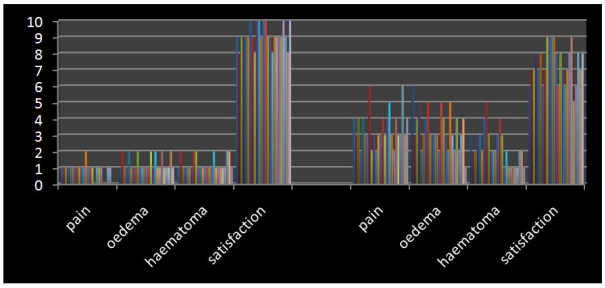

Figure 1. Comparative postoperative differences between diode laser (left) and conventional oral soft tissue surgery (right).

At the Department of Oral Surgery, School of Dental Medicine, University of Zagreb, a clinical study was performed. The aim was to compare diode laser and conventional scalpel surgery for the treatment of oral soft tissue lesions with regard to edema, hematoma, postoperative pain and patient satisfaction. The study group consisted of 7 men and 18 women, (age range 12-80, mean 44.9 ±20.8). The control group consisted of 13 men and 12 women, (age range 15-67, mean 42.4 ± 17.8). Local anesthetic (Ubistesin™, 3M ESPE, Espe Plazt, D-82229 Seefeld, Germany) was administered to all patients before the procedure. Soft tissue lesions in the control group were treated with conventional scalpel excision and silk sutures (0,3 mm, Mersillk 3.0, Ethicon, New Jersey, USA), while in the study group a diode laser (LaserHF, Hager&Werken, Duisburg, Germany, 2008.), without sutures or intraoral bandage was used. For the laser group, fibroma removal programme was used (wavelength of 975nm, power of 5W, CW). None of the soft tissue lesions, either in the study or control group, were larger than 1 cm in diameter before treatment. Three days after the surgical procedure edema, hematoma, postoperative pain and patient satisfaction were assessed by a single examiner and the patient himself. Edema was assessed as the presence of swollen tissue around incision lines and was measured in millimetres. Hematoma was defined as the presence of blood extravasation around the incision line and was measured in millimetres as well; both measurements were performed with a digital calliper. Postoperative pain was assessed via visual analogue scale (VAS, 0 – no pain at all; 10 worst possible pain). Patient satisfaction with the procedure

was also assessed on VAS (0 – dissatisfied; 10 - fully satisfied). Statistical analysis was performed with $\chi 2$ test and t-test for independent samples. P-values lower than 0.05 were considered as significant. No significant differences regarding age, gender of the participants and diagnosis were observed between the groups. Results are shown in Figure 1. Patients in the study group had significantly less edema and hematoma compared to the patients in the control group ($P<0.05$). Patients in the study group reported significantly less pain and higher satisfaction compared to the patients in the control group ($P<0.05$).

D'Arcangelo et al [41] reported that diode lasers tend to produce more changes with regard to the degree of inflammatory response and delay in tissue organization than a scalpel but only at the initial stage. Long-term results of the diode laser on the tissue histology are not known. Histological analysis on rats performed by D'Arcangelo et al showed that healing after laser surgery is not compromised; although rather slower it is satisfactory when higher output power (6W) is used. Therefore, the same authors concluded that lasers at lower output (4W) reduce the effectiveness of the incision, but minimize thermal damage of the tissues. The same authors concluded that use of diode lasers should be further investigated as they are good alternatives to the scalpel. Bryant et al [42] evaluated wound healing of oral soft tissues after diode laser irradiation and concluded that their clinical application in oral surgical procedures has beneficial effects. The absence of bleeding significantly reduces postoperative swelling and discomfort and obviates the need for sutures. There are only two studies in humans so far in the published literature which compare healing effects after carbon dioxide laser surgery and scalpel surgery [43, 44]. Jin et al [46] reported that the diode laser is a good cutting device for oral mucosa; however, more tissue damage occurs than with the use of a scalpel or an Er,Cr:YSGG laser producing more pronounced tissue change. Such changes are associated with an increased inflammatory response and an initial delay in healing. Romanos and Nentwig [47] reported that the diode laser (980 nm) was beneficial in 22 patients when treating soft tissue tumors, gingival hyperplasia, frenectomy, removal of hemangioma, vestibuloplasty and peri-implant tissue surgery. The same authors concluded that the diode laser has postoperative advantages, i.e. lack of swelling, bleeding, pain, scar formation and good wound healing. However, their results were not compared to the other surgical procedures. Furthermore, Stübinger et al [48] investigated usefulness of the diode laser in 40 patients. The same authors concluded that postoperative clinical findings were excellent due to the sufficient cutting abilities, good coagulation effect and extremely small zone of thermal necrosis to the nearby tissues. Based on the results of our study and other studies, we can conclude that diode lasers provide better outcomes for the treatment of oral soft tissue lesions when compared to the scalpel surgery; therefore laser can be employed in oral surgical procedures for coagulation effects, sterilization of the surgical site, minimizing or obviating swelling and significantly reducing postoperative pain.

3.1. Fibromas

Fibromas are often due to lip biting. The soft tissue surgery can be performed using Laser HF using the fibroma removal mode (975nm, 5W, CW) without side effects or complications after surgery (Figures. 2-6).

Figure 2. Clinical appearance of a lower lip fibroma.

Figure 3. Use of Laser HF for soft tissue surgery.

Figure 4. Postsurgical view.

Figure 5. Follow up three days after surgery.

http://dx.doi.org/10.5772/52404

Figure 6. Follow up two weeks after surgery.

3.2. Mucoceles

Mucoceles of the lip can be unroofed, then excised with gland tissue using Laser HF, again using fibroma removal mode (975nm, 5W, CW). The wound margins may be sealed with a defocused beam without side effects or complications. Re-epithelization takes about three weeks (Figures 7-11).

Figure 7. Clinical appearance of the mucocele.

Figure 8. Unroofed lesion after first laser use.

Figure 9. Excision of the lesion together with adjacent salivary gland using diode laser.

Figure 10. Final postoperative view.

Figure 11. Sealing the wound margins with a defocused beam.

3.3. Palatal lesions

Lesions of the soft palate such as traumatic fibromas in the soft palate can be treated using Laser HF, fibroma removal mode (975nm, 5W, CW). Application of LLLT immediately after surgery may expedite healing (Acupuncture mode, 660nm, 90mW, 90s interval) without side effects or complications (Figures 12-17).

http://dx.doi.org/10.5772/52404

Figure 12. Clinical appearance of the fibroma of the soft palate.

Figure 13. Usage of diode laser for soft tissue surgical procedure.

Figure 14. Application of LLLT immediately after surgery.

Figure 15. Follow up three days after surgery.

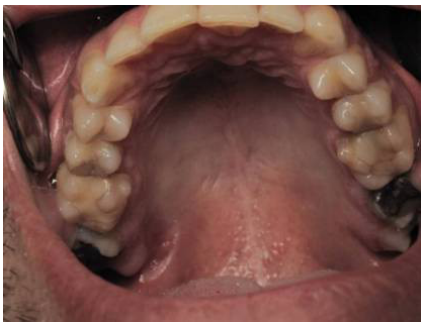

Figure 16. Follow up ten days after surgery.

Figure 17. Follow up three weeks after surgery.

Fibroepithelial polyps of the hard palate may be treated via Laser HF (Fibroma removal mode, 975nm, 5W, CW). Application of LLLT immediately after surgery may be performed (Acupuncture mode, 660nm, 90mW, 90s interval) without complications (Figures 18-22).

http://dx.doi.org/10.5772/52404

Figure 18. Clinical appearance of the palatal fibroepithelial polyp.

Figure 19. a. Surgical procedure performed using diode laser. b. Surgical specimen removed using diode laser.

Figure 20. Follow up three days after surgery.

Figure 21. Follow up seven days after surgery.

Figure 22. Follow up two weeks after surgery.

3.4. Epulis fissuratum

Epulis fissuratum of the jaws can be removed using Laser HF, via a combination of Fibroma removal (975nm, 5W, CW) and Gingivectomy modes (975nm, 3W, 10ms, 1:2), followed by LLLT application immediately after the surgical procedure (Acupuncture mode, 660nm, 90mW, 90s interval). The aPDT may also be performed (660nm, 50mW, 30s interval) without complications (Figures 23-30).

Figure 23. Clinical appearance of a maxillary epulis fissuratum.

Figure 24. Surgical procedure performed using diode laser.

http://dx.doi.org/10.5772/52404

Figure 25. Immediate postsurgical view.

Figure 26. Follow up three days after surgery.

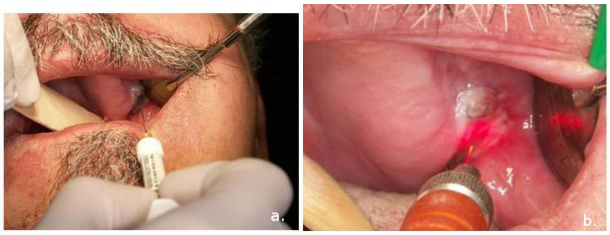

Figure 27. Application of the ''photosensitizer'', a coloring solution for aPDT, and photodynamic therapy using diode laser. b. Application of the diode laser.

Figure 28. Follow up one week after surgery.

Figure 29. Follow up two weeks after surgery.

Figure 30. Follow up five weeks after surgery.

Palatal fibroepithelial polyp and inflammatory papillary hyperplasia of the hard palate can be treated similarly using Laser HF using (Fibroma removal mode, 975nm, 5W, CW) in combination with loop of high frequency. LLLT application (Acupuncture mode, 660nm, 90mW, 90s interval) immediately after surgery (Figures 31-35).

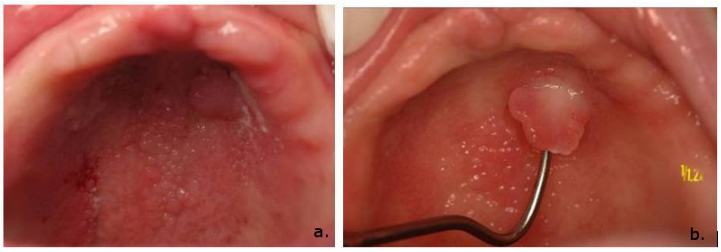

Figure 31. a. Clinical appearance of the palatal fibroepithelial polyp and inflammatory papillary hyperplasia of the hard palate. b. Clinical appearance of the palatal fibroepithelial polyp and inflammatory papillary hyperplasia of the hard palate.

http://dx.doi.org/10.5772/52404

Figure 32. Immediate postsurgical view.

Figure 33. Follow up third day after surgery.

Figure 34. Follow up one week after surgery.

Figure 35. Follow up three weeks after surgery.

3.5. Exposure of impacted teeth

Exposure of an impacted tooth (soft tissue impaction) can be done using Laser HF, (Gingivectomy mode, 975nm, 3W, CW). After laser incision around the impacted crown, the mucosal tissue is removed with an elevator until the underlying crown is identified (Figures 36-39).

Figure 36. Clinical view before surgery.

Figure 37. Incision using diode laser.

Figure 38. Removal of the mucosal flap with an elevator.

http://dx.doi.org/10.5772/52404

Figure 39. Immediate application of the orthodontic element.

3.6. Crown lengthening

Crown lengthening is easily done using lasers. After raising the mucoperiosteal flap, selective osteotomy with the surgical bur is performed. Subsequent to the suturing and frenectomy, laser gingivectomy using LaserHF (Gingivectomy mode, 975nm, 3W, 10ms, 1:2) for the lengthening of clinical crowns is done and prepared for the immediate resin restoration, prior to final ceramic restoration (Figures 40-43).

Figure 40. a. Clinical appearance before surgery b. Clinical appearance before surgery.

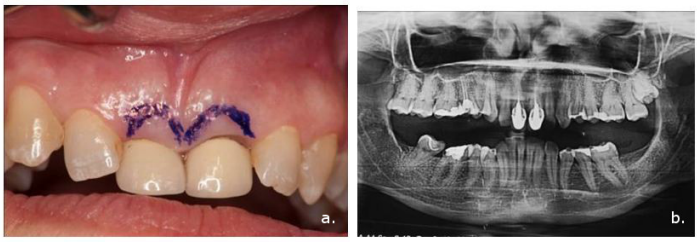

Figure 41. a. Treatment planning before surgery. b. Radiograph before surgery.

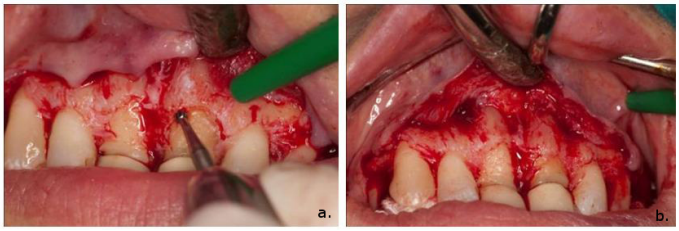

Figure 42. a. Selective osteotomy after raising the mucoperiosteal flap. b. Selective osteotomy completed.

Figure 43. a. Subsequent to the suturing and frenectomy, gingivectomy using diode laser was performed.b. Frenectomy, gingivectomy completed.

3.7. Dental implantology

Modification of the surgical laser technique can make it useful in dental implantology. The incisional mode of the diode laser can be used safely to uncover implants as long as care is taken to prevent heat conduction from surrounding tissues does not conduct back into the implant; this is done simply by limiting prolonged exposure. When using the proper wavelength, titanium does not absorb, but rather reflects the laser energy. Hydroxyapatite-coated implants might absorb this wavelength and are at risk. Another excellent use of the laser is for removal of any hyperplastic peri-implant tissue. This removal is accomplished easily by maintaining the tip of the laser parallel to the long axis of the implant, and running the laser arround the implant body. Using standard laser parameters, the tissue can be lowered uniformly to a level that allows good hygiene of the implant along with a bloodless working field [7, 15, 16, 24, 31]. The most important indication of laser treatment in implantology is application in the peri-implant soft tissues, as well as decontamination of the implant surfaces in order to treat peri-implant bony defects (open and close technique) and rehabilitate failing implants [7, 24-29]. This effect is significantly greater in combination with antimicrobial photodynamic therapy. For implant exposure in 2-stage implants, exposure of the osseointegrated dental implant in the second surgical phase can be done using Laser HF (Implant exposure mode, 975nm, 4W, CW) and healing abutment may be placed (Figures 44 a,b).

http://dx.doi.org/10.5772/52404

Figure 44. a. Dental implant exposure using diode laser. b. Healing abutment in place.

Re-exposure of osseointegrated dental implants may be performed using Laser HF (Implant exposure mode, 975nm, 4W, CW) following peri-implant mucositis and a healing abutment can be placed again; aPDT using Laser HF (PDT mode, 660nm, 50mW, 30s interval), in combination with antibiotic therapy for 5 postoperative days can be prescribed (Figures 45,46).

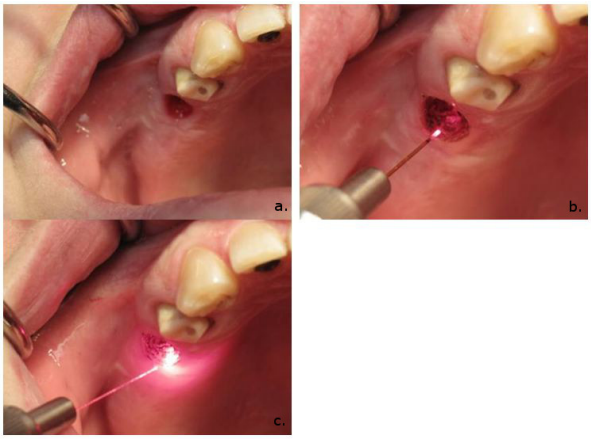

Figure 45. a. Peri implant mucositis. b. Reexposure of the dental implant using diode laser. c. Reexposure of the dental implant using diode laser.

Figure 46. aPDT and healing abutment placement.

Peri-implantitis treatment may also be done via a closed technique when identified radiographically just before second surgical phase of exposure. The aPDT using Helbo (Bredent, Senden, Germany, 2010) with 3DPerioprobe (650nm, 100mW, 60mW/cm^2), in combination with antibiotic therapy, during 10 days may be used (Figures 47-49).

Figure 47. a. Application of the photosensitizer (Helbo Endo Blue) through the periodontal area, without surgical opening. b. Application of the photosensitizer (Helbo Endo Blue) through the periodontal area, without surgical opening.

Figure 48. aPDT using diode laser with 3DPerioprobe.

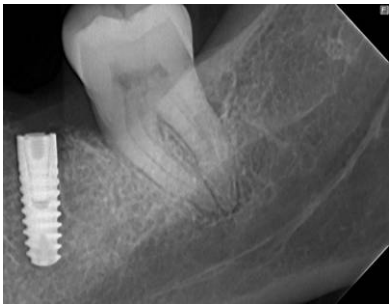

Figure 49. Control/follow-up RVG image 6 weeks after finishing the treatments and before implant exposure.

http://dx.doi.org/10.5772/52404

Advanced peri-implantitis identified on CBCT scan may also be treated. After raising the mucoperiosteal flap, periodontal treatment around implant using LaserHF (Perio-curretage mode, 975nm, 2W, 20ms, 1:4) can be used. The aPDT using the same device (PDT mode, 660nm, 50mW, 30s interval) was performed immediately before augmentation procedure and suturing (Figures 50-53).

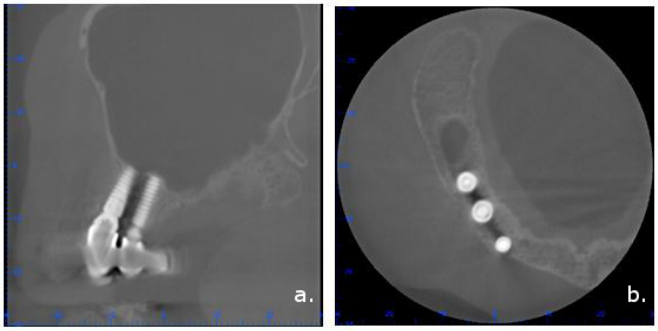

Figure 50. a. Coronal CBCT scan. b. Axial CBCT scan.

Figure 51. After diode laser periodontal treatment, aPDT using the same device.

Figure 52. a. Augmentation using bone substitute material and collagen resorbable membrane. b. Augmentation completed.

Figure 53. Follow-up OPG 12 months after peri-implantitis treatment, without any clinical symptoms.

3.8. Therapeutic uses

Diode or therapeutic lasers, also called biostimulators have an anti-inflammatory activity, being highly efficient in the rapid healing of wounds as well as the reduction of acute and chronic pain based on the photobiostimulating activity. Anti-inflammatory laser activity is based on the reduction of prostaglandin concentration (PGE2), changing the direction of arachidonic acid. It has been proven that in acute inflammatory conditions laser lowers the activity of tumor necrosis factors (TNFs). The changes in activity of neurotransmitters especially serotonin, beta-endorphin and acetylcholinesterase result in its analgesic mechanism. Diode lasers cause the transient varices along the neuron, resulting in the disturbance of transmission signals as well as the inhibition of complex reaction creating the action potential [12-15, 37-39, 48-50].

LLLT (Low Level Laser Therapy) is the application of red and near infra-red light over injuries or lesions to improve wound and soft tissue healing, reduce inflammation and give relief for both acute and chronic pain. LLLT is used to increase the speed, quality and tensile strength of tissue repair to resolve inflammation and relieve pain. The effects of LLLT are photochemical (like photosynthesis in plants). When the correct intensity and treatment times are used, the red and near infrared light reduces oxidative stress and increases adenosine triphosphate (ATP). This improves cell metabolism and reduces inflammation. Low level laser therapy effects are biochemical and not thermal and cannot cause heating and therefore do not damage living tissue. Four distinct effects are known to occur when using low level laser therapy:

- growth factor response within cells and tissue as a result of increased ATP and protein synthesis; improved cell proliferation; change in cell membrane permeability to calcium up-take
- pain relief as a result of increased endorphin release; increased serotonin; suppression of nociceptor action
- strengthening the immune system response via increasing levels of lymphocyte activity and through a newly researched mechanism termed photomodulation of blood

- acupuncture point stimulation [13, 48-50].

Antimicrobial photodynamic therapy (aPDT) is a non-thermal light-induced inactivation of cells, microorganisms or molecules. "Antimicrobial" photodynamic therapy targets pathogenic microorganisms. Using a dye, the bacteria that cause infections are stained, sensitized and destroyed following exposure with light of a suitable wavelength and energy density. A ''photosensitizer", a coloring solution (Toluidine Blue, Methylene Blue etc.) is used. The oxygen atoms in the color molecules are activated by irradiation of appropriate light. They initiate singulet conditions, which have a toxic effect on the cells [7, 13, 51].

Third molar surgery. At the Department of Oral Surgery, School of Dental Medicine, University of Zagreb, a clinical study was performed. The aim of the study was to evaluate the impact of diode laser on the healing of wounds, pain symptoms and other postoperative symptoms which usually accompany the third molar surgery. The research included 150 participants, 61% of them were females and 39% of them were males. All the participants had absolute indication for the surgical removal of the lower third molar. The participants were randomly selected into three groups: the first group "P1" consisted of 50 patients that received the antimicrobial photodynamic therapy (aPDT); the second group "P2" consisted of 50 patients that received LLLT therapy (acupuncture mode). The remaining 50 patients were controls. In the photodynamic group ''P1" (n=50) just before the surgical suturing of the wound, a photosensitive substance (toluidine blue) was applied. After 60 seconds Paro-PDT solution was thoroughly washed with saline, and laser light was applied in two intervals (30 seconds each). The radiation power was 50 mW while the wavelength was 660 nm. Laser therapy in "acupunctured second group P2" was performed before surgical suturing of the wound without the application of Paro-PDT substance. After three intervals (90 seconds each), radiation power 90 mW, wavelength the same as in the first group 660 nm, all patients received identical postoperative instructions. Postoperative follow-ups were scheduled on third and seventh day after the laser therapy for patients in groups "P1" and "P2." On those days the treatment was repeated following the same protocol as on the day of surgery, and evaluation of the healing process and postoperative complications with two questionnaires, as wells as quality of life and patient's satisfaction (OHIP-CRO14) was performed. Fourteen days after surgery all patients were contacted by e-mail or telephone considering certain problems if problems occurred, and their satisfaction with the results of the surgery was noted. Average score of pain, swelling, halitosis, difficulties in feeding, sleeping and speech was exponentially lower within 14 days after postoperative monitoring in all 3 groups of patients (P1, P2 and K). The greatest drop of the average score, and the lowest intensity and number of postoperative problems was found in the group of patients treated with aPDT. This result can be explained with the positive influence of laser therapy, but also with the additional antimicrobial effect within hardly reachable places of toluidine chloride solution which was used in "P1" group of patients. Patients in laser acupuncture therapy group (LLLT) (P2), on the first and third postoperative day, did not show lower intensity of postoperative problems considering the control (K) group. On the seventh and fourteenth day, the intensity of problems was lower and equalized with the intensity of postoperative problems of the P1 group, which were better results considering the results of

the control group on the days mentioned. Results can be explained with the cumulative effect of laser therapy, while every new postoperative received dose of laser radiation stays and cumulates in the tissue. Every new dose of laser therapy had stronger effect on tissue that the one received before. The best indicators of positive effects with laser therapy on all of the postoperative problems can also be seen considering the difference with patient's work days lost between the groups. Results are shown on Figures 54-56, and Tables 1 and 2.

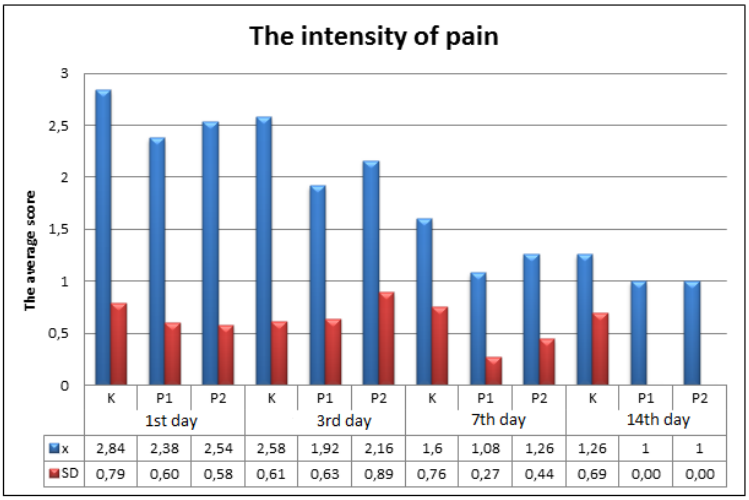

Figure 54. Distribution of pain intensity between groups.

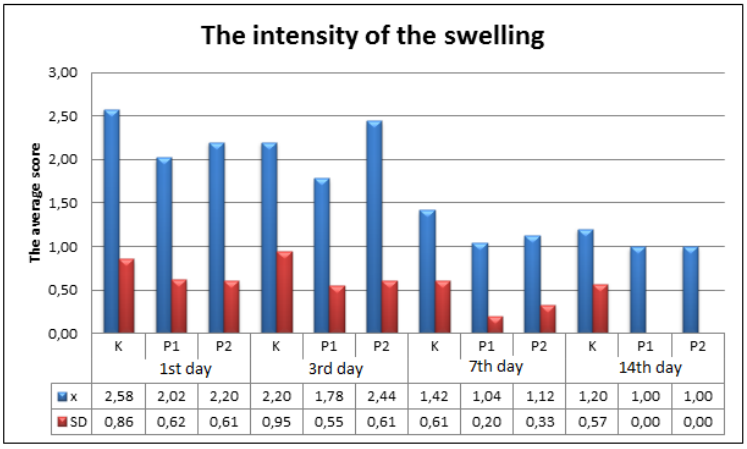

Figure 55. Distribution of swelling intensity between groups.

http://dx.doi.org/10.5772/52404

Variable	F	Df	P		Investigated groups of participants		
					P1	P2	K
Eating 1st postoperative day	3,46	149	0,034*	P1		NS	
				P2			
				K			
					P1	P2	K
Eating 3rd postoperative day	6,79	149	0,002**	P1		0,003**	0,022*
				P2		0,003**	NS
				K	0,022*	NS	
					P1	P2	K
Eating 7th postoperative day	17,90	149	<0,001**	P1		NS	<0,001**
				P2	NS		<0,001**
				K	<0,001**	<0,001**	
					P1	P2	K
Eating 14th postoperative day	5,16	149	0,007**	P1		NS	0,023*
				P2	NS		0,023*
				K	0,023*	0,023*	

Table 1. *=significant with 95% confidence; **= significant with 99% confidence; NS=non significantThe significance of differences in postoperative quality in eating.

Variable	F	Df	p		Investigated groups of participants		
					P1	P2	K
Halitosis 1st postoperative day	4,22	149	0,016*	P1		NS	0,02*
				P2	NS		NS
				K	0,02*	NS	
					P1	P2	K
Halitosis 3rd postoperative day	7,23	149	0,001**	P1		0,004**	0,008**
				P2	0,004**		NS
				K	0,008**	NS	
					P1	P2	K
Halitosis 7th postoperative day	17,37	149	<0,001**	P1		NS	<0,001**
				P2	NS		<0,001**
				K	<0,001**	<0,001**	
					P1	P2	K
Halitosis 14th postoperative day	8,02	149	<0,001**	P1		NS	0,002**
				P2	NS		0,005**
				K	0,002**	0,005**	

Table 2. *=significant with 95% confidence; **= significant with 99% confidence; NS=non significantThe significance of differences in the intensity of postoperative halitosis.

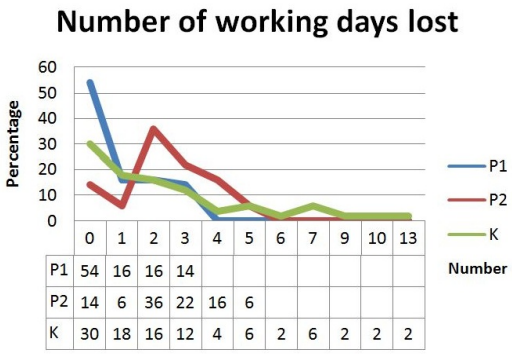

	0	1	2	3	4	5	6	7	9	10	13
P1	54	16	16	14							
P2	14	6	36	22	16	6					
K	30	18	16	12	4	6	2	6	2	2	2

Figure 56. Distribution of the number of working days lost in groups.

Based on these results, it was concluded that:

- aPDT group (P1) had the lowest postoperative problems of all three groups.
- No complications in patients from groups P1 and P2 were found.
- Laser therapy significantly reduces postoperative problems after third molar surgery.
- Postoperative application of laser therapy reduces patient's use of analgesics.
- Laser therapy application prevents fever, and postoperative inflammation.
- Laser therapy improves patient's postoperative quality of life, reduces the number of lost working days.

3.9. Endodontic surgery

Among the various lasers appearing in the mid 1990s, diode lasers represent an attractive and valuable system due to many advantages including small size, possibility of various treatment applications, low power consumption and attractive price which makes them accessible to a wide range of dental professionals. Diode lasers have been used in soft tissue surgery, periodontal pocket therapy and peri-implantitis. Effective application is demonstrated also in endodontics, for root canal decontamination, and tooth whitening. The sterilization effect of the diode laser resembles that of Nd:YAG laser because their wavelengths are not absorbed by hard dental tissues so they do not have ablative effect on dentinal surface, and the risk of adverse effects is greatly diminished. In addition, this laser system has the bactericidal effect deep in the dentin. The 810 nm diode laser is able to penetrate the dentinal walls up to 750 μm. It has been demonstrated as being highly effective in decontamination of the root canals when used as a final disinfection protocol after chemomechanical preparation [52, 53]. De Souza et al [53] reported increased disinfection of the deep radicular dentin after irradiation with the 830 nm diode laser set at 3W for 5 s, repeated 4 times at intervals of 10 s. Gutknecht et al [54] have found 99.91% reduction in the bacteria number after irradiating teeth, which were previously incubated with *E. faecalis* suspension. Moritz

et al. [55] compared the antimicrobial efficacy of a diode laser (2W, 20ms pulse duration, 50 Hz) and conventional root canal disinfection methods in an *in vivo* study. He found higher reduction of streptococci and staphylococci in the laser group after each appointment during the endodontic therapy. Contrary results were reported in a clinical study of Gutknecht et al. [56], where no difference between the diode laser and 5% hypochlorite, when used for the root canal disinfection, was found. When using laser therapy, a major concern is the thermal effect of the laser energy on periodontal and alveolar bone tissues. The high energies that are delivered by medical lasers can lead to irreversible thermal damage to the surrounding structures. A study indicated that bone tissue was sensitive to heat at the level of 47°C, which represented an approximate 10°C increase in temperature for 1min [57]. Moritz et al [58] demonstrated that as long as correct parameters were used there was no need for concern. After measuring the canal depth, the optic fiber should be inserted in the root canal to 1 mm from the apex. As the fiber emits light from its distal end only, it should be withdrawn in slow spiral-forming movements from the apical to the coronal part in order to irradiate the dentinal walls completely, and to avoid excessive temperature rise on the tooth surface. It is very important to keep the fiber in constant motion during the root canal irradiation because if the fiber is kept stationary in the root canal, temperature rises.

Apart from decontamination efficacy, laser therapy has shown great promise in the removal of the smear layer and debris that remains on the root canal walls after mechanical instrumentation. Removal of the smear layer facilitates the antibacterial effect of intracanal irrigants and medicaments, and deeper penetration and adaptation of a filling material to the canal walls. Several studies have shown that the diode laser has similar effects on the dentinal walls like Nd:YAG laser, closing the opening of the tubules [58, 59].

Diode lasers energy has also been recommended to activate chemical irrigants such as 17% EDTA and sodium hypochlorite in LAI technique. Hmud et al. [60] used the 940 and 980 nm diode lasers with output power of 0.5-7W at 1-10Hz to activate water. They concluded that laser energy, delivered in the fluid, created cavitations, which could have potential to enhance the removal of debris and smear layer. Diode lasers with lower wavelengths and output powers of several milliwatts can be used to activate various photosensitizers, which in turns exert a lethal effect on bacteria [61]. There are several terms for this photochemical interaction: photo activated disinfection (PAD), photodynamic disinfection (PDD) or antimicrobial photodynamic therapy (aPDT).

Antimicrobial photodynamic therapy is based on the concept that a nontoxic photosensitizer, which bears a positive charge can directly target both gram-positive and gram-negative bacteria. After exposure to the light of an appropriate wavelength, the photosensitizer is activated, resulting in energy or electron transfer to available molecular oxygen with consequent formation of highly reactive oxygen such as singlet oxygen and free radicals. This process produces a cascade of oxidative events that cause damage to intracellular proteins, membrane lipids, and nucleic acids. In recent years, photodynamic therapy has been evaluated in root canals in many *in vitro* [62, 63] and *in vivo* studies [64, 65]. These studies suggested the potential of photodynamic therapy as an adjunct to conventional chemomechanical root canal preparation [66, 67]. Recent *in vivo* study of Silva et al [68] evaluated the

response of the apical and periapical tissues of dogs' teeth with apical periodontitis after one-session endodontic treatment with and without aPDT. They found moderate neoangiogenesis, fibrogenesis without signs of inflammation in the periapical region after aPDT, and concluded that aPDT could be a promising adjunct therapy to the one-session conventional chemomechanical root canal treatment. Garces et al. [65] conducted a randomized clinical study to find the benefits of aPDT used as an adjunct to conventional root canal treatment in patients with necrotic pulp harboring microflora resistant to previous antibiotic therapy. Their results showed that this combination of endodontic therapy and aPDT eradicated all 9 multi-drug resistant bacterial species in root canals.

Bago et al [69] compared in a recent *ex vivo* study performed at the Department of Endodontics and Restorative Dentistry and the Department of Oral Surgery, School of Dental Medicine, University of Zagreb, the antimicrobial action of a 975 nm diode laser (2W, t-on 5ms, t-off 25 ms, irradiation time: 20 s repeated for 3 times), aPDT, conventional and sonic activated irrigation, using EndoActivator system (Dentsply Maillefer) during root canal treatment against *E. faecalis* biofilm. The PDT was performed with 660 nm diode laser (Laser HF, Hager Werken, Duisburg, Germany), which uses toluidine blue, and with the Helbo laser (Grieskirchen, Austria), which uses phenothizine chloride. Power of both lasers was set at 100 mW and root canals were irradiated for 60 s. The results clearly showed the superiority of the PAD and the sonic activated irrigation, which achieved 99.99% reduction rate. Only these techniques succeeded in the eradication of *E. faecalis* from the root canals of 6 samples. Regarding the high-power diode laser, the results demonstrated greater difficulties in eliminating *E. faecalis*. Survival of *E.faecalis* and lower reduction rate can be attributed to the high resistance of *E. faecalis* to heat, due to its cell-wall structure [70].

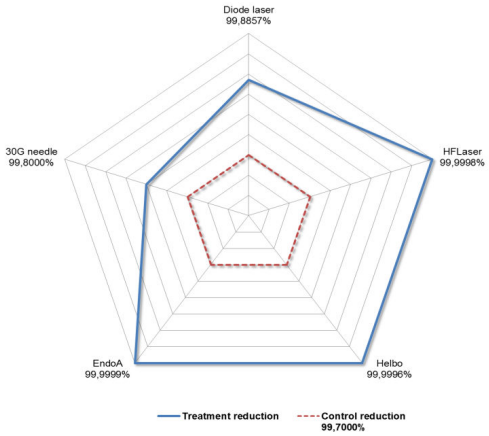

Figure 57. Antimicrobial efficacy of a high-power diode laser, photo activated disinfection, conventional and sonic activated irrigation.

http://dx.doi.org/10.5772/52404

The complexity of root canal system (inaccessible or unreachable areas such as isthmus, anastomoses, cul de sacs, fins), biofilm and therapy resistant micro-organisms on the root canal wall and in dentinal tubuli, make complete debridment and removal of bacteria almost impossible. The failure of the conservative endodontic therapy of teeth with periapical process, that do not heal, requires endodontic surgery protocols. Therefore, the application of laser in the root canals system has been recommended in many *in vivo* and *in vitro* studies due to its ability to disinfect root canals effectively. However, laser therapy cannot be used instead of the conventional instrumentation/irrigation protocol but as an adjunctive final disinfection protocol. Special attention has been given to the evaluation of the antimicrobial photodynamic therapy, which shows great promise in the field of endodontic disinfection, particularly because it does not affect ''friendly" bacterial flora, nor host cells.

3.10. Safety aspects

Lasers and intense pulsed light systems continue to advance rapidly in technology and applications. Serious consideration must be given to the correct selection, installation, training and use of the equipment. Many hazards exist with laser use, including electrical, mechanical, chemical, biological, optical and firehazards as well as concerns with regards to toxic effect of laser plume. Control measures should be implemented to minimize these hazards in accordance with legislation and common sense, and protective equipment that is available should be used and maintained appropriately [6]. It is recommended that a laser safety policy and procedure be written in each institution using lasers to treat patients. Laser safety warning signs should be placed on the door of any operating room using laser prior to usage. These signs should include the type and power of the laser being used [14].

The first aspect is the device safety. During the laser operation the actual power output must be supervised and if defective system causes a wrong dosage, an alarm must be activated. A safety switch off in the case of a component breakdown should be a standard feature of any medical laser system. Another aspect is the safety of staff and patients when laser procedures is undertaken. A prime consideration in laser safety is appropriate eyewear for both staff and patients. The patient must be protected against unintentional irradiation by safety covers and non-inflammable tubing, anaesthetics, and sterile sheets must be used. The issue of carrying off excessive heat and any pyrolysis products, which may be generated, must be reconsidered. It should be noted that dental mirrors absorb laser energy to various degrees and thus should never be deliberately lased. Likewise, surfaces which present reflection hazards should be identified and avoided. Generous use of wet gauze squares within the oral cavity provides an effective means for "trapping" scattered and reflected laser energy and for protecting soft tissues [1, 31]. Finally, it should be noted that lasers used during general anesthesia may pose a risk of ignition for flammable anesthetic gases [14, 15, 31].

4. Conclusion

Laser technology has made rapid progress over few past decades, and lasers have found a niche in many surgical specialities. Because of their many advantages, lasers have become indispensable in OMF surgery as an additional modality for soft tissue surgery. There are many uses for lasers in OMF surgery, and the advent of new wavelengths will undoubtedly lead to new procedures that can be performed with laser technology.

Practitioners should be satisfied that novel clinical approaches have a sound scientific basis, and are not adopted solely just on the basis of anecdotal reports or incomplete research. Despite the enthusiastic acceptance of this technology by professionals and the public, further research, including controlled clinical studies, to investigate the higher efficacy, as well as the other side effects of laser therapy, is still needed.

As Dr. Theodore Maiman, the inventor of the first laser stated: "The medical application of the laser is fascinating for two reasons. It is an optimistic mission on the one hand, while on the other it counteracts the original impression of the laser being a death ray."

Acknowledgements

The authors are grateful to Hager&Werken and Bredent for technical support. We would like to especially thank all employees of the Department of Oral Surgery and Department of Endodontics and Restorative Dentistry, School of Dental Medicine, University of Zagreb.

Author details

Dragana Gabrić Pandurić[1*], Ivona Bago[2], Irina Filipović Zore[1], Mato Sušić[1], Davor Katanec[1], Aleksandar Milenović[3] and Vanja Vučićević Boras[4]

*Address all correspondence to: dgabric@sfzg.hr

1 Department of Oral Surgery, School of Dental Medicine, University of Zagreb; University Dental Clinic, Clinical Hospital Center Zagreb, Croatia

2 Department of Endodontics and Restorative Dentistry, School of Dental Medicine, University of Zagreb; University Dental Clinic, Clinical Hospital Center Zagreb, Croatia

3 Department of Oral and Maxillofacial Surgery, School of Dental Medicine, University of Zagreb; Clinical Hospital Dubrava, Croatia

4 Department of Oral Medicine, School of Dental Medicine, University of Zagreb; University Dental Clinic, Clinical Hospital Center Zagreb, Croatia

References

[1] Müller, J. G., Berlien, P., & Scholz, C. (2006). The Medical Laser. *Medical Laser Application*, 21(2), 99-108.

[2] Einstein, A. (1917). Zür Quantentheorie der Stralung. *Physiol Z*, 18-121.

[3] Schawlow, A. L., & Townes, C. H. (1958). Infrared and Optical Masers. *Physical Review*, 1112-1940.

[4] Golnabi, H., & Mahdieh, M. H. (2006). Trend of Laser Research Developments in Global Level. *Optics & Laser Technology*, 38(2), 122-131.

[5] Maiman, T. H. (1960). Stimulated Optical Radiation in Ruby. *Nature*, 187-493.

[6] Shokrollahi, K., Raymond, E., & Murison, MS. (2004). Lasers: Principles and Surgical Applications. *Journal of Surgery*, 2(1), 28-34.

[7] Deppe, H., & Horch, H. H. (2007). Laser Applications in Oral Surgery and Implant Dentistry. *Lasers in Medical Science*, 22(4), 217-221.

[8] Driggers, R. G. (2003). Encyclopedia of Optical Engineering. *New York: Taylor&Francis*.

[9] Niemz, M. H. (2007). Laser-Tissue Interactions: Fundamentals and Applications (Biological and Medical Physics, Biomedical Engineering). *Springer-Verlag: Berlin*.

[10] Dederich, D. N. (1991). Laser/Tissue Interaction. *Alpha Omegan*, 84(4), 33-36.

[11] Dederich, D. N. (1993). Laser/Tissue Interaction: What Happens to Laser Light When it Strikes Tissue? *Journal of American Dental Association*, 124(2), 57-61.

[12] Parker, S. (2007). Verifiable CPD Paper: Laser-Tissue Interaction. *British Dental Journal*, 202(2), 73-81.

[13] Clayman, L., & Kuo, P. (1997). Lasers in Maxillofacial Surgery and Dentistry. *Thieme: New York*.

[14] Convissar, R. A. (2010). Principles and Practise of Laser Dentistry. *Mosby Elsevier: St Louis*.

[15] Strauss, R. A. (2000). Lasers in Oral and Maxillofacial Surgery. *Dental Clinics of North America*, 44(4), 851-873.

[16] Stabholz, A., Zeltser, R., Sela, M., Peretz, B., Moshonov, J., Ziskind, D., & Stabholz, A. (2003). The Use of Lasers in Dentistry: Principles of Operation and Clinical Applications. *Compendium of Continuing Education in Dentistry*, 24(12), 935-948.

[17] Gabrić, Pandurić. D. (2010). Physical and Ultrastructural Bone Effect Comparison Between Laser and Surgical Drill. PhD thesis. *University of Zagreb*.

[18] Eyrich, G. K. (2005). Laser-Osteotomy Induced Changes in Bone. *Medical Laser Application*, 20(1), 25-36.

[19] De Mello, E. D., Pagnoncelli, R. M., Munin, E., Filho, M. S., de Mello, G. P., Arisawa, E. A., & de Oliveira, M. G. (2008). Comparative Histological Analysis of Bone Healing of Standardized Bone Defects Performed With the Er:YAG Laser and Steel Burs. *Lasers in Medical Science*, 23(3), 253-260.

[20] Li, Z. Z., Reinisch, L., & Van de Merwe, W. P. (1992). Bone Ablation With Er:YAG and CO_2 Laser: Study of Thermal and Acoustic Effects. *Lasers in Surgery and Medicine*, 12(1), 79-85.

[21] Walsh, J. T. Jr, Flotte, T. J., & Deutsch, T. F. (1989). Er:YAG Laser Ablation Tissue: Effect of Pulse Duration and Tissue Type on Thermal Damage. *Lasers in Surgery in Medicine*, 9(4), 314-326.

[22] Frentzen, M., Götz, W., Ivanenko, M., Afilal, S., Werner, M., & Hering, P. (2003). Histological Results After Osteotomy With 80-μs CO_2 Laser Pulses and Air-Water Spray. *International Congress Series*, 1248, 383-384.

[23] Gontijo, I., Navarro, R. S., Haypek, P., Ciamponi, A. L., & Haddad, A. E. (2005). The Applications of Diode and Er:YAG Lasers in Labial Frenectomy in Infant Patients. *Journal of Dentistry for Children (Chic)*, 72(1), 10-15.

[24] Deppe, H., & Horch, H. H. (2007). Current Status of Laser Application in Oral and Cranio-Maxillofacial Surgery. *Medical Laser Application*, 22(1), 39-42.

[25] Romanos, G. E. (2003). Laser Surgical Tools in Implant Dentistry for the Long-Term Prognosis of Oral Implants. *International Congress Series*, 1248-109.

[26] Deppe, H., Horch, H. H., Greim, H., Brill, T., Wagenpfeil, S., & Donath, K. (2005). Peri-Implant Care With the CO_2 Laser: In Vitro and In Vivo Results. *Medical Laser Application*, 20(1), 61-70.

[27] Kreisler, M., Götz, H., & Duschner, H. (2002). Effect of Nd:YAG, Er:YAG, CO2, and GaAIAs Laser Irradiation on Surface Properties of Endosseous Dental Implants. *International Journal of and Oral Maxillofacial Implants*, 17(2), 202-211.

[28] Matsuyama, T., Aoki, A., Oda, S., Yoneyama, T., & Ishikawa, I. (2003). Effects of the Er:YAG Laser Irradiation on Titanium Implant Materials and Contaminated Implant Abutment Surfaces. *Journal of Clinical Laser Medicine and Surgery*, 21(1), 7-17.

[29] Park, C. Y., Kim, S. G., Kim, M. D., Eom, T. G., Yoon, J. H., & Ahn, S. G. (2005). Surface Properties of Endosseous Dental Implants After Nd:YAG and CO2 Laser Treatment at Various Energies. *Journal of Oral and Maxillofacial Surgery*, 63(10), 1522-1527.

[30] Giannini, R., Vassalli, M., Chellini, F., Polidori, L., Dei, R., & Giannelli, M. (2006). Neodymium:yttrium Aluminium Garnet Laser Irradiation With Low Pulse Energy: a Potentional Tool for the Treatment of Periimplant Disease. *Clinical Oral Implants Research*, 17(6), 638-643.

[31] Walsh, L. J. (1992). The Use of Lasers in Implantology: an Overview. *Journal of Oral Implantology*, 18(4), 335-340.

[32] Schwarz, F., Olivier, W., Herten, M., Sager, M., Chaker, A., & Becker, J. (2007). Influence of Implant Bed Preparation Using an Er:YAG Laser on the Osseointegration of Titanium Implants: a Histomorphometrical Study in Dogs. *Journal of Oral Rehabilitation*, 34(4), 273-281.

[33] Kesler, G., Romanos, G., & Koren, R. (2006). Use of Er:YAG Laser to Improve Osseointegration of Titanium Alloy Implants- a Comparison of Bone Healing. *International Journal of Oral and Maxillofacial Implants*, 21(3), 375-379.

[34] Salina, S., Maiorana, C., Iezzi, G., Colombo, A., Fontana, F., & Piattelli, A. (2006). Histological Evaluation, in Rabbit Tibiae, of Osseointegration of Mini-Implants in Sites Prepared With Er:YAG Laser Versus Sites Prepared With Traditional Burs. *Journal of Long Term Effects of Medical Implants*, 16(2), 145-156.

[35] El -Montaser, M., Devlin, H., Dickinson, M. R., Sloan, P., & Lloyd, R. E. (1999). Osseointegration of Titanium Metal Implants in Erbium-YAG Laser-Prepared Bone. *Implant Dentistry*, 8(1), 79-85.

[36] Arnabat-Dominguez, J., Espana-Tost, A. J., Berini-Aytés, L., & Gay-Escoda, C. (2003). Erbium:YAG Laser Application in the Second Phase of Implant Surgery: a Pilot Study in 20 Patients. *International Journal of Oral and Maxillofacial Implants*, 18(1), 104-112.

[37] Dörtbudak, O., Haas, R., & Mallath-Pokorny, G. (2000). Biostimulation of Bone Marrow Cells With a Diode Soft Laser. *Clinical Oral Implants Research*, 11(6), 540-545.

[38] Pinheiro, A. L., Lopes, C. B., Sathaiah, S., & Duarte, J. (2003). Laser Biomodulation in Bone Implants: a Raman Spectral Study. *International Congress Series*, 1248-449.

[39] Pinheiro, A. L., Limeira Junior., F.de A., Gerbi, M. E., Ramalho, L. M., Marzola, C., & Ponzi, E. A. (2003). Effect of Low Level Laser Therapy on the Repair of Bone Defects Grafted With Inorganic Bovine Bone. *Brazilian Dental Journal*, 14(3), 177-181.

[40] Frame, J. W. (2003). Recent Progress With the CO2 Laser in Oral Surgery. *International Congress Series*, 1248-3.

[41] D'Arcangelo, C., Di Nardo Di, Maio. F., Prosperi, G. D., Conte, E., Baldi, M., & Caputi, S. (2007). A Preliminary Study of Healing of Diode Laser Versus Scalpel Incisions in Rat Oral Tissue: a Comparison of Clinical, Histological, and Immunohistochemical Results. *Oral Surgery Oral Medicine, Oral Pathology, Oral Radioliology, and Endodontics*, 103(6), 764-773.

[42] Bryant, G. L., Davidson, J. M., Ossoff, R. H., Garrett, C. G., & Reinisch, L. (1998). Histologic Study of Oral Mucosa Wound Healing: a Comparison of a 6.0 to 6.8-Micrometer Pulsed Laser and a Carbon Dioxide Laser. *Larygoscope*, 108(1 Pt 1), 13-17.

[43] Greene, C. H., Debias, D. A., Henderson, M. J., Fair-Covely, R., Dorf, B., Radin, A. L., & Young-Seidman, W. L. (1994). Healing of Incisions in the Tongue: a Comparison of

Results with Miliwatt Carbon Dioxide Laser Tissue Welding Versus Suture Repair. *Annals of Otology, Rhinology and Laryngology*, 103(12), 964-974.

[44] Liboon, J., Funkhouser, W., & Terris, D. J. (1997). A Comparison of Mucosal Incisions Made by Scalpel, CO2 Laser, Electrocautery and Constant-Voltage Electrocautery. *Otolaryngology- Head and Neck Surgery*, 116(3), 379-385.

[45] Jin, J. Y., Lee, S. H., & Yoon, H. J. (2010). A Comparative Study of Wound Healing Following Incision With a Scalpel, Diode Laser or Er, Cr: YSGG Laser in Guinea Pig Oral Mucosa: a Histological and Immunohistochemical Analysis. *Acta Odontologica Scandinavica*, 68(4), 232-238.

[46] Romanos, G., & Nentwig, G. H. (1999). Diode Laser (980 nm) in Oral and Maxillofacial Surgical Procedures: Clinical Observations Based on Clinical Applications. *Journal of Clinical Laser Medicine and Surgery*, 17(5), 193-197.

[47] Stübinger, S., Saldamli, B., Jürgens, P., Ghazal, G., & Zeilhofer, H. F. (2006). Soft Tissue Surgery With the Diode Laser-Theoretical and Clinical Aspects. *Schweizer Monatsschrift fur Zahnmedicine*, 116(8), 812-820.

[48] Blaya, D. S., Guimarães, M. B., Pozza, D. H., Weber, J. B., & de Oliveira, M. G. (2008). Histologic Study of the Effect of Laser Therapy on Bone Repair. *The Journal of Contemporary Dental Practice*, 9(6), 41-48.

[49] Pinheiro, A. L. (2003). Recent Studies on Bone Regeneration. *International Congress Series*, 1248-69.

[50] De Medeiros, V. P., Toma, L., Reginato, R. D., Katchburian, E., Nader, H. B., & Faloppa, F. (2012). The Low Level Laser Therapy Effect on the Remodeling of Bone Extracellular Matrix. Photochemistry and PhotobiologyEpub ahead of print]

[51] Houk, L. D., & Humphreys, T. (2007). Masers to Magic Bullets: an Updated History of Lasers in Dermatology. *Clinical Dermatology*, 25(5), 434-442.

[52] Gutknecht, N., van Gogswaardt, D., Conrads, G., Apel, C., Schubert, C., & Lampert, F. (2000). Diode Laser Radiation and its Bactericidal Effect in Root Canal Wall Dentin. *Journal of Clinical Laser Medicine and Surgery*, 18(2), 57-60.

[53] Souza, E. B., Cai, S., Simionato, M. R. L., & Lage-Marques, J. L. (2008). High-Power Diode Laser in the Disinfection in Depth of the Root Canal Dentin. *Oral Surgery Oral Medicine Oral Pathology Oral Radiology and Endodontics*, 106(1), 68-72.

[54] Gutknecht, N., Moritz, A., Conrads, C., & Lampert, F. (1997). Der Dioden Laser und seine Bakterizide Wirkung im Wuzelkanal: Eine in Vitro Studie. *Endodontie*, 3-217.

[55] Moritz, A., Gutknecht, N., Schoop, U., Goharkhy, K., Doertbudak, O., & Sperr, W. (1997). Irradiation of Infected Root Canals with a Diode Laser in vivo: Results of Microbiological Examinations. *Laser sin Sirgery and Medicine*, 21(3), 221-226.

[56] Gutknecht, N., Alt, T., Slaus, G., Bottenberg, P., Rosseel, P., Lauwers, S., & Lampert, F. (2002). A Clinical Comparison oft he Bactericidal Effect of the Diode Laser and 5%

Sodium Hypochlorite in Necrotic Root Canals. *Journal of Oral Laser Application*, 2(3), 151-157.

[57] Eriksson, A. R., & Albrektsson, T. (1983). Temperature Threshold Levels for Heat-Induced Bone Tissue Injury: A Vital Microscopic Study int he Rabbit. *Journal of Prosthetic Dentistry*, 50(1), 101-107.

[58] Moritz, A., Gutknecht, N., Goharkhy, K., Schoop, U., Wernisch, J., & Sperr, W. (1997). In Vitro Irradiation of Infected Root Canals with a Diode Laser: Results of Microbiologic, Infrared Spectrometric, and Stain Penetration Examinations. *Ouintessence International*, 28(3), 490-493.

[59] Wang, X., Sun, Y., Kimura, Y., Kinoshita, J. I., Ishizaki, N. T., & Matsumoto, K. (2005). Effects of diode Laser Irradiation on Smear Layer Removal from Root Canal Walls and Apical Leakage after Opturation. *Phtomedicine and Laser Surgery*, 23(5), 575-581.

[60] Hmud, R., Kahler, W. A., George, R., & Walsh, L. J. (2009). Cavitational Effects in Aqueous Endodontic Irrigants Generated by Near-Infrared Lasers. *Journal of Endodontics*, 36(2), 275-278.

[61] Dobson, J., & Wilson, M. (1992). Sensitization of Oral Bacteria in Biofilms to Killing by Light from a Low Power Laser. *Archives of Oral Biology*, 37(11), 883-7.

[62] Seal, G. J., Ng, Y. L., Spratt, D., Bhatti, M., & Gulabivala, K. (2002). An in vitro Comparison of the Bactericidal Efficacy of Lethal Photosensitization or Sodium Hyphochlorite Irrigation on Streptococcus intermedius Biofilms in Root Canals. *International Endodontic Journal*, 35(3), 268-274.

[63] Soukos, N. S., Chen, P. S., Morris, J. T., Ruggiero, K., Abernethy, A. D., Som, S., Foschi, F., Doucette, S., Bammann, L. L., Fontana, C. R., Doukas, A. G., & Stashenko, P. P. (2006). Photodynamic Therapy for Endodontic Disinfection. *Journal of Endodontics*, 31(10), 979-984.

[64] Meire, M. A., Coenye, T., Nelis, H. J., & De Moor, R. J. G. (2012). Evaluation of Nd:YAG and Er:YAG irradiation, antibacterial photodynamic therapy and sodium hypochlorite treatment on Enterococcus faecalis. *International Endodontic Journal*, 45(5), 482-492.

[65] Garces, A. S., Nunez, S. C., Hamblim, M. R., Suzuki, H., & Ribeiro, M. (2010). Photodynamic Therapy Associated with Conventional Endodontic Treatment in Patients with Antibiotic-Resistant Microflora: A Preliminary Report. *Journal of Endodontics*, 36(9), 1463-1466.

[66] Lee, M. T., Bird, P. S., & Walsh, L. J. (2004). Photo-Activated Disinfection of the Root Canal: A New Role for Lasers in Endodontics. *Australian Endodontic Journal*, 30(3), 93-8.

[67] Rios, A., He, J., Glickman, G. N., Spears, R., Schneiderman, E. D., & Honeyman, A. L. (2011). Evaluation of Photodynamic Therapy Using a Light-Emitting Diode Lamp

against Enterococcus faecalis in Extracted Human Teeth. *Journal of Endodontics*, 37(6), 856-9.

[68] Silva, L. A. B., Novaes, A. B., de Oliveira, R. R., Nelson-Filho, P., Santamaria, M., & Silba, R. A. B. (2012). Antimicrobial Photodynamic Therapy for the Treatment of Teeth with Apical Periodontitis: A Histopathological Evaluation. *Journal of Endodontics*, 38(3), 360-366.

[69] Bago, I., Plečko, V., Gabrić, Pandurić. D., Schauperl, Z., Baraba, A., & Anić, I. (2012). Antimicrobial efficacy of a high-power diode laser, photo activated disinfection, conventional and sonic activated irrigation during endodontic therapy. *International Endodontic Journal. In Press.*

[70] Schoop, U., Kluger, W., Moritz, A., Nedjelik, N., Georgopoulos, A., & Sperr, W. (2004). Bactericidal effect of different laser systems in the deep layers of dentin. *Lasers in Surgery and Medicine*, 35(2), 111-6.