

---

# Treatment of Leg Chronic Wounds with Dermal Substitutes and Thin Skin Grafts

---

Silvestro Canonico, Ferdinando Campitiello,  
Angela Della Corte, Vincenzo Padovano and  
Gianluca Pellino

Additional information is available at the end of the chapter

<http://dx.doi.org/10.5772/51852>

---

## 1. Introduction

Tissue repair is a natural process occurring any time the skin is injured. Repair is achieved through different successive phases: inflammation, formation of granulation tissue, formation of the extracellular matrix (ECM), and remodeling. ECM plays an important role in tissue regeneration representing the principal component of the dermal skin layer. The composition of ECM includes proteoglycans, hyaluronic acid, collagen, fibronectin and elastin. As well as providing a structural support for cells, some components of the ECM bind to growth factors, creating a reservoir of active molecules that can be rapidly mobilized following injury to stimulate cell proliferation and migration [1].

Acute wounds, such as traumatic or surgical wounds, generally require topical treatments leading to complete scar formation within 14 days. Treatment modalities, from topical treatments administered as a support for the physiological mechanisms of scarring to surgical repair with skin grafts, are usually chosen according to: dimension, location, and severity of the lesion; exposition of visceral or skeletal structures; age of the patient; risks related to other illnesses.

Some lesions, despite careful clinical examination, good physiopathologic classification, and adequate treatment (e.g. etiologic therapy, debridement and disinfection of the lesion, “humidification” of the surface) do not heal but achieve only temporary clinical improvement. Chronic wounds represent a state in which healing has stagnated.

Some studies showed that in chronic wounds the hyperproliferation of the edges inhibits the apoptosis of fibroblasts and keratinocytes [2]. Anomalies of the phenotype have also been

associated with fibroblasts, such as altered morphology and a slower rate of proliferation [3,4]. Moreover, the fibroblasts obtained from chronic ulcers and cultivated *in vitro* have shown lesser response to exogenous application of growth factors such as platelet-derived growth factor [5,6]. This is because of fibroblasts being senescent and not truly responsive to stimuli, which would explain why the local application of growth factors to a chronic wound will not heal it [7,8]. In many chronic wounds, increased levels of inflammatory cells lead to elevated levels of proteases that seem to degrade the ECM components, growth factors, protein and receptors that are essential for healing [9].

Many surgical techniques and various types of advanced dressings are used for the treatment of these ulcers, assuming that the physiologic processes of tissue repair are competent and that the lesion can heal “spontaneously”; this occurs quite frequently, but there are ulcers, usually defined as “complex”, which do not heal within an acceptable timeframe, despite a correct diagnostic and therapeutic procedure, or relapse rapidly. This may be due to concomitant systemic pathologies (e.g. diabetes, immunodeficiency, cardiac failure) and/or to the presence of local factors (e.g. oedema, arterial or venous failure, infections) that inhibit the healing process. The lack of healing of the ulcer, even for years, affects the whole circumference of the leg, often involving deep structures such as aponeuroses and tendons. In such cases, a reconstructive surgical operation using skin grafts must always be considered, though it may also be difficult or likely to fail because of the position, width, and depth of the lesion(s).

When dealing with large full-thickness wounds of the lower limbs, the use of reconstructive operations with autologous skin grafting is widespread. Epidermis with a superficial part of the dermis is harvested with a dermatome from an undamaged skin donor site and applied to the full-thickness wound. Being applied to the wound, capillaries of the split skin graft (SSG) form anastomoses or “plug in” into the existing capillary network to provide nutrients for graft survival; this is referred to as graft “take”. In the case of an extensive wound, donor sites are limited and in such cases, meshing techniques can be used meaning grafted skin is uniformly perforated and stretched to cover greater areas of the wound.

Nevertheless, full-thickness skin grafts require the taking of a sample, determining the creation of a wound that is itself deep and susceptible to complications such as infections and retractions of the scar, and precludes the use of the same site for the taking of further samples [10]. For this reason, one tends to prefer partial-thickness skin grafts, which in some cases may fail to attach and tend to retract, leading to unsatisfying results. That is for the most part due to the paucity or absence of derma in the partial-thickness skin grafts, as the dermal matrix plays a fundamental role in determining the success of a skin graft [11,12].

In these patients a new therapeutic perspective is “regenerative surgery” with the use of tissue-engineered products. In fact recognition of the importance of the ECM in wound healing has led to the development of wound products that aim to stimulate or replace the ECM. These tissue-engineered products comprise a reconstituted or natural collagen matrix that mimics the structural and functional characteristics of native ECM [13]. When placed into the wound bed, the three-dimensional matrix provides a temporary scaffold or support into

which cells can migrate and proliferate in an organized manner, leading to tissue regeneration and ultimately wound closure.

An ideal replacing skin product should principally contain these factors:

- the ECM;
- dermal fibroblasts;
- a semipermeable membrane between dermis and epidermis.

These components may act synergistically as part of a fully integrated tissue to protect the underlying tissues of a wound bed and to direct healing of the wound. Dermis containing fibroblasts could be necessary for the maintenance of the epidermal cell population.

All tissue-engineered skin substitute bioconstructs need to comply with three major requirements. They must be: safe for the patient, clinically effective, and convenient in handling and application. In general, such biomaterials must not be toxic, immunogenic or cause excessive inflammation, and should also have no or low level of transmissible disease risk. The biomaterial for skin reconstruction should be biodegradable, repairable and able to support the reconstruction of normal tissue, with physical and mechanical properties similar to those of the skin it replaces. It should provide pain relief, prevent fluid and heat loss from the wound surface and protect the wound from infection. It is also of great advantage if the skin substitute bioconstruct is cost-effective, readily available, user-friendly and with a long shelf life. No tissue-engineered skin replacement biomaterials currently available in commerce possess all the above-mentioned properties nor can any fully replace the functional and anatomical properties of the native skin. There are, however, a number of bioengineered skin-replacement products suitable for wound-healing purposes which are currently available to clinicians. In general, these tissue replacements only partially address skin functional requirements and surgeons tend to use different products to achieve specific purposes.

Tissue-engineered skin products may be either cellular, containing living cells (Table 1), or acellular, biologically inert (Table 2), and sourced from:

- Biological tissue: animal (e.g. equine/bovine/porcine); human (e.g. cadaveric skin); plant (e.g. containing oxidized regenerated cellulose/collagen)
- Synthetic materials
- Composite materials (containing two or more components, which may be biological or synthetic).

Different types of tissue-engineered products are available and confusion exists concerning the used terminology. Products may be classified as skin substitutes, xenografts, allografts or collagen dressings. "Skin substitutes" is an *umbrella term* for a group of products. Depending on individual characteristics, they may substitute or replace all or some components that compose normal skin (e.g. epidermis and/or dermis, cells and matrix). They can be bilayered, acellular or cellular, synthetic or biological and may consist of a synthetic epidermis and a collagen-based dermis to encourage formation of new tissue. In products with

a synthetic epidermis, this may act as a temporary wound covering. Alternatively, these products may be described as *biological dressings* in that they serve as a protective wound cover. However, while most wound dressings need to be changed frequently, matrices provide a scaffold for tissue repair and therefore must remain in the wound for a sufficient length of time [23].

Product	Industry	Scaffold	Type	Cell Source	Indicated for Acute Wounds	Indicated for Chronic Wounds
Epicel®	Genzyme	Autologous keratinocytes, murine fibroblasts	Dermal +Epidermic	Autograft	+	+
Epidex®	Modex	Nitrocellulose	Epidermic	Autograft	+	+
MySkin	CellTRan Ltd.	Cultured Keratinocytes (subconfluent cell sheet)+silicon support layer with a specially formulated surface coating	Epidermic	Autograft	+	+
Cell Spray	Clinical Cell Culture	Non-/cultured Keratinocytes	Epidermic	Autograft	+	+
Bioseed-S	BioTissue Technologies	Cultured Keratinocytes (subconfluent cell sheet)+fibrin sealant	Epidermic	Autograft	+	+
Epibase	Laboratoires Genevirier	Cultured Keratinocytes (subconfluent cell sheet)	Epidermic	Autograft	+	+
Apligraf	Organogenesis Inc.	Cultured keratinocytes and fibroblast and bovine collagen	Dermal + Epidermic	Allograft	+	+
Orcel	Ortec International, Inc. NY	Cultured keratinocytes and fibroblast and bovine collagen sponge	Dermal + Epidermic	Allograft	+	+
PolyActive	HC Implants Bv, Leiden	Cultured keratinocytes and fibroblast in PEO/PBT	Dermal + Epidermic	Allograft	+	+

Product	Industry	Scaffold	Type	Cell Source	Indicated for Acute Wounds	Indicated for Chronic Wounds
Trancyte®	ATS	Silicon film, Nylon mesh, Porcine collagen+cultured neonatal fibroblast	Dermal	Allo- and synthetic graft	+	-
Dermagraft®	ATS	PLA/PGA+ ECM derived from fibroblast	Dermal	Allo - and synthetic graft	+	+
Graftskin	Organogenesis	Bovine collagen+ human keratinocytes and fibroblast	Dermal + Epidermic	Allograft	+	+
CSS®	Ortec International	Cross-linked bovine collagen and human cells	Dermal + Epidermic	Allograft	+	+
Keratinocytes crops	Lab. Ingegneria tessutale Università Milano	HYAFF®	Epidermic	Autograft	+	+
Laserskin®Autograft Hyalograft™ 3D	FAB	Cultured keratinocytes and fibroblast +HYAFF®	Dermal + Epidermic	Autograft	+	+

**Table 1.** Cellular-based tissue-engineered skin products currently in commerce

Engineered epidermal constructs with qualities similar to those of autologous skin have been used to facilitate repair of split-thickness wounds. Autologous cultured keratinocyte grafts have been used in humans since the 1980s. As a result there has been extensive experience with cultured epidermal grafts for the treatment of burns as well as other acute and chronic wounds [24]. Although they act as permanent wound coverage, since the host does not reject them, disadvantages include the two to three week time interval required before sufficient quantities of keratinocytes are available.

Cultured keratinocyte allografts were developed to overcome the need for biopsy and cultivation to produce autologous grafts and the long lag period between epidermal harvest and graft production. Cultured epidermal cells from both cadavers and adult donors have been used for the treatment of burns. Although a previous study showed that allografts made from neonatal foreskin keratinocytes were more metabolically active than those from cadaver, a recent study has shown that such allografts are immunogenic [16]. As an alternative, a chemically modified hyaluronic membrane acting as keratinocyte delivery system was developed. In this graft cells were delivered to the injury site via a biodegradable scaffold.

Product	Industry	Scaffold	Type	Cell Source	Indicated For Acute Wounds	Indicated For Chronic Wounds
Integra®	Integra Lifesciences-USA	Bovine type I collagen, chondrotin-6-sulfate, silicone	Dermal	Xeno - and synthetic graft	+	+
Matriderm®	Dr Suvelack Skin & Healthcare Ag-Germany	Bovine non-cross-linked lyophilized collagen +elastinhydrolysate	Dermal	Xenograft	+	+
Unite Biomatrix®	TEVA-Pharmaceutical Industries LTD	Equin pericardium type I collagen	Dermal + Epidermic	Xenograft	+	+
Matristem™ Wound Care Matrix	ACELL Inc./Medline	Porcine urinary bladder matrix	Dermal	Xenograft	+	+
Ez-Derm™	AM Scientific / Brennen Medical	Porcine aldehyde cross-linked reconstituted dermal collagen	Dermal + Epidermic	Xenograft	+	+
Biodesign® (Surgisis®) Hernia Graft	Cook Medical	Porcine small intestine submucosa (SIS)	Dermal	Xenograft	+	-
Permacol	Covidien	Porcine acellular diisocyanite cross-linked dermis	Surgical biological implant for hernia & abdominal wall repair	Xenograft	+	-
CollaMend Implant	Davol Inc/Bard	Porcine Dermis	Surgical biological implantfor hernia & abdominal wall repair	Xenograft	+	-
XenMatrix Surgical Graft	Davol Inc/Bard	Porcine Dermis	Surgical biological implantfor hernia & abdominal wall repair	Xenograft	+	-
Puracol® Plus Microscaffold Collagen(Puracol Plus Ag)	Dr Suvelack Skin & Healthcare AG/Medline	Bovine Collagen(plus antimicrobial Ag)	Surgical biological implantfor hernia & abdominal wall repair	Xenograft	+	-

Product	Industry	Scaffold	Type	Cell Source	Indicated For Acute Wounds	Indicated For Chronic Wounds
Biopad Collagen Wound Dressing	Euroresearch	Equine flexor tendon	Dermal	Xenograft	+	+
OASIS Wound Matrix	Healthpoint Ltd./ Cook Biotech, Inc	Porcine small intestine submucosa (SIS)	Dermal	Xenograft	+	+
Strattice™ Reconstructive Tissue Matrix	LifeCell	Porcine Dermis	Dermal	Xenograft	+	+
Endoform™ Dermal Template	Mesyntes	Propria submucosa layers of ovine forestomach	Dermal	Xenograft	+	-
Veritas Collagen Matrix	Synovis Orthopedic and Woundcare	Bovine pericardium	Surgical biological implant for abdominal wall repair & breast reconstruction	Xenograft	+	-
Primatrix™ Dermal Repair Scaffold	TEI Biosciences	Fetal bovine dermis	Dermal	Xenograft	+	-
SurgiMend®/ SurgiMend® Hernia Repair Matrix	TEI Biosciences	Fetal bovine dermis	Surgical biological implant for hernia & abdominal wall repair	Xenograft	+	-
Alloderm®	KCL/ LifeSciences	Human skin tissue	Dermal	Allograft	+	-
Hyalomatrix PA®	FAB	Membrane HYAFF® layered on silicon	Dermal	Allo - and synthetic graft	+	-
Biobrane®	Smith&Nephew	Silicon film, nylon fabric, porcine collagen	Dermal + Epidermic	Xeno - and synthetic graft	+	+
Suprathel®	Healtcare	Polylattic acid	Epidermic	Xenograft	+	+
Jaloskin®	FAB	HYAFF11	Epidermic	Xenograft	+	-
Graftygen Epidermis®	TEVA	Mycrolose	Epidermic	Xenograft	+	+
Graftygen Derma®	TEVA	Collagen (3D)	Dermal	Allograft	+	+

Product	Industry	Scaffold	Type	Cell Source	Indicated For Acute Wounds	Indicated For Chronic Wounds
Neoform™	Mentor	Human dermis	Dermal	Allograft	+	+
Pelnac Standard/ Pelnac Fortified	Gunze Limited, Medical Material Center	Silicone/silicone fortified with silicone gauze TRX, Porcine tendon -derived atenocollagen	Dermal	Xeno - and synthetic graft	+	-
SureDerm Acellular	Hans Biomed Corporation	Human acellular lyophilized dermis	Dermal	Allograft	+	+
GraftJacket	Wright Medical Technology, Inc.	Human acellular pre-meshed dermis	Dermal	Allograft	+	-
Karoderm	Karocell Tissue Engineering AB	Human acellular dermis	Dermal	Allograft	+	+
AllomaxSurgical Graft	Davol Inc/Bard	Human acellular dermis	Surgical biological implant for hernia & abdominal wall	Allograft	+	-
Dermamatrix Acellular Dermis	MusculoskeletalTran splant Foundation/ Synthes CMF	Human acellular dermis	Surgical biological implant for hernia & abdominal wall	Allograft	+	-
FlexHD Acellular Hydrated Dermis	MusculoskeletalTran splant Foundation/ Ethicon	Human acellular dermis	Dermal	Allograft	+	-
Terudermis	Olympus Terumo Biomaterial	Silicone, bovine lyophilized cross- linked collagen sponge made of heat-denatured collagen	Dermal	Xeno - and synthetic graft	+	-

**Table 2.** Acellular tissue-engineered skin products in commerce.

Keeping in mind that good skin regeneration requires an appropriate dermal layer, allografts (containing dermis) from other sources have been used for many years, although they provide only temporary coverage due to their tendency to induce acute inflammation. However, this skin can be chemically treated to remove the antigenic epidermal cellular elements and has been used alone or in combination with cultured autologous keratinocytes for closure of various chronic wounds and burns. In spite of these modifications, allogeneic grafts,



when compared with autologous grafts, have been shown to promote lower percentages of re-epithelization and excessive wound contraction [17].

Acellular matrices may be either animal- or human-derived, with all cells removed during manufacture, or they may be either synthetic or composite, if cells are naturally not present from the outset. These matrices or tissue scaffolds provide a collagen structure for tissue remodeling, while the removal of viable cells aims to minimize or prevent an inflammatory or immunogenic response [18]. A matrix may be described as a tissue scaffold in that it provides a supporting structure into which cells can migrate. However, it should be noted that a scaffold does not have to be a matrix (e.g. it does not interact with cells to the same degree as a matrix). For example, fibronectin may act as a matrix, but it is not necessarily a scaffold; similarly, polyglactin may act as a scaffold, but it is not a matrix [14].

Given current knowledge, the ideal acellular matrix is one that most closely approximates the structure and function of the native ECM it is replacing.

An acellular composite skin graft containing bovine collagen and chondroitin-6-sulfate with an outer silicone covering was developed in the 1980s. After placement on the wound, the acellular dermal component recruits the host dermal fibroblasts while undergoing simultaneous degradation. About two or three weeks later, the silicone sheet is removed and covered with an autograft. This composite graft has been used successfully to treat burns [19]. However, these constructs cannot be used in patients who are allergic to bovine products.

Another type of dermal substitute consists of an inner nylon mesh in which human fibroblasts are embedded, together with an outer silicone layer. After an appropriate time, fibroblasts are laid in the final product by freeze-thawing. Prior to that time, fibroblasts produce autologous collagen, matrix proteins and cytokines, all of which promote wound healing by the host. This product has been used successfully as temporary wound coverage after excision of burn wounds, until the appearance of the modified product on the market. The new graft contains a biodegradable polyglactin mesh, in which fibroblasts retain viability, instead of the nylon mesh. The use of this dermal substitute has had limited success in the treatment of diabetic foot ulcers, owing largely to its inability to form stable adhesions with the final epidermal graft [20].

Full-thickness wounds involve the loss of both the epidermal and dermal layers of the skin. To treat such extensive wounds, a two-layer skin composite was developed consisting of a collagen sponge containing dermal fibroblasts covered with epidermal cells. A subsequent amendment containing type I bovine collagen and live allogeneic human skin fibroblasts and keratinocytes has been developed. It has been used successfully in surgical wounds and venous ulcers [21]. In a multicenter trial, this product produced accelerated healing of chronic non-healing venous stasis ulcers when compared to standard compressive therapy [22].

Several other composite skin substitutes combining dermal and epidermal elements have been developed. Composite cultured skin composed of an overlay of stratified neonatal keratinocytes on fibroblasts embedded in distinct layers of bovine type I collagen is currently being evaluated in clinical trials for the treatment of burns.

Currently the acellular matrix products differ mainly in the source of cells and tissue materials and methods used during manufacture. A variety of animal- and human-derived products are available (Table 2), as in the reference [14].

Products derived from animal sources (xenografts) are developed by harvesting living tissue (e.g. dermis, small intestine submucosa, pericardium, etc) from various donor animals (e.g. porcine, equine or bovine) at different stages of development. The tissue materials are subsequently processed to remove the cells (decellularization), leaving the collagen matrix. Products derived from animal sources may either consist of the tissue scaffold only (e.g. Unite® BioMatrix Collagen Wound Dressing, Synovis) or may be combined with synthetic materials to create a composite product (e.g. INTEGRA® Bilayer Matrix Wound Dressing, Integra LifeSciences).

Products derived from human sources, i.e. donated human cadaver skin allografts, undergo various processes to remove the cells and deactivate or destroy pathogens (e.g. AlloDerm®, Lifecell; GraftJacket®, Wright Medical).

The mechanisms by which acellular matrices promote wound healing remain to be elucidated and there is ample scope for further research. It is known from the literature that chronic or hard-to-heal wounds are characterized by a disrupted or damaged ECM that cannot support wound healing. Treatment strategies that are designed to replace the absent or dysfunctional ECM may be beneficial [9]. As a result, there is renewed interest in collagen-based advanced wound care products.

In chronic wounds, there is an excess of MMPs and reduced growth factor activity. Together these result in the degradation of the ECM. For wound healing to occur the balance between protease and growth factor activity needs to be adjusted [9]. Research has demonstrated that topically applied collagen-based products can initiate wound healing by binding to and inactivating harmful proteases, while encouraging angiogenesis and formation of granulation tissue [23].

Current information about the mode of action of acellular matrices is largely based on pre-clinical data, mainly from research focusing on a porcine-derived small intestinal submucosa (SIS) wound matrix. These data show that matrices may:

- Act as a scaffold to support cell ingrowth and granulation tissue formation [24]
- Have receptors that permit fibroblasts to attach to the scaffold [25]
- Stimulate angiogenesis [26]
- Act as a chemoattractant for endothelial cells [27]
- Contain/protect growth factors [28].

When used as an implant, the acellular matrix appears to be fully incorporated into the wound. However, when used in a chronic wound, the matrix is eventually displaced and is not fully incorporated. As such, the role of acellular matrices in chronic wounds is not fully understood. It has been suggested that they act as a biological cover that modulates the wound environment to promote normal wound healing.

In the references [29,30] the Authors suggested the mode of action of collagen-based acellular matrix products:

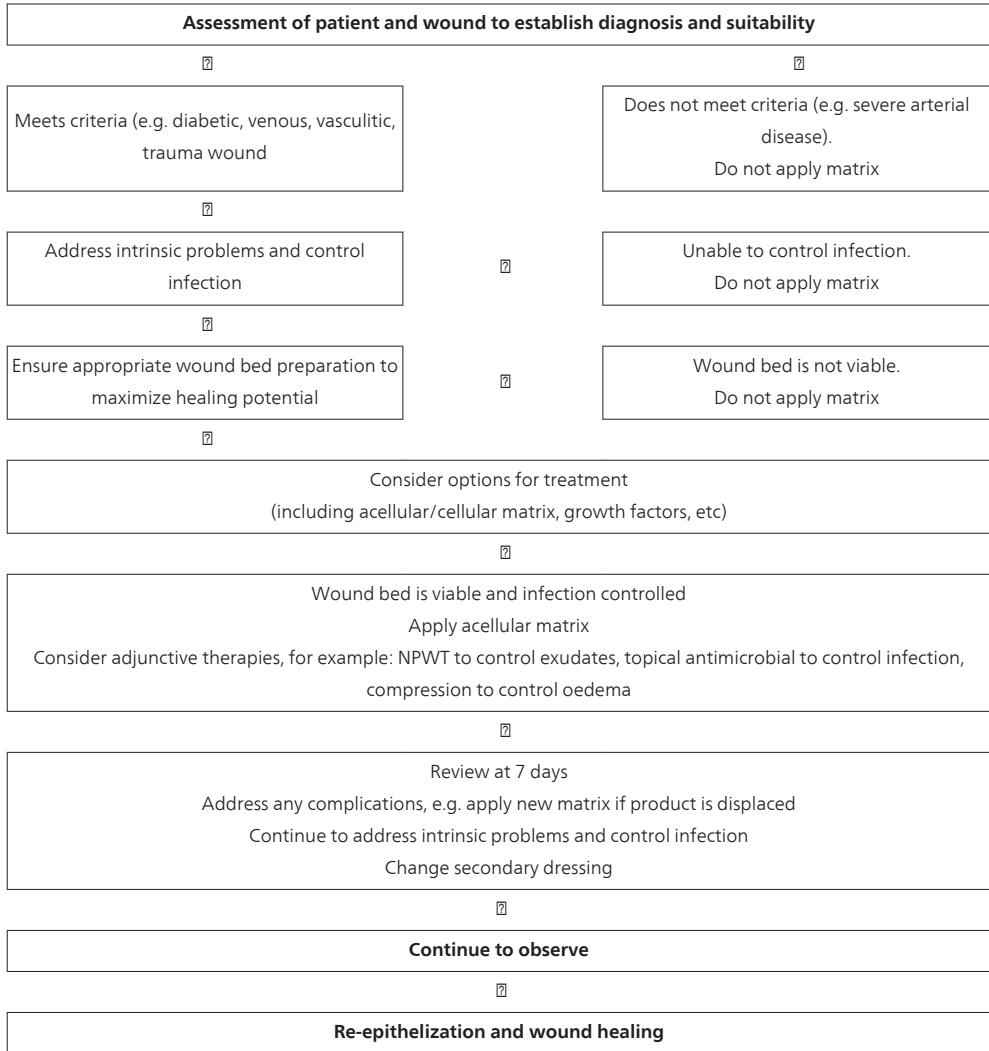
- Chronic wounds contain high levels of MMPs which can:
- Degrade the ECM and growth factors
- Increase inflammatory response
- Reduce cell responsiveness in the wound
- Delay wound healing
- An acellular matrix that closely resembles native ECM may act as a scaffold for:
- MMPs to bind to and break down collagen in the product
- Epithelial cells, fibroblasts and vascular endothelial cells to migrate into and proliferate
- Reduced levels of MMPs to be released back into wound as collagen matrix breaks down, rebalancing protease and growth factor levels in the wound
- Enhanced wound healing environment, where matrix has been replaced by new collagen with remodeling of ECM.

Acellular matrices should be considered in wounds that are unresponsive to traditional wound management modalities or present as a complex surgical wound. Factors to consider will be dependent on the wound type, underlying etiology, patient suitability and treatment goal. In a non-healing chronic wound (e.g. diabetic foot ulcer), for example, an acellular matrix may be selected to replace the damaged ECM, fill the defect and optimize the wound environment for healing.

In the reference [14] the Authors have proposed an algorithm for application of acellular matrices in a chronic wound, as reported in Table 3. Previous studies have shown that reduction in the area of the chronic wound during the first four weeks of treatment is a predictor of complete healing at 12 weeks [31]. If no improvement is seen at this time, there should be further evaluation of the patient and current treatment strategy.

Our own experience in the treatment of complex leg ulcers is prevalently related to the use of a dermal matrix that stimulates the production of endogenous collagen, determining the constitution of a functional dermis (Integra Dermal Regeneration Template). It is a "semibiological implant" consisting of a two-layered membrane. The thin external pellicle, in silicone, allows for the immediate closure of the wound, controlling the loss of fluids and proteins, providing it with mechanical and antibacterial protection [32]. The internal layer consists of a porous matrix composed of type 1 collagen from bovine tendons and from glycosaminoglycan (chondroitin-6-sulfate) that produces a histoinductive and histoconductive action on the mesenchyme, leading to the formation of normal derma. The collagen represents only its structural base, whereas the chondroitin (8% of its weight) confers its principal properties on the matrix. The glycosaminoglycans, such as hyaluronan, dermatan, and keratan, are important in the constitution of the ECM and in the regulation of the cellular devel-

opment and differentiation. They are predominant in the embryonic tissue and accumulate in fetal wounds, which repair through regeneration without inflammation or scarring in fibrosis [33,34]. The chondroitin, moreover, masks the sites of binding on the collagen, preempting platelet adhesion and the consequent inflammation [35].



**Table 3.** Algorithm for application of acellular matrices in a chronic wound [14]

When the Integra is applied to a lesion, the inflammation stops because the matrix not only seems to be invisible to the platelets and inflammatory leucocytes, but also seems to be rec-

ognized as self. One does not find microscopic inflammatory infiltrates or clinical signs of inflammation. Pain is often absent after the application of Integra, and perilesional erythema and oedema disappear quickly. The hypotheses that explain the phenomenon can be summarized as follows. The lack of adhesion of the platelet anticipates the acute inflammation, and the artificial dermis confines the lesion, eliminating local exposition, desiccation, bio-burden, and similar secondary damage. The chondroitin matrix is sufficiently similar to normal tissue such that the leukocytes and lymphocytes cross the matrix without recognizing any abnormality and without thus producing any defensive reaction [36]. In summary, when the dermal matrix is imposed on a skin lesion, all of the factors that cause damage are stopped, and from a functional perspective, regeneration is the only available response.

Four distinct phases of regeneration of the dermis were recognized in the period of attachment of the dermal matrix (imbibition, migration of the fibroblasts, new vascularization, and maturation with remodeling) without the presence of nerve endings or elastic fibers. The new collagen is therefore indistinguishable from the normal collagen of the dermis [37].

Compared with the healing obtained with autotransplantation of skin, that achieved using grafting with Integra are also found to be clinically better and comparable with normal skin [38].

Brought into clinical use in 1981, Integra was first used for the treatment of burns, predominantly those that were deep and covering a large area [39-41]. Subsequently, its use was extended to reconstructive surgery on strongly retracted scars [42]. It was found to be particularly useful in covering deep structures such as periosteum and tendons.

Before the application of Integra, the wounds are to be cleaned and disinfected with antibiotic drugs and advanced dressings during periodic close examinations. Once surgery is planned, the choice of local or epidural anesthesia is based on the number and dimensions of the ulcers treated. First, surgical debridement of the lesion(s) is performed aiming to reduce the bacterial ratio, level the deep surface of the ulcer, and regulate its edges: we perform surgical cleansing and the preparation of the margins of the ulcers with a hydro-surgery system. To facilitate and improve modeling and attachment of the dermal matrix, its margins are modeled with scissors to fit perfectly and fixed to the skin with metal clips or topical skin adhesive. Petroleum jelly dressing and compressed multilayer bandages are applied on the wound. Postoperative treatment consists of antibiotic and analgesic drugs; analgesic therapy is provided according to the level of patient pain.

The first postoperative medication is administered after 8 days, the metallic clips (if present) are removed, and the antibiotic therapy suspended. Usually at the first follow-up a notable reduction of moisture and surrounding oedema is ascertained. The patients are then treated in the outpatient clinic with silver dressings every 5 to 7 days, based on the degree of moisture.

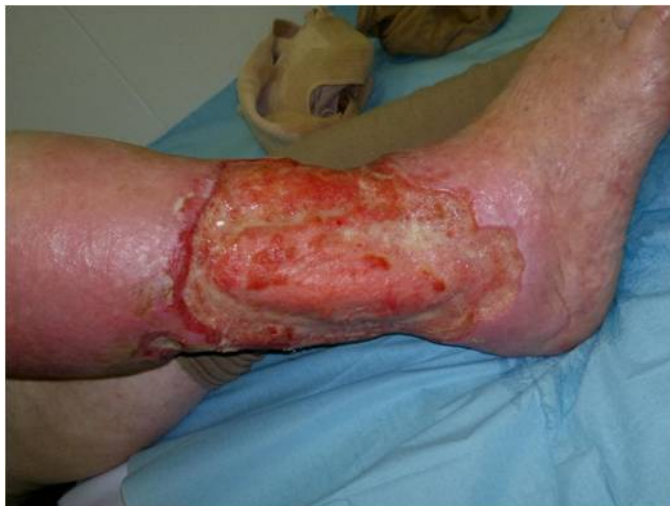After 21 days, the attachment of the artificial dermis is tested. Usually the dermal matrix is completely integrated with the guest tissue, having formed a new homogeneous and living derma. The next skin-graft operation is planned and the patient is readmitted for surgery. The epidermis (0.15–0.25 mm thick) is extracted with dermatome from the front part of the thigh, treated with mesh graft, and fixed on the lesion with metal clips. The wounds are cov-

ered again with petroleum jelly gauze and compressive bandages, and the previous antibiotic therapy is recommenced. After 8 days, the first follow-up is planned for the removal of the clips and the first test of the attachment of the graft. This is covered again with silver medications, and antibiotics are stopped. Further checks are planned weekly until the ulcer is completely healed. After that, a monthly follow-up is planned.

We performed a prospective observational study from April 2005 to June 2011 enrolling patients with leg ulcers that were not healing for at least 1 year. The ulcers were at least 100 cm<sup>2</sup> in area (in the case of multiple ulcers of the same limb, the overall surface area was taken into account) and at least 3 mm deep over at least 50% of the surface area. Patients who had an obstructive arterial disease were excluded from the study. The dimensions and depth of the ulcers were measured using the Visitrak digital apparatus (Smith & Nephew Medical Limited, Hull, UK). For all patients, there was a preliminary culture on the biopsy of the lesion. All patients' wounds were cleaned and disinfected with antibiotic drugs and advanced dressings during periodic close examinations at the outpatient clinic of the operating Unit.

Once surgery was planned, the patients were informed about the procedure and gave their written consent. The choice of anaesthetic (local or epidural) was based on the number and dimensions of the ulcers to be treated. First, surgical debridement of the lesion(s) was performed aiming to reduce the level of bacteria, level the deep surface of the ulcer, and establish the periphery of the dermal matrix to facilitate and improve its modeling and attachment. The matrix was modeled with scissors to fit perfectly and was applied by fixing the edges of the matrix to the skin with metal clips or topical skin adhesive (2-octyl-cyanoacrylate, Dermabond, Ethicon Inc., Somerville, NJ). The medication was applied with petroleum jelly gauze and compressed multilayer bandage. Postoperative treatment consisted of antibiotic and analgesic drugs. Analgesic therapy was provided according to the level of pain that the patient reported. The same nurse evaluated pain using a 10 cm visual analogical scale (VAS) from 0 (no pain) to 10 (maximum pain) before the operation and on postoperative day third, eighth, and fifteenth. The first postoperative medication was administered after 8 days, the metallic clips (if present) were removed and the antibiotic therapy suspended. The patients were then treated in the outpatient clinic with silver dressings every 5 to 7 days, based on the degree of the exudates. After 21 days, the attachment of the artificial dermis was tested, and in positive cases, the patient was readmitted for the surgical application of a "thin" skin graft. The epidermis (0.15-0.25 mm thick) was extracted with dermatome from the front part of the thigh, treated with mesh graft, and fixed on the lesion with metal clips. The lesions were covered again with petroleum jelly gauze and compressive bandages, and the previous antibiotic therapy was recommenced. After 8 days, the first follow-up was planned for the removal of the clips and the first test of the attachment of the graft. This was covered again with the silver medication, and antibiotic therapy was stopped. Further checks were planned weekly until the ulcer was completely healed. After that, a monthly follow-up was planned. Independent experts photographically documented all of the treatment phases in all cases.

Three-hundred eighty-three consecutive patients were admitted to the study: 109 were male (28.45%) and 274 were female (71.54%). The median age was 64 (range 37–90) years. The ulcers were classified according to their etiology: 135 were lymphovenous (35.24%) (Figures 1-6), 87 venous (22.71%), 69 due to vasculitis (18.01%), 38 cancerous (9.92%), 29 posttraumatic (7.57%), 18 neuropathic (4.69%) (Figures 7-11), three were due to chemotherapy (0.78%) one was the consequence of laser therapy (0.26%), and one was the consequence of surgery (0.26%). In 117 patients (30.05%), the ulcers were located on both legs and were treated contemporaneously with an identical technique, for a total of 646 limbs treated. All of the ulcers were infected and required targeted antibiotic therapy. The germs identified were *Staphylococcus aureus* (50.0%), *Pseudomonas aeruginosa* (50.0%) *Enterobacter cloacae* (15.4%), *S. epidermis* (15.4%), *Proteus mirabilis* (7.6%), and *Streptococcus Beta-Haemoliticus* (7.6%). Sometimes more than one type of germ was found in the same patient. At the preoperative evaluation, all of the patients complained of continuous and intense pain, ranging from a minimum of 6 to a maximum of 10 (average 7.8) on the VAS scale. In 169 patients (44.1%) who had good cleansing of the ulcer, the Integra was applied using a local anaesthetic, fixing it to the skin with the Dermabond after debridement of brushing and washing with a physiological solution. For the other 214 patients (55.8%), 133 (58.8%) of whom had bilateral lesions and 71 (41.2%) exposed aponeuroses or tendons, the operation was performed using an epidural anaesthetic. In all of these cases, the surgical cleansing and the preparation of the margins of the ulcers were performed using a hydro-surgery system, and the Integra was attached with metal clips.

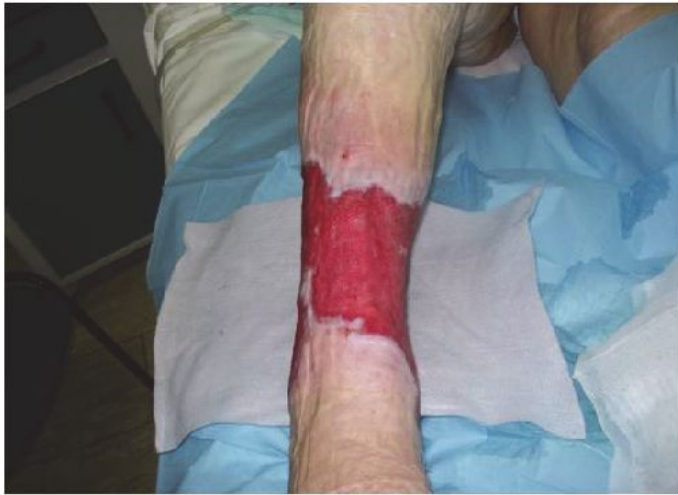

**Figure 1.** Lympho-venous ulcer of the right leg lasting for more than 12 months.

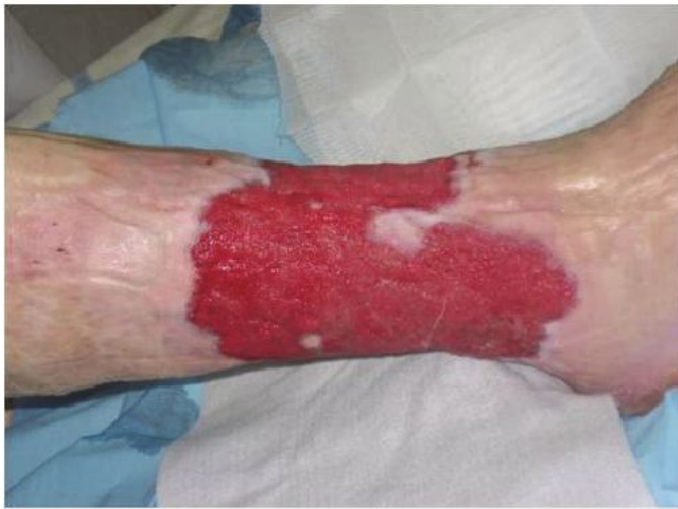At the follow-up on the third day after surgery, all patients reported a substantial reduction in local pain (median VAS 3.8, range 1–6) which allowed 88 (23.1%) patients to suspend the



analgesic therapy. At the follow-up on the eighth day, there was a further reduction in the level of pain (median VAS 2.8, range 1–4). By the third check on the 15th day, the pain reported had reduced further (median VAS 1.7, range 0–3) and all of the patients were able to stop the analgesic therapy.



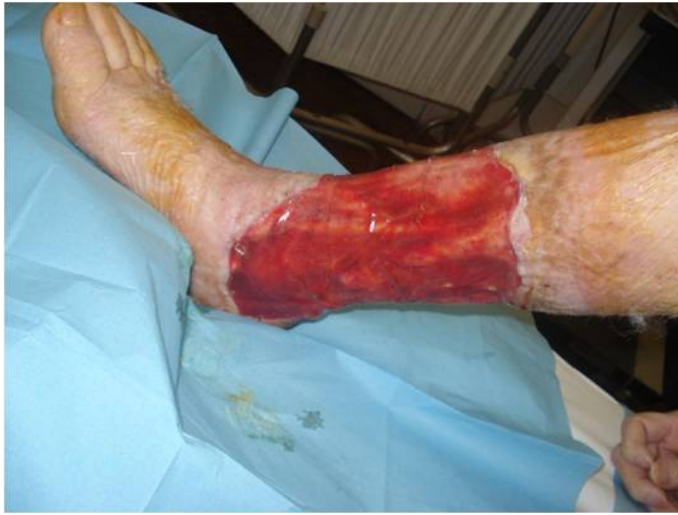(a)



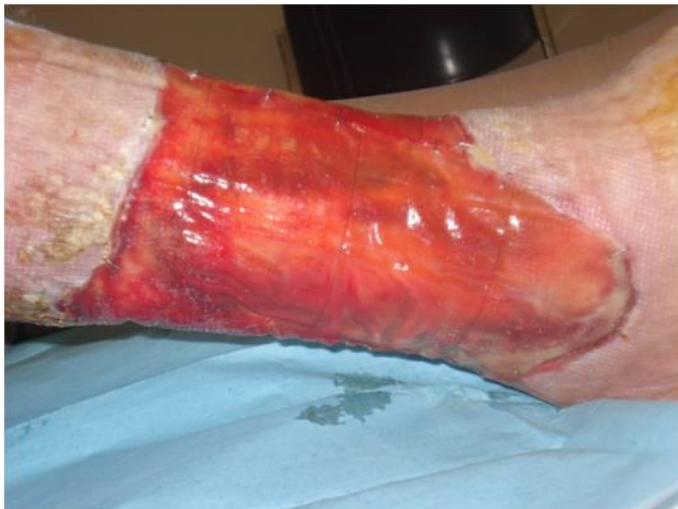(b)

**Figure 2.** a,b) The same case as figure 1. View after outpatient treatment of the wound and its debridement with Versajet hydrosurgery.

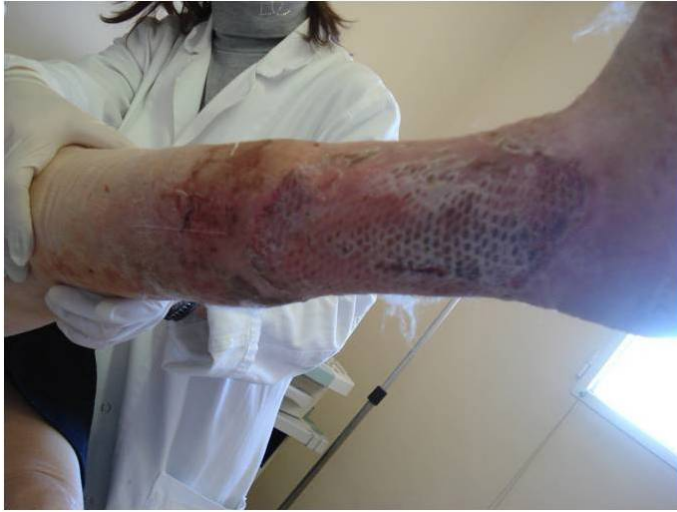



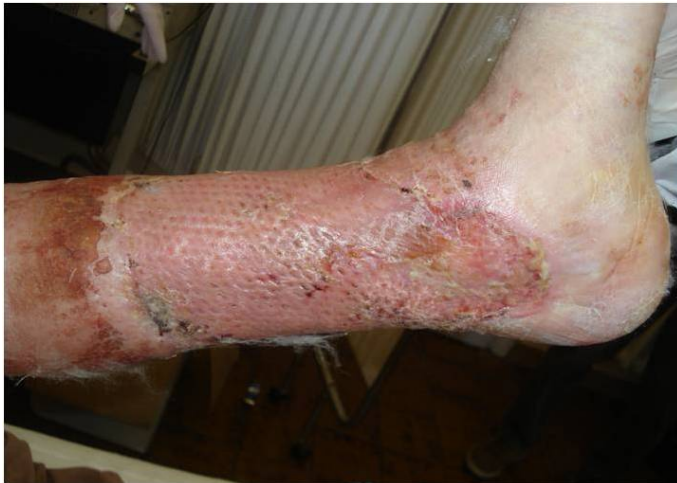**Figure 3.** The same case as figure 1. View of the ulcer 1 week after the application of the Integra dermal substitute. The brightness of the silicone layer is evident.



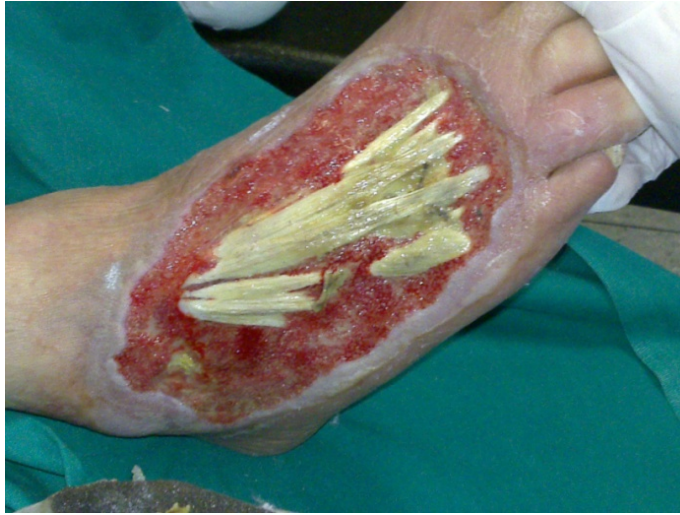**Figure 4.** The same case as figure 1. View of the ulcer 3 weeks after the application of the Integra dermal substitute. The new dermis is completely reconstructed, and the wound is ready for the epidermis skin graft.



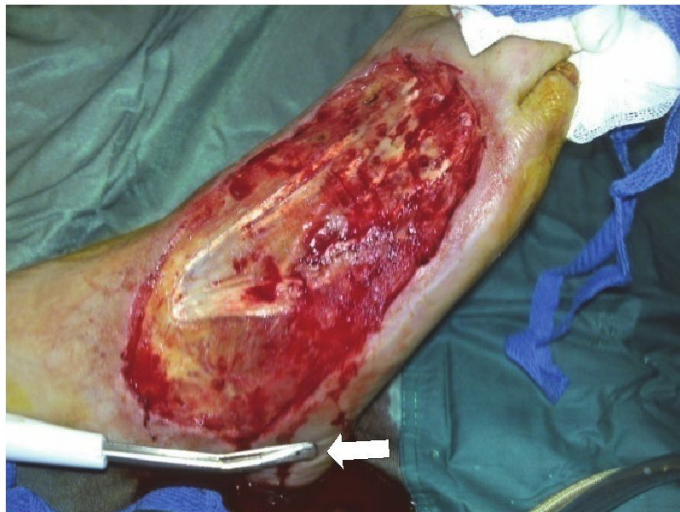**Figure 5.** The same case as figure 1. View of the wound at the end of thin skin graft



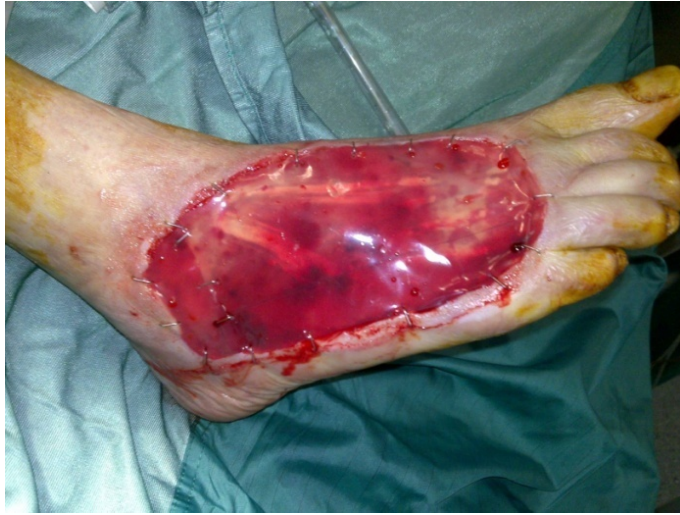**Figure 6.** The same case as figure 1. View of the wound 2 weeks after thin skin graft, which is completely attached.



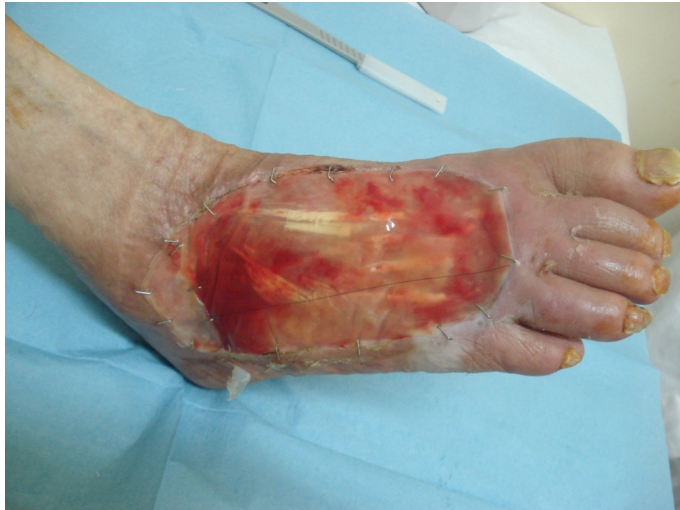**Figure 7.** Neuropathic ulcer of the right leg.



**Figure 8.** The same case as figure 7. Intraoperative view during wound debridement with Versajet hydrosurgery (arrow).

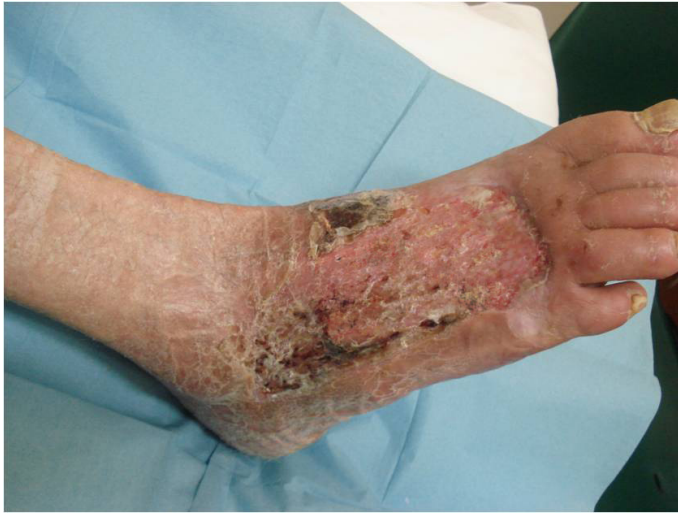

**Figure 9.** The same case as figure 7. View of the ulcer 1 week after the application of the Integra dermal substitute.



**Figure 10.** The same case as figure 7. View of the ulcer 3 weeks after the application of the Integra dermal substitute.





**Figure 11.** The same case as figure 7. View of the wound 2 weeks after thin skin graft..

In all patients, at the first follow-up, a notable reduction in the exudate and the perilesional oedema was ascertained. After 2 weeks the progressive substitution of granulation tissue with new yellow or gold derma became evident through the layer of silicone. Only in 50 cases (7.7%) was it necessary to partially remove the layer of silicone because some areas showed abundant yellowish exudates under the lamina. The neodermis, remaining thus uncovered and without protection, was covered with hydrofibrous and silver dressings, although that did not prevent, even in these patients, the complete formation of the neodermis.

At the check on the 21st day, in all cases, the dermal matrix was completely integrated with the guest tissue, having formed a new homogeneous and living derma, and the next skin-graft operation was planned.

In 339 patients (88.5%) the attachment of the skin graft was complete, whereas in 44 patients (11.5%) it was partial but nevertheless larger than 70% of the surface, but, even in these cases, complete healing of the lesion was achieved within 4 weeks at the most. The definitive result was therefore the complete healing of all of the lesions. All of the patients were examined in follow-up visits for a minimum of 3 months; none suffered from an ulcerous recurrence.

According to our experience, in all of the patients suffering from deep and wide leg ulcers, the use of Integra dermal matrix allowed for the complete refilling of the loss of tissue, with covering of the uncovered anatomical structures such as tendons and aponeuroses, fast and occasionally immediate disappearance of pain in almost all cases, and rapid regeneration of a permanent dermis. The quality, flexibility, and elasticity of the neodermis confirmed the difference from the scar tissue and its similarity to the normal dermis, resulting in better mechanical resistance of the neodermis and fewer tendencies toward hypertrophy of the scar.

This therefore allows the application of a thin epidermal skin graft that requires a secure and faster attachment than a total- or partial-thickness skin graft but also consistent improvement in terms of functional and aesthetic results.

Future directions and research lines in chronic wounds treatment will have to deal with several issues. Concerning tissue-engineered products for skin substitution, these have been associated with improved survival rate and quality of life in patients with extensive burns [43]. However, despite promising results have been reported in clinical trial with products based on autologous cultured keratinocytes and fibroblasts [44], actually these can only serve as a bridge to autografting rather than being suitable for fully replace damaged skin [43,45].

Tissue-engineered tissues cannot replace all skin functions. Protective barrier function is preserved, but touch and temperature sensation, perspiration, thermoregulation, protection from ultraviolet rays, and synthetic function are not restored [43,45], though several studies have investigated the possibility of re-establishing other skin functions with the combination of different cell types [46-48]. Skin-substitute products may be extracted from bone marrow cells [49], and the addition of skin appendages [50] or signaling molecules regulating cell-cell and cell-matrix interactions [51] has been studied to further functionalize bioconstructs.

Aesthetic results remain controversial. Issues of cosmesis and quality of life as well as functionality are nowadays to be considered altogether when dealing with skin-restoration treatment. Human skin does not regenerate postnatally; postnatal healing consists of repair rather than regeneration. Skin replacement products obtained from postnatal cellular materials are unlikely to obtain a true regeneration, and scarring is almost always the final consequence of the process [52,53]. As a matter of fact, skin repair results in scars formation. Uncontrolled scarring may cause possible loss of function where excessive tissue production and contraction occur, apart of poor aesthetic results. Hence, prevention of scar is a problem to be addressed after restoration of the damaged skin. Improved understanding of foetal wound healing has led to therapeutic measures directed at scar-free healing, mainly based on the principle that scarless healing is facilitated by a decreased inflammatory response [45,52]. It has been observed that during foetal life growth factors TGF- $\beta$ 1 and TGF- $\beta$ 2 are low or absent while TGF- $\beta$ 3 is higher; conversely, in adult individuals the latter is insignificant and TGF- $\beta$ 1 and - $\beta$ 2 are predominantly expressed during the inflammation phase of wound healing [54]. A complex interplay of these isoforms is crucial for optimal healing results, as studies on pig and human succeeded in reducing scarring by selectively increasing TGF- $\beta$ 3 and inhibiting TGF- $\beta$ 1 and - $\beta$ 2 levels, whilst neutralization of all three isoforms did not result in reduced scarring [54,55].

The role of stem cells has also been investigated. Both embryonic and adult stem cells have been used in several trials, but research on the former still is delayed by ethical debate. Adult stem cells are being used widely in different research fields. However, results are not as brilliant as expected, due to the impossibility of identifying a stem cell within human skin tissue without ambiguity [50,56,57] and also to unsuitable biochemical and mechanical conditions in a wound which may limit plasticity and proliferative activity of implanted stem cells [57]. Nevertheless, experimental studies conducted on murine models [50,58,59] suggest that research on stem cells should be encouraged as it may achieve production of fully functional true skin equivalents should pattern of cell differentiation be identified in human.

## Author details

Silvestro Canonico\*, Ferdinando Campitiello, Angela Della Corte, Vincenzo Padovano and Gianluca Pellino

\*Address all correspondence to: [silvestro.canonico@unina2.it](mailto:silvestro.canonico@unina2.it)

Department of Medical, Surgical, Neurologic, Metabolic and Ageing Sciences, Second University of Naples, Naples, Italy

## References

- [1] Schultz, G. S., & Wysocki, A. Interactions between extracellular matrix and growth factors in wound healing. *Wound Repair Regen* (2009). , 17(2), 153-62.
- [2] Falanga, V. Classifications for wound bed preparation and stimulation of chronic wounds. *Wound Repair Regen* (2000). , 8, 347-52.
- [3] Stanley, A., & Osler, T. Senescence and the healing rates of venous ulcers. *J Vasc Surg* (2001). , 33, 1206-11.
- [4] Cook, H., Davies, K. J., Harding, K. G., & Thomas, D. W. Defective extracellular matrix reorganization by chronic wound fibroblasts is associated with alterations in TIMP-1, TIMP-2, and MMP-2 activity. *J Invest Dermatol* (2000). , 115, 225-33.
- [5] Hasan, A., Murata, H., Falabella, A., et al. Dermal fibroblasts from venous ulcers are unresponsive to the action of transforming growth factor-beta 1. *J Dermatol Sci* (1997). , 16, 59-66.
- [6] Agren, Steenfos. H. H., Dabelsteen, S., et al. Proliferation and mitogenic response to PDGF-BB of fibroblasts isolated from chronic venous leg ulcers is ulcer-age dependent. *J Invest Dermatol* (1999). , 112, 463-9.
- [7] Mendez, M. V., Stanley, A., Park, H. Y., et al. Fibroblasts cultured from venous ulcers display cellular characteristics of senescence. *J Vasc Surg* (1998). , 28, 876-83.
- [8] Van de Berg, J. S., Rudolph, R., Hollan, C., & Haywood-Reid, P. L. Fibroblast senescence in pressure ulcers. *Wound Repair Regen* (1998). , 6, 38-49.
- [9] Gibson, D., Cullen, B., & Legerstee, R. (2009). Available from <http://www.woundsinternational.com>
- [10] Frame, Still, J., Lakhel Le, Coadou. A., et al. Use of dermal regeneration template in contracture release procedures: a multicenter evaluation. *Plast Reconstr Surg* (2004). , 113, 1330-8.
- [11] Mac, Neil. S. What role does the extracellular matrix serve in skin grafting and wound healing? *Burns* (1994). suppl 1): S, 67-70.

- [12] Iwuagwu, F. C., Wilson, D., & Bailie, F. The use of skin grafts in postburn contracture release: a 10-year review. *Plast Reconstr Surg* (1999). , 103, 1198-207.
- [13] Zhong SP, Zhang YZ, Lim CT. Tissue scaffolds for skin wound healing and dermal reconstruction. *WIREs Nanomed Nanobiotechnol* (2010). , 2, 510-25.
- [14] International consensus. Acellular matrices for the treatment of wounds. An expert working group review. London: Wounds International, (2010).
- [15] Matouskova, E., Broz, L., Sotbova, et al. Human allogeneic keratinocytes cultured on acellular xenoderms: the use in healing of burns and other skin defects. *Biomed Mater Eng* (2006). suppl 4): SS71., 63.
- [16] Brychta, P., Adler, J., Rihova, H., et al. *Cell Tissue Bank* (2002). , 3, 15-23.
- [17] Erdag, G., & Morgan, J. R. Allogeneic versus xenogeneic immune reaction to bioengineered skin grafts. *Cell Transplant* (2004). , 13, 701-12.
- [18] Nataraj, C., Ritter, G., Dumas, S., et al. *Wounds* (2007). , 19(6), 148-56.
- [19] Morimoto, N., Saso, Y., Tomihata, K., et al. Viability and function of autologous and allogeneic fibroblasts seeded in dermal substitutes after implantation. *J Surg Res* (2005). , 125, 56-67.
- [20] Dantzer, E., Queruel, P., Salinier, L., et al. Dermal regeneration template for deep hand burns: clinical utility for both early grafting and reconstructive surgery. *Br J Plast Surg* (2003). , 56, 764-74.
- [21] Rennekampff, H. O., Hansbrough, J. F., Woods, V., & Jr Kiessig, V. Integrin and matrix molecule expression in cultured skin replacements. *J Burn Care Rehabil* (1996). , 17, 213-21.
- [22] Griffiths, M., Ojeh, N., Livingstone, R., et al. Survival of Apligraf in acute human wounds. *Tissue Eng* (2004). , 10, 1180-95.
- [23] Cullen, B., Watt, P. W., Lundqvist, C., et al. The role of oxidised regenerated cellulose/collagen in chronic wound repair and its potential mechanism of action. *Int J Biochem Cell Biol* (2002). , 34(12), 1544-56.
- [24] Brown-Etris, M., Cutshall, W. D., & Hiles, M. C. *Wounds* (2002). , 50-66.
- [25] Voytik-Harbin SL, Brightman AO, Kraine MR, et al. Identification of extractable growth factors from small intestine submucosa. *J Cell Biochem* (1997). , 57, 478-91.
- [26] Hodde JP, Record RD, Liang HA, Badylak SF. Vascular endothelial growth factor in porcine derived extracellular matrix. *Endothelium* (2001). , 8(1), 11-24.
- [27] Cornwell, K. G., Landsman, A., & James, K. S. Extracellular matrix biomaterials for soft tissue repair. *Clin Podiatr Med Surg* (2009). , 26, 507-23.
- [28] Powell HM, Boyce ST. EDC cross-linking improves skin substitute strength and stability. (2006). *Biomaterials*, 27(34), 5821-27.



- [29] Wiegand, C., Abel, M., Ruth, P., & Hipler, U. C. Influence of the collagen origin on the binding affinity for neutrophil elastase. Abstract presented at: 18th Conference of the European Wound Management Association (EWMA); May (2008). , 14-16.
- [30] Mulder, G., & Lee, D. K. Wounds (2009). , 21(9), 254-61.
- [31] 2003, Sheehan, P., Jones, P., Caselli, A., et al. Percent change in wound area of diabetic foot ulcers over a 4-week period is a robust predictor of complete healing in a 12-week prospective trial. *Diabetes Care*, 26(6), 1879-82.
- [32] Burke JF, Yannas IV, Quinby WC Jr, et al. Successful use of a physiologically acceptable artificial skin in the treatment of extensive burn injury. *Ann Surg* (1981). , 194, 413-20.
- [33] Dostal GH, Gamelli RL. Fetal wound healing. *Surg Gynecol Obstet* (1993). , 176, 299-306.
- [34] Bullard, K. M., Longaker, M. T., & Lorenz, H. P. (2003). 27, 54-61.
- [35] Olutoye OO, Barone EJ, Yager DR. Hyaluronic acid inhibits fetal platelet function: implications in scarless healing. *J Pediatr Surg* (1997). , 32, 1037-40.
- [36] Gottlieb, Furman. J. Successful management and surgical closure of chronic and pathological wounds using Integra. *J Burns Surg Wound Care* (2004). , 3, 54-60.
- [37] Moiemens NS, Staiano JJ, Ojeh NO, et al. Reconstructive surgery with a dermal regeneration template: clinical and histologic study. *Plast Reconstr Surg* (2001). , 108, 93-103.
- [38] Orgill DP, Straus FH II, Lee RC. The use of collagen-GAG membranes in reconstructive surgery. *Ann NY Acad Sci* (1999). , 888, 233-48.
- [39] Heimbach, D., Luterman, A., Burke, J., et al. Artificial dermis for major burns: a multi-center randomized clinical trial. *Ann Surg* (1988). , 208, 313-20.
- [40] Sheridan, R. L., Hegarty, M., Tompkins, R. G., et al. Artificial skin in massive burns: results to ten years. *Eur J Plast Surg* (1994). , 17, 91-3.
- [41] Heimbach, D. M., Warden, G. D., Luterman, A., et al. Multicenter postapproval clinical trial of Integra dermal regeneration template for burn treatment. *J Burn Care Rehabil* (2003). , 24, 42-8.
- [42] Chou TD, Chen SL, Lee TW, et al. Reconstruction of burn scar of the upper extremities with artificial skin. *Plast Reconstr Surg* (2001). , 108, 378-84.
- [43] Mac, Neil. S. (2007). Progress and opportunities for tissue-engineered skin. *Nature*, 445, 874-80.
- [44] Boyce ST, Kagan RJ, Greenhalgh DG, et al. Cultured skins substitutes reduce requirements for harvesting of skin autograft for closure of excised, full-thickness burns. *J Trauma* (2006). , 60, 821-9.

- [45] Metcalfe AD, Ferguson MW. Tissue engineering of replacement skin: the crossroads of biomaterials, wound healing, embryonic development, stem cells and regeneration. *J R Soc Interface* (2007). , 4, 413-37.
- [46] Ponec, M., El Ghalbzouri, A., Dijkman, R., et al. (2004). Endothelial network formed with human dermal microvascular endothelial cells in autologous multicellular skin substitutes. *Angiogenesis*, 7, 295-305.
- [47] Dezutter-Dambuyant, C., Black, A., Bechetoille, N., et al. *Biomed Mater Eng* (2006). S, 85-94.
- [48] Rolin, G., Placet, V., Jacquet, E., et al. Development and characterization of a human dermal equivalent with physiological mechanical properties. *Skin Res Technol* (2012). , 18, 251-8.
- [49] Fioretti, F., Lebreton-Decoster, C., Gueniche, F., et al. Human bone-marrow derived cells: an attractive source to populate dermal substitutes. *Wound Repair Regen* (2008). , 16, 87-94.
- [50] Blanpain, C., Lowry, W. E., Geoghegan, A., et al. *Cell* (2004). , 118, 635-48.
- [51] Ma PX. Biomimetic materials for tissue engineering. *Adv Drug Deliv Rev* (2008). , 60, 184-98.
- [52] Martin, P., & Leibowich, S. J. Inflammatory cells during wound repair: the good, the bad and the ugly. *Trend Cell Biol* (2005). , 15, 599-607.
- [53] Metcalfe AD, Ferguson MW. (2007). Bioengineering skin using mechanisms of regeneration and repair. *Biomaterials*, 28, 5100-13.
- [54] Ferguson, M. W., & O'Kane, S. *Phil Trans R Soc Lond B* (2004). , 359, 839-50.
- [55] O'Kane, S., & Ferguson, M. W. Transforming growth factor  $\beta$ s and wound healing. *Int J Biochem Cell Biol* (1997). , 29, 63-78.
- [56] Tumber, T. Epithelial skin stem cells. *Methods Enzymol* (2006). , 419, 73-99.
- [57] Lemoli, R. M., Bertolini, F., Cancedda, R., et al. (2005). 90, 360-81.
- [58] Toma, J. G., Akhavan, M., Fernandes, K. J., et al. Isolation of multipotent adult stem cells from the dermis of mammalian skin. *Nat Cell Biol* (2001). , 3, 778-84.
- [59] Blanpain, C., Horsley, V., & Fuchs, E. *Cell* (2007). , 128, 445-58.