

---

# Stent-Assisted Techniques for Intracranial Aneurysms

---

Igor Lima Maldonado and Alain Bonafé

Additional information is available at the end of the chapter

<http://dx.doi.org/10.5772/51295>

---

## 1. Introduction

The aim of this chapter is to present the current state of stent-assisted techniques for the treatment of intracranial aneurysms. Most of the information that is presented here is based on recent international literature, as well as the personal experience of the authors. It is illustrated with diagrams of key procedures. Since it is a technical chapter, the subject will be discussed from an operative point of view, and the topics will be presented in the order in which they would probably be approached by the operator: *background, indication, patient evaluation and preparation, equipment, operative technique, results, complications and post-operative management.*

## 2. History

In the early years of endovascular techniques, the main method for the treatment of wide-neck aneurysms was surgical. Attempts at embolization presented significant risks of coil herniation, migration, parent artery occlusion and poor mid-term morphological results with high recurrence rates. A great effort has been made by engineers and manufacturers to develop coils that present a better arrangement inside the aneurysm sac and fulfil two important conditions: a good apposition with the aneurysm wall, and a stable three-dimensional conformation, so that loops do not herniate through the aneurysm neck.

The first issue was approached by the development of coils with a geometry intended to fill the aneurysm sac, even if it is irregular. A good apposition with all regions of the cavity may improve the aneurysm embolization ratio and increase the stability of the coil mass, preventing migration. The second issue was approached through the development of coils with a memory of their three-dimensional shape, so that they may be used to create a

---

relatively predictable cage that would keep the subsequent coils inside. As one may imagine, the above properties are relatively antagonistic. A coil that penetrates irregular spaces and has a good position to the aneurysm wall is also a coil that may herniate through a large aneurysm neck. In this context of technical difficulty, balloon and stent-assisted techniques have been used to provide protection for the parent artery as well as to treat coil mass herniation.

Intracranial stents also serve as scaffolding for neo-endothelization, providing additional reduction of the flow into the aneurysm. Consequently, their use improves intrasaccular thrombosis and decreases the risk of recanalization.

Even if these concepts seem attractive, manufacturers were rapidly confronted with technical difficulties, such as the narrowness and fragility of the intracranial vasculature, the need to navigate tortuous vessels, and the obligation to provide materials that were thin enough so that a microcatheter could be placed simultaneously in the vasculature.

The first case of intracranial stenting for treating a brain aneurysm was reported by Higashida et al. in 1997 (Higashida et al., 2005). In that occasion, the authors used a balloon-expandable cardiac stent in combination with Guglielmi detachable coils to treat a fusiform aneurysm of the vertebrobasilar junction. At that time, other authors had already attempted the placement of stent and coils in a fusiform aneurysm in an experimental context in pigs. Soon after, different groups reported a number of strategies using a combination of balloon-mounted stents and coils. In 2000, the use of stents for managing coil migration during the treatment of wide neck aneurysms was reported (Fessler et al., 2000, Lavine et al., 2000) and the case series became progressively larger.

The first stent specifically designed for the intracranial area to obtain Food and Drug Administration (FDA) approval was the Neuroform™ (Boston Scientific Corporation, Natick, USA). The device was approved for 'humanitarian device exemption' in 2002. This means that its use was complicit to the additional approval of an Institutional Review Board and was supposed to be limited to use on no more than 4000 individuals per year in the United States of America (USA).

Outside the USA, especially in Europe and in the context of clinical research, other stents became rapidly available. That was the case with the Leo™ (Balt, Montmorency, France), the first self-expanding closed cell design stent released in Europe in 2003, and then the Enterprise™ (Cordis Neurovascular I., Miami Lakes, USA), which was approved by the FDA in the US in 2007.

Flow diverters are the last technical advances bringing the concept of 'reverse remodeling' for intracranial aneurysm treatment. Silk™ (Balt, Montmorency, France) and Pipeline™ (Chestnut Medical Technologies Incorporation, Menlo Park, CA, USA) are in this category. These devices are intended to exclude the aneurysm sac from the parent artery by creating significant flow disruption, so that blood significantly stagnates inside the aneurysm sac and thromboses.

### 3. Indications

For treatment of intracranial aneurysms, stents are used mainly in two different situations: wide neck aneurysm and unfavourable anatomy. Wide neck aneurysm has been defined as a saccular aneurysm in the diameter of the neck larger than 4 mm, in which the dome-to-neck ratio is less than 2, or in which the ASPECT ration is superior to 1.6. These circumstances are associated with an increased risk of coil migration and compromising of parent artery patency during non-assisted endovascular coiling. Both situations are not uncommon with large and giant sacciform aneurysms. Circumstances for unfavourable anatomy are MCA trifurcation, neck-to-parent artery diameter  $<1$  and fusiform aneurysms.

The indication stent-assisted endovascular treatment of cerebral aneurysms goes beyond vascular morphology. In the last few years, issues regarding patient selection have received progressively more attention, with the aim of reducing perioperative complications. A candidate for such a procedure must understand the risks and benefits, and be capable of following medical recommendations, especially the use of double antiplatelet therapy. As a consequence, any social and psychiatric conditions in which the compliance of the use of such medications and follow-up are significantly compromised should be considered as relative contra-indications.

Caution should be taken with individuals who may need surgery or a ventricular drainage shortly after the aneurysm treatment - situations that are more frequent with ruptured aneurysms. As the use of antiplatelet medication is mandatory, significant controversy exists on the placement of intracranial stents in the acute phase of intracranial haemorrhage. If subtotal embolization of the aneurysm sac may be performed with coils only, a valuable strategy is to complete treatment in a different session. In such a case, stenting would be performed far from the subarachnoid haemorrhage. Other relative contra-indications are exaggerated; vessel tortuosity, significant atherosclerotic disease and coagulation disorders.

### 4. Pre and per-operative evaluation

The decision to deploy an intracranial stent is taken after considering the feasibility of performing the treatment without it (e.g. aneurysm coiling to be safely treatable using balloon remodeling techniques), or the possibility of not completing the treatment due to technical difficulties such as poor navigability. The diameter and length of each device is chosen according to the diameter of the native vessel and the extension of the pathological segment.

Important issues for treatment planning are: exact aneurysm anatomical location, parent artery morphology and presence of side branches and perforators. These factors are studied on CT, MRI or DSA images before the operative procedure. The size and shape of the aneurysm, as well as the diameter of the neck, are recorded. The diameter of the parent artery is then measured, as well as the segment of the artery that will be covered by the stent. The operator will then be able to choose the adequate diameter and length of the device to use so that adequate covering of the neck can be assured.

The tortuosity of the parent artery and the technique for coiling (e.g. jailing, semi-jailing, 'X' and 'Y' stents, etc.) also influences the type of stent used (open cell versus closed cell, self-expandable versus balloon-mounted, etc). It is particularly important to detect potential irregularities due to other vascular pathologies such as atherosclerosis or fibromuscular dysplasia. Part of the assessment of feasibility of the stent-assisted treatment is the study of branches presenting with sharp angle of bifurcation or incorporation of its origin into the neck of the aneurysm. Such vessels may be very difficult to catheterize. If it needs to be stented, this may result in a longer and more laborious procedure. If the progression of a microguidewire and a microcatheter inside a recurrent branch is impossible after numerous attempts, other treatment modalities (e.g. surgical) must be considered. As a consequence, the patient must be properly informed before the endovascular procedure that his or her treatment presents elements of technical complexity, and that endovascular treatment may not be feasible.

## 5. Pre-operative preparation

A baseline neurological examination is performed and neurological scores are attributed when applicable (e.g. modified Rankin and NIHSS score), which are useful for follow-up, especially for patients who have a past history of neurological disease.

Antiplatelet agents are highly recommended in the preparation patients undergoing intracranial stenting. Insufficient platelet inhibition (PI) has been associated with an augmented risk of thrombus formation and embolic complications. As a consequence, patients receive either a loading-dose or a period of antiplatelet therapy. A loading-dose of 300 or 600 mg of clopidogrel is then administered the day before the endovascular treatment. Alternatively a dose of 75mg PO QD for five or more days has also been proposed for some authors. This is supported by both literature to date and previous experience in the cardiology field.

Since double antiaggregation is recommended, administration of acethyl-salicylic acid (ASA) is also performed perioperatively. Some authors have suggested the use of preparations of 325mg or more for three or more days before the procedure, concomitant with clopidogrel. Other teams have preferred to administer a single intravenous bolus of 250-500 mg of injectable ASA at the moment of the endovascular procedure. This presents the advantage of avoiding the use of double antiaggregation in the pre-operative period, in which the aneurysm is not yet secured. However, injectable preparations are not available in all countries worldwide.

Whilst ASA resistance seems relatively uncommon, clopidogrel resistance seems to be frequent. The prevalence of low-response to this drug varies from 28% to 66% in literature. Little data is available specifically for patients undergoing stent-assisted treatment of intracranial aneurysms, but thromboembolic adverse events do seem highly concentrated in the low responder group. Some authors have consequently recommended a level of at least 40% of platelet inhibition.

Individual response to clopidogrel may be evaluated using different techniques. Recently, point-of-care assays have been commercially available, allowing practitioners to perform prompt measurements pre-operatively. The level of PI is now routinely assessed before intracranial stenting in a number of centers. In selected cases, the doses of antiplatelet agents might be adapted in order to achieve the desired levels. Another advantage of these point-of-care assays is the fact that they may be performed per-operatively, so that the operator is informed of the percentage of antiaggregation at the moment of stent deployment.

Such an approach requires systematic blood sampling, subsequent drug administration and financial investment. At present, no prospective study assessed the potential benefits in achieving a level of anti-aggregation over 40% in patients undergoing intracranial procedures. The same applies for the assessment of the risk of hemorrhagic adverse events that may be related to the combination of intravenous heparin and double antiaggregation.

We have witnessed a proliferation of portable devices and this technology is increasingly being used, and particularly in the cardiology field. Different assays are now commercially available: VerifyNow (Accumetrics, San Diego, USA), PlateletWorks (Helena Lab.; Beaumont, USA), IMPACT-R (with and without ADP stimulation, DiaMed AG, Cressier sur Morat, Switzerland), DADE PFA collagen/ADP test (Siemens Healthcare Diagnostics Products, Marburg, Germany) and others. Even so, there is some evidence that only measurements using light transmittance aggregometry (VerifyNow and PlateletWorks) are significantly correlated to the occurrence of ischemic adverse events in interventional cardiology as suggested by the POPULAR study in 2010 (Breet et al., 2010). Other studies, such as the BOCLA (Neubauer et al., 2011), showed that the concept of clopidogrel resistance may be relative, and that more than half of poor responders may have a good response by increasing (two-fold) the dose.

In the field of interventional neuroradiology, studies specifically focused on the importance of antiaggregation are rare. Four case series were published in 2008 (Lee et al., 2008, Muller-Schunk et al., 2008, Pandya et al., 2008, Prabhakaran et al., 2008). Only two have studied the incidence of thromboembolism using techniques and different cut-offs. We recently performed a study on 271 procedures in which the VerifyNow assay was used and observed a significant association between thromboembolism and poor antiaggregation. The ability to predict the risk of a thromboembolic event occurring does exist, but it is moderate given the multifactorial nature of these events. In our experience, body weight should be considered as an important factor to observe. After a homogenous, single loading dose of 300mg of clopidogrel, the prevalence of low-response (<40% of PI) is significantly lower in patients weighing less than 60 kilograms (43% versus 29%). If a stent has to be deployed urgently and the patient has not been prepared with antiplatelet agents, the risk of thromboembolic events may be significant, since post-operative aspirin and clopidogrel will take time to act. Some authors have suggested the use of a loading dose just after the procedure. Others have preferred to use a GPIIb/IIIa inhibitor. A bolus of 0.025 mg/Kg of intravenous abciximab may be administered and followed by infusion at 10 mcg/min per 12 hours. Evidently, this strategy should be used with caution and not as routine in view of the well-known hemorrhagic side effects of intravenous GPIIb-IIIa inhibitors.

## 6. Equipment

### 6.1. Leo™

Leo™ (Balt, Montmorency, France) was the first closed-cell stent to be released in the market. A second generation was released thereafter as Leo+™. This is a self-expandable device made of nitinol (nickeltitanium) wires with a braided design. Its main features are good visibility and the availability of long devices (up to 75 mm). According to the manufacturer, the following product characteristics should be noted:

- Available in four nominal diameters: 2.5, 3.5, 4.5 and 5.5 mm, for vessels from 2.0 to 6.5 mm;
- Available in nine lengths: 12, 18, 25, 30, 35, 40, 50, 60, 75 mm;
- Braided design of nitinol wires;
- Self-expandable;
- Good wall apposition;
- Very good visibility;
- Significant shortening after deployment;
- Retrievable up to its 90% deployment;
- Equipped with a double helix radio-opaque, easily visible strands;
- Equipped with delivery microguidewire with a radio-opaque distal tip;
- Compatible and recommended to be delivered with a Vasco+ microcatheter;
- Recommended to be used in a triaxial system with a distal access system 6F Fargo-Fargomax.

### 6.2. Neuroform™

The first version of the Neuroform stent was approved in 2002 for the treatment of wide-neck, intracranial aneurysms. It was designed for vessels with diameters from 2 to 4.5 mm. It was the first self-expandable device specifically designed for assisting the treatment of brain aneurysms with coils. Made of nitinol, the Neuroform stent has an open-cell design. In its first version, a low radial force resulted in a number of cases of inadequate support for the coil mass within the aneurysm and technical problems such as stent migration. The Neuroform2 stent was launched in 2003 and the Neuroform3 in 2005. According to the manufacturer, the following product characteristics should be noted:

- Available in a range of sizes from 10 to 30 mm in length;
- Available in a range of diameters from 2.5 to 4.5 mm;
- Open cell geometry;
- Minimal shortening after deployment;
- Self-expandable;
- Flexibility and conformable in tortuous distal anatomy;
- Capable of apposition in tapered vessels;
- Interstices of 2–2.5 F (<1mm), allowing the positioning of a microcatheter through the stent;

- Proximal and distal stent markers
- Thin mesh;
- Minimal radial force;
- Not retrievable.
- Equipped with 131cm delivery microcatheter (3F proximal, 2.8F distal)
- Compatible and more appropriate for use with 0.014" Transend 300 Floppy microguidewire
- Equipped with a 150cm (2F) stabilizer (pusher) catheter with a marker band at the distal tip that indicates the proximity of the stabilizer catheter to the proximal end of the stent.

In 2010, the fourth version of the Neuroform stent was released: Neuroform EZ™. This newest version eliminated the need for an exchange maneuver using a 3m microguidewire. It may be delivered using a standard 3F microcatheter. As a consequence, the following features should be noted:

- Equipped with a Neuro Renegade™ Hi-Flo™ Microcatheter for deployment (total usable length 150cm, flexible tip length 10 cm)
- Equipped with a 185cm stainless stent delivery wire with a radio-opaque 19mm 45° pre-shaped distal tip and two radio-opaque positioning bumpers, one proximal, the other distal to the stent.

### 6.3. Enterprise™

The Cordis Enterprise Vascular Reconstruction Device and Delivery System consists of a self-expanding closed-cell stent and a delivery system. Its design is that of tubular mesh made of nitinol. The delivery system is composed of a delivery wire that acts also as a pusher. A major characteristic of this device is its easy placement, with good wall apposition and excellent support of the coil mass. A partially deployed device can be recaptured once and redeployed. A disadvantage of the delivery system is the absence of a very long microguidewire distal to the parent artery. In the context of very tortuous vessels, this may be a factor of instability during deployment. According to the manufacturer, the following product characteristics should be noted:

- Available in one diameter, 4.5 mm and can be used in vessels from 2.5 to 4 mm;
- Available in four lengths: 14, 22, 28, and 37 mm;
- Closed-cell geometry;
- Self-expandable;
- Good wall apposition;
- May present significant shortening after deployment, from 1.1 to 4.7mm, depending on the length of the stent and the diameter of the parent vessel;
- Proximal and distal stent markers;
- Equipped with a delivery wire with three radio-opaque segments (distal, at the tip of the wire; intermediate, long radio-opaque segment for stent positioning; and proximal marker, just before the proximal stent markers)

- Retrievable once, if the proximal end of the stent-positioning marker the (intermediate marker on the delivery wire) is not beyond the distal microcatheter markerband.
- Compatible and recommended with a 0.021 Prowler Select Plus Infusion Catheter, positioned at least 12 mm beyond aneurysm neck before stent delivery.

#### 6.4. Solitaire AB™

The Solitaire AB (aneurysm bridging) Neurovascular remodeling Device (ev3 Cooperate, Plymouth, USA) is the first fully deployable and retrievable device for assisting intracranial aneurysm embolization with coils. It is a nitinol self-expanding stent that can be delivered and deployed by a single operator. The stent works with an open longitudinal split and is fixed to its pusher. There is no guidewire beyond the distal markers. It can be detached electrolytically using a dedicated detachment system. According to the manufacturer, the following product characteristics should be noted:

- Available in two diameters, 4mm for vessels from 3 to 4mm, and 6 mm for vessels from 5 to 6mm. Since recently, a new 3mm version is also available.
- Available in three lengths: 15 (only with 4mm diameter), 20 (both 4 and 6 mm diameter) and 30mm (only with 6 mm diameter);
- Closed-cell geometry;
- Self-expandable;
- Presence of a longitudinal split with overlapping of the stent cells, depending on the diameter of the parent vessel;
- Good wall apposition;
- High cell deformation resistance;
- Presents significant shortening after deployment, depending on the length of the stent and the diameter of the parent vessel;
- One Proximal and three distal stent markers;
- Equipped with a delivery wire, with a detachment zone just before the proximal marker;
- Can be retrieved and repositioned before detachment, even when fully deployed;
- Compatible and recommended with a Rebar 18-27 Microcatheter (\*but also compatible with a 0.021 Prowler Select Plus Infusion Catheter).

#### 6.5. Pharos™

The Pharos stent (Micrus, San Jose, USA) was launched in 2006 in Europe for the treatment of ischemic disease. The Pharos Vitesse stent is the second generation of this balloon-expandable stent for both intracranial ischemic stenosis and wide-neck aneurysm treatment. It is a rapid exchange balloon-delivered device, which enables the operator to deliver and deploy the stent in one step. Made of cobalt chromium, the stent is opened by the radial force of the balloon. There is no self-expansion of the device. According to the manufacturer, the following product characteristics should be noted:



- Available in eight diameters: 2, 2.5, 2.75, 3, 3.5, 4, 4.5 and 5 mm, for vessels from 2 to 5 mm;
- Available in six lengths: 8, 10, 13, 15, 18 and 20 mm;
- Double helix geometry with thin struts (60 micra);
- Not self-expandable;
- Good wall apposition;
- High radial force
- Good visibility;
- Compatible with a 0.014" microguidewire
- Very low shortening after deployment (<1%);
- Proximal and distal stent markers;

## 6.6. LVIS™

The Low-profile Visualized Intraluminal Support (MicroVention Incorporation, Tustin, USA) is a very recent generation of devices intended for use with embolic coils, now available in Europe. It is a hybrid closed-cell stent in nitinol with flared ends and a double helix of tantalum strands to assist full-length visualization. It presents a high metal-to-surface coverage intended to help promote neo-endothelization. However, the sliding design of its cells ensures the feasibility of crossing the struts with a microcatheter. According to the manufacturer, the following product characteristics should be noted:

- Available in three nominal diameters, 2.5, 3.5, and 4.0 mm, respectively for vessels from 2 to 3 mm, 2.5 to 3.5 mm and 3.5 to 4.5 mm;
- Available in six lengths, 17 and 25 mm for the 2.5 mm diameter, 15, 25 and 41 mm for the 3.0 mm diameter, 35 and 49 mm for the 4.0 diameter stent;
- Hybrid, compliant closed-cell geometry with thin struts;
- Self-expandable;
- Good wall apposition;
- Flared ends;
- Good visibility;
- High metal-to-surface coverage;
- Significant shortening after deployment;
- Retrievable up to 80% deployment;
- Proximal and distal stent markers, as well as double helix radio-opaque tantalum strands;
- Equipped with delivery microguidewire with a radio-opaque distal tip;
- Compatible with a 0.021 Headway microcatheter.

## 6.7. Flow diverters

These are braided, tubular stents with very small struts that are intended to provide significant flow disruption along the aneurysm neck, but allow preservation of both large branches and small perforators. Such devices may reduce shear stress on the aneurysm wall

and promote intra-aneurysmal blood stagnation and thrombosis (Pierot, 2011). Besides their effects on flow, these devices also provide significant scaffolding for neo-endothelization across the aneurysm neck. They are high-cost devices and their main characteristic is the very high metal-to-artery coverage in comparison to conventional stents. Two devices are currently available, as follows.

#### 6.7.1. *Silk™*

The Silk and its more recent version Silk Plus (Balt, Montmorency, France) are self-expanding stents made of braided nitinol strands, with the following technical characteristics.

- Available in eight nominal diameters: 2.0, 2.5, 3.0, 3.5, 4.0, 4.5, 5.0 and 5.5 mm, for vessels from 1.5 to 5.75 mm;
- Available in six nominal lengths, 15, 20, 25, 30, 35 and 40 mm;
- Also available in tapered version (Tapered Silk+) in three combinations of diameters: 4.0 mm proximal and 3.0 mm distal (30mm long), 4.5 mm proximal and 3.0 mm distal (25 mm long), 4.5 mm proximal and 3.5 mm distal (30 mm long);
- Dense mesh geometry with very high metal-to-surface coverage;
- High radial force (Silk Plus has 15% more radial force than Silk) thanks to a different strut configuration;
- Good wall apposition;
- Good visibility;
- Slight flared ends
- Double helix radio-opaque markers through the entire body of the stent, combined with extra Platinum small wires in the Silk Plus version, that allow visualization of the borders of the stent;
- Equipped with delivery pusher/microguidewire with a radio-opaque distal tip;
- Compatible and recommended with a Vasco+ microcatheter for delivery and a triaxial system with a long introducer and a distal access system 6F Fargo-Fargomax;
- Compatible with concentric Leo+ stents for lumen reconstruction before deployment of Silk or Silk Plus, if needed in fusiform aneurysms.

#### 6.7.2. *PED – Pipeline Embolisation Device™*

The Pipeline Embolisation Device (ev3-MTI, Irvine, USA) is a newer, self-expanding, flexible device, composed of 25% platinum tungsten and 75% cobalt chromium in interwoven strands. According to the manufacturer, the following product characteristics should be noted:

- Available in eleven nominal diameters: 2.0, 2.75, 3.0, 3.25, 3.5, 3.75, 4.0, 4.25, 4.5, 4.75 and 5.0;
- Available in nine nominal lengths, 10, 12, 14, 16, 18, 20, 25, 30 and 35 mm;

- Dense mesh geometry with braided construction and very high metal-to-surface coverage, which can be customized according to the push that is imposed to the microcatheter (increased push narrows stent cells);
- High radial force and flexibility, resistant to kinking;
- Good wall apposition;
- Uniform visibility through entire device;
- Ability to telescope multiple devices, one inside another to create longer constructs;
- Equipped with delivery pusher/microguidewire with a radio-opaque distal tip and a 'capture coil' that keeps the device in contact to the guidewire until significant length is deployed;
- Compatible and recommended with a 2.8F/3.2F Marksman™ microcatheter for delivery and deployment.

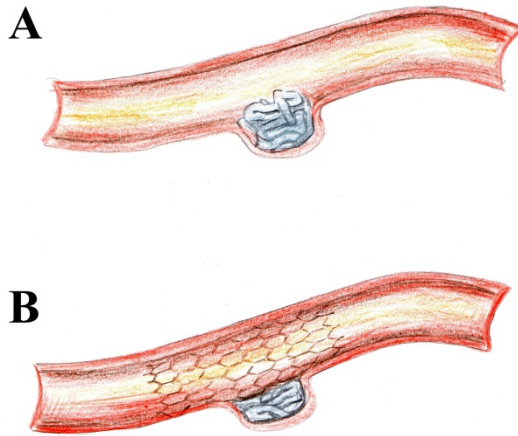
## 6.8. Other

It is worth noting that a number of stents that were not specifically designed for use with intracranial aneurysms have non-rarely been used as adjunctive devices. This situation was much more frequent in the early times of stent-assisted aneurysm embolization, when a lesser variety of devices were available. That is the case with the Jostent GraftMaster Stent Graft (Abbott Vascular, Redwood City, Calif), a balloon-mounted system consisting of two stainless steel flexible devices with an expandable layer of polytetrafluoroethylene between them. It was developed for use within the coronary circulation, particularly for cases of leakage or vessel perforation. However, cases of repair of internal carotid artery, middle cerebral artery and vertebral artery aneurysms were regularly reported with this system (Chan et al., 2004, Mehta et al., 2003, Pero et al., 2006, Saatci et al., 2004, Wang et al., 2009). During the advancement of neurointerventional tools for wide-neck aneurysms, several stents initially designed for the cervical carotid or coronary circulation were also used as adjunctive devices, such as Wallstent™ (Boston Scientific, Natick, USA), Multilink™ (Abbott Vascular, Redwood City, Calif), and others (Lavine & Meyers, 2007, Morizane et al., 2000, Wanke & Forsting, 2008).

## 7. Operative technique

### 7.1. Coiling and stenting: 'finishing stent' and 'rescue stent'

An intracranial stent may be used at the end of an aneurysm embolization when coils have been used, which is particularly useful in cases in which the aneurysm neck was not fully respected by the coil mass, or to insure protection of the parent artery against coil migration. In addition, when a stent is deployed after an aneurysm coil, significant scaffolding for neo-endothelisation is provided and an increase in pack density may be observed. This technique may be particularly useful for small aneurysms, in which the introduction of a microcatheter and repetitive manipulations may be dangerous. The coil is deployed first and then a preloaded stent is released, pushing the coil loop into the sac. This method has been also been known as a 'stent-jack' technique.



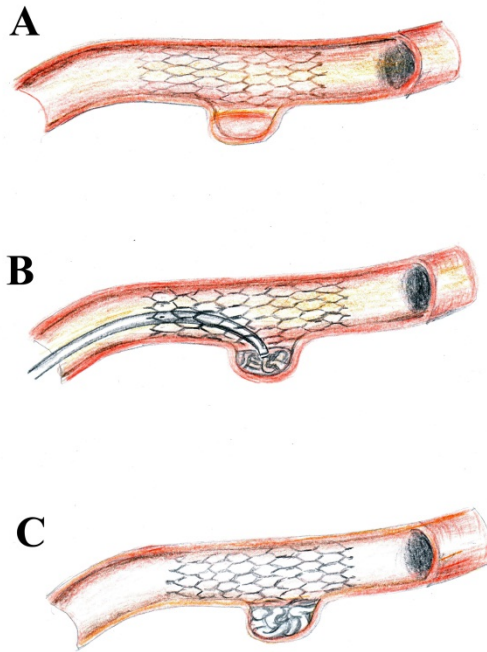
**Figure 1.** 'Finishing stent'. *A*, The coil mass protrudes slightly in the lumen of the parent vessel. *B*, The coils are pushed back into the aneurysm sack with a 'finishing stent'.

When non-assisted coiling is performed, coil migration or herniation of the coil mass may be observed, even if the neck is not very wide. This may also be observed during balloon-assisted embolization. If a large amount of material is present in the lumen of the parent artery, its patency may be threatened, or the patient may be exposed to a risk of embolic phenomena. In such a situation, a valuable technique can be the deployment of what is called a 'rescue stent', which pushes the herniated coils against the vessel wall or back inside the aneurysm sac.

## 7.2. Stenting and coiling: crossing a deployed stent with a microcatheter

When stent-assisted coiling is performed, the microcatheter tip may be placed inside the aneurysm through the stent struts. The choice between this method and placement of the microcatheter before stenting depends on the operator's experience, the vascular morphology and aneurysm size. Placement of a microcatheter into the aneurysm is evidently more difficult after stenting, especially if a closed-cell device was used. In this last case, a thinner microcatheter may be necessary. Some practitioners prefer using a Neuroform stent in such situations, for the same reason. Furthermore, with a Neuroform stent, it is easier to regain access to the aneurysm sac in cases of microcatheter kickback into the parent vessel.

If the operator experiences difficulty in penetrating the aneurysm sac, especially when the angle of penetration is not favorable, caution should be taken in order to avoid abrupt release of energy accumulated in the system, which may have disastrous consequences, especially with small or ruptured cerebral aneurysms.



**Figure 2.** Crossing a deployed stent with a microcatheter. *A*, A stent is deployed, bridging the aneurysm neck. *B*, A microcatheter is introduced into the aneurysm sac through the stent struts allowing treatment with coils. *C*, Final result, after removal of the microcatheter.

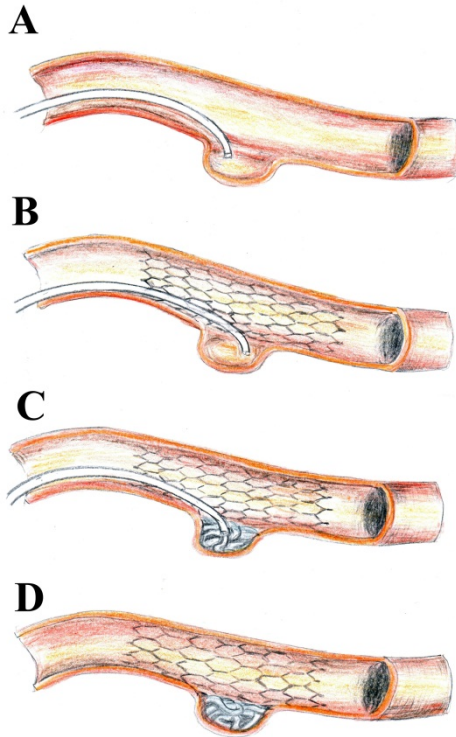
### 7.3. 'Jailing' technique

The technique of placement of the microcatheter tip inside the aneurysm before deployment of the stent has the advantages of being technically easier and being less susceptible to microcatheter kickback phenomena. However, when significant kickback occurs, it may be problematic to regain access to the aneurysm sac. Some authors argue that the previous deployment of coil loops before stent placement may be useful. The previously deployed coil may be used as a guidewire and allow reintroduction of the microcatheter in case of early kickback (Kim et al., 2011).

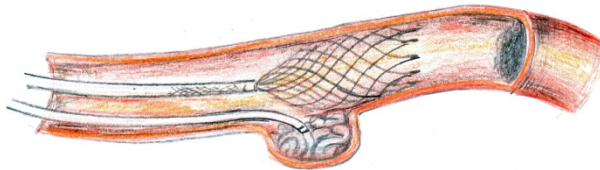
### 7.4. 'Semi-jailing' technique

In this technique, a stent is partially deployed in front of the aneurysm neck to act as a remodeling device. For this, the operator chooses a retrievable device such as Solitaire AB or Enterprise (retrievable if the proximal end intermediate marker of the delivery wire is not beyond the distal microcatheter markerband). This technique presents several advantages: the possibility to regain access to the aneurysm sac in case of kickback by a slight repositioning of the stent; the absence of blood flow arrest as observed with balloon-

remodeling techniques; the possibility to chose to either retrieve or definitely deploy the stent after coiling; and the possibility of not using double antiplatelet treatment if the stent is retrieved at the end of the procedure.



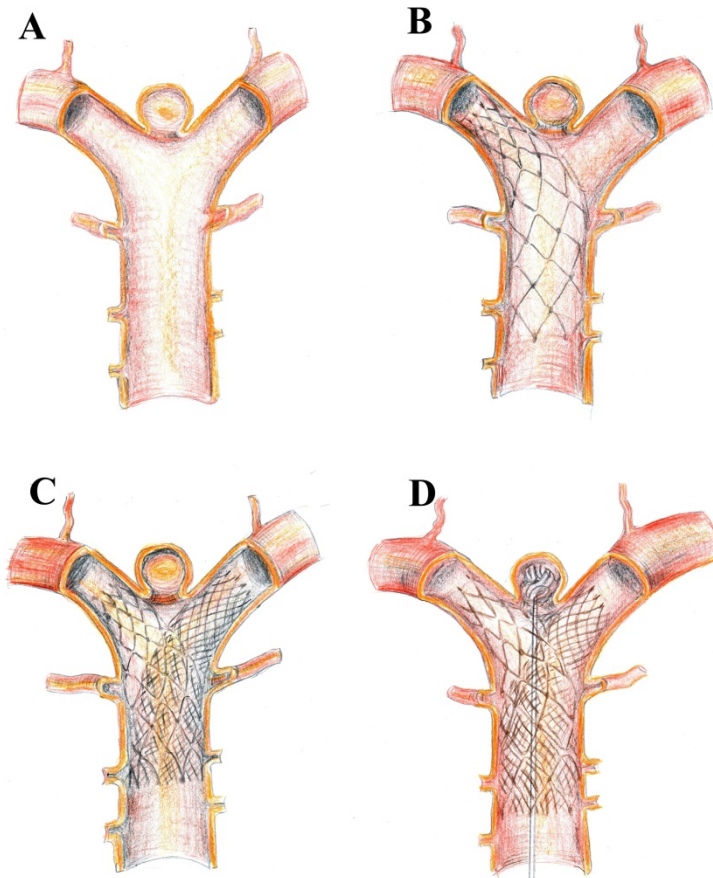
**Figure 3.** The 'jailing technique'. *A*, A microcatheter is positioned inside the aneurysm. *B*, The stent is deployed. *C*, The aneurysm is treated with coils. *D*, Final result.



**Figure 4.** The 'semi-jailing' technique with a partially deployed stent.

### 7.5. 'Y' and 'X' stenting

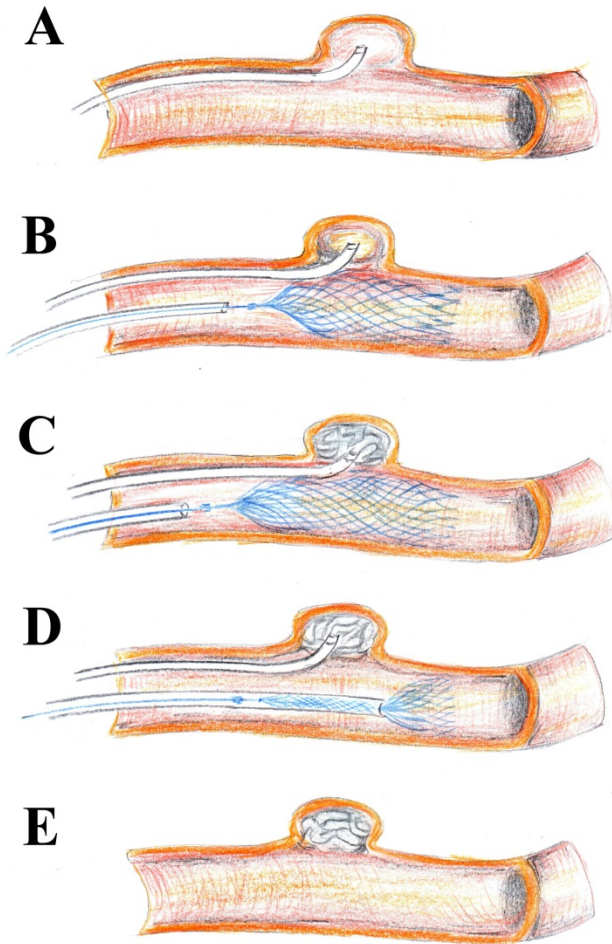
If one stent is not able to adequately protect the parent artery or a bifurcation branch, a possible solution is the deployment of two devices in a 'Y' configuration. A first stent is deployed in one of the branches, preferably an open-cell device. A microcatheter is then navigated into the other branch and a second stent is released. Another possibility is to place both stents in a parallel configuration, without crossing the first one. For confluent vessels such as in the anterior communicating territory, crossing stents are also possible, what has been called an 'X' configuration (Kim et al., 2011).



**Figure 5.** The 'Y' Stent Technique. *A*, A basilar tip aneurysm. *B*, An open-cell stent is deployed into the basilar artery and right posterior cerebral artery, but is not sufficient to provide adequate protection against coil herniation or migration. *C*, A second (closed-cell) stent is placed in the basilar artery (concentric to the first stent) and left posterior cerebral artery. *D*, A microcatheter is positioned inside the aneurysm sac, which is treated with coils.

**7.6. Temporary stenting (Solitaire AB™)**

Similar to the 'semi-jailing' technique, temporary stenting consists of using a stent as a remodeling device, with full retrieval of the device at the end of the procedure. Up to date, only stents from the Solitaire group may be retrieved after full deployment. It is worth noting that with this kind of stent (but not exclusive to this brand) the use of a dynamic push in the delivery wire increases notoriously the apposition to the vascular walls, an effect that is important to remember when using this device as a remodeling tool.



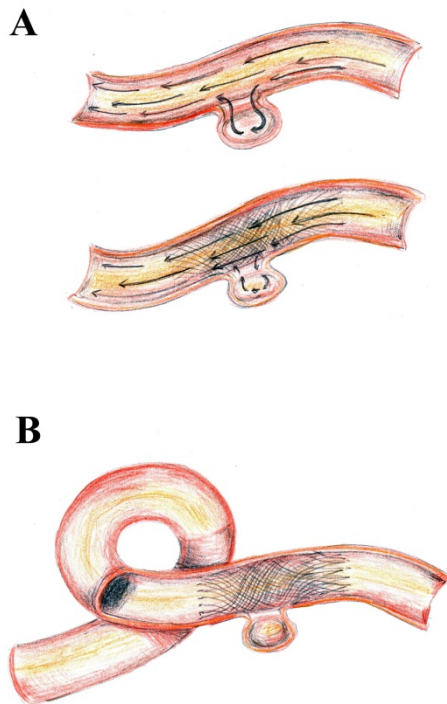
**Figure 6.** Temporary stenting with a Solitaire AB device. *A*, The microcatheter is positioned inside the aneurysm. *B*, The microcatheter is 'jailed' in the aneurysm by the Solitaire AB stent, which is completely deployed but not detached. *C*, The aneurysm is treated with coils. *D*, The Solitaire AB device is retrieved. *E*, Final result, no stent is left in the parent vessel.



## 7.7. Flow diversion

Even though a large part of the deployment steps are common for the majority of intracranial stents, the technique for flow diverters differs in some details that make the method more challenging. The operator must work within a technique of pushing the delivery microguidewire forward, of pulling the microcatheter back, and pushing the entire system so that the stent opening and apposition are optimal. In addition, the phenomenon of shortening after deployment must be taken into consideration for the adequate selection of the stent length.

For the Pipeline Embolization Device, adequate pushing on the microcatheter is also important to release the distal extremity of the device from the capture coil that keeps it attached to the delivery microguidewire. In addition, forward pushing may increase mesh density, and accounts for the customization that is possible with this type of device. With an adequate push at the right site, one may deploy a PED with an increased metal-to-artery coverage at the aneurysm neck.

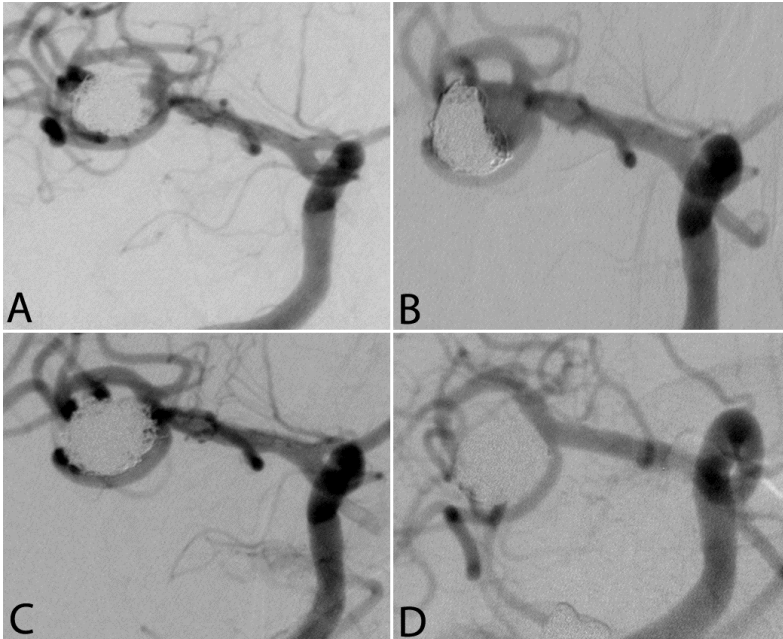


**Figure 7.** Treatment of a cerebral aneurysm using flow diversion with a Pipeline Embolization Device. *A*, Aspect of blood flow before and after placement of the device. *B*, Final result with thrombosis of the aneurysm. Note the higher density of the mesh near the aneurysm neck, which can be obtained with proper deployment technique.

## 8. Results

The morphological results on immediate and late post-operative angiograms are categorized according to the revised Raymond classification into 1 of the following groups: complete occlusion, neck remnant, and residual aneurysm. Follow-up examinations with Digital Subtraction Angriography or Magnetic Resonance Angiograms are then scheduled at minimum intervals of 6, 18 and 36 months. In cases of early recanalization, a DSA would be preferred in order to properly assess the need for retreatment.

The rates of complete occlusion differ significantly from the results observed on the immediate postoperative angiogram after stent-assisted coiling. In a recent study on the Neuroform Stent in our institution, we observed that the percentage of complete occlusion tends to stabilize after six months. However, progressive thrombosis and subsequent increase of the degree of aneurysm occlusion between the immediate postoperative and six-month angiograms are observed in roughly 50% of the aneurysms treated with stent-assisted techniques (Maldonado et al., 2010). Of 76 aneurysms studied, 31.6% were completely occluded in the initial embolization, 63.8 at six months and 64.7% at 18 months. However, in three years of follow-up, six aneurysms with an initial complete occlusion and five with a neck remnant recanalized. The analysis by type of coil did not demonstrate any association between complete occlusion and coil type.



**Figure 8.** Endovascular treatment of a repermeabilized aneurysm of the right middle cerebral artery using the Neuroform Stent System. *A*, after initial embolization; *B*, repermeabilization seven months later; *C*, after re-treatment using a Neuroform stent and a 'jailing' technique; *D*, angiographic control 14 months after retreatment, showing adequate reconstruction and re-endothelization of the bifurcation zone.

Stents may contribute to the progression of thrombosis, independent to the size of the aneurysm and type of coils used. Fiorella et al (Fiorella et al., 2005) reported an improvement of anatomic results with progressive thrombosis in 52% of cases of patients treated with the Neuroform stent. Lubicz et al (Lubicz et al., 2009) observed progressive thrombosis in 53% of aneurysms coiled with MicroPlex bare coils or GDCs using the Leo stent.

The overall complete occlusion rate obtained with stent-assisted coiling seems superior to results obtained with coils alone or other adjunctive devices in cases of large or complex aneurysms. Sedat et al (Sedat et al., 2009) documented 9.5% of aneurysmal regrowth at a mean follow-up of 42 months.

## 9. Complications

Recent case series report incidences of adverse events ranging from 8.4 to 18.9%. Risk factors for complications are age, presence of significant atherosclerotic disease, subarachnoid hemorrhage, small aneurysm and large/giant aneurysm. The most common of those adverse events in the peri-operative phase are navigation problems, stent misplacement, stent migration, vessel dissection or perforation, and thromboembolic events.

Delayed stroke due to intrastent thrombosis or intrastent stenosis are less frequent but may be observed, especially in patients with irregular use of antiplatelets. In a recent study published by the authors on 76 aneurysms treated with a Neuroform Stent-assisted technique, a five-month delayed symptomatic stroke and three clinically silent in-stent stenosis were observed.

There is currently significant concern about the risk of delayed rupture after flow-diversion treatment. The exact mechanism of this adverse event is not completely understood. There are two main hypotheses for this phenomenon. First, the mural thrombus may act as a source of inflammatory substances such as proteases leading to chemical degradation and weakening of the aneurysm wall. Second, flow diversion may induce changes in intra-aneurysmal flow pattern with a consequent increase in stress to areas that were not previously exposed. In a series of recent international cases of rupture after flow diversion, the following risk factors seemed to be important (Kulcsar et al., 2010):

- Large or giant aneurysm;
- Symptomatic aneurysm;
- Saccular aneurysm with AR>1.6;
- Morphologic characteristics predisposing to an inertia-driven inflow.

## 10. Post-operative management

During the procedure, patients are anticoagulated with a bolus of standard heparin (70–100 IU/kg) followed by an intravenous drip through an automated syringe (40–60 IU/kg/h) to maintain an activated clotting time of 250 seconds, which may be continued for 12–24 hours. At the end of the procedure, they receive an IV dose of 250–500 mg of ASA unless they are

already using oral Aspirine. A daily dose of clopidogrel (75 mg) and ASA (75 mg) is then administered for two or three months. After that period, only one of those antiplatelet agents is continued, for a period of time that has varied in literature from three months to indefinitely.

## Author details

Igor Lima Maldonado  
*Universidade Federal da Bahia, Brazil*

Alain Bonafé  
*Université Montpellier 1, France*

## 11. Acknowledgement

We would like to express our thanks to Mr José Alberto Maldonado Via for his assistance with the illustrations.

## 12. References

- Breet N. J., van Werkum J. W., Bouman H. J., Kelder J. C., Ruven H. J., Bal E. T., Deneer V. H., Harmsze A. M., van der Heyden J. A., Rensing B. J., Suttorp M. J., Hackeng C. M. & ten Berg J. M. (2010). Comparison of platelet function tests in predicting clinical outcome in patients undergoing coronary stent implantation. *JAMA*, Vol. 303, No. 8, pp. 754-62.
- Chan A. W., Yadav J. S., Krieger D. & Abou-Chebl A. (2004). Endovascular repair of carotid artery aneurysm with Jostent covered stent: initial experience and one-year result. *Catheter Cardiovasc Interv*, Vol. 63, No. 1, pp. 15-20.
- Fessler R., Ringer A., Qureshi A., Guterman L. & Hopkins L. (2000). Intracranial stent placement to trap an extruded coil during endovascular aneurysm treatment: Technical note. *Neurosurgery*, Vol. 46, No., pp. 248-251.
- Fiorella D., Albuquerque F. C., Deshmukh V. R. & McDougall C. G. (2005). Usefulness of the Neuroform stent for the treatment of cerebral aneurysms: results at initial (3-6-mo) follow-up. *Neurosurgery*, Vol. 56, No. 6, pp. 1191-201; discussion 1201-2.
- Higashida R., Halbach V., Dowd C., Juravsky L. & Meagher S. (2005). Initial clinical experience with a new self-expanding nitinol stent for the treatment of intracranial cerebral aneurysms: The Cordis Enterprise stent. *American Journal of Neuroradiology*, Vol. 26, No., pp. 1751-1756.
- Kim B. M., Kim D. J. & Kim D. I. (2011). Stent application for the treatment of cerebral aneurysms. *Neurointervention*, Vol. 6, No. 2, pp. 53-70.
- Kulcsar Z., Houdart E., Bonafe A., Parker G., Millar J., Goddard A. J., Renowden S., Gal G., Turowski B., Mitchell K., Gray F., Rodriguez M., van den Berg R., Gruber A., Desal H., Wanke I. & Rufenacht D. A. (2010). Intra-Aneurysmal Thrombosis as a Possible Cause of Delayed Aneurysm Rupture after Flow-Diversion Treatment. *AJNR Am J Neuroradiol*, Vol., No., pp.

- Lavine S., Larsen D., Giannotta S. & Teitelbaum G. (2000). Parent vessel Guglielmi detachable coil herniation during wide-necked aneurysm embolization: Treatment with intracranial stent placement: Two technical case reports. *Neurosurgery*, Vol. 46, No., pp. 1013-1017.
- Lavine S. D. & Meyers P. M. (2007). Application of new techniques and technologies: stenting for cerebral aneurysm. *Clin Neurosurg*, Vol. 54, No., pp. 64-9.
- Lee D. H., Arat A., Morsi H., Shaltoni H., Harris J. R. & Mawad M. E. (2008). Dual antiplatelet therapy monitoring for neurointerventional procedures using a point-of-care platelet function test: a single-center experience. *AJNR Am J Neuroradiol*, Vol. 29, No. 7, pp. 1389-94.
- Lubicz B., Bandeira A., Bruneau M., Dewindt A., Balériaux D. & De Witte O. (2009). Stenting is improving and stabilizing anatomical results of coiled intracranial aneurysms. *Neuroradiology*, Vol. 51, No., pp. 419-25.
- Maldonado I. L., Machi P., Costalat V., Mura T. & Bonafé A. (2010). Neuroform Stent - Assisted Coiling of Unruptured Intracranial Aneurysms: Short- and Midterm Results from a Single-Center Experience with 68 Patients. *American Journal of Neuroradiology*, Vol. 32, No., pp. 131-136.
- Mehta B., Burke T., Kole M., Bydon A., Seyfried D. & Malik G. (2003). Stent-within-a-stent technique for the treatment of dissecting vertebral artery aneurysms. *AJNR Am J Neuroradiol*, Vol. 24, No. 9, pp. 1814-8.
- Morizane A., Sakai N., Nagata I., Nakahara I., Sakai H. & Kikuchi H. (2000). [Combined endovascular stent implantation and coil embolization for the treatment of a vertebro-basilar fusiform aneurysm: technical case report]. *No Shinkei Geka*, Vol. 28, No. 9, pp. 811-6.
- Muller-Schunk S., Linn J., Peters N., Spannagl M., Deisenberg M., Bruckmann H. & Mayer T. E. (2008). Monitoring of clopidogrel-related platelet inhibition: correlation of nonresponse with clinical outcome in supra-aortic stenting. *AJNR Am J Neuroradiol*, Vol. 29, No. 4, pp. 786-91.
- Neubauer H., Kaiser A. F., Endres H. G., Kruger J. C., Engelhardt A., Lask S., Pepinghege F., Kusber A. & Mugge A. (2011). Tailored antiplatelet therapy can overcome clopidogrel and aspirin resistance--the BOchum CLopidogrel and Aspirin Plan (BOCLA-Plan) to improve antiplatelet therapy. *BMC Med*, Vol. 9, No., pp. 3.
- Pandya D. J., Fitzsimmons B. F., Wolfe T. J., Hussain S. I., Lynch J. R., Ortega-Gutierrez S. & Zaidat O. O. (2008). Measurement of antiplatelet inhibition during neurointerventional procedures: the effect of antithrombotic duration and loading dose. *J Neuroimaging*, Vol. 20, No. 1, pp. 64-9.
- Pero G., Denegri F., Valvassori L., Boccardi E. & Scialfa G. (2006). Treatment of a middle cerebral artery giant aneurysm using a covered stent. Case report. *J Neurosurg*, Vol. 104, No. 6, pp. 965-8.
- Pierot L. (2011). Flow diverter stents in the treatment of intracranial aneurysms: Where are we? *J Neuroradiol*, Vol. 38, No. 1, pp. 40-6.

- Prabhakaran S., Wells K. R., Lee V. H., Flaherty C. A. & Lopes D. K. (2008). Prevalence and risk factors for aspirin and clopidogrel resistance in cerebrovascular stenting. *AJNR Am J Neuroradiol*, Vol. 29, No. 2, pp. 281-5.
- Saatci I., Cekirge H. S., Ozturk M. H., Arat A., Ergungor F., Sekerci Z., Senveli E., Er U., Turkoglu S., Ozcan O. E. & Ozgen T. (2004). Treatment of internal carotid artery aneurysms with a covered stent: experience in 24 patients with mid-term follow-up results. *AJNR Am J Neuroradiol*, Vol. 25, No. 10, pp. 1742-9.
- Sedat J., Chau Y., Mondot L., Vargas J., Szapiro J. & Lonjon M. (2009). Endovascular occlusion of intracranial wide-necked aneurysms with stenting (Neuroform) and coiling: mid-term and long-term results. *Neuroradiology*, Vol. 51, No. 6, pp. 401-9.
- Wang C., Xie X., You C., Zhang C., Cheng M., He M., Sun H. & Mao B. (2009). Placement of covered stents for the treatment of direct carotid cavernous fistulas. *AJNR Am J Neuroradiol*, Vol. 30, No. 7, pp. 1342-6.
- Wanke I. & Forsting M. (2008). Stents for intracranial wide-necked aneurysms: more than mechanical protection. *Neuroradiology*, Vol. 50, No. 12, pp. 991-8.