
False Aneurysms

Igor Banzić, Lazar Davidović, Oliver Radmili,
Igor Končar, Nikola Ilić and Miroslav Marković

Additional information is available at the end of the chapter

<http://dx.doi.org/10.5772/48656>

1. Introduction

Although great strides have been made in vascular and endovascular surgery in last decade, still remains challenge to resolve problems with false aneurysm or pseudoaneurysm. This problem is especially connected to sites that are managing vascular patients mostly with open surgical treatment.

2. Definition

All aneurysms can be classified by location, size, shape and etiology. However, there is always significant confusion about what a false aneurysm or pseudoaneurysm is. True aneurysm presents with all three layers of arterial wall. Pseudoaneurysm or false aneurysm occurs as result of blood flow outside the normal layers of the arterial wall. Basically blood is going through the hole in the wall of artery into contained space outside. That blood is compressed by surrounding tissue so it finally reenters the artery during the cardiac cycle. Repeating this process, false aneurysm (outside the artery) begins to grow.

False aneurysm could be caused by trauma, infections, iatrogenic or every kind of conditions that could promote focal weakness within the arterial wall.

3. False traumatic aneurysms (FTA)

The management of FTA of arteries has a long history. One of the earliest texts known, the Ebers Papyrus (2000 BC), contains a description of FTA of the peripheral arteries [1]. During the second century AD; Antyllus treated FTA by applying a ligature above and below the lesion, incising the aneurysmal sac, and extracting the clot. In 1873 Pick provided an interesting and detailed account on his management of an FTA of a large femoral artery by digital compression, which had an unsatisfactory final result [1]. The first reported FTA repair was by Matas in 1888. He

operated on a young male patient with a large FTA of the brachial artery that had developed after multiple gunshots [2]. After ligation of the main proximal and distal arteries, he opened the aneurysm sac and sutured all collaterals with back-bleeding. Fifteen years later, Matas described this procedure as a reconstructive endoaneurysmorrhaphy [3]. Vojislav Soubbotich, a Serbian surgeon treated 60 FTA and 17 traumatic arteriovenous fistulas (TAVF) during the Balkan wars between 1912 and 1913. He performed some of the reconstructive procedures in 32 cases [4]. Rich published an interesting article titled, "Matas Soubottich Connection." He said that Soubbotich's technique and results had been outrun 40 years later, during the Korean conflict [5].

4. Incidence

It is difficult to determine the true incidence of FTA. Some series combine iatrogenic with traumatic lesions. During World War II Elkin and Shumacker noted that there were 558 (22.58%) FTA and TAVF among the total 2471 vascular injuries [6]. According to Hughes and Jahnke's data, 215 cases of TAVF and FTA were described during the Korean conflict [7]. The largest series of surgically treated combat-related vascular injuries of about 1000 cases was published by Rich after the Vietnam war. They included 558 (incidence 55.8%) TAVF and FTA [8]. The first large civilian series of traumatic AVF and false aneurysms were published by Pattman et al. in 1964 [9], and Hewitt et al. in 1973 [10]. The incidence of TAVF and FTA was 2.3% (6/256) in the first study and 6.8% (14/206) in the second. According to experience of Davidović et al, is not that low. The incidence of TAVF and FTA, which included 140 cases, was 17.85%, and in civilian study with 273 cases it was 21.24% [11].

The most frequent cause of penetrating wounds during wars, as under civilian conditions, are bullets (figure 1) and fragments from various exploding devices (figure 2). In civilian experience, FTA and TAVF result from stab wounds as well [12]. FTA can also be caused by secondary damage, followed by pathologic moving of a bone fracture after penetrating and blunt trauma. In Davidović et al study, most of the FTA (superficial femoral 23.4% and popliteal 19.15%) were found at vessels near long bones (figure 3 and 4) [13]. Blunt trauma without associated bone fracture can also result in FTA and [14-16] (figure 5).

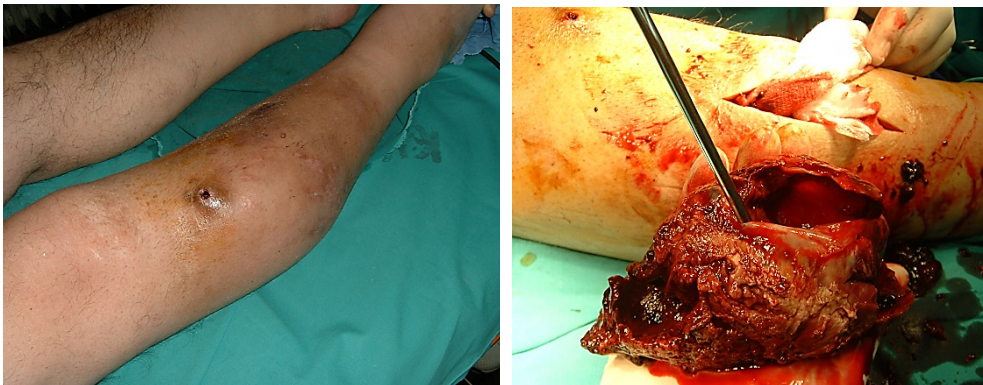

Figure 1. FTA after gun-shut injury

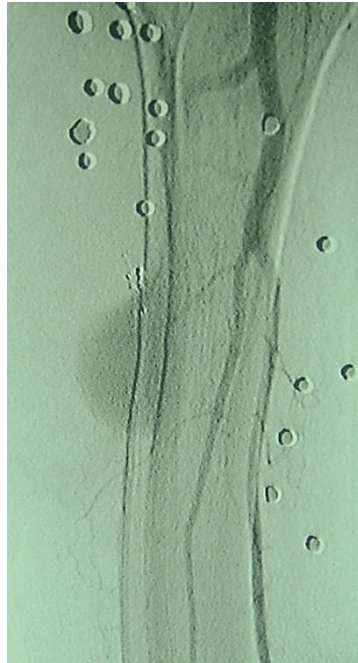


Figure 2. FTA and multifragments in right limb

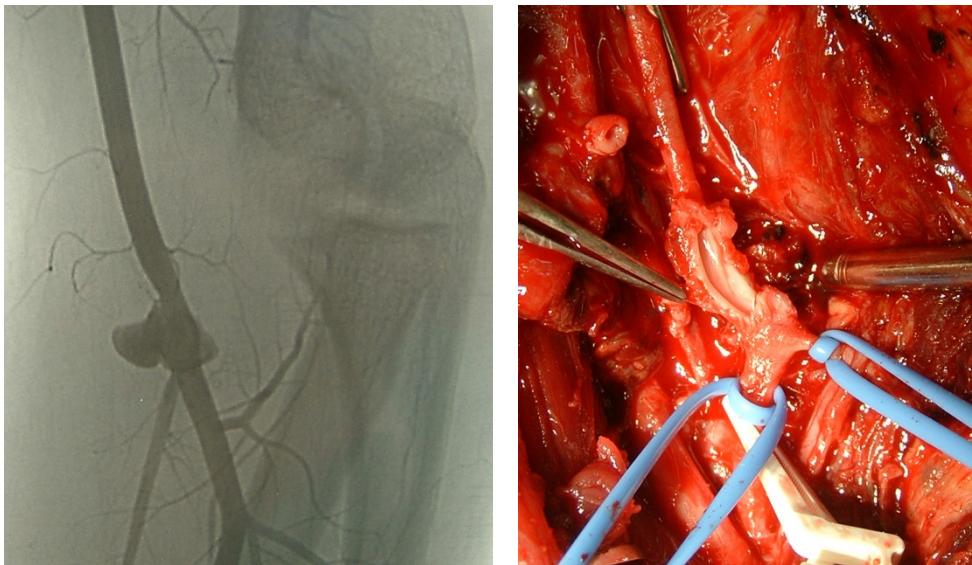


Figure 3. False traumatic aneurysm of the left-side brachial artery developed after a stab injury, which was accidental, job-related, and self-inflicted. a Angiography. b Intraoperatively, a laceration is apparent on the front wall of the brachial artery

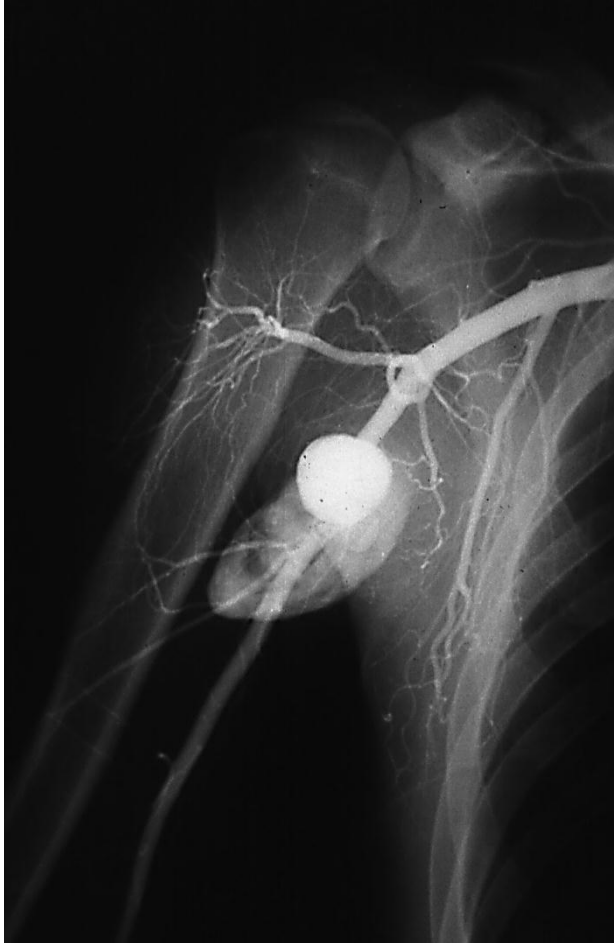


Figure 4. False traumatic aneurysm of the right-side axillary artery developed as the result of a gunshot injury

Lesions of the intrathoracic segment of the supraortic branches can be often fatal. Formation of an FTA is not uncommon [17,18]. In 1968, Vollmar and Krumhaar described two such cases among 200 FTA, while Beall et al [19], Rich et al. [5], and Davidović et al [13] found only one such case (figure 6). In the most important war studies published between 1946 and 1975, all carotid arteries (common, external, internal) were involved in 3.8–20.5% of cases [6-8,20]. The incidence of all carotid arteries (common, external, internal) being involved, according to two of the most important civilian studies published during the same period, was 14.3–18% [10,12,13,21] (figure 6, 7 and 8).

In all of these studies FTA were mainly associated with lower extremity vessel (46.0–69.46%).^{6-13, 20}

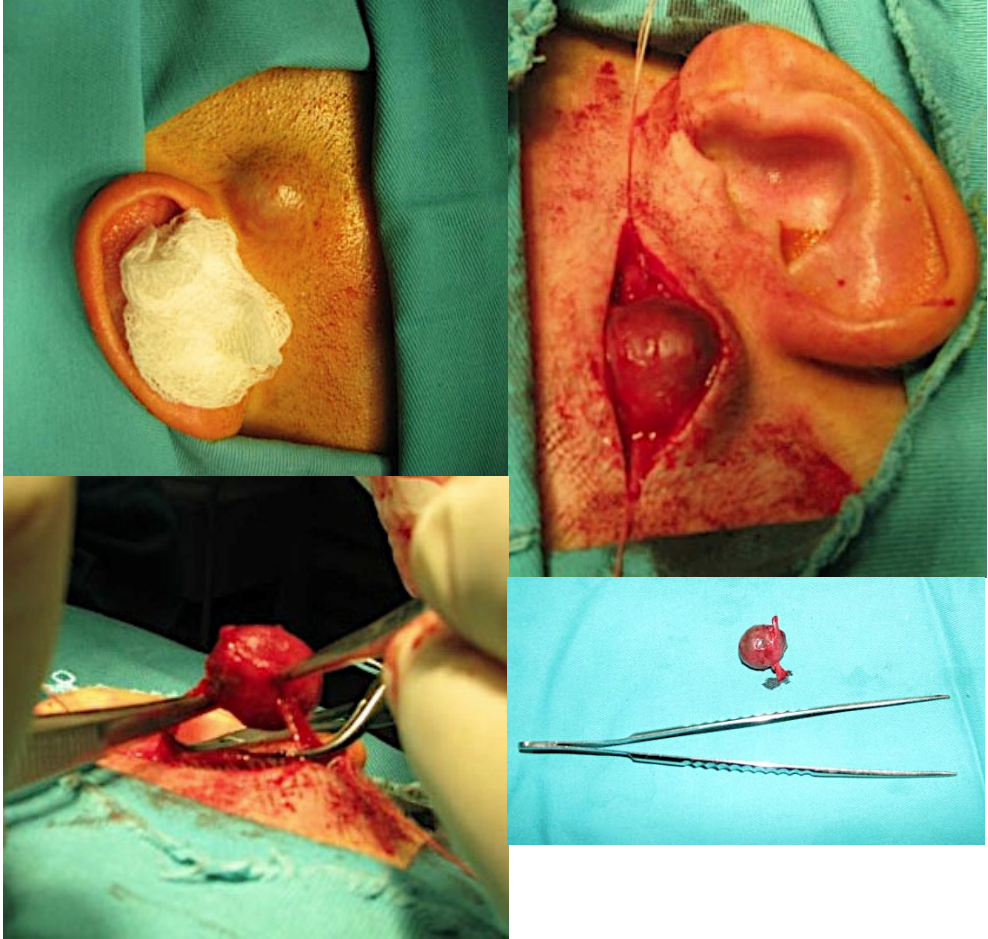


Figure 5. FTA of temporal artery after blunt injury

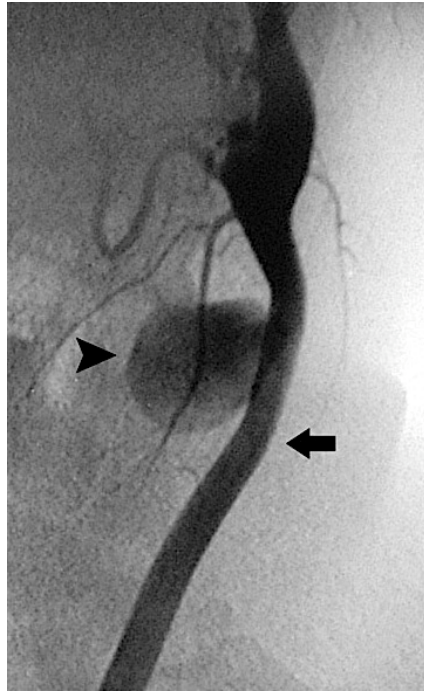


Figure 6. False traumatic aneurysm (arrowhead) of the left common carotid artery (arrow) developed after blunt trauma

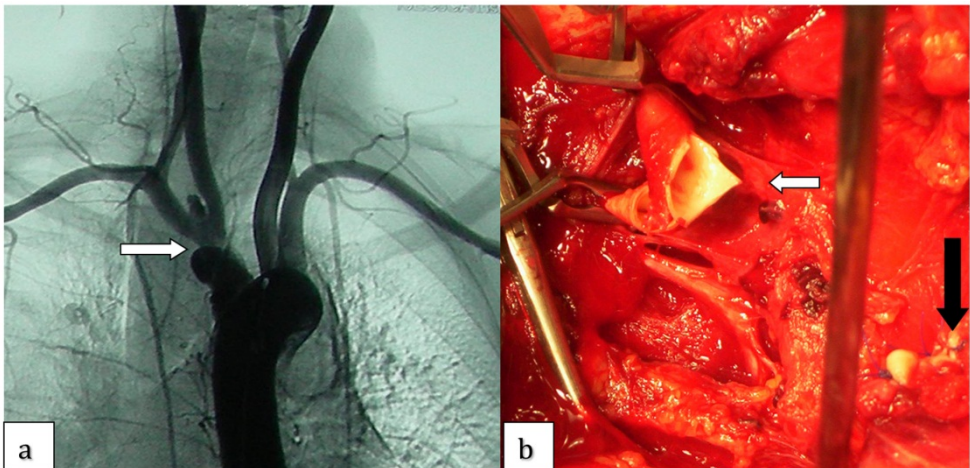


Figure 7. a Angiography reveals a false traumatic innominate artery aneurysm (arrow) that developed after chest blunt trauma during a car accident. b Note the right common carotid artery (white arrow) and the closed proximal end of the innominate artery (black arrow)

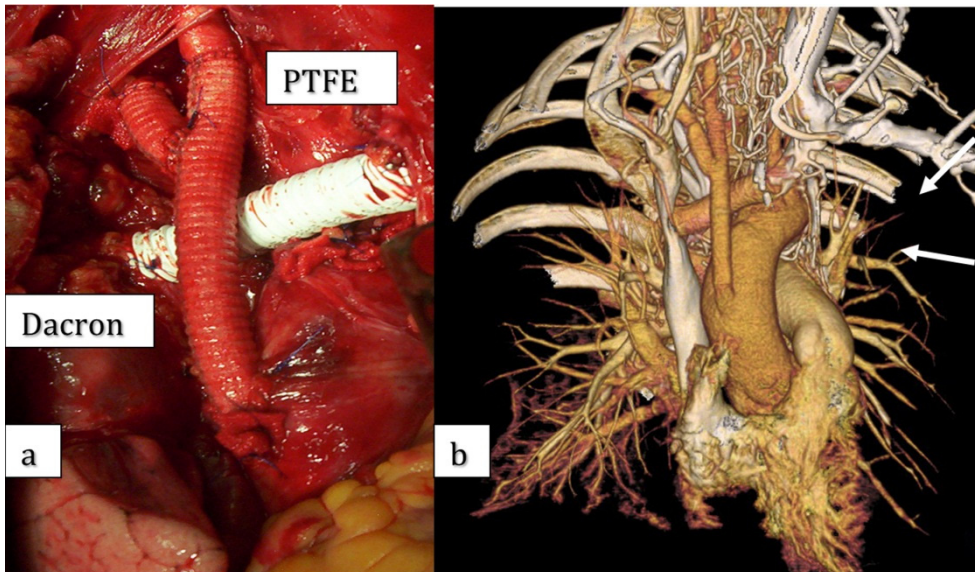


Figure 8. a Dacron bypass graft from the ascending aorta to the right common carotid and right subclavian artery. An 8-mm ringed polytetrafluoroethylene (PTFE) graft has been used to repair the injured left brachiocephalic vein. b MSCT performed 1 month later showed that both Dacron and PTFE grafts are patent

5. Diagnostic

The diagnosis of FTA is not difficult when the “hard signs” are present [22-24]. The problem is finding a way to recognize these signs and avoid failing to recognize FTA when the clinical picture is not typical [25]. Angiography has still very important roll as method of diagnostic, appropriate surgical approach as well as the type of vascular repair. Sophisticated diagnostic procedures, such as computed tomography, are extremely useful in cases of complex FTA.

6. Natural history and treatment

Natural history of FTA could be distal embolization (figure 9), rupture (figure 10), neurogenic compression or venous (figure 11) and cardiac failure. These lesions require prompt treatment. The treatment is relatively simple if the interval between injury and operation is not long [8,14,25-31]. Primary arterial repair without grafting is usually not feasible in late-presenting cases owing to the chronic nature of the FTA and the presence of fibrosis and inflammation. In the case of a small aneurysm, resection and primary end-to-end repair can be the safest alternative, although some advocate graft interposition [32]. The material of choice for repair is autologous saphenous vein [8,26,28-32]. The use of synthetic grafts is not recommended during the early phase because of infection. Synthetic grafts should be used only for a chronic FTA that involves large arteries (e.g., common femoral, subclavian).

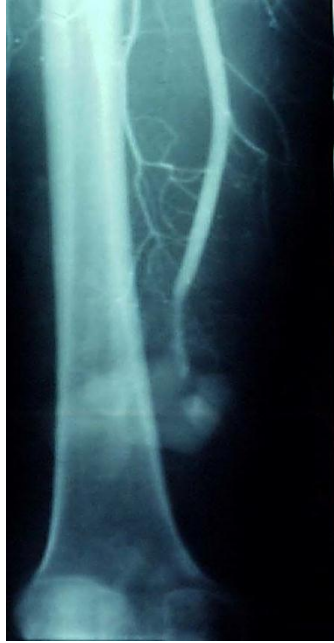

Figure 9. Embolization FAA and severe right foot ischemia after femoropopliteal reconstruction

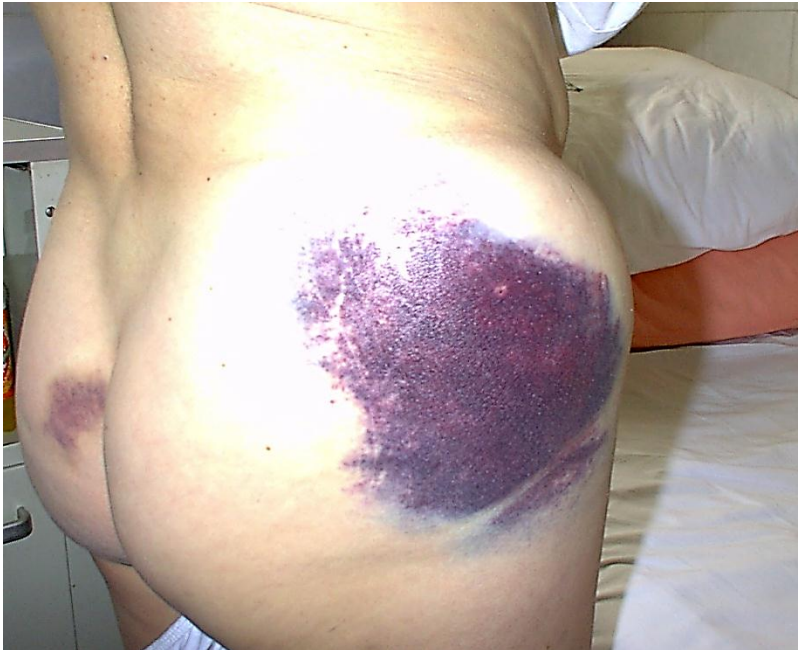

Figure 10. Rare case of ruptured FTA after blunt injury in right gluteal reg.

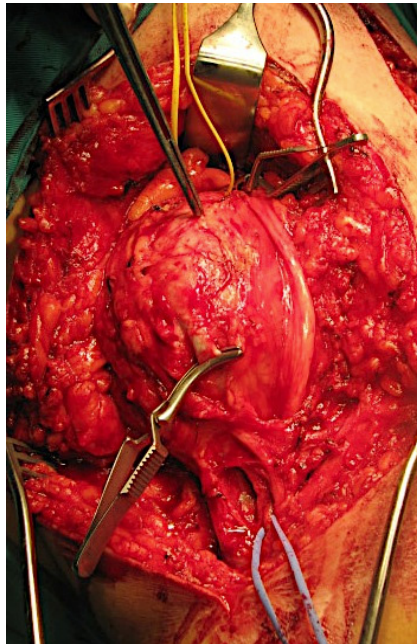
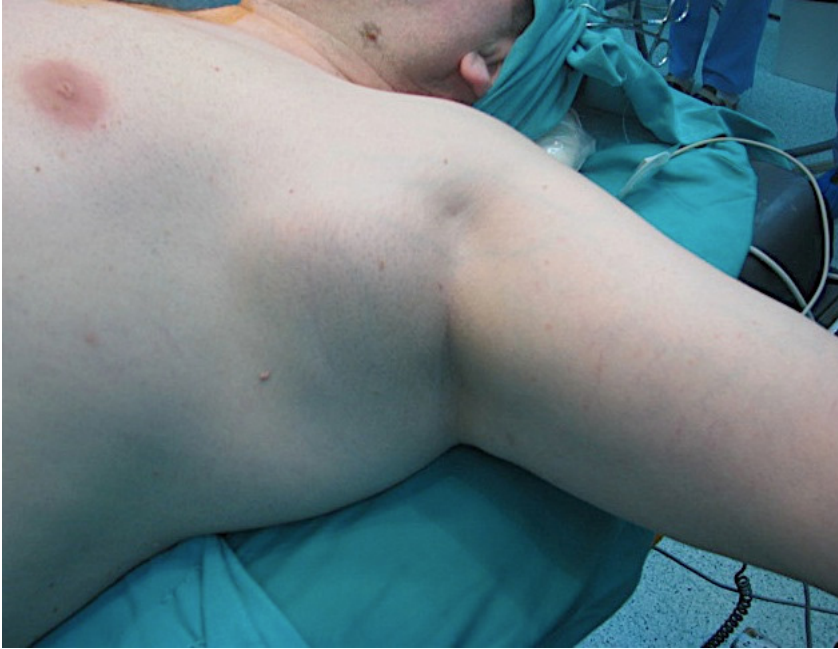

Figure 11. FTA of left axillar artery; neurogenic and venous compression

According to some, endovascular procedures can be important in the management of critically injured patients, as well as those with chronic FTA [33-43]. Endovascular repair of a peripheral FTA seems attractive because it theoretically results in less morbidity and shorter hospitalization [33]. However, this experience is still limited, especially in young patients. There is also skepticism regarding the use of stents in the popliteal artery. The reason is the mobility of the knee joint. Because of their history of numerous complications, FTAs require prompt treatment. The treatment is simpler if there is not an extended interval between the injury and the operation. Endovascular repair is mostly indicated in locations where a surgical approach is not easily attained.

7. False anastomotic aneurysms (FAA)

Most common false aneurysm belongs to group of anastomotic aneurysms and they present clinical challenges in detection, evaluation, and treatment. The incidence is approximately between 1.4% and 4% [44]. Claytor and associates, in 1956, reported the first case of anastomotic aneurysm in a patient after prosthetic aortic graft placement [45].

In 1978, Wesolowski outlined these common causes of FAA [46]:

1. Suture material
2. Prosthesis defects in manufacture
3. Arterial changes
4. Other factors

Although silk was used as a suture material for anastomosis (prior to 1967), the most frequent cause of FAA was breaking of the suture material [47-54]. Introduction of synthetic polyfilament suture materials has significantly decreased this cause. Also, the prosthesis defects in manufacture have long ceased to be the cause of the FAA. A whole range of arterial wall changes could lead to the formation of an FAA: infection arterial degeneration, aseptic necrosis of the suture line, extensive endarterectomy, and large "patch" or anastomosis, according to the Laplace rule [53-63]. A mechanical stress in the anastomotic area was the most important cause from the group of "other" factors. Movements in the hip area creating this kind of stress are recognized as the reason for the most frequent occurrence of FAA in the inguinal area after aortobifemoral reconstruction [49,55,62,64,65]. Growth of tissue created between the graft and the inguinal ligament prevents the graft from "sliding" over the ligament when a hip movement is performed [49]. For this reason, the FAA often develops after aortofemoral reconstruction but rarely develops after axillofemoral, femorofemoral, or femoropopliteal reconstruction. Szilagyi and colleagues believed this is the reason for the FAAs that manifest later [53]. In his discussion of the Stoney and Albo study [47], Baker suggested that anastomosis in the femoral region must be covered by a mobilized sartorius muscle to decrease stress. Mechanical stress caused by insufficient graft length [50] or configuration of end-to-side anastomosis [47,56,66] and the mechanical stress caused by an extensive mismatch, occurring if the prosthesis is too rigid, are also described. With every pulse wave, the anastomotic part of the artery is dilated at least 10% more than the prosthesis. Given that this difference increases with the size of

mismatch, the least resistant structures (suture material, artery, prosthesis) could be broken [57,67-70]. These pathogenic mechanisms are more likely to happen on an end-to-side than on an end-to-end anastomosis [66-71]. At first sight, it is normal to expect that FAAs develop more often after the reconstructive procedures performed owing to aneurysmal and not occlusive diseases. In other words, it could be expected that aneurysmal degeneration can enhance FAA development. However, there are not many studies on that.

There are some systemic factors which are thought to contribute to anastamotic aneurysm formation: smoking, hypertension, hyperlipidemia, anticoagulation, systemic vasculitides and generalized arterial weakness [72,73].

8. Incidence

According to the literature, FAAs most often develop in the inguinal area [74-78]. They can develop after the aortofemoral or infrainguinal bypass (figure 13, 14 and 15). They develop in 14 to 44% of inguinal anastomoses [57,63,68,79], although the cumulative risk in clinically significant FAAs is probably less than 10% [80-84]. Inguinal FAA development is clearly a matter of time for the risk increases with the age of the patient and the graft. The literature cites the following frequency of FAA after the aortofemoral bypass operation: 0.4% [85], 1.4% [86], 2% [87], 3.2% [88], 3.3% [89], 3.9% after 17 years of monitoring [53], 4% [90], 4.7% [91], 7% [92], 3.88% [93], and 4.3 [94]%. Cintora and colleagues stated that the FAA incidence in the aortobifemoral position is 4% if a Dacron graft is used and just 1% if a PTFE graft is used, all types taken into account [95]. If the publishing dates are analyzed, the number of FAAs was larger at an early age owing to the poorer quality of the prosthesis and suture material. Data in table 1. show changes in interval of inguinal FAA development through time [96].

<i>Period</i>	<i>Time Interval (mo)</i>
Before 1975	36–48 [53,100]
1976–1980	37–73 [52,70,78,88]
1981–1990	72–92 [49,83,99]
After 1990	111 [99]

Table 1. Time Intervals of the Appearance of False Anastomotic Aneurysm

The main reason for this is the improvement in surgical technique and better quality of prosthetic and suture material. Also, it takes longer for the other etiopathogenetic factors, with the exception of the infections, to develop. Some literature data cite the fact that partial section of the inguinal ligament and enlargement of the tunnel in which the prosthesis lies, combined with free omental wrapping of the entire suture line, decrease the incidence of FAA [80].

Aortic FAAs are rare [77,97-99], and with the total number of operations in mind, their incidence of occurrence ranges from 2 to 10% [68-71]. They are believed to be more frequent after emergency procedures. Also, they are much more frequent after end-to-side than after end-to-end anastomosis [77] (figure 16) Owing to the development of surgical procedures, the occurrence of aortic FAAs has decreased to less than 1% [99]. With the lack of symptoms,

it is difficult to diagnose aortic FAA. They are often detected during the evaluation of other abdominal diseases and conditions. Sometimes patients can notice the existence of a pulsatile abdominal mass, back pain, or weight loss [97,98]. Unfortunately, many aortic FAAs present only with acute expansion, rupture, gastrointestinal bleeding, infection, or distal embolism [94,95,97]. They are, in that manner, similar to abdominal aortic aneurysms.

The incidence of anastomotic aneurysm after carotid endarterectomy (with or without patch angioplasty) is approximately 0.3% [100]. They are most commonly associated with prosthetic infection [101].

9. Natural history and treatment

The disease development course of FAA, as well as that of any other aneurysm in general, can be complicated by a rupture (figure 12), compression, thrombosis, neurogenic compression and distal embolism [53,59,77,78,102,104,105]. Demarche and colleagues describe their experience with 142 femoral anastomotic aneurysms [106]. 64% were presented as an asymptomatic pulsatile mass, 19% presented with acute limb ischemia, 9% presented as a painful groin mass, 7% presented with acute hemorrhage, two patients (1%) presented with distal microemboli and limb edema. Infection was presented in 7% of all anastomotic aneurysms. Other series report similar presentations [107-109].

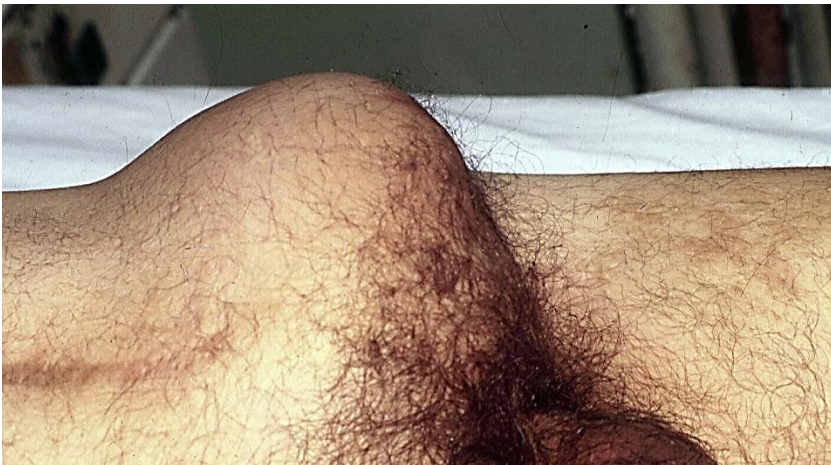

Figure 12. Ruptured FAA in left groin

Sometimes it is very difficult to prove that infection is the cause of an FAA. Keeping in mind that an intraoperative culture and blood culture can often have a false-negative result, the surgeon has to rely on intraoperative findings. Perigraft infiltration or fluid and the absence of graft incorporation in the surrounding tissue could be the only signs of graft infection. Laboratory parameters such as CRP level and white blood cell count can help us make a decision. In cases characterized by the absence of infection, there is a choice in FAA treatment between the methods of complete or partial resection and graft interposition or

bypass procedure [58,92,94,96,105]. In case of an infection as the cause of the FAA, only two treatment options are considered: "in situ" repair with a homoarterial graft and EAR [67,110]. Incidence of infection as a cause of FAA can be an underestimation considering the existence of low-virulence pathogens and false-negative intraoperative culture examinations. On the other hand, Edwards and colleagues found in their 45-month follow-up study that only 5.5% had FAA as a symptom of late graft infection [63]. Reinfection after 30 postoperative days appeared in one patient (4.8%).

Other than standard surgical approach, there have been cases in the literature recently in which FAA was treated by an endovascular placed graft [111]. Using this method in cases of FAA in the groin, problems can be caused by kinking and thrombosis of the implanted stent graft. It is hoped that very soon technology development will resolve this problem and provide a fast, safe, and less invasive procedure with better results. Several authors have published recent series on successful endovascular treatment of anastomotic aneurysms (table 2).

Series	Year	Number of Patients	Location	Technique	Adjunctive Procedure	Infected	Results (%)				Mean Follow-up (mo)
							Technical Success	Major Complications	30-Day Mortality	Patency	
Yuan et al. ^[112]	1997	12	A/I	Covered stent	No	No	100	17	0	100%	16
Curti et al. ^[113]	2001	11	I	Covered stent	No	Yes	100	0	0	100%	28
Magnan et al. ^[114]	2003	10	A	Covered stent	Yes	No	100	10	0	90%	17.7
Faries et al. ^[115]	2003	33	A/I	Covered stent	Yes	No	100	11	0	—	—
Gawenda et al. ^[116]	2003	10	A/I	Covered stent	Yes	No	100	0	10	100%	—
van Herwaarden et al. ^[117]	2004	8	A/I	Covered stent	No	No	100	20	0	88%	12
Derom and Nout ^[118]	2005	7	F	Covered stent	No	No	100	0	0	100%	18.6
Mitchell et al. ^[119]	2007	10	A/I	Covered stent	Yes	No	100	10	0	—	—
Di Tommaso et al. ^[120]	2007	6	A	Covered stent	Yes	No	100	0	0	100%	26.1
Lagana et al. ^[121]	2007	30	A/I	Covered stent	Yes	No	100	0	3	91%	19.7
Piffaretti et al. ^[122]	2007	22	A/I	Covered stent	Yes	No	100	5	0	96%	16
Sachdev ^[123]	2007	65	A/I	Covered stent	Yes	Yes	98	9	3.80	94%	18.1

A, aortic; F, femoral; I, iliac.

Table 2. (Taken from Rutherford's Vascular Surgery, 7th ed. -- *Endovascular Management of Anastomotic Aneurysms*)

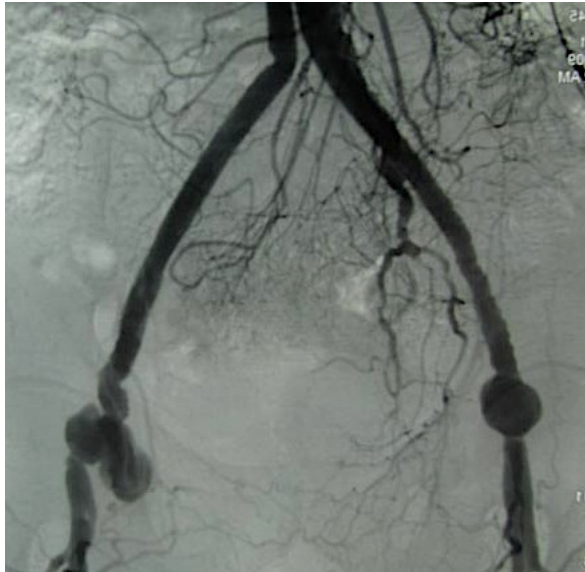


Figure 13. Angiography; False anastomotic aneurysms in both groins

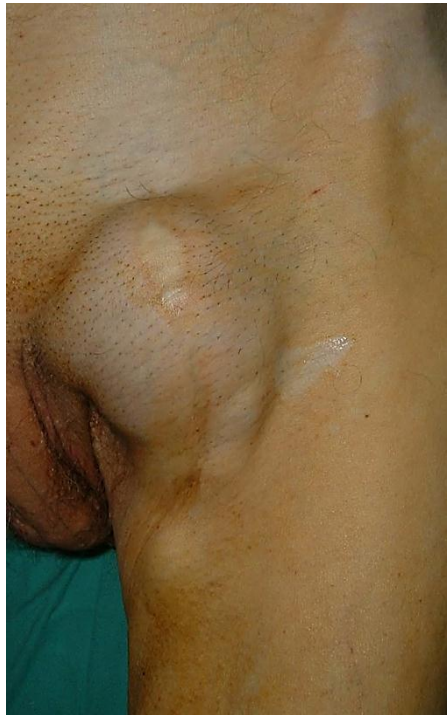

Figure 14. FAA in left groin after femoropopliteal reconstruction

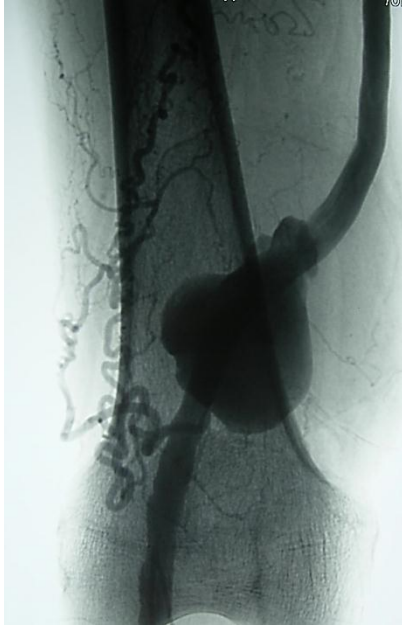

Figure 15. FAA in distal anastomosis after femoropopliteal reconstruction

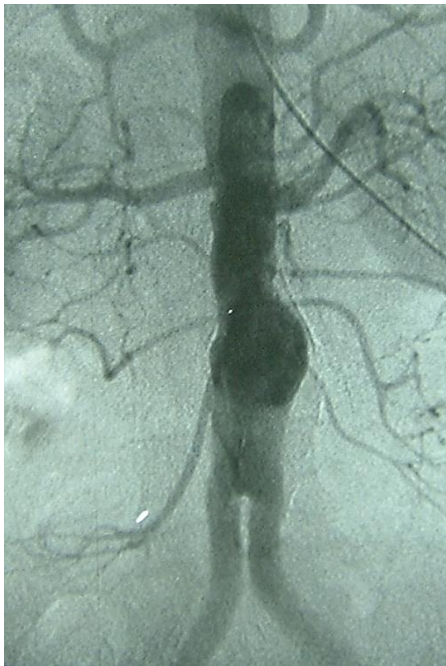

Figure 16. FAA after aortobifemoral reconstruction with end to side proximal anastomosis

Author details

Igor Banžića, Lazar Davidovića, Oliver Radmilia,
Igor Končara, Nikola Ilić and Miroslav Marković
Clinic for Vascular and Endovascular Surgery, Clinical Center of Serbia, Belgrade, Serbia
Medical Faculty, University of Belgrade, Serbia

10. References

- [1] Schwartz AM (1958) The historical development of methods of hemostasis. *Surgery* 44:604
- [2] Matas R (1888) Traumatic aneurysm of left brachial artery. *Med News* 53:462
- [3] Matas R (1909) Aneurysms. In: Keen WW, Da Costa JC (eds) *Surgery: its principles and practice*, vol 5. Saunders, Philadelphia, pp 266–268
- [4] Soubbotich V (1913) Military experiences of traumatic aneurysms. *Lancet* 2:720–721
- [5] Rich NM, Clagett GP, Salander JM et al (1983) The Matas/ Soubbotitch connection. *Surgery* 93:17–19
- [6] Elkin DC, Schumacker HB Jr (1955) Arterial aneurysms and arteriovenous fistula: general considerations. In: Elkin DC, De Bakey ME (eds) *Surgery in World War II. Vascular surgery*. Office of the Surgeon General, Department of the Army, Washington, DC, pp 149–180
- [7] Hughes CW, Jahnke EJ Jr (1958) The surgery of traumatic arteriovenous fistulas and aneurysms: a five year follow up study of 215 lesions. *Ann Surg* 148:790–797
- [8] Rich NM, Hobson RW, Collins GJ Jr (1975) Traumatic arterio- venous fistulas and false aneurysms: a review of 558 lesions. *Surgery* 78:817–828
- [9] Pattman RD, Poulos E, Shires GT (1964) The management of civilian arterial injuries. *Surg Gynecol Obstet* 118:725–738
- [10] Hewitt RL, Smith AD, Drapanas T (1973) Acute traumatic arteriovenous fistulas. *J Trauma* 13:901–906
- [11] Davidovic LB, Cinara IS, Ille T et al (2005) Civil and war peripheral arterial trauma: review of risk factors associated with limb loss. *Vascular* 13:141–147
- [12] Roobs JV, Carrim AA, Kadwa AM et al (1994) Traumatic arte- riovenous fistula: experience with 202 patients. *Br J Surg* 81:1296
- [13] Davidovic LB, Banžić I, Rich N, Dragaš M, Cvetkovic SD, Dimic A. False traumatic aneurysms and arteriovenous fistulas: retrospective analysis. *World J Surg.* 2011 Jun;35(6):1378-86.
- [14] Megalopoulos A, Siminas S, Trelopoulos G (2007) Traumatic pseudo aneurysm of the popliteal artery after blunt trauma: case report and a review of the literature. *Vasc Endovasc Surg* 1:499–504 17.
- [15] Gillespie DL, Cantelmo NL (1991) Traumatic popliteal artery pseudo aneurysms: case report and review of the literature. *J Trauma* 31:412–415 18.
- [16] Rosenbloom MS, Fellows BA (1989) Chronic pseudo aneurysm of the popliteal artery after blunt trauma. *J Vasc Surg* 10:187–189

- [17] Matas R (1902) Traumatic arteriovenous aneurysms of the subclavian vessels, with an analytical study of fifteen reported cases, including one operated upon. *JAMA* 38:103–20.
- [18] Gallen J, Wiss DA, Cantelmo N et al (1984) Traumatic pseudo-aneurysm of the axillary artery: report of three cases and literature review. *J Trauma* 24:350–354
- [19] Beall AC Jr, Harrington OB, Crawford ES et al (1963) Surgical management of traumatic arteriovenous aneurysms. *Am J Surg* 106:610–618
- [20] Vollmar J, Krumhaar D (1968) Surgical experience with 200 traumatic arteriovenous fistulae. In: Hierton T, Rybeck B (eds) *Traumatic arterial lesions*. Forsvarets Forskningsanstalt, Stockholm
- [21] Yetkin U, Gurbuz A (2003) Investigation of post-traumatic pseudo aneurysm of the brachial artery and its surgical treatment. *Tex Heart Inst J* 30:293–297
- [22] Woodlark JD, Reddy DS, Robs JV (2003) Delayed presentation of traumatic popliteal artery pseudo aneurysms: a review of seven cases. *Eur J Vasc Endovasc Surg* 23:255–25930.
- [23] Pritchard DA, Maloney JD, Barnhorst DA et al (1977) Traumatic popliteal arteriovenous fistula: diagnostic methods and surgical management. *Arch Surg* 112:849–85231.
- [24] La ¨dermann A, Stern R, Bettschart V et al (2008) Delayed post-traumatic pseudoaneurysm of the anterior tibial artery mimicking a malignant tumor. *Orthopedics* 31:500
- [25] Davidovic L, Lotina S, Vojnovic B et al (1997) Post-traumatic AV fistulas and pseudoaneurysms. *J Cardiovasc Surg* 38:645–651
- [26] Linder F (1985) Acquired arterio-venous fistulas: report of 223 operated cases. *Ann Chir Gynaecol* 74:1–27.
- [27] Hegarty MM, Angorn IB, Gollogly J et al (1975) Traumatic arterio-venous fistulae. *Injury* 7:20
- [28] Treiman L, Cohen L, Gaspard J et al (1971) Early repair of acute arteriovenous fistulas. *Arch Surg* 102:559–561
- [29] Kollmeyer R, Hunt L, Ellman A et al (1981) Acute and chronic traumatic arteriovenous fistulae in civilians. *Arch Surg* 116: 697–702
- [30] Folley J, Allen V, Janes M (1956) Surgical treatment of acquired arteriovenous fistulas. *Am J Surg* 91:611
- [31] Losev RZ, IuA Burov, Alimov VK et al (1994) The treatment of posttraumatic and true arterial aneurysms of the extremities. *Vestn Khir Im I Grek* 153:43–47
- [32] Darbari A, Tandon S, Chandra G et al (2006) Post-traumatic peripheral arterial pseudo aneurysms: our experience. *Indian J Thorac Cardiovasc Surg* 22:182–187
- [33] Marin ML, Veith FJ, Panetta TF et al (1994) Transluminally placed endovascular stented graft repair for arterial trauma. *J Vasc Surg* 20:466–472
- [34] Dorros G, Joseph G (1995) Closure of a popliteal arteriovenous fistula using an autologous vein-covered Palmaz stent. *J Endo- vasc Surg* 2:177–181
- [35] Uflacker R, Elliot BM (1996) Percutaneous endoluminal stent- graft repair of an old traumatic femoral arteriovenous fistula. *Cardiovasc Interv Radiol* 19:120

- [36] Criado E, Marston WA, Ligush J et al (1997) Endovascular repair of peripheral aneurysms, pseudoaneurysms, and arteriovenous fistulas. *AnnVascSurg* 11:256–263
- [37] Manns RA, Duffield RG (1997) Case report: intravascular stenting across a false aneurysm of the popliteal artery. *Clin Radiol* 52:151–153
- [38] Reber PU, Patel AG, Do DD et al (1999) Surgical implications of failed endovascular therapy for posttraumatic femoral arteriovenous fistula repair. *J Trauma* 46:352
- [39] Coldwell DM, Novak Z, Ryu RK et al (2000) Treatment of posttraumatic internal carotid arterial pseudoaneurysms with endovascular stents. *J Trauma* 48:470–472
- [40] Redekop G, Marotta T, Weill A (2001) Treatment of traumatic aneurysms and arteriovenous fistulas of the skull base by using endovascular stents. *J Neurosurg* 95:412–419
- [41] Assali AR, Sdringola S, Moustapha A et al (2001) Endovascular repair of traumatic pseudoaneurysm by uncovered self-expandable stenting with or without transstent coiling of the aneurysm cavity. *Catheter Cardiovasc Interv* 53:253–258
- [42] Ramsay DW, McAuliffe W (2003) Traumatic pseudoaneurysm and high flow arteriovenous fistula involving internal jugular vein and common carotid artery: treatment with covered stent and embolization. *Australas Radiol* 47:177–180
- [43] Self ML, Mangram A, Jefferson H et al (2004) Percutaneous stent-graft repair of a traumatic common carotid-internal jugular fistula and pseudoaneurysm in a patient with cervical spine fractures. *J Trauma* 57:1331–1334
- [44] Goldstone J: Anastomotic aneurysms. In: Bernard VM., Towne JB, ed. *Complications in Vascular Surgery*, St Louis, MO: Quality Medical Publishing; 1991.
- [45] Birch L, Cardwell ES, Claytor H, et al: Suture-line rupture of a nylon aortic bifurcation graft into small bowel. *AMA Arch Surg* 1954;73:947
- [46] Wesolowski AS. A plea for early recognition of late vascular prosthetic failure. *Surgery* 1978;84:575–6.
- [47] Stoney RJ, Albo EJ. False aneurysms occurring after arterial grafting operations. *Am J Surg* 1965;110:153–61.
- [48] Moore WS, Hall AD. Late suture failure in the pathogenesis of anastomotic false aneurysms. *Ann Surg* 1970;172:1064–8.
- [49] Read RC, Thompson BW. Uninfected anastomotic false aneurysms following arterial reconstruction with prosthetic grafts. *J Cardiovasc Surg* 1975;16:558–61.
- [50] Kim GE, Imparato AM, Nathan I, Riles TS. Dilatation of synthetic grafts and junctional aneurysms. *Arch Surg* 1979;114:1296–303.
- [51] Sawyers JL, Jacobs JK, Sutton JP. Peripheral anastomotic aneurysms. *Arch Surg* 1967;95:802–9.
- [52] Gaylis H. Pathogenesis of anastomotic aneurysms. *Surgery* 1981;90: 509–15.
- [53] Szilagyi DE, Smith RF, Elliot JP, et al. Anastomotic aneurysms after vascular reconstruction: problems of incidence, etiology and treatment. *Surgery* 1975;78:800–16.
- [54] Markovic DM, Davidović LB, Kostić DM, Maksimović ZL, Kuzmanović IB, Koncar IB, Cvetkovic DM. False anastomotic aneurysms. *Vascular*. 2007 May-Jun;15(3):141-8.
- [55] Watanabe T, Kusaba A, Kuma H, et al. Failure of Dacron arterial prostheses caused by structural defect. *J Cardiovasc Surg* 1983;24: 95–100.

- [56] Clark ET, Gewertz BL. Pseudoaneurysms. In: Rutherford RB, editor. *Vascular surgery*, 4th ed. Philadelphia: W.B. Saunders; 1995. p. 1153–61.
- [57] Gutman H, Zelinovski A, Reiss R. Ruptured anastomotic pseudo-aneurysms after prosthetic vascular graft bypass procedures. *J Med Sci* 1984;20:613–7.
- [58] Broyn T, Christensen O, Fossdal E, et al. Early complications with a new bovine arterial graft (Solcograft-P). *Acta Chir Scand* 1986; 152:263–6.
- [59] Seabrook GR, Schmitt DD, Bandyk DF, et al. Anastomotic femoral pseudoaneurysm: an investigation of occult infection as an etiologic factor. *J Vasc Surg* 1990;11:629–34.
- [60] Merrill EW, Salzam EW. Properties of material affecting the behavior of blood and their surfaces. In: Sawyer PN, Kaplitt MJ, editors. *Vascular graft*. New York: Appleton Century Crofts; 1978. p. 119–29.
- [61] Nunn DB, Freeman MH, Hudgins L. Postoperative alterations in size of Dacron aortic grafts: an ultrasonic evaluation. *Ann Surg* 1979;189:741–5.
- [62] Dubost C, Allary M, Olconomos N. Resection of an aneurysm of the abdominal aorta. Reestablishment of the continuity by a preserved human arterial graft with result after five months. *Arch Surg* 1952;64:405–8.
- [63] Edwards MJ, Richardson JD, Klammer TW. Management of aortic prosthetic infections. *Am J Surg* 1988;155:327–30.
- [64] Orringer MD, Rutherford RB, Skinner DB. An unusual complication of axillary femoral arterial bypass. *Surgery* 1972;72:769–71.
- [65] Dardik H, Ibrahim IM, Jarah M, et al. Synchronous aortofemoral or iliofemoral bypass with revascularization of the lower extremity. *Surg Gynecol Obstet* 1979;149:676–80.
- [66] Dadgar L, Downs AR, Deng X, et al. Longitudinal forces acting at side-to-end and end-to-side anastomoses when a knitted polyester arterial prosthesis is implanted in the dog. *J Invest Surg* 1995;8: 163–78.
- [67] Paasche RE, Kinly CE, Dolan FG, et al. Consideration of suture line stresses in the selection of synthetic grafts for implantation. *J Biomech* 1973;6:253–9.
- [68] Sieswerda C, Skotnicki SH, Barentz JO, Heystraten FMJ. Anastomotic aneurysms—an underdiagnosed complication after aorto-iliac reconstructions. *Eur J Vasc Surg* 1989;3:233–8.
- [69] McCann RL, Schwartz LB, Georgiade GS. Management of aortic graft complications. *Ann Surg* 1993;217:729–34.
- [70] Bastounis E, Georgopoulos S, Maltezos C, Balas P. The validity of current vascular imaging methods in the evaluation of aortic anastomotic aneurysms developing after abdominal aortic aneurysm repair. *Ann Vasc Surg* 1996;10:537–45.
- [71] Berger K, Sauvage LR. Late fiber deterioration in Dacron arterial grafts. *Ann Surg* 1981;193:477–91.
- [72] Alpogut U, Ugurlucan M, Daytoglu E: Major arterial involvement and review of Behçet's disease. *Ann Vasc Surg* 2007; 21:232.
- [73] Oderich GS, Panneton JM, Bower TC, et al: The spectrum, management and clinical outcome of Ehlers-Danlos syndrome type IV: a 30-year experience. *J Vasc Surg* 2005; 42:98.

- [74] Wandschneider D, Bull PH, Denck A. Anastomotic aneurysms— an insoluble problem. *Eur J Vasc Surg* 1988;2:115–9.
- [75] Knox GW. Aneurysm occurring in a femoral arterial Dacron prosthesis five and a half years after insertion. *Ann Surg* 1962;156: 827–30.
- [76] Giordanengo F, Pizzocari P, Rampoldi V, et al. Femoral non-infected anastomotic pseudoaneurysm. Clinical contribution. *Minerva Chir* 1992;1547:823–9.
- [77] Guinet C, Buy JN, Ghossain MA, et al. Aortic anastomotic pseudoaneurysms: US, CT, MR, and angiography. *J Comput Assist Tomogr* 1992;16:128–8.
- [78] Waibel P. False aneurysm after reconstruction for peripheral arterial occlusive disease. Observations over 15 to 25 years. *Vasa* 1994;23:43–51.
- [79] Shwartz LB, Clark ET, Gewertz BL. Anastomotic and other pseudoaneurysms. In: Rutherford RB, editor. *Vascular surgery*. 5th ed. Philadelphia: W.B. Saunders; 2000. p. 752–63.
- [80] Courbier R, Ferdani M, Jausseran JM, et al. The role of omentopexy in the prevention of femoral anastomotic aneurysm. *J Cardiovasc Surg* 1992;33:149–53.
- [81] Melliere D, Becquemin JP, Cervantes-Monteil F, et al. Recurrent femoral anastomotic false aneurysms: is long term repair possible? *Cardiovasc Surg* 1996;4:480–2.
- [82] Millili JJ, Lanes JS, Nemir P. A study of anastomotic aneurysms following aortofemoral prosthetic bypass. *Ann Surg* 1980;192:69–73
- [83] Ernst CB, Elliott JP Jr, Ryan CJ, et al. Recurrent femoral anastomotic aneurysms: a 30-year experience. *Ann Surg* 1988; 201:401–9.
- [84] Ernst CB. Anastomotic aneurysm. In: Ernst CB, Stanley JC, editors. *Current therapy in vascular surgery*. St. Louis: Mosby-Year Book; 1995. p. 415–9.
- [85] Poulia GE, Polemis L, Skoutas B, et al. Bilateral aorto-femoral bypass in the presence of aorto-iliac occlusive disease and factors determining result. *J Cardiovasc Surg* 1985;26:257–37.
- [86] Brewster DC, Darling DC. Optimal methods of aortoiliac reconstruction. *Surgery* 1978;84:739–47.
- [87] Malone JM, Moore WS, Goldstone J. Life expectancy following aortofemoral arterial grafting. *Surgery* 1977;81:551–5.
- [88] Nevelsteen A, Wouters L, Suy R. Long-term patency of the aortofemoral Dacron graft. A graft limb related study on a 25 year period. *J Cardiovasc Surg* 1991;32:174–80.
- [89] Gomes MR, Bernatz PE, Jurgens JL. Influence of clinical factors on results. *Arch Surg* 1967;95:387–94.
- [90] Martinez BD, Hertzner NR, Beven EG. Influence of distal arterial occlusive disease on prognosis following aortobifemoral bypass. *Surgery* 1973;74:519–23.
- [91] Crawford ES, Bomberger RA, Glaeser DH, et al. Aortoiliac occlusive disease: factors influencing survival and function following reconstructive operation over a twenty-five year period. *Surgery* 1981;90:1055–67.
- [92] Crawford ES, Manning LG, Kelly TF. “Redo” surgery after operations for aneurysm and occlusion of the abdominal aorta. *Surgery* 1977;81:41–52.

- [93] Davidovic' L. Comparison between bifurcated Dacron and PTFE grafts in aortobifemoral position [dissertation]. Belgrade: University of Belgrade School of Medicine; 1995.
- [94] Levi N, Schroeder TV. Anastomotic femoral aneurysms: is an increase in interval between primary operation and aneurysms formation related to a change in incidence? *Panminerva Med* 1998; 40:210-3.
- [95] Cintora I, Paero DE, Canon JA. A clinical survey of aortobifemoral bypass using two inherently different graft types. *Ann Surg* 1988; 208:625-30.
- [96] Levi N, Schroeder TV. Anastomotic femoral aneurysms: increase in interval between primary operation and aneurysm formation. *Eur J Vasc Endovasc Surg* 1996;11:207-9.
- [97] Gautier C, Borie H, Lagneau P. Aortic false aneurysms after prosthetic reconstruction of the infrarenal aorta. *Ann Vasc Surg* 1992;6:413-7.
- [98] Chen FZ, Xu X, Fu WG, Wu ZG. Anastomotic false aneurysm following abdominal aortic aneurysmectomy and prosthetic grafting. *Chin Med J (Engl)* 1994;107:832-5.
- [99] De Monti M, Ghilardi G, Sgroi G, Scorzo R. Proximal anastomotic pseudoaneurysms. *Minerva Cardioangiol* 1995;43:127-34.
- [100] Branch Jr CL, Davis Jr CH: False aneurysm complicating carotid endarterectomy. *Neurosurgery* 1986; 19:421.
- [101] Borazjani BH, Wilson SE, Fujitani RM, et al: Postoperative complications of carotid patching: pseudoaneurysm and infection. *Ann Vasc Surg* 2003; 17:156.
- [102] DeBakey ME, Crawford ES, Morris GC, Cooley LA. Patch graft angioplasty in vascular surgery. *J Cardiovasc Surg* 1963;3: 106-41.
- [103] Satiani B, Karmers M, Evans NE. Anastomotic arterial aneurysms. *Ann Surg* 1980;192:674-82.
- [104] Tridico F, Zan S, Panier Suffat P, et al. Femoral anastomotic pseudoaneurysms. The etiopathogenetic hypotheses and the therapy. *Minerva Chir* 1992;47:37-40.
- [105] Morbidelli A, Caron R, Caldana G, et al. Bilateral thrombosis of a femoral pseudoaneurysm. *Minerva Chir* 1995;50:1013-8.
- [106] Demarche M, Waltregny D, van Damme H, et al: Femoral anastomotic aneurysms: pathogenic factors, clinical presentations and treatment. A study of 142 cases. *Cardiovasc Surg* 1999; 7:315.
- [107] Schellack J, Salam A, Abouzeid MA, et al: Femoral anastomotic aneurysms: a continuing challenge. *J Vasc Surg* 1987; 6:308.
- [108] Youkey JR, Clagett GP, Rich NM, et al: Femoral anastomotic false aneurysms: an 11-year experience analyzed with a case control study. *Ann Surg* 1984; 199:703.
- [109] Argifoglio G, Costantini A, Lorenzi G, et al: Femoral noninfected anastomotic aneurysms.. *J Cardiovasc Surg* 1990; 31:453.
- [110] Mulder EJ, van Bockel JH, Maas J, et al. Morbidity and mortality of reconstructive surgery of noninfected false aneurysms detected long after aortic prosthetic reconstruction. *Arch Surg* 1998;133:45-9.
- [111] Dorros G, Jaff MR, Parikh A, et al. In vivo crushing of an aortic stent enables endovascular repair of a large infrarenal aortic pseudoaneurysm. *J Endovasc Surg* 1998;5:359-64.

- [112] Yuan JG, Marin ML, Veith FJ, et al: Endovascular grafts for noninfected aortoiliac anastomotic aneurysms. *J Vasc Surg* 1997; 26:210.
- [113] Curti T, Stella A, Rossi C, et al: Endovascular repair as first-choice treatment for anastomotic and true iliac aneurysms. *J Endovasc Ther* 2001; 8:139.
- [114] Magnan PE, Albertini JN, Bartoli JM, et al: Endovascular treatment of anastomotic false aneurysms of the abdominal aorta. *Ann Vasc Surg* 2003; 17:365.
- [115] Faries PL, Won J, Morrissey NJ, et al: Endovascular treatment of failed prior abdominal aortic aneurysm repair. *Ann Vasc Surg* 2003; 17:43.
- [116] Gawenda M, Zaehring M, Brunkwall J: Open versus endovascular repair of para-anastomotic aneurysms in patients who were morphological candidates for endovascular treatment. *J Endovasc Ther* 2003; 10:745.
- [117] Van Herwaarden JA, Waasdorp EJ, Bendermacher BLW, et al: Endovascular repair of paraanastomotic aneurysms after previous open aortic prosthetic reconstruction. *Ann Vasc Surg* 2004; 18:280.
- [118] Derom A, Nout E: Treatment of femoral pseudoaneurysms with endograft in high-risk patients. *Eur J Vasc Endovasc Surg* 2005; 30:644.
- [119] Mitchell JH, Dougherty KG, Strickman NE, et al. Endovascular repair of paraanastomotic aneurysms after aortic reconstruction. *Tex Heart Inst J*. 2007;34:148-153.
- [120] Di Tommaso L, Monaco M, Piscione F, et al. Endovascular stent grafts as a safe secondary option for para-anastomotic abdominal aortic aneurysm. *Eur J Vasc Endovasc Surg*. 2007;33:91-93.
- [121] Lagana D, Carrafiello G, Mangini M, et al: Endovascular treatment of anastomotic pseudoaneurysms after aorto-iliac surgical reconstruction. *Cardiovasc Intervent Radiol* 2007; 30:1185.
- [122] Piffaretti G, Tozzi M, Lomazzi C, et al: Endovascular treatment for para-anastomotic abdominal aortic and iliac aneurysms following aortic surgery.. *J Cardiovasc Surg* 2007; 48:711.
- [123] Sachdev U, Baril DT, Morrissey NJ, et al. Endovascular repair of para-anastomotic aortic aneurysms. *J Vasc Surg*. 2007;46:636.