

Dermatomyositis

Fred van Gelderen
*Radiology Department, Dunedin Hospital,
Southern District Health Board & Clinical Senior Lecturer,
University of Otago, Dunedin,
New Zealand*

1. Introduction

1.1 Dermatomyositis is an autoimmune inflammatory myopathy with diffuse nonsuppurative inflammation of the skin and striated muscles. [In polymyositis, skeletal muscles only are involved.]

1.2 The disease is uncommon, occurs twice as often in female patients, and most present between 40 and 60 years of age, with a smaller peak between the ages of 5 and 15. There is a two-to-seven fold increase in the frequency of malignancy, especially in older patients in the adult age group (about 21% for dermatomyositis and 15% for polymyositis) (Hansell, et al., 2005).

2. Clinical features

2.1 Nomenclature and classification

These different classifications are included:

2.1.1 Polymyositis and dermatomyositis (Hansell, et al., 2005)

- Primary idiopathic polymyositis
- Primary idiopathic dermatomyositis
- Amyopathic dermatomyositis
- Polymyositis/dermatomyositis associated with:
 - i. malignant disease
 - ii. other collagen vascular disease (overlap syndrome)
- Polymyositis/dermatomyositis of childhood

2.1.2 Inflammatory disease of muscle (Resnick & Kransdorf, 2005)

Idiopathic inflammatory myopathies:

- Polymyositis
- Dermatomyositis
- Juvenile (childhood) dermatomyositis

- Myositis associated with malignancy
- Inclusion body myositis

Other inflammatory myopathies:

- Myositis associated with eosinophilia
- Myositis ossificans
- Localized (focal) myositis
- Myopathies caused by infection
- Myopathies caused by drugs and toxins

2.1.3 Further classification (Resnick & Kransdorf, 2005)

Type I. Typical polymyositis (most common, 35% of patients)

Type II. Typical dermatomyositis (25% of patients)

Type III. Typical dermatomyositis with malignancy. (Malignancy occurs in 15-25%)

Type IV. Childhood dermatomyositis (20% of patients)

Type V. Acute myolysis (3% of patients)

Type VI. Polymyositis in Sjögren's syndrome and other connective tissue diseases (5%).

2.2.1 The most constant clinical finding is muscle weakness, the initial symptom in about 50% of patients. (Resnick & Kransdorf, 2005). Symmetric involvement of the proximal muscles is most characteristic. Clinical presentation may be with an acute, subacute or chronic illness, with progressive symmetric weakness of the girdle and neck muscles. In the acute form, muscle pain and tenderness are common features. Low grade fever and fatigue are further manifestations.

2.2.2 In children the acute form is more common with clinical features of fever, joint pain, lymphadenopathy, splenomegaly and subcutaneous oedema. The skin changes tend to be very severe, and prognosis is poor.

2.2.3 In adults the onset is often more insidious with periods of spontaneous remission. On relapse, skin changes are the first symptom in 25% of patients. These are more severe and more frequent in children. There are no skin changes in polymyositis, however, in dermatomyositis the changes are characteristic, with a heliotrope periorbital rash and violaceous/red papular rash over bony prominences.

2.2.4 In addition to the typical proximal muscle weakness and the skin rash, the raised muscle enzymes and characteristic electromyography and muscle biopsy, also contribute to characteristic clinical criteria.

2.2.5 Further clinical features include: Arthralgia and arthritis, with typical symmetrical involvement of the small joints of the fingers, the wrists and the knees. Permanent involvement is uncommon.

2.2.6.1 Visceral involvement due to dermatomyositis may include pharyngeal and oesophageal symptoms with dysphagia, pulmonary disease due to respiratory muscle weakness with aspiration pneumonia and/or interstitial lung disease. (Pulmonary

involvement occurs in 50% of patients and contributes directly to death in about 10% of patients.)

2.2.6.2 Other systemic involvement includes myocardial disease, pericarditis, renal, neurological and ocular abnormalities.

2.2.7 In addition to typical muscular involvement with bilateral symmetric superficial oedema and palpable sheetlike confluent calcifications, especially in the thigh muscles, there may also be pointing and resorption of the terminal tufts of the fingers with distal soft tissue loss. The 'floppy-thumb' sign has been described as a common feature (Resnick & Kransdorf, 2005).

2.2.8 The aforementioned clinical features may be readily diagnosed on physical examination of the patient.

2.3 After effective treatment for dermatomyositis, the soft tissue oedema may decrease or disappear altogether, though fibrosis, muscle atrophy and contractures may become apparent in the later stages of the disease. With constant aggressive prednisone treatment, the development of progressive muscular weakness, contractures and disabling calcifications occur in less than 20% of patients with childhood dermatomyositis (Hesla, et al, 1990).

2.4 Polymyositis/dermatomyositis may precede, accompany or follow malignant disease, though usually found within one year of diagnosis. The course of the myopathy often follows the course of the malignancy, improving when the malignancy is treated, and increasing with relapse, suggesting that it is a true paraneoplastic symptom (Hansell, et al., 2005). There is an increased prevalence of malignant neoplasms of the breast, prostate, lung, ovary, gastrointestinal tract and kidney (Dähnert, 2007).

2.5.1 Furthermore for many patients, the manifestations of the disease process are incompatible with a single diagnosis. These patients appear to have more than one collagen vascular disease, and the diagnosis of an overlap syndrome (mixed connective tissue disease) is suggested to correlate the diverse clinical, imaging and laboratory findings. As many as 85% of patients with connective tissue disease may be included in this category. The existence of this entity is not universally accepted (Resnick & Kransdorf, 2005).

2.5.2 The overlap syndrome includes features similar to dermatomyositis, scleroderma, lupus erythematosus and rheumatoid arthritis, although Sjögren's syndrome and polyarteritis nodosa could also be included.

2.6 There is no cure for dermatomyositis, but the symptoms can be treated. Options include medication (e.g. corticosteroids or immunoglobulins), physical treatment (e.g. removal of calcium deposits that may cause nerve pain and recurrent infections), exercise, heat treatment, orthotics and assisting devices, and rest.

2.7 Other inflammatory diseases of muscles (Resnick & Kransdorf, 2005) include

2.7.1 Inclusion body myositis, occurs more often in men older than 55 years, the clinical findings resemble those of polymyositis, but there are distinctive microscopic findings with inclusion bodies noted.

2.7.2 Focal nodular myositis is a benign inflammatory muscle disorder, mostly affecting the thigh or lower extremity, and patients present with a painful, localised intramuscular mass. The histology of the small nodules or pseudotumours is similar to polymyositis, and the disease may progress to a more generalised distribution typical of polymyositis.

2.7.3 Eosinophilic myositis may present with an eosinophilic inflammatory infiltrate in skeletal muscle as a localised disorder, or as a generalised disease.

2.7.4 Drug-related myositis may vary from acute inflammatory changes to chronic fibrosis, the latter may appear as a consequence of direct intramuscular injection of drugs in the deltoid or quadriceps muscles. Alcohol, aspirin, penicillin and sulphonamides may also lead to myopathic changes.

3. Case reports

Three cases are included to highlight diverse and protean manifestations, also to demonstrate specific radiological investigations, with more advanced and specific tests for dermatomyositis now being available at many larger centres.

3.1 Case 1

A 17-year-old teenager was known to have dermatomyositis, having been diagnosed in 1978 at age 13. He had been treated since that time with prednisone (corticosteroid), alas, with little improvement. In 1981 he was referred for chest and pelvis X-rays, with increasing weakness, atrophy and contractures of the upper extremities. He furthermore experienced loss of strength in his legs and neck. The patient had extensive skin changes consistent with dermatomyositis and in addition was very emaciated. No clinical history of tuberculosis was elicited. The PA (posteroanterior) chest X-ray (Fig. 1a) demonstrated minimal left basal areas of opacification due to active lung disease; infective, inflammatory or due to aspiration. Hairline thickness fibrotic changes were identified in the left upper lobe due to longstanding disease, probably previous tuberculosis.

In the left supraclavicular region, the skin was noted to be retracted with soft tissue loss, and a subtle 2 cm long thin linear calcification was detected. (Fig.1b, magnified image). This finding is most suggestive of dermatomyositis, whereas the pulmonary changes are non-specific. [These images predate readily available high-resolution CT (computed tomography) of the chest.]

An AP (anteroposterior) view of the pelvis (Fig. 1c) demonstrated minimal and subtle calcification of the inner upper thighs, however, the diagnosis of dermatomyositis with multiple coarse linear calcifications overlying the outer aspect of the left iliac bone was clinched by observing this latter feature. There was an undisplaced fracture of the medial part of the left superior pubic ramus; this observation was unrelated to the known dermatomyositis.

3.2 Case 2

A 41-year-old woman with known dermatomyositis for many years (though not known whether she had had dermatomyositis as a child) was referred for radiographs of the chest, hands and thighs. She presented with cellulitis/myositis of the posterior aspect of the left

thigh, with a possible abscess, despite 1 week of treatment with antibiotics. A shell of curvilinear calcification was noted around the chest on the PA chest radiograph (Fig. 2a). Predominant calcification was seen of the lateral chest wall, the axillary region and within the neck, superior and parallel to the first rib, with bilateral changes. Some tramline-like calcifications were detected overlying the peripheral midzones on both sides, thereby mimicking pleural or pulmonary parenchymal disease. However, these rather coarse calcifications were situated in the superficial soft tissue and superimposed on the lung fields. No bony abnormality was observed. No cardiac or pulmonary abnormalities were detected.

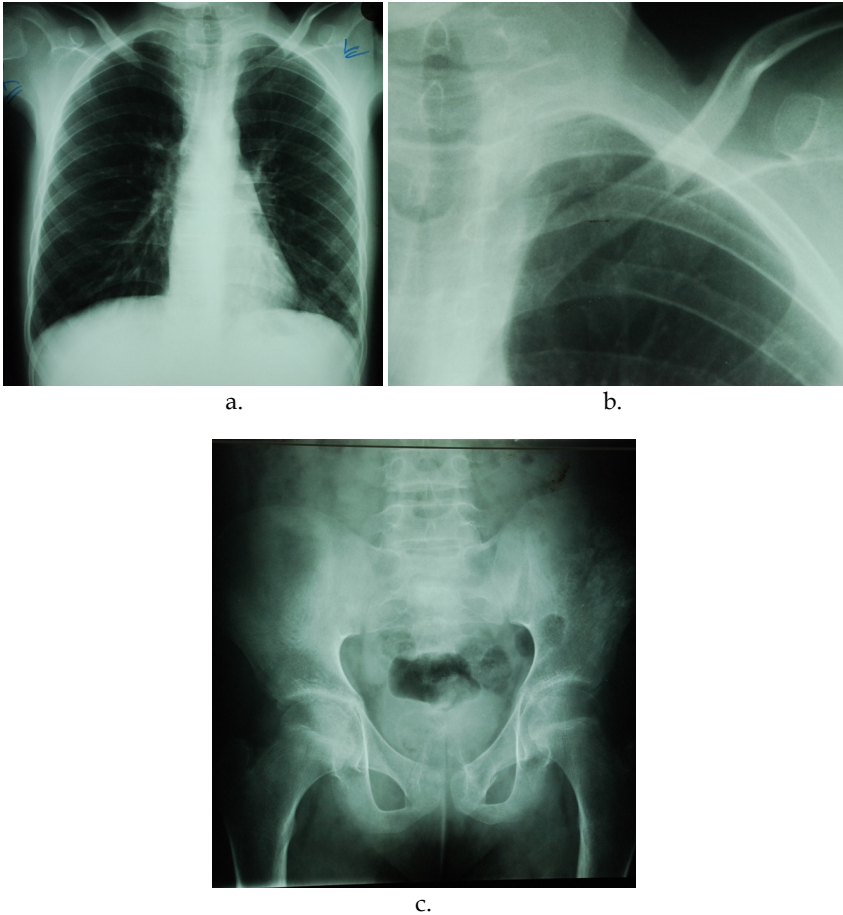


Fig. 1. a.,b.,c. Case 1. A 17-year-old teenager with known dermatomyositis was referred for chest and pelvis radiographs. There is slight left based patchy opacification. Furthermore there is a minimal linear calcification of the left side of the neck (Fig. 1a,b). (Fig. 1b is a magnified image to demonstrate the calcification). The AP pelvis X-ray demonstrates extensive linear plaque-like calcification overlying the outer aspect of the left iliac bone (Fig. 1c). The radiological features correlate exactly with the clinical diagnosis of dermatomyositis.

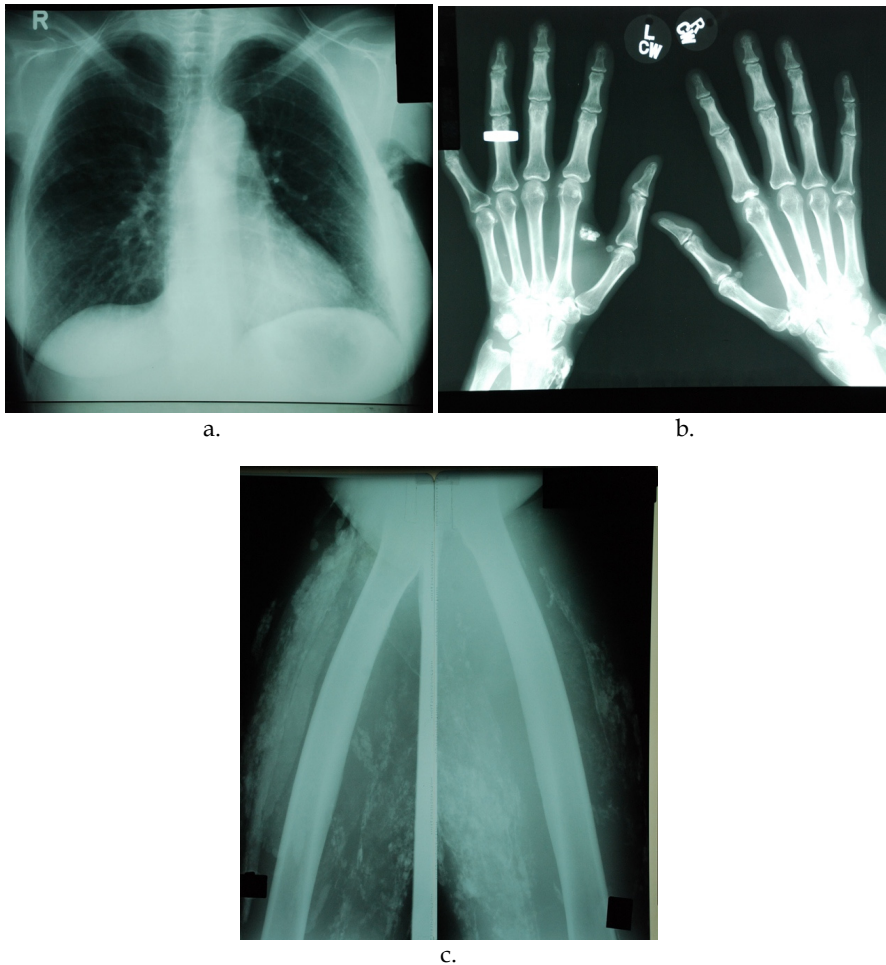


Fig. 2. a-c. Case 2. A 41-year-old woman with known clinical manifestations of dermatomyositis was referred for radiographs of the chest, hands, and thighs. Ultrasound of the thighs was also performed. The PA chest X-ray demonstrates a thick shell of plaque-like calcifications within the superficial soft tissue (Fig. 2a). The PA radiograph of the hands shows more discrete and dense calcific areas, and also soft tissue loss relating to the tips of some of the fingers (Fig. 2b). Radiography of the thighs reveals multiple dense calcified plaques involving the muscles of both thighs (Fig. 2c).

A PA radiograph of the hands (Fig. 2b) demonstrated a number of discrete, yet heavily calcified, foci in the soft tissue, involving both wrist areas (especially overlying the distal radius), intermetacarpal in position, and even more marked relating to the webspace between the left 1st and 2nd metacarpals. Juxtaarticular osteopaenia was noted, but no erosive articular changes were seen. Loss of soft tissue relating to the terminal tufts of the distal phalanges was detected, especially affecting the index fingers.

Layered dense plaques of calcification were observed relating to both thighs, both in the skin and in the deeper tissues, more extensive on the left posteriorly (Fig 2c). Ultrasound examination (US) of both thighs confirmed extensive subcutaneous and intermuscular plaque-like calcifications with marked shadowing from the superficial calcifications (Fig. 2d). Within the deeper tissues of the left thigh posteriorly, a flattened tubular, anechoic area was noted, with a long fluid level and high level echoes below the level (Fig. 2e). The hyperechoic material below the level was disturbed with transducer pressure. When the examination was subsequently continued in the erect position, a shorter fluid calcium level formed, along the short dimension of the collection.

The above features were reported as a fluid-calcium level because of the known dermatomyositis, but as the area was tender, a localized intermuscular abscess could not be excluded. Aspiration of the lesion yielded sterile, yellowish-white fluid with the consistency of toothpaste. After aspiration the signs and symptoms relating to the left thigh resolved and the patient made an uneventful recovery.

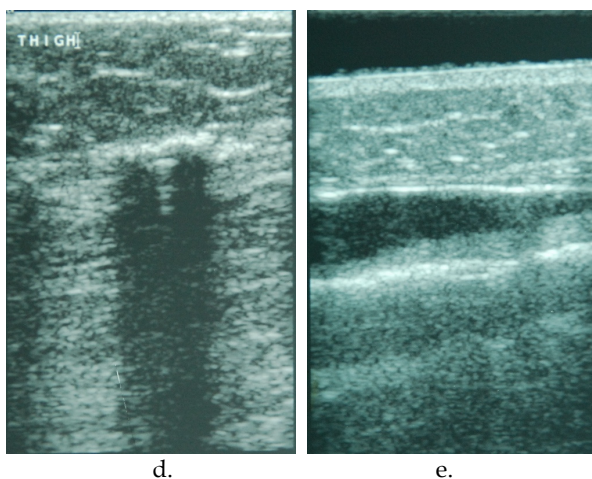


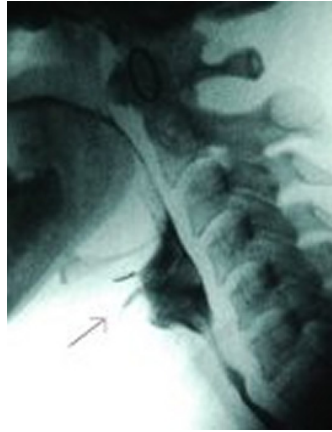Fig. 2. d.-e. Case 2. US of the thighs again demonstrates the superficial plaques with typical shadowing consistent with calcification. Fig. 2d shows the US appearance of the right thigh. Within the deep tissue on the left side, with the patient in the prone position, a flattened anechoic area was detected with a long fluid level and high level echoes below this level, due to a fluid-calcium level (Fig. 2e).

3.3 Case 3

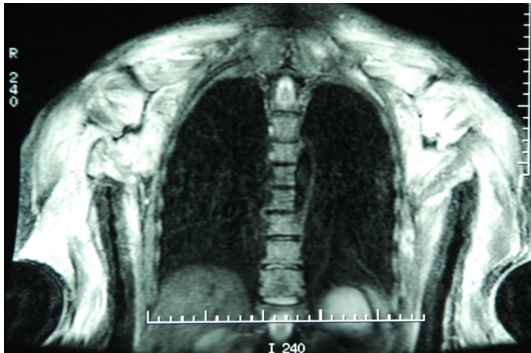
A 46-year-old woman presented with severe proximal muscle weakness. An electromyogram demonstrated an active myopathy with neurophysiologic features of marked myopathic changes in the right deltoid muscle.

The diagnosis of dermatomyositis was made due to concomitant skin changes. The patient had also had difficulty swallowing. A limited speech language therapy barium swallow was performed. No abnormality was detected, except for uncoordination and slight aspiration into the trachea (Fig. 3a). Subsequent chest radiographs and high-resolution CT of the chest

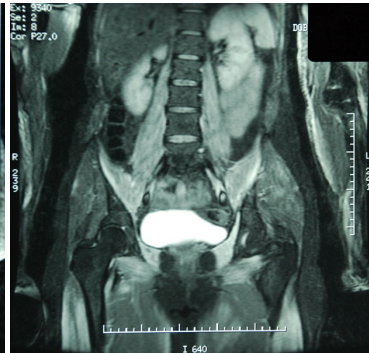
did not reveal an abnormality. MRI (magnetic resonance imaging) of the brain did not demonstrate any abnormal features of consequence.



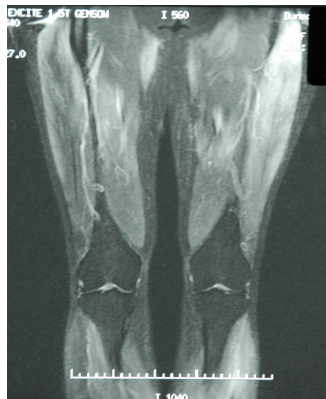a.



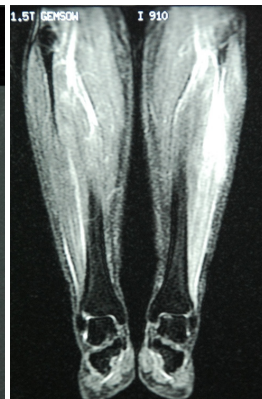
b.



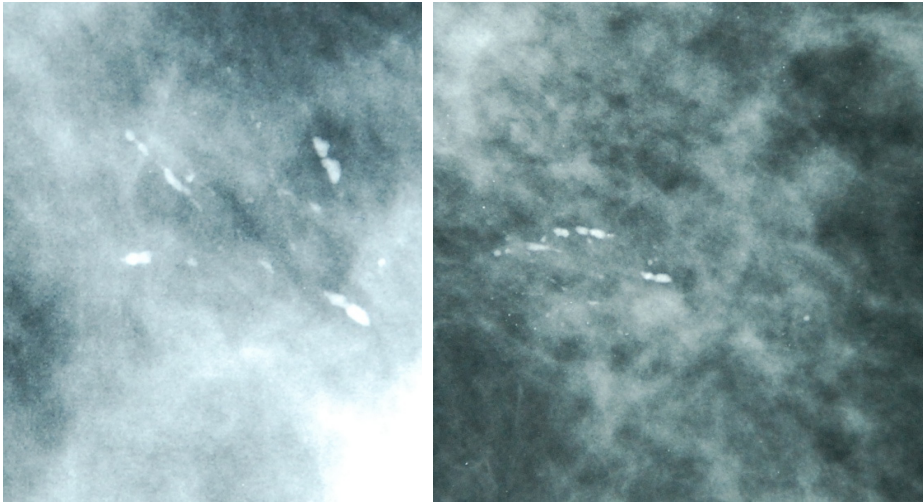
c.



d.

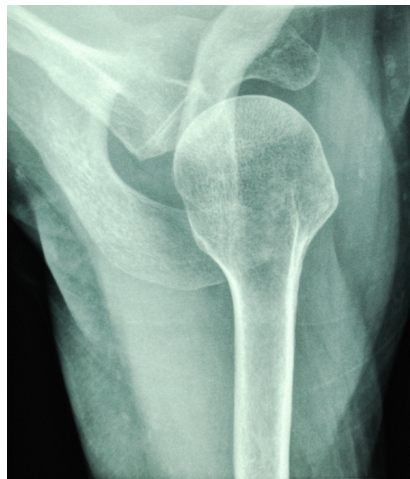

e.



f.

g.



h.

Fig. 3. a.-h. Case 3. A 46-year-old woman was referred with typical skin lesions of dermatomyositis and dysphagia. A speech language therapy barium swallow reveals slight aspiration into the trachea (Fig. 3a). Four station STIR MRI (Fig. 3b-e) demonstrates features consistent with dermatomyositis, especially involving the shoulder girdles and trapezius muscles, the quadriceps musculature particularly the left vastus lateralis and the lateral head of the left gastrocnemius muscle. Subsequent X-ray mammography revealed a carcinoma in the superolateral quadrant of the left breast with typical minute malignant microcalcification (Fig. 3f,g). At the time of further follow-up, six years later, the patient experienced right shoulder girdle pain. No abnormality was demonstrated, except for a few small rounded superficial areas with faint rim calcification (Fig. 3h).

Four station whole body STIR (short tau inversion recovery) and T1-weighted MRI was performed on four occasions over a three year period. The later STIR MRI demonstrated more widespread low grade oedema within the muscles when compared to previous MRI. Initially the patient was treated with steroids, and later with methotrexate/plaquenil. The initial STIR MRI demonstrated marked increase in signal within the muscles of both shoulder girdles and trapezius muscles and to a lesser extent of the psoas muscles. Furthermore relatively symmetrical increased signal was noted in the quadriceps musculature, especially the left vastus lateralis. There was high signal intensity in the lateral head of the left gastrocnemius muscles. (Fig. 3b-e).

The patient had continued to be afflicted by severe dermatomyositis, with little response to treatment, and had had follow-up clinical management by the departments of rheumatology and neurology. There was concern that there might have been a concomitant underlying undetected malignancy; she had noted some tenderness of the left breast, though no lump had been palpable.

The patient was therefore referred for priority X-ray mammography and US of the breasts. Within the superolateral aspect of the left breast there was a group of dense linear casting type calcifications, but more concerning were some associated smaller, ill-defined, calcifications, the latter probably malignant. The magnification mediolateral oblique view (Fig. 3f) and craniocaudal view (Fig. 3g) demonstrated the microcalcifications to better advantage. No soft tissue mass, superficial skin thickening or retraction, or other features of malignancy were noted. US had not demonstrated a mass. Core biopsies were obtained of the calcifications under stereoradiographic guidance. The diagnosis of a carcinoma was confirmed and local excision of the tumour was performed (T₁ No, grade III). Following on surgery the patient developed infective changes of the superolateral quadrant of the left breast; these resolved with antibiotic treatment.

At a later stage the clinical diagnosis of a right ischial abscess had been considered, with the right buttock having become swollen, red and painful with point tenderness. However, US had demonstrated subcutaneous induration and oedema only (as compared to the opposite side) and no abscess or collection had been detected.

CT of the chest, abdomen and pelvis had not shown metastases from the breast carcinoma or other abnormality, except for postoperative appearances of the left breast. Specifically no soft tissue calcification had been seen relating to the subcutaneous tissues or muscles.

Six years after the initial diagnosis of dermatomyositis, the patient had experienced tightness and aching of the right shoulder girdle. Radiography of the shoulder had not revealed a bony abnormality or supraspinatus tendon calcification. However, multiple, small, rounded peripherally calcified lesions had been detected especially on the axial view of the shoulder (Fig. 3h). One of the larger calcifications anterior to the shoulder had measured 6 mm in long axis. These had been thought to be due to early changes of dermatomyositis, though rather atypical in shape and configuration.

At the same time as the shoulder pain, a palpable lump had been discovered clinically in the lateral part of the right breast. MRI, before and after the intravenous administration of 20 cc of gadolinium, had demonstrated the post surgical appearances of the left breast, and in addition a very small 4 mm simple cyst within the superolateral quadrant of the right breast.

Therefore, six years after the initial diagnosis of left breast cancer and dermatomyositis, no further malignant disease had been detected. The clinical and radiological features of dermatomyositis, however, had not improved, and appeared to be refractory to treatment, as had been shown at multiple follow-up STIR MRI.

4. Radiographic abnormalities

4.1 Musculoskeletal system

4.1.1 Soft tissue abnormalities

4.1.1.1 Soft tissue calcifications may be preceded by oedema of the subcutaneous tissue and muscle, causing increased muscular bulk and radiodensity, thickening of subcutaneous septa and poor definition of the subcutaneous tissue-muscle interface. These features may be detected on radiographs specifically exposed to show soft tissue to better advantage. Present day digital radiography generally shows the soft tissue far more optimally, as compared to film radiography, and even an incidental diagnosis of subtle changes of dermatomyositis may be established more readily with modern digital imaging (Fig. 3h). CT is more sensitive than MRI for demonstrating soft tissue calcifications, however, CT is rarely indicated.

4.1.1.2 The changes are more prominent in the proximal musculature, axilla, chest wall, forearms, thighs and calves (Fig. 3b-e).

4.1.1.3 Following on effective treatment, the soft tissue oedema may decrease or disappear entirely. However, fibrosis, muscle atrophy and contractures may develop later. There tends to be decreased soft tissue and muscular bulk, increased translucency of the soft tissue, osteopaenia, calcification and sometimes eventual contractures.

4.1.1.4 Soft tissue calcification occurs in 30–70% of children and 10% of adults, and may occur within the first year of the illness (Moses, 2008). The extent of calcification, especially within the muscles, appears to increase with the severity of the illness. Small or large calcareous intramuscular fascial plane calcification is distinctive of dermatomyositis and polymyositis, though subcutaneous calcification is more common. The large muscles of the proximal parts of the extremities are more frequently affected. Sheetlike confluent calcifications especially occur in the thigh (particularly the vastus lateralis) (Fig. 2c), the pelvic girdle, the upper extremity (deltoid muscles, especially), and the flexor muscles of the neck. Further areas include the elbows, knees, hands, chest and abdominal wall, axillary and inguinal regions.

4.1.1.5 There are four distinct patterns of soft tissue calcifications that occur in childhood dermatomyositis; deep calcareous masses, superficial calcareous masses, deep linear deposits and lacy, reticular, subcutaneous collections that encase the torso. The deep deposits are more commonly encountered (Resnick & Kransdorf, 2005).

4.1.1.6 The amorphous calcifications of dermatomyositis should be differentiated from the bone formation in myositis ossificans, where native bone with immature trabecular bone centrally surrounded by compact bone may be seen.

4.1.1.7.1 The term ‘milk of calcium’ has been used to describe calcium-laden fluid collections in the gall bladder and kidney and more recently by US, in the soft tissue of the

subcutaneous and intermuscular regions of the thigh and calf in two patients with childhood dermatomyositis (Hesla, et al., 1990). Case 2 (Fig. 2e) presents similar features except that fluid-calcium layering (the sedimentation sign) was also demonstrated with an unusually long level indicating the flattened elongated shape of the collection. There was also localized tenderness and this prompted aspiration, even though from a US point of view the fluid-calcium level militated against a soft-tissue abscess.

4.1.1.7.2 Complications of diagnostic and therapeutic aspiration of such collections include introducing secondary infection and secondly the formation of a chronic sinus tract. The latter could result especially if a large bore needle was used to penetrate the frequently hard, brittle subcutaneous calcified tissues. If possible, formal surgical incision and drainage should therefore also be avoided.

4.1.1.7.3 Most conventional radiographic studies fail to show the layering as they are not taken with a horizontal ray beam.

4.1.1.7.4 The diagnosis of fluid-calcium layering can also be established by CT or MRI, when associated bony changes can also be assessed. However, in the absence of skeletal changes on conventional radiographs, US is thought to be more expeditious, less expensive, readily available and no ionizing radiation is involved, especially in childhood dermatomyositis. (Van Gelderen, 2007).

4.1.1.8 Abnormal accumulation of technetium polyphosphate in affected muscle (nuclear medicine study) was a useful technique, however this has now been superseded by MRI, with MRI more accurate and not employing ionizing radiation. Signal intensity would alternate according to the activity of the disease, and therefore changes in the signal pattern were useful to monitor response to treatment. MRI may allow the correct diagnosis of dermatomyositis (or polymyositis) to be made where muscle involvement is not detected clinically (Resnick & Kransdorf, 2005). T2-weighted imaging may be used, but fat-suppressed imaging and STIR-MRI are particularly optimal (Fig. 3b-e). The calcific mass might be of low signal but the affected muscle and perimuscular oedema would be hyperintense, and return to normal after treatment. Follow-up STIR MRI had shown no improvement in Case 3. Phosphorus-31 MR spectroscopy may be used for quantitative characterisation of inflammatory disease. (Park, et al., 1990). MRI may also aid in the clinical dilemma of differentiation between myositis from persistent steroid dermatomyositis.

4.1.2 Articular abnormalities

4.1.2.1 Transient radiographic features with soft tissue swelling and periarticular osteopaenia may be present, but bony erosive changes are uncommon and may involve the metacarpophalangeal and interphalangeal joints. Periosteal and soft tissue calcifications with flecks or small clumps of calcium may be detected on radiographs of the hands. (Fig. 2b). Rheumatoid-like changes are, however, uncommon. The 'floppy-thumb' sign may be detected with radial subluxation or dislocation of the interphalangeal joint of the thumb.

4.1.2.2 Acroosteolysis with pointing and resorption of the terminal tufts of the fingers may occur uncommonly, but reduced soft tissue relating to the tips of the fingers is less infrequent. (Fig. 2b). Flexion contractures and soft tissue ulceration may involve the fingers, though larger joints may be involved.

4.1.2.3 Arthralgias and arthritis are present in 20-50% of patients with the wrists, knees and small joints of the fingers affected symmetrically. Permanent joint changes are infrequently seen.

4.2 Pulmonary involvement

4.2.1 Lung changes will occur in up to 50% of patients, and aspiration pneumonia is probably the most common finding seen on chest X-rays (Fig. 1a). Aspiration is due to cough impairment, dysfunction of the pharynx and general weakness relating to body movement (Fig. 3a). Weakness of the respiratory muscles is associated with stiffness of the lungs, small lung volumes and diaphragmatic elevation with basal plate atelectasis. The myositis may, furthermore, affect the diaphragm directly.

4.2.2 Pulmonary arterial hypertension, with large main and proximal pulmonary arteries, may occur as a complication of interstitial lung disease, hypoventilation or vasculitis, however, may also be seen in isolation.

4.2.3 Interstitial fibrosis was first described in 1956, is now well recognised and occurs in 5-10% of patients (Hansell, et al., 2005). (It correlates strongly with the presence of anti-Jo-1, a myositis specific autoantibody.) The illness may be acute, rapidly fatal and resistant to therapy, or benign, indolent and asymptomatic, with favourable response to steroid treatment.

4.2.4 The more acute patients may demonstrate airspace opacity or even widespread groundglass shadowing, with alveolar opacities earlier in the course and more likely to be steroid responsive. These changes are likely to be predominantly due to organising pneumonia.

4.2.5 Radiographic changes often consist of symmetric reticulonodular changes, mostly in the base of the lungfields. In time the entire lungfields may be involved and a fine honeycomb pattern may form.

4.2.6 The chest X-ray may be normal, despite the presence of confirmed clinical disease. Multifocal dystrophic pulmonary ossifications, which have been demonstrated pathologically, are not detected radiographically.

4.2.7 High-resolution CT changes consist principally of groundglass opacification, diffuse but patchy, mostly peripheral, and also parenchymal bands and consolidation. Bronchiectasis occurs in 40% of patients, though honeycombing was uncommon. Pleural thickening and irregularity was frequently encountered.

4.3 Cardiac abnormalities

4.3.1 The myocardium may be affected in a similar way to the involvement of skeletal striated muscle. Cardiac complications include arrhythmias, congestive cardiac failure, and pericarditis (O'Brien & Kelleher, 2008).

4.4 Gastrointestinal abnormalities

4.4.1 Patients may complain of dysphagia and a barium swallow may reveal disordered peristalsis involving the upper oesophagus, that portion with striated muscle. [The lower

oesophagus has smooth muscle, and is more likely to be affected by scleroderma.] Because of the progressive weakness of the proximal striated oesophageal muscle, there tends to be atony and dilatation. Aspiration into the tracheobronchial tree may occur during barium swallow examination (Fig. 3a). Atony of the small intestine and colon may furthermore be a feature. It should be emphasized that involvement of the gastrointestinal is not a common manifestation of dermatomyositis.

5. Conclusion

5.1 Some of the protean radiological manifestations of dermatomyositis in childhood and adults are illustrated, with the aid of various radiological examinations.

The superficial soft tissue changes may be very extensive and florid. In recent years MRI has become more important to demonstrate activity of disease.

The effect of treatment, for example, with corticosteroids, can be monitored by four-station STIR MRI. The very extensive disease with deformities and contractures, seen previously, are now less common as a consequence of more optimal management.

6. References

- Dähnert, W. 2007. *Radiology Review Manual, 6th Ed.* pp. 64-65, Wolters Kluwer, ISBN 0 7817 6620 6, Philadelphia
- Hansell, D., Armstrong, P., Lynch, D., & McAdams, H. 2005. In: *Imaging of Diseases of the Chest*, pp. 581-585, Elsevier Mosby, ISBN 0 3230 36600, Philadelphia
- Hesla, R., Karlson, L., & McCauley, R. 1990. Milk of calcium collection in dermatomyositis : ultrasound findings. *Pediatr Radiol*, 20:, pp. 344-346
- Moses, S. 2008. Dermatomyositis. *Family Practice Notebook.com*. 2008
- O'Brien, J., & Kelleher, J. 2008. Calcinosis associated with dermatomyositis. *J. Belge de Radiol.*, 91. pp. 27
- Park, J., Vansant, J, Kumar, N., Gibbs, S., Curvin, M., Price, D., Partain, C., & James, A. 1990. Dermatomyositis : correlatiive MR imaging and P-31 MR spectroscopy for quantitative characterisation of inflammatory disease. *Radiology*, 177(2), pp. 473-479
- Resnick, D., & Kransdorf, M. 2005. *Bone and Joint Imaging, 3rd Ed.*, pp. 337-343; 349-352. Elsevier Saunders, ISBN 0 7216 0270 3, Philadelphia
- van Gelderen, W., 2007. Fluid-calcium level in the thigh versus clinical diagnosis of a soft tissue abscess : ultrasound features of dermatomyositis. *Australasian Radiol*, 51, pp. B83-B85

© 2012 The Author(s). Licensee IntechOpen. This is an open access article distributed under the terms of the [Creative Commons Attribution 3.0 License](#), which permits unrestricted use, distribution, and reproduction in any medium, provided the original work is properly cited.