

Parenchymatous Brain Injury in Premature Infants: Intraventricular Hemorrhage and Periventricular Leukomalacia

Mauricio Barría and Ana Flández
*Universidad Austral de Chile,
Hospital Clínico Regional Valdivia,
Chile*

1. Introduction

Prematurity is a condition associated with high mortality and overall survival rates are near 77.5% (Stoll et al., 2010). Those who survived are at high risk of severe impairment (Bassler et al., 2009). Two percent of all live births are premature with less than 32 weeks of gestational age and 1.5% of them are very low birth weight (Mathews et al., 2011). The most common injury affecting brain of these children is periventricular leukomalacia (PVL) and intraventricular hemorrhage (IVH). PVL is the main cause of cognitive behavioural, motor and sensory impairments found in children born before 32 weeks of gestational age (Volpe, 2003). IVH has a negative impact on the neurodevelopmental outcome and is due not only to the direct consequences of IVH but also associated lesions, such as posthemorrhagic hydrocephalus (PHH) and PVL. The knowledge, prevention, diagnosis and early treatment of these clinical conditions improve the prognosis and neurological outcomes.

2. Brain injury in the premature infant

2.1 Intraventricular hemorrhage

In the late 1970s the incidence of IVH was near 50%. At the present time it is near 20 to 30%. The absolute number of infants with IVH remains significant due to increase survival rate of premature infants especially in very low birth weight, who are at high risk of IVH. Virtually all IVH in premature infants occurs within the first five days of life, with 50, 25 and 15 percent on the first, second and third day respectively, and 10 percent on the fourth day or after. IVH progresses over three to five days in approximately 20 to 40 percent of cases (Volpe, 2008; Groenendaal et al., 2010). PHH, periventricular hemorrhagic infarction (PVHI), and PVL are the most important sequelae of IVH. The first occurs in approximately 25% of infants with IVH and usually it begins within one to three weeks after the brain bleeding (Murphy et al., 2002). PVHI pathogenesis is thought to result from infarction caused by venous obstruction after a germinal matrix IVH (Bassan, 2009; Volpe, 1998). The parietal and frontal cerebral areas are the most often involved (Bassan et al., 2006a). PVL is the mayor form of brain white matter in neonates especially in premature infants. There is a strong association between PVL and IVH and data suggest the IVH may exacerbate PDL (Bassan,

2009). The short term outcome is closely related to the severity of IVH (Kusters et al., 2009). The long term outcome of infants, who survive of IVH, worsens with increasing severity of IVH and decreasing gestational age (Sherlock et al., 2005; Luu et al., 2009).

2.1.1 Risk factors and pathogenesis

IVH originates from the fragile involuting vessels of subependymal germinal matrix, located in the caudothalamic groove. The pathogenesis of this in preterm infants has been demonstrated to be related to numerous risk factors which can be divided into intravascular, probably the most important and amenable to preventive efforts, vascular and extravascular factors (Table 1). Intravascular factors are ischemia and reperfusion, like in volume infusion after hypotension, fluctuating cerebral blood flow (CBF), like in mechanical ventilation, increase in CBF, like in hypertension, anemia and hypercarbia, increase in cerebral venous pressure and platelet dysfunction and coagulation disturbances. Vascular factors consider tenuous and involuting capillaries with large diameter lumen. Extravascular factors are deficient vascular support and excessive fibrinolytic activity (Perlman et al., 1983; Lou, 1988; Pryds et al., 1989). For developing PVHI the risk factors are low birth gestational age, low Apgar scores, early life acidosis, patent ductus arteriosus, pneumothorax, pulmonary hemorrhage and needed for significant respiratory or blood pressure support (Bassan et al., 2006b). PHH likely relates at least in part to impaired cerebral spinal fluid resorption or obstruction of the aqueduct or the foramina of Luschka or Magendie by particulate clot (Larroche, 1972).

Pathogenesis of IVH	
Intravascular factors	Ischemia /reperfusion
	Fluctuating cerebral blood flow
	Increase in cerebral blood flow
	Increase in cerebral venous pressure
Vascular factors	Platelet dysfunction and coagulation disturbances
	Tenuous, involuting capillaries with large diameter lumen
Extravascular factors	Deficient vascular support
	Excessive fibrinolytic activity

Table 1. Pathogenesis of IVH.

2.1.2 Classification – Severity and grading of IVH

There are two main systems for grading the severity of IVH based on the amount of blood in the germinal matrix and lateral ventricles demonstrated by ultrasound or computed tomography (CT) scan (Table 2). By US, Volpe grades the IVH in: I, for germinal matrix hemorrhage (GMH) with no or minimal IVH, with less than 10% of ventricular volume occupying, II for IVH occupying 10%-50% of ventricular area on parasagittal view, III for IVH occupying more than 50% of ventricular area on parasagittal view, usually distends lateral ventricle. Separate notation: persistent periventricular echodensity (Volpe, 2008). Using CT scan Papile grading system is: I for isolated germinal matrix hemorrhage II for IVH without ventricular dilatation, III for IVH with ventricular dilatation and IV for IVH with parenchymal hemorrhage (Papile et al., 1978).

Reference	Method	Grading	Findings
Papile (1978)	Computed Tomography	I	Isolated germinal matrix hemorrhage (without IVH)
		II	IVH without ventricular dilatation
		III	IVH with ventricular dilatation
		IV	IVH without ventricular dilatation
Volpe (2008)	Cranial Ultrasonography	I	Germinal matrix hemorrhage with no or minimal IVH (10% ventricular volume)
		II	IVH occupying 10-50% of ventricular area
		III	IVH occupying >50% of ventricular area

Table 2. Grading IVH by Computed Tomography and Cranial Ultrasonography.

2.1.3 Clinical presentation and diagnosis

Clinical presentation varies from a silent syndrome, recognized only when a routine cranial US is performed, a mild form with decreased levels of consciousness, hypotonia, abnormal eye movements or skew deviation. A catastrophic way with rapid and severe neurological deterioration, with seizures, tonic posturing and coma is more rarely (Soul, 2008).

Whereas any cerebral imaging test is useful, it is almost invariably made by portable cranial US. The diagnosis of HIV and PHH is easy and performing fast, quick to make. Premature infants are fragile patients carry them to make CT scan or magnetic resonance adds more costs, time and risk, and there are hospitals where this exams aren't available.

2.1.4 Prevention and treatment

The most effective strategy to prevent IVH is the prevention of preterm birth. When it cannot be avoided, the following prenatal and delivery interventions are associated with a reduced risk of IVH. Antenatal corticosteroids, reducing the risk of IVH detected by cranial US examination (OR 0.29, CI_{95%} 0.14 to 0.61) (Crowley, 2000). Delayed clamping of the umbilical cord more than 30 seconds demonstrated a lower relative risk of IVH versus early clamping (RR 0.56, CI_{95%} 0.36 to 0.93) (Rabe et al., 2004). Mothers who are at risk of preterm delivery must be transferred to a perinatal center with experience in high risk deliveries and care of prematures. Infants who are transferred after delivery are at higher risk for developing IVH. Inborn patients compared to those who are transported had a lower incidence of IVH (13.2 versus 27.4) and a lower relative distribution of severe IVH (39.2 versus 44.1 percent) (Mohamed & Aly, 2010). Delivery mode does not appear to affect the risk of severe IVH (Riskin et al., 2008) whereas the presence or absence of labor in cesarean delivery the data are conflicting. In the neonatal care units the efforts must be put on: prompt and appropriate resuscitation of the neonate, avoiding hemodynamic instability, hypoxia, hyperoxia, hypercarbia and hypocarbia. All these factors affect the cerebrovascular autoregulation; avoid hypotension and hypertension and hemodynamic instability must be care avoiding large bolus infusions. Metabolic abnormalities such as hyperosmolarity, hyperglycemia and hypoglycemia should be prevented. Abnormalities in coagulation should be corrected (Bada et al., 1990; Dani et al., 2009; Perry et al., 1990).

The incidence of IVH is higher in preterm infants with patent ductus arteriosus, they should be treated (Jim et al., 2005). Ineffective interventions for prevention IVH include: antenatal

administration of phenobarbital (Shankaran et al., 1997), antenatal administration of magnesium sulfate and vitamin K to the mother has no benefit in prevent IVH (Crowther et al., 2010; Volpe, 2008). Postnatal indomethacin and vitamin E are associated a lower risk of IVH, but the first increases other risks like gastrointestinal and renal negative effects and the other with an increased risk of sepsis, so it's use is controversial (Fowlie et al., 2010; Brion et al., 2003).

The treatment doesn't includes a specific therapy, it is supportive and the main goal is to preserve more perfectly cerebral perfusion. Treatment and early detection of complications like seizures and PHH, with serial cranial US, will improve the outcome, minimizing further brain injury.

2.1.5 Evolution and prognosis

IVH is still an important cause of injury in premature infants. The negative impact of IVH on neurodevelopmental outcome is due not only to direct consequences of IVH because it is also associated to other lesions like PHH or PVL. Long term prognosis for infants with IVH varies considerably depending on the severity of IVH, complications or other brain lesions such PVL, the most lower birth weight and gestational age add to others significant illness will determinate the outcome. Studies have suggested that preterm infants with grade I-II IVH have an increased risk of cerebral palsy and cognitive impairment compared who those without (Sherlock et al., 2005; Ancel et al., 2006; Patra et al., 2006). Infants with the mayor complications, like PVHI and PHH are at much higher risk of permanent neurologic impairments like cerebral palsy than dose with IVH alone (de Vries et al., 1999). More than 50% of children born before 32 weeks gestational age have school difficulties whether or not they had IVH, although the risk is clearly higher among children and adolescents with a story of IVH and lower birth gestational age or weight (Bowen et al., 2002; van de Bor & den Ouden, 2004). These cognitive or behavioural handicaps are related in part to white matter brain injury. The most effective strategy to prevent IVH is the prevention of preterm birth.

2.2 Periventricular leukomalacia

PVL refers to damage of cerebral white matter brain injury. The name is based on the characteristic distribution and consists of periventricular focal necrosis with subsequent cystic formation and more diffuse cerebral white matter injury (Volpe, 2008).

PVL is the mayor form of brain white matter injury that affects premature infants and it is associated with subsequent development of cerebral palsy, intellectual impairment and visual disturbances. The great risk for developing PVL is under 32 weeks of gestational age. The incidence of PVL varies among centers and in relation with imaging testing realized. Based on US, frequency of PVL ranges from 5 to 15% in VLBW infants (Stevenson et al., 1998). Using MRI, white matter abnormalities are found in 21%, and are associated with adverse neurodevelopment outcomes at a corrected age of 2 years. Gray matter abnormalities are present in half of infants, and are also significantly associated, but less strongly, with cognitive delay motor and cerebral palsy (Woodward et al., 2006). PVL is still the principal cause of this neurodevelopmental impairment (Volpe, 2003).

2.2.1 Risk factors and pathogenesis

PVL, lesion found predominantly in preterm infants, can be caused by ischemia or infection. The distinctive lesion of PVL found in the immature white matter newborns likely results from the interaction of multiple pathogenic factors (Table 3).

Pathogenesis of PVL	
Vascular anatomic factors	Incomplete development of vessels Boundary zone around the ventricles
Circulatory factors	Impaired cerebral vascular autoregulation and vasoconstriction
Cellular factors	Cystic PVL: affects all cell components Non cystic PVL: affects predominantly oligodendrocytes
Oxidative stress	Associated to: maternal/fetal infection Cytokines
Axonal development	Particularly susceptible to damage Beta amyloid precursor protein identified in swollen axons around PVL (marker of axonal damage)
Genetics	Individual genetic variations

Table 3. Pathogenesis of PVL.

To date, the several mayor factors identified are: vascular anatomic factors, pressure-passive cerebral circulation, intrinsic vulnerability of cerebral white matter of the premature neonate and infection/inflammation. The anatomy of the developing cerebral vasculature renders makes the premature infant especially vulnerable to periventricular white matter injury. The area near ventricles result in a boundary zone, with incomplete development of vessels that penetrates the deep and subcortical white matter, therefore this area is vulnerable to reduced flow (Takashima & Tanaka, 1978; Rorke, 1992).The circulatory factors and metabolic disturbances can impair autoregulation, resulting in higher risk for developing PVL, like HIV. In cystic PVL necrotic changes usually affects all cell components. Diffuse non cystic PVL affects predominantly a specific cell lineage, that of oligodendrocytes (Oka et al., 1993). Another risk factor is oxidative stress attributed to cerebral ischemia and reperfusion and or maternal infection (Khwaja & Volpe, 2008). Expression of inducible nitric oxide synthase is increased in brains with PVL (Haynes et al., 2009). Axonal maturation studies suggest that axons may be particularly susceptible to damage at time in development that coincides with the highest risk of PVL (Haynes et al., 2005). Antenatal risk factors like infection increase the risk of premature birth. In a meta-analysis, chorioamnionitis was associated with cystic PVL (RR 3.0) and cerebral palsy (RR 1.9) (Pidcock et al., 1990). Cytokines produced as a consequence of maternal or fetal infection, even the infection is asymptomatic may be associated with PVL, because the white matter is especially susceptible to damage mediated by this inflammation factor (Dammann & Leviton, 1997).

2.2.2 Classification – Severity and grading PVL

Using cranial ultrasound PVL can be classified according to Volpe or de Vries (Volpe, 1990; de Vries et al., 1992). Volpe categorizes PVL in mild, with micro cysts smaller than 0.2 mm

in specially in parasagittal view, moderate with cysts between 0.2 to 0.5 mm, and severe when exists multiple cyst bilaterally bigger than 0.5 mm. According to de Vries, PVL can be classified from I to IV grades (Table 4).

Reference	Method	Grading	Findings
de Vries (1992)	Cranial Ultrasonography	I	transient periventricular echodensities persisting for ≥ 7
		II	transient periventricular echodensity evolving into small, lo-calised fronto-parietal cysts
		III	periventricular echodensities evolving into extensive periven-tricular cystic lesions
		IV	densities extending into the deep white matter evolving intoextensive cystic lesions
Volpe (1990)	Cranial Ultrasonography	Mild	micro cysts smaller than 0.2 mm
		Moderate	cysts between 0.2 to 0.5 mm
		Severe	multiples cysts bilaterally bigger than 0.5 mm

Table 4. Grading PVL by Cranial Ultrasonography.

The existence of echogenic lesions without cysts formation for more than 14 days is considered as persistent periventricular echogenicity (Larroque et al., 2003).

For RMI the grading of PVL is more descriptive. Several studies have shown that MRI is more sensitive than cranial US for detection of PVL especially for non cystic form of PVL (Maalouf et al., 2001; Roelants-van Rijn et al., 2001).

2.2.3 Diagnosis

PVL is detected in newborns by brain imaging using US or CT or RMI. Ultrasound is the initial standard method because is portable and less expensive. The criteria for US diagnosis are not well defined. A standard examination includes coronal and sagittal view (Veyrac et al., 2006). The US findings evolve on repeated examinations. The cysts appear after one or three weeks and disappear after one or three months if they are moderate or severe ventriculomegaly may results (Blankenberg et al., 1997). US has limited sensitivity and specificity to detect PVL specially if the lesion are less than 0.5 cm. Sonograms may detect only one third of lesion identified at autopsy (Papile, 1997). The routine ultrasound recommended by the Quality Standard Subcommittee of the America Academy of Neurology and the Practice Committee of the Child Neurology Society made the following recommendations: Routine ultrasound screening should be performed on all infants with gestational age less than 30 weeks. Screening should be performed at 7 to 14 days of age and repeated at 36 to 40 weeks postmenstrual age. This strategy is designed to detect unsuspected PVHI, development of PHH or ventriculomegaly. CT scanning is less useful for

the diagnosis of PVL in the very preterm infant because it detects fewer lesions than does MRI or US (Keeney et al., 1991). Whereas MRI is the most sensible examination the routine use of MRI scans for all premature infants has not been recommended although it may be useful in some high risk premature infants or older infant or child born prematurely who presents with cognitive, motor or sensory impairment (Ment et al., 2002).

2.2.4 Prevention and treatment

The strategies to prevent PVL emphasize the maintenance of cerebral perfusion. All conditions that impair cerebrovascular autoregulation should be avoided by correcting abnormalities in blood pressure and blood gases. Antenatal exposure to betamethasone may be associated with decreased risk of cystic PVL, more than in infants whose mothers received dexamethasone or no received glucocorticoid treatment (Baud et al., 1999). Management of PVL after discharge from the hospital is directed at identification of any cognitive, sensory or motor impairments, and appropriate therapies for any such impairment. Promising studies of neuroprotective strategies to prevent or minimize PVL are being conducted in animal models, but human trials of such agents are probably still years away (Oka et al., 1993; Follett et al., 2004).

2.2.5 Evolution and prognosis

Cranial US and brain MRI may yield prognostic information in neonates and children with PVL. Infants with more extensive white matter injuries and persistent ventricular enlargements are more likely to have severe motor and cognitive deficits. When PVL and cystic formation are found in the neonatal period using US, there is a subsequent risk for developing cerebral palsy. In a twelve studies review 50% of infants with periventricular echolucency developed cerebral palsy compared with 2.6% with infants with normal cranial US scans (Holling & Leviton, 1999). Considering the increase in survival rates of extremely preterm infants (birth weight less than 1000g) it would be reasonable to consider MRI to add more prognostic information for such high risk infants. Abnormal white matter or gray matter findings on brain MRI at term are predictors of adverse neurodevelopment outcome. In VLBW there is an approximately 10% incidence of cerebral palsy and up to 50% incidence of school difficulties largely due to PVL with PVHI being the other cerebral lesion that contributes significantly to neurologic disabilities. The incidence of neurologic impairments increases with lower gestational age at birth. Cerebral palsy in children born before 36 weeks gestational age is 20%. Spastic diparesis is the most common form of cerebral palsy in children born prematurely because PVL typically affects the periventricular white matter closest to the ventricles (Ancel et al., 2006). Despite these negative numbers thanks to therapy and family support some of these children get a social adaptation that increases the quality of their lives.

3. A Chilean experience

From the years 2001 to 2006, we carried out a prospective cohort study at a tertiary care hospital at Valdivia, Chile that includes all inborn neonates with gestational age of 32 weeks or less and birth weight of 1500 g or less (Barria & Flandez, 2008). Neonates dead within first seven days of age, with major malformation at birth or transferred to another center without

ultrasound evaluation were excluded. For this study an experienced pediatric neurologist performed serial cranial ultrasound to 164 neonates according to the protocol of the Chilean Ministry of Health. The images were obtained by using a 7.5-MHz transducer with Medison Mysono 201® equipment. The US began within the first week of life, and then at 15 and 30 days.

The following epidemiological and clinical variables were obtained from all premature infants: gestational age, birth weight, adequacy of weight to gestational age, gender, Apgar score, antenatal use of corticosteroids, type of delivery, rupture of membranes, maternal pre-eclampsia and chorioamnionitis.

Based on the main outcome (IVH: yes/no; PVL: yes/no), variables among groups were compared using Fisher exact test for categorical data and the Student t-test or Mann-Whitney U test for continuous variables. Relative risk (RR) and its 95% confidence interval (CI_{95%}) were calculated as univariate estimation of the risk of IVH and PVL. Adjusted odds ratios (OR) were estimated using multiple logistic regression with backward stepwise incorporation into the initial model of every variable showing a P value $\leq .25$ after the univariate analysis. The established level of statistical significance was $p < .05$. Data processing and analysis were carried out using Stata 8.1 (Stata Corporation, College Station, Texas).

3.1 Incidence of IVH and PVL, and factors related

The accumulated incidence of IVH was 18.3% (30/164), distributed in 30% grade I (9/30), 36.7% grade II, (11/30), 20% grade III (6/30) and 13.3% grade IV (4/30). The percentual distribution of IVH by birth weight and gestational age is show in figure 1 and 2, respectively.

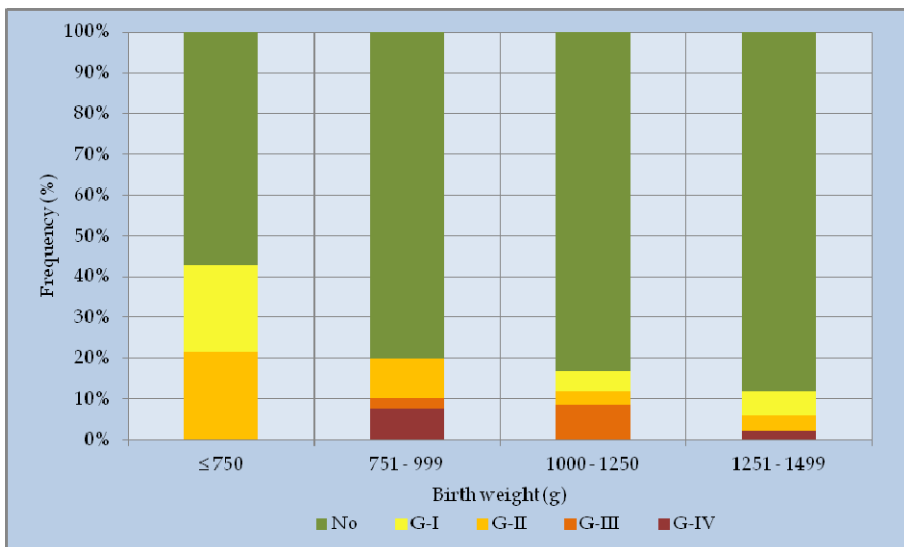


Fig. 1. Incidence of IVH by birth weight categories.

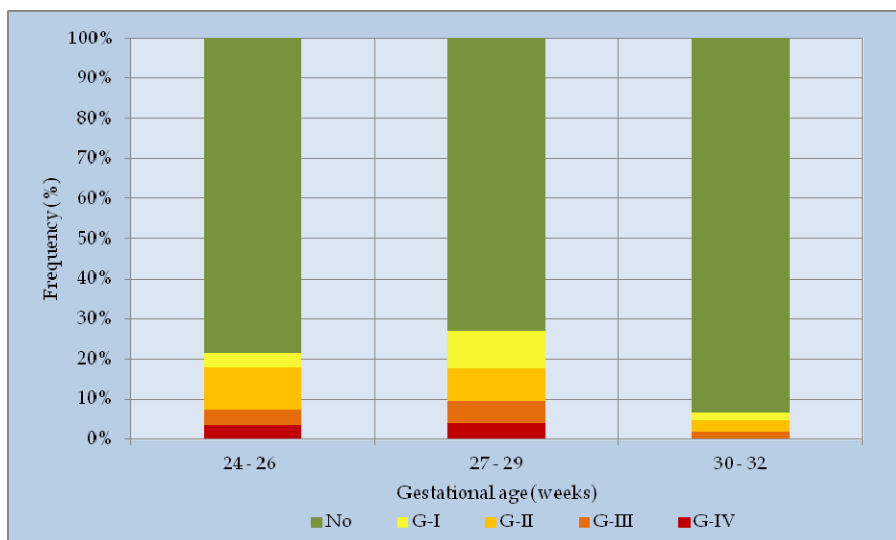


Fig. 2. Incidence of IVH by gestational age categories.

In the univariate analysis IVH was significantly associated with birth weight, estimating an OR of 5.6 (CI_{95%} 1.4 to 21.8) in infants under 750g. In other weight categories there was no significant association. According with gestational age, comparing with the group over 30 weeks, a significant association was found in infants among 24-26 weeks (OR 5.4, CI_{95%} 1.72 to 16.7) and among 27-29 weeks (OR 5.4, CI_{95%} 1.72 to 16.7). On the other hand, the Apgar at first minute showed a significant reduction in the risk of IVH for each additional point in the score (OR 0.82, CI_{95%} 0.70 to 0.95). Other factors analyzed (chorioamnionitis, rupture of membranes, pre-eclampsia, etc.) were not significantly associated with IVH. In multivariate analysis, only Apgar at one minute was associated independently of the outcome of interest.

Ultrasound assessment allowed the detection of 61 neonates (37.2%) with abnormal white matter, 22 with PPVE and 39 with cystic lesion. Thus, the overall incidence for each event was 13.4 and 23.8% respectively. PVL was classified as mild in 64.1% (25/39), moderate in 30.8% (12/39) and severe in 5.1% (2/39). In addition, 23.3% of children with IVH also developed PVL (7/30). While PPVE was found in 50% (2/4) at 24 weeks of gestational age, a lower incidence remained relatively stable between 25 and 30 weeks, fluctuating between 14.3 and 16.7%, and declined clearly from week 31. For its part, the c-PVL was found most often below 28 weeks, accumulating 66.7% of cases (26/39). Between 24 and 27 weeks, the PVL incidence reached at least 50%, and significantly decreased from week 28 (Figure 3). A similar pattern occurred in the distribution of c-PVL and PPVE by weight strata, which the highest incidence occurred under 1000 g, reaching to below 750 g up to 21.4 and 64.3%, respectively. Additionally, the severity of periventricular lesions was higher in most premature infants, finding medians of gestational age for PPVE, mild c-PVL and moderate to severe c-PVL of 29, 27 and 26.5 weeks, respectively.

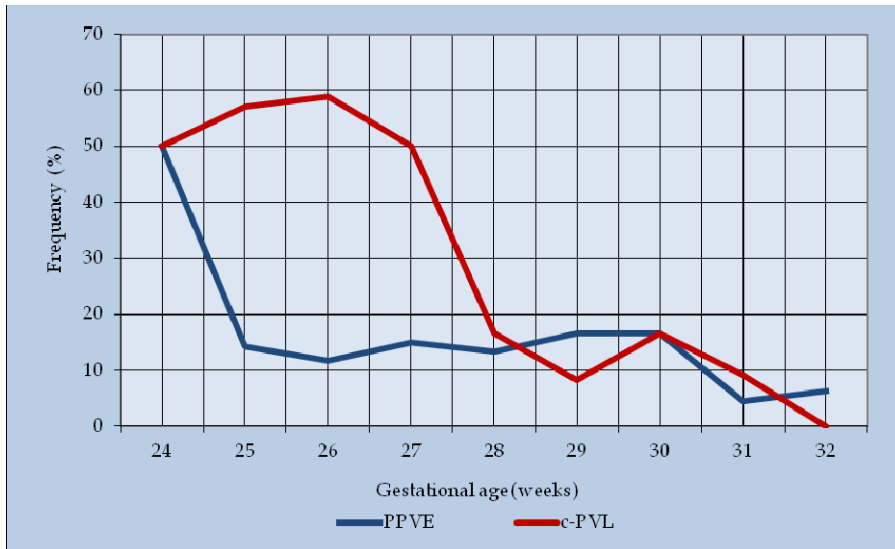


Fig. 3. Distribution of PPVE and c-PVL by gestational age.

Birth weight, gestational age, Apgar score and maternal hypertension were significantly associated with c-PVL ($p < 0.05$). There were no significant differences in other characteristics assessed such as chorioamnionitis, antenatal corticosteroids nor other perinatal factors. In the univariate risk estimation, there was an increased risk of c-PVL in extremely low-birth weight newborns ($< 1000\text{g}$) (RR 5.18, $CI_{95\%}$ 2.8 to 9.61) and in infant under 28 weeks of gestational age (RR 4.83, $CI_{95\%}$ 2.72 to 8.58). A risk reduction effect at border of statistic significance was detected for the presence of maternal hypertension (RR 0.48, $CI_{95\%}$ 0.23 to 1.02). There was no effect of Apgar score and other perinatal conditions on the development of c-PVL. To PPVE, we found an increased risk with Apgar score ≤ 3 at one minute and presence of IVH. The male showed a risk reduction in the limit of statistical significance ($p = 0.058$). The extremely low-birth weight and prematurity below 28 weeks showed no association with PPVE.

Our results verify the effect of gestational age (prematurity) and birth weight commented previously in this chapter. Highlight of our findings the association found between PVL and pre-eclampsia. Consistent with this finding, a study previously has reported that children of whose mothers developed preeclampsia with intrauterine growth retardation had a low incidence of PVL (0.9%) and showed a significantly lower risk of cystic lesions (OR 0.08, $CI_{95\%}$ 0.02 to 0.41) (Baud et al., 2000). In this sense, other study showed that none of the infants with a history of preeclampsia had c-PVL (Murata et al., 2005). However, other researchers found that this effect has been limited until 32 weeks, observing, on the contrary, an increased risk in children between 33 and 35 weeks of gestational age (Resch et al., 2000). Consequently, although the evidence is unclear, there is pathophysiologic support for considering hypertension in pregnancy as a protective factor on the incidence of c-PVL, based on self-regulatory mechanisms of the fetoplacental circulation developed in response to fluctuations of vascular tone. This would allow deal adequately potential hypoxic-ischemic episodes in the fetal brain. In this function, activation of the renin-angiotensin

system in the fetoplacental unit caused by pre-eclampsia, would have a principal action (Ito et al., 2002). Likewise, hypertension and growth restriction can accelerate neurological maturity (Hadi, 1984), suggesting that early maturation may reduce brain disorders. It is also likely, however, that there are intermediate factors in this causal chain that must be clarified.

3.2 Follow up at four years

From 153 children potentially eligible born between September 2001 and June 2005 were included 81 preterm infants <32 weeks and/or VLBW with neurological evaluation at the fourth year of life (52.9%). Of the remainder, in 12 cases there was no record and in 60 there was no neurological control at this age. We calculated the incidence of neurological disorders and assessed association for different variables using t-test and Fisher exact test. Risks were calculated for overall and specific neurological areas for different variables, by estimating crude and adjusted odds ratio using multiple logistic regression.

At discharge from the hospital, 17.5% of the infants developed IVH and 23.4% cystic PVL of varying degrees. At 4 years, 30.9% of patients were diagnosed with some degree of alteration in any of the evaluated areas. Eighteen children (22.2%) showed cognitive impairment: 61% mild, 33.3% moderate and 5.5% severe. In motor area, 16 children showed affection, highlighting 37.5% (6/16) of spastic diplegia and 43.7% (7/16) hemiparesis. Six children (7.4%) showed sensory (visual, auditory or both) and social deficits.

In multivariate analysis, the gestational age was significantly associated with motor disorder estimating an adjusted OR 0.57 for each additional week (CI_{95%} 0.40 to 0.81). The history of IVH also showed a significant association estimating an OR 4.3(CI_{95%} 1.1 to 17.7). Similarly, for cognitive impairment, was estimated a lower risk with higher gestational age (OR 0.64, CI_{95%} 0.42 to 0.95).

4. Conclusion

Gestational age is an important predictor of neurologic outcomes and therefore the systematic monitoring of premature infants allows the diagnosis need to target intervention and/or rehabilitation for improving the quality of life of the child and family. Since prematures improve surviving, decreasing the adverse outcomes taking the best strategies to prevent brain injury is must necessary. Preventing the premature birth is the main goal. When it isn't possible, knowing the pathophysiology of the brain lesions and it's risk factors can minimizes the final results in terms of neurodevelopment. Strategies in early intervention for lower motor handicaps, specially in whose have cranial US altered is needed. Their periodic neurological evaluation for finding behavioural and cognitive impairments is needed for giving them the best expectations in their quality of live.

5. References

Ancel, P. Y., Livinec, F., Larroque, B., Marret, S., Arnaud, C., Pierrat, V. et al. (2006). Cerebral palsy among very preterm children in relation to gestational age and neonatal ultrasound abnormalities: the EPIPAGE cohort study. *Pediatrics*, Vol.117, No.3, (March 2006), pp. (828-835), ISSN 0031-4005.

- Bada, H. S., Korones, S. B., Perry, E. H., Arheart, K. L., Pourcyrus, M., Runyan, J. W., III et al. (1990). Frequent handling in the neonatal intensive care unit and intraventricular hemorrhage. *The Journal of Pediatrics*, Vol.117, No.1 Pt 1, (July 1990), pp. (126-131), ISSN 0022-3476.
- Barria, R. M. & Flandez, J. (2008). [Leukomalacia and periventricular echogenicity in very low birth weight premature infants]. *Revista de Neurologia*, Vol.47, No.1, (July 2008), pp. (16-20), ISSN 0210-0010.
- Bassan, H. (2009). Intracranial hemorrhage in the preterm infant: understanding it, preventing it. *Clinics in Perinatology*, Vol.36, No.4, (December 2009), pp. (737-62, v), ISSN 0095-5108.
- Bassan, H., Benson, C. B., Limperopoulos, C., Feldman, H. A., Ringer, S. A., Veracruz, E. et al. (2006a). Ultrasonographic features and severity scoring of periventricular hemorrhagic infarction in relation to risk factors and outcome. *Pediatrics*, Vol.117, No.6, (June 2006), pp. (2111-2118), ISSN 0031-4005.
- Bassan, H., Feldman, H. A., Limperopoulos, C., Benson, C. B., Ringer, S. A., Veracruz, E. et al. (2006b). Periventricular hemorrhagic infarction: risk factors and neonatal outcome. *Pediatric Neurology*, Vol.35, No.2, (August 2006), pp. (85-92), ISSN 0887-8994.
- Bassler, D., Stoll, B. J., Schmidt, B., Asztalos, E. V., Roberts, R. S., Robertson, C. M. et al. (2009). Using a count of neonatal morbidities to predict poor outcome in extremely low birth weight infants: added role of neonatal infection. *Pediatrics*, Vol.123, No.1, (January 2009), pp. (313-318), ISSN 0031-4005.
- Baud, O., Foix-L'Heliass, L., Kaminski, M., Audibert, F., Jarreau, P. H., Papiernik, E. et al. (1999). Antenatal glucocorticoid treatment and cystic periventricular leukomalacia in very premature infants. *The New England Journal of Medicine*, Vol.341, No.16, (October 1999), pp. (1190-1196), ISSN 0028-4793.
- Baud, O., Zupan, V., Lacaze-Masmonteil, T., Audibert, F., Shojaei, T., Thebaud, B. et al. (2000). The relationships between antenatal management, the cause of delivery and neonatal outcome in a large cohort of very preterm singleton infants. *British Journal of Obstetrics and Gynaecology*, Vol.107, No.7, (July 2000), pp. (877-884), ISSN 1470-0328.
- Blankenberg, F. G., Loh, N. N., Norbash, A. M., Craychee, J. A., Spielman, D. M., Person, B. L. et al. (1997). Impaired cerebrovascular autoregulation after hypoxic-ischemic injury in extremely low-birth-weight neonates: detection with power and pulsed wave Doppler US. *Radiology*, Vol.205, No.2, (November 1997), pp. (563-568), ISSN 0033-8419.
- Bowen, J. R., Gibson, F. L., & Hand, P. J. (2002). Educational outcome at 8 years for children who were born extremely prematurely: a controlled study. *Journal of Paediatrics and Child Health*, Vol.38, No.5, (October 2002), pp. (438-444), ISSN 1034-4810.
- Brion, L. P., Bell, E. F., & Raghuvver, T. S. (2003). Vitamin E supplementation for prevention of morbidity and mortality in preterm infants. *Cochrane Database of Systematic Reviews (Online)*, No.4, CD003665, ISSN 1469-493X.
- Crowley, P. (2000). Prophylactic corticosteroids for preterm birth. *Cochrane Database of Systematic Reviews (Online)*, No.2, CD000065, ISSN 1469-493X.

- Crowther, C. A., Crosby, D. D., & Henderson-Smart, D. J. (2010). Vitamin K prior to preterm birth for preventing neonatal periventricular haemorrhage. *Cochrane Database of Systematic Reviews (Online)*, No.1, (January 2010), CD000229, ISSN 1469-493X.
- Dammann, O. & Leviton, A. (1997). Maternal intrauterine infection, cytokines, and brain damage in the preterm newborn. *Pediatric Research*, Vol.42, No.1, (July 1997), pp. (1-8), ISSN 0031-3998.
- Dani, C., Poggi, C., Ceciari, F., Bertini, G., Pratesi, S., & Rubaltelli, F. F. (2009). Coagulopathy screening and early plasma treatment for the prevention of intraventricular hemorrhage in preterm infants. *Transfusion*, Vol.49, No.12, (December 2009), pp. (2637-2644), ISSN 0041-1132.
- de Vries, L. S., Eken, P., & Dubowitz, L. M. (1992). The spectrum of leukomalacia using cranial ultrasound. *Behavioural Brain Research*, Vol.49, No.1, (1992), pp. (1-6), ISSN 0166-4328.
- de Vries, L. S., Groenendaal, F., van Haastert, I. C., Eken, P., Rademaker, K. J., & Meiners, L. C. (1999). Asymmetrical myelination of the posterior limb of the internal capsule in infants with periventricular haemorrhagic infarction: an early predictor of hemiplegia. *Neuropediatrics*, Vol.30, No.6, (December 1999), pp. (314-319), ISSN 0174-304X.
- Follett, P. L., Deng, W., Dai, W., Talos, D. M., Massillon, L. J., Rosenberg, P. A. et al. (2004). Glutamate receptor-mediated oligodendrocyte toxicity in periventricular leukomalacia: a protective role for topiramate. *The Journal of Neuroscience*, Vol.24, No.18, (May 2004), pp. (4412-4420), ISSN 0270-6474.
- Fowlie, P. W., Davis, P. G., & McGuire, W. (2010). Prophylactic intravenous indomethacin for preventing mortality and morbidity in preterm infants. *Cochrane Database of Systematic Reviews (Online)*, No.7, (July 2010), CD000174, 1469-493X.
- Groenendaal, F., Termote, J. U., Heide-Jalving, M., van Haastert, I. C., & de Vries, L. S. (2010). Complications affecting preterm neonates from 1991 to 2006: what have we gained? *Acta Paediatrica*, Vol.99, No.3, (March 2010), pp. (354-358), ISSN 0803-5253.
- Hadi, H. A. (1984). Fetal cerebral maturation in hypertensive disorders of pregnancy. *Obstetrics and Gynecology*, Vol.63, No.2, (February 1984), pp. (214-219), ISSN 0029-7844.
- Haynes, R. L., Borenstein, N. S., Desilva, T. M., Folkerth, R. D., Liu, L. G., Volpe, J. J. et al. (2005). Axonal development in the cerebral white matter of the human fetus and infant. *The Journal of comparative Neurology*, Vol.484, No.2, (April 2005), pp. (156-167), ISSN 0021-9967.
- Haynes, R. L., Folkerth, R. D., Trachtenberg, F. L., Volpe, J. J., & Kinney, H. C. (2009). Nitrosative stress and inducible nitric oxide synthase expression in periventricular leukomalacia. *Acta neuropathologica*, Vol.118, No.3, (September 2009), pp. (391-399), ISSN 0001-6322.
- Holling, E. E. & Leviton, A. (1999). Characteristics of cranial ultrasound white-matter echolucencies that predict disability: a review. *Developmental Medicine and Child Neurology*, Vol.41, No.2, (February 1999), pp. (136-139), ISSN 0012-1622.
- Ito, M., Itakura, A., Ohno, Y., Nomura, M., Senga, T., Nagasaka, T. et al. (2002). Possible activation of the renin-angiotensin system in the fetoplacental unit in preeclampsia. *The Journal of Clinical Endocrinology and Metabolism*, Vol.87, No.4, (April 2002), pp. (1871-1878), ISSN 0021-972X.

- Jim, W. T., Chiu, N. C., Chen, M. R., Hung, H. Y., Kao, H. A., Hsu, C. H. et al. (2005). Cerebral hemodynamic change and intraventricular hemorrhage in very low birth weight infants with patent ductus arteriosus. *Ultrasound in Medicine & Biology*, Vol.31, No.2, (February 2005), pp. (197-202), ISSN 0301-5629.
- Keeney, S. E., Adcock, E. W., & McArdle, C. B. (1991). Prospective observations of 100 high-risk neonates by high-field (1.5 Tesla) magnetic resonance imaging of the central nervous system. II. Lesions associated with hypoxic-ischemic encephalopathy. *Pediatrics*, Vol.87, No.4, (April 1991), pp. (431-438), ISSN 0031-4005.
- Khawaja, O. & Volpe, J. J. (2008). Pathogenesis of cerebral white matter injury of prematurity. *Archives of Disease in Childhood. Fetal and Neonatal Edition*, Vol.93, No.2, (March 2008), pp. (F153-F161), ISSN 1359-2998.
- Kusters, C. D., Chen, M. L., Follett, P. L., & Dammann, O. (2009). "Intraventricular" hemorrhage and cystic periventricular leukomalacia in preterm infants: how are they related? *Journal of Child Neurology*, Vol.24, No.9, (September 2009), pp. (1158-1170), ISSN 0883-0738.
- Larroche, J. C. (1972). Post-haemorrhagic hydrocephalus in infancy. Anatomical study. *Biology of the Neonate*, Vol.20, No.3, pp. (287-299). ISSN 0006-3126.
- Larroque, B., Marret, S., Ancel, P. Y., Arnaud, C., Marpeau, L., Supernant, K. et al. (2003). White matter damage and intraventricular hemorrhage in very preterm infants: the EPIPAGE study. *The Journal of Pediatrics*, Vol.143, No.4, (October 2003), pp. (477-483), ISSN 0022-3476.
- Lou, H. C. (1988). The "lost autoregulation hypothesis" and brain lesions in the newborn--an update. *Brain & Development*, Vol.10, No.3, (1988), pp. (143-146), ISSN 0387-7604.
- Luu, T. M., Ment, L. R., Schneider, K. C., Katz, K. H., Allan, W. C., & Vohr, B. R. (2009). Lasting effects of preterm birth and neonatal brain hemorrhage at 12 years of age. *Pediatrics*, Vol.123, No.3, (March 2009), pp. (1037-1044), ISSN 0031-4005.
- Maalouf, E. F., Duggan, P. J., Counsell, S. J., Rutherford, M. A., Cowan, F., Azzopardi, D. et al. (2001). Comparison of findings on cranial ultrasound and magnetic resonance imaging in preterm infants. *Pediatrics*, Vol.107, No.4, (April 2001), pp. (719-727), ISSN 0031-4005.
- Mathews, T. J., Minino, A. M., Osterman, M. J., Strobino, D. M., & Guyer, B. (2011). Annual summary of vital statistics: 2008. *Pediatrics*, Vol.127, No.1, (January 2011), pp. (146-157), ISSN 0031-4005.
- Ment, L. R., Bada, H. S., Barnes, P., Grant, P. E., Hirtz, D., Papile, L. A. et al. (2002). Practice parameter: neuroimaging of the neonate: report of the Quality Standards Subcommittee of the American Academy of Neurology and the Practice Committee of the Child Neurology Society. *Neurology*, Vol.58, No.12, (June 2002), pp. (1726-1738), ISSN 0028-3878.
- Mohamed, M. A. & Aly, H. (2010). Transport of premature infants is associated with increased risk for intraventricular haemorrhage. *Archives of Disease in Childhood. Fetal and Neonatal Edition*, Vol.95, No.6, (November 2010), pp. F403-F407, ISSN 1359-2998.
- Murata, Y., Itakura, A., Matsuzawa, K., Okumura, A., Wakai, K., & Mizutani, S. (2005). Possible antenatal and perinatal related factors in development of cystic periventricular leukomalacia. *Brain & Development*, Vol.27, No.1, (January 2005), pp. (17-21), ISSN 0387-7604.

- Murphy, B. P., Inder, T. E., Rooks, V., Taylor, G. A., Anderson, N. J., Mogridge, N. et al. (2002). Posthaemorrhagic ventricular dilatation in the premature infant: natural history and predictors of outcome. *Archives of Disease in Childhood. Fetal and Neonatal Edition*, Vol.87, No.1, (July 2002), pp. F37-F41, ISSN 1359-2998.
- Oka, A., Belliveau, M. J., Rosenberg, P. A., & Volpe, J. J. (1993). Vulnerability of oligodendroglia to glutamate: pharmacology, mechanisms, and prevention. *The Journal of Neuroscience*, Vol.13, No.4, (April 1993), pp. (1441-1453), ISSN 0270-6474.
- Papile, L. A. (1997). Intracranial hemorrhage. In: *Neonatal-Perinatal Medicine. Diseases of the Fetus and Infant*, Fanaroff, A.A. & Martin, R. J. (Eds.), Mosby year Book, ISBN 978-0-323-06545-0, St. Louis.
- Papile, L. A., Burstein, J., Burstein, R., & Koffler, H. (1978). Incidence and evolution of subependymal and intraventricular hemorrhage: a study of infants with birth weights less than 1,500 gm. *The Journal of Pediatrics*, Vol.92, No.4, (April 1978), pp. (529-534), ISSN 0022-3476.
- Patra, K., Wilson-Costello, D., Taylor, H. G., Mercuri-Minich, N., & Hack, M. (2006). Grades I-II intraventricular hemorrhage in extremely low birth weight infants: effects on neurodevelopment. *The Journal of Pediatrics*, Vol.149, No.2, (August 2006), pp. (169-173), ISSN 0022-3476.
- Perlman, J. M., McMenamin, J. B., & Volpe, J. J. (1983). Fluctuating cerebral blood-flow velocity in respiratory-distress syndrome. Relation to the development of intraventricular hemorrhage. *The New England Journal of Medicine*, Vol.309, No.4, (July 1983), pp. (204-209), ISSN 0028-4793.
- Perry, E. H., Bada, H. S., Ray, J. D., Korones, S. B., Arheart, K., & Magill, H. L. (1990). Blood pressure increases, birth weight-dependent stability boundary, and intraventricular hemorrhage. *Pediatrics*, Vol.85, No.5, (May 1990), pp. (727-732), ISSN 0031-4005.
- Pidcock, F. S., Graziani, L. J., Stanley, C., Mitchell, D. G., & Merton, D. (1990). Neurosonographic features of periventricular echodensities associated with cerebral palsy in preterm infants. *The Journal of Pediatrics*, Vol.116, No.3, (March 1990), pp. (417-422), ISSN 0022-3476.
- Pryds, O., Greisen, G., Lou, H., & Friis-Hansen, B. (1989). Heterogeneity of cerebral vasoreactivity in preterm infants supported by mechanical ventilation. *The Journal of Pediatrics*, Vol.115, No.4, (October 1989), pp. (638-645), ISSN 0022-3476.
- Rabe, H., Reynolds, G., & Diaz-Rossello, J. (2004). Early versus delayed umbilical cord clamping in preterm infants. *Cochrane Database of Systematic Reviews (Online)*, No.4, (October 2004), CD003248, ISSN 1469-493X.
- Resch, B., Vollaard, E., Maurer, U., Haas, J., Rosegger, H., & Muller, W. (2000). Risk factors and determinants of neurodevelopmental outcome in cystic periventricular leukomalacia. *European Journal of Pediatrics*, Vol.159, No.9, (September 2000), pp. (663-670), ISSN 0340-6199.
- Riskin, A., Riskin-Mashiah, S., Bader, D., Kugelman, A., Lerner-Geva, L., Boyko, V. et al. (2008). Delivery mode and severe intraventricular hemorrhage in single, very low birth weight, vertex infants. *Obstetrics and Gynecology*, Vol.112, No.1, (July 2008), pp. (21-28), ISSN 0029-7844.
- Roelants-van Rijn, A. M., Groenendaal, F., Beek, F. J., Eken, P., van Haastert, I. C., & de Vries, L. S. (2001). Parenchymal brain injury in the preterm infant: comparison of

- cranial ultrasound, MRI and neurodevelopmental outcome. *Neuropediatrics*, Vol.32, No.2, (April 2001), pp. (80-89), ISSN 0174-304X.
- Rorke, L. B. (1992). Anatomical features of the developing brain implicated in pathogenesis of hypoxic-ischemic injury. *Brain Pathology*, Vol.2, No.3, (July 1992), pp. (211-221), ISSN 1015-6305.
- Shankaran, S., Papile, L. A., Wright, L. L., Ehrenkranz, R. A., Mele, L., Lemons, J. A. et al. (1997). The effect of antenatal phenobarbital therapy on neonatal intracranial hemorrhage in preterm infants. *The New England Journal of Medicine*, Vol.337, No.7, (August 1997), pp. (466-471), ISSN 0028-4793.
- Sherlock, R. L., Anderson, P. J., & Doyle, L. W. (2005). Neurodevelopmental sequelae of intraventricular haemorrhage at 8 years of age in a regional cohort of ELBW/very preterm infants. *Early Human Development*, Vol.81, No.11, (November 2005), pp. (909-916), ISSN 0378-3782.
- Soul, J. (2008). Intracranial Hemorrhage and Periventricular Leukomalacia. In: *Manual of Neonatal Care*, Cloherty, J.P., Eichenwald, E. C., & Stark, A. R. (Eds.), pp. (500-518), Lippincott Williams & Wilkins, ISBN 978-0-7817-6984-6, Philadelphia, USA.
- Stevenson, D. K., Wright, L. L., Lemons, J. A., Oh, W., Korones, S. B., Papile, L. A. et al. (1998). Very low birth weight outcomes of the National Institute of Child Health and Human Development Neonatal Research Network, January 1993 through December 1994. *American Journal of Obstetrics and Gynecology*, Vol.179, No.6 Pt 1, (December 1998), pp. (1632-1639), ISSN 0002-9378.
- Stoll, B. J., Hansen, N. I., Bell, E. F., Shankaran, S., Laptook, A. R., Walsh, M. C. et al. (2010). Neonatal outcomes of extremely preterm infants from the NICHD Neonatal Research Network. *Pediatrics*, Vol.126, No.3, (September 2010), pp. (443-456), ISSN 0031-4005.
- Takashima, S. & Tanaka, K. (1978). Development of cerebrovascular architecture and its relationship to periventricular leukomalacia. *Archives of Neurology*, Vol.35, No.1, (January 1978), pp. (11-16), ISSN 0003-9942.
- van de Bor, M. & den Ouden, L. (2004). School performance in adolescents with and without periventricular-intraventricular hemorrhage in the neonatal period. *Seminars in perinatology*, Vol.28, No.4, (August 2004), pp. (295-303), ISSN 0146-0005.
- Veyrac, C., Couture, A., Saguintaah, M., & Baud, C. (2006). Brain ultrasonography in the premature infant. *Pediatric Radiology*, Vol.36, No.7, (July 2006), pp. (626-635), ISSN 0301-0449.
- Volpe, J. J. (1990). Brain injury in the premature infant: is it preventable? *Pediatric research*, Vol.27, No.6 Suppl, pp. S28-S33, ISSN 0031-3998.
- Volpe, J. J. (1998). Neurologic outcome of prematurity. *Archives of Neurology*, Vol.55, No.3, (March 1998), pp. (297-300), ISSN 0003-9942.
- Volpe, J. J. (2003). Cerebral white matter injury of the premature infant-more common than you think. *Pediatrics*, Vol.112, No.1 Pt 1, (July 2003), pp. (176-180), ISSN 0031-4005.
- Volpe, J. J. (2008). Intracranial Hemorrhage: Germinal matrix-intraventricular hemorrhage of the premature infant. In: *Neurology of the newborn*, Volpe, J.J. (Ed.), pp. (517-588), Saunders, ISBN 1-4160-3995-3, Philadelphia, USA.
- Woodward, L. J., Anderson, P. J., Austin, N. C., Howard, K., & Inder, T. E. (2006). Neonatal MRI to predict neurodevelopmental outcomes in preterm infants. *The New England Journal of Medicine*, Vol.355, No.7, (August 2006), pp. (685-694), ISSN 0028-4793.

© 2012 The Author(s). Licensee IntechOpen. This is an open access article distributed under the terms of the [Creative Commons Attribution 3.0 License](#), which permits unrestricted use, distribution, and reproduction in any medium, provided the original work is properly cited.