

# Bronchoscopic Balloon Dilation (BBD) for Benign Tracheobronchial Stenosis

Masayuki Tanahashi, Hiroshi Niwa, Haruhiro Yukiue,  
Eriko Suzuki, Hiroshi Haneda, Naoko Yoshii and Hisanori Kani  
*Division of Thoracic Surgery, Respiratory Disease Center,  
Seirei Mikatahara General Hospital  
Japan*

## 1. Introduction

Bronchoscopic balloon dilation (BBD) is a useful method of treating tracheobronchial stenosis. Tracheobronchial stenosis in adults can arise from benign or malignant disease. Benign stenosis causes include sarcoidosis, tuberculosis, Wegener's granulomatosis, trauma, berylliosis, and foreign body reaction. Furthermore, it can arise after prolonged endotracheal intubation, after sleeve resection or after lung transplantation. Despite adequate systemic therapy, airway stenosis may progress due to tuberculosis or sarcoidosis. In infants, prior use of endobronchial and tracheostomy tubes or congenital stenosis from complete cartilaginous rings are the primary reasons for such stenosis (McDonald & Stocks, 1965; Parkin et al., 1976). Subglottic or tracheal sites are thus common and may continue to present serious and often fatal respiratory problems in infants. In adults, the etiologies are variable and the stricture can happen in any part of the airway. Tracheobronchial stenosis may produce symptoms such as dyspnea, cough, wheeze, stridor, or recurrent lower respiratory tract infections, and these symptoms cause the airway stricture to mimic asthma. There are various treatments including surgical resection, laser resection, and bougie dilation during rigid bronchoscopy. For lesions causing impending respiratory failure, surgical resection or stent placement is the most prudent treatment. In less urgent conditions, BBD has been considered a simple, rapid, and safe method to restore airway caliber. BBD has been used alone or in combination with other modalities such as laser resection, cryotherapy, and electrocautery. In 1984, Cohen et al. (Cohen et al., 1984) reported a successful balloon dilation through a tracheostomy tube under propylidone injection for a stricture after segmental resection of congenital stenosis in an infant. In 1987, Fowler et al. (Fowler et al., 1987) described bronchoscopic balloon dilation using a rigid bronchoscope for anastomotic stenosis in an adult who had had a sleeve resection for an endobronchial squamous cell carcinoma of the right main-stem bronchus 2 years earlier. The following year Carlin et al. (Carlin et al., 1988) reported two cases of bronchial stenosis successfully treated with a combination of bronchoscopic balloon dilation and Nd-YAG laser photoresection with a rigid bronchoscope. In 1991, balloon dilation using flexible bronchoscopy was described for the first time by Nakamura et al. (Nakamura et al., 1991). They treated two patients with tuberculous bronchial stenosis through a flexible bronchoscope under local anesthesia. Since then, several reports of BBD have been published (Ball et al., 1991; Keller &

Frost, 1992; Carre et al., 1994; Fouty et al., 1994; Ferretti et al., 1995; Sheski & Mathur, 1998). The major advantages of BBD are lower morbidity and mortality than surgery, stent placement, or bougienage. BBD has thus become an accepted treatment for benign tracheobronchial stenosis.

## 2. Indications and contraindications

Balloon dilation has an indication in almost all benign tracheobronchial strictures. The bronchial stenosis caused by tuberculosis finally heals with fibrous scarring through a submucosal infiltration by tubercles and lymphocytes, followed by ulceration and growth of granulation tissue (Bugher et al., 1937; Wilson, 1945; Auerbach, 1949; Judd, 1947). Stenosis from other medical causes such as Wegener's granulomatosis, sarcoidosis (Fouty et al., 1994; Olsson et al., 1979), berylliosis, post-tracheostomy, and complicated tracheobronchial anastomosis may also ultimately result in fibrous scars. Such fibrotic stenosis is a good indication for BBD. Visual characteristics such as pale or nonedematous mucosa may suggest a lesion with little inflammation and a greater likelihood of successful opening (Ferretti et al., 1995; Brown et al., 1987). In particular, inoperable long segmental stenosis is well treated by BBD. On the other hand, if the bronchial cartilage is destroyed, the success rate of BBD is low (Carre et al., 1994). An airway stricture with tracheobronchomalacia usually requires combination therapy with another therapeutic modality such as stent placement to maintain airway patency. Iwamoto et al. (Iwamoto et al., 2004) reported that endobronchial ultrasonography (EBUS) imaging was useful in making a diagnosis of cartilaginous tracheobronchomalacia and in aiding the decision as to whether or not a stent was needed. In lung transplantation, this endobronchial stenosis may be a result of airway rejection or due to ischemic changes at the site of the bronchial implantation. When there must be an ongoing process such as airway rejection or ischemia, even if repeated BBD is performed, endobronchial stenosis is often recurrent. In malignancy, balloon dilation is performed in combination with other modalities such as laser resection, stent placement, cryotherapy, and electrocautery (Hautmann et al., 2001). Assessment of the patient's coagulation status before the procedure is important because bleeding is a frequent complication of BBD. The decision to continue or withhold anticoagulant or antiplatelet drugs should reflect a balance of the consequences of periprocedural hemorrhage versus the risk of periprocedural vascular complications. Aspirin, NSAIDs, ibuprofen, clopidigrel, and warfarin should be discontinued at least 7-10 days, 3 days, 24 hours, 7-10 days, and 3-5 days before BBD, respectively (Douketis et al., 2008; Kearon et al., 1997; Larson et al., 2005). Nonacetylated NSAIDs can be continued in the periprocedural period. If the patient cannot stop taking any anticoagulant or antiplatelet medication, BBD should be performed prudently.

## 3. Technique

BBD is generally performed under topical anesthesia and conscious sedation, but BBD for tracheal stenosis will be performed better under general anesthesia with laryngeal mask ventilation or tracheal intubation, because long-term respiratory arrest is needed during inflation and this would cause great anxiety to the patient. Patients are maintained with 100% oxygen during the procedure and are hyperventilated immediately before balloon inflation.

After local or general anesthesia, bronchoscopy is first performed with a diagnostic bronchoscope (BF-260; Olympus, Tokyo) or a therapeutic bronchoscope (BF-1T60; Olympus, Tokyo) to assess and localize the airway stenosis before balloon dilatation. Bronchoscopy provides information about not only the localization and extent of the stenosis but also the condition of the mucosa and influence of extra-bronchial lesions. Radiopaque markers are placed on the surface of the skin to identify the proximal and distal limits of the stenosis. A flexible, 0.035-inch guidewire (Jagwire™ Plus; Boston Scientific/Medi-tech, Natick, MA) is then inserted through the working channel of the bronchoscope and is passed through the stenosis (Fig. 1a). This is performed under fluoroscopy to ensure that the guidewire does not extend to the pleura. With the guidewire held in place, the bronchoscope is withdrawn. The placement of the guidewire should be confirmed with fluoroscopy after the bronchoscope has been removed. Next, a balloon catheter (CRE™ Fixed Wire & Wire Guided Balloon Dilators, Hurricane™ RX Biliary Balloon Dilatation Catheter, Max Force™ TTS; Boston Scientific/Medi-tech, Natick, MA) is selected, based on balloon length and diameter in relation to the stenosis dimensions. These balloon catheters are made of polyamide and have radiopaque markers at the proximal and distal ends of the balloon. They are available in variety of size ranges. The balloon is constructed of such material that the nominal diameter of the balloon is proportional to the inflation pressure (3-12 atm). The balloon is inflated based on that particular balloon catheter's characteristics. The diameter of the balloon is chosen to be the same diameter as that of the lumen measured at the proximal region of the normal airway. The length of the balloon is at least 0.5cm greater than that of stenotic segment, since the entire stenosis will be dilated when the balloon is inflated. If the inflated balloon length is insufficient, the balloon can slip out of the stenosis. If the balloon length is too great, there is a potential for airway damage. This diameter and length of the balloon are measured by both bronchoscope and chest CT scans. The required width can be estimated from a comparison of the bronchoscope diameter to that of the stenosis. The required length of balloon is estimated by passing the bronchoscope through the stenosis and by measuring the distance between the proximal and distal limits of the obstruction. Three-dimensional CT is a useful noninvasive evaluation for BBD (Rooney et al., 2005). It allows for preoperative determination of balloon size and length, even if the bronchoscope cannot be passed through the obstruction. It can allow an accurate determination of the degree and length of stenosis, an evaluation of the airway distal to the stenosis and show the presence of multiple stenoses as well as the relationships with mediastinal structures. Furthermore, it is a useful noninvasive technique for postoperative follow-up. It can not only evaluate the effect of BBD, but also detect complications related to BBD such as a deep laceration, pneumomediastinum or mediastinal bleeding (Y. H. Kim et al., 2006). When the stenosis is too narrow for a balloon catheter, a smaller balloon catheter is used first to create a passage for the larger balloon catheter and a wider and longer balloon may be used by exchanging the balloon catheter for another over the guidewire. Under fluoroscopic guidance, an appropriately sized balloon catheter is then advanced over the guidewire and positioned such that the balloon markers are properly located with respect to the stenosis (Fig. 1b). The bronchoscope is again inserted to visualize the stenosis and the balloon catheter (Fig. 1c). The balloon is then inflated with a dilute nonionic contrast medium (Iopamidol; Bracco, Milan), and the results are observed via both fluoroscopy and bronchoscopy (Fig. 1d). The inflation time is between approximately 30 seconds and 2 minutes, depending on the clinical tolerance and consequences on cutaneous oxygen saturation. Occasionally the initial inflation times must be very short, but they can be increased as dilatation proceeds. Nonionic

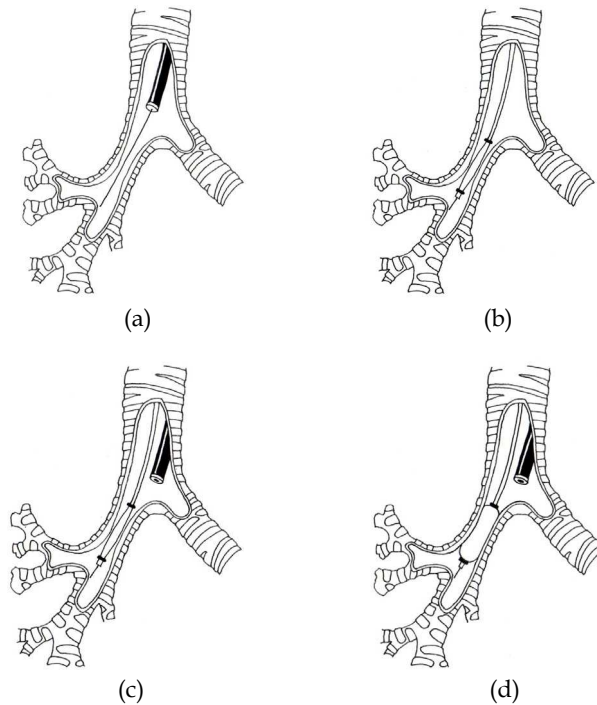


Fig. 1. a) A guidewire is passed beyond the stenosis, using bronchoscopy and fluoroscopy to ensure that the guidewire does not extend to the pleura and then the bronchoscope is withdrawn, leaving the guidewire in place. b) The balloon catheter is advanced over a guidewire and positioned under fluoroscopy. c) Proper positioning of the proximal end of the balloon is confirmed with visualization through the bronchoscope. d) Bronchoscopy allows direct monitoring of balloon inflation and deflation with fluoroscopy.

contrast media are safe for the bronchus because bronchography using nonionic contrast media instead of propylidone is performed safely (Morcos et al., 1989, 1990; Riebel & Wartner, 1990).

If the diameter of the deflated catheter is less than that of the working channel, a bronchoscope is not needed to remove before the balloon catheter is inserted. A balloon catheter is passed over the guidewire through the working channel and positioned within the narrowed segment of the airway under bronchoscopic visualization (Fig. 2a, Fig. 2b).

During inflation, a balloon inflation device with pressure-gauge monitor (Alliance™ Inflation Device; Boston Scientific/Medi-tech, Natick, MA) is used to inflate the balloon and to monitor the inflation pressure. Success is defined as loss of the typical waist made in the wall of the balloon by the stenosis as observed by fluoroscopy and a stable increase in tracheobronchial diameter of the stenotic segment by bronchoscopy. If necessary, the balloon catheter then can be repositioned or replaced by a larger sized balloon catheter, and the procedure repeated until the desired effect is obtained. Adjunctive treatments such as laser vaporization or stent placement may precede or follow balloon dilation. Patient who

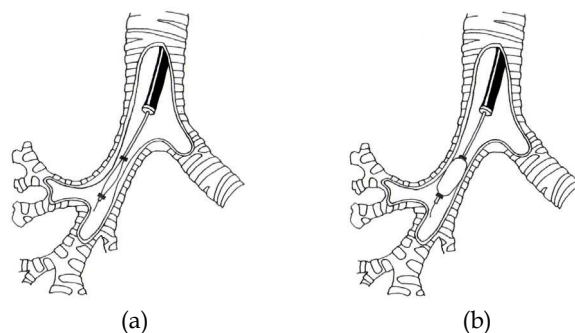


Fig. 2. a) If the diameter of the deflated catheter is less than that of the working channel, the bronchoscope need not be removed before the balloon catheter is inserted. A balloon catheter is passed over the guidewire through the working channel and positioned within the narrowed segment of the airway under bronchoscopic visualization. b) The balloon is inflated and deflated, and the results are observed via both bronchoscopy and fluoroscopy.

underwent BBD usually discharges the next day of the procedure. If a complication such as laceration occurs, the patient needs to be hospitalized for several days to monitor his conditions. Follow-up bronchoscopy is performed about 2-4 weeks after dilation. If the desired airway diameter is not attained or recurrent stenosis is observed, the balloon dilation is repeated until the desired effect is obtained.

#### 4. Complications

During BBD, chest pain, bronchospasm and atelectasis have been reported (Brown et al., 1987; Elkerbout et al., 1993; Hebra et al., 1991). Excessive balloon inflation may lacerate or rupture the airway, causing bleeding, pneumothorax, pneumomediastinum, or mediastinitis. As far as we know, there are few reports describing lacerations of the tracheobronchial tree after balloon dilation. One case of rupture requiring surgical management has been reported (Knott et al., 2004). However, other lacerations except for this one healed spontaneously and there were no clinical problems (Y. H. Kim et al., 2006; J. H. Kim et al., 2007; K. H. Lee et al., 2002). No patients have died during or from problems related to BBD.

#### 5. Results

Several reports of BBD in adults are available. Technical success is defined by successful passing of a balloon catheter through a stenosis. Short-term clinical success is defined as the loss of the typical waist in the wall of the balloon by the stenosis by fluoroscopy, an increase in tracheobronchial diameter of the stenotic segment immediately after bronchoscopy, and improvement of the patient's clinical symptoms. Long-term success is based on the patient remaining asymptomatic. Recurrence is defined as the return of symptoms. Some patients have undergone radiographic evaluation with chest roentgenography or CT scan, pulmonary function testing, or bronchoscopy as part of follow-up care. The short-term results of balloon dilation to treat benign tracheobronchial stenosis have been favorable. Clinical success rates of 63% to 100% have been reported

(Carre et al., 1994; Ferretti et al., 1995; Sheski & Mathur, 1998; J. H. Kim et al., 2007; K. W. Lee et al., 1999; Mayse et al., 2004). However, the long-term efficacy of balloon dilation in a large group of patients has rarely been reported. According to the reports, recurrence rates range from 30% to 80% (Carre et al., 1994; Ferretti et al., 1995; Iwamoto et al., 2004; J. H. Kim et al., 2007; K. H. Lee et al., 2002; K. W. Lee et al., 1999).

Kim et al. (J. H. Kim et al., 2007) reported that a group of patients with tracheobronchial lacerations (n=64) showed better cumulative airway patency than a group without tracheobronchial lacerations (n=60) (medium patency duration, 24 vs. 4 months, respectively). They concluded that better clinical outcomes might occur following superficial or deep lacerations after BBD in patients with a benign tracheobronchial stricture. Lee et al. (K. H. Lee et al., 2002) reported that initial symptomatic improvement after BBD was achieved in 83% (49/59) of patients, however, during a mean of 32 months follow-up the recurrence rate of BBD was high (80%, 39/49). They also reported that the secondary patency rate with repeat balloon dilation at 32 months was 43%, a relatively acceptable long-term result. Lee et al. (K. W. Lee et al., 1999) reported that improvements in dyspnea after BBD for tuberculous bronchial stenosis occurred immediately in 73% (11/15), 73% after 1 month, 73% after 6 months, 64% after 1 year, 64% after 3 years, and 42% after 6 years. They concluded that the long-term results of BBD were acceptable.

We performed BBD in eleven sessions for benign tracheobronchial stenoses in 8 patients between December 1987 and March 2009. The patients were four males and four females, and ranged in age from 30 to 60 years. The indications were tuberculous stenosis (n=6), post-tracheostomy stricture (n=1) and post-bronchoplasty anastomotic stenosis (n=1). The sites of stenosis were the trachea (n=4), left main bronchus (n=3), right main bronchus (n=2), left upper bronchus (n=1), and left lower bronchus (n=1). Stenoses ranged in diameter from pinhole (more than 90%) to 70%, and in length from 0.5 to 6 cm. They were followed up for 3-48 months (mean follow-up 26.7 months) with radiographic evaluation by chest roentgenography or CT scan, pulmonary function testing, or bronchoscopy after BBD. BBD was performed under local anesthesia in 3 patients and general anesthesia in 5 patients. For tracheal stenosis, 8-18 mm diameter balloons (55-80 mm long) were used. For bronchial stenosis, 4-12 mm diameter balloons (20-55 mm long) were used. The results in seven of eight treated patients were successful in maintaining airway patency. The only one unsuccessful patient was one of post-tracheostomy stenosis resulting in secondary tracheomalacia, and this patient needed T-tube stent placement to support the weakened cartilage and prevent dynamic airway collapse. As regards complications, there were four patients with longitudinal tracheal or bronchial lacerations, but all lacerations healed spontaneously after conservative treatment. Thus, a laceration should be regarded as an expected result of sufficient balloon dilation, not as a major complication. There were no recurrences during 3-48 months follow up period in our study. Tables 1 and 2 summarize our experience. Figures 3 to 12 show the patients with tracheobronchial stenosis who underwent BBD.

Respiratory functional improvement can be obtained after BBD, as well as improved tracheobronchial diameter. Lee et al. (K. H. Lee et al., 2002) reported significant improvements in the mean forced vital capacity (FVC), forced expiratory volume in 1 second (FEV1), and forced expiratory flow 25%-75% after technically and clinically successful balloon dilation in 49 patients. Lee et al. (K. W. Lee et al., 1999) reported that improvement of dyspnea occurred immediately in 11 of 15 patients (73%) after balloon

Patient	Age	Sex	C.C.	Etiology	Area	Length	Severity
1	42	F	DOE	Tb	Tr	4cm	70%
2	60	F	DOE	Tb	Tr	3cm	70%
3	30	M	#	Tracheostomy	Tr	6cm	70%
4	33	F	Cough, Sputum	Tb	Lt-MB	2cm	Pinhole
5	19	M	DOE	Tb	Lt-MB Lt-UB	2cm 0.5cm	Pinhole Pinhole
6	38	M	DOE	Bronchoplasty	Rt-MB	1cm	Pinhole
7	48	F	DOE	Tb	Tr Rt-MB	6cm 2cm	80% pinhole
8	30	M	Cough, Stridor	Tb	Lt-MB Lt-LB	5cm 1cm	70% Pinhole

C.C.=Chief complaint, DOE=Dyspnea on exertion, #=Difficulty in removing tracheostomy tube, Tb=Tuberculosis, Tr=Trachea, Lt-MB left main bronchus, Lt-UB=left upper bronchus, Rt-MB=right main bronchus, Lt-LB=left lower bronchus

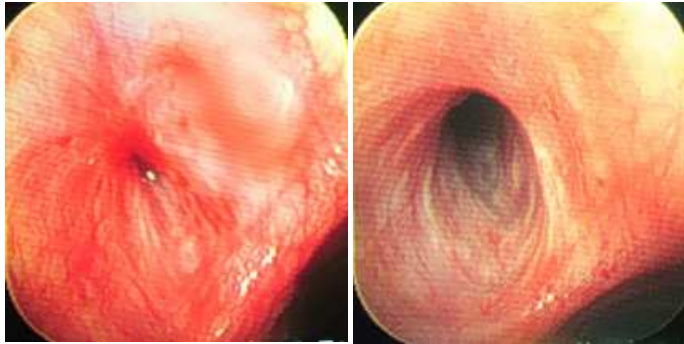Table 1. Patients underwent bronchoscopic balloon dilation

Patient	Anes.	Balloon Catheter (d×l, mm)	Pressure (atm)	Complications	Patency
1	G	18×55	3	None	3 mos good
2	G	12~15×55	3	Laceration	4 mos good
3	G	18 × 80	2~4	Laceration	Fair
4	L	10 × 40	4	None	3 yrs good
5	L	10×40, 12×55	3~4	None	3 yrs good
	L	10×20	3~4	None	3 yrs good
6	L	10×20	6	None	3 yrs good
7	G	8~18×80	3~8	Laceration	4 yrs good
	G	8~12×55	3~8	Laceration	4 yrs good
8	G	6~10×55	3~10	Laceration	2 yrs good
	G	4~6×20	7~12	None	2 yrs good

Anes.=anesthesia, G=general anesthesia, L=local anesthesia, d=diameter, l=length, atm=atmosphere, BBDs=balloon dilations, mos=months, yrs=years

Table 2. Details and results of bronchoscopic balloon dilation

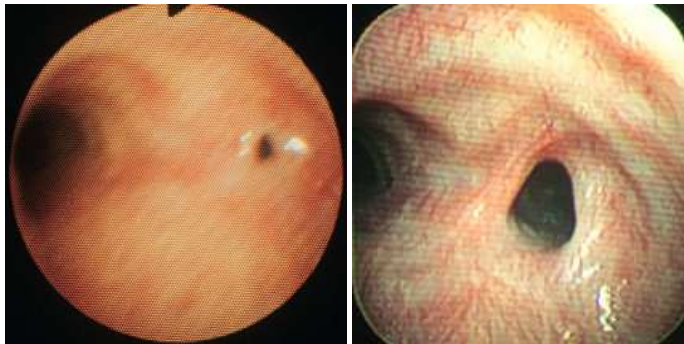
dilation and an increase of FEV1 or FVC of more than 15% after BBD was obtained in five of 13 patients after 1 or 2 days and that eight of the 13 patients (62%) showed improvement of FEV1 or FVC after 1 year. Hautmann et al. (Hautmann et al., 2001) reported that lung function analysis demonstrated a small but significant increase in FEV1, peak expiratory flow rate (PEFR), FEV1/FVC, and PaO2 within 72 hours after BBD in 42 patients with malignant tracheobronchial disease. In our study, the improvements in symptoms such as dyspnea, cough, and stridor following dilation were dramatic in most patients. Patients' respiratory status was evaluated before and after BBD by means of pulmonary function test and Hugh-Jones classification (Table 3). All patients showed improvements of FEV1, peak expiratory flow (PEF) and Hugh-Jones classification (Fig. 13). Thus, BBD is useful not only for increasing the tracheobronchial diameter of the stenotic segment but also for improving respiratory function and symptoms.



(a)

(b)

Fig. 3. Tuberculous bronchial stenosis of a 19-year-old man (patient 5). a) Pre-balloon dilation bronchoscopic view shows severe stenosis at the left main bronchus. The orifice is almost obstructed. b) Bronchoscopy three years after balloon dilation shows an almost normal airway. His symptoms immediately improved and he has done well.



(a)

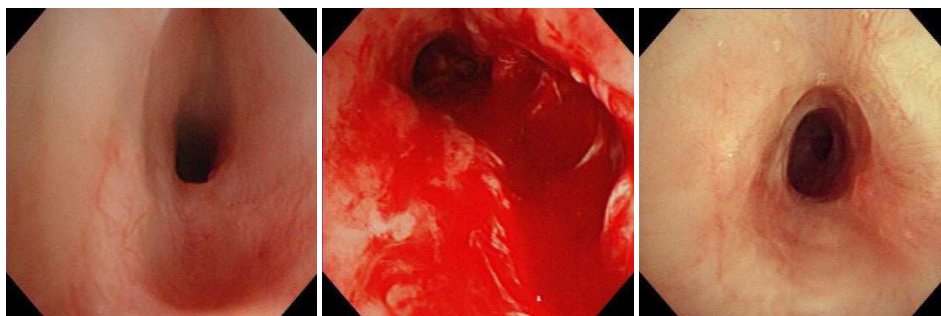
(b)

Fig. 4. Post-bronchoplastic stenosis of a 38-year-old man (patient 6). a) Pre-balloon dilation bronchoscopic view shows pinhole size opening of the right main bronchus. b) At follow up bronchoscopy 3 years after BBD an almost normal lumen of the right main bronchus is maintained. He is doing well without evident respiratory symptoms.



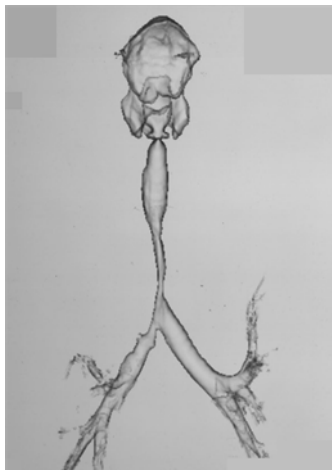

Fig. 5. Tuberculous tracheal and right main bronchial stenosis of a 48-year-old female (patient 7). She had progressive severe dyspnea at rest with continuous coughing and stridor. Three-dimensional reconstruction CT shows 60mm segment of 8mm diameter severe narrowing from upper trachea to right main bronchus.

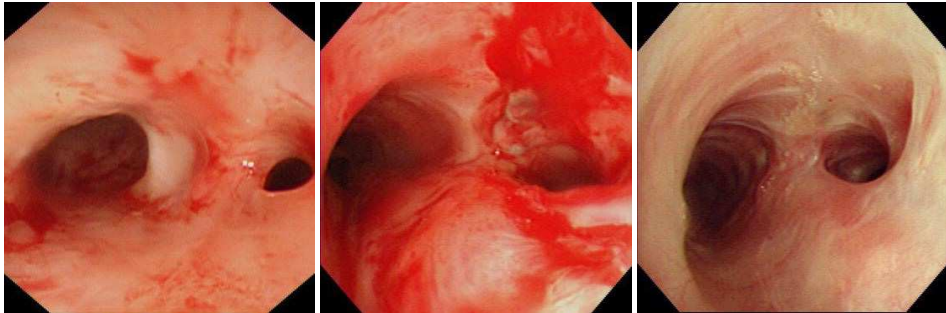


(a)

(b)

(c)

Fig. 6. a) Pre-balloon dilation bronchoscopic view of patient 7 shows severe long segmental stenosis at the trachea. b) Immediately after balloon dilation, a deep laceration is observed from the trachea to the right main bronchus at the membrane portion, but the patient is stable and asymptomatic. c) Two months later, the laceration is spontaneously healed and the airway is markedly wider than before dilation. Following the balloon dilation the patient is less dyspnetic at rest and can perform housework without becoming short of breath.

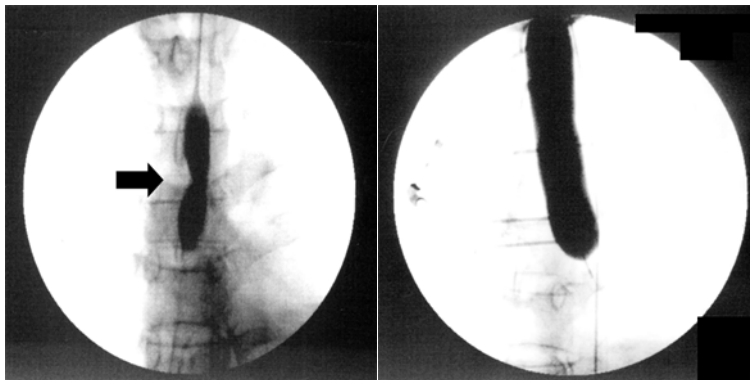


(a)

(b)

(c)

Fig. 7. a) Pre-balloon dilation bronchoscopic view of patient 7 shows severe stenosis of the right main bronchus. b) Immediately after balloon dilation, a deep laceration is observed at the right main bronchus. c) Bronchoscopic findings two months after dilation demonstrate that the laceration is spontaneously healed and the airway is significantly improved.



(a)

(b)

Fig. 8. a) Fluoroscopic image of patient 7 obtained at the beginning of balloon inflation clearly demonstrates a waist (arrow) on the wall of the balloon at the level of the severe part of the stenosis. b) Fluoroscopic image obtained at the end of the dilation no longer shows a waist.

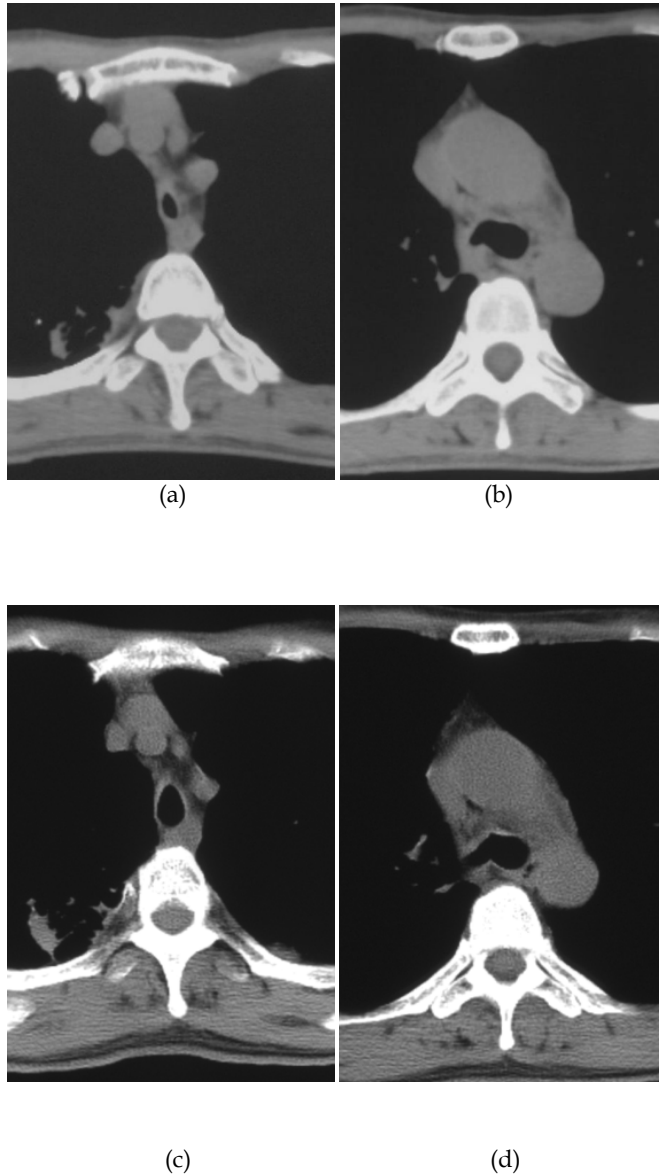


Fig. 9. Chest CT of patient 7 shows severe stenosis of the trachea (a) and the right main bronchus (b) before BBD. However, BBD brings a significant increase in the diameter of the trachea (c) and the right main bronchus (d).

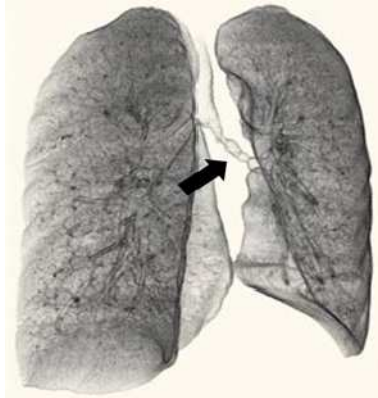


Fig. 10. Tuberculous stenosis of the left main bronchus and left lower bronchus of a 30-year-old male (patient 8). He developed continuous stridor and cough. Three-dimensional reconstruction CT shows irregular luminal narrowing from the left main bronchus to the left lower bronchus (arrow).

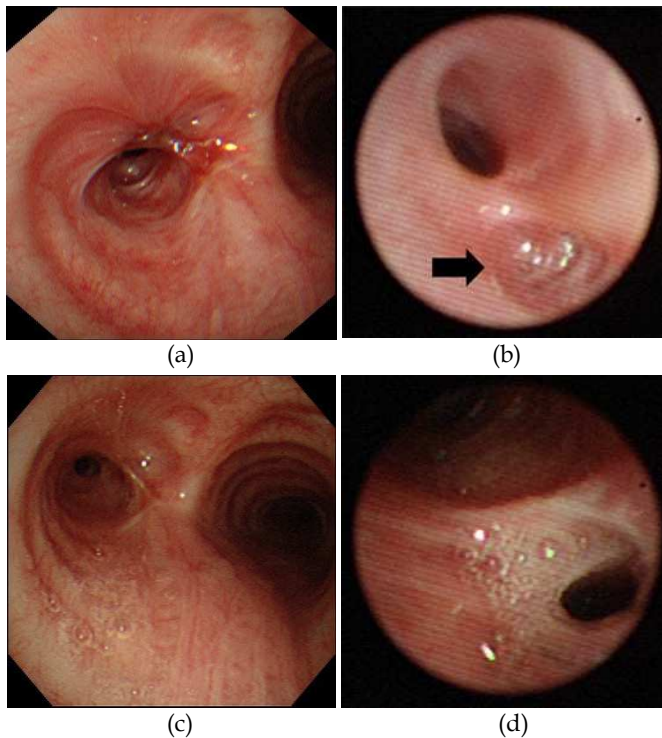


Fig. 11. a-b) Pre-balloon dilation bronchoscopic view of patient 8 shows severe stenosis at the left main bronchus (a) and the left lower bronchus (arrow in (b)). c-d) Bronchoscopic view shows improvement of the stenosis at the left main bronchus (c) and the left lower bronchus (d) after balloon dilation.

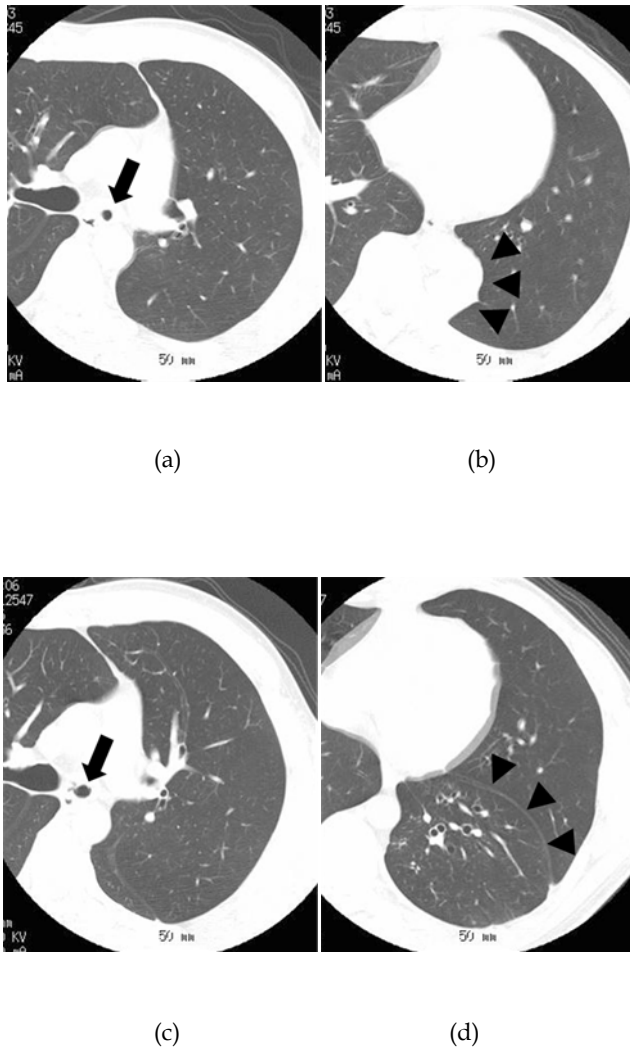


Fig. 12. a) Chest CT of patient 8 shows the stenosis of the left main bronchus (arrow). b) Chest CT shows the atelectasis of the left lower lobe caused by tuberculous bronchial stenosis (arrow heads). c) After balloon dilation. Chest CT shows increase of the diameter of the left main bronchus (arrow). d) After balloon dilation, the atelectasis is obliterated and the left lower lobe is expanded (arrow heads). He has been without symptoms and chest film evidence of atelectasis for 2 years.

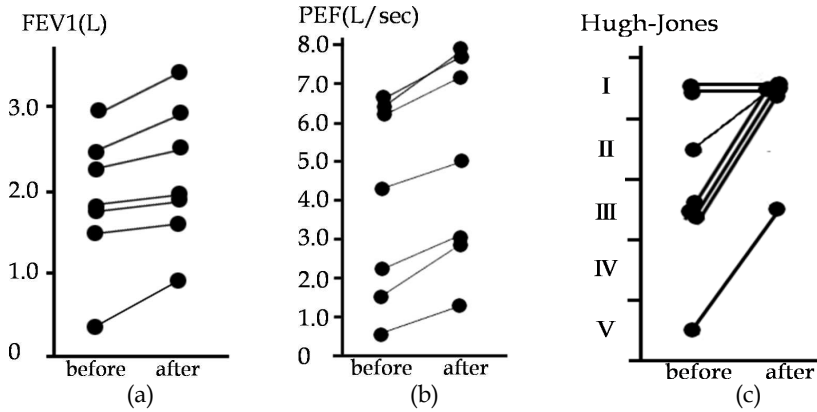


Fig. 13. All patients who underwent pulmonary function testing showed improvement of forced expiratory volume in 1 second (FEV1), peak expiratory flow (PEF) and Hugh-Jones classification.

I	The patient's breathing is as good as that of others of the same sex, age, and build while at work, on walking, or on climbing hills or stairs
II	The patient is able to walk with healthy persons of the same sex, age, and build on the level but is unable to keep up on hills or stairs
III	The patient is unable to keep up with healthy persons on the level but is able to walk a mile or more at a slower speed
IV	The patient is unable to walk more than about 100 yards on the level without a rest
V	The patient is breathless on talking or undressing or is unable to leave the house because of breathlessness

Table 3. Hugh-Jones classification

**6. Conclusion**

Bronchoscopic balloon dilation is a very useful therapy for benign tracheobronchial stenosis. The advantages of this procedure in comparison with other procedures are that it is minimally invasive, safe, and rapid. It can be performed under either local or general anesthesia. Balloon dilation can be performed safely and effectively because the balloon placement and inflation-deflation can be monitored via both fluoroscopy and bronchoscopy. A guidewire permits easy exchange of the balloon catheter. A relatively common complication is transmural laceration, but lacerations should be regarded as an expected result of sufficient balloon dilation and not as a major complication. No deaths have been attributed directly to balloon dilation alone. Only fibrous stenosis responds to balloon dilation alone; bronchial stenosis with coexisting tracheobronchomalacia usually requires combination therapy with another therapeutic modality such as stent placement to maintain bronchial patency. The procedure often needs to be repeated to achieve a satisfactory result.

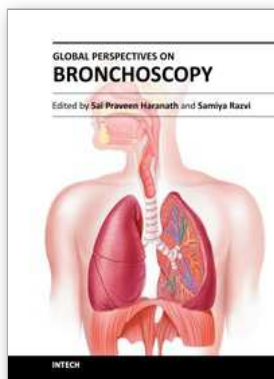
**7. References**

Auerbach, O. (1949). Tuberculosis of the trachea and major bronchi. *Am Rev Tuberc*, Vol.60, pp. 604-620.

- Ball, JB.; Delaney, JC.; Evans, CC.; Donnelly, RJ. & Hind, CRK. (1991). Endoscopic bougie and balloon dilatation of multiple bronchial stenoses: 10 year follow up. *Thorax*, Vol.46, pp. 933-935.
- Brown, SB.; Hedlund, GL.; Glasier, CM.; Williams, KD.; Greenwood, LH. & Gilliland, JD. (1987). Tracheobronchial stenosis in infants: Successful balloon dilatation therapy. *Radiology*, Vol.164, pp. 475-478.
- Bugher, JC.; Littig, J. & Culp, J. (1937). Tuberculous tracheobronchitis: its pathogenesis. *Am J Med Sci*, Vol.193, pp. 515-525.
- Carlin, BW.; Harrell, JH. & Moser, KM. (1988). The treatment of endobronchial stenosis using balloon catheter dilatation. *Chest*, Vol.93, No.6, pp. 1148-1151.
- Carre, P.; Rousseau, H.; Lombart, L.; Didier, A.; Dahan, M.; Fournial, G.; Leophonte, P. & the Toulouse Lung Transplantation Group. (1994). Balloon dilatation and self-expanding metal Wallstent insertion for management of bronchostenosis following lung transplantation. *Chest*, Vol.105, No.2, pp. 343-348.
- Cohen, MD.; Weber, TR. & Rao, CC. (1984). Balloon dilatation of tracheal and bronchial stenosis. *AJR*, Vol.142, pp. 477-478.
- Douketis, JD.; Berger, PB.; Dunn, AS.; Jaffer, AK.; Spyropoulos, AC.; Becker, RC. & Ansell, J. (2008). The perioperative management of antithrombotic therapy: American college of chest physicians evidence-based clinical practice guidelines (8<sup>th</sup> edition). *Chest*, Vol.133, No.6, pp. 299S-339S.
- Elkerbout, SC.; van Lingen, RA.; Gerritsen, J. & Roorda, RJ. (1993). Endoscopic balloon dilatation of acquired airway stenosis in newborn infants: a promising treatment. *Arch Dis Child*, Vol.68, pp. 37-40.
- Ferretti, G.; Jouvan, FB.; Thony, F.; Pison, C. & Coulomb, M. (1995). Benign noninflammatory bronchial stenosis: treatment with balloon dilatation. *Radiology*, Vol.196, pp. 831-834.
- Fouty, BW.; Pomeranz, M.; Thigpen, TP. & Martin, RJ. (1994). Dilatation of bronchial stenoses due to sarcoidosis using a flexible fiberoptic bronchoscope. *Chest*, Vol.106, No.3, pp. 677-680.
- Fowler, CL.; Aaland, MO. & Harris, FL. (1987). Dilatation of bronchial stenosis with Gruentzig balloon. *J Thorac Cardiovasc Surg*, vol.93, pp. 308-315.
- Hautmann, H.; Gamarra, F.; Pfeifer, KJ. & Huber, RM. (2001). Fiberoptic bronchoscopic balloon dilatation in malignant tracheobronchial disease: indications and results. *Chest*, Vol.120, No.1, pp. 43-49.
- Hebra, A.; Powell, DD.; Smith, CD. & Othersen, HB. (1991). Balloon tracheoplasty in children: results of a 15-year experience. *J Pediatr Surg*, Vol.26, No.8, pp. 957-961.
- Iwamoto, Y.; Miyazawa, T.; Kurimoto, N.; Miyazu, Y.; Ishida, A.; Matsuo, K. & Watanabe, Y. (2004). Interventional bronchoscopy in the management of airway stenosis due to tracheobronchial tuberculosis. *Chest*, Vol.126, No.4, pp. 1344-1352.
- Judd, AR. (1947). Tuberculous tracheobronchitis: a study of 500 consecutive cases. *J Thorac Surg*, Vol.16, pp. 512-523.
- Kearon, C. & Hirsh, J. (1997). Management of anticoagulation before and after elective surgery. *N Engl J Med*, Vol.336, No.21, pp. 1506-1511.
- Keller, C. & Frost, A. (1992). Fiberoptic bronchoplasty: Description of a simple adjunct technique for the management of bronchial stenosis following lung transplantation. *Chest*, Vol.102, No.4, pp. 995-998.

- Kim, JH.; Shin, JH.; Song, HY.; Shim, TS.; Ko, GY.; Yoon, HK. & Sung, KB. (2007). Tracheobronchial laceration after balloon dilation for benign strictures: incidence and clinical significance. *Chest*, Vol.131, No.4, pp. 1114-1117.
- Kim, YH.; Sung, DJ.; Cho, SB.; Chung, KB.; Cha, SH.; Park, HS. & Um, JW. (2006). Deep tracheal laceration after balloon dilation for benign tracheobronchial stenosis: case reports of two patients. *Br J Radiol*, Vol.79, pp. 529-535.
- Knott, PD.; Lorenz, RR.; Eliachar, I. & Murthy, SC. (2004). Reconstruction of a tracheobronchial tree disruption with bovine pericardium. *Int Cardiovasc Thorac Surg*, Vol.3, pp. 554-556.
- Larson, BJ.; Zumberg, MS. & Kitchens CS. (2005). A feasibility study of continuing dose-reduced warfarin for invasive procedures in patients with high thromboembolic risk. *Chest*, Vol.127, No.3, pp. 922-927.
- Lee, KH.; Ko, GY. Song, HY. Shim, TS. & Kim, WS. (2002). Benign tracheobronchial stenoses: long-term clinical experience with balloon dilation. *J Vasc Interv Radiol*, Vol.13, pp. 909-914.
- Lee, KW.; Im, JG.; Han, JK.; Kim, TK.; Park, JH. & Yeon, KM. (1999). Tuberculous stenosis of the left main bronchus: results of treatment with balloons and metallic stents. *J Vasc Interv Radiol*, Vol.10, No.3, pp. 352-358.
- Mayse, ML.; Greenheck, J.; Friedman, M. & Kovitz, KL. (2004). Successful bronchoscopic balloon dilation of nonmalignant tracheobronchial obstruction without fluoroscopy. *Chest*, Vol.126, No.2, pp. 634-637.
- McDonald, IH. & Stocks, JG. (1965). Prolonged nasotracheal intubation. *Br J Anaesth*, Vol.37, pp. 161-173.
- Morcos, SK.; Baudouin, SV.; Anderson, PB.; Beedie, R. & Bury, RW. (1989). Iotrolan in selective bronchography via the fiberoptic bronchoscope. *Br J Radiol*, Vol.62, No.736, pp. 383-385.
- Morcos, SK.; Anderson, PB.; Baudouin, SV.; Clout, C.; Fairlie, N.; Baudouin, C. & Warnock, N. (1990). Suitability of and tolerance to Iotrolan 300 in bronchography via the fiberoptic bronchoscope. *Thorax*, Vol.45, pp. 628-629.
- Nakamura, K.; Terada, N.; Ohi, M.; Matsushita, T.; Kato, N. & Nakagawa, T. (1991). Tuberculous bronchial stenosis: treatment with balloon bronchoplasty. *AJR*, Vol.157, pp. 1187-1188.
- Olsson, T.; Bjornstad-Pettersen, H. & Stjernberg, NL. (1979). Bronchostenosis due to sarcoidosis. *Chest*, Vol.75, No.6, pp. 663-666.
- Parkin, JL.; Stevens, MH. & Jung, AL. (1976). Acquired and congenital subglottic stenosis in the infant. *Ann Otol Rhinol Laryngol*, Vol.85, pp. 573-581.
- Riebel, T. & Wartner, R. (1990). Use of non-ionic contrast media for tracheobronchography in neonates and young infants. *Eur J Radiol*, Vol.11, pp. 120-124.
- Rooney, CP.; Ferguson, JS.; Barnhart, W.; Cook-Granroth, J.; Ross, A.; Hoffman, EA. & McLennan, G. (2005). Use of 3-dimensional computed tomography reconstruction studies in the preoperative assessment of patients undergoing balloon dilatation for tracheobronchial stenosis. *Respiration*, Vol.72, pp. 579-586.
- Sheski, FD. & Mathur, PN. (1998). Long-term results of fiberoptic bronchoscopic balloon dilation in the management of benign tracheobronchial stenosis. *Chest*, Vol.114, No.3, pp. 796-800.
- Wilson, NJ. (1945). Bronchoscopic observations in tuberculous tracheobronchitis-clinical and pathological correlation. *Dis Chest*, Vol.11, pp.36-59.





## Global Perspectives on Bronchoscopy

Edited by Dr. Sai P. Haranath

ISBN 978-953-51-0642-5

Hard cover, 240 pages

**Publisher** InTech

**Published online** 13, June, 2012

**Published in print edition** June, 2012

Bronchoscopy has become an essential part of modern medicine . Recent advances in technology have allowed integration of ultrasound with this tool. The use of lasers along with bronchoscopes has increased the therapeutic utility of this device. Globally an increasing number of pulmonary specialists, anaesthesiologists and thoracic surgeons are using the bronchoscope to expedite diagnosis and treatment. The current volume on bronchoscopy adds to the vast body of knowledge on this topic. The democratic online access to this body of knowledge will greatly increase the ease with which both trainees and expert bronchoscopists can learn more .The contributions from around the world cover the breadth of this field and includes cutting edge uses as well as a section on pediatric bronchoscopy . The book has been an effort by excellent authors and editors and will surely be a often reviewed addition to your digital bookshelf. . In summary, this book is a great testament to the power of collaboration and is a superb resource for doctors in training, ancillary team members as well as practicing healthcare providers who have to perform or arrange for bronchoscopy or the associated procedures.

### How to reference

In order to correctly reference this scholarly work, feel free to copy and paste the following:

Masayuki Tanahashi, Hiroshi Niwa, Haruhiro Yukiue, Eriko Suzuki, Hiroshi Haneda, Naoko Yoshii and Hisanori Kani (2012). Bronchoscopic Balloon Dilation (BBD) for Benign Tracheobronchial Stenosis, Global Perspectives on Bronchoscopy, Dr. Sai P. Haranath (Ed.), ISBN: 978-953-51-0642-5, InTech, Available from: <http://www.intechopen.com/books/global-perspectives-on-bronchoscopy/bronchoscopic-balloon-dilation-bbd-for-benign-tracheobronchial-stenosis>

**INTECH**  
open science | open minds

### InTech Europe

University Campus STeP Ri  
Slavka Krautzeka 83/A  
51000 Rijeka, Croatia  
Phone: +385 (51) 770 447  
Fax: +385 (51) 686 166  
[www.intechopen.com](http://www.intechopen.com)

### InTech China

Unit 405, Office Block, Hotel Equatorial Shanghai  
No.65, Yan An Road (West), Shanghai, 200040, China  
中国上海市延安西路65号上海国际贵都大饭店办公楼405单元  
Phone: +86-21-62489820  
Fax: +86-21-62489821

© 2012 The Author(s). Licensee IntechOpen. This is an open access article distributed under the terms of the [Creative Commons Attribution 3.0 License](#), which permits unrestricted use, distribution, and reproduction in any medium, provided the original work is properly cited.