

Update on IgM Nephropathy

Javed I. Kazi and Muhammed Mubarak
*Sindh Institute of Urology and Transplantation, Karachi
Pakistan*

1. Introduction

IgM nephropathy (IgMN) is a relatively recently described, and still a controversial clinico-immunopathologic entity which presents mainly as idiopathic nephrotic syndrome (INS) in both children and adults (Al-Eisa et al., 1996). The disease, like IgA nephropathy (IgAN), is defined by its immunohistologic features: the presence of immunoglobulin M (IgM) as the sole or dominant immunoglobulin in the mesangium of the glomeruli in a diffuse (all glomeruli) and global (whole glomerulus) distribution (Bhasin et al., 1978; Cohen et al., 1978). Similar to IgAN, the light microscopic (LM) features on renal biopsy are very heterogeneous, ranging from minimal change lesion to variable degree of mesangial proliferation to focal segmental glomerulosclerosis (FSGS) (Mubarak et al., 2010). Electron-dense deposits in the mesangium are a variable ultrastructural feature. Its epidemiology is interesting; the disease is reported mostly from South East Asia and Eastern Europe, but sparse studies have also appeared from USA, Canada, and parts of Western Europe. Its etiology and pathogenesis are still not well understood (Myllimaki et al., 2003). Owing chiefly to controversy over its distinct nature, it has attracted little interest in the scientific community. There are very few studies on the prognostic factors (Jungthirapanich et al., 1997; Myllimaki et al., 2003). Currently, IgMN is treated along the similar lines as minimal change disease (MCD) or FSGS, but the response to steroids is less favorable than that of MCD. Its prognosis is relatively guarded as compared with MCD. Upto one third of individuals with IgMN develop renal insufficiency or one fourth, the end-stage renal disease (ESRD) over 15 years of follow-up (Myllimaki et al., 2003). In this chapter, we briefly discuss the historical background, etiology, pathogenesis, pathology, clinical manifestations, treatment, and prognosis of this relatively young and still largely controversial primary glomerulopathy. Further long term longitudinal studies are needed to clarify the status of the disease among the primary glomerulopathies.

2. Historical background

Although, it is widely believed that this lesion was described for the first time in 1978 by two independent research groups led by Cohen (1978), and Bhasin (1978) in patients presenting with heavy proteinuria, the deposits of predominant IgM in the glomeruli, in fact, were first described in renal biopsies in 1974 by Putte et al. (1974) in patients presenting with persistent or recurrent hematuria. Soon after the formal recognition of the disease as a distinct entity in 1978, many series were reported on the disease mostly from USA, UK, other countries of Europe, and South East Asia (Al-Eisa et al., 1996; Cavallo & Johnson, 1981;

Kobayashi et al., 1982; Hamed 2003; Helin et al., 1982; Hsu et al., 1984; Jungthirapanich et al., 1997; Lawler et al., 1980; Mampaso et al., 1981; Myllymaki et al., 2003; Pardo et al., 1984; Saha et al., 1989). Among these, the large series of patients with this disease from Finland are of note (Helin et al., 1982; Myllymaki et al., 2003; Saha et al., 1989). However, the interest in the disease soon faded, and many investigators, especially in the western world, were reluctant to accept the disease as a distinct clinicopathologic entity. The disease is however still being reported from different parts of the world (Mubarak et al., 2011).

3. Epidemiology

Few studies have been reported on the population based incidence and prevalence, mode of presentation, immunopathologic features, pattern of steroid response and the long term prognosis of IgMN in either children or adults (Myllymaki et al., 1993). Most of the studies have reported the prevalence of the disease as frequency or percentage of renal biopsies with a diagnosis of IgMN. The frequency of IgMN reported in literature has varied considerably from 2% to 18.5% (Al-Eisa et al., 1996; Cavalo et al., 1981; Kazi et al., 2010; Kopolovic et al., 1987; Lawler et al., 1980; Mampaso et al., 1981; Cavalo & Johnson, 1981; Chan et al., 2000; Donia et al., 2000; Hsu et al., 1984; Jungthirapanich et al., 1997; Kobayashi et al., 1982; Mubarak et al., 2011; Singhai et al., 2011; Tejani & Nicastri, 1983). The first two pioneering studies found frequencies of 2 and 6.1% respectively in their biopsy series (Cohen et al., 1978; Bhasin et al., 1978). Soon thereafter, a frequency of 11.7% of IgMN was reported in a study by Lawler et al. from UK (1980). Hsu et al. (1984) found a frequency of 10% of IgMN in all biopsies with primary glomerular disease. One of the largest and long-term longitudinal series on IgMN has come from Finland, comprising of 110 patients, including both adults and children (Myllymaki et al., 2003). More recently, we have published our experience in the largest study ever carried out on 135 children with INS and IgMN as the biopsy diagnosis (Mubarak et al., 2011). The exact cause for this wide variation in the prevalence of IgMN is unclear but may be partly due to varying biopsy indications, varying criteria for the diagnosis of this lesion used in different studies, and partly to genetic or environmental factors. Most of the studies have been undertaken on native renal biopsies; however, occasional cases of its occurrence in renal transplant recipients have also been reported (Salmon AH et al., 2004).

4. Etiology

As with IgAN, the etiology of this common form of primary GN is still largely unknown. IgM deposits in the glomeruli may be seen in a variety of systemic diseases, such as systemic lupus erythematosus (SLE), rheumatoid arthritis, diabetes mellitus, Alport's syndrome, and paraproteinemia. For a diagnosis of primary IgMN, the above conditions must be excluded.

5. Pathogenesis

As with the etiology, the pathogenesis of this disease is also still elusive. Very few studies have been undertaken on the pathogenesis of this condition, mainly because this disease is not accepted widely as a distinct entity in most of the western countries (Border, 1988). Some investigators have suggested classical immune complex mediated activation of complement system leading to mesangial injury and reaction (Hsu et al., 1984). They cite as evidence the presence of C1q and C4 deposits along with IgM in glomerular mesangium in

majority of cases, while properdin and factor B were not found (Hsu et al., 1984). Others have found C3 in majority of cases and C1q only infrequently (Mubarak et al., 2011). The source of antigens triggering immune complex formation is not known, but it is hypothesized that certain antigens in the food or environment which preferentially elicit IgM response may be responsible. Abnormalities of T-lymphocyte function or a disturbance in immune complex clearance by mesangial cells have also been suggested (Hsu et al., 1984). Many studies have found increased serum IgM or IgM immune complex concentrations in patients with IgMN (Disciullo et al., 1988; Hsu et al., 1984). No abnormalities of IgM molecule, as are observed in IgA, have been detected or reported as yet. Similarly, no animal studies have been conducted on this disease till now.

6. Pathology

The diagnosis of IgMN requires, like IgAN, examination of renal biopsy by at least LM and IF methods. EM is not essential but optional and often confirms the findings seen on LM and IF. The pathologic findings are correlated with clinical and serological studies to diagnose the primary form of the disease.

6.1 Light microscopy

The LM findings in IgMN are heterogeneous, as in IgAN. The spectrum of changes is however not as wide as in IgAN and includes minor changes, variable degree of mesangial proliferation, usually of mild to moderate degree, and FSGS (Mubarak et al., 2011; Myllimaki et al., 2003) (Fig. 1, 2). Many biopsies also display small cellular crescents (Lawler et al., 1980; Kishimoto & Arakawa, 1999). The most common morphologic change reported consists of mesangial proliferation of the glomeruli, mostly of mild to moderate degree (Hsu et al., 1984). In a minority of cases, severe mesangial proliferation with interpositioning of the expanded mesangium into the peripheral capillary walls with consequent splitting and tram-track appearance have also been noted (Kishimoto & Arakawa, 1999). Minor changes on LM are reported in about one third of cases (Hsu et al., 1984; Mubarak et al., 2011; Myllimaki et al., 2003). FSGS morphology is also commonly reported in IgMN. These cases show diffuse mesangial positivity of IgM in contrast to nonspecific, segmental trapping of IgM in idiopathic FSGS. The previously reported prevalence of this morphologic pattern in biopsies of IgMN shows wide variation (Lawler et al., 1980; Mubarak et al., 2011; Myllimaki et al., 2003). Some investigators have entirely excluded this lesion in their study patients; others have included those cases of FSGS showing diffuse mesangial positivity of IgM in the category of IgMN, as in our study (Mubarak et al., 2011). The reported rates of this lesion have varied from 9 to 65.2% (Mubarak et al., 2011; Myllimaki et al., 2003). This pattern was also noted in one third of the cases in our study (Mubarak et al., 2011). Still other investigators have reported progression of IgMN cases with minor changes or mesangial proliferation into FSGS on repeat biopsies (Myllimaki et al., 2003; Zeis et al., 2001). We have observed one case each of florid crescentic GN and a case of collapsing FSGS as a morphologic expression of IgMN (unpublished data). Tubular atrophy and interstitial scarring are also commonly observed on renal biopsies of IgMN at the time of diagnosis and are usually mild (Mubarak et al., 2011; Myllimaki et al., 2003). Moderate and severe tubular atrophy have been rarely reported. Mild fibrointimal thickening of arteries has also been reported in a minority of cases (Mubarak et al., 2011).

6.2 Immunofluorescence

Like IgAN, IgMN is a diagnosis of IF microscopy. Characteristic of the disease is a diffuse and global mesangial positivity of IgM (either as sole immunoglobulin or predominant) of at least 1+ intensity on a scale of 0-3+ (where 0 is absent, 1+ is mild, 2+ is moderate, and 3+ is marked) (Mubarak et al., 2011; Myllimaki et al., 2003) (Fig. 3). Some studies have included trace positivity of IgM on IF as IgMN. Concomitant but not dominant deposits of IgA and IgG are found in a small percentage of cases (Mubarak et al., 2011; Myllimaki et al., 2003). Complement fragments of C3 and C1q are found in majority of cases co-localized with IgM deposits (Mubarak et al., 2011; Myllimaki et al., 2003; Zeis et al., 2001).

6.3 Electron microscopy

There are very few studies on the ultrastructural features of IgMN. In majority of cases, no EM was done and the diagnosis was made solely on IF microscopy. The few studies that have carried out EM examination have noted small, granular to short linear, electron-dense deposits in the mesangium and paramesangium, along with variable degrees of mesangial cell proliferation and mesangial matrix expansion. Variable degrees of fusion of foot processes commensurate with the degree of proteinuria have also been observed. The electron-dense deposits have typically been of low volume and low density, and in many cases, rather ill-defined (Al-Eisa et al., 1996; Hsu et al., 1984; Myllimaki et al., 2003).

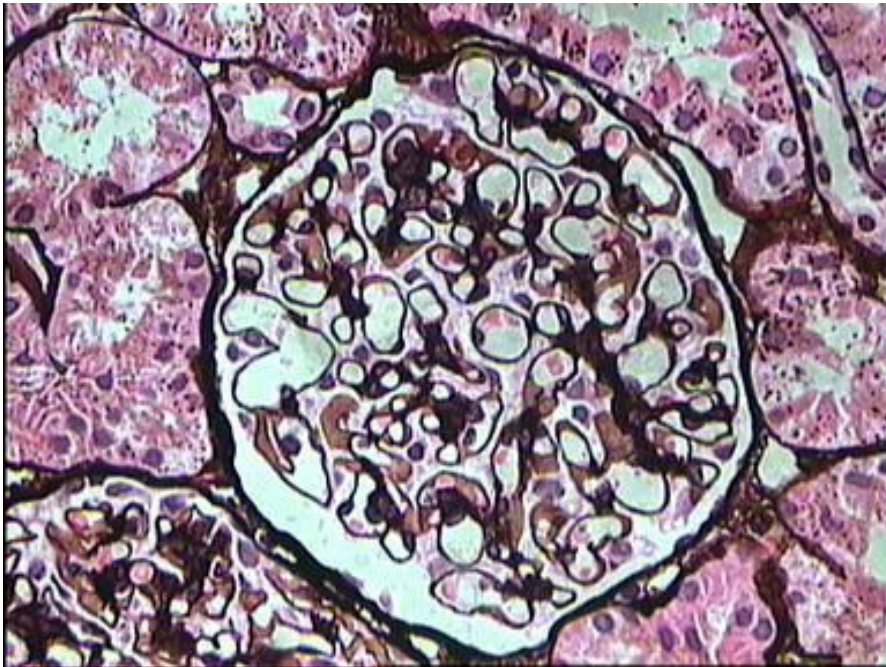


Fig. 1. Medium-power view showing a glomerulus with minor changes on light microscopy. There is no significant mesangial proliferation. Capillary lumena are intact. This morphological pattern is observed in about one third of cases of IgM nephropathy. (Jones's methenamine silver, $\times 200$).

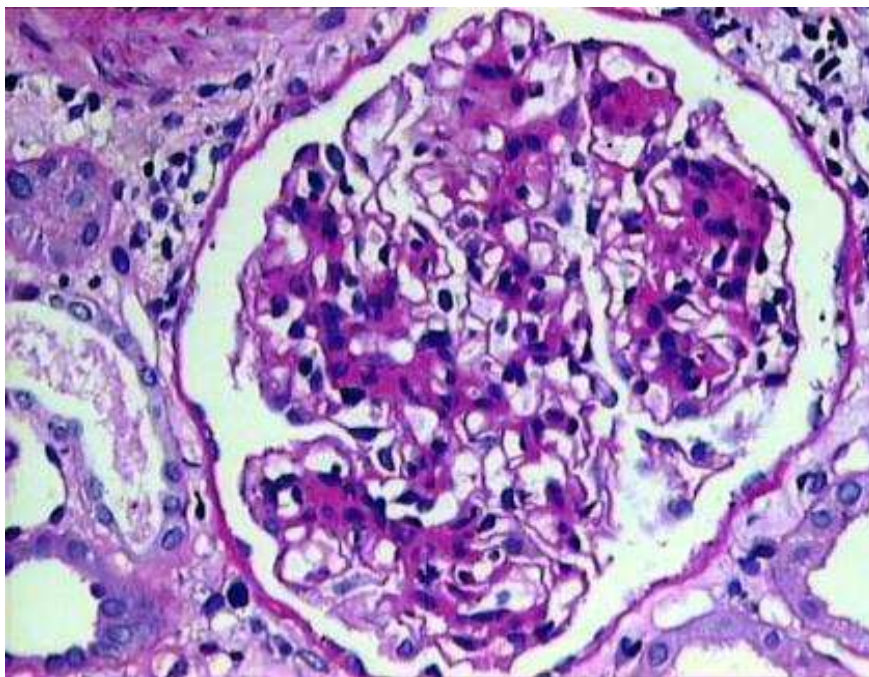


Fig. 2. High-power view showing a glomerulus with mild mesangial cell proliferation and moderate mesangial matrix expansion. Peripheral capillary walls are thin. This is the most common morphological pattern observed in cases of IgM nephropathy. (PAS, $\times 400$).

7. Clinical manifestations

Clinically, the disease most commonly presents with INS in both children and adults. The disease also frequently presents with hematuria (HU) or asymptomatic urinary abnormalities (AUA). However, in many centers of the world, patients with the later manifestations are not subjected to renal biopsy, which accounts for the low number of patients presenting with these manifestations. It is believed that patients with HU, especially adult females, have a good prognosis, as compared with patients with NS or proteinuria (PU) (Myllimaki et al., 2003). Hypertension is frequent at presentation or biopsy, being found in roughly one third of cases. Its prevalence increases with increasing duration of the disease approaching 50% at 15 years of follow-up (Myllimaki et al., 2003).

The disease predominantly affects males as compared with females. Some studies have found a female preponderance, especially in those patients presenting with HU. Isolated HU or proteinuria-hematuria (PU-HU) have constituted almost half of biopsy indications in some previous reports (Myllimaki et al., 2003). This may have implications for the severity of the pathological lesions observed on renal biopsy and the long term outcome of disease. It has been observed, however, that IgMN in children mostly presents as INS rather than as HU or PU, as shown in the study by Myllimaki et al. (2003), in which 32 of 36 children with IgMN presented as NS and only four children presented with non nephrotic proteinuria and none presented with PU-HU or HU.

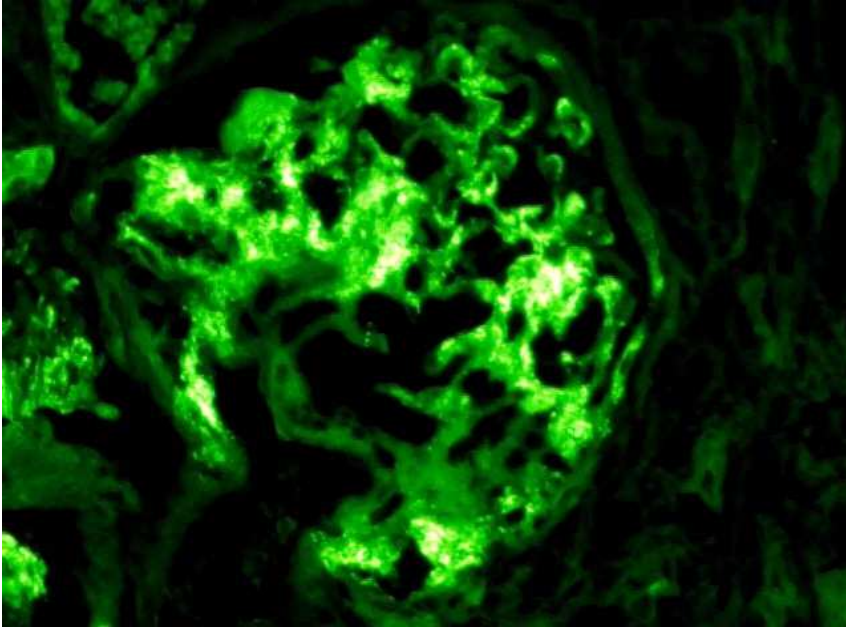


Fig. 3. Medium-power view showing a glomerulus with bright (3+ on a scale of 0 to 3+), granular, and global positivity of IgM mainly in the mesangium of the glomerulus on immunofluorescence. (Immunofluorescence for IgM, $\times 200$).

8. Treatment

IgMN is treated in the same manner as MCD or FSGS. Corticosteroids form the mainstay of treatment. Similar to its prevalence, the steroid response pattern in IgMN varies considerably; steroid resistance reported varies from 0 to 52% (Border, 1988). We found a steroid resistance pattern in about one third of our children presenting with INS. Border (1988). also found a mean of 28% steroid resistance on a review of nine published studies of IgMN (Border, 1988). It follows from these studies that IgMN responds less well to steroids compared to typical minimal change disease (MCD), and favors the hypothesis that IgMN is distinct from MCD (Mubarak et al., 2011; Myllimaki et al., 2003). Other researchers have not found any significant differences in clinical, pathological or steroid response pattern among these diseases (Al-Eisa et al., 1996; Ji-Yun et al., 1984).

9. Clinical course and prognosis

The clinical course and prognosis of IgMN are also very variable. Part of the variation in the studies is due to variable length of follow-up of the patients and variable case definitions. In the largest and longest follow-up study from Finland, renal insufficiency was observed in 35% of cases at 15 years after biopsy, and ESRD was found in 23% of cases (Myllimaki et al., 2003). They also looked for clinical and pathological prognostic factors leading to renal insufficiency or ESRD. In multivariate analysis, hypertension was the only factor that predicted renal insufficiency; on the other hand, none of the multiple factors analyzed was

predictive of ESRD. They proposed that this may be due to small number of patients reaching ESRD in their study (Myllimaki et al., 2003). Another study identified microscopic HU, extent of mesangial proliferation, and global glomerulosclerosis as independent prognostic markers on multivariate analysis (O'Donoghue et al., 1991).

One important complication of IgMN is the transition of the usual mesangial proliferative lesion into the morphologic expression of FSGS. The later is diagnosed only in re-biopsies (Myllimaki et al., 2003; Zeis et al., 2001).

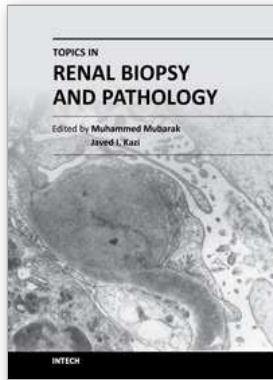
10. Conclusion

In conclusion, IgMN is an important cause of renal morbidity in both children and adults in many parts of the world. It shows a spectrum of morphologic changes ranging from minor changes to FSGS. Immunofluorescence is necessary for its diagnosis. Clinically, a poor response to steroid therapy distinguishes this disease from MCD. Further long term longitudinal studies are needed to clarify the status of the disease among the primary glomerulopathies. More studies are also needed to elucidate the etiology and pathogenesis of this disease and develop effective therapeutic regimens.

11. References

- Al Eisa A, Carner JE, Lirenman DS, & Magil AB. (1996). Childhood IgM nephropathy: comparison with minimal change disease. *Nephron*, Vol. 72, No. 1, pp. 37-43.
- Bhasin HK, Abeulo JG, Nayak R, & Esparza AR. (1978). Mesangial proliferative glomerulonephritis. *Lab Invest*, Vol. 39, No. 1, pp. 21-9.
- Border WA. (1988). Distinguishing minimal change disease from mesangial disorders. *Kidney Int*, Vol. 34, No. 3, pp. 419-24.
- Cavalo T, Johnson MP. (1981). Immunopathologic study of minimal change glomerular disease with mesangial IgM deposits. *Nephron*, Vol. 27, No. 6, pp. 281-4.
- Chan YH, Wong KM, Choi KS, Chak WL, Cheung CY. (2000). Clinical manifestation and progression of IgM mesangial nephropathy: a single center perspective. *Hong Kong J Nephrol*, Vol. 2, No. 1, pp. 23-6.
- Cohen AH, Border WA, Glassock RJ. (1978). Nephrotic syndrome with glomerular mesangial IgM deposits. *Lab Invest*, Vol. 38, No. pp. 610-9.
- Disciullo SO, Abeulo JG, Moalli K, & Pezzullo JC. (1988). Circulating heavy IgM in IgM nephropathy. *Clin Exp Immunol*, Vol. 73, No. 3, pp. 395-400.
- Donia AF, Sobh MA, Moustafa FE, Bakr MA, Foda MA. (2000). Clinical significance and long term evolution of minimal change histopathologic variants and of IgM nephropathy among Egyptians. *J Nephrol*, Vol. 13, No. 4, pp. 275-81.
- Habib R, Girardin E, Gagnadoux M-F, Hinglais N, Levy M, Broyer M. (1988). Immunopathological findings in idiopathic nephrosis: clinical significance of glomerular "immune deposits". *Pediatr Nephrol*, Vol. 2, No. pp. 402-8.
- Hamed RM. (2003). Clinical significance and long term evolution of mesangial proliferative IgM nephropathy among Jordanian children. *Ann Saudi Med*, Vol. 23, No. 5, pp. 323-7.
- Helin H, Mustonen J, Pasternack A, Anttonen J. (1982). IgM associated glomerulonephritis. *Nephron*, Vol. 31, No. 1, pp. 11-6.
- Hsu HC, Chen WY, Lin GJ, Chen L, Kao S-L, Huang C-C, et al. (1984). Clinical and immunopathologic study of mesangial IgM nephropathy: report of 41 cases. *Histopathology*, Vol. 8, No. 3, pp. 435-46.

- Ji-Yun Y, Melvin T, Sibley R, Michael AF. (1984). No evidence for a specific role of IgM in mesangial proliferation of idiopathic nephrotic syndrome. *Kidney Int*, Vol 25, No. 1, pp. 100-6.
- Jungthirapanich J, Singkhwa V, Watana D, Futrakul P, Sensirivatana R, Yenrudi S. (1997). Significance of tubulointerstitial fibrosis in paediatric IgM nephropathy. *Nephrology*, Vol. 3, No. pp. 509-14.
- Kazi JI, Mubarak M, Mallick S. Clinicopathologic characteristics of IgM nephropathy in pediatric nephrotic population from Pakistan. Letter to the editor. *J Pak Med Assoc* 2010;76:878.
- Kishimoto H, Arakawa M. (1999). Clinico-pathological characterization of mesangial proliferative glomerulonephritis with predominant deposition of IgM. *Clin Exp Nephrol*, Vol. 3, No. 2, pp. 110-5.
- Koplovic J, Shvil Y, Pomeranz A, Ron N, Rubinger D, Oren R. (1987). IgM nephropathy: morphological study related to clinical findings. *Am J Nephrol*, Vol. 7, No. 4, pp. 275-80.
- Lawler W, Williams G, Tarpey P, Mallick NP. (1980). IgM associated primary diffuse mesangial proliferative glomerulonephritis. *J Clin Pathol*, Vol. 33, No. 11, pp. 1029-38.
- Mampaso F, Gonzalo A, Teruel J, Losada M, Gallego N, Ortuno J, & Bellas C. (1981). Mesangial deposits of IgM in patients with the nephrotic syndrome. *Clin Nephrol*, Vol. 16, No. 5, pp. 230-4.
- Mubarak M, Kazi JI, Malik S, Lanewala A, Hashmi S. (2011). Clinicopathologic characteristics and steroid response of IgM nephropathy in children presenting with idiopathic nephrotic syndrome. *APMIS*, Vol. 119, No. pp. 180-6.
- Mubarak M, Lanewala A, Kazi JI, Akhter F, Sher A, Fayyaz A, et al. (2009). Histopathological spectrum of childhood nephrotic syndrome in children in Pakistan. *Clin Exp Nephrol*, Vol. 13, No. 6, pp. 589-93.
- Myllymaki J, Saha H, Mustonen J, Helin H, Pasternack A. (2003). IgM nephropathy: clinical picture and long term prognosis. *Am J Kidney Dis*, Vol. 41, No. 2, pp. 343-50.
- O'Donoghue DJ, Lawler W, Hunt LP, Acheson EJ, & Mallick NP (1991). IgM associated primary diffuse mesangial proliferative glomerulonephritis: natural history and prognostic indicators. *Q Med J*, Vol. 79, No. 1, pp. 333-50.
- Pardo V, Riesgo I, Zilleruelo G, Strauss J. (1984). The clinical significance of mesangial IgM deposits and mesangial hypercellularity in minimal change nephrotic syndrome. *Am J Kidney Dis*, Vol. 3, No. 4, pp. 264-9.
- Saha H, Mustonen J, Pasternack A, Helin H. (1989). Clinical follow up of 54 patients with IgM nephropathy. *Am J Nephrol*, Vol. 9, No. 2, pp. 124-8.
- Salmon AH, Kamel D, & Mathieson PW. (2004). Recurrence of IgM nephropathy in a renal allograft. *Nephrol Dial Transplant*, Vol. 19, No. 10, pp. 2650-2.
- Singhai AM, Vanikar AV, Goplani KR, Kanodia KV, Patel RD, Suthar KS, Patel HV, Gumber MR, Shah PR, & Trivedi HL. (2011) Immunoglobulin M nephropathy in adults and adolescents in India: a single center study of natural history. *Indian J Pathol Microbiol*, Vol. 54, No. 1, pp. 3-6
- Tejani A, Nicastrì AD. (1983). Mesangial IgM nephropathy. *Nephron*, Vol. 35, No. 1, pp. 1-5.
- Van de Putte LBA, DeLa Riviere GB, Van Breda Vriesman PJC. (1974). Recurrent or persistent hematuria, sign of mesangial immune-complex deposition. *N Engl J Med*, Vol. 290, No. 21, pp. 1165-70.
- Zeis PS, Kavazarakis E, Nakopoulou L, Moustaki M, Messaritaki A, Zeis MP, & Nicolaidou P. (2001). Glomerulopathy with mesangial IgM deposits: long-term follow up of 64 children. *Pediatr Int*, Vol. 43, No. 3, pp. 287-92.



Topics in Renal Biopsy and Pathology

Edited by Dr. Muhammed Mubarak

ISBN 978-953-51-0477-3

Hard cover, 284 pages

Publisher InTech

Published online 04, April, 2012

Published in print edition April, 2012

There is no dearth of high-quality books on renal biopsy and pathology in the market. These are either single author or multi-author books, written by world authorities in their respective areas, mostly from the developed world. The vast scholarly potential of authors in the developing countries remains underutilized. Most of the books share the classical monotony of the topics or subjects covered in the book. The current book is a unique adventure in that it bears a truly international outlook and incorporates a variety of topics, which make the book a very interesting project. The authors of the present book hail not only from the developed world, but also many developing countries. The authors belong not only to US but also to Europe as well as to Pakistan and Japan. The scientific content of the book is equally varied, spanning the spectrum of technical issues of biopsy procurement, to pathological examination, to individual disease entities, renal graft pathology, pathophysiology of renal disorders, to practice guidelines.

How to reference

In order to correctly reference this scholarly work, feel free to copy and paste the following:

Javed I. Kazi and Muhammed Mubarak (2012). Update on IgM Nephropathy, Topics in Renal Biopsy and Pathology, Dr. Muhammed Mubarak (Ed.), ISBN: 978-953-51-0477-3, InTech, Available from: <http://www.intechopen.com/books/topics-in-renal-biopsy-and-pathology/update-on-igm-nephropathy>

INTECH

open science | open minds

InTech Europe

University Campus STeP Ri
Slavka Krautzeka 83/A
51000 Rijeka, Croatia
Phone: +385 (51) 770 447
Fax: +385 (51) 686 166
www.intechopen.com

InTech China

Unit 405, Office Block, Hotel Equatorial Shanghai
No.65, Yan An Road (West), Shanghai, 200040, China
中国上海市延安西路65号上海国际贵都大饭店办公楼405单元
Phone: +86-21-62489820
Fax: +86-21-62489821

© 2012 The Author(s). Licensee IntechOpen. This is an open access article distributed under the terms of the [Creative Commons Attribution 3.0 License](#), which permits unrestricted use, distribution, and reproduction in any medium, provided the original work is properly cited.