

Role of Dexamethasone in Meningitis

Emad uddin Siddiqui
and Ghazala Irfan Qazi
*Aga Khan University Hospital
Pakistan*

1. Introduction

The inflammatory cascade in acute bacterial meningitis leads to tissue damage and exudates accumulation especially in *H. influenza*, pneumococcal meningitis and in tuberculous meningitis. The administered antibiotics will also exaggerate the formation of inflammatory exudates from tissue destruction and endotoxins from bacterial lysis, resulting in edema formation. Accumulation of these inflammatory substrates, neutrophils and edema ultimately results in ischemia and pressure effect on neurons and nerve fibers with worsening of neurological signs and symptoms.

Despite the effective antibiotic therapies, bacterial meningitis still has considerable morbidity and mortality in both adult and pediatric population. (Brouwer MC et al., 2010). Other than the definitive treatment with appropriate antibiotics, supportive and adjuvant therapy has its own characteristic role in the improved outcome of disease. Evidence from experimental models also support the role of adjuvant therapy like, early administration of glucocorticoids in selective cases of pyogenic meningitis, however most modalities investigated so far have not been sufficiently supportive for their routine use in the management of all cases of meningitis.

2. Pathophysiology

According to Monro-Kellie doctrine (Morki B, 2008), if there is an increasing size of one constituent or a mass within the cranial vault, the pressure will be shared by either brain, arterial and venous blood flow and/or the CSF. Similarly, if there is trauma or inflammation to brain parenchyma or meninges, exudates will accumulate with oedema, and edematous and inflamed brain causes either partial or complete obstruction of CSF flow which may result in hydrocephalus. Edematous and inflamed brain reduces the venous blood flow from cranial vault, leading to venous congestion and edema, on the other hand, it also hampered arterial blood supply and hence reduce brain perfusion, and oxygenation which may further aggravate hypoxic inflammation and hence worsening of edema, thereby further increasing intra cranial venous congestion and pressure, consequently compromising the brain parenchyma results in different clinical presentation like altered mental status.

Monro-kellie doctrine

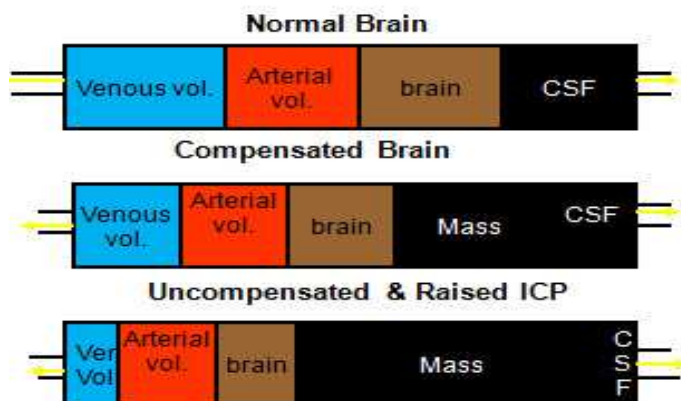


Fig. 1. Monro-Kellie hypothesis: Increase in volume (mass effect) of cranial constituents (blood, CSF, and brain tissue) must be compensated by a decrease in volume of another.

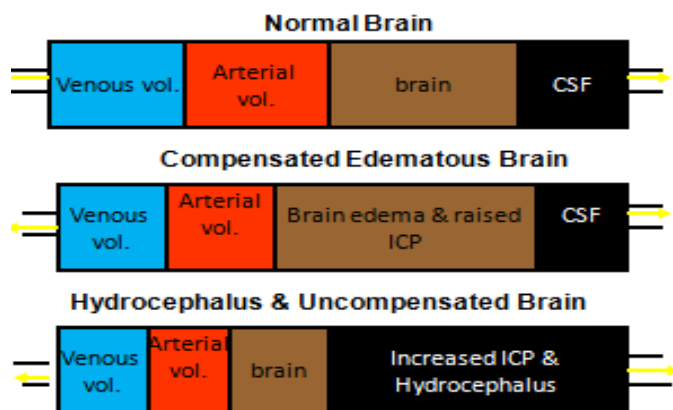


Fig. 2. Monro-Kellie hypothesis in case of increase intracranial pressure and hydrocephalus, compromising arterial and venous blood and compressed brain parenchyma and CSF.

3. Role of anti inflammatory agents

There are wide spectrum of complications associated with meningitis, these may be neurological and non neurological (systemic). Systemic complications relate with bacteremia and related toxins, which ranges from sepsis to septic shock, disseminated intravascular coagulation, respiratory distress syndrome and respiratory arrest, while prolong fever, vasomotor collapse, pericardial effusion, arthritis, hypothalamic and other endocrine dysfunction including hyponatremia and bilateral adrenal hemorrhage are also not uncommon. Anemia may also manifest as a part of meningitis.

Several anti-inflammatory agents have been studied in reducing the inflammatory exudates in animal model of pyogenic and other type of meningitis. Indomethacin, platelet factor inhibitors and pentoxifylline, recombinant protein C, intravenous immunoglobulin and monoclonal antibodies, have been evaluated for their isolated and combine anti-inflammatory properties in reducing the CSF inflammation and edema, but none of them have evident promising results. (Singhi P et al., 2008)

Though the role of glucocorticoids in systemic complications of meningitis is not discussed in the literature as extensively as it has been described for neurological outcomes, especially in reducing the incidence of hearing loss and other acute or chronic neurological sequel, on the contrary, use of glucocorticoids did not reduce overall mortality in most cases of meningitis. Cochrane review data supports its use in patients with bacterial meningitis in high-income countries, but results were not found to be beneficial from low-income countries. (Daoud AS et al., 1999). Bacterial immunogenicity, host immunity and response, timing and efficacy of antibiotics and steroids used and susceptibility of organism all account for the consequences in low income countries. The adjunctive benefit of corticosteroids during treatment of meningitis caused by other organisms (viral, fungal, and parasitic) is unknown.

4. Role of steroids in meningitis

With its unique anti-inflammatory and immune suppressive properties, efficacy of this drug has been extensively studied in different types of meningitis. Adjuvant therapy of glucocorticoids like dexamethasone is useful in both adult and pediatric meningitis and tuberculous meningitis as evident from experimental studies and vast growing clinical data. (Friedland IR et al., 1994).

Steroid limits the production of inflammatory mediators like IL-1, IL-6 and TNF and exudates and help in reduction of edema, resulting in the decrease cerebral pressure and hence improve CSF flow within the cistern thus helps in stabilizing the blood brain barrier (BBB), this in turn leads to improvement of neurological symptoms. (Karen & Tyler 2008). Dexamethasone also inhibits the production of TNF by macrophages and microglia, but only if it is administered before these cells are activated by endotoxin.

A meta-analysis conducted in 2010 on the role of dexamethasone in pediatric meningitis has shown that dexamethasone did not improve overall mortality; however it can reduce severe hearing loss in children. (Brouwer MC et al., 2010). However, the etiological agents, nutritional status, prior immunity and immunization and demography play an important role in outcome of such meningitis.

Most experts had consensus on the beneficial role of steroid with its maximum benefits when it is used at least one hour prior to recommended antibiotics therapy. (King, 1994; Pickering, 2009). Regarding H. Influenzae meningitis in children older than six week age, the use of steroid prior to antibiotics is recommended by American Academy of Pediatrics and as describe Infectious Diseases Society of America (IDSA) guidelines 2004. (Tunkel AR et al., 2004). In H. Influenzae meningitis steroids significantly reduce the risk of sensorineural hearing loss, while other experts' belief that outcome of meningitis is not dependent on steroids when it was given. Dexamethasone also did not help in ameliorating the other neurologic consequences especially in children. (Brouwer MC et al., 2010).

Beneficial role of dexamethasone in neonatal meningitis has not been evidence from the literature. It is not indicated in bacterial meningitis in children younger than six weeks as it does not shown promising results in different past studies. Steroids are also not advised as adjuvant therapy in patients with congenital or acquired CNS anomalies. (Daoud AS et al., 1999).

The severity of illness at the time of presentation may appear to play a prominent role in outcome than just administration of adjuvant therapy with dexamethasone. (Peltola H et al., 2010). On the other hand dexamethasone may also mask the clinical presentation of meningitis, or any of its associated sequels like abscess, empyema, subdural collection, tuberculous meningitis, resistant meningitis. Routine administration of dexamethasone is also not recommended in developing countries as most patients got their first few doses of antibiotics before the diagnosis of meningitis. Still dexamethasone has a role in reducing the inflammatory exudates if given with or given soon after the initial antibiotics preferably within one hour, but this time interval is not clearly defined in literature. (King SM et al., 1994).

With the advent of effective immunization against H. Influenzae globally, Streptococcal Pneumoniae is becoming the common organism causing meningitis. Resistant of *S. pneumoniae* to cephalosporins group is also evidently increasing from literature. Widespread use of susceptible vancomycin against these resistant species of *S. pneumoniae* is increasing. At the same time studies had shown an increasing number of therapeutic failures when dexamethasone is combine with vancomycin and various other antibiotics like rifampicin and cephalosporin etc. steroids may reduce the penetration of these antibiotics in CSF or it may lead to decrease level of some antibiotic (eg, vancomycin, ceftriaxone, and rifampin) within the CSF, mechanism is not clear. (Friedland, 1994; Moellering, 1984).

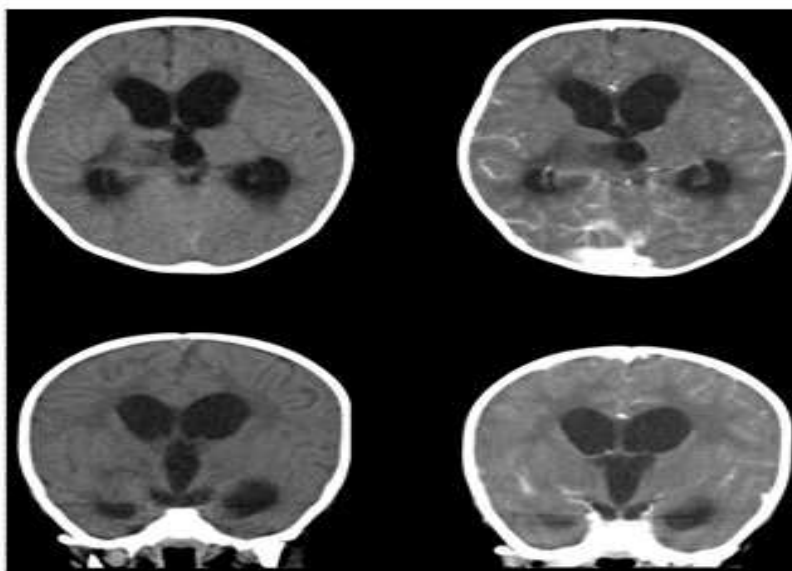


Fig. 3. CT scan brain showing low attenuated areas and increase enhancements with hydrocephalus in patient with pneumococcal meningitis

Dexamethasone in case of pneumococcal meningitis should be use after considering the risks and benefits. In adults with pneumococcal meningitis; dexamethasone has shown to have clinical benefits in term of neurological outcomes, but in children its use is controversial in pneumococcal meningitis. On the other hand few experts recommend that it should be used in all cases of confirm or suspected pneumococcal meningitis even if they are previously vaccinated, while other focused on the risk and benefits. However experts' consensus that steroid is only effective in reducing hearing loss if given before antibiotics. (Pickering 2009).

In patients with hypo spleenism, sickle cell disease and complement and immune deficiency, corticosteroids should be use cautiously. Thus controversies for its use in pneumococcal meningitis still persist. Dexamethasone is also not recommended in patients with aseptic meningitis, nonbacterial, or meningitis with gram-negative enteric bacteria. In such cases dexamethasone if started before should be discontinued as soon as a diagnosis of nonbacterial or gram-negative enteric meningitis is confirmed. (Tunkel AR et al., 2004).

Randomized controlled trials from low income country with steroid therapy in tuberculosis meningitis for initial 6-8 weeks of anti tubercular treatment were found to have significantly reduced mortality in patients who present with stage I disease; there was also reduce mortality noticed in patients who present with stage II disease. (Thwaites, GE. et al., 2008). However there was no significant long term reduction in the residual neurologic deficits and disability among survivors. Prednisone as compare to dexamethasone is associated with a significant reduction in mortality in children with tuberculous meningitis as compare to adults. (Thwaites, GE. et al., 2008).

5. Doses of dexamethasone in meningitis

In case of pyogenic meningitis dexamethasone should be used at 0.15 mg/kg per dose (10 mg intravenously in adults) every six hours for two to four days (Tunkel AR et al., 2004). Two days of dexamethasone appear to be as effective as and less toxic than longer courses. (Syrogiannopolus GA et al., 1994)

Steroids should be started at presentation or before or with the commencement of anti tubercular therapy. Dexamethasone, dose of 8 mg/day for children weighing <25 kg, 12 mg/day for adults and children >25 kg, for 3 weeks, and then tapered off gradually over the following 3 to 4 weeks. Prednisone, dose of 2 to 4 mg/kg/day for children and 60 mg/day for adults, for 3 weeks, then tapered off gradually over the following 3 weeks.

6. Complication of dexamethasone

Problems related with the glucocorticoids use are usually associated with it prolong duration. There may be complexity in clinical assessment and response to therapy, gastrointestinal bleeding, secondary fever, hypertension, hyperglycemia, leukocytosis etc. It may also impair antibiotic penetration into the cerebrospinal fluid (CSF) that can lead to therapeutic failure, particularly in areas with increasing rates of penicillin-resistant *S. pneumoniae*. (Thomas R et al., 1999).

Corticosteroids do not reverse CNS damage that has already resulted from the pathophysiological consequences of bacterial meningitis (e.g., cerebral edema and increased

intracranial pressure). However, even in children with bacterial meningitis in the developing world, use of adjunctive dexamethasone should be considered, because no adverse effects were attributable to its administration in this trial and its use may benefit some of the children with this devastating disorder. (Mongelluzo J et al., 2008)

7. Dexamethasone in adult meningitis

Clinical trials of corticosteroids (dexamethasone) as adjuvant therapy have been conducted in different centers all over the world with inconsistent results. However studies shown that corticosteroids significantly reduced severe hearing loss and other neurologic sequel, while on other hand, it is also helpful in reducing the overall mortality. Meta analysis using dexamethasone in adult meningitis demonstrates favorable outcomes in terms of both morbidity and mortality especially in cases of pneumococcal meningitis. It also reduces mortality in adult onset streptococcal pneumoniae meningitis. (Daniel J S et al., 2010). Dexamethasone is also associated with reduce rate of acute neurological and hearing defect, however there was no difference in long term neurological sequelae, (Brouwer MC et al., 2010) although some experts recommend to discontinue dexamethasone if *S. pneumoniae* was not found in the CSF culture, but others still recommend the use of adjunctive dexamethasone regardless of microbial etiology in conjunction with the first dose of antimicrobial therapy. (de Gans & Van de, 2002)

8. Dexamethasone in pediatric meningitis

The role of dexamethasone use in cases of pediatric meningitis is more controversial, it must be individualized according to the organism especially in case of *H. influenzae* and pneumococcal meningitis. Even though, a better outcome can only be attained if dexamethasone is use before or at the same time of first dose of antibiotics. (Tunkel AR et al., 2004). Routine use of dexamethasone in pediatric population is not recommended, potential risk and benefits must be taken in to account as it may not reverse neuronal damage that has already resulted from the pathophysiologic consequences of bacterial meningitis.

However, even in children with bacterial meningitis in the developing world, use of adjunctive dexamethasone should be considered, because no adverse effects were attributable to its administration in different trials and its use may benefit some of the children with this devastating disorder.

9. Dexamethasone in neonatal meningitis

The administration of dexamethasone did not significantly affect mortality or neurologic outcome in small children up to two years of age, hence it is not currently recommended. (Daoud AS et al., 1999).

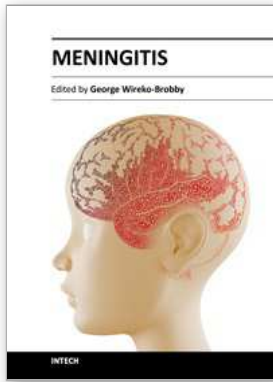
10. Acknowledgment

I would like to thanks Ms Uzma Siddiqui who gave me enormous moral assistant in writing this book chapter. I am also be thankful to Saif ul Islam and Zain ul Islam for their kind support.

11. References

- Brouwer, MC. McIntyre, P. de-Gans, J. Prasad, K. Van-de-Beek, D. (2010). Corticosteroids for acute bacterial meningitis. *Cochrane database systemic review* 2010, Sept 08 ;(09). CD004405.
- Daniel, J S. Stephen, B C. Anna, R T. (October 4, 2010). Dexamethasone to prevent neurologic complications of bacterial meningitis in adults. *Up to date on line. Version 18.3: September 2010*. Accessed on 12/06/2011.
http://www.uptodate.com/contents/dexamethasone-to-prevent-neurologic-complications-of-bacterial-meningitis-in-adults?source=search_result&selectedTitle=1%7E150
- Daoud, AS. Batiha, A. Al-Sheyyab, M. (1999). Lack of effectiveness of dexamethasone in neonatal bacterial meningitis. *Eur J Pediatr* 1999; 158:230-33.
- De-Gans, J. Van-de-Beek, D. (2002). Dexamethasone in adults with bacterial meningitis. *N Engl J Med* 2002; 347:1549-1556.
- Friedland, IR. Paris, M. Shelton, S. McCracken, GH. (1994). Time-kill studies of antibiotic combinations against penicillin-resistant and susceptible *Streptococcus pneumoniae*. *J Antimicrob Chemother* 1994; 34:231.
- King, SM. Law, B. Langley, JM. (1994). Dexamethasone therapy for bacterial meningitis: Better never than late? *Can J Infect Dis* 1994; 5:210
- Mace, SE. (2008). Acute Bacterial Meningitis. *Emerg Med Clin N Am*; 26(2) :2008 281–317
- Moellering, RC. (1984). Pharmacokinetics of vancomycin. *J Antimicrob Chemother* 1984; 14 Suppl D: 43.
- Mokri, B. The Monro–Kellie hypothesis. Applications in CSF volume depletion. *Neurology* 2001;56:1746–1748
- Mongelluzo, J. Mohamad, Z. Ten-Have, TR. Shah, SS. (2008). Corticosteroids and mortality in children with bacterial meningitis. *JAMA* 2008; 299:2048-2055.
- Odio, CM. Faingezicht, I. Paris, M. Nassar, M. Baltodano, A. Rogers, J. Saez-Lioren, X. Olsen, KD. Mccracken, GH. (1991). The beneficial effects of early dexamethasone administration in infants and children with bacterial meningitis. *N Engl J Med* 1991; 30: 324 (22):1525-31
- Peltola, H. Roine, I. Fernández, J. Gonzalez Mata, A. Zavala, I. Gonzalez, AYala, S. Arbo, A. Bolonga, R. Govo, J. Lopez, E. Mino, G. Dourando de Andrade, S. Sarna, S. Jauhianinen, T. (2010). Hearing impairment in childhood bacterial meningitis is little relieved by dexamethasone or glycerol. *Pediatrics* 2010; 125(1): e1-8.
- Peltola, H. Roine, I. Fernández, J. Zavala, I. Avala, SG. Mata, AG. Arbo, A. Bolonga, R. Mino, G. Goyo, J. Lopez, E. deAndrade, SD. Sarna, S. (2007). Adjuvant glycerol and/or dexamethasone to improve the outcomes of childhood bacterial meningitis: a prospective, randomized, double-blind, placebo-controlled trial. *Clin Infect Dis* 2007, 15; 45(10):1277-86.
- Pelton, SI. Yogev, R. (2005). Improving the outcome of pneumococcal meningitis. *Arch Dis Child* 2005; 90(4):333–4.
- Pickering, LK. (2009). Summaries of infectious disease. Haemophilus influenzae infections: Page 314-321. *Red Book: Report of the Committee on Infectious Diseases, 28th ed, American Academy of Pediatrics, Elk Grove Village, IL.*

- Pickering, LK. (2009). Summaries of infectious disease. Pneumococcal infections: Page 524-535. *Red Book: Report of the Committee on Infectious Diseases, 28th ed*, American Academy of Pediatrics. Elk Grove Village, IL
- Roine, I, Peltola, H, Fernández, J, Zavala, I, González Mata, A, González Ayala, S, Arbo, A, Bologna, R, Miño, G, Goyo, J, López, E, Dourado de Andrade, S, Sarna, S. (2008). Influence of admission findings on death and neurological outcome from childhood bacterial meningitis. *Clin Infect Dis* 2008; 46(8):1248-52.
- Roos, Kl, Tyler, TL. (2008). *Harrison's Principles of Internal Medicine*. "Chapter 376. Meningitis, Encephalitis, Brain Abscess, and Empyema" [EDITOR NAME] Fauci AS, Braunwald E, Kasper DL, Hauser SL, Longo DL, Jameson JL, Loscalzo J: Harrison's Principles of Internal Medicine 17e: www.accessmedicine.com/content.aspx?aID=2906668. ISBN 978-0-07-147691-1
- Singhi, PD, Singhi, SC, Newton, CRJ, Simon, J. (2008). *Text book of pediatric intensive care, CNS infection, 2008.*, Lippincot Williams and Wilkins. 530 Walnut street Philadelphia, PA 19106 ISBN 970-7817-8275-3.
- Syrogianopoulos, GA, Lourida, AN, Theodoridou, MC, Pappas, IG, Babilis, GC, Economidis, JJ, Zoumboulakis, DJ, Beratis, NG, Matsaniotis, NS. (1994). Dexamethasone therapy for bacterial meningitis in children: 2- versus 4-day regimen. *J Infect Dis* 1994; 169(4):853-8.
- Thomas, R, Le Tulzo, Y, Bouget, J, Camus, C, Michelet, C, Le Corre, P, Bellissant, E. (1999). Trial of dexamethasone treatment for severe bacterial meningitis in adults. *Intensive Care Med* (1999) 25(5): 475-480
- Thwaites, GE, Duc Bang, N, Huy Dung, N, Quy, HT, Oanh Do, TT, Cam Thoa, NT, Hien, NQ, Thuc, NT, Hai, NN, Ngoc Lan, NT, Lan, NN, Duc, NH, Tuan, VN, Hiep, CH, Hong Chau, TT, Mai, PP, Dung, NT, Stepniewska, K, White, NJ, Hien, TT, Farrar, JJ. (2008). Dexamethasone for the treatment of tuberculous meningitis in adolescents and adults. *N Engl J Med* 2004; 351:1741-51.
- Tunkel, AR, Hartman, BJ, Kaplan, SL. (2004). Practice guidelines for the management of bacterial meningitis. *Clin Infect Dis* 2004; 39:1267. Uploaded from <http://www.thecochranelibrary.com/> dated 20/07/2011
- Van de Beek, D, Weisfelt, M, De Gans, J, Tunkel, AR, Wijdicks, EFM. (2006). Drug insight: adjunctive therapies in adults with bacterial meningitis. *Nat Clin Pract Neurol* 2006; 2:504-16.
- Van-de-Beek, D, Farrar, JJ, De Gans, J, Mai, NT, Molyneux, EM, Peltola, H, Peto, TE, Roine, I, Scarborough, M, Schultz, C, Thwaites, GE, Taun, PQ, Zwinderman, AH. (2010). Adjunctive dexamethasone in bacterial meningitis: a meta-analysis of individual patient data. *Lancet Neurol* 2010; 9(3): 254-63



Meningitis

Edited by Prof. George Wireko-Brobby

ISBN 978-953-51-0383-7

Hard cover, 232 pages

Publisher InTech

Published online 30, March, 2012

Published in print edition March, 2012

Meningitis is a medical emergency requiring a rapid diagnosis and an immediate transfer to an institution supplied with appropriate antibiotic and supportive measures. This book aims to provide general practitioners, paediatricians, and specialist physicians with an essential text written in an accessible language, and also to highlight the differences in pathogenesis and causative agents of meningitis in the developed and the developing world.

How to reference

In order to correctly reference this scholarly work, feel free to copy and paste the following:

Emad uddin Siddiqui and Ghazala Irfan Qazi (2012). Role of Dexamethasone in Meningitis, Meningitis, Prof. George Wireko-Brobby (Ed.), ISBN: 978-953-51-0383-7, InTech, Available from:
<http://www.intechopen.com/books/meningitis/role-of-dexamethasone-in-meningitis>

INTECH
open science | open minds

InTech Europe

University Campus STeP Ri
Slavka Krautzeka 83/A
51000 Rijeka, Croatia
Phone: +385 (51) 770 447
Fax: +385 (51) 686 166
www.intechopen.com

InTech China

Unit 405, Office Block, Hotel Equatorial Shanghai
No.65, Yan An Road (West), Shanghai, 200040, China
中国上海市延安西路65号上海国际贵都大饭店办公楼405单元
Phone: +86-21-62489820
Fax: +86-21-62489821