

Aortoiliac Occlusive Disease

Tarek Al-Shafie and Paritosh Suman
*Harlem Hospital Center,
USA*

1. Introduction

Atherosclerotic occlusive (AI) disease of the abdominal aorta and iliac arteries and its clinical manifestation is a common therapeutic challenge encountered by vascular surgeons. It is one subset of peripheral arterial disease which affects 8 to 10 million people in the United States per year. (1)

The aortoiliac occlusive diseases ultimately start at the terminal aorta and the origin of the iliac arteries. The natural history of the disease is slow progression proximally and distally over time to end in complete occlusion of the aorta and iliac arteries. **Fig: 1**

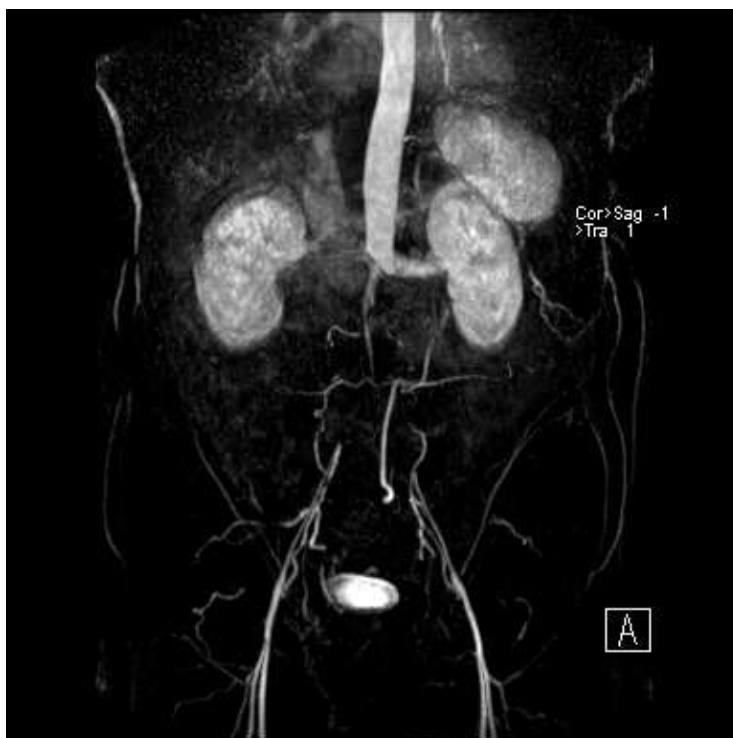


Fig. 1.

Starrett and Stony suggest that the natural history is not always benign and report that in a third of their patients the aortic occlusive disease extends to show thrombosis of the renal arteries over a period of 5 to 10 years. (2)

Others suggest that renal arteries remain open with no incidence of extension of the thrombosis proximally to involve the renal or the mesenteric vessels. (3)

Atherosclerotic occlusive disease is segmental in nature. Stenosis may be in a short or long segment, calcified, ulcerated, concentric or eccentric, single or multiple, unilateral or bilateral and may involve the aorta and iliac arteries alone or together. Approximately 30% of patients with infra inguinal atherosclerotic occlusive disease will have aortoiliac occlusive disease if their circulation is studied carefully.

The majority of patients with atherosclerotic aortoiliac occlusive disease have diffuse disease involving femoro popliteal and infrageniculate vessels. They are commonly older, more likely to be men, have diabetes and hypertension and have concomitant coronary and cerebrovascular diseases. (4)

The aortoiliac occlusive disease can involve isolated segments of the aorta and iliac vessels and usually presents in a younger population, female as male, and have a higher incidence of smoking and hypercholesterolemia as associated risk factors.

Focal infra renal aortic stenosis with no other arteries involved is fairly rare. (5)

Aortoiliac atherosclerotic occlusive disease is characterized by abundant collateralization between abdominal, pelvic and infra inguinal arteries which make the presentation with critical limb ischemia a rare event. A more common presentation is of claudication of varying severity and levels. The two exceptions to this observation are a large thrombus lodged at the narrow aorta causing acute limb ischemia and blue toe syndrome where micro emboli target the small vessels in the toes or the heel.

Being a part of atherosclerotic disease spectrum, aortoiliac occlusive disease has many common risk factors most notably smoking, dyslipidemia, hypertension, diabetes mellitus, male gender, advanced age and high genetic risk.

Isolated aortoiliac occlusive disease primarily occurs in younger patients, more commonly in females and have a higher incidence of smoking and hypercholesterolemia as associated risk factors. They usually have a normal life expectancy. (7) On the other hand, patients with aortoiliac occlusive disease and a more diffuse multilevel pattern of the disease are commonly older, more likely to be male, and more frequently have diabetes and hypertension. They have a higher incidence of concomitant coronary, cerebrovascular, and visceral atherosclerosis. These patients have a significant reduction in their life expectancy when compared with age-matched counterparts. (6) Patients with multi segment diffuse disease present with rest pain, tissue loss and gangrene as opposed to isolated claudication.(8) An aggressive form of the disease was described in a young woman who was a heavy cigarette smoker where a circumscribed calcified occlusive lesion of the middle of the aorta was found. Despite the fact that the upper abdominal aorta is usually spared in the aortoiliac occlusive disease, a minority of such patient has marked involvement of this segment of the aorta with occlusion of the origins of the visceral and renal arteries. (9)

2. Presenting symptoms

Chronic obliterative atherosclerosis of the distal aorta and iliac arteries commonly manifests as symptomatic arterial insufficiency of the lower extremities, producing a range of symptoms from mild claudication to the most severe, critical limb ischemia (CLI).

Claudication, with its characteristic association with ambulation and relief with rest, is the presenting symptom in most of the cases. Severity of claudication and involvement of muscle groups depends on the disease localization.

Intermittent claudication presents with symptoms involving muscles of the thigh, hip and buttock as well as the calf. Because calf claudication is the early manifestation for the infra-inguinal occlusive disease the involvement of more proximal muscle groups may help in identifying the aortoiliac as the diseased level of the circulatory tree. (10)

Unfortunately, sizable numbers of the patient complain of only calf claudication.

Isolated erectile dysfunction is the sole presenting symptom in some men due to significant involvement of hypo gastric arteries. At the other extreme, patients with multilevel disease will suffer from severe rest pain with tissue loss and is usually combined with femoropopliteal occlusive disease.

Aortoiliac disease can present with classic symptoms of Leriche syndrome- namely bilateral lower extremity claudication, impotence, atrophy of muscles and absence of femoral pulses. (11) The equivalent impact of impaired pelvic perfusion in women remains poorly understood but has recently attracted investigative attention. (12)

3. Diagnosis

3.1 History and physical examination

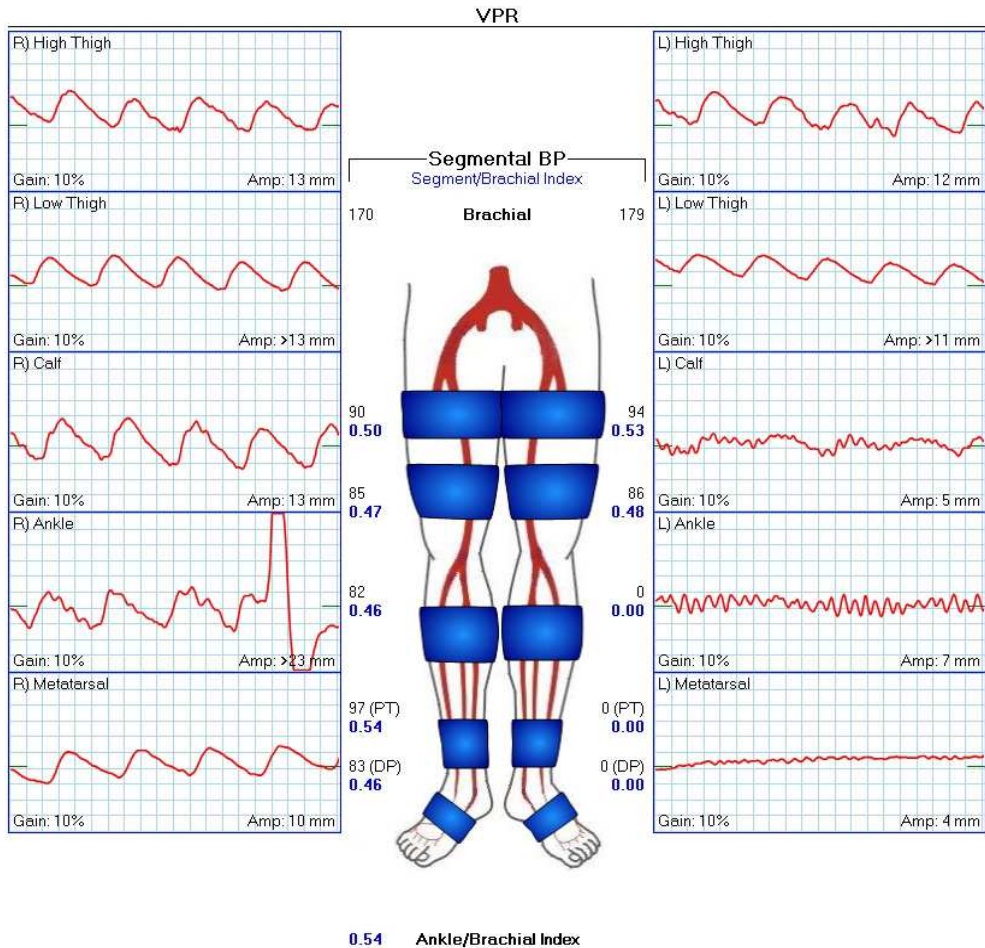
Evaluation of aortoiliac disease commences with a good history and physical examination. The diagnosis of aortoiliac occlusive disease in patients with vascular risk factors with buttock or high thigh claudication and absent femoral pulses is usually straightforward. Claudication symptoms however must be distinguished from those of nerve root irritation due to spinal stenosis or disk herniation or arthritis. These symptoms are produced by standing as well as by walking and follow sciatic nerve distribution. (13)

The variability of presenting signs and symptoms in patients with AI disease sometimes leads to diagnostic confusion. Although proximal claudication is most common, patients with AI occlusive disease in isolation or those with combined infrainguinal disease may present exclusively with calf claudication.

Acute embolism of the distal extremities and toes could be associated with chronic aortoiliac disease. Rare patients who present with complete acute occlusion of aorta can have symptoms related to intestinal and renal ischemia.

The history will often help in determining the need of any systemic evaluation required including cardiac evaluation.

Physical examination will often reveal an absent or diminished femoral pulse. In a minority of patients, pulses could be palpable but will disappear with ambulatory efforts. An occasional bruit over the lower abdomen or groin can help in unmasking an underlying arterial lesion resulting in a turbulent blood flow. Advanced long-standing aortoiliac disease often has signs of atrophic changes such as cool, shiny, hairless skin with rubor. Patients with chronic multilevel disease can have atrophic leg muscles or in more severe cases gangrene or nonhealing ulcers. (14)



Absent arterial flow in left PTA and DPA

Fig. 2.

3.2 Non invasive arterial studies

Noninvasive laboratory testing serves two major purposes in evaluation of suspected aortoiliac occlusive disease: confirmation of disease when history and physical examination is equivocal; second to establish a baseline for follow up and assessing the therapeutic outcomes.

Ankle-brachial indexes (ABIs), segmental pressure measurement, and pulse volume recordings are the three most common employed modalities. **Fig. 2**

Noninvasive arterial studies show inflow problems and decrease in the thigh brachial index and decrease in the wave amplitude. A difference of at least 20 mm Hg between the brachial pressure and the proximal thigh pressure reflects a significant stenosis in the aorta or iliac arteries, but it may be confused by proximal SFA occlusion. A further reduction in pressure between the thigh and ankle level is consistent with concomitant SFA, popliteal, or tibial outflow disease. (15)

Patients with disabling claudication occasionally demonstrate normal or near normal ankle brachial indices. Repeating the tests after a period of gradual exercise show marked fall in the ankle brachial index if the patients have significant aortoiliac disease. (16)

Noninvasive evaluation is sufficient for diagnosis of aortoiliac occlusive disease in most of the patients. If patient is deemed suitable for operative intervention, further disease localization is determined with Duplex sonography and CT angiography (CTA) or MR angiography (MRA).

4. Imaging

4.1 Duplex ultrasound

By an experienced technician, duplex ultrasound is an excellent noninvasive tool to delineate arterial lesion with further color mapping and stenosis identification. **Fig 3**

Duplex ultrasound is particularly useful in patients with renal insufficiency in whom avoidance of usage of contrast agents is important. Some institutions obtained useful information for preoperative planning. (17).

Duplex assessment of the AI, renal, and visceral arteries is operator dependent, time consuming and needs a dedicated vascular laboratory and trained personnel. The presence of bowel gas, obesity and vessel tortuosity make the precise determination location and the severity of the stenosis difficult. We do not usually use arterial duplex as a sole modality in the management of aortoiliac disease. With the continuous advance in the technology, as operator skill and training improve, and as novel adjunctive duplex imaging agents evolve, this modality will likely play an increasing role in the management of patients with visceral and AI disease. At present, however, it remains inferior to other imaging techniques for preoperative planning. (18)

5. Computerized Tomographic Angiography (CTA)

With the development of the 64-slice multidetector scanner, with shorter acquisition time, high quality, non invasive and three dimensional processing capabilities CTA has become most frequently used imaging modality. The studies are obtained quickly, requiring no more than a few minutes to scan from the proximal abdominal aorta to the feet, which

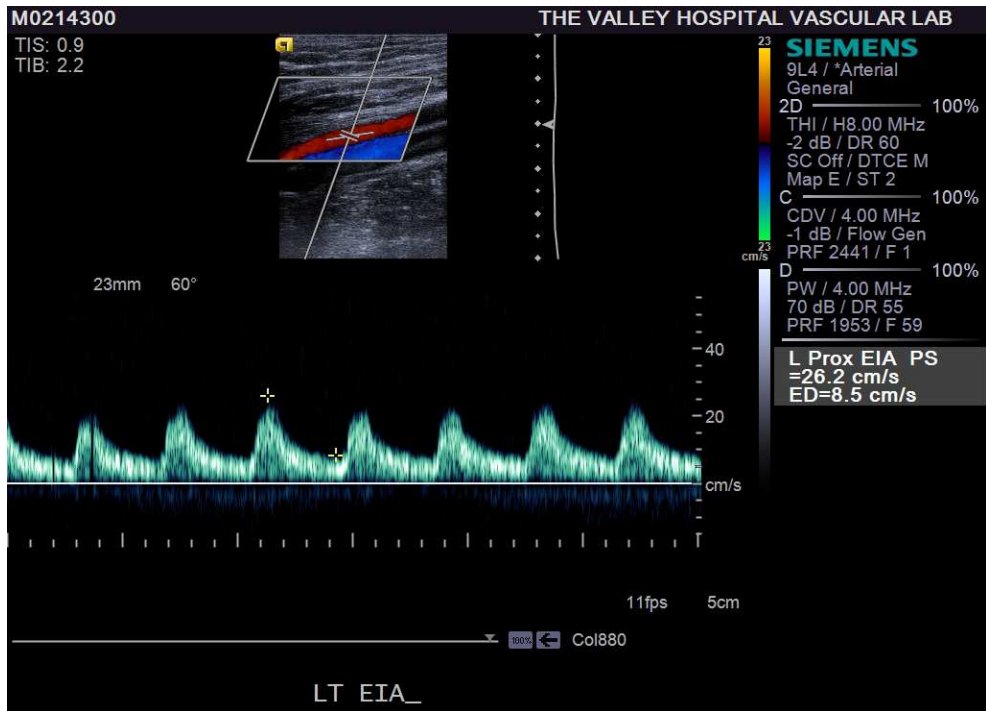


Fig. 3.

minimizes issues related to patient noncompliance. The three-dimensional reconstruction of images provides the physician not only with views of angiographic quality but also with the ability to rotate images along vertical and horizontal axes to obtain a 360-degree assessment of the vessels. A recent meta-analysis of multidetector CTA for the evaluation of the lower extremity arterial tree confirmed the value of this modality. This analysis revealed that CTA has an overall sensitivity and specificity of 96% and 97%, respectively. (19)

Despite these excellent results, there are limitations to the widespread use of CTA. There is concern because of the requirement for an intravenous bolus of iodinated contrast. This high contrast load limits the use of CTA to patients with normal renal function, unless medical necessity dictates otherwise. Also, in the presence of significant amounts of arterial wall calcium, small arteries that are occluded with calcified plaque may be misconstrued as patent. The cross-sectional images must be carefully reviewed and compared with the reconstructed three-dimensional images. Metal artifact may obscure images in patients with metal implants or surgical clips in their legs. (20)

In many centers CT angiography with three dimensional processing capabilities has supplanted contrast angiography and MRA as the initial imaging study of choice for aortoiliac occlusive disease especially for patients who are not candidates for MRA because of the presence of a pacemaker or other metallic implant not suitable for the magnetic field, and those who are unable to lie in the supine position for long periods. (21) **Fig 4**

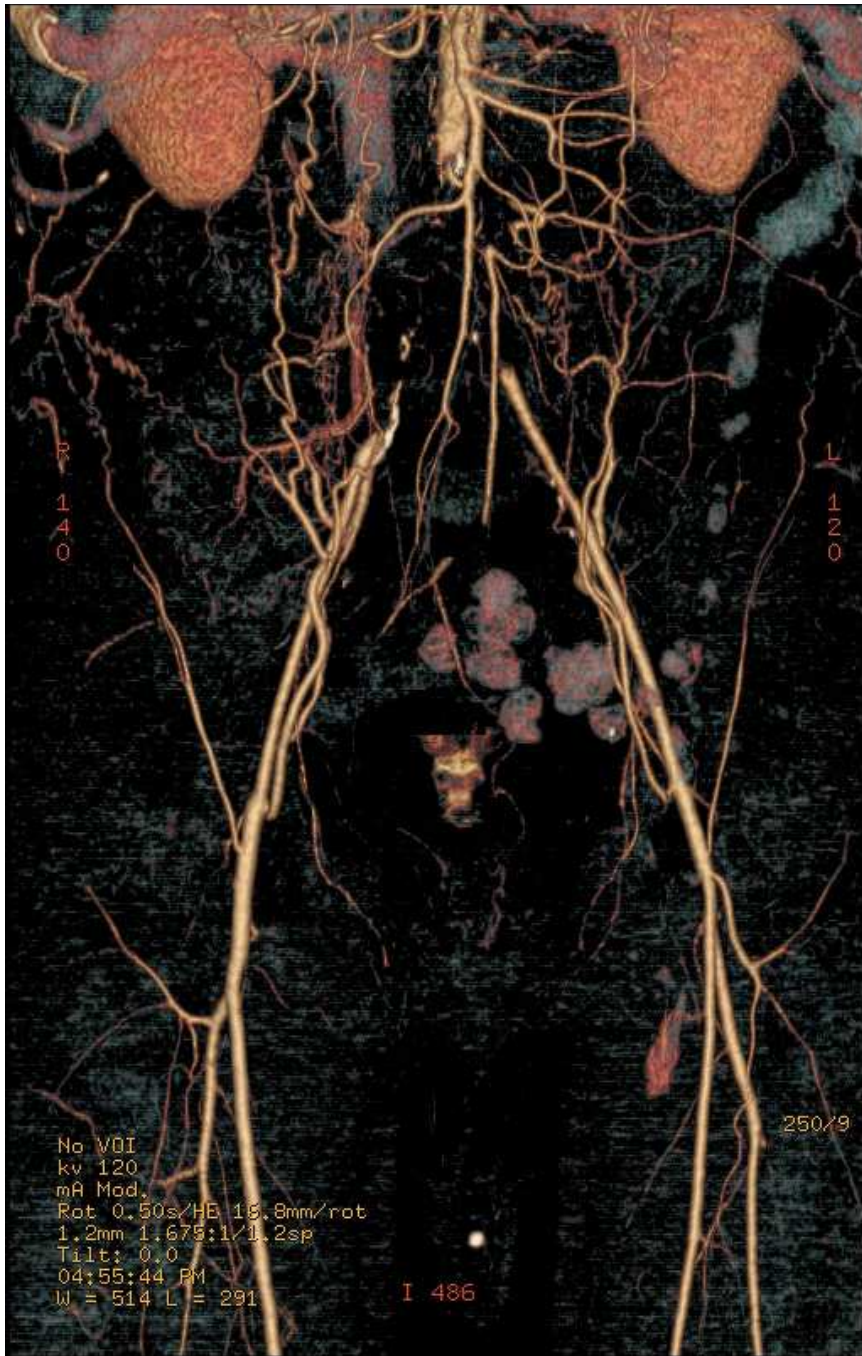

Fig. 4.

6. Magnetic Resonance Angiography (MRA)

MRA is used for the evaluation of patients with aortoiliac occlusive disease because it can visualize the entire arterial tree, including pedal vessels, without the use of arterial puncture or standard ionic contrast agents. MRA can reveal a patent pedal vessel suitable for grafting that was not seen on conventional angiography. Exaggeration of the degree of stenosis within a vessel has been noted. Contrast-enhanced MRI had a sensitivity of 92 % and a specificity of 92%. (22)

MRA also has patient-related difficulties. Patients with newly placed metallic implants are frequently not candidates. Others may require sedation because of claustrophobia or difficulty lying flat for a long time. Additionally, although gadolinium is only mildly nephrotoxic, it may adversely affect renal function in patients with preexisting renal insufficiency. (23) More recently, there have been reports of nephrogenic systemic fibrosis related to the administration of gadolinium to patients with a glomerular filtration rate less than 30 mL/min. The incidence may be highest in those with end-stage renal failure who require hemodialysis. Although this complication is infrequent overall, in view of the large number of gadolinium-enhanced magnetic resonance angiograms performed each year, nephrogenic systemic fibrosis is associated with significant disability and mortality. (24) **Fig 1**

7. Arteriography

Digital subtraction angiography (DSA) which is the gold standard for diagnosis of all arterial occlusive diseases, especially if anatomic questions remain, has largely been replaced by computerized tomographic angiography (CTA) and MRA and increasingly been selectively performed for endovascular intervention. **Fig 5**

In many centers magnetic resonance angiography with three dimensional processing capabilities has supplanted contrast angiography as the initial imaging study of choice.

When CTA or MRA show a lesion which is amenable for percutaneous intervention arteriography is then performed for confirming the finding and for treatment. If the anatomic pattern is unfavorable to a percutaneous approach, aortoiliac reconstruction can be planned directly from the information obtained by MRA or CTA. In cases in which the decision has been made to proceed with surgical revascularization, angiography may be undertaken to obtain a final detailed roadmap of the relevant anatomy. (25) Attention should be directed to the inferior mesenteric artery; a large patent inferior mesenteric artery, particularly in the presence of superior mesenteric artery or hypogastric artery occlusive disease, may require preservation during aortic reconstruction to avoid potentially disastrous bowel ischemia. Multiple projections of the iliac and femoral bifurcations are essential to clarify the extent of disease in these regions. Full runoff views of the lower extremities are also needed to assess the presence or absence of femoropopliteal or tibial disease. (26)

Standard retrograde femoral approach is used more frequently despite long-segment near-occlusive or occlusive aortic or bi-iliac disease. Lateral and oblique views of the abdominal aorta are essential to delineate possible concomitant mesenteric or renal artery occlusive disease. Transbrachial approach is sometimes required. (27)

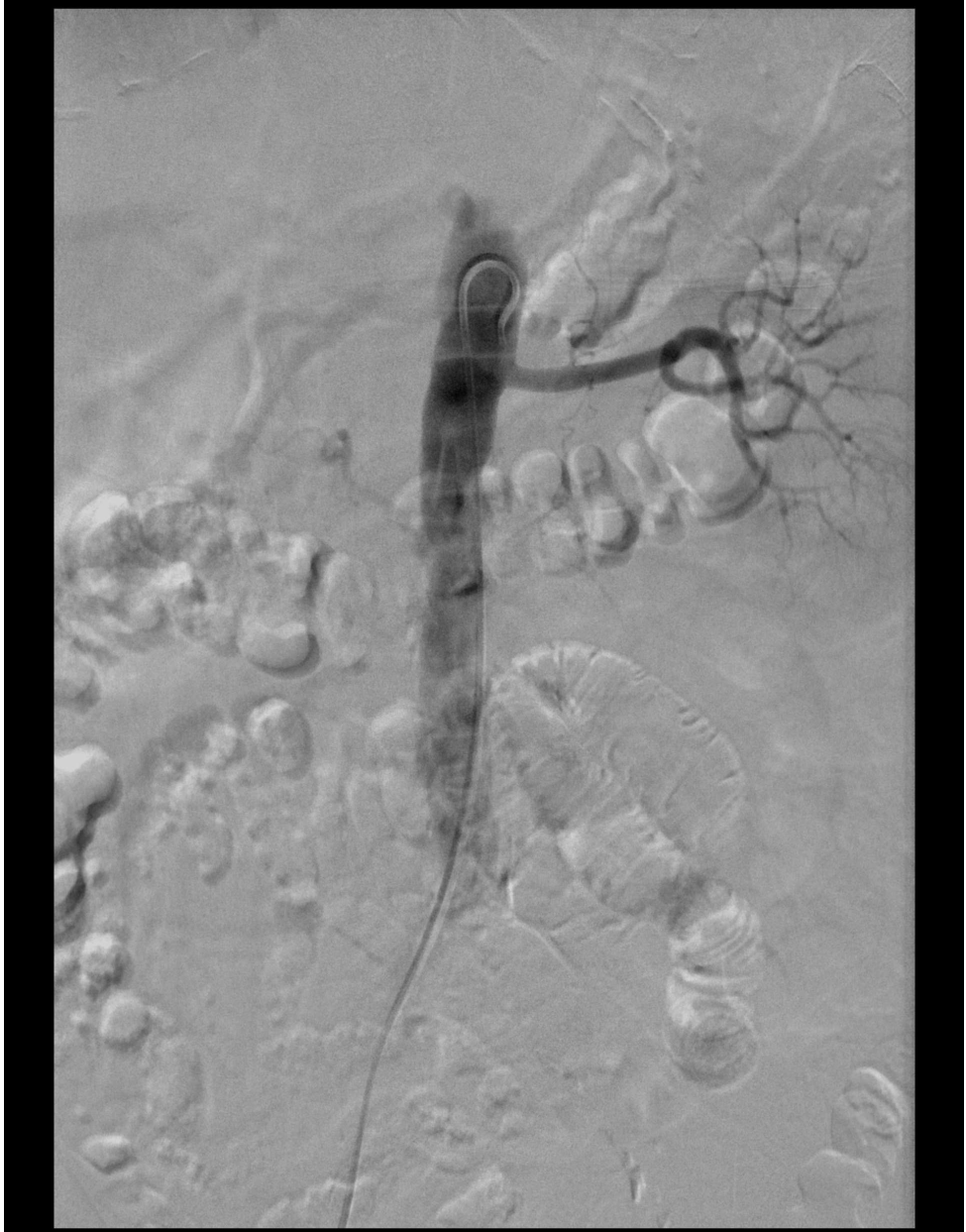
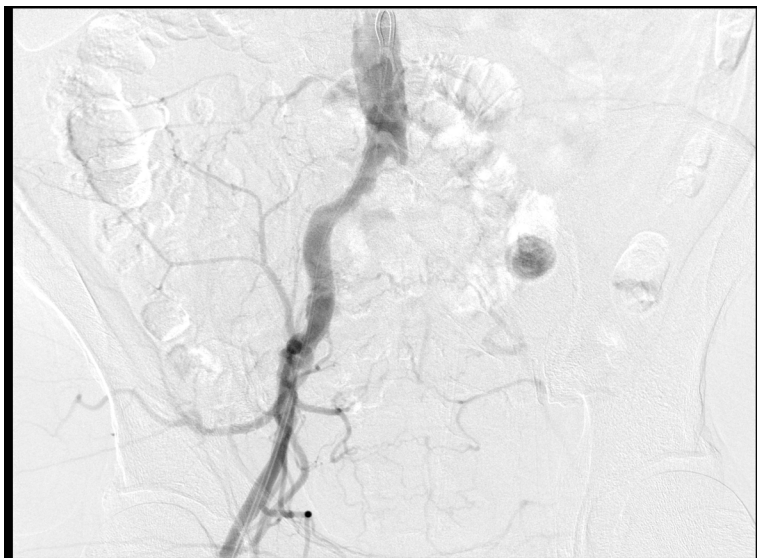

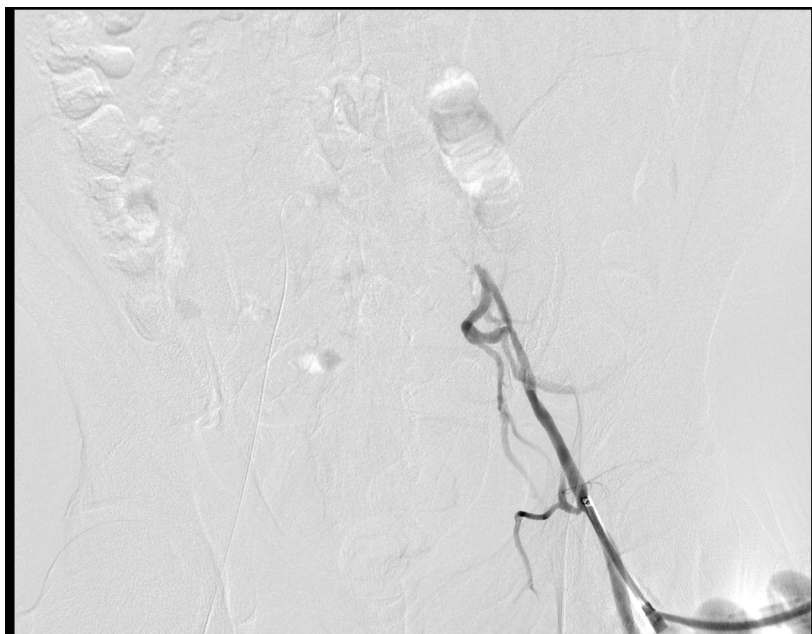
Fig. 5.

At the time of angiogram, obtaining pressure gradient across the iliac artery lesions of doubtful significance is a useful technique to demonstrate whether such lesions are interfering with the blood flow. Measurements should be obtained and if there is no

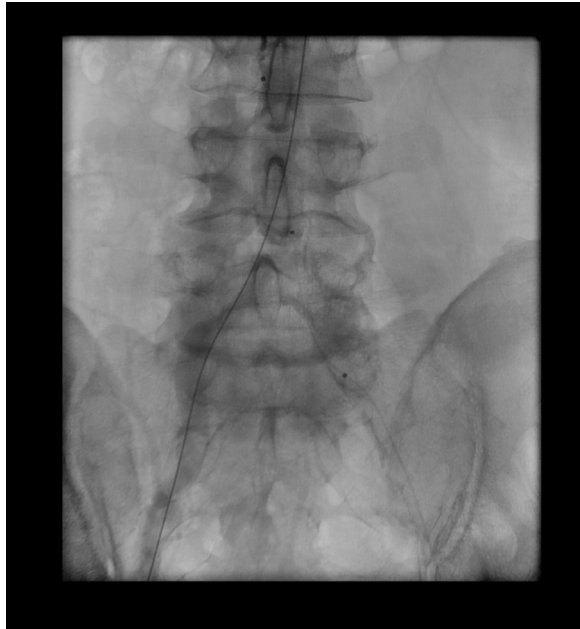significant difference, it should be repeated after induction of vasodilatation in the arteries of the lower extremities by intra-arterial injection of papaverine. Alternatively, causing reactive hyperemia by applying a tourniquet to the lower extremity. A resting systolic



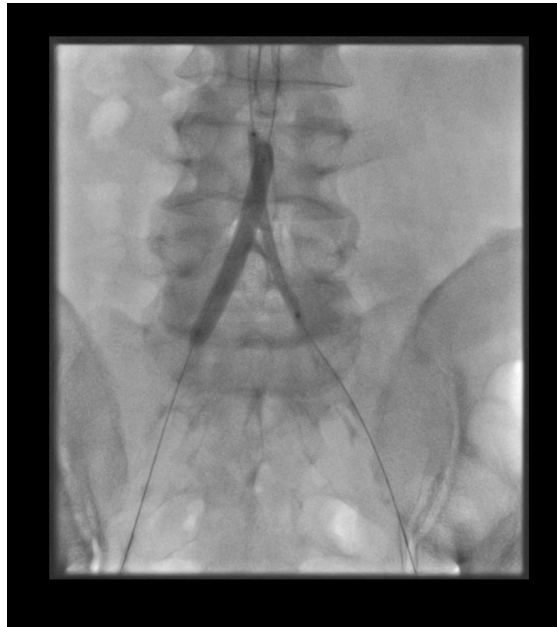
A



B



C



D

Fig. 6.

gradient of approximately 5 to 10 mm Hg or a change in the systolic pressure greater than 15% following pharmacologic vasodilatation is a reliable indicator of disease warranting inflow revascularization. (28) Because there is no image loss induced by arterial wall calcium, angiography is required in patients in whom the distal vasculature cannot be completely evaluated. Angiography is associated with higher morbidity and mortality risks, however, than other imaging modalities. There is an estimated 0.1% risk of a significant reaction to the contrast medium, a 0.16% risk of mortality, and a 0.7% risk of a serious complication adversely affecting planned therapy. (29) Fig 6 (A-D)

Patients with borderline renal function, especially those who are diabetic, present a special challenge. Improvements in image processing have renewed the interest in carbon dioxide angiography, a modality that can clearly delineate both large, high-flow vessels and smaller, distal vessels. The gas infusion is well tolerated and has no adverse effect on renal function, although it may be difficult to clear in patients with severe chronic obstructive pulmonary disease. (30) In patient with renal insufficiency angiography using carbon dioxide as a contrast has been used routinely in our institute.

Whatever the modality used for the diagnosis of aorto iliac occlusive disease, delineation of the infrainguinal arterial tree is essential in the pre intervention planning. **Fig 7**

Adoption of these advanced diagnostic modalities has made the diagnosis of aortoiliac disease very straightforward. Nonetheless, there will always be patients presenting with lower extremity pain when other causes are responsible for the symptoms. Most often neurogenic claudication, arthritis of hip joints and peripheral nerve disease are the culprits. Again a good history and physical examination supplemented with noninvasive evaluations should be sufficient to distinguish these diagnoses. Determination of the contribution of these associated causes in symptomatology prior to any therapeutic intervention will help in avoiding disappointment with the outcome.

8. Treatment of aortoiliac occlusive disease

Management of aortoiliac occlusive disease present a unique challenge due to the complex interplay of factors that must be considered, including the underlying pathology, anatomic defect, presence of distal disease, degree of ischemia, co-morbid conditions, functional status, ambulation potential, and suitability of anatomy for successful revascularization.

In general patients with lower extremity ischemia are typically divided into two groups in regard to their presentation, those with intermittent claudication and those with critical limb ischemia (CLI). (31)

There is an agreement on the treatment of the CLI because the natural history of untreated CLI more frequently leads to limb loss. Patients with CLI often have severe associated cardiovascular co-morbidities and are generally older and in poorer health than those with claudication. In contrast, patients with claudication typically seek treatment for the relief of lifestyle-limiting pain with ambulation. These patients exhibit a more benign natural history with respect to limb viability, with amputation rates of 1% to 7% at 5 years and clinical deterioration of the limb in only 25%. (32)

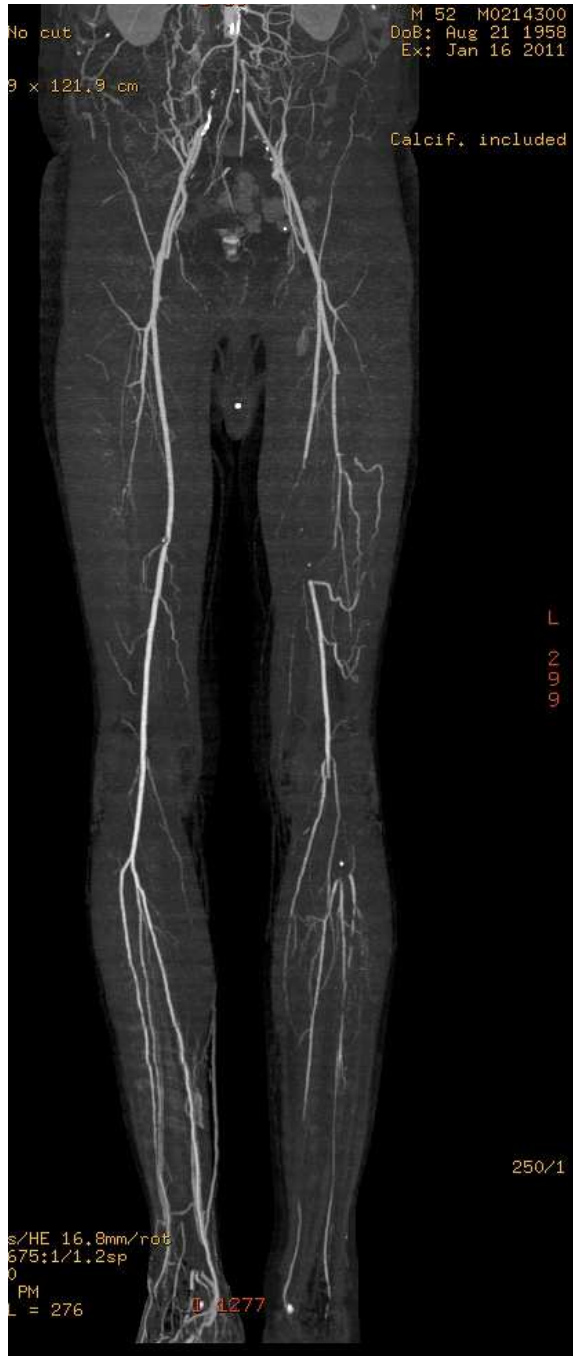

Fig. 7.

9. Medical therapy

In patient with CLI, claudication is a marker of significant systemic atherosclerosis, with associated cardiovascular mortality rates at 1, 5, and 10 years as high as 12%, 42%, and 65%, respectively. All patients with PAD require medical management and often benefit from interventional or surgical treatment, as discussed later.(30)

Medical therapy plays an essential part in the management regimen of aortoiliac occlusive disease. It is instituted in all patients with the aims of symptom improvement, prevention of limb loss and reduction of the risk of cardiovascular complications. Risk factor modification is an integral part of medical therapy. Smoking cessation and an optimal control of diabetes mellitus, hypertension and hyperlipidemia has been shown to reduce the proliferation of the atherosclerotic disease process. (32) The primary care physician in collaboration with the vascular surgeon should follow the risk-factor modification guidelines.

Parameter	Target Goal	Therapy
Blood pressure	Systolic <130 to 140 mm Hg Diastolic <80 to 90 mm Hg	β -Blockers, ACE inhibitors
Diabetes mellitus	Hemoglobin A1c <7%	Insulin, \uparrow insulin sensitivity
LDL cholesterol	<100 mg/dL	Diet, statins
HDL cholesterol	Men, \geq 35 mg/dL Women, \geq 45 mg/dL	Diet, fibric acid derivative
Tobacco cessation	Complete abstinence	Nicotine replacement, antidepressants, behavioral therapy
Exercise therapy	All patients	Supervised program three or more times a week
Antiplatelet therapy	All patients	Aspirin (81 or 325 mg/day), clopidogrel (75 mg/day)
Pharmacologic therapy	Trial in all patients with claudication in the absence of heart failure	Cilostazol

Hirsch AT, Haskal ZJ, Hertzner NR, et al: ACC/AHA guidelines for the management of patients with peripheral arterial disease: summary of recommendations, *J Vasc Interv Radiol* 17(9):1383–1397, 2006. ACE, Angiotensin-converting enzyme; LDL, low-density lipoprotein; HDL, high-density lipoprotein.

Table 1. American College of Cardiology/ American Heart Association guidelines for the management of patients with peripheral arterial disease

Smoking cessation has been shown to reduce the risk of MI and death in patients with PAD and to delay the progression of lower extremity symptoms from claudication to CLI and limb loss.(34) The importance of smoking cessation extends to patients who have undergone lower extremity revascularization because there is a threefold increased risk of graft failure in smokers compared with nonsmokers. (35)

In association with the risk-factor modification, daily exercise regimen can also significantly alleviate the symptoms and help in regaining some functional capacity. An increased

tolerance to demand ischemia has been postulated as a probable mechanism for such observed improvement.

Institution of antiplatelet therapy is often prudent in aortoiliac occlusive disease. Although antiplatelet agents have not been shown to directly improve the outcome of aortoiliac occlusive or peripheral arterial disease, aspirin or clopidigrel do achieve a significant improvement in the treatment of atherosclerotic disease of coronary and cerebral arterial systems. Cilostazol (100 mg two times a day) is effective in increasing overall ambulation distance. This medication is limited to patients with peripheral arterial disease with intermittent claudication and no history of congestive heart failure.

Other pharmacological agents like pentoxifylline can also be used but none of these agents have been shown to gain a significant practical improvement in symptoms.(33)

In claudication there is a convincing data suggesting that the efficacy of medical treatment is comparable to interventional therapy like Edinburgh walking study.

In Critical limb ischemia medical treatment plays a secondary role and revascularization is the essential component for limb salvage.

10. Surgical and endovascular treatment

The indications for surgery and intervention in symptomatic aortoiliac disease are disabling claudication and ischemia at rest manifested by rest pain in the foot, ischemic ulceration or pre gangrenous skin changes. (1)

10.1 Open vs. endovascular

Traditionally aortoiliac occlusive lesions were operated by an open approach. Aortobifemoral bypass is the method of choice. Increasingly endovascular techniques are being adopted for less severe occlusion when there is no extensive involvement of aorta or common iliac arteries. Also for patients with severe comorbidities endovascular methods could be an alternative.

A significant change has occurred in the treatment of atherosclerotic arterial disease. Angioplasty and stenting have become first-line therapy for most patients with aortoiliac occlusive disease. An 850% increase in the use of percutaneous transluminal angioplasty and stenting for AI occlusive disease from 1996 to 2000, along with a simultaneous decrease of 16% in the rate of aortobifemoral grafting. (36)

The Trans-Atlantic Inter-Society Consensus for the Management of Peripheral Arterial Disease (TASC) published a document authored by a working group of representatives from 14 surgical vascular, cardiovascular, and radiologic societies and upgraded document (TASC II) was published in January 2007. These important works interpreted evidence-based data concerning the treatment of lower extremity PAD and offered a series of treatment recommendations based on presentation. (1) **Fig 8**

Whereas percutaneous treatment of the aorta and iliac arteries was previously limited to short-segment, Trans-Atlantic Inter-Society Consensus (TASC) type A or B iliac lesions, wire-based technology has now been successfully applied to even long-segment (TASC type D) occlusions extending for the length of the iliac arteries. (36).

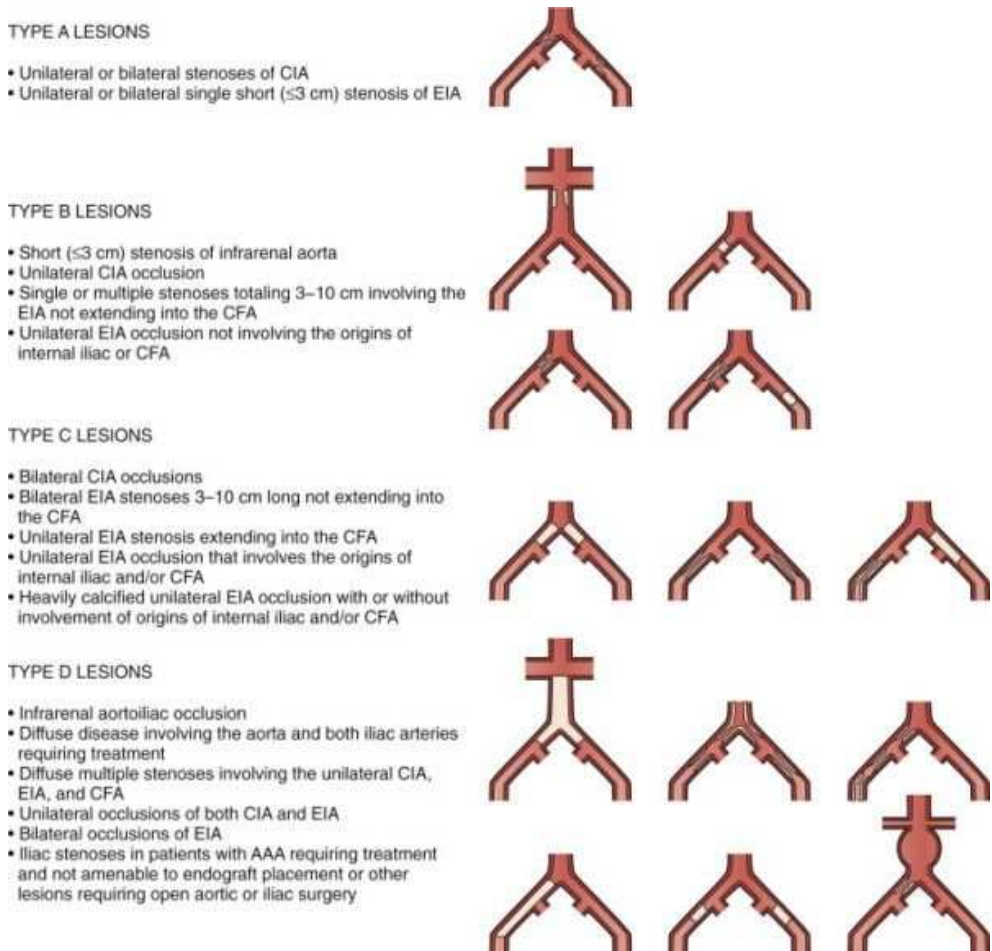


Fig. 8. TASC classification of aortoiliac lesions. AAA, abdominal aortic aneurysm; CFA, common femoral artery; CIA, common iliac artery; EIA, external iliac artery.

Surgical risk assessment is routinely performed preoperatively as coronary artery disease and other comorbidities have frequently been shown to be associated with aortoiliac occlusive disease.

11. Open procedures

Open surgery for aortoiliac disease become a second- or even third-line therapy and is increasingly undertaken in patients in whom endovascular treatment has been technically unsuccessful or in those with such extensive disease that an endovascular approach is deemed inadvisable. Patients with a combination of more proximal aneurysmal disease and common or external iliac occlusive disease continue to be good candidates for open reconstruction. (37) Patients with disease extending to the CFA are can potentially be

managed with a hybrid approach, whereby the CFA plaque is treated with a traditional endarterectomy and patch repair and the iliac component is concurrently addressed with endovascular techniques. (38) Patients with significant renal failure in whom endovascular therapy entails a prohibitive risk of triggering dialysis dependence are also considered better suited for operative repair.

Preoperative evaluation of the patients with aortoiliac occlusive disease and assessment of the factors that can increase the intra operative and postoperative complication are essential. About 50% of patients with aortoiliac occlusive disease have evidence of coronary artery disease. Despite the fact that myocardial infarction remains the leading perioperative complication, the reduced perioperative mortality and morbidity after aorto iliac surgery are due to advance in the treatment of concomitant coronary artery diseases. The routine use of perioperative beta blockade is probably the most important practice. The cardioprotective value of continuing aspirin through the time of AI reconstruction has now been clearly documented. Patient with mild or stable coronary artery disease with no recent angina or myocardial infarction can go for surgery without great risk. Patient with unstable angina or recent MI will need more investigation and coronary revascularization first. (39)

Patients with renal insufficiency should be given time for their kidneys to recover from the effect of the contrast and also be hydrated. Pulmonary function should be optimized in patients with restrictive pulmonary disease with bronchodilators and smoking cessation before going for aortoiliac surgery.

Preoperative fluid status optimization, adequate intravenous access, intra-arterial pressure monitoring, Foley catheter placement, and preoperative antibiotics to minimize the risk of prosthetic and wound infection are routine aspects of aortic replacement surgery. (40) Attention should be paid to maintaining normothermia throughout the procedure to reduce the significant organ dysfunction and operative mortality associated with intraoperative hypothermia. An epidural catheter is usually placed for postoperative pain control. (41)

11.1 Aortofemoral bypass graft

As mentioned earlier, aortofemoral bypass graft is the most preferred surgical method whenever feasible.

In the standard operative technique the femoral vessels are typically exposed first to reduce the time during which the abdomen is open and the viscera exposed. The extent of exposure is dictated by the severity of disease and the level of reconstruction planned at the CFA and its bifurcation. A crossing vein normally present beneath the inguinal ligament must be ligated or carefully avoided to prevent bleeding during the tunneling process.

Infrarenal aortic exposure is often performed through a transperitoneal approach via a longitudinal midline laparotomy; some surgeons prefer a transverse incision. The abdomen is explored for any other pathology. The transverse colon is retracted cephalad, and the small bowel is shifted to the patient's right side. The duodenum is mobilized to the right, allowing access to the infrarenal aorta. The retroperitoneal tissue overlying the aorta is dissected superiorly to the level of the left renal vein, and the larger lymphatic vessels encountered within the retroperitoneal lymphatic network are ligated. Careful dissection should be used below the left renal artery to avoid injury to the lumbar vein draining to the

left renal and to gonadal vein. Extensive dissection anterior to the aortic bifurcation and proximal left iliac artery should be avoided because the autonomic nerve plexus regulating erection and ejaculation in men sweeps over the aorta in this region.

It is important to extend the reconstruction close to the level of the renal arteries to minimize the risk of failure secondary to disease progression. If end-to-side repair is planned, exposing and controlling all relevant lumbar or accessory renal arteries before performing the aortotomy helps avoid backbleeding.

Creation of the tunnel for the graft is done by finger dissection on the anterior surface of the iliac arteries. On the left side, the tunnel passes beneath the sigmoid mesentery and slightly more laterally in an effort to avoid disruption of the autonomic nerve plexus. Moist umbilical tapes or Penrose drains are passed with a smooth aortic clamp to mark the tunnels. With vessel exposure and tunnel creation complete, but before vascular occlusion, heparin for anticoagulation is given as an intravenous bolus and repeated doses may be necessary, depending on the length of the clamp placement.

The aorta is clamped first proximally at the site of least disease to avoid dislodgement and potential distal embolization of plaque. If an end-to-end anastomosis is planned, the aorta is transected below the proximal clamp, and the distal aorta is oversewn in two layers with running monofilament suture.

Although some surgeons prefer polytetrafluoroethylene (PTFE) grafts, knitted polyester (Dacron) grafts are more commonly used.

There is still considerable debate involves the type of proximal anastomosis, both end-to-end and end-to-side techniques are acceptable and effective and each may be preferred in certain circumstances.

Surgeons favoring an end-to-end anastomosis claim that it has less turbulence, lower rates of proximal suture line pseudoaneurysm and better long-term patency rates reported in some series. (42) The graft lies flatter in the retroperitoneum, this enhances the ability to close the retroperitoneum over the graft, resulting in a lower rate of late graft infection and aortoenteric fistulae.

There are certain circumstances when an end-to-side proximal anastomosis is advantageous. The most common indication is in patients with occluded or severely diseased external iliac arteries but patent common and internal iliac arteries. Without the retrograde flow through the external iliac arteries normally present in an end-to-end configuration, pelvic ischemia, ranging from mild hip claudication to severe buttock rest pain or ulceration, may result. (43) Additional ischemic complications, such as erectile dysfunction in males and rarely seen paraplegia. (44)

Large inferior mesenteric artery with little back flow and important accessory renal artery can be re-implanted to the graft.

The graft limbs are then passed through the retroperitoneal tunnels, taking care to prevent twisting and to eliminate excess redundancy. Care is taken to match graft size to femoral artery diameter. Arteriotomy limited to the distal CFA sometimes is sufficient. More commonly, extension of the arteriotomy across the profunda femoris artery origin and profundaplasty will prove necessary. The distal anastomoses are completed in an end-to-

side fashion using flushing maneuvers before completing the anastomoses. It is very important to alert the anesthetic team before releasing the clamp, to be prepared to avoid blood pressure drop with reperfusion.

Once hemostasis is sufficient, the abdomen is irrigated and the retroperitoneum is closed. If adequate retroperitoneal coverage is not possible, particularly with an end-to-side proximal anastomosis, a sleeve of omentum should be fashioned to cover any exposed segment of the anastomosis and to separate the graft from the adjacent bowel. The groin wounds are copiously irrigated with antibiotic solution, and the deeper tissue is closed in several layers using absorbable Vicryl sutures.

Confirm adequate distal perfusion and ensure that no distal embolization has occurred.

Although aortobifemoral bypass is easier and has better long term patency compared to aortobiiliac bypass, in certain circumstances performing an aortobiiliac bypass remains advantageous. In patients with hostile groin creases from prior surgery or radiation therapy, or are obese, diabetic patients with an intertriginous rash at the inguinal crease and patent external iliac arteries, the impact of synchronous SFA disease on the results of AI revascularization remains undefined. Although up to 80% of patients with claudication and both inflow and outflow disease manifest symptomatic improvement following aortofemoral bypass grafting alone. (45) If significant tissue loss is present, concurrent inflow and outflow procedures are likely warranted if limb salvage is to be achieved. (46)

The graft patency rates continues to improve and the accumulated experience to date has shown that 5-year primary patency rates between 85% and 90% and 10-year rates between 75% and 85% can be expected with aortobifemoral grafting

Similarly the perioperative mortality rate continues to decline and less than 2% mortality is a standard now. (47, 48) Age has proved to be a significant predictor of outcome; in one report, primary patency rates at 5 years were greater than 95% for patients older than 60 years but only 66% for those younger than 50 years. (49)

11.2 Complications

Reported overall morbidity rates range from 17% to 32% following aortic surgery for occlusive disease include cardiac complications which are the most common cause of mortality and result from the hemodynamic stress associated with major vascular surgery and the obligatory fluid shifts during the early postoperative period. Pulmonary complications are most likely to occur in the elderly or those with chronic obstructive pulmonary disease. Acute renal failure following aortic reconstruction for occlusive disease is relatively uncommon in patients with normal preoperative renal function.

Adequate hydration and avoiding repetitive aortic cross-clamping and perioperative hypotension are valuable prophylactic maneuvers; the adjunctive use of mannitol and furosemide (Lasix) prior to aortic cross-clamping is less documented despite its wide use. Intraoperative injury to the ureters during dissection, graft tunneling, intraoperative injury to the small and large bowel can usually be avoided with careful surgical technique. For patients undergoing aortobifemoral grafting, postoperative hemorrhage is a relatively rare event, occurring in 1% to 2% of cases. (37, 47)

Careful postoperative monitoring of the abdominal girth, hematocrit, bladder pressure, coagulation parameters, and hemodynamic status is paramount to identify ongoing bleeding significant enough to require urgent reoperation.

Intestinal ischemia following aortic reconstruction has been reported in 2% of cases.

If compromised bowel perfusion is recognized intraoperatively inferior mesenteric artery re-implantation is indicated. Maintaining a high index of suspicion and having a low threshold for performing sigmoidoscopy during the early postoperative period are critical (50)

Spinal cord ischemia is a devastating complication of aortic surgery and the main component of prophylaxis is careful preservation of hypogastric perfusion. Fortunately, this complication is uncommon, occurring in only 0.3% of AI reconstructions for occlusive disease in one series. (51)

Late complications following aortobifemoral grafting include graft limb thrombosis, graft infection, aortoenteric fistula, and anastomotic pseudoaneurysm

Graft thrombosis is the most frequently encountered late complication. It occurs in as many as 30% of cases in some series in which the grafts were observed for 10 years or longer. (52) Inflow can frequently be restored with aggressive efforts using special thrombectomy catheters. If successfully restored, revising the distal anastomotic site with a profundaplasty or extension of the graft may prove necessary. If restoring the flow through the graft is unsuccessful a femorofemoral or axillofemoral graft usually suffices as a secondary source of inflow.

Prosthetic graft infection is a particularly feared complication of aortic reconstruction, given its high associated morbidity and mortality. Diagnosis can be established with CT if there is clinical suspicion. Once infection is diagnosed, graft excision is usually indicated and inflow established with extra anatomical bypass. (53)

Aortoenteric fistula is another rare but potentially devastating late complication associated with aortobifemoral. The most common pathophysiologic process is erosion of the proximal aortic suture line through the third or fourth portion of the duodenum, although fistulae between the iliac anastomoses into the small bowel or colon are also well described. Commonly presented with a small, self-limited bleed then become large or massive bleeding. Treatment is usually similar to that for graft infection; extra-anatomic bypass and graft removal are usually required, covering the aortic stump with adequate tissue coverage and repair of the involved gastrointestinal tract. (54)

Pseudoaneurysm of the anastomotic line are far less but they continue to be seen as a late complication in 1% to 5% of patient after aortobifemoral bypass. They arise secondary to a weakening in the suture line as a result of structural fatigue or fabric degeneration. Undue tension, poor suturing technique, and focal weakening of the recipient arterial wall have been implicated as causative factors. Infection undoubtedly plays a role in many cases, despite the frequent absence of any obvious clinical signs; Staphylococcus species are the predominant organisms identified in culture. Femoral anastomotic false aneurysms are most common and typically present as a slowly enlarging, asymptomatic groin bulge. Given the potential complications of thrombosis, embolization, or rupture, repair is generally recommended for femoral false aneurysms larger than 2 cm or aortic false aneurysms greater than 50% of the graft diameter. Proximal anastomotic false aneurysms are often

discovered incidentally or noted when they rupture. Treatment usually consists of débridement of the degenerated tissue and placement of a short interposition graft. (55)

11.3 Aortoiliac endarterectomy

During the 1950s and 1960s, endarterectomy was the standard therapy for severe AI occlusive disease. Enthusiasm for the procedure dimmed, however, with the introduction of prosthetic graft. An obvious benefit of endarterectomy is the elimination of the need for a prosthetic graft, making it an appealing alternative in the setting of infection. Advocates have likewise pointed to the advantages of endarterectomy for younger patients or those with small vessels who are less than ideal candidates for endovascular therapy or aortobifemoral grafting.

In patients with localized aortoiliac disease, aortoiliac endarterectomy may be suitable options and have excellent long-term patency rates, compare with aortic bypass grafting, have been reported. (56) In contrast, results in cases of long-segment disease involving the entire infrarenal aorta and extending into the external iliac arteries have been disappointing. (57) In our practice, aortoiliac endarterectomy is rarely done. The increasing popularity of endovascular therapy is further decrease the small proportion of patients considered suitable for this reconstructive approach.

11.4 Crossover bypass

A few patients with only one iliac artery involvement with good aortic and contralateral iliac artery can be offered the choice of supra pubic ilioiliac and femorofemoral bypass graft. Hemodynamic studies confirm that one iliac artery can support both legs, at least at rest, in the absence of flow-limiting lesions in the planned donor iliac arterial system. (58, 59) Even a diseased donor iliac arterial system may be improved with endovascular techniques to allow a less invasive yet effective femorofemoral bypass when a more invasive procedure would otherwise be required. The majority of the studies published have found that iliofemoral bypass yields somewhat better patency than femorofemoral bypass, assuming the presence of an appropriate common iliac artery for inflow to the graft. (60-62) Ipsilateral iliofemoral bypass is a good procedure when anatomically feasible. Kretschmer and colleagues found no difference between femorofemoral bypass and unilateral iliofemoral bypass with respect to patency. (63) Van der Vliet and associates, in a truly remarkable study, compared the results of 184 unilateral iliac reconstructions (62% based on iliac artery inflow) to 350 contemporaneous patients undergoing aorta-to-bilateral iliac or femoral reconstruction over a 10-year period and found no difference in patency between the groups, implying that iliofemoral bypass yields results comparable to the "benchmark" aortofemoral bypass. (64) The abdomen is prepped along with the groins and anterior thighs to allow access to the abdomen in case of unexpected findings during surgery. Longitudinal incisions and less frequent oblique incisions are generally used to expose and control the femoral arteries on both sides. The graft is tunneled from one groin incision to the other within the abdominal wall superior to the pubis. The tunnel is created bluntly with fingers, a large clamp, or a tubular tunneler. The graft tunneled in the prefascial subcutaneous plane or in the preperitoneal position if unfavorable conditions exist in the abdominal wall, such as prior surgery, radiation-damaged skin or other skin changes, an unusually thin subcutaneous fat layer, or obesity. (65) If the inflow provided in by a contralateral iliac artery, these iliac origin crossover grafts are usually most conveniently placed in the preperitoneal

position. (66) Anastomoses are end-to-side anastomoses in nearly all cases. Kinking of the graft should be avoided by taking the graft lower on the common femoral to the origin of the profunda parallel to the artery. A prosthetic graft is now used in nearly all cases.

Exposure for the iliac site of the anastomosis usually done through suprainguinal curved incision which is simple also in the obese patient avoid the groin and the graft is more deeply placed and more cushioned than in the femoro femoral bypass.

It is not surprising that endovascular procedures to improve suboptimal donor iliac arteries might be considered prior to or concomitant with femorofemoral bypass. The results of these studies generally support the view that donor iliac artery balloon angioplasty with stenting in selected cases is associated with a satisfactory hemodynamic outcome and patency rate. (67)

The perioperative mortality associated with femorofemoral bypass is highly dependent on patient selection but should be well under 5% in elective operations. Estimated 3-year survival rates of 71% for patients undergoing femorofemoral bypass, versus 35% for those having axillofemoral bypass. (67, 68) The primary and secondary patency rates for femorofemoral bypass at 3 to 5 years should be about 60% and 70%, respectively. (67, 69) There is a trend toward better patency in claudicants, consistent with observations in virtually every other arterial intervention. (70)

11.5 Axillofemoral bypass

In high risk patient with a combination of aortic and proximal iliac occlusive disease, those with other co-morbidities such as multiple prior abdominal operations, abdominal stomas, or prior radiation therapy, axillofemoral bypass is a valuable alternative for distal revascularization. Axillofemoral bypass is an essential tool for the treatment of many patients with infected aortic or prosthetic arterial grafts or aortoenteric fistulae (53,54)

Axillofemoral bypass is nearly always performed with general anesthesia. Supine position. Either axillary artery can be chosen as a donor unless there is disease in the subclavian or axillary artery. The axillary artery on the side with the higher blood pressure is chosen if there is a 10 mm Hg or greater systolic pressure discrepancy between the arms. (71) A transverse infraclavicular incision is carried through the claviopectoral fascia, exposing the pectoralis major muscle. The pectoralis major muscle fibers are pushed superiorly and inferiorly, exposing the deep fascia and, beneath that, the fat containing the axillary vein, artery, and brachial plexus elements. The axillary artery is exposed from the clavicle medially to the pectoralis minor muscle laterally, often requiring the ligation of crossing veins or small arterial branches. Conventional longitudinal or oblique groin incisions are used for femoral artery exposure. It is very important to place the axillary graft anastomosis as medially as possible to avoid tension on the axillary anastomosis when the arm is abducted. (72) The axillofemoral graft must be tunneled in the midaxillary line to prevent kinking of the graft. The anastomosis of the proximal end of the graft to the side of the axillary artery is generally performed first. The distal anastomosis is conventionally performed end to side to an appropriate artery in the groin. It is important to ensure adequate outflow. (72) It is very important to confirm distal flow using continuous-wave Doppler after the anastomoses are completed and all clamps are removed. It is also essential to ensure adequate blood flow in the donor arm beyond the axillary anastomosis. Patency rates with axillofemoral bypass varies widely between 30% to as high as 85%. (73) The reasons for this variability is due to in part to patient selection, indication and status of the

outflow arteries. Patient with claudication do better than limb salvage patients because of the inherent outflow restriction in the latter group. Patients with a previous distal bypass have better results. 25% of declotted grafts go on to long term patency. (74) Due to co morbidities estimated survival of only 43% at 28 months after axillofemoral bypass. (75) Devolve and coworkers observed an approximately 35% 3-year survival. (76) Patients whose initial presentation was CLI 3-year limb salvage estimates ranging from 69% to slightly more than 80%. (77)

11.6 Axillopopliteal bypass

Occasionally axillofemoral bypass has been extended to the popliteal artery, primarily for cases in which there is groin sepsis and the superficial femoral artery is an unacceptable distal target vessel. Patency was inferior to that expected with more conventional reconstructions. Nevertheless, this technique is occasionally the only reasonable approach to patients with groin sepsis. (78)

11.7 Obturator bypass

Obturator bypass used to avoid frankly contaminated fields during reconstruction after the removal of infected grafts in the groin, but obturator bypass can also be used for reconstruction in patients after the removal of infected ePTFE dialysis access grafts based on the femoral arteries; in patients with infected femoral pseudoaneurysms after diagnostic or therapeutic femoral arterial access or recreational drug use; in those with groin neoplasms requiring en bloc removal of tumor and artery, with a residual soft tissue defect that would expose an in situ reconstruction and in patients who have undergone therapeutic radiation in the groin. (79, 80)

11.8 Thoraco-femoral and supraceliac to iliofemoral bypass

These procedures have most often been applied to patients with failure or infection of previous infrarenal aortic reconstructions, previous abdominal surgery for other than aortic pathology, prior radiation treatment, or other reasons that would make a conventional transperitoneal or retroperitoneal approach to infrarenal aortic surgery difficult or impossible and who are not candidates for endovascular intervention. Passman and colleagues reported a 5-year primary patency rate of 79% in 50 patients. (81)

11.9 Laparoscopic aortic surgery

Laprosopic general surgery shows tremendous advance s, new applications in different fields. However, its role in vascular surgery has yet to be defined. Several authors report aorto iliac surgical reconstruction performed laparoscopic ally or hand assisted. (82) As the technology evolves and intracorporeal anastomotic techniques are refined the rule of aortofemoral bypass will expand and become clear.

11.10 Endovascular treatment

The advent of endovascular surgery has resulted in a dramatic shift in the treatment of patients with aortoiliac occlusive disease. It is likely that even patients with more advanced aortoiliac occlusive disease will be candidates for endovascular therapy by means of stent-

grafts and hybrid open-endovascular approaches. The indication for therapy is similar to the indication of open surgery. Patients with disabling claudication constitute the largest group of patients who undergo aortoiliac endovascular revascularization. Patients with critical limb ischemia (CLI) manifesting as either rest pain or tissue loss frequently have multilevel occlusive disease. In patients with a significant CFA disease burden, combined femoral artery endarterectomy and patch angioplasty with simultaneous aortoiliac stenting or stent-grafting often provides adequate perfusion to treat CLI. Juxta renal aortic occlusion, circumferential heavy calcification, hypoplastic aortic syndrome, and adjacent aneurysmal disease. Renal insufficiency is also a relative contraindication owing to potential contrast-induced nephropathy, although preventive regimens and minimal contrast techniques have reduced the impact of this complication. (1, 83)

Endovascular therapy is the recommended first-line therapy for TASC A and B lesions and increasingly for TASC C lesions as endovascular techniques improve. Good-risk patients with TASC type C disease can also be treated with open surgery, depending on patient preference. Surgery is usually recommended for TASC D lesions, but advanced endovascular approaches are now being applied in these lesions as well, with good results. (1)

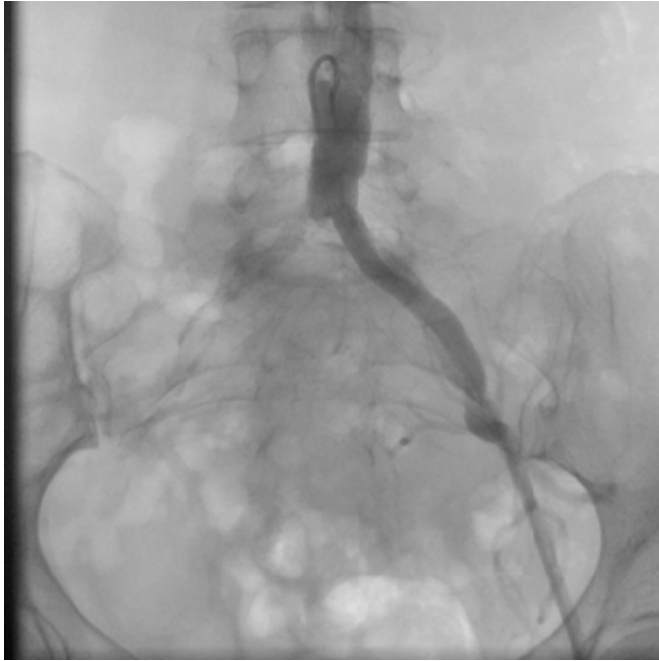High-risk patients with TASC C and D disease, CLI may be treated with endovascular therapy, acknowledging that this approach will be less durable than open surgical options. (84) Once a decision has been made that intervention is indicated, information must be gathered to determine the location and extent of the atherosclerotic occlusive disease. Evaluation of the femoral artery as an access for intervention is crucial. Patients with greater than 50% CFA stenosis on duplex arterial mapping, MRA, or CTA are usually treated with a hybrid approach that entails open femoral endarterectomy, patch angioplasty, and simultaneous stent or stent-graft placement. In patients with less severe CFA disease, a percutaneous approach can be undertaken and ipsilateral retrograde, contralateral, bilateral femoral, or brachial approach can be planned. (85)

Aortic lesions are frequently calcified, exophytic and have a higher risk of rupture and embolization and stent graft may warranted.

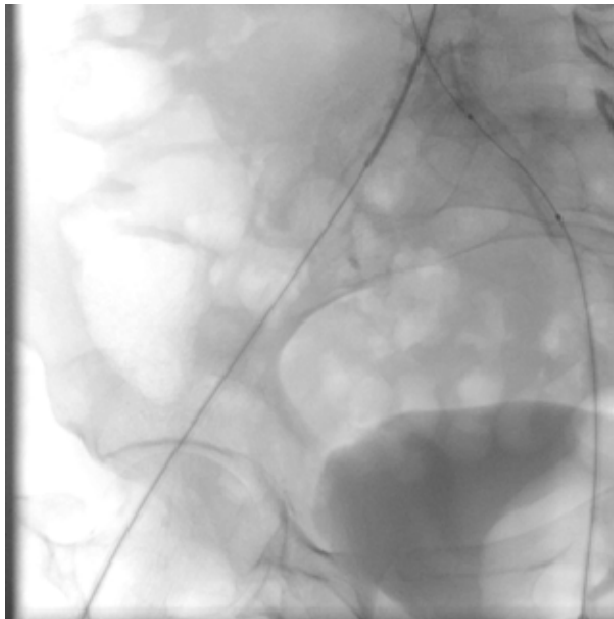
Different techniques are used for the endovascular treatment of aortoiliac occlusive diseases. Common iliac artery (CIA) disease is generally treated through an ipsilateral, retrograde approach. A complete diagnostic angiogram can be performed through a catheter in the contralateral femoral artery before any intervention; this also provides access to protect the contralateral CIA from injury during ipsilateral CIA intervention.

In general, the contralateral oblique projection shows the iliac artery bifurcations, whereas the ipsilateral oblique projection best displays the profunda origins at the femoral artery bifurcations. The infringuinal runoff is visualized before inflow intervention. If the obstruction is distal in the external iliac artery it may be better to approach from the contralateral because it permits more extensive treatment of the external iliac artery (EIA) into the proximal portion of the CFA if needed

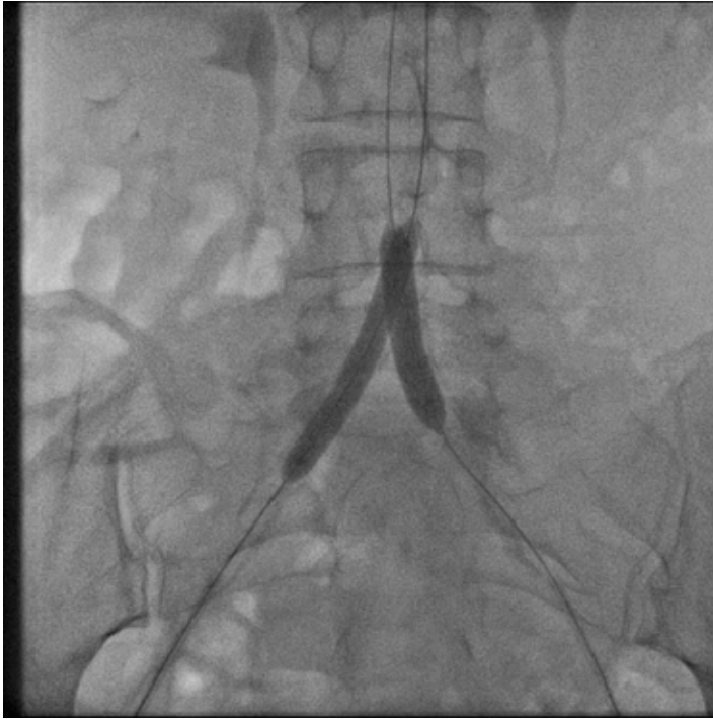An arterial sheath to facilitate catheter exchanges. The lesion is crossed with a floppy-tipped glide wire is used to cross the lesion supported by soft low profile catheter. After advancing the catheter across the lesion, the wire is removed, and free aspiration of blood ensures that the catheter tip is intraluminal. Injection of contrast follows to confirm the position. Pressure measurements across the lesion should be obtained as mentioned in the angiogram technique earlier.



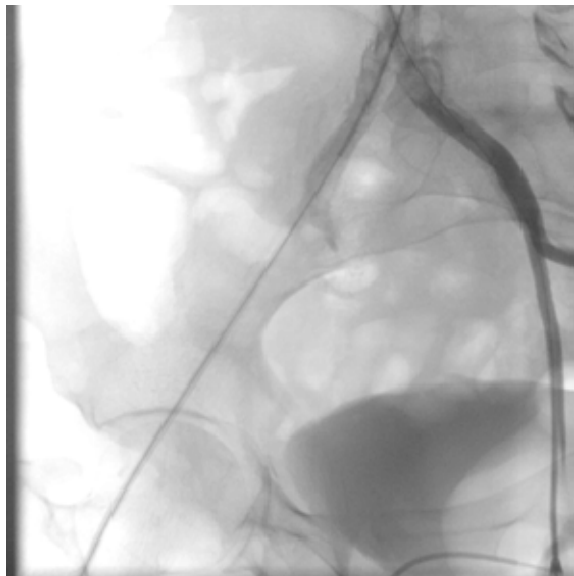
A



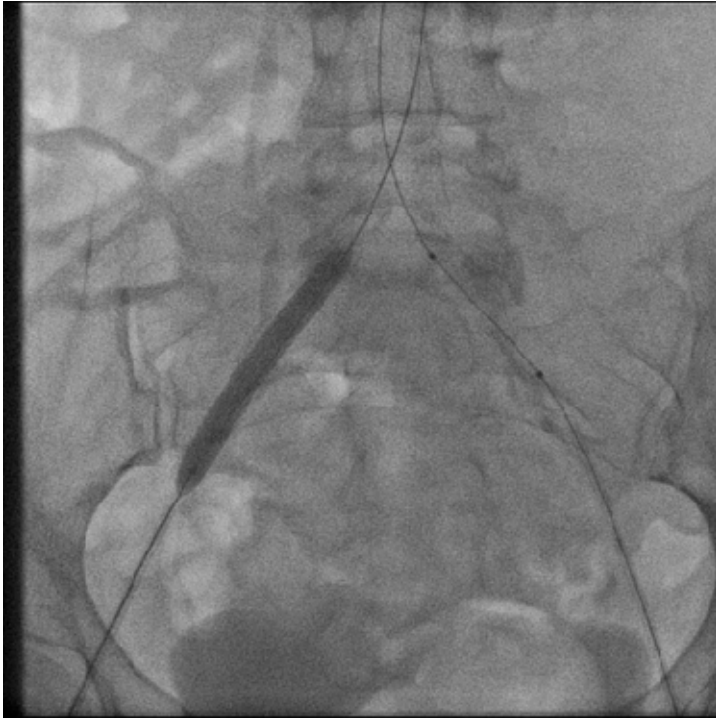B



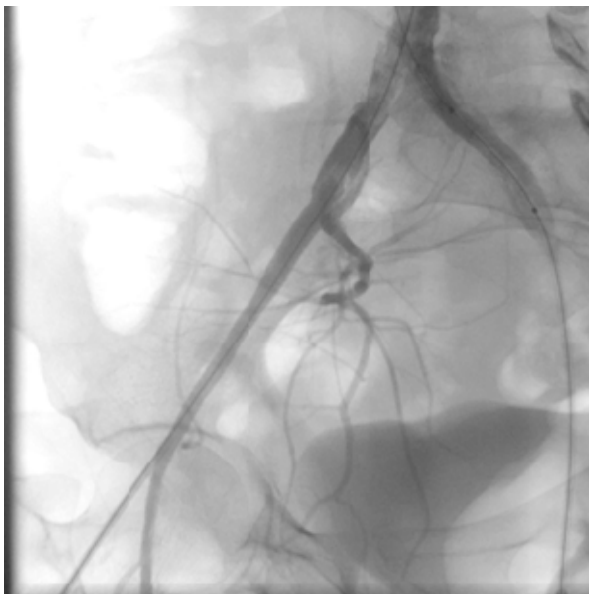
C



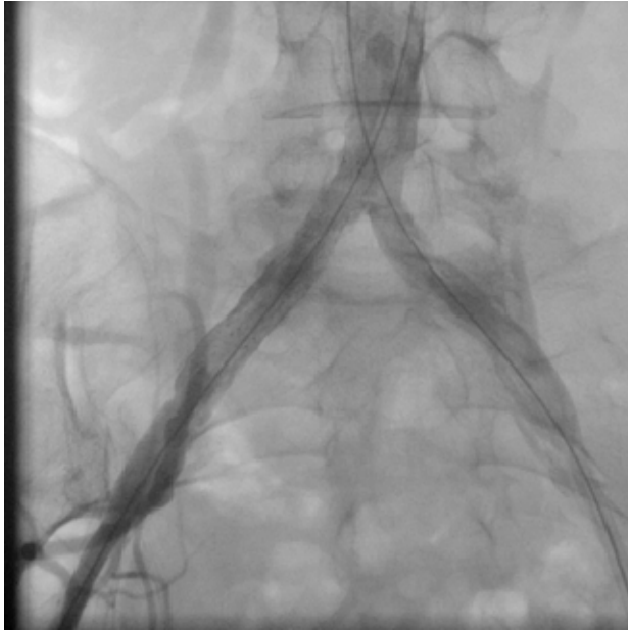
D



E



F



G

Fig. 9.

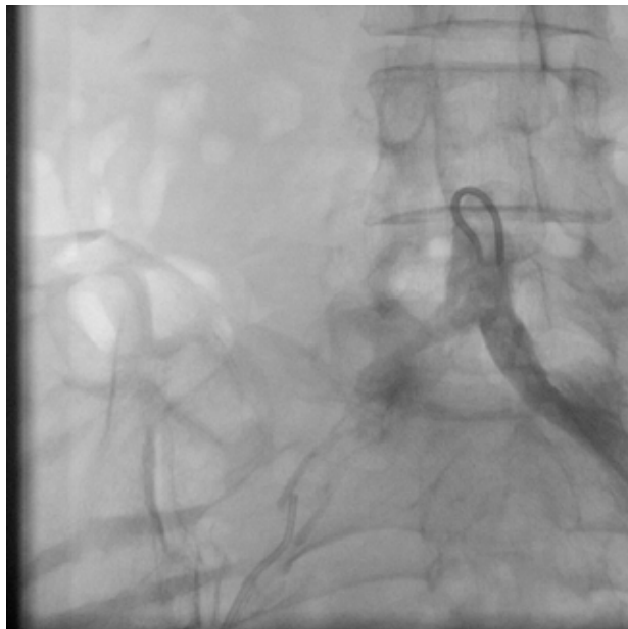


Fig. 10.

During the attempt to recanalize an occluded iliac artery in a retrograde fashion, the guide wire frequently follows a subintimal path. Once this has occurred, it may be difficult to redirect the guide wire into the lumen. Fig 9 (A-G)

An antegrade approach from the contralateral CFA is frequently successful. As soon as the guide wire has crossed the obstructive lesion and lies within the ipsilateral EIA lumen, it is snared from the ipsilateral CFA. The hydrophilic guide wire is then removed, and a working guide wire is inserted to facilitate the intervention. Fig 10

If the CIA occlusion is flush with aorta a contralateral femoral approach to cross the lesion is generally unsuccessful; transbrachial or ipsilateral femoral approaches are more likely to achieve success.

The recent development of reentry catheters has greatly increased the technical success of crossing complete arterial occlusions.

On angioplasty of the common iliac arteries a 'Kissing Balloon' technique which involves simultaneous balloon dilatation at the origins of both CIAs is advocated, even in the presence of a unilateral lesion, to protect the contralateral CIA from dissection, plaque dislodgement, or subsequent embolization.

If significant CFA disease, a 'hybrid technique', open femoral approach with combined endovascular iliac therapy and femoral endarterectomy should be strongly considered

Selection of the appropriate balloon or stent diameter is of utmost importance for a successful intervention. Slight oversizing of 5% to 10% is recommended, except in the case of heavily calcified lesions that may rupture. A calibrated catheter inserted into the vessel allows measurement of the artery. The length of the balloon or stent should cover the diseased area without damaging the normal vessel. The lesion cause a waist on the balloon and the waist disappears after successful dilatation. Mild pain during dilatation is acceptable excessive or persistent pain may indicate arterial rupture. Less than 20% residual stenosis and less than 10 mm Hg pressure gradient consider a technical success. (86) Contrast-induced nephropathy can be decreased by preprocedural volume loading and the use of low-osmolar or iso-osmolar contrast agents. (87)

The reported 4-year success rates for iliac angioplasty are approximately 44% to 65%. (88) In another study kissing iliac stents showed good results in aortic bifurcation disease with primary and secondary patency rates of 78% and 98%, respectively, at 3 years. (89)

Comparing stenting with stand-alone PTA, the Dutch Iliac Stent Trial Study Group performed a randomized comparison of primary balloon-expandable stent placement with primary angioplasty followed by selective stent placement in patients with iliac artery occlusive disease. Iliac patency ranged from 97% at 3 months to 83% at 5 years in the patients with primary stent placement; it ranged from 94% to 74% in the patients treated with PTA and selective stent placement. This difference was not significant. (90)

Other randomized trials have shown primary stenting to be superior to selective stent placement. The 4-year primary patency rate for claudication, with technical failures excluded, was 68% (range, 65% to 74%) after PTA, compared with 77% (range, 72% to 81%) after stenting. The 4-year primary patency rate for critical ischemia, with technical failures excluded, was 55% (range, 48% to 63%) after PTA, versus 67% (range, 55% to 79%) after

stenting. The authors concluded that stent placement reduced the risk of long-term failure by 39% compared with PTA alone. (91)

Meta-analysis of primary iliac artery stent placement in a total of 2058 limbs shows the technical success rate was 97%, the complication rate was 6%, and the 5-year primary and secondary patency rates were 73% and 85%, respectively. (92)

Outcomes of iliac intervention depend on TASC lesion classification. Galaria and associates examined reported 10-year patency results for patients with TASC types A and B lesions. Sixty-two percent of the lesions were TASC type A, and the remainder were type B. Of the 394 primary interventions, 51% included the placement of stents. Technical success (defined as <30% residual stenosis) was achieved in 98% of treated vessels. The procedure-related mortality rate was 1.8% at 30 days and 4.7% at 90 days; the procedure-related complication rate was 7%. A rise in the ABI >0.15) was achieved in 82%. Within 3 months, 84% of patients demonstrated clinical improvement. The cumulative assisted patency rate was 71% ± 7 at 10 years. (93)

Although iliac angioplasty and stenting of TASC types A and B common iliac lesions achieve a patency similar to that of open surgical reconstruction, patients with diffuse aortoiliac occlusive disease (TASC types C and D lesions) have markedly inferior patency with stenting when compared with aortobifemoral bypass.

Recently, several authors have documented more promising results in the treatment of more complex TASC types C and D iliac lesions with 2-year primary patency ranges from 69% to 76%, with secondary patency rates of 85% to 95%. (94, 95)

In a series of 212 patients with chronic iliac occlusions, successful recanalization was accomplished in nearly 90% of patients, with marked clinical improvement in the vast majority. The primary patency at 4 years was 75.7%. (96)

The primary patency at 4 years was 75.7%. Leville and coworkers recently reported late results of the treatment of complex iliac occlusive disease. Three-year primary patency, secondary patency, and limb salvage rates were 76%, 90%, and 97%, respectively. (97)

Extension of disease into the EIA increases procedural complexity and decreases the durability of the intervention. (93)

Rzucidlo and colleagues the use of stent-grafts, (85% TASC types C and D lesions) increased the primary and primary assisted patency at 1 year to 70% and 88%, respectively, compared with patients treated with stents alone, and led to 100% early hemodynamic and clinical success. (98)

12. References

- [1] Norgren L, Hiatt WR, Dormandy JA, et al. Inter-Society Consensus for the Management of the Peripheral Arterial Disease (TASC II). *J Vasc Surg* 2007, 45(SupplS) S5-S67.
- [2] Starrett RW, Stoney RJ: Juxtarenal Aortic occlusion. *Surgery* 76:890, 1974.
- [3] Reilly LM, Sauer I, L, Weinstein ES, et al; Infra renal aortic occlusion. Does it threaten renal perfusion or function? *J Vasc Surg* 11:216, 1990.

- [4] Debakey ME, Lawrie GM, Glaeser DH: Patterns of atherosclerosis and their surgical significance. *Ann Surg* 201;1115-131, 1985.
- [5] Brewster DC. Clinical and anatomical consideration for surgery in aortoiliac disease and result of surgical treatment. *Circulation* 83, (2 suppl) I42-I52, 1991.
- [6] Darling RC, Brewster DC, Hallett Jr JW, et al: Aortoiliac reconstruction. *Surg Clin North Am* 1979; 59:565.
- [7] Malone JM, Moore WS, Goldstone J: Life expectancy following aortofemoral arterial grafting. *Surgery* 1977; 81:551.
- [8] Brewster DC, Perler BA, Robison JG, et al: Aortofemoral graft for multilevel occlusive disease: predictors of success and need for distal bypass. *Arch Surg* 1982; 117:1593.
- [9] Krug RT, Calligaro KD, Dougherty MJ: Claudication in the young patient. *Perspect Vasc Surg* 2000; 13:27.
- [10] Flanigan DP, Schuler JJ, Keifer T, et al: Elimination of iatrogenic impotence and improvement of sexual dysfunction after aortoiliac revascularization. *Arch Surg* 1982; 117:544.
- [11] Leriche R, Morel A: The syndrome of thrombotic obliteration of the aortic bifurcation. *Ann Surg* 1948; 127:193.
- [12] Berman JR, Berman LA, Goldstein I: Female sexual dysfunction: incidence, pathophysiology, evaluation and treatment options. *Urology* 1999; 54:385.
- [13] Hirsch AT, Haskal ZJ, Hertzler NR, et al: ACC/AHA 2005 Practice Guidelines for the management of patients with peripheral arterial disease. *J Am Coll Cardiol* 2006; 47:1239.
- [14] Cournot M, Boccalon H, Cambou JP, et al: Accuracy of the screening physical examination to identify subclinical atherosclerosis and peripheral arterial disease in asymptomatic subjects. *J Vasc Surg* 2007; 46:1215-1221.
- [15] Gahtan V: The noninvasive laboratory. *Surg Clin North Am* 1998; 78:507-518.
- [16] *Evaluation of claudication. Vascular Diagnosis*, Philadelphia: Elsevier, Inc.; 2004.
- [17] Platt JF: Doppler ultrasound of the kidney. *Semin Ultrasound CT MR* 1997; 18:22.
- [18] Soares GM, Murphy TP, Singha MS, et al: Renal artery duplex ultrasonography as a screening and surveillance tool to detect renal artery stenosis: a comparison with current reference standard imaging. *J Ultrasound Med* 2006; 25:293.
- [19] Heijenbrok-Kal MH, Kock MC, Hunink MG: Lower extremity arterial disease: multidetector CT angiography – meta-analysis. *Radiology* 2007; 245:433-439.
- [20] Ota H, Takase K, Igarashi K, et al: MDCT compared with digital subtraction angiography for assessment of lower extremity arterial occlusive disease: importance of reviewing cross-sectional images. *Am J Roentgenol* 2004; 182:201-209.
- [21] Ouwendijk R, Kock MC, van Dijk LC, et al: Vessel wall calcifications at multi-detector row CT angiography in patients with peripheral arterial disease: effect on clinical utility and clinical predictors. *Radiology* 2006; 241:603-608.
- [22] Kreitner KF, Kalden P, Neufang A, et al: Diabetes and peripheral arterial occlusive disease: prospective comparison of contrast-enhanced three-dimensional MR angiography with conventional digital subtraction angiography. *Am J Radiol* 2000; 174:171-179.
- [23] Sam AD, Morasch MD, Collins J, et al: Safety of gadolinium contrast angiography in patients with chronic renal insufficiency. *J Vasc Surg* 2003; 38:313-318.

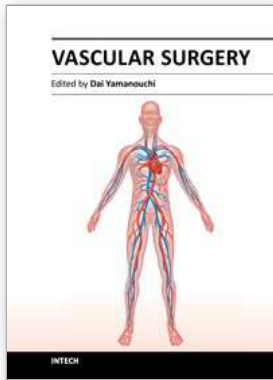
- [24] Othersen JB, Maize JC, Woolson RF, Budisavljevic MN: Nephrogenic systemic fibrosis after exposure to gadolinium in patients with renal failure. *Nephrol Dial Transplant* 2007; 22:3179-3185.
- [25] Bostrom AA, Karacagil S, Hellberg A, et al: Surgical reconstruction without preoperative angiography in patients with aortoiliac occlusive disease. *Ann Vasc Surg* 2002; 16:273.
- [26] Bettmann MA, Heeren T, Greenfield A, et al: SCVIR contrast agent registry report. *Radiology* 1997; 203:611-620.
- [27] Armstrong P, Han D, Baxter J, et al: Complication rates of percutaneous brachial artery access in peripheral vascular angiography. *Ann Vasc Surg* 2003; 17:107.
- [28] Udoff EJ, Barth KH, Harrington DP, et al: Hemodynamic significance of iliac artery stenosis: pressure measurements during angiography. *Radiology* 1979; 132:289.
- [29] Waugh JR, Sacharias N: Arteriographic complications in the DSA era. *Radiology* 1992; 182:243-246.
- [30] Back MR, Caridi JG, Hawkins IF, Seeger JM: Angiography with carbon dioxide (CO₂). *Surg Clin North Am* 1998; 78:575-591.
- [31] O'Riordan DS, O'Donnell JA: Realistic expectations for the patient with intermittent claudication. *Br J Surg* 1991; 78:861-863.
- [32] Muluk SC, Muluk VS, Kelley ME, et al: Outcome events in patients with claudication: a 15 year study in 2777 patients. *J Vasc Surg* 2001; 33:251-257.
- [33] Hirsch AT, Haskal ZJ, Hertzner NR, et al: ACC/AHA guidelines for the management of patients with peripheral arterial disease: summary of recommendations, sc Interv Radiol 17(9):1383-1397, 2006.
- [34] Creager MA, Jones DW, Easton JD: Atherosclerotic Vascular Disease Conference: Writing Group V: Medical decision making and therapy. *Circulation* 2004; 109:2634-2642.
- [35] Tonstad S, Farsang C, Klaene G, et al: Bupropion SR for smoking cessation in smokers with cardiovascular disease: a multicentre, randomised study. *Eur Heart J* 2003; 24:946-955.
- [36] Upchurch GR, Dimick JB, Wainess RM, et al: Diffusion of new technology in health care: the case of aorto-iliac occlusive disease. *Surgery* 2004; 136:812.
- [37] Hertzner NR, Bena JF, Karafa MT: A personal experience with direct reconstruction and extra-anatomic bypass for aortobifemoral occlusive disease. *J Vasc Surg* 2007; 45:527.
- [38] Chang RW, Goodney PP, Baek JH, et al: Long-term results of combined common femoral endarterectomy and iliac stenting/stent grafting for occlusive disease. *J Vasc Surg* 2008; Jun: epub
- [39] Stevens RD, Burri H, Tramer MR: Pharmacologic myocardial protection in patients undergoing noncardiac surgery: a quantitative systematic review. *Anesth Analg* 2003; 97:623.
- [40] Hoeks SE, Scholte Op Reimer WJ, van Urk H, et al: Increase of 1-year mortality after perioperative beta-blocker withdrawal in endovascular and vascular surgery patients. *Eur J Vasc Endovasc Surg* 2007; 33:13.
- [41] Bush Jr HL, Hydo LJ, Fischer E, et al: Hypothermia during elective abdominal aortic aneurysm repair: the high price of avoidable morbidity. *J Vasc Surg* 1995; 21:392.

- [42] Juleff RS, Brown OW, McKain MM, et al: The influence of competitive flow on graft patency. *J Cardiovasc Surg* 1992; 33:415.
- [43] Pierce GE, Turrentine M, Stringfield S, et al: Evaluation of end-to-side v end-to-end proximal anastomosis in aortobifemoral bypass. *Arch Surg* 1982; 117:1580.
- [44] Gloviczki P, Cross SA, Stanson AW, et al: Ischemic injury to the spinal cord or lumbosacral plexus after aorto-iliac reconstruction. *Am J Surg* 1991; 162:131.
- [45] Brewster DC, Perler BA, Robison JG, et al: Aortofemoral graft for multilevel occlusive disease: predictors of success and need for distal bypass. *Arch Surg* 1982; 117:1593.
- [46] Martinez BD, Hertzner NR, Beven EG: Influence of distal arterial occlusive disease on prognosis following aortobifemoral bypass. *Surgery* 1980; 88:795.
- [47] Ballard JL, Bergan JJ, Singh P, et al: Aortoiliac stent deployment versus surgical reconstruction: analysis of outcome and cost. *J Vasc Surg* 1998; 28:94.
- [48] Faries PL, LoGerfo FW, Hook SC, et al: The impact of diabetes on arterial reconstructions for multilevel arterial occlusive disease. *Am J Surg* 2001; 181:251.
- [49] Reed AB, Conte MS, Donaldson MC, et al: The impact of patient age and aortic size on the results of aortobifemoral bypass grafting. *J Vasc Surg* 2003; 37:1219.
- [50] Steele SR: Ischemic colitis complicating major vascular surgery. *Surg Clin North Am* 2007; 87:1099.
- [51] Gloviczki P, Cross SA, Stanson AW, et al: Ischemic injury to the spinal cord or lumbosacral plexus after aorto-iliac reconstruction. *Am J Surg* 1991; 162:131.
- [52] Nevelsteen A, Suy R: Graft occlusion following aortofemoral Dacron bypass. *Ann Vasc Surg* 1991; 5:32.
- [53] O'Connor S, Andrew P, Batt M, Becquemin JP: A systematic review and meta-analysis of treatments for aortic graft infection. *J Vasc Surg* 2006; 44:38-45.
- [54] Armstrong PA, Back MR, Wilson JS, et al: Improved outcomes in the recent management of secondary aortoenteric fistula. *J Vasc Surg* 2005; 42:660.
- [55] Hagino RT, Taylor SM, Fuitani RM, et al: Proximal anastomotic failure following infrarenal aortic reconstruction: late development of true aneurysms, pseudoaneurysms, and occlusive disease. *Ann Vasc Surg* 1993; 7:8.
- [56] Connolly JE, Price T: Aortoiliac endarterectomy: a lost art?. *Ann Vasc Surg* 2006; 20:56.
- [57] Van der Akker PJ, van Schilfaarde R: Long-term results of prosthetic and non-prosthetic reconstruction for obstructive aorto-iliac disease. *Eur J Vasc Surg* 1992; 6:53.
- [58] Sumner DS, Strandness Jr DE: The hemodynamics of the femorofemoral shunt. *Surg Gynecol Obstet* 1972; 134:629-636.
- [59] Nicholson ML, Beard JD, Horrocks M: Intra-operative inflow resistance measurement: a predictor of steal syndromes following femoro-femoral bypass grafting. *Br J Surg* 1988; 75:1064-1066.
- [60] Couch NP, Clowes AW, Whittemore AD, et al: The iliac-origin arterial graft: a useful alternative for iliac occlusive disease. *Surgery* 1985; 97:83-87.
- [61] Sidawy AN, Menzoian JO, Cantelmo NL, LoGerfo FW: Retroperitoneal inflow procedures for iliac occlusive vascular disease. *Arch Surg* 1985; 120:794-796.

- [62] Ricco J-B, Probst H: Long-term results of a multicenter randomized study on direct versus crossover bypass for unilateral iliac artery occlusive disease. *J Vasc Surg* 2008; 47:45-54.
- [63] Kretschmer G, Niederle B, Schemper M, Polterauer P: Extra-anatomic femoro-femoral crossover bypass (FF) vs. unilateral orthotopic ilio-femoral bypass (IF): an attempt to compare results based on data matching. *Eur J Vasc Surg* 1991; 5:75-82.
- [64] Van der Vliet JA, Scharn DM, de Waard J-WD, et al: Unilateral vascular reconstruction for iliac obstructive disease. *J Vasc Surg* 1994; 19:610-614.
- [65] Tyson RR, Reichle FA: Retropubic femorofemoral bypass: a new route through the space of Retzius. *Surgery* 1972; 72:401-403.
- [66] Mosley JG, Marston A: Long term results of 66 femoral-to-femoral by-pass grafts: a 9-year follow-up. *Br J Surg* 1983; 70:631-634.
- [67] Schneider JR, Besso SR, Walsh DB, et al: Femorofemoral versus aortobifemoral bypass: outcome and hemodynamic results. *J Vasc Surg* 1994; 19:43-57.
- [68] Schneider JR, McDaniel MD, Walsh DB, et al: Axillofemoral bypass: outcome and hemodynamic results in high-risk patients. *J Vasc Surg* 1992; 15:952-963.
- [69] Brener BJ, Brief DK, Alpert J, et al: Femorofemoral bypass: a twenty-five year experience. In: Yao JST, Pearce WH, ed. *Long-term Results in Vascular Surgery*, East Norwalk: Appleton & Lange; 1993:385-393.
- [70] Pursell R, Sideso E, Magee TR, Galland RB: Critical appraisal of femorofemoral crossover grafts. *Br J Surg* 2005; 92:565-569.
- [71] Calligaro KD, Ascer E, Veith FJ, et al: Unsuspected inflow disease in candidates for axillofemoral bypass operations: a prospective study. *J Vasc Surg* 1990; 11:832-837.
- [72] Sullivan LP, Davidson PG, D'Anna Jr JA, Sithian N: Disruption of the proximal anastomosis of axillobifemoral grafts: two case reports. *J Vasc Surg* 1989; 10:190-192.
- [73] LoGerfo FW, Johnson WC, Corson JD, et al: A comparison of the late patency rates of axillobilateral femoral and axillobifemoral grafts. *Surgery* 1977; 81:33-40.
- [74] Harris Jr EJ, Taylor Jr LM, McConnell DB, et al: Clinical results of axillobifemoral bypass using externally supported polytetrafluoroethylene. *J Vasc Surg* 1990; 12:416-421.
- [75] Bliss BP, Barrett GS: Axillo-femoral and axillo-profunda bypass grafts. Their use for limb salvage in the bad-risk patient with occlusion or infection of the abdominal aorta and iliac arteries. *Ann R Coll Surg Engl* 1972; 50:268-273.
- [76] Devolve C, Adeleine P, Violet F, Descotes J: La revascularisation des membres inférieurs à partir de l'artère axillaire est-elle fiable? Analyse informatique de 98 pontages. *Lyon Chir* 1981; 77:88-93.
- [77] Naylor AR, Ah-See AK, Engeset J: Axillofemoral bypass as a limb salvage procedure in high risk patients with aortoiliac disease. *Br J Surg* 1990; 77:659-661.
- [78] Keller MP, Hoch JR, Harding AD, et al: Axillopopliteal bypass for limb salvage. *J Vasc Surg* 1992; 15:817-822.
- [79] Tilson MD, Sweeney T, Gusberg RJ, Stansel HC: Obturator canal bypass grafts for septic lesions of the femoral artery. *Arch Surg* 1979; 114:1031-1033.

- [80] Mentha C, Launois B, Delaere J: Les pontages artériels ilio-fémoraux par le trou obturateur [Ilio-femoral arterial bridging by the obturator foramen]. *J Chir (Paris)* 1965; 90:131-140.
- [81] Passman MA, Farber MA, Criado E, et al: Descending thoracic aorta to iliofemoral artery bypass grafting: a role for primary revascularization for aortoiliac occlusive disease?. *J Vasc Surg* 1999; 29:249-258.
- [82] Said S, Mall J, Peter F, et al: Laparoscopic aorto-femoral bypass grafting: human cadaveric and initial clinical experiences. *J Vasc Surg* 1999; 29:639-648.
- [83] Briguori C, Airolidi F, D'Andrea D, et al: Renal Insufficiency Following Contrast Media Administration Trial (REMEDIAL): a randomized comparison of 3 preventive strategies. *Circulation* 2007; 115:1211-1217.
- [84] Leville CD, Kashyap VS, Clair DG, et al: Endovascular management of iliac artery occlusions: extending treatment to TransAtlantic Inter-Society Consensus class C and D patients. *J Vasc Surg* 2006; 43:32-39.
- [85] Rzcuidlo EM, Powell RJ, Zwolak RM, et al: Early results of stent-grafting to treat diffuse aortoiliac occlusive disease. *J Vasc Surg* 2003; 37:1175-1180.
- [86] Haulon S, Mounier-Vehier C, Gaxotte V, et al: Percutaneous reconstruction of the aortoiliac bifurcation with the "kissing stents" technique: long-term follow-up in 106 patients. *J Endovasc Ther* 2002; 9:363-368.
- [87] Aspelin P, Aubry P, Fransson SG, et al: Nephrotoxic effects in high-risk patients undergoing angiography. *N Engl J Med* 2003; 348:491-499
- [88] Parsons RE, Suggs WD, Lee JJ, et al: Percutaneous transluminal angioplasty for the treatment of limb threatening ischemia: do the results justify an attempt before bypassgrafting?. *J Vasc Surg* 1998; 28:1066-1071.
- [89] Haulon S, Mounier-Vehier C, Gaxotte V, et al: Percutaneous reconstruction of the aortoiliac bifurcation with the "kissing stents" technique: long-term follow-up in 106 patients. *J Endovasc Ther* 2002; 9:363-368.
- [90] Tetteroo E, van der Graaf Y, Bosch JL, et al: Randomised comparison of primary stent placement versus primary angioplasty followed by selective stent placement in patients with iliac-artery occlusive disease. Dutch Iliac Stent Trial Study Group. *Lancet* 1998; 351:1153-1159.
- [91] Bosch JL, Hunink MG: Meta-analysis of the results of percutaneous transluminal angioplasty and stent placement for aortoiliac occlusive disease. *Radiology* 1997; 204:87-96.
- [92] Murphy TP: The role of stents in aorto-iliac occlusive disease. New York, Thieme, 1998.
- [93] Galateria II, Davies MG: Percutaneous transluminal revascularization for iliac occlusive disease: long-term outcomes in TransAtlantic Inter-Society Consensus A and B lesions. *Ann Vasc Surg* 2005; 19:352-360.
- [94] Carnevale FC, De Blas M, Merino S, et al: Percutaneous endovascular treatment of chronic iliac artery occlusion. *Cardiovasc Intervent Radiol* 2004; 27:447-452.
- [95] Uher P, Nyman U, Lindh M, et al: Long-term results of stenting for chronic iliac artery occlusion. *J Endovasc Ther* 2002; 9:67-75.
- [96] Scheinert D, Schroder M, Ludwig J, et al: Stent-supported recanalization of chronic iliac artery occlusions. *Am J Med* 2001; 110:708-715.

-
- [97] Leville CD, Kashyap VS, Clair DG, et al: Endovascular management of iliac artery occlusions: extending treatment to TransAtlantic Inter-Society Consensus class C and D patients. *J Vasc Surg* 2006; 43:32-39.
- [98] Rzucidlo EM, Powell RJ, Zwolak RM, et al: Early results of stent-grafting to treat diffuse aortoiliac occlusive disease. *J Vasc Surg* 2003; 37:1175-1180.



Vascular Surgery

Edited by Dr. Dai Yamanouchi

ISBN 978-953-51-0328-8

Hard cover, 262 pages

Publisher InTech

Published online 04, April, 2012

Published in print edition April, 2012

This book aims to provide a brief overview of conventional open vascular surgery, endovascular surgery and pre- and post-operative management of vascular patients. The collections of contributions from outstanding vascular surgeons and scientists from around the world present detailed and precious information about the important topics of the current vascular surgery practice and research. I hope this book will be used worldwide by young vascular surgeons and medical students enhancing their knowledge and stimulating the advancement of this field.

How to reference

In order to correctly reference this scholarly work, feel free to copy and paste the following:

Tarek Al-Shafie and Paritosh Suman (2012). Aortoiliac Occlusive Disease, Vascular Surgery, Dr. Dai Yamanouchi (Ed.), ISBN: 978-953-51-0328-8, InTech, Available from:
<http://www.intechopen.com/books/vascular-surgery/aortoiliac-occlusive-disease>

INTECH

open science | open minds

InTech Europe

University Campus STeP Ri
Slavka Krautzeka 83/A
51000 Rijeka, Croatia
Phone: +385 (51) 770 447
Fax: +385 (51) 686 166
www.intechopen.com

InTech China

Unit 405, Office Block, Hotel Equatorial Shanghai
No.65, Yan An Road (West), Shanghai, 200040, China
中国上海市延安西路65号上海国际贵都大饭店办公楼405单元
Phone: +86-21-62489820
Fax: +86-21-62489821

© 2012 The Author(s). Licensee IntechOpen. This is an open access article distributed under the terms of the [Creative Commons Attribution 3.0 License](#), which permits unrestricted use, distribution, and reproduction in any medium, provided the original work is properly cited.