

# Coronary Flow: From Pathophysiology to Clinical Noninvasive Evaluation

Francesco Bartolomucci<sup>1</sup>, Francesco Cipriani<sup>1</sup> and Giovanni Deluca<sup>2</sup>

<sup>1</sup>U.O.C. - Cardiologia - UTIC, Ospedale "L. Bonomo", Andria (BT)

<sup>2</sup>U.O.C. di Cardiologia, Ospedale Civile Bisceglie (BT)  
Italy

## 1. Introduction

Coronary artery disease is the leading cause of mortality in western countries. Myocardial contraction is indeed closely connected to coronary flow and oxygen delivery; the balance between oxygen supply and demand is a crucial determinant of the normal function of the heart. Acute impairment of this relationship due to coronary blood flow reduction results in a vicious cycle, where ischemia-induced contractile dysfunction causes hypotension and further myocardial ischemia.

The presence of an atheromatous plaque modifies the normal pressure profile of the epicardial coronary vessels, obstructing its lumen and stimulating the circulation counter-measures to face it properly. An accurate knowledge of the coronary flow is essential to fully understand the nature and pathophysiological bases of many disorders. Systolic and diastolic variations in coronary blood flow are markers of myocardial oxygen demand due to the various flow control systems, such as mechanic, anatomic, hemodynamic. Microcirculation disorders affect the coronary flow controls too. The availability of high effective therapies able to prevent major cardiac events raised great interest in early diagnosis and widened the indications of Doppler Echocardiography in the evaluation of the ischemic cardiomyopathy.

## 2. CFR: the invasive assessment

The Coronary Flow Reserve (CFR) assessment via Trans-Thoracic Echo-color Doppler is nowadays a reality in clinical practice: it is a reliable, cheap, non-invasive and easy to perform test to assess the coronary flow at rest and after the administration of drugs. Other techniques, such as thermodilution, Magnetic Resonance (MR), Positron Emission Tomography (PET) and intracoronary Doppler Flow Wire have limited indications, because they are time and money consuming and, of course, because they are invasive techniques<sup>1</sup>.

PET is considered the *gold standard* among all invasive methods to estimate the CFR<sup>2</sup>. Newer techniques recently introduced in clinical practice are Thermodilution, Fractional Flow Reserve and Doppler Flow Wire.

Thermodilution is an indicator-dilution method of measuring blood flow. This method is based on the premise that when an indicator substance is added to circulating blood, the

rate of blood flow is inversely proportional to the change in concentration of the indicator over time. CFR assessment with the thermodilution method requires a pressure wire introduced into a coronary vessel for at least 5-7 in. using a guiding catheter during a coronary catheterization. 70 I.U. of heparin intravenously and 100-200 mg of intracoronary nitroglycerin have to be given before starting the procedure, to reduce vasoconstriction. The pressure sensor is located 1 in. far from the wire soft tip, being the distal sensor, while the proximal one is the wire shaft. A software program calculates all the gathered data to provide information about the *mean transit time* of a determined quantity of saline solution injected at ambient temperature. The baseline value is the mean of 3 consecutive injections of 3 ml of saline solution; the operator must repeat this procedure immediately after the administration of a pharmacological stressor, obtaining the *hyperemic mean transit time*. Hyperemic peak value is inducible with the intracoronary administration of papaverine (12 mg for the right coronary artery; 20 mg for the left coronary artery) or using a continuous administration of adenosine (140 mg/Kg/min). Being the vessel volume invariable, the mean transit time is inversely proportional to the flow: the mean hyperemic on the mean baseline time ratio provides the CFR estimation. This is a fast and cheap assessment, which can be performed with the simultaneous Fractional Flow Reserve (FFR) estimation using the Doppler technique without any additional hardware<sup>3</sup>. Its limits are in being invasive, in the mismatch with the CFR Doppler Flow Wire values (the variability range is 20%) and the usual over estimated values in distal coronary vessels.

The FFR (**FIG 1**) is a technique used in coronary catheterization, allowing the pressure and the flow measurement in a defined coronary artery. Measuring the pressure differences across a stenosis means understanding if that stenosis impedes the oxygen delivery to the heart muscle. The FFR itself is the ratio between maximum post-stenotic flow and maximum pre-stenotic flow. The assessment is performed after coronary catheterization and during maximal blood flow, using a pressure flow wire pulled back as the pressures are detected by the sensors on it. The CFR values obtained are well related with PET data<sup>4</sup>. The obtained values are considered normal if above 0.80 (**FIG 2**). The combined use of FFR and thermodilution give answers on the state of myocardial microcirculation in patients with diffuse vessel injuries<sup>5</sup>.

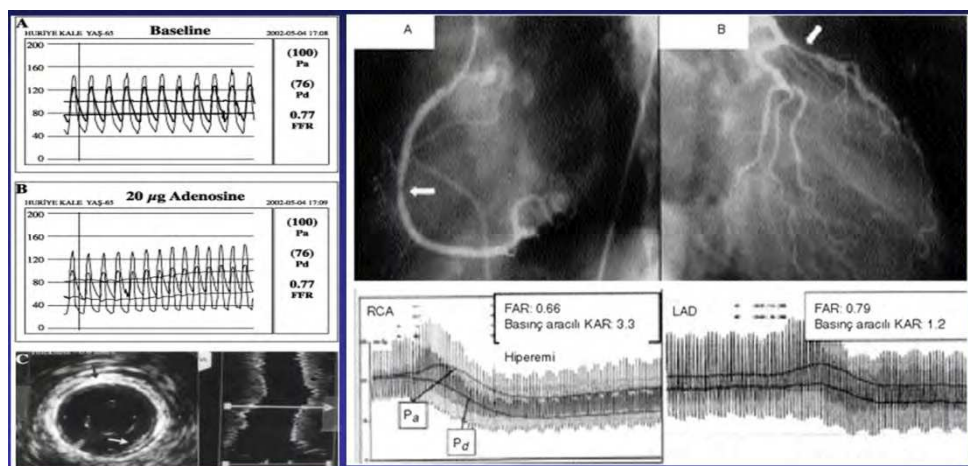


Fig. 1.

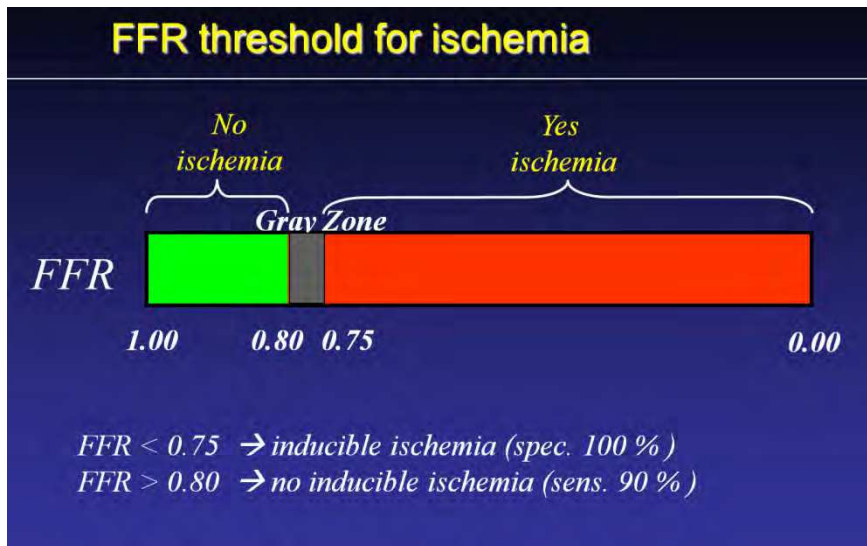


Fig. 2.

The Doppler Flow Wire (**FIG 3**) allows an invasive measurement of CFR and coronary flow speed at rest and during maximal blood flow. The Flow Wire is a floppy and flexible tipped wire, whose top carries a Doppler transducer to assess peak and mean flow speed within the vessels. Flow and flow speed are directly proportional, so it is possible to obtain a CFR estimation using the flow ratio. Doppler Flow Wire (DFW) and CFR are well related with other, already diffused techniques<sup>6</sup>.

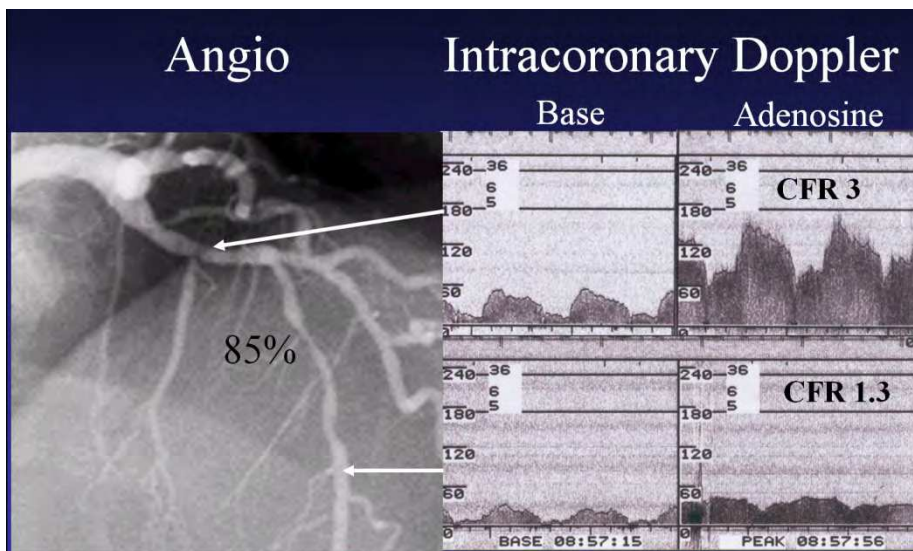


Fig. 3.

### 3. Echocardiography and CFR: from trans-esophageal to trans-thoracic approach

Non invasive techniques are attractive methods to quantify pathophysiology.

The assessment of coronary flow reserve with trans-thoracic doppler echocardiography (**FIG 4**), measured as the ratio between hyperaemic and baseline coronary flow velocities, is a new tool for coronary artery disease and coronary microcirculation evaluation.

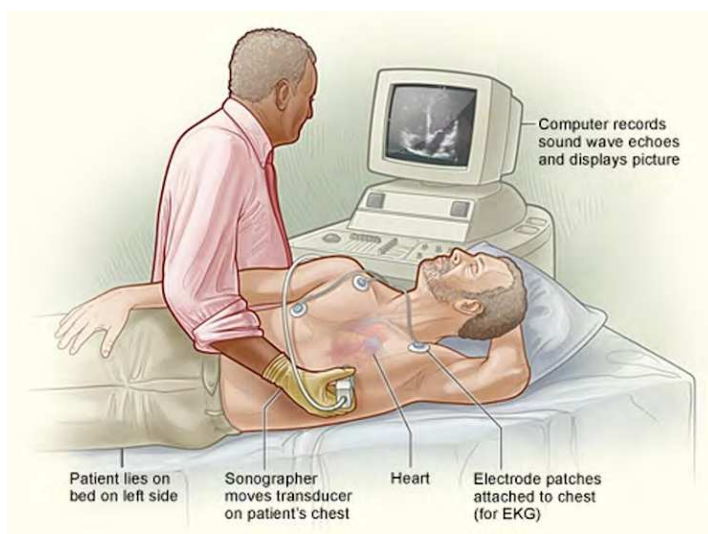


Fig. 4.

For the proximity of the heart to the thoracic wall and the wide spaces between the ribs, echocardiography always provided lots of useful information about cardiac morphology and functionality. The Trans-Esophageal Echocardiography (TEE) uses an even closer point of view on the heart (**FIG 5**) and then it expanded the diagnostic capabilities of echocardiography. This happened thanks to multi-planar, high frequency (7 MHz) transducers, capable of color Doppler and Pulsed Wave Doppler visualization of the coronary flow. The superior resolution and the lack of anatomical obstacles are the best advantages of this technique<sup>7</sup>: TEE allows the visualization of the ascending aorta and the first segments of the coronary arteries. There are Authors who documented the stenosis of the proximal part of the common trunk using TEE<sup>8</sup>. Anterior descending artery is almost parallel to the ultrasound beam, thus being ideal for a Doppler assessment: resting flow speeds are normal before to a stenosis, faster within the stenosis and significantly slower after it<sup>7</sup>. The most important information are provided by the TEE-CFR assessment with the intravenous administration of adenosine or dipyridamole<sup>9</sup>. This kind of evaluation is very easy to perform and its prognostic value, concerning the proximal segment of the anterior descending artery, is very high<sup>10</sup>, allowing the common trunk cross-sectional area and the coronary flow measurement<sup>11</sup> (**FIG 6**). The clinical usefulness of TEE-CFR is limited by an important factor: the difficulty, for the patient, to undergo such an invasive assessment. The evaluation of CFR in cases of distal coronary stenoses still remains impossible and this is another important limitation.

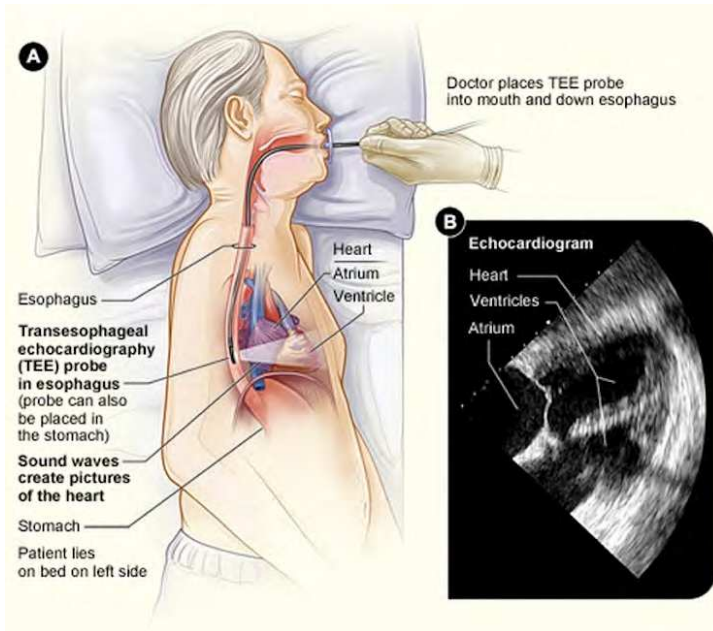


Fig. 5.

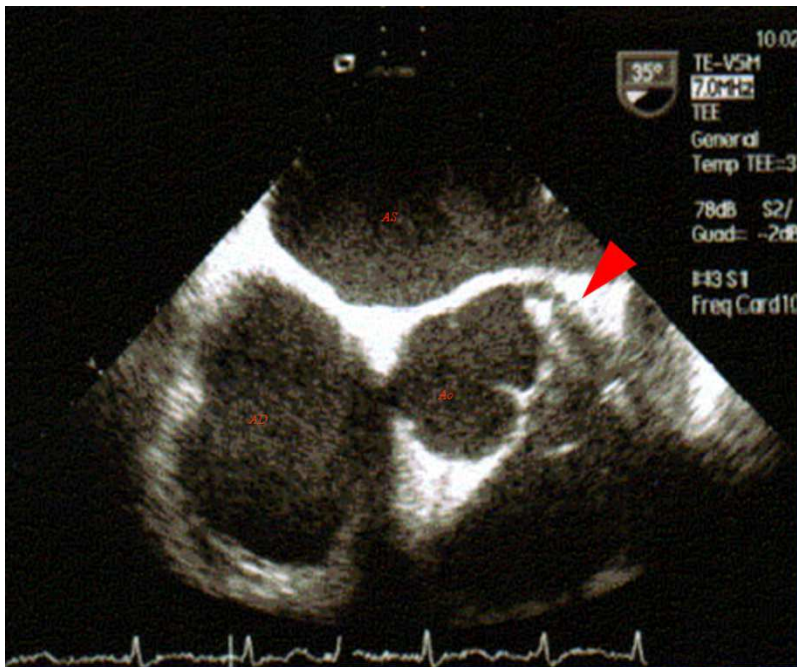


Fig. 6.



Trans Thoracic Echocardiography (TTE), especially after the introduction of Tissue Harmonic Imaging (THI), made possible the evaluation of the coronary flow via pulsed-wave Doppler, color Doppler guided<sup>12</sup>. Anterior descending artery, in its intermediate and terminal parts is ideal for this kind of assessment: it is very close to the thoracic wall, while the circumflex branch of left coronary and posterior descending artery are less reachable by the ultrasonic beam (**FIG 7**). The frames are acquired through an apical 2-chambers modified echocardiographic view, using the color-Doppler guidance to optimize the targeting of the vessel with the probe. The Doppler signal itself can be enhanced, if necessary, giving a contrast agent (e.g.: SonoVue, Levovist). In this specific projection a cranial tilting of the probe is requested: at first the operator must target the anterior interventricular groove, looking for the anterior descending artery, with the color-Doppler function active. Then, rotating the transducer counterclockwise and tilting it cranial, the requested point of view should be reached. All this procedure is ECG-gated (**FIG 8**), being the images much sharper during the diastole; moreover, it is noticeable that the coronary blood flow is continuous and its diastolic part is wider than the systolic. The diastolic coronary flow speeds usually span the range 15 to 30 cm/sec. It's crucial to identify the internal mammary artery, which, for its close proximity to the anterior descending one, can be a confounding factor for the assessment: this is easily possible because for that artery there are no heartbeat movements and the systolic part of the flow is wider than the diastolic (**FIG 9**). TTE-CFR assessment is made possible by a main factor: the easy sampling of anterior descending artery, both in resting and hyperemic conditions (**FIG 10**). Each cardiac ultrasound unit is equipped with the right hardware to perform this kind of analysis, however, the operators must take care of some parameters: using low color Doppler rates (PRF 11-25 cm/sec); keeping a constant Doppler angle between the probe and

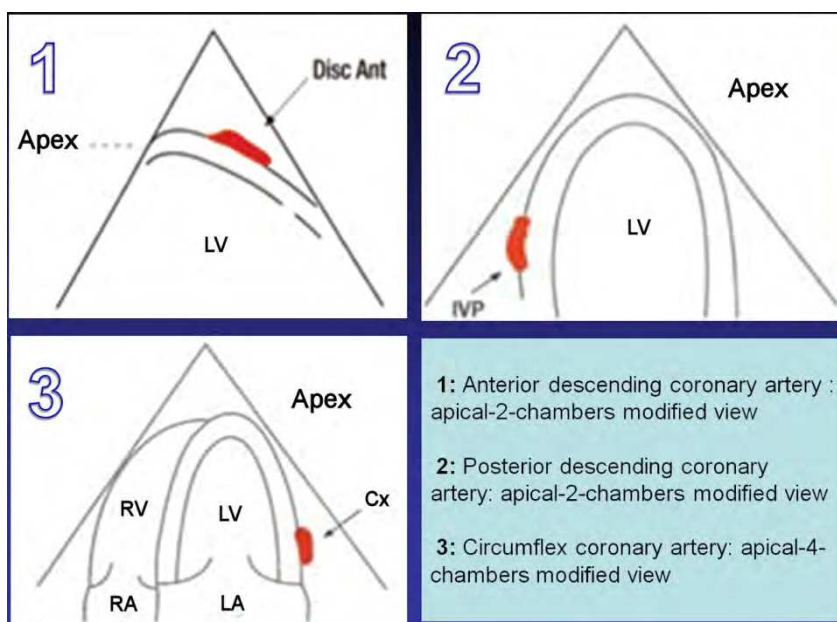


Fig. 7.

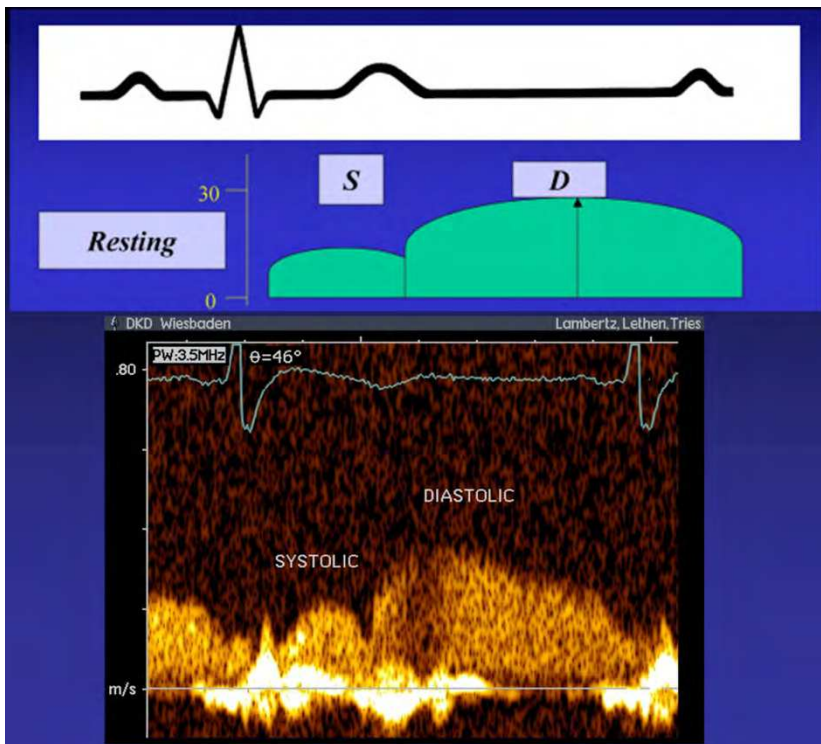


Fig. 8.

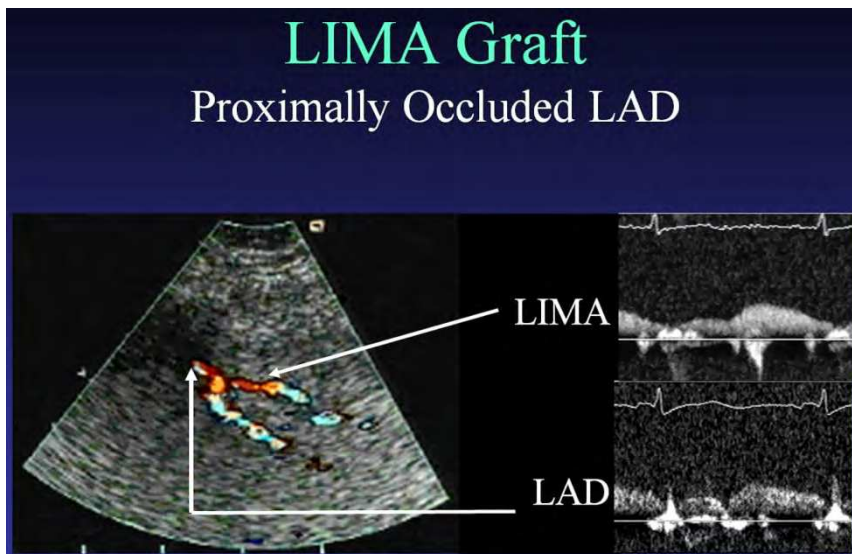


Fig. 9.

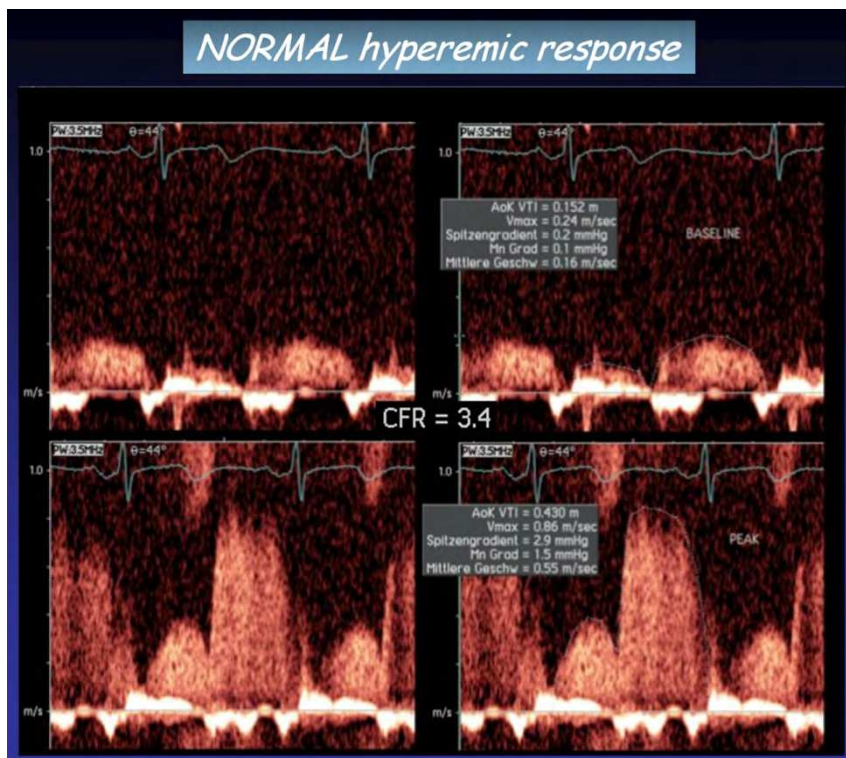


Fig. 10.

the observed flow for the duration of the exam in order to compare the baseline and the hyperemic Doppler patterns; using a pulsed-wave Doppler volume dimension wider than 2 mm, in order to overcome the sampling problems due to hyperventilation. TTE-CFR assessment feasibility is up to 98% and it is highly repeatable: for these reasons Doppler signal enhancement and contrast agents as well are not necessary. All collected data are strictly congruent with DFW. Using an apical, 2-chambers echocardiographic view is also possible to check the posterior interventricular artery: the feasibility of this examination is clearly worse, in this case, due to the over breathing induced by adenosine and for the use of common transducers (while for the anterior descending artery is already mandatory the use of dedicated probes). The overall feasibility of the TTE-CFR assessment is quite good in all the main epicardial coronary arteries: 98% for the anterior descending artery; 81% for the posterior interventricular one; 73% for the circumflex<sup>13</sup>.

TTE-CFR assessment limitations: TTE-CFR has limited spatial resolution, making it impossible to evaluate the vessel cross-sectional area. According to some Authors<sup>14</sup> opinion, a CFR estimation is not fully reliable, if only based on flow speed data collection, but the reality is that adenosine-induced diameter variation of epicardial coronary arteries is always less than 5%, which means there is no statistical significance in such values<sup>15</sup>. Like in each Doppler analysis, CFR assessment is angle-dependant and it's important that this angle should be  $>30^\circ$ , to avoid an underestimation of the factors, and it must be kept constant



before and after the hyperemic stimulation. The production of sampling artifacts is possible too: when a big marginal artery is mistaken for the anterior descending one; when the anterior descending artery is affected by a very distal stenosis, causing a CFR assessment which is exclusively based on a pre-stenotic data acquisition.

#### 4. Stressors used in CFR assessment

There are various stressors used to induce myocardial ischemia and they all act these ways: the steal effect and the increased myocardial oxygen demand. The most commonly used stressors are drugs and non-pharmacologic stressors.

Non pharmacological stressors are: exercise, which is the most commonly used, and pacing. Exercise test echocardiography is the closest to every day conditions: coronary flow increases as the double product of heart rate and systolic blood pressure ( $HR \times SBP$ ), which is used as an estimate of myocardial work and is proportional to myocardial oxygen consumption.

The steal effect is caused by dipyridamole, while the increased myocardial oxygen demand is caused by the administration of dobutamine, by the pacing<sup>16</sup> and by transient coronary obstruction<sup>17</sup>.

Drugs used to induce coronary vasodilation are: dipyridamole, adenosine and papaverine, being this last one, the least commonly used. Dipyridamole reduces myocardial oxygen demand acting on the A2 adrenergic receptors placed on the smooth muscle cells and on the endothelial cells: it causes a bad blood flow distribution, thus a "steal effect". The fact is that it also indirectly raises the adenosine concentration, limiting its re-uptake and consumption<sup>18</sup>. Dipyridamole must be given in an intravenous administration of 0.84 mg/Kg: in the *traditional protocol*<sup>19</sup> this happens in 10 minutes, divided in 2 infusions (0.56 mg/Kg over 4 minutes; 4 minutes of no dose and, if still negative, an additional 0.28 mg/Kg over 2 minutes) and eventually followed by the delivery of up to 1 mg of atropine in order to maximize the accuracy of the test. The sensitivity of the test increases using the *fast protocol*, that consists in the administration of a one-shot dose of 0.84 mg/Kg of dipyridamole in 6 minutes<sup>20</sup> (**FIG 11**). This is useful to limit the duration of the test too. Wall Motion Score Index (WMSI) and anterior descending artery coronary flow are further parameters evaluable during CFR assessment with the fast protocol. Dipyridamole effects are quite long-lasting: up to 30 minutes and the peak effect can last up to 6-16. For this reason the main side effects of its use are hypotension, headache, nausea, flushing, then a fast administration of the right antidote, aminophylline<sup>21</sup>, should be considered. Contraindications to dipyridamole use are: third degree atrio-ventricular block, sick sinus syndrome, asthma. No more adenosine must be administered in the 24 hours following a CFR assessment, for its long lasting blood concentration; during the 24 hours before the examination the patient must avoid the use of coffee or tea-based drinks in order to test the largest number of free adenosine receptors.

Adenosine acts through specific A2 inhibitor receptors located on the surface of smooth muscle cells and on the endothelium of epicardial coronary vessels. Its ischemia-inducing action is similar to dipyridamole, but for the direct and short-lasting effects (only a few seconds)<sup>22</sup>. Even side effects are the same, but really brief, in these cases and no aminophylline

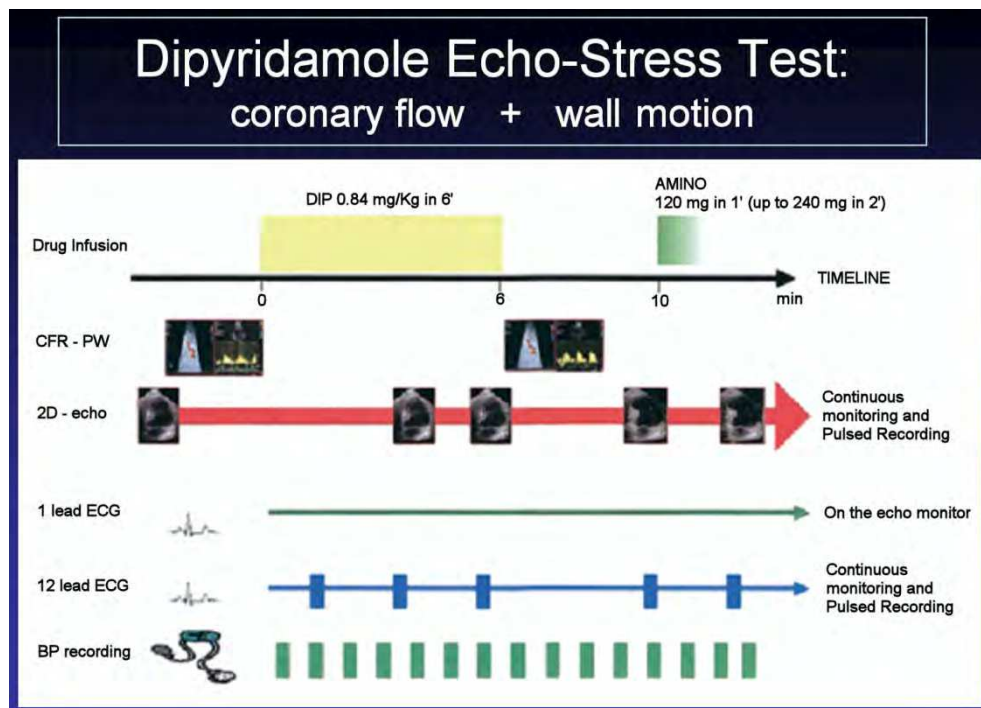


Fig. 11.

is usually required. In normal patients adenosine administration raises up to 4-5 times the coronary flow, just like high-dose dipyridamole<sup>23</sup>, however always much more than after dobutamine or after stress exercise. Dipyridamole can be manually injected using a syringe, but for adenosine an infusion pump is necessary and the starting dose is 100  $\mu\text{g}/\text{Kg}/\text{min}$ , slowly raising up to 200  $\mu\text{g}/\text{Kg}/\text{min}$ . The final administration of atropine at the end of the test to reach the maximal heart rate, raises its sensitivity in these cases too. To evaluate the CFR via TTE a dose of 140  $\mu\text{g}/\text{Kg}/\text{min}$  in an endovenous infusion of 5 minutes is ideal<sup>24</sup>: imaging is performed prior and after the starting of the injection. Even better, because significantly cheaper, is the IV injection of only 6 mg of drug in 10-15 seconds (FIG 12). Adenosine test is always safe and reliable for the assessment of anterior descending artery stenoses<sup>25</sup>.

Dobutamine is a sympathomimetic drug, directly acting on the  $\beta_1$  adrenergic myocardial receptors increasing heart rate and contractility and also acting on the  $\beta_2$  receptors on the epicardial coronary vessels, as a vasodilator<sup>26</sup>. Chronotropic and inotropic response to the dobutamine stimulation raises myocardial oxygen consumption, inducing ischemia: coronary flow increases 3 times the baseline value to face this condition. The drug is administered intravenously in incremental doses spanning the range 5 to 40  $\mu\text{g}/\text{Kg}/\text{min}$  in repeated stages, each one lasting 3 minutes. If the maximal heart rate is not reached is possible a final administration of atropine. The feasibility of these tests is about 90%<sup>27</sup>, being also possible a WMSI and a anterior descending artery flow assessment.

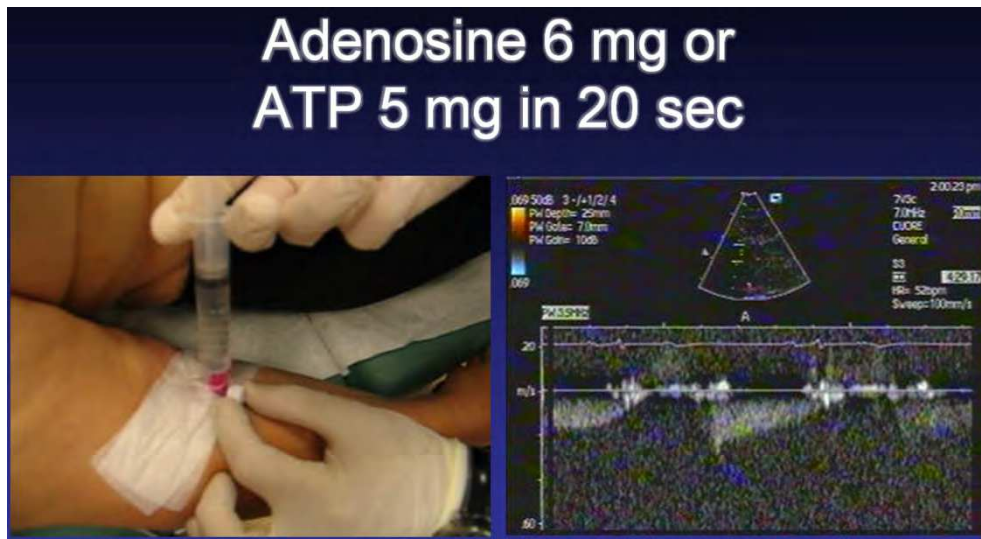


Fig. 12.

The most commonly used non-pharmacologic stressors are physical exercise, cardiac pacing and the Cold Pressure Test (CPT).

Exercise echocardiography can be performed using either a treadmill or a bicycle protocol: when using a treadmill, scanning during exercise is not feasible, so it's mandatory an immediate post-exercise imaging as soon as possible (<1 minute from cessation of exercise). Bicycle exercise is performed during either an upright or a recumbent posture: in every moment during the various levels of exercise the collection of data is possible. Physical exercise acts raising the heart rate, the blood pressure values and the inotropic state, then raising the myocardial oxygen consumption as well: as a consequence, the CFR values raise too, because the coronary flow is controlled by the oxygen demand. The stress CFR is easier to assess using nuclear medicine techniques, such as Single-Photon Emission Computed Tomography (SPECT) or PET, than using ultrasound due to hyperventilation and chest wall movements.

Cardiac pacing allows the induction of a controlled myocardial stress raising the heart rate, which is the main determinant of the oxygen demand. This result can be achieved via right atrium direct pacing during a catheterization procedure, via transesophageal atrial pacing or via atrial or ventricular noninvasive pacing exploiting the presence of a permanent pacemaker. External cardiac pacing requires the use of the standard echo-stress protocol: starting from 110 beats per minute, the heart rate should be increased by 10 beats every 3 minutes until the target heart rate is reached (85% of age-predicted maximal heart rate). The same goals can be achieved in an accelerated fashion, increasing the heart rate every 30 seconds<sup>16</sup>. A limiting factor is that several pacemakers cannot be programmed to reach the target heart rate. Echocardiographic image acquisition is performed at baseline conditions and throughout the test; the final data collection is made after 3 minutes of pacing at the highest heart rate or at the target heart rate. The diagnostic accuracy of this stress test is remarkable.

The CPT is based on an endothelial dependant response to a thermal stimulation. The exam is performed putting a patient's hand in the cold water for 2-3 minutes, inducing a reactive hyperemia. This vasodilator response is caused by endothelial NO release, due to an *a frigore* sympathetic nervous system activation. With the subsequent reduced NO bioavailability,  $\alpha$ -adrenergic effects are no longer balanced and the ischemia prevails. The CPT assessed endothelial dysfunction is a good predictor of major cardiac events and is useful in prognostic stratification<sup>28</sup>. Nowadays normal reference ranges for CFR assessed via CPT still don't exist, so this test cannot be used to diagnose inducible ischemia yet<sup>29</sup>.

## 5. Coronary Flow Reserve and epicardial coronary stenoses

Estimating the patients' coronary reserve allows to estimate the rate at which this reserve may disappear: as a direct consequence it become possible to pronounce a correct prognosis and to give a proper therapy, directed to increase this reserve, preventing or eliminating the stresses that might compromise it. Downstream to an epicardial coronary stenosis there is a pressure drop directly proportional to the obstruction itself. If the stenosis is little or moderate, the blood flow is maintained by the vasodilation activated as a reaction. For an hemodynamically significant stenosis, angina symptoms start to appear. Over 70% of stenosis the coronary flow reserve cannot increase over the factor of 2x, defined as the normality cutoff. 85-90% stenoses can reduce the coronary blood flow even at rest, because the adaptive capabilities of coronary flow are completely lost: this is why CFR assessment is important in order to identify the least important obstructions, being an estimation of the functionality of compensatory mechanisms (**FIG 13**). The CFR dissolves for >90% obstructions. These data are true for isolated stenoses of a single vessel, without the involvement of microcirculation, nor side branches (**FIG 14**). Many more confounding factors may arise: the main one is certainly the microcirculatory dysfunction. TTE-CFR can be used in clinical practice to collect data comparable with that from invasive tests<sup>30</sup>. CFR normality cutoff is >2. This technique samples the blood flow typically from the anterior

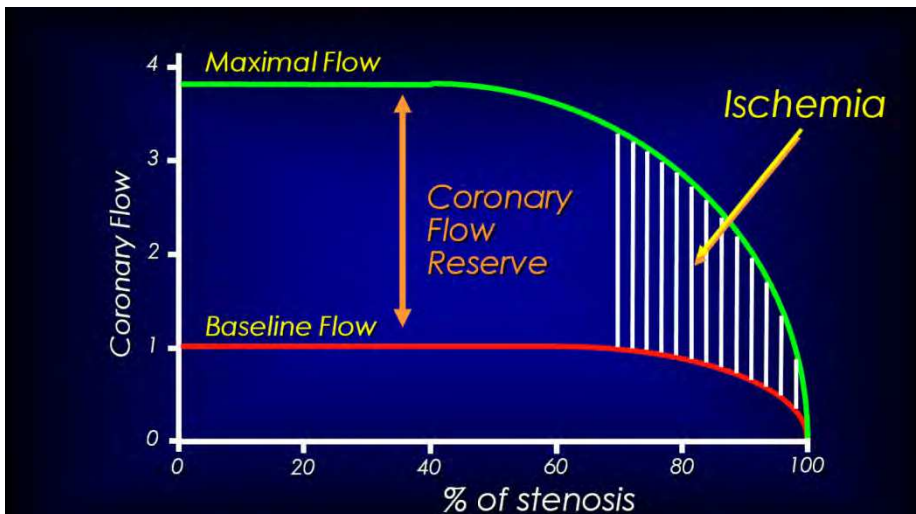


Fig. 13.



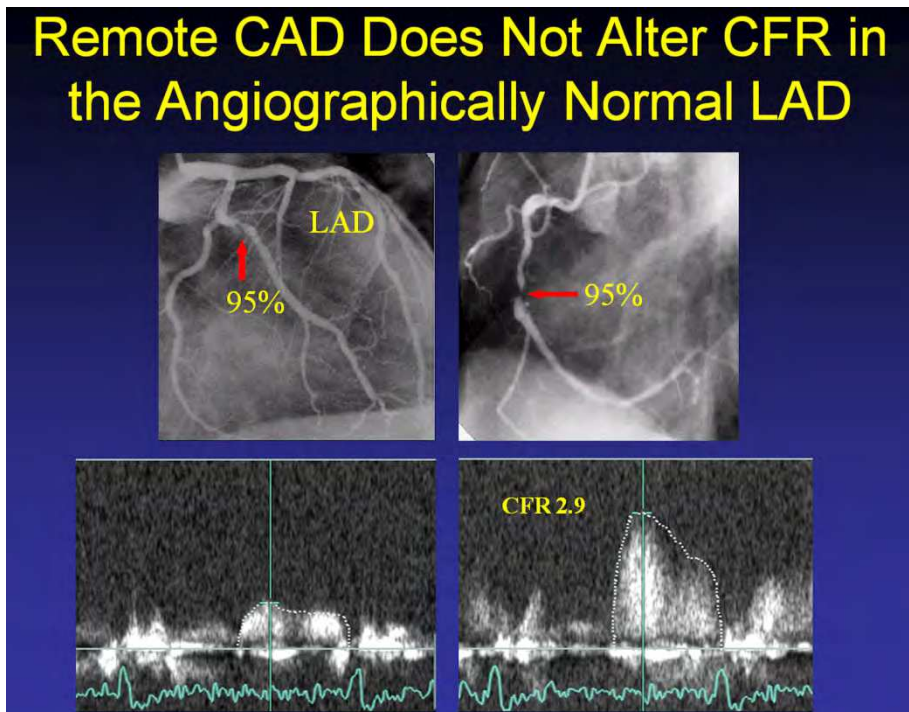


Fig. 14.

descending artery, neglecting microcirculatory conditions: for this reason it should be integrated in a classic pharmacologic echocardiographic stress test to evaluate the regional wall motion. Both tests can be conducted using the same pharmacological stressor: dipyridamole. The combined Wall motion and CFR assessment, then, adds more sensitivity without a significant loss of specificity to the echocardiographic stress examination (**FIG 15**). Dipyridamole is a stressor drug particularly suitable for this use. A skilled operator can exploit another chance, assessing not only the anterior descending, but also the posterior descending and the circumflex arteries<sup>31</sup>. Performing the TTE-CFR assessment requires a skilled operator because of hyperventilation too: from 5 to 10 seconds after the administration of the pharmacological stressor the maximal hyperemia is observable and a significant hyperventilation occurs, making difficult to focus the ultrasonic beam on the assessed coronary artery. After all, without hyperventilation the test is not acceptable and the risk of an underestimation of CFR becomes very high (maybe because of the inadequate dose of drug or for a peculiar pool of cardiac receptors in the evaluated patient). Angiography may be unable to determine intermediate (40-70%) stenoses, revealing the need for a revascularization: a functional evaluation of the stenoses appears then crucial. Only the functionally significant stenoses, which are related to scintigraphically observable regional myocardial perfusion defects should be addressed to revascularization<sup>32</sup>. Moreover, CFR, if between 1.8 and 2.0, have a positive predictive value of 88-100% and a negative predictive value of 77-95% when there is a scintigraphically evident myocardial perfusion defect (**FIG 16**). CFR, then, recovers very early, even in the next few hours after the

### Diagnostic value of 2D Echo-Stress test and CFR

	Sensitivity	Specificity	Accuracy
Echo 2D	74%	91%	86%
CFR (cut-off=2)	89%	77%	81%
CFR (cut-off=1.9)	81%	84%	83%
CFR (cut-off=1.8)	69%	90%	83%
CFR (cut-off=1.7)	63%	97%	86%
CFR (cut-off=1.6)	50%	100%	85%
CFR (cut-off=1.5)	30%	100%	79%
<b>2D Echo+CFR cutoff = 1.9</b>	<b>90%</b>	<b>94%</b>	<b>93%</b>

Fig. 15.

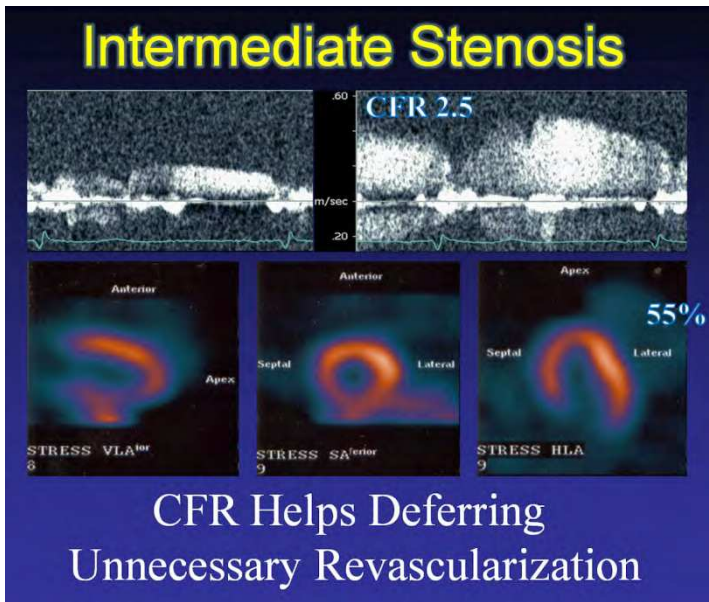


Fig. 16.

procedure if all epicardial coronary stenoses are treated. TTE-CFR is also useful to evaluate the outcomes of revascularization procedures after acute events: it's very important during the follow-up of a stenting procedure to assess the eventual in-stent restenosis with a sensitivity of 78% and a specificity of 93% for each restenosis<sup>33</sup> (FIG 17). It should be remembered that post surgical procedures a flow competition from the native coronary artery can reduce the blood stream even without a bypass stenosis. In these cases the best choice is to perform the TTE-CFR directly on the native anterior descending artery<sup>34</sup> (FIG 18)(FIG 19).

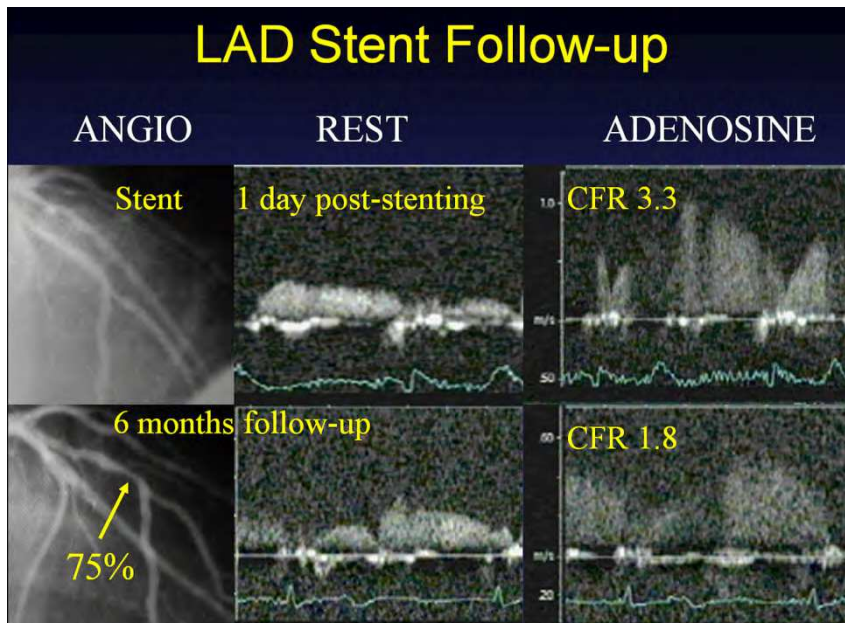


Fig. 17.

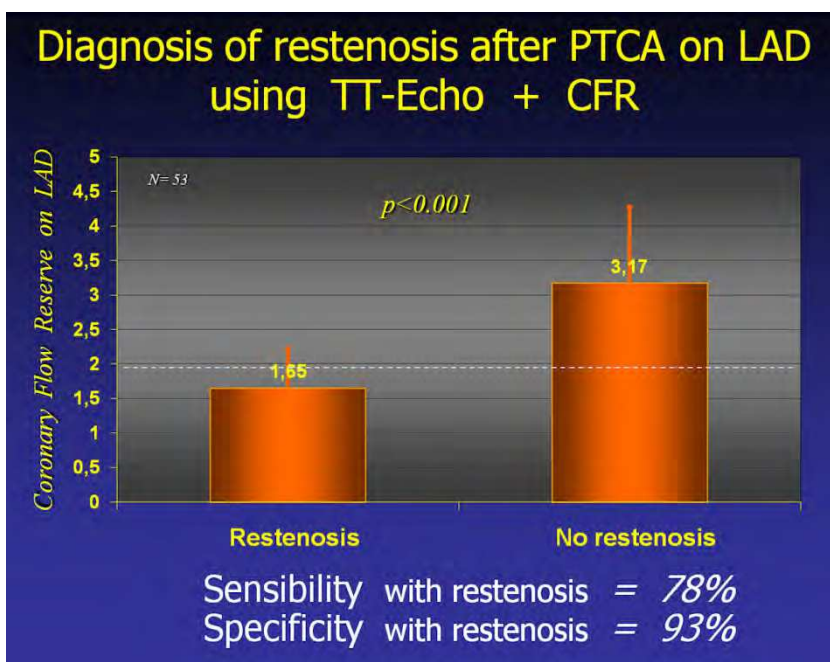


Fig. 18.

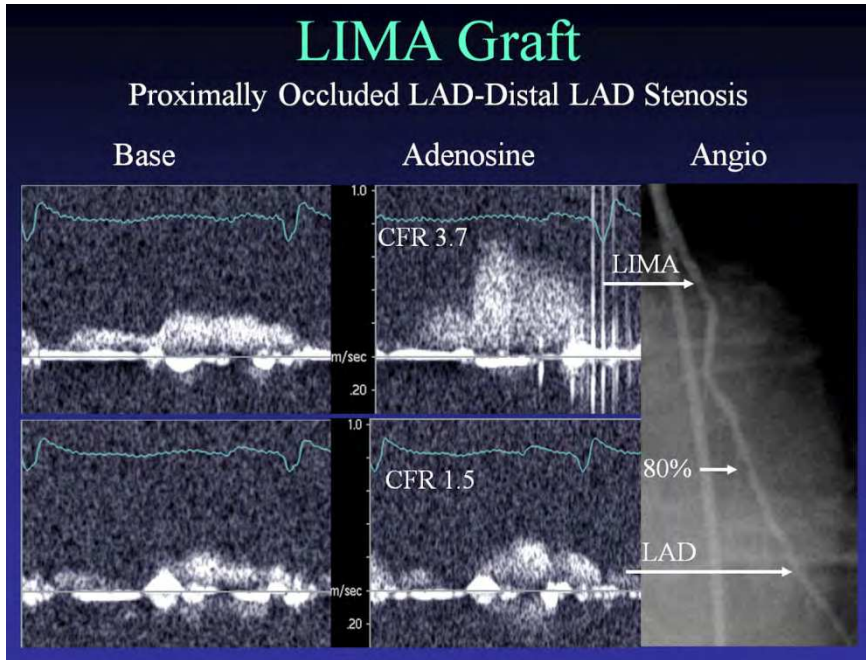


Fig. 19.

## 6. Coronary Flow Reserve and microcirculatory dysfunctions

High intraventricular pressure, determining compression on microcirculation, generates a CFR much greater in subepicardial layer, than in subendocardial. CFR, then, dissolves first in subendocardial layer, when problems occur<sup>35</sup> (FIG 20). Whether an epicardial coronary stenosis is present or not, CFR reduction can be caused by any condition producing microcirculation impairment: for intrinsic (inflammations,, endothelial damages, etc.) or extrinsic reasons (extra-vascular compression). There are 3 main types of microvascular dysfunctions (MD):

- *MD with epicardial coronary obstruction:* atheromatous lesions are often related to microcirculation flow regulation impairment.
- *Inadequate revascularization:* after surgical or percutaneous revascularization procedures, tissue edema and increased blood levels of free radicals can greatly damage microcirculation functionality.
- *No angiographically significant lesions:* these are the cases of cardiac syndrome X (microvascular angina) or conditions related to several risk factors causing microvascular functionality damages, such as hypertension or diabetes mellitus.

A reduced TTE-CFR means microcirculation impairment only if the coronary angiography does not show any epicardial stenosis. Performing a TTE-CFR assessment combined with an echocardiographic stress test for the coronary flow estimation in the anterior descending artery and the regional wall motion study is possible to overcome such limitations. The resulting scenarios are<sup>29</sup>:



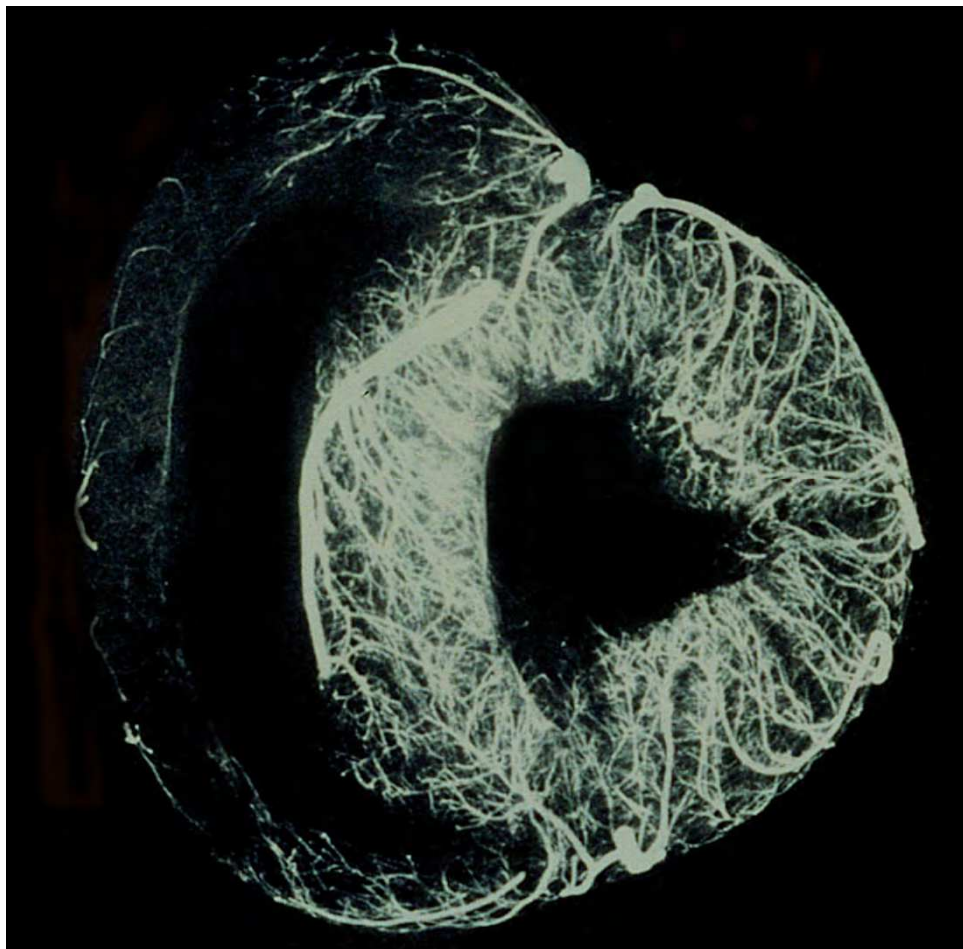


Fig. 20.

- a. Normal TTE-CFR + Normal wall motion = no damage.
- b. Reduced TTE-CFR + Impaired wall motion = epicardial coronary stenosis
- c. Reduced TTE-CFR + Normal or increased wall motion = coronary microcirculation isolated dysfunction.
- d. Normal TTE-CFR + impaired wall motion in locations far from the observed artery

In this last possibility, it's mandatory to perform TTE-CFR on right and circumflex coronary arteries too or to base any further decision only on the analysis of regional wall motion.

Microvascular dysfunction without angiographically assessed epicardial coronary stenoses knows various causes, such as hypertensive cardiomyopathy, diabetes mellitus, hypertrophic cardiomyopathy, idiopathic dilated cardiomyopathy, cardiac syndrome X. TTE-CFR reduction, in these conditions, is highly variable, but it may become wider than observed as an exclusive consequence of anterior descending artery stenoses<sup>36</sup>. Hypertensive cardiomyopathy is nowadays the most assessed in all these conditions, using TTE-CFR; many studies showed that coronary reserve is reduced even without a clear left ventricle hypertrophy: probably this happens because of microcirculatory remodeling<sup>37</sup>. Functional and morphological microcirculatory modifications are strictly joined and bioptic myocardial samples confirm this linkage. Endothelial dysfunction and extra-vascular compression are further possible causes. Concerning diabetes mellitus, especially for type 2, CFR reduction is insulin resistance<sup>38</sup> related, while hyperglycaemic concentrations play a background role. Microangiopathy in diabetes knows the same progression, both in coronary microcirculation and in retina<sup>39</sup>. CFR can be reduced in dilated cardiomyopathy, mostly for the ventricular shear stress, which characterises this condition<sup>40</sup>. Cardiac syndrome X may reduce CFR just like observable in epicardial coronary stenoses<sup>41</sup>: stress tests induce angina pectoris, ST segment depression and scintigraphically relevant myocardial perfusion defects. TTE-CFR test effectiveness and wall motion analysis (echographic stress test using the fast protocol of dipyridamole injection) are maximized if also a coronarographic assessment is performed as a cross-check for the presence of epicardial coronary stenoses. After a revascularization procedure, microcirculatory conditions are crucially important: many studies showed that microvascular damage after acute myocardial infarction reaches its peak 48 hours after reperfusion<sup>42</sup>. Then, performing a CFR assessment after that peak time, provides important information on the microcirculatory damage and is a predictor of left ventricle functional recovery. In Myocardial Contrast Echocardiography (MCE) the non-reflow extent, which is greater in patients with a reduced TTE-CFR (<2.5) than observable in patient with normal TTE-CFR (>2.5) and during the follow-up, the highest TTE-CFR values are related to the functional recovery, well indicated by the WMSI<sup>43</sup>. The CFR assessment does not help in differentiating microcirculatory dysfunction and epicardial stenoses when both problems are present, but in one case: in patients who underwent heart transplantation. TTE-CFR provides useful information on microcirculation and on the Cardiac Allograft Vasculopathy (CAV), a condition implying both epicardial coronary and microvasculature disease<sup>44</sup>. Angiography usually underestimate the seriousness of the problem<sup>44</sup> and the Intravascular Ultrasound (IVUS) is the (invasive) gold standard examination to perform<sup>45</sup>. This is a micro- and macrovascular kind of damage and a reduced TTE-CFR allows a diagnosis of CAV if <2.7 (sensitivity 87%, specificity 82%)<sup>46</sup>.

## 7. References


- [1] Hozumi T, Yoshida K, Akasaka T, et al. "Noninvasive assessment of coronary flow velocity and coronary flow velocity reserve in the left anterior descending coronary artery by Doppler echocardiography: comparison with invasive technique". *J Am Coll Cardiol* 1998; 32: 1251-1260.
- [2] Beanlands RS, Muzik O, Melon P, et al. "Noninvasive quantification of regional myocardial flow reserve in patients with coronary atherosclerosis using nitrogen-13 ammonia positron emission tomography. Determination of extent of altered vascular reactivity". *J Am Coll Cardiol* 1995; 26: 1465-1475.
- [3] Barbato A, Arnadouse W, Aengevaeren GW, et al. "Validation of coronary flow reserve measurement by thermodilution in clinical practice" *Eur Heart J* 2004; 25:219-223.
- [4] De Bruyne B, Baudhuin T, Melin JA, et al. "Coronary flow reserve calculated from pressure measurement in humans. Validation with Positron Emission Tomography". *Circulation* 1994; 89: 1013-1022.
- [5] Fearon WP, Balsam LB, Farouque HM, et al. "Novel index for invasively assessing the coronary microcirculation". *Circulation* 2003; 107: 3129-3132.
- [6] Wilson RF, Laughlin DE, Ackell PH, et al. "Transluminal subselective measurement of coronary artery blood flow velocity and vasodilator reserve in humans". *Circulation* 1985; 72: 82-92.
- [7] Youn HJ & Forster E. "Transesophageal echocardiography (TEE) in the evaluation of the coronary arteries". *Cardiol Clin* 2000; 18: 833-848.
- [8] Yamagishi M, Yasu T, Ohara K, et al. "Detection of coronary blood flow associated with main left coronary artery stenosis by transesophageal Doppler color flowechocardiography". *J Am Coll Cardiol* 1991; 17: 87-93.
- [9] Iliceto S, Marangelli V, Memmola C, et al. "Transesophageal Doppler echocardiography evaluation of coronary blood flow velocity in baseline conditions and during dipyridamole-induced coronary vasodilation". *Circulation* 1991; 83: 61-69.
- [10] Redberg RF, Sobol Y, Chou TM, et al. "Adenosine-induced coronary vasodilation during transesophageal Doppler echocardiography. Rapid and safe measurement of coronary flow reserve ratio can predict significant left anterior descending stenosis". *Circulation* 1995; 92: 190-196.
- [11] Paraskevaïdis IA, Tsiapras D, Karavolias GK, et al. "Serial evaluation of coronary flow reserve by transesophageal Doppler Echocardiography after angioplasty of proximal left anterior descending left coronary artery: a 6-month follow-up study". *Coron Artery Dis* 2001; 12: 45-52.
- [12] de Simone L, Caso P, Severino S, et al. "Reduction of coronary flow reserve non invasively determined by transthoracic Doppler echocardiography as a predictor of left anterior descending coronary artery stenosis". *It Heart J* 2000; 1: 234-239.
- [13] Murata E, Hozumi T, Matsumura Y, et al. "Coronary flow velocity reserve measurement in three major coronary arteries using transthoracic Doppler echocardiography" *Echocardiography* 2006; 23: 279-286.
- [14] Kaufmann PA, Jenni R. "Coronary flow reserve assessment from average peak velocity profiles alone must be judged with caution". *J Am Coll Cardiol* 2000; 35: 1363-1364.

- [15] Reis ES, Holubkov R, Lee JS, et al. "Coronary flow velocity response to adenosine characterizes coronary microvascular function in women with chest pain and no obstructive coronary artery disease". *J Am Coll Cardiol* 1999; 33: 1469-1475.
- [16] Gilgorova S, Agrusta M. "Pacing stress echocardiography". *Cardiovasc Ultrasound* 2005; 3: 36.
- [17] Marcus M, Wright C, Doty D, et al. "Measurement of coronary velocity and reactive hyperemia in the coronary circulation in humans". *Circ Res* 1981; 49: 877-891.
- [18] Picano E. "Stress echocardiography". Springer-Verlag, Heidelberg (Germany) 2003 (4th Edition).
- [19] Picano E, Lattanzi F, Masini M, et al. "High dose dipyridamole echocardiography test in effort angina pectoris". *J Am Coll Cardiol* 1986; 8: 848-854.
- [20] Dal Porto R, Faletta F, Picano E, et al. "Safety, feasibility and diagnostic accuracy of accelerated high-dose dipyridamole stress echocardiography". *Am J Cardiol* 2001; 87: 520-524.
- [21] Dimitrow PP, Galderisi M, Rigo F. "The noninvasive documentation of coronary macrocirculation impairment: role of transthoracic echocardiography". *Cardiovasc Ultrasound* 2005; 3: 184.
- [22] Iskandrian AS, Verani MS, Heo J. "Pharmacologic stress testing: mechanism of action, hemodynamic responses and results in detection of coronary artery disease". *J Nucl Cardiol* 1994; 1: 94-111.
- [23] Rossen JD, Quillen JE, Lopez AG, et al. "Comparison of coronary vasodilation with intravenous dipyridamole and adenosine". *J Am Coll Cardiol* 1991; 18: 485-491.
- [24] Caiati C, Montaldo C, Zedda N, et al. "Validation of a new, noninvasive method (contrast-enhanced transthoracic second Harmonic echo Doppler) for the evaluation of coronary flow reserve: comparison with intracoronary Doppler flow wire". *J Am Coll Cardiol* 1999; 34: 1193-1200.
- [25] Voci P, Pizzuto F, Mariano E, et al. "Usefulness of coronary flow reserve measured by transthoracic coronary Doppler ultrasound to detect severe left anterior descending coronary artery stenosis". *Am J Cardiol* 2003; 92: 1320-1324.
- [26] Warltier DC, Zywoloski M, Gross GJ, et al. "redistribution of myocardial blood flow distal to a dynamic coronary arterial stenosis by sympathomimetic amines: comparison of dopamine, dobutamine and isoproterenol". *Am J Cardiol* 1981; 48: 269-279.
- [27] Takeuchi M, Miyazaki C, Yoshitani H, et al. "Assessment of coronary flow velocity with transthoracic Doppler echocardiography during dobutamine stress echocardiography". *J Am Coll Cardiol* 2001; 38: 117-123.
- [28] Schächinger V, Britten MB, Zeiher AM, et al. "Prognostic impact of coronary vasodilator dysfunction on adverse long-term outcome of coronary heart disease". *Circulation* 2000; 101: 1899-1906.
- [29] Galderisi M, D'Errico A. "Beta-blockers and coronary flow reserve: the importance of a vasodilatory action". *Drugs* 2008; 68: 579-590.
- [30] Daimon M, Watanabe H, Yamagishi H, et al. "Physiologic assessment of coronary artery stenosis by coronary flow reserve measurements with transthoracic Doppler



- echocardiography: comparison with exercise thallium-201 single-photon emission computed tomography. *J Am Coll Cardiol* 2001; 37: 1310-1315.
- [31] Krzanowski M, Bodzon W, Dimitrow PP. "Imaging of all three coronary arteries by transthoracic echocardiography. An illustrated guide". *Cardiovascular Ultrasound* 2003, 1.
- [32] Chamuleau SA, Tio RA, de Cock CC, et al. "Prognostic value of coronary blood flow velocity and myocardial perfusion in intermediate coronary narrowings and multivessel disease". *J Am Coll Cardiol* 2002; 39: 852-858.
- [33] Ruscazio M, Montisci R, Colonna P, et al. "Detection of coronary restenosis after coronary angioplasty by contrast-enhanced transthoracic echocardiographic Doppler assessment of coronary flow velocity reserve". *J Am Coll Cardiol* 2002; 40: 896-903.
- [34] Pizzuto F, Voci P, Mariano E, et al. "Evaluation of flow in the left anterior descending coronary artery but not in the left internal mammary artery graft predicts significant stenosis of the arterial conduit". *J Am Coll Cardiol* 2005; 45: 424-432.
- [35] Dimitrow PP, Galderisi M, Rigo F. "The non-invasive documentation of coronary microcirculation impairment: role of transthoracic echocardiography". *Cardiovasc Ultrasound* 2005; 3: 184.
- [36] Rigo F, Gherardi S, Galderisi M, Cortigiani L. "Coronary flow reserve evaluation in stress-echocardiography laboratory". *J Cardiovasc Med* 2006; 7: 472-479.
- [37] Kozakova M, Galletta F, Gregorini L, et al. "Coronary vasodilator capacity and epicardial vessel remodeling in physiological and hypertensive hypertrophy". *Hypertension* 2000; 36: 343-349.
- [38] Quinones MJ, Hernandez Pampaloni M, Schelbert H, et al. "Coronary vasomotor abnormalities in insulin-resistant individuals". *Ann Intern Med* 2004; 140: 700-708.
- [39] Pop-Busui R, Kirkwood I, Schmid H, et al. "Sympathetic dysfunction in type I diabetes: association with impaired myocardial blood flow reserve and diastolic dysfunction". *J Am Coll Cardiol* 2004; 44: 2368-2374.
- [40] Vanderheyden M, Bartunek J, Verstreken S, et al. "Non-invasive assessment of coronary flow reserve in idiopathic dilated cardiomyopathy: hemodynamic correlations". *Eur J Echocardiogr* 2005; 6: 47-53.
- [41] Crea F, Lanza GA. "Angina pectoris and normal coronary arteries: cardiac Syndrome X". *Heart* 2004; 90: 457-463.
- [42] Rochitte CE, Lima JA, Bluemke DA, et al. "Magnitude and time course of microvascular obstruction and tissue injury after acute myocardial infarction". *Circulation* 1998; 98: 1006-1014.
- [43] Montisci R, Chen L, Ruscazio M, et al. "Noninvasive coronary flow reserve is correlated with microvascular integrity and myocardial viability after primary angioplasty in acute myocardial infarction". *Heart* 2006; 92: 1113-1118.
- [44] Caforio AL, Tona F, Fortina AB, et al. "Immune and nonimmune predictors of cardiac allograft vasculopathy onset and severity: multivariate risk factor analysis and role of immunosuppression". *Am J Transplant* 2004; 4: 962-970.

- [45] Rickenbacher PR, Pinto FJ, Lewis NP, et al. "Prognostic importance of intimal thickness as measured by intracoronary ultrasound after cardiac transplantation". *Circulation* 1995; 92: 3445-3552.
- [46] Tona F, Caforio AL, Montisci R, et al. "Coronary flow reserve by contrast-enhanced echocardiography: a new noninvasive diagnostic tool for cardiac allograft vasculopathy". *Am J Transplant* 2006; 6 (5 Pt 1): 998-1003.



**Coronary Artery Disease - Current Concepts in Epidemiology, Pathophysiology, Diagnostics and Treatment**

Edited by Dr. David Gaze

ISBN 978-953-51-0262-5

Hard cover, 272 pages

**Publisher** InTech

**Published online** 16, March, 2012

**Published in print edition** March, 2012

Cardiovascular disease is ranked as the leading cause of death world wide, responsible for 17.1 million deaths globally each year. Such numbers are often difficult to comprehend. Heart disease kills one person every 34 seconds in the USA alone. Although the leading killer, the incidence of cardiovascular disease has declined in recent years due to a better understanding of the pathology, implementation of lipid lowering therapy new drug regimens including low molecular weight heparin and antiplatelet drugs such as glycoprotein IIb/IIIa receptor inhibitors and acute surgical intervention. The disease burden has a great financial impact on global healthcare systems and major economic consequences for world economies. This text aims to deliver the current understanding of coronary artery disease and is split into three main sections: 1. Epidemiology and pathophysiology of coronary artery disease 2. Coronary artery disease diagnostics and 3. Treatment regimens for coronary artery disease

**How to reference**

In order to correctly reference this scholarly work, feel free to copy and paste the following:

Francesco Bartolomucci, Francesco Cipriani and Giovanni Deluca (2012). Coronary Flow: From Pathophysiology to Clinical Noninvasive Evaluation, Coronary Artery Disease - Current Concepts in Epidemiology, Pathophysiology, Diagnostics and Treatment, Dr. David Gaze (Ed.), ISBN: 978-953-51-0262-5, InTech, Available from: <http://www.intechopen.com/books/coronary-artery-disease-current-concepts-in-epidemiology-pathophysiology-diagnostics-and-treatment/coronary-flow-from-pathophysiology-to-clinical-noninvasive-evaluation>

**INTECH**  
open science | open minds

**InTech Europe**

University Campus STeP Ri  
Slavka Krautzeka 83/A  
51000 Rijeka, Croatia  
Phone: +385 (51) 770 447  
Fax: +385 (51) 686 166  
[www.intechopen.com](http://www.intechopen.com)

**InTech China**

Unit 405, Office Block, Hotel Equatorial Shanghai  
No.65, Yan An Road (West), Shanghai, 200040, China  
中国上海市延安西路65号上海国际贵都大饭店办公楼405单元  
Phone: +86-21-62489820  
Fax: +86-21-62489821

© 2012 The Author(s). Licensee IntechOpen. This is an open access article distributed under the terms of the [Creative Commons Attribution 3.0 License](#), which permits unrestricted use, distribution, and reproduction in any medium, provided the original work is properly cited.