

Metastatic Basal Cell Carcinoma

Anthony Vu and Donald Jr. Laub
University of Vermont,
College of Medicine
USA

1. Introduction

Basal cell carcinoma (BCC) is the most common skin malignancy, accounting for up to 80% of all cancers arising from the epidermis.¹ The disease usually presents as a slow growing, non-healing raised lesion with rolled borders and telangiectasias. These cancers arise from cells lining the deepest layer of the epidermis. BCC affects approximately 1 million Americans each year, more than squamous cell carcinoma and melanoma combined.² It is most commonly diagnosed in older, fair skinned individuals from ages 40-60.³ Large amounts of sun exposure and UV radiation are the most common cause of BCC. Other etiologies include arsenic and various genetic disorders such as Nevus Sebaceous of Jadassohn, Xeroderma Pigmentosum, Basal Cell Nevus syndrome, Bazex syndrome, and Rombo syndrome.

An overwhelming majority of BCCs occur on the face or ear, but other likely sites include the neck, scalp, and upper trunk. Classically, it clinically presents as a pearly, non-healing, papulonodular lesion with rolled borders and telangiectasias, with or without ulcerations. These lesions are typically slow growing, minimally invasive, and thus have a very favorable prognosis. Surgical excision has long been considered the gold standard of treatment.⁴

2. Incidence

Since non-melanoma skin cancers are not reported in most cancer registries, it is hard to determine the exact yearly incidence of BCC. In a study by Miller et al.,⁵ the age-

¹Rubin, AI., Chen, EH., & Ratner, D. (2005). Basal-Cell Carcinoma. *New England Journal of Medicine*, Vol. 353, No. 21, (November 2005), pp. 2262-2269.

²Basal Cell Carinoma. n.d. In: *Skin Cancer Foundation*, May 2011, Available from: <http://www.skincancer.org/basal-cell-carcinoma.html>

³Chuang, TY., Popescu, A., Su, WP., & Chute, CG. (1990). Basal cell carcinoma: a population-based incidence study in Rochester, Minnesota. *Journal of the American Academy of Dermatology*, Vol. 22, No. 3, (March 1990), pp. 413-417.

⁴Bader, RS. (March 2011). Basal Cell Carcinoma, In: *Medscape Reference*, April 2011, Available from: <http://emedicine.medscape.com/article/276624-overview>

⁵Miller, DL. & Weinstock, MA. (1994). Nonmelanoma skin cancer in the United States: incidence. *Journal of the American Academy of Dermatology*, Vol. 30, No. 5.1, (May 1994), pp. 774-778

standardized yearly rates in the United States have been estimated at up to 407 cases of BCC per 100,000 white men and 212 cases per 100,000 white women. The yearly incidence is estimated to range between 900,000 and 1,200,000 cases per year with the trend towards an increasing number of cases each year. The estimated lifetime risk of BCC in the white population is 33-39% in men and 23-28% in women. In a population study of people younger than 40 years, the incidence of BCC per 100,000 persons was 25.9 for women and 20.9 for men.⁶

While the lifetime risk of BCC is high, it is well known to physicians that metastasis is relatively rare.⁴ Using the criteria proposed by Lattes and Kessler in 1951, studies have indexed a metastasis rate of 0.0028-0.5%.⁷ The proposed criteria for the diagnosis of metastatic BCC include:

1. The primary tumor must arise in the skin and not the mucous membranes
2. Metastases must be demonstrated at a site distant to the primary and must not be related to simple extension.
3. Histologic similarity between the primary tumor and the metastasis must exist.
4. The metastases must not have squamous cell features.

In a study by Wadhera et al., the currently published rate of metastasis was found to be higher than the reported numbers seem to show.⁸ Using an incidence of 1 million cases per year in the United States and a metastasis rate of 0.0028%, there should be at least 30 cases of metastatic basal cell carcinoma (MBCC) per year. They report that this number conflicts with the number of cases reported to date. Dating back to 1894, when Beadles reported the first case of MBCC in a 56-year-old male, there have been around 300 reported cases, or an average of 3 cases of MBCC per year over 100 years. This discrepancy supports the idea that the current estimation of the rate of metastasis is incorrect and reporting of this disease in all cancer registries would be of great benefit.

3. Risk factors

3.1 Clinical

Several studies have tried to elucidate the clinical risk factors for metastasis. It is thought that primary tumors in the head and neck region have a higher metastatic potential; up to 85% of primary BCCs that metastasize originate from these regions.⁹ Primary tumors arising

⁶Christenson, L., Borrowman, T., Vachon, C., Tellefson, M., Otley, C., Weaver, A., & Roenigk, R. (2005). Incidence of basal cell and squamous cell carcinomas in a population younger than 40 years. *Journal of the American Medical Association*, Vol. 294, No. 6, (August 2005), pp. 681-690.

⁷Lattes, R., & Kessler, RW. (1951). Metastasizing basal-cell epithelioma of the skin - Report of two cases. *Cancer*, Vol. 4, No. 4, (July 1951), pp. 866-878.

⁸Wadhera, A., Fazio, M., Bricca, G., & Stanton, O. (2006). Metastatic basal cell carcinoma: A case report and literature review. How accurate is our incidence data? *Dermatology Online Journal*, Vol. 12, No. 5, (September 2006), pp. 7.

⁹Malone, JP., Fedok, FG., Belchis, DA., & Maloney, ME. (2000). Basal cell carcinoma metastatic to the parotid: report of a new case and review of the literature. *Ear Nose & Throat Journal*, Vol. 79, No. 7, (July 2000), pp.511-515, 518-519.

from the face alone account for at least two-thirds of metastatic BCC.¹⁰ This may be related to the high concentration of blood vessels and thin skin around these areas.¹¹

Tumors with any of the following characteristics have been thought to be high risk for metastatic potential: long duration, location in the mid face or ear, diameter larger than 2cm, aggressive histological subtype, previous treatment, neglected, or history of radiation.¹² There is a 2% incidence of metastasis for tumors larger than 3cm in diameter. The incidence increases to 25% for tumors larger than 5cm in diameter and 50% for tumors larger than 10cm in diameter.¹ Increased of tissue invasion and extension of the tumor into adjacent anatomical structures also enhance metastatic potential.¹ The male to female ratio is about 2:1.¹³ Immunosuppression and evidence of perineural spread or invasion of blood vessels have also been implicated as risk factors for metastasis.¹⁴

3.2 Histopathologic

While clinical risk factors remain the most widely studied, others have tried to elucidate histopathologic risk factors associated with MBCC. BCC is made up of 5 major histological subtypes which include nodular, superficial, micronodular, infiltrating, and morpheaform. While nodular is thought to be the most common subtype,¹⁵ there is no evidence that supports a particular subtype predisposes to MBCC.¹⁶

The concept of stromal dependence for primary tumor survival was first proposed in 1953 by Pinkus.¹⁷ Several years later, this concept has proven to be applicable to metastatic tumors as well.¹⁸ In a study with nude mice, successful transplantation of tumors occurred

¹⁰Grimwood, RE., Glanz, SM., & Siegle, RJ. (1988). Transplantation of human basal cell carcinoma to C57/Balb/Cbg/bg-nu/nu (nude) mouse. *The Journal of Dermatologic Surgery and Oncology*, Vol. 14, No. 1, (January 1988), pp. 59-62.

¹⁰Snow, SN., Sahl, W., Lo, JS., Mohs, FE., Warner, T., Dekkinga, JA., & Feyzi, J. (1994). Metastatic basal cell carcinoma. Report of five cases. *Cancer*, Vol. 73, No. 2, (January 1994), pp. 328-335.

¹¹Cotran, RS. (1961). Metastasizing basal cell carcinomas. *Cancer*, Vol. 14., No. 5, (September-October 1961), pp. 1036-1040.

¹²Randle, HW. (1996). Basal cell carcinoma. Identification and treatment of the high-risk patient. *Dermatologic Surgery*, Vol. 22, No. 3, (March 1996), pp. 255-261.

¹³von Domarus, H. & Stevens, PJ. (1984). Metastatic basal cell carcinoma. Report of five cases and review of 170 cases in the literature. *Journal of the American Academy of Dermatology*, Vol. 10, No. 6, (June 1984), pp.1043-1060.

¹⁴Robinson, JK. & Dahiya, M. (2003). Basal cell carcinoma with pulmonary and lymph node metastasis causing death. *Archives of Dermatology*, Vol. 139, No. 5, (May 2003), pp. 643-648.

¹⁵Sexton, M., Jones, DB., & Maloney ME. (1990). Histologic pattern analysis of basal cell carcinoma. Study of a series of 1039 consecutive neoplasms. *Journal of the American Academy of Dermatology*, Vol. 23, No. 6.1, (December 1990), pp. 1118-1126.

¹⁶Berlin, JM., Warner, MR., & Bailin, PL. (2002). Metastatic basal cell carcinoma presenting as unilateral axillary lymphadenopathy: report of a case and review of the literature. *Dermatologic Surgery*, Vol. 28, No. 11, (November 2002), pp. 1082-1084.

¹⁷Pinkus, H. (1953). Premalignant fibroepithelioma tumors of the skin. *Archives of Dermatology*, Vol. 67, No. 6, (June 1953), pp. 598-615.

¹⁸Van Scott, EJ. & Reinertson, RP. (1961). The modulating influence of the stromal environment on epithelial cells studied in human autotransplants. *The Journal of Investigative Dermatology*, Vol. 36, Issue 2, (February 1961), pp. 109-131.

when accompanied with its surrounding stroma.¹⁹ Other studies have failed to achieve successful transplantation when the tumors' stroma was not included.²⁰ Stromal dependency thus implies that either metastatic tumor cells are required to carry along their stroma or develop ways to support independent stromal proliferation in order to survive in a new location – perhaps explaining the low rate of metastasis.¹⁷

3.3 Cellular

Cytogenic aberrations have also been described in MBCC. Chromosomal abnormalities, specifically Trisomy 6, originating in primary tumor cells have been implicated as a factor in giving BCC its metastatic potential. In a study by Nangia et al., Trisomy 6 was identified in metastatic tumor cells of all four cases reported.²¹ In addition, all twenty cases of nonaggressive BCCs showed no tumor cells with Trisomy 6 abnormalities. Immunohistochemical markers such as p53, Ki-67, and Bcl-2 can be helpful in differentiating aggressive versus non-aggressive BCCs.^{22,23} Unfortunately, they have not proven to be distinguishing factors between metastatic and non-metastatic BCCs.²⁴

4. Staging

The American Joint Committee On Cancer (AJCC) staging manual groups non-melanoma, non-Merkel cell skin cancers, including BCC, along with over 80 different types of other tumors in the cutaneous Squamous Cell Carcinoma Staging System.²⁵ As a result, the applicability of these guidelines to any individual cancer may be impaired. It is argued that some cutaneous tumors such as BCC do not require the staging needed for cutaneous squamous cell carcinomas, because of the infrequency of metastasis.²⁶ Although full staging is unnecessary for the majority of BCCs, the identification of high-risk behaviors should indicate the need for more in depth evaluation and staging.

²⁰Lyles, TW., Freeman, RG., & Knox, JM. (1960). Transplantation of basal cell epitheliomas. *The Journal of Investigative Dermatology*, Vol. 34, No. 6, (June 1960), pp. 353.

²¹Nangia, R., Sait, SN., Block, AW., & Zhang, PJ. (2001). Trisomy 6 in basal cell carcinomas correlates with metastatic potential. *Cancer*, Vol. 91, No. 10, (May 2001), pp. 1927-1932.

²²Abdelsayed, RA., Guijarro-Rojas, M., Ibrahim, NA., & Sanguenza, OP. (2000). Immunohistochemical evaluation of basal cell carcinoma and trichopilioma using Bcl-2, Ki67, PCNA and P53. *Journal of Cutaneous Pathology*, Vol. 27, No. 4, (April 2000), pp. 169-175.

²³Staibano, S., Lo Muzio, L., Pannone, G., Scalvenzi, M., Salvatore, G., Errico, ME., Fanali, S., De Rosa, G., & Piattelli, A. (2001). Interaction between bcl-2 and P53 in neoplastic progression of basal cell carcinoma of the head and neck. *Anticancer Research*, Vol. 21, No. 6A, (November-December 2001), pp. 3757-3764.

²⁴Ionescu, DN., Arida, M., & Jukic, DM. (2006). Metastatic basal cell carcinoma: four case reports, review of literature, and immunohistochemical evaluation. *Archives of Pathology and Laboratory Medicine*, Vol. 130, No. 1, (January 2006), pp. 45-51.

²⁵Edge, SE., Byrd, DR., Compton, CC., Fritz, AG., Greene, FL., & Trotti, A., (Ed(s).). (2009) *American Joint Committee On Cancer: Cancer Staging Manual, 7th edition*, Springer, 978-0-387-88440-0, New York, NY, USA.

²⁶Warner, CL & Cockerell, CJ. (2011). The new 7th edition American Joint Committee On Cancer staging of cutaneous non-melanoma skin cancer: a critical review. *American Journal of Clinical Dermatology*, Vol. 12, No. 3, (June 2011), pp. 147-154.

Based on current research, depth of invasion may be the most important tumor variable associated with prognosis (See Table 1). In a study by Rowe et al., the presence of either tumor thickness >4mm or depth of invasion \geq Clark level IV was found to be associated with an increased risk of recurrence by a factor of 2, as well as an increase in the risk of metastasis by a factor of 5.²⁷ Similar to melanoma, there is evidence that Breslow thickness may be more important for determining prognosis in non-melanoma cutaneous carcinoma than Clark's level, although both are predictive of advanced disease. Additionally, while early studies identified Breslow thickness >4mm as predictive of aggressive behavior, subsequent studies have shown that a 2mm cutoff more appropriately stratifies low and high-risk lesions.²⁶

Primary tumor (T)*.

Tx	Primary tumor cannot be assessed
T0	No evidence of primary tumor
Tis	Carcinoma in situ
T1	Carcinoma less than 2cm in greatest dimension, with less than 2 high risk features**
T2	Carcinoma greater than 2cm in greatest dimension, Or Tumor of any size with at least 2 high risk features**
T3	Tumor invasion of the maxilla, mandible, orbit, or temporal bone
T4	Tumor invasion of the skeleton (appendicular or axial) or with perineural involvement of the skull base

*Excludes cutaneous squamous cell carcinoma of the eyelid.

**High-risk features for the primary tumor (T) staging: Depth/invasion: >2mm thickness, Clark level \geq IV, Perineural invasion. Anatomic location: Primary site ear, Primary site non-hair-bearing lip. Differentiation: Poorly differentiated or undifferentiated. From the American Joint Committee On Cancer 7th edition "Cutaneous Squamous Cell Carcinoma and Other Cutaneous Carcinomas."

Table 1. Primary Tumor (T) Staging.

Perineural invasion has also been found to be a significant indicator of high-risk disease.^{1,28} Although less commonly identified (only present in 5 percent of non-melanoma cutaneous carcinomas), there is some evidence that perineural invasion is associated with an increase in both the recurrence rate and the metastatic rate by a factor of 5.²⁷ As perineural spread can be difficult to follow histologically and clinically, such tumors can spread much more prior to detection. The diagnosis of perineural invasion carries a generally dismal prognosis, as the 5-year mortality rate approaches 90%.²⁸

The 7th edition AJCC manual chose to include advanced tumor depth/invasion (defined as >2mm in thickness, \geq Clark level IV) among the high-risk features capable of upstaging a T1 neoplasm. Overall, this represents an improvement over previous editions, as it allows for

²⁷Rowe, DE., Carroll, RJ., & Day, CL Jr. (1992). Prognostic factors for local recurrence, metastasis, and survival rates in squamous cell carcinoma of the skin, ear, and lip. Implications for treatment modality selection. *Journal of the American Academy of Dermatology*, Vol. 26, No. 6, (June 1992), pp. 976-990.

²⁸Garcia-Serra, A., Hinerman, RW., Mendenhall, WM., Amdur, RJ., Morris, CG., Williams, LS., & Mancuso, AA. (2003). Carcinoma of the skin with perineural invasion. *Head & Neck*, Vol. 25, No. 12, (December 2003), pp. 1027-1033.

the identification of a subset of lesions that, although small in size, nevertheless are likely to demonstrate aggressive clinical behavior.^{29,30}

The final high-risk feature identified in the 7th edition of the AJCC: Cancer Staging Manual guidelines is the location of the primary tumor on high-risk anatomic sites. This is based on evidence that lesions located on the lip and ear are more aggressive compared to tumors presenting on other locations throughout the body.³¹ These anatomic sites are associated with recurrence and metastatic rates between 10 to 25 percent. Similar to the previously mentioned high-risk variants, recognition of the increased risk associated with these sites. Warner and Cockerell feel that tumors located on the central face and dorsal hands and feet also should be considered high-risk sites.²⁶

Recurrent disease is a high-risk factor worth special discussion. Recurrent or persistent diseases are strong prognostic factors for metastasis.^{3,32} Recurrent or previously treated tumors tend to be more aggressive, less responsive to treatment, and associated with decreased survival (78% 5-year survival compared to 97% for primary lesions).³³ Although rarely performed for Non-Melanoma Cutaneous Carcinoma, the current TNM staging system, denotes recurrent neoplasms with an “r” qualifier prior to TNM-specific designations. For example, a locally recurrent tumor greater than 2cm in size, without evidence of lymph node involvement or metastasis would be staged as: rT2N0M0. As a result, a subset of high-risk lesions is clearly defined as such, and data collection for these tumors can be significantly enhanced. T3 tumors are now classified as those with bony extension to the mandible, maxilla, temple, or orbit whereas the T4 designation is reserved for perineural involvement of the skull base or bony extension to the axial or appendicular skeleton.

Under the 7th edition of the AJCC Cancer Staging Manual guidelines (See table 2), metastasis to a single node less than 3cm in greatest dimension is defined as N1. The N2 designation refers to either a single node 3–6cm in size, or multinodal disease where no individual node is greater than 6cm in size. Based on the specific pattern of nodal involvement, N2 is subcategorized into three separate groupings. Involvement of a single ipsilateral node is categorized as N2a, metastasis to multiple ipsilateral nodes as N2b, and involvement of contralateral or bilateral lymph nodes as N2c. The N3 designation is reserved for any lymph node greater than 6cm in greatest dimension, regardless of number of nodes involved.

²⁹Lardaro, T., Shea, SM., Sarfman, W., Liegeois, N., & Sober, AJ. (2010). Improvements in the staging of cutaneous squamous-cell carcinoma in the 7th edition of the American Joint Committee On Cancer: Cancer Staging Manual. *Annals of Surgical Oncology*, Vol. 17, No. 8, (August 2010), pp. 1979-1980.

³⁰Buethel, D., Warner, C., Miedler, J., & Cockerell, CJ. (2011). Focus Issue on Squamous Cell Carcinoma: Practical Concerns Regarding the 7th Edition American Joint Committee On Cancer: Staging Guidelines. *Journal of Skin Cancer*, Vol. 2011, Article ID 156391, (2011), 9 pages.

³¹Preston, DS. & Stern, RS. (1992). Nonmelanoma cancers of the skin. *The New England Journal of Medicine*, Vol. 327, No. 23, (December 1992), pp. 1649-1662.

³²Rowe, DE., Carroll, RJ., & Day, CL Jr. (1992). Prognostic factors for local recurrence, metastasis, and survival rates in squamous cell carcinoma of the skin, ear, and lip. Implications for treatment modality selection. *Journal of the American Academy of Dermatology*, Vol. 26, No. 6, (June 1992), pp. 976-990.

³³Andruchow, JL., Veness, MJ., Morgan, GJ., Gao, K., Clifford, A., Shannon, KF., Poulsen, M., Kenny, L., Palme, CE., Gullane, P., Morris, C., Mendenhall, WM., Patel, KN., Shah, JP., & O'Brien, CJ. (2006). Implications for clinical staging of metastatic cutaneous squamous carcinoma of the head and neck based on a multicenter study of treatment outcomes. *Cancer*, Vol. 106, No. 5, (March 2006), pp. 1078-1083.

The distant metastasis designation of the 7th edition of the AJCC Cutaneous Squamous Cell Carcinoma staging system is unchanged from previous editions (See table 3). Importantly, there is no provision for classification of lymph node metastasis far removed from regional nodal basins as distant metastasis.²⁶

Regional lymph nodes (N).

Nx	Regional lymph nodes cannot be assessed.
N0	No regional lymph node metastases.
N1	Metastasis in a single ipsilateral lymph node, 3cm or less in greatest dimension.
N2	Metastasis in a single ipsilateral lymph node, more than 3cm but not more than 6cm in greatest dimension; or in multiple ipsilateral lymph nodes, none more than 6cm in greatest dimension; or in bilateral or contralateral lymph nodes, none more than 6cm in greatest dimension.
N2a	Metastasis in a single ipsilateral lymph node, more than 3cm but not more than 6cm in greatest dimension.
N2b	Metastasis in multiple ipsilateral lymph nodes, none more than 6cm in greatest dimension.
N2c	Metastasis in bilateral or contralateral lymph nodes, none more than 6cm in greatest dimension.
N3	Metastasis in a lymph node, more than 6cm in greatest dimension.

Table 2. Regional Lymph Node (N) Staging.

Distant metastasis (M).

M0	No distant metastasis
M1	Distant metastasis

Table 3. Metastasis (M) Staging.

The staging groups offer reasonable stratification of patients based on prognosis (See table 4). Briefly, T1 and T2 tumors are assigned Stage I and Stage II, respectively, Stage III includes all T3 or N1 tumors that do not meet criteria for Stage IV, and the presence of any T4, N2-3, or M1 designation is required for Stage IV classification.²⁷

Anatomic stage/prognostic groups.

Stage 0	Tis	N0	M0
Stage I	T1	N0	M0
Stage II	T2	N0	M0
Stage III	T3	N0	M0
	T1	N1	M0
	T2	N1	M0
	T3	N1	M0
Stage IV	T1	N2	M0
	T2	N2	M0
	T3	N2	M0
	T Any	N3	M0
	T4	N Any	M0
	T Any	N Any	M1

Table 4. Staging Classification.

Cutaneous neoplasms that rarely metastasize, such as BCC, full staging is often unnecessary and perhaps should be mentioned in the staging guidelines as an exception.³³ In other cases, although relevant, full initial evaluation of high-risk features may not be possible, as primary biopsies frequently involve only a small portion of the primary tumor, precluding accurate assessment. Moreover, surgeons and dermatologists need to alter their clinical practice and begin assessing for vertical depth of invasion. Other issues that need to be clarified include the definition of tumors of the lip and the histologic designation of “poorly differentiated” and “undifferentiated” neoplasms.³⁰ However, the incorporation of these factors might be impractical for widespread use in clinical practice.¹

There is a single report of the use of sentinel lymph node biopsy in high-risk lesions.³⁴ This approach would not detect any hematogenous spread, and so its role in the staging of the disease remains to be determined.

5. Treatment

Treatment for non-MBCC can be either surgical or nonsurgical. Surgical excision is generally curative with five-year cure rates of more than 99 percent for primary tumors not involving the head.³⁵ For lesions involving the head, the five-year cure rate is 97 percent for lesions less than 6mm and 92 percent for lesions greater than 6mm. Other surgical options include Mohs micrographic surgery, curettage and electrodesiccation, and cryosurgery. In a Cochrane review of different treatment modalities, one study showed no significant difference between Mohs micrographic surgery and surgical excision in recurrence rates at 30 months for high-risk facial BCCs.³⁶

Non-surgical options include radiotherapy, photodynamic therapy, and topical therapy. In one randomized control trial of surgery versus radiotherapy, surgery provided significantly better cure rates when compared to radiotherapy.³⁶ Radiotherapy has been shown to provide better cure rates when compared to cryosurgery. Imiquimod cream has shown promising early results but long-term data is lacking.³⁶ With un-reviewed information available on the Internet and an un-regulated herbal therapeutic industry, patients will self-treat tumors with anecdotally supported alternative medicine.³⁷ We discourage the use of these forms of treatment, especially within the current culture of practicing evidence-based medicine.³⁸

There are currently no established guidelines for the treatment of metastatic disease specifically because all forms of treatment thus far have provided dismal results in terms of morbidity and mortality. Primary BCC metastasizes usually via lymphatics, although it can also spread hematogenously. Metastasis most commonly occurs in regional lymph nodes,

³⁴Harwood M, Wu H, Tanabe K, et al. Metastatic basal cell carcinoma diagnosed by sentinel lymph node biopsy. *J Am Acad Dermatol* 2005; 3:475-8.

³⁵Silverman, MK., Kopf, AW., Bart, RS., Grin, CM., & Levenstein, MS. (1992). Recurrence rates of treated basal cell carcinomas. Part 3: surgical excision. *The Journal of Dermatologic Surgery and Oncology*, Vol. 18, No. 6, (June 1992), pp. 471-476.

³⁶Bath-Hextall, FJ., Perkins, W., Bong, J., & Williams, HC. (2007). Interventions for basal cell carcinoma of the skin. In: *Cochrane Database of Systematic Reviews*, Issue 1, (January 2007), Art. No.: CD003412.

³⁷Laub, DR Jr. (2008). Death from metastatic basal cell carcinoma: herbal remedy or just unlucky? *Journal of Plastic, Reconstructive, & Aesthetic Surgery*, Vol. 61, No. 7, (July 2008), pp. 846-848.

³⁸McDaniel S, Goldman GD (2002) Consequences of using escharotic agents as primary treatment for nonmelanoma skin cancer. *Archives of Dermatology* Vol. 138, No.12, (December 2002), pp. 1593-6.

lung, and bone although there have been documented cases involving the spinal cord, parotid gland, skin, bone marrow, spleen, liver, adrenal glands, brain, dura mater, esophagus, heart, and kidney. The prognosis for these patients is poor with a mean survival time of only 8 months from the time at diagnosis.⁵ In cases where metastasis is only to lymph nodes, patients live up to an average of 3.6 years.³⁹ There has been one reported case in which a patient lived 25 years after diagnosis.⁴⁰ Median age at the first sign of metastasis is 59 years while the median interval between the onset of the primary tumor and the first sign of metastasis is 9 years.¹³ Systemic chemotherapy has been attempted with mixed results. Combinations of 5-fluorouracil, bleomycin, and methotrexate have been unsuccessful.^{41,42} However, there has been one case with a positive response to cyclophosphamide and cis-diamine dichloroplatinum in a patient with pulmonary metastasis.⁴³ Cisplatin-based therapy has also been shown to be of benefit for patients with metastasis.^{44,45}

Surgical resection is recommended for isolated metastasis, as the results of systemic chemotherapeutic treatment are generally not as promising. Ducic and Mara treated metastatic lesions to the parotid gland with parotidectomy with adjuvant radiation therapy with good results.⁴⁶ Presentation with widely disseminated disease would not allow this approach, however.

It has long been thought that treatment of primary cancers with radiotherapy can contribute to their metastatic potential, although there is no evidence to support this. In fact, the incidence of MBCC in patients treated primarily by radiotherapy is estimated to be 1 in 25,000, which is much less than the incidence of MBCC in all patients with primary tumors.⁴⁷ There have been, however, case reports in which radiotherapy has been found to be beneficial in the treatment of metastatic disease.⁴⁸ In cases where clear surgical margins

³⁹Raszewski, RL. & Guyuron, B. (1990). Long-term survival following nodal metastases from basal cell carcinoma. *Annals of Plastic Surgery*, Vol. 24, No. 2, (February 1990), pp. 170-175.

⁴⁰Lo, JS., Snow, SN., Reizner, GT., Mohs, FE., Larson, PO., & Hruza GJ. (1991). Metastatic basal cell carcinoma: report of twelve cases with a review of the literature. *Journal of the American Academy of Dermatology*, Vol. 24, No. 5.1, (May 1991), pp. 715-719.

⁴¹Costanza, ME., Dayal, Y., Binder, S., Nathanson, L., Safai, B., & Good R.A. (1974). Metastatic basal cell carcinoma: Review, report of a case and chemotherapy. *Cancer*, Vol. 34, No. 1, (July 1974), pp. 230-235.

⁴²Bason, MM., Grant-Kels, JM., & Govil, CT. Metastatic basal cell carcinoma: response to chemotherapy. *Journal of the American Academy of Dermatology*, Vol. 22, No. 5, (May 1990), pp. 905-908.

⁴³Woods, RL. & Steward, JF. (1980). Metastatic basal cell carcinoma: report of a case responding to chemotherapy. *Postgraduate Medical Journal*, Vol. 56, No. 654, (May 1980), pp. 272-273.

⁴⁴Khandekar, J. (1990). Complete response of metastatic basal cell carcinoma to cisplatin chemotherapy: A report on two patients. *Archives of Dermatology*, Vol. 126, No. 12, (December 1990), pp. 1660.

⁴⁵Moeholt, K., Aagaard, H., Pfeiffer, P., & Hansen, O. (1996). Platinum-based cytotoxic therapy in basal cell carcinoma - a review of the literature. *Acta Oncologica*, Vol. 35, No. 6, (January 1996), pp. 677-682.

⁴⁶Ducic Y, Marra DE. Metastatic basal cell carcinoma Am J Otolaryngol. [Epub ahead of print] (October 2010)

⁴⁷Christie, D. The benefit of radiotherapy in metastatic basal cell carcinoma. *Australian and New Zealand Journal of Surgery*, (July 1997), Vol. 67, No. 7, pp. 491-493.

⁴⁸Ozgediz, D., Smith, EB., Zheng, J., Otero, J., Tabatabai, Z., & Corvera, C. (2008). Basal cell carcinoma does metastasize. *Dermatology Online Journal*, Vol. 14, No. 8, August 2008, Article 5.

Available at: http://dermatology-s10.cdlib.org/148/case_reports/bcc/corvera.html

may be difficult to obtain, radiotherapy can offer an advantage of tissue preservation in patients with large lesions through deep tissue penetration.

More recently, a clinical trial with GDC-0449, a small-molecule inhibitor of smoothed homologue (SMO), has shown promising results. SMO is involved in activation of the hedgehog pathway that has been implicated in the development of BCC⁴⁹ and various other cancers.⁵⁰ In a phase 1 trial by Von Hoff et al., GDC-0449 was used to treat 33 patients with locally advanced or MBCC.⁵¹ Of the 15 patients with locally advanced disease, 60% of patients showed a good response. Of the 18 patients with metastatic disease, 50% of patients showed a good response.

The management of patients with suspected metastasis often involves obtaining a CT or MRI scan to look for evidence of occult disease. Recently, a study using FDG-PET has proven to be effective in detecting subclinical disease in a man presenting with multiple primary cutaneous lesions.⁵² While further studies are required, FDG PET may prove to be more effective than both CT and MRI in the radiographic evaluation of suspected metastatic disease.

6. Conclusion

BCC generally follows a very predictable clinical course from the time of diagnosis to subsequent treatment. The standard of care is surgical excision, which provides excellent cure rates. Other methods of treatment include radiotherapy, photodynamic therapy, cryotherapy and topical chemotherapy.

For patients with metastatic disease, morbidity and mortality remains exceedingly high. The biggest risk factors for metastasis are tumor size, depth, and recurrence. Primary tumors arising from the mid face and ears provide a majority of the cases of metastasis but this is also the case for non-metastasizing BCC.

With the exception of platinum-based chemotherapeutic agents, combinations of most other forms of chemotherapy with radiation and/or surgery have not improved mortality rates. It is clear that the development of metastatic potential in BCC, like many cancers, is multi-factorial in etiology. Research aimed at the clinical, histopathologic, and molecular characteristics of metastasis has helped us better understand the risk factors associated with such rare occurrences. As we further our understanding of the pathogenesis behind MBCC, more promising drugs such as GDC-0449 will be developed.

⁴⁹Johnson, R., Rothman, A., Xie, J., Goodrich, L., Bare, J., Bonifas, J., Quinn, A., Myers, R., Cox, D., Epstein, E., & Scott M. (1996). Human homolog of patched, a candidate gene for the basal cell nevus syndrome. *Science*, Vol. 272, No. 5268, (June 1996), pp. 1668-1671.

⁵⁰Katoh, Y. & Katoh, M. (2009). Hedgehog target genes: mechanisms of carcinogenesis induced by aberrant hedgehog signaling activation. *Current Molecular Medicine*, Vol. 9, No. 7, (September 2009), pp. 873-886.

⁵¹Von Hoff, D., LoRusso, PM., Rudin, CM., Reddy, JC., Yauch, RL., Tibes, R., Weiss, GJ., Borad, MJ., Hann, CL., Brahmer, JR., Mackey, HM., Lum, BL., Darbonne, WC., Marsters, JC Jr., de Sauvage, FJ., & Low, JA. (2009). Inhibition of the Hedgehog Pathway in Advanced Basal-Cell Carcinoma. *The New England Journal of Medicine*, Vol. 361, No. 12, (September 2009), pp. 1164-1172.

⁵²Niederkoher, RD. & Gamie, SH. (2007). F-18 FDG PET as an imaging tool for detecting and staging metastatic basal-cell carcinoma. *Clinical Nuclear Medicine*, Vol. 32, No. 6, (June 2007), pp. 491-492.

The incidence of BCC will continue to increase over the years as the baby-boomer generation continues to age. Although the estimated rates of metastasis are low, there will still be a growing number of patients that will need treatment for this presently incurable disease. Physicians need to be aware of the poor prognosis that MBCC carries. Because adequate treatments are not available for metastasis, prevention should be practiced by all providers through vigilant monitoring of suspicious skin lesions and early surgical excision of primary tumor.

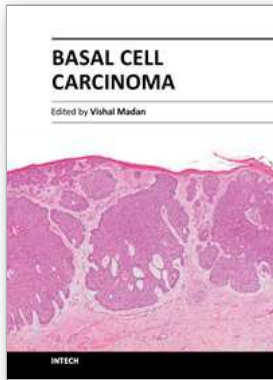
7. References

- Abdelsayed, RA., Guijarro-Rojas, M., Ibrahim, NA., & Sanguenza, OP. (2000). Immunohistochemical evaluation of basal cell carcinoma and trichepithelioma using Bcl-2, Ki67, PCNA and P53. *Journal of Cutaneous Pathology*, Vol. 27, No. 4, (April 2000), pp. 169-175.
- Andruchow, JL., Veness, MJ., Morgan, GJ., Gao, K., Clifford, A., Shannon, KF., Poulsen, M., Kenny, L., Palme, CE., Gullane, P., Morris, C., Mendenhall, WM., Patel, KN., Shah, JP., & O'Brien, CJ. (2006). Implications for clinical staging of metastatic cutaneous squamous carcinoma of the head and neck based on a multicenter study of treatment outcomes. *Cancer*, Vol. 106, No. 5, (March 2006), pp. 1078-1083.
- Bader, RS. (March 2011). Basal Cell Carcinoma, In: *Medscape Reference*, April 2011, Available from: <http://emedicine.medscape.com/article/276624-overview>
- Basal Cell Carcinoma. n.d. In: *Skin Cancer Foundation*, May 2011, Available from: <http://www.skincancer.org/basal-cell-carcinoma.html>
- Bason, MM., Grant-Kels, JM., & Govil, CT. Metastatic basal cell carcinoma: response to chemotherapy. *Journal of the American Academy of Dermatology*, Vol. 22, No. 5, (May 1990), pp. 905-908.
- Bath-Hextall, FJ., Perkins, W., Bong, J., & Williams, HC. (2007). Interventions for basal cell carcinoma of the skin, In: *Cochrane Database of Systematic Reviews*, Issue 1, (January 2007), Art. No.: CD003412.
- Berlin, JM., Warner, MR., & Bailin, PL. (2002). Metastatic basal cell carcinoma presenting as unilateral axillary lymphadenopathy: report of a case and review of the literature. *Dermatologic Surgery*, Vol. 28, No. 11, (November 2002), pp. 1082-1084.
- Buethel, D., Warner, C., Miedler, J., & Cockerell, CJ. (2011). Focus Issue on Squamous Cell Carcinoma: Practical Concerns Regarding the 7th Edition American Joint Committee On Cancer: Staging Guidelines. *Journal of Skin Cancer*, Vol. 2011, Article ID 156391, (2011), 9 pages.
- Christenson, L., Borrowman, T., Vachon, C., Tellefson, M., Otley, C., Weaver, A., & Roenigk, R. (2005). Incidence of basal cell and squamous cell carcinomas in a population younger than 40 years. *Journal of the American Medical Association*, Vol. 294, No. 6, (August 2005), pp. 681-690.
- Christie, D. The benefit of radiotherapy in metastatic basal cell carcinoma. *Australian and New Zealand Journal of Surgery*, (July 1997), Vol. 67, No. 7, pp. 491-493.
- Chuang, TY., Popescu, A., Su, WP., & Chute, CG. (1990). Basal cell carcinoma: a population-based incidence study in Rochester, Minnesota. *Journal of the American Academy of Dermatology*, Vol. 22, No. 3, (March 1990), pp. 413-417.

- Costanza, ME., Dayal, Y., Binder, S., Nathanson, L., Safai, B., & Good R.A. (1974). Metastatic basal cell carcinoma: Review, report of a case and chemotherapy. *Cancer*, Vol. 34, No. 1, (July 1974), pp. 230-235.
- Cotran, RS. (1961). Metastasizing basal cell carcinomas. *Cancer*, Vol. 14., No. 5, (September-October 1961), pp. 1036-1040.
- Ducic Y. & Marra DE. (2010) Metastatic basal cell carcinoma *American Journal of Otolaryngology* [Epub ahead of print] (October 2010)
- Edge, SE., Byrd, DR., Compton, CC., Fritz, AG., Greene, FL., & Trotti, A., (Ed(s)). (2009) *American Joint Committee on Cancer: Cancer Staging Manual, 7th edition*, Springer, 978-0-387-88440-0, New York, NY, USA.
- Garcia-Serra, A., Hinerman, RW., Mendenhall, WM., Amdur, RJ., Morris, CG., Williams, LS., & Mancuso, AA. (2003). Carcinoma of the skin with perineural invasion. *Head & Neck*, Vol. 25, No. 12, (December 2003), pp. 1027-1033.
- Grimwood, RE., Glanz, SM., & Siegle, RJ. (1988). Transplantation of human basal cell carcinoma to C57/Balb/Cbg/bg-nu/nu (nude) mouse. *The Journal of Dermatologic Surgery and Oncology*, Vol. 14, No. 1, (January 1988), pp. 59-62.
- Harwood M, Wu H, Tanabe K & Bercovitch L. (2005). Metastatic basal cell carcinoma diagnosed by sentinel lymph node biopsy. *Journal of the American Academy of Dermatology* Vol. 53, No. 3, (September 2005), pp. 475-8.
- Ionescu, DN., Arida, M., & Jukic, DM. (2006). Metastatic basal cell carcinoma: four case reports, review of literature, and immunohistochemical evaluation. *Archives of Pathology and Laboratory Medicine*, Vol. 130, No. 1, (January 2006), pp. 45-51.
- Johnson, R., Rothman, A., Xie, J., Goodrich, L., Bare, J., Bonifas, J., Quinn, A., Myers, R., Cox, D., Epstein, E., & Scott M. (1996). Human homolog of patched, a candidate gene for the basal cell nevus syndrome. *Science*, Vol. 272, No. 5268, (June 1996), pp. 1668-1671.
- Katoh, Y. & Katoh, M. (2009). Hedgehog target genes: mechanisms of carcinogenesis induced by aberrant hedgehog signaling activation. *Current Molecular Medicine*, Vol. 9, No. 7, (September 2009), pp. 873-886.
- Khandekar, J. (1990). Complete response of metastatic basal cell carcinoma to cisplatin chemotherapy: A report on two patients. *Archives of Dermatology*, Vol. 126, No. 12, (December 1990), pp. 1660.
- Lardaro, T., Shea, SM., Sarfman, W., Liegeois, N., & Sober, AJ. (2010). Improvements in the staging of cutaneous squamous-cell carcinoma in the 7th edition of the American Joint Committee On Cancer: Cancer Staging Manual. *Annals of Surgical Oncology*, Vol. 17, No. 8, (August 2010), pp. 1979-1980.
- Lattes, R., & Kesser, RW. (1951). Metastasizing basal-cell epithelioma of the skin - Report of two cases. *Cancer*, Vol. 4, No. 4, (July 1951), pp. 866-878.
- Laub, DR Jr. (2008). Death from metastatic basal cell carcinoma: herbal remedy or just unlucky? *Journal of Plastic, Reconstructive, & Aesthetic Surgery*, Vol. 61, No. 7, (July 2008), pp. 846-848.
- Lo, JS., Snow, SN., Reizner, GT., Mohs, FE., Larson, PO., & Hruza GJ. (1991). Metastatic basal cell carcinoma: report of twelve cases with a review of the literature. *Journal of the American Academy of Dermatology*, Vol. 24, No. 5.1, (May 1991), pp. 715-719.
- Lyles, TW., Freeman, RG., & Knox, JM. (1960). Transplantation of basal cell epitheliomas. *The Journal of Investigative Dermatology*, Vol. 34, No. 6, (June 1960), pp. 353.

- Malone, JP., Fedok, FG., Belchis, DA., & Maloney, ME. (2000). Basal cell carcinoma metastatic to the parotid: report of a new case and review of the literature. *Ear Nose & Throat Journal*, Vol. 79, No. 7, (July 2000), pp.511-515, 518-519.
- McDaniel S & Goldman GD (2002) Consequences of using escharotic agents as primary treatment for nonmelanoma skin cancer. *Archives of Dermatology* Vol. 138, No.12, (December 2002), pp. 1593-6.
- Miller, DL. & Weinstock, MA. (1994). Nonmelanoma skin cancer in the United States: incidence. *Journal of the American Academy of Dermatology*, Vol. 30, No. 5.1, (May 1994), pp. 774-778.
- Moeholt, K., Aagaard, H., Pfeiffer, P., & Hansen, O. (1996). Platinum-based cytotoxic therapy in basal cell carcinoma - a review of the literature. *Acta Oncologica*, Vol. 35, No. 6, (January 1996), pp. 677-682.
- Nangia, R., Sait, SN., Block, AW., & Zhang, PJ. (2001). Trisomy 6 in basal cell carcinomas correlates with metastatic potential. *Cancer*, Vol. 91, No. 10, (May 2001), pp. 1927-1932.
- Niederkoher, RD. & Gamie, SH. (2007). F-18 FDG PET as an imaging tool for detecting and staging metastatic basal-cell carcinoma. *Clinical Nuclear Medicine*, Vol. 32, No. 6, (June 2007), pp. 491-492.
- Ozgediz, D., Smith, EB., Zheng, J., Otero, J., Tabatabai, Z., & Corvera, C. (2008). Basal cell carcinoma does metastasize. *Dermatology Online Journal*, Vol. 14, No. 8, August 2008, Article 5. Available at: http://dermatology-s10.cdlib.org/148/case_reports/bcc/corvera.html
- Pinkus, H. (1953). Premalignant fibroepithelioma tumors of the skin. *Archives of Dermatology*, Vol. 67, No. 6, (June 1953), pp. 598-615.
- Preston, DS. & Stern, RS. (1992). Nonmelanoma cancers of the skin. *The New England Journal of Medicine*, Vol. 327, No. 23, (December 1992), pp. 1649-1662.
- Quaedvlieg, PJ., Creytens, DH., Epping, GG., Peutz-Kootstra, CJ., Nieman, FH., Thissen, MR., & Krekels, GA. (2006). Histopathological characteristics of metastasizing squamous cell carcinoma of the skin and lips. *Histopathology*, Vol. 49, No. 3, (September 2006), pp. 256-264.
- Randle, HW. (1996). Basal cell carcinoma. Identification and treatment of the high-risk patient. *Dermatologic Surgery*, Vol. 22, No. 3, (March 1996), pp. 255-261.
- Raszewski, RL. & Guyuron, B. (1990). Long-term survival following nodal metastases from basal cell carcinoma. *Annals of Plastic Surgery*, Vol. 24, No. 2, (February 1990), pp. 170-175.
- Robinson, JK. & Dahiya, M. (2003). Basal cell carcinoma with pulmonary and lymph node metastasis causing death. *Archives of Dermatology*, Vol. 139, No. 5, (May 2003), pp. 643-648.
- Rowe, DE., Carroll, RJ., & Day, CL Jr. (1992). Prognostic factors for local recurrence, metastasis, and survival rates in squamous cell carcinoma of the skin, ear, and lip. Implications for treatment modality selection. *Journal of the American Academy of Dermatology*, Vol. 26, No. 6, (June 1992), pp. 976-990.
- Rubin, AL., Chen, EH., & Ratner, D. (2005). Basal-Cell Carcinoma. *New England Journal of Medicine*, Vol. 353, No. 21, (November 2005), pp. 2262-2269.

- Sexton, M., Jones, DB., & Maloney ME. (1990). Histologic pattern analysis of basal cell carcinoma. Study of a series of 1039 consecutive neoplasms. *Journal of the American Academy of Dermatology*, Vol. 23, No. 6.1, (December 1990), pp. 1118-1126.
- Silverman, MK., Kopf, AW., Bart, RS., Grin, CM., & Levenstein, MS. (1992). Recurrence rates of treated basal cell carcinomas. Part 3: surgical excision. *The Journal of Dermatologic Surgery and Oncology*, Vol. 18, No. 6, (June 1992), pp. 471-476.
- Snow, SN., Sahl, W., Lo, JS., Mohs, FE., Warner, T., Dekkinga, JA., & Feyzi, J. (1994). Metastatic basal cell carcinoma. Report of five cases. *Cancer*, Vol. 73, No. 2, (January 1994), pp. 328-335.
- Staibano, S., Lo Muzio, L., Pannone, G., Scalvenzi, M., Salvatore, G., Errico, ME., Fanali, S., De Rosa, G., & Piattelli, A. (2001). Interaction between bcl-2 and P53 in neoplastic progression of basal cell carcinoma of the head and neck. *Anticancer Research*, Vol. 21, No. 6A, (November-December 2001), pp. 3757-3764.
- Van Scott, EJ. & Reinertson, RP. (1961). The modulating influence of the stromal environment on epithelial cells studied in human autotransplants. *The Journal of Investigative Dermatology*, Vol. 36, Issue 2, (February 1961), pp. 109-131.
- von Domarus, H. & Stevens, PJ., (1984). Metastatic basal cell carcinoma. Report of five cases and review of 170 cases in the literature. *Journal of the American Academy of Dermatology*, Vol. 10, No. 6, (June 1984), pp.1043-1060.
- Von Hoff, D., LoRusso, PM., Rudin, CM., Reddy, JC., Yauch, RL., Tibes, R., Weiss, GJ., Borad, MJ., Hann, CL., Brahmer, JR., Mackey, HM., Lum, BL., Darbonne, WC., Marsters, JC Jr., de Sauvage, FJ., & Low, JA. (2009). Inhibition of the Hedgehog Pathway in Advanced Basal-Cell Carcinoma. *The New England Journal of Medicine*, Vol. 361, No. 12, (September 2009), pp. 1164-1172.
- Wadhera, A., Fazio, M., Bricca, G., & Stanton, O. (2006). Metastatic basal cell carcinoma: A case report and literature review. How accurate is our incidence data? *Dermatology Online Journal*, Vol. 12, No. 5, (September 2006), pp. 7.
- Warner, CL & Cockerell, CJ. (2011). The new 7th edition American Joint Committee On Cancer staging of cutaneous non-melanoma skin cancer: a critical review. *American Journal of Clinical Dermatology*, Vol. 12, No. 3, (June 2011), pp. 147-154.
- Woods, RL. & Steward, JF. (1980). Metastatic basal cell carcinoma: report of a case responding to chemotherapy. *Postgraduate Medical Journal*, Vol. 56, No. 654, (May 1980), pp. 272-273.



Basal Cell Carcinoma

Edited by Dr. Vishal Madan

ISBN 978-953-51-0309-7

Hard cover, 126 pages

Publisher InTech

Published online 14, March, 2012

Published in print edition March, 2012

Basal cell carcinoma is the commonest cutaneous malignancy. The last decade has witnessed exponential research which has broadened our understanding of the pathogenesis of basal cell carcinomas. This is also important from a therapeutic point of view as targeted approach to therapy is now being increasingly experimented. Although it is impossible to condense and present all good research in one book, the authors have to be commended on presenting their research on several aspects of basal cell carcinoma in a succinct manner, which shall not only enhance our understanding of, but also hopefully via this open exchange of ideas pave ways for successful targeted therapy of the commonest human cancer.

How to reference

In order to correctly reference this scholarly work, feel free to copy and paste the following:

Anthony Vu and Donald Jr. Laub (2012). Metastatic Basal Cell Carcinoma, Basal Cell Carcinoma, Dr. Vishal Madan (Ed.), ISBN: 978-953-51-0309-7, InTech, Available from: <http://www.intechopen.com/books/basal-cell-carcinoma/metastatic-basal-cell-carcinoma>

INTECH

open science | open minds

InTech Europe

University Campus STeP Ri
Slavka Krautzeka 83/A
51000 Rijeka, Croatia
Phone: +385 (51) 770 447
Fax: +385 (51) 686 166
www.intechopen.com

InTech China

Unit 405, Office Block, Hotel Equatorial Shanghai
No.65, Yan An Road (West), Shanghai, 200040, China
中国上海市延安西路65号上海国际贵都大饭店办公楼405单元
Phone: +86-21-62489820
Fax: +86-21-62489821

© 2012 The Author(s). Licensee IntechOpen. This is an open access article distributed under the terms of the [Creative Commons Attribution 3.0 License](#), which permits unrestricted use, distribution, and reproduction in any medium, provided the original work is properly cited.