

# Radiologic Features of Triple Negative Breast Cancer

Yasuyuki Kojima, Reika In and Hiroko Tsunoda  
*Division of Breast and Endocrine Surgery, Department of Surgery,  
St. Marianna University School of Medicine  
Department of Radiology, St. Luke's International Hospital  
Japan*

## 1. Introduction

Triple negative (TN) breast cancer is defined as cancer with negative expressions of hormone receptors and human epidermal growth factor receptor 2 (HER2). This subtype is characterized as a cancer with a high malignancy potential and a poor prognosis. Endocrine therapy and anti-HER2 therapy are ineffective in the treatment of TN breast cancer as they have less specific targets compared with other subtypes of breast cancer. At present, chemotherapy is the only option to treat this type of cancer. This subtype is found in approximately 15.5% of all breast cancer cases in Japan (Iwase et al., 2010). The percentage of other subtypes are as follows; Luminal A (hormone receptors positive and HER2 negative), 69.0%; Luminal B (hormone receptors positive and HER2 positive), 7.3% and HER2-enriched (hormone receptor negative and HER2 positive), 8.2%. Some reports described a subtype of DCIS that correlates to the progression to invasive carcinoma; comedo type DCIS progresses to invasive carcinoma, both more often and more rapidly than low-grade DCIS (Pinder SE & Ellis IO, 2003; Ketcham AS & Moffat FL, 1990). This may be a reason for the rarity of TN DCIS. The incidence of TN DCIS accounts for less than 5% of DCIS. If this is true, early detection of this particularly aggressive type of breast cancer is vital. (Moriya et al, 2010) There have been reports claiming that TN IDC occurs from ER negative, HER2 positive DCIS lesion and loses its HER2 expression when it progresses to an invasive cancer, which may indicate a precursor process is at work (Bradley BB et al., 2006; Livasy CA et al., 2007; Flora Z et al., 2007). To clarify these hypotheses, comparison between TN IDC and TN DCIS is also essential. There are no other reports that we were able to find that focus specifically on TN DCIS. We cannot predict the outcome of TN DCIS, if it is not diagnosed and treated, because this has not been researched nor documented (Page DL et al., 1995; Page DL et al., 1982; Betsill WLJ et al., 1978). We reviewed another report on a series of cases in which DCIS was not completely excised. The findings from those reports indicate that a more frequent and rapid progression from DCIS to invasive cancer is related to the comedo subtype of DCIS, which is comparable to low-grade DCIS (Pinder SE & Ellis IO, 2003; Simpson JF, 2009). We need to investigate the specific features of this subtype, and we need to determine the radiological and pathological features of TN breast cancer via retrospective evaluation in a large population, in order to make a more precise diagnosis.

## 2. Patients and methods

TN breast cancer cases were studied by conducting chart reviews between January 2007 and January 2011 to assess mammogram (MMG), ultrasound (US), magnetic resonance imaging (MRI), methods of detection, and pathology findings. Routine diagnostic breast mammography, ultrasound, and MRI were performed before surgeries in our hospital.

### 2.1 Mammography

For each patient, mammograms with mediolateral oblique and craniocaudal view were carried out. In all cases, mammograms were retrospectively reviewed by two breast radiologists, and classified as focal asymmetric density (FAD), masses, calcifications, or architectural distortion, according to the Japanese mammography guidelines (The Committee of Mammography Guideline, 2010). Margins of masses were reviewed for being circumscribed, microlobulated, indistinct, and speculated. Mammography was performed by using Senographe 800T and Senographe DMR units from GE (films, MIN-R EV; screen, EV150) till August 2008. In August 2008, digital mammography with the Selenia from Hitachi was introduced.

### 2.2 Ultrasound

Each patient underwent whole-breast US which was performed and diagnosed by one of two radiologists, specialized in breast imaging. The ultrasound findings were classified as masses, low echoic area, distortions, and calcifications. Noted features included shapes (oval, lobulated, polygonal, or irregular), patterns of the internal echoes (hypoechoic, isoechoic, or hyperechoic), the posterior echoes (accentuating, no change, or attenuating), vascularity (avascular, spotty signals, hypovascular, hypervascular) and elasticity scores (1-5; scores defined as previously reported (Itoh A et al., 2006)).

For patients, ultrasound was performed by using 10 MHz linear-array transducers (LOGIQ 7 system, GE) and 12 MHz linear-array transducers (HDI 5000, Philips) until September 2007, and from October 2007, 12 MHz linear-array transducers (SSA 790A, Toshiba Medical Systems) and 14 MHz linear-array transducers (EUB 7500, Hitachi Medical) were used. All elasticity images were obtained by using EUB 7500.

### 2.3 Magnetic resonance imaging

The equipment used for MRI was a Signa Excite HD ver. 12 (1.5 Tesla) from GE with 4- or 8-channel breast coil. The protocol was as follows: fat-suppressed T1WI, sagittal (pre-and post-enhancement) fast SPGR: TR/TE 6.5/1.5, FA 15°, FOV 16 cm, matrix 256 9 192, slice thickness 2 mm, scan time 2 min 10 s; fat-suppressed T2WI, sagittal FSE: TR/TE; 3,000/85, FOV 16 cm, matrix 256 9 224, slice thickness 5 mm, gap 1 mm, scan time 2 min 24 s; and delayed axial scan with VIBRANT: TR/TE 6.4/3.0, FOV 34 cm, matrix 350 9 350, slice thickness 1.2 mm, ASSET 2.0, scan time 2 min 40 s.

### 2.4 Pathological findings

All resected specimens were diagnosed by whole sectioning. Hematoxylin-eosin staining was performed in formalin-fixed, paraffin-embedded material for pathological diagnosis.

Immunohistochemistry of estrogen receptor (ER), progesterone receptor (PgR), and HER2 were evaluated. The assessments of ER and PgR were done using Allred score, and the HER2 status was graded as 0, 1+, 2+, and 3+. HER2 score 3+ was defined as positive, and 2+ was checked by fluorescence in situ hybridization for its positivity. Five cases were eliminated, because the postoperative hormonal status turned out to be positive. In this cohort, 61 patients underwent neoadjuvant chemotherapy.

### 3. Results

Our cohort included 2,868 operations performed for primary breast cancer diagnosed in our institute between January 2007 and January 2011. Table 1 shows the characteristics of all triple-negative cases. Women with triple-negative invasive breast cancer were likely to have histologically higher-grade tumors compared to ductal carcinoma in situ.

Age	56.3 (26-91)
Ductal carcinoma in situ	n=20
Size (cm)	2.9 (0.5-6.6)
Nuclear grade	
1	14
2	3
3	3
Invasive cancer	n=101
Size (cm)	2.6 (0.7-6.0)
Nuclear grade	
1	21
2	26
3	54

Table 1. Characteristics of TN breast cancer patients (n=121).

#### 3.1 DCIS

Our cohort included 657 DCIS patients, who were diagnosed and treated in our institute between January 2007 and January 2011. Among all 657 DCIS cases, 20 cases (3.0%) were ER-negative, PgR-negative, and HER2-negative. Ages in this group ranged from 40 to 73 years old, with an average age of 55.8. In 12 cases, patients underwent partial resection, and in 8 cases, patients underwent total mastectomy. DCIS was confirmed in all patients by whole sectioning of the resected specimens.

The radiology and pathology findings are shown in Table 2. Mammographic findings of TN DCIS were as follows: there were no abnormal findings in six cases, masses were revealed in two cases, FAD was detected in three cases, and architectural distortion was noted in five cases. However, calcifications, which have been considered as typical radiological findings in DCIS, were observed in only four cases (20.0%) out of our TN DCIS (Tables 2, 3). US findings were as follows: low echoic masses were noted in 7 cases, low echoic areas were noted in 14 cases, architectural distortion was noted in four cases. MRI findings revealed typical DCIS findings, including 7 masses and 12 non-mass-like enhancements (one patient did not undergo MRI). The average lesion size measured 2.9 cm in diameter (with a range of

0.5–8.5 cm). Fourteen cases were classified as nuclear grade (NG) 1, three cases were classified as NG2, and three cases were classified as NG3. Histological findings confirmed non-comedo type in 9 cases; mixed types, including some comedo components, were found in 8 cases; comedo type in 3 cases. In seven cases, apocrine metaplasia was observed, and in seven cases we noted a remarkable sclerosing adenosis in the background breast tissue areas of DCIS.

case	MMG	US	MRI	NG	Type of DCIS
1	mass	low echoic mass	Non-mass like, segmental clumped enhancement	1	mixed
2	distortion	low echoic area, distortion	Non-mass like, ductal enhancement	1	non-comedo, SA
3	distortion	low echoic mass	Non-mass like, segmental homogenous enhancement	1	non-comedo, SA
4	no findings	low echoic mass	Mass	1	non-comedo, apocrine metaplasia
5	no findings	low echoic area	Mass	1	mixed
6	no findings	low echoic area	Non-mass like, segmental homogenous enhancement	3	mixed
7	mass	low echoic mass	Not performed	1	comedo
8	no findings	low echoic area	Non-mass like, segmental clumped enhancement	2	mixed, apocrine metaplasia
9	FAD	low echoic area, distortion	Non-mass like, segmental clumped enhancement	1	non-comedo, SA
10	calcifications	low echoic area	Mass, foci	3	mixed
11	distortion	low echoic mass	Non-mass like, segmental heterogenous enhancement	1	non-comedo, SA, apocrine metaplasia
12	distortion	low echoic area, distortion	Mass	1	non-comedo, SA, apocrine metaplasia
13	calcifications	low echoic area	Non-mass like, segmental heterogenous enhancement	2	mixed
14	FAD	low echoic area	Non-mass like, segmental heterogenous enhancement	1	mixed
15	FAD	low echoic mass	Mass	2	mixed
16	no findings	low echoic area	Non-mass like, segmental heterogenous enhancement	1	non-comedo, apocrine metaplasia
17	calcifications	low echoic area	Non-mass like, segmental clumped enhancement	3	comedo
18	calcifications	low echoic area	Mass	1	comedo
19	no findings	low echoic area	Non-mass like, segmental heterogenous enhancement	1	non-comedo, SA, apocrine metaplasia
20	distortion	low echoic mass	Mass	1	comedo, SA, apocrine metaplasia

Table 2. Radiology and pathology findings of TN DCIS cases.

Findings	Number (%)
Calcifications	4 (20)
Mass	2 (10)
Focal asymmetric density	3 (15)
Architectural distortion	5 (25)
No abnormal findings	6 (30)

Table 3. Mammogram findings of triple negative ductal carcinoma in situ.

Representative cases are shown in Figs. 1 and 2. In the first case, the MMG revealed an architectural distortion in the right breast. Spot view revealed no abnormal calcifications. US revealed an irregularly shaped low echogenic area with architectural distortion. The MRI revealed a non-mass like, segmental heterogeneous enhancement. The pathological findings confirmed non-comedo DCIS, with sclerosing adenosis and apocrine metaplasia.

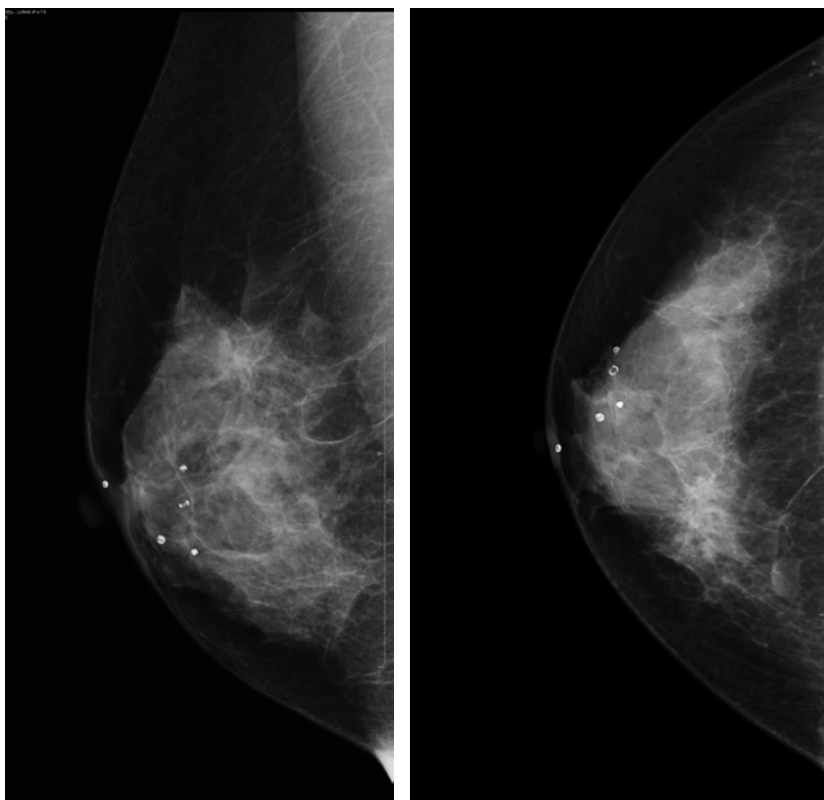


Fig. 1.1. A first representative case of DCIS, mammography of the right breast.

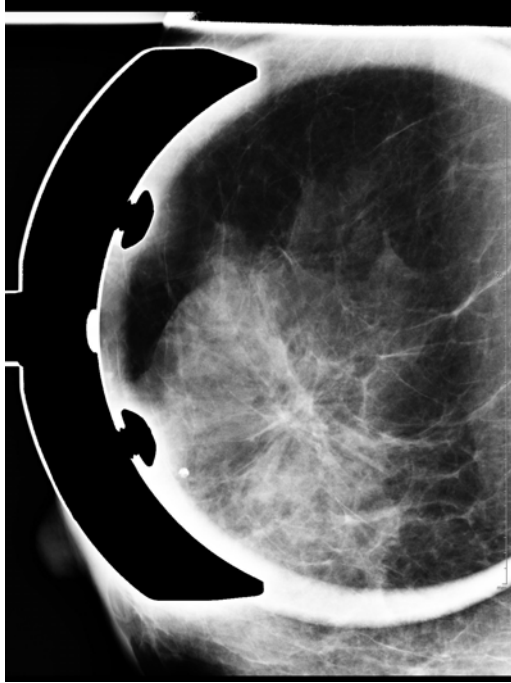


Fig. 1.2. A first representative case of DCIS, mammography with spot view.

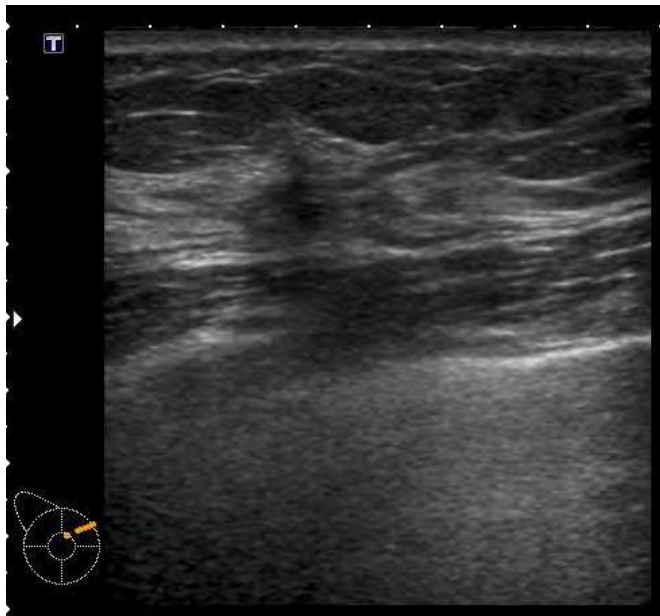


Fig. 1.3. A first representative case of DCIS, Ultrasound.

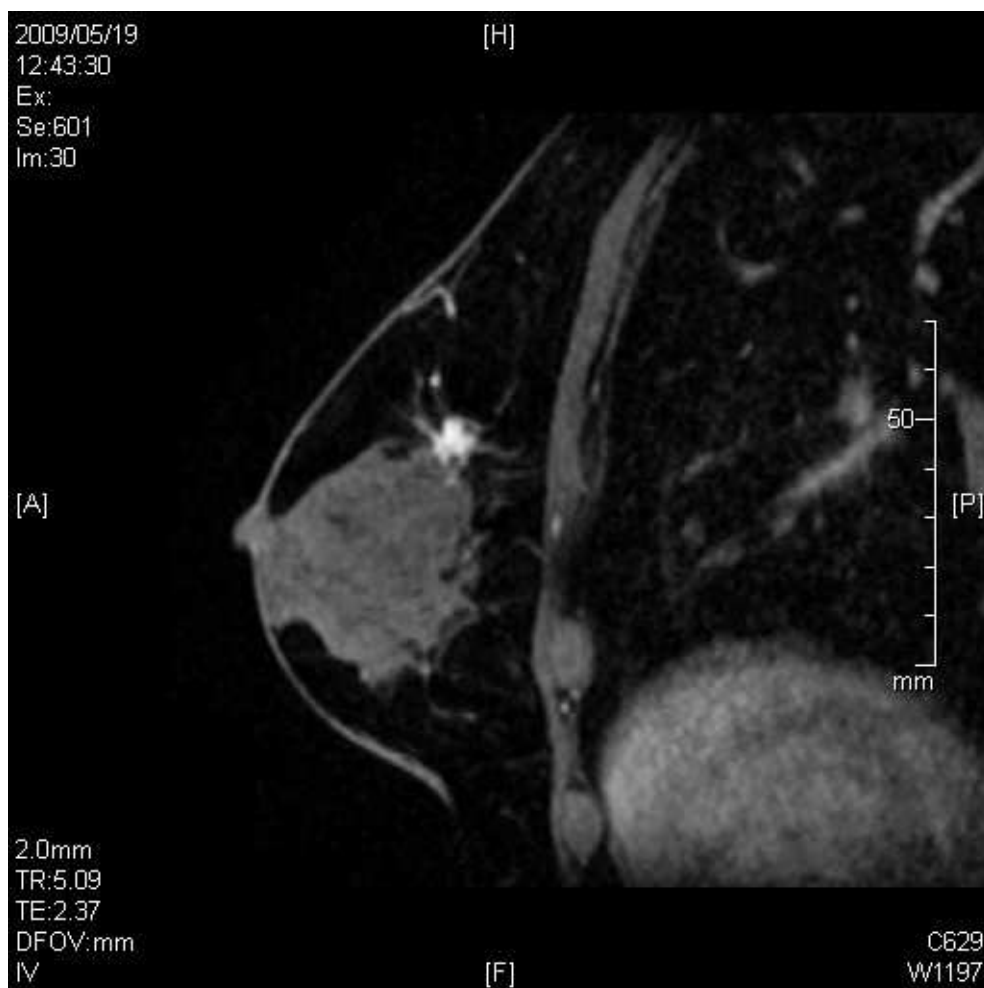

Fig. 1.4. A first representative case of DCIS, MRI.

In the second case, MMG revealed a focal asymmetric density with architectural distortion in the right breast. US revealed an irregularly shaped low echoic mass. The MRI revealed a segmental enhancement with an architectural distortion. Pathological diagnosis confirmed DCIS with sclerosing adenosis.

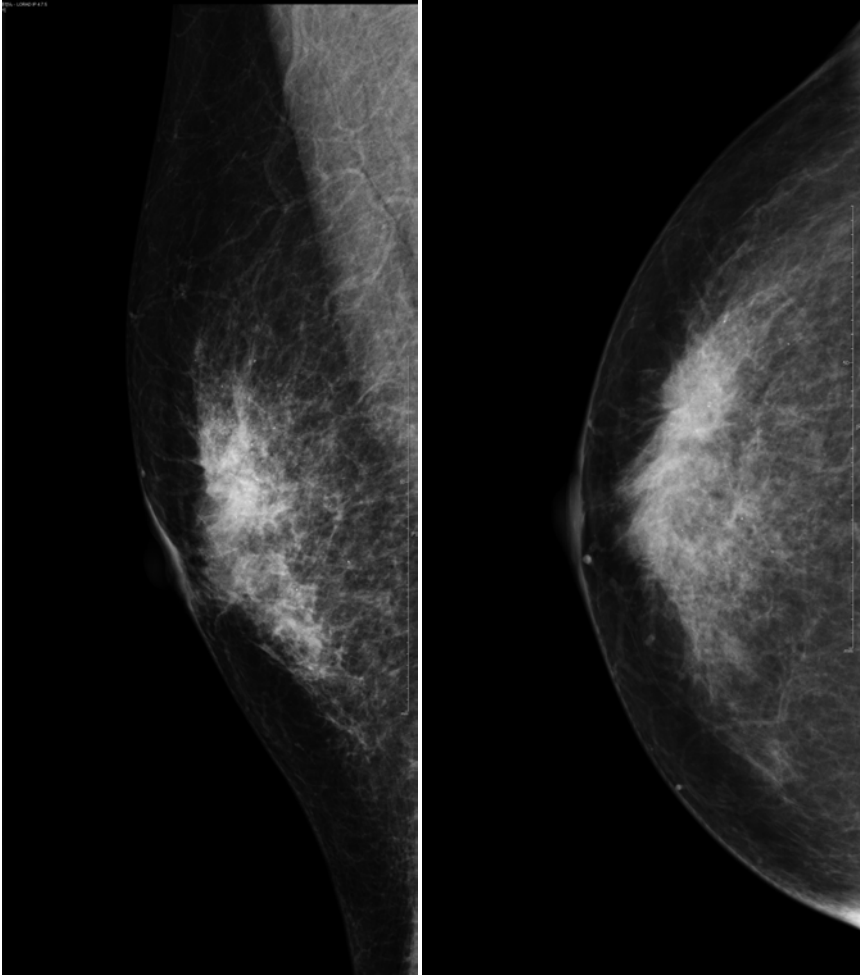


Fig. 2.1. A second representative case of DCIS, mammography of the right breast.



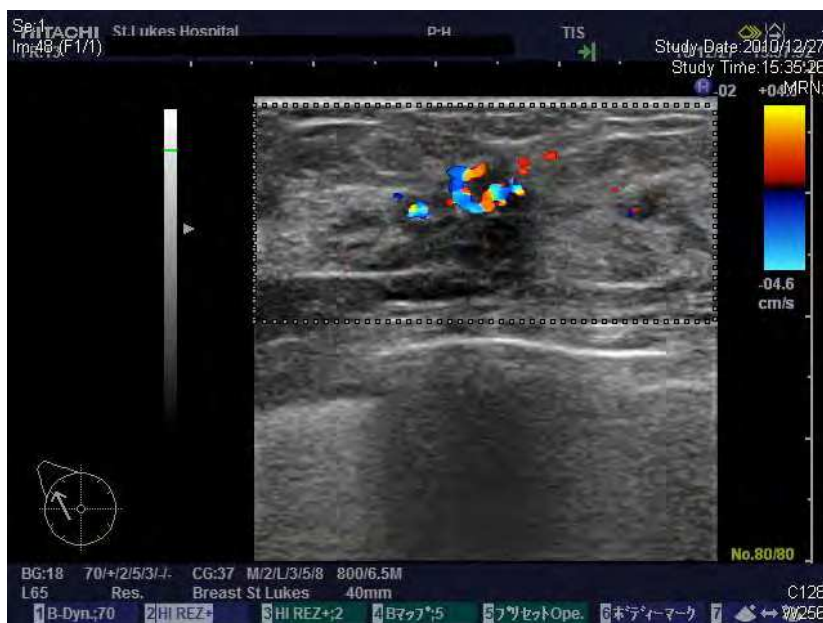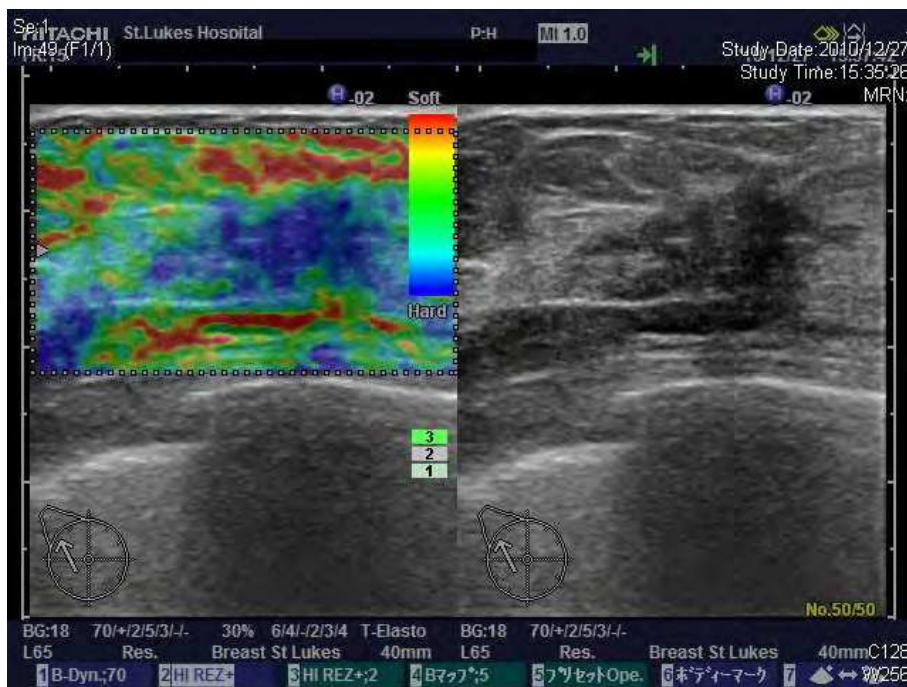


Fig. 2.2. A second representative case of DCIS, Ultrasound; elastography (above) and collar Doppler view (below).

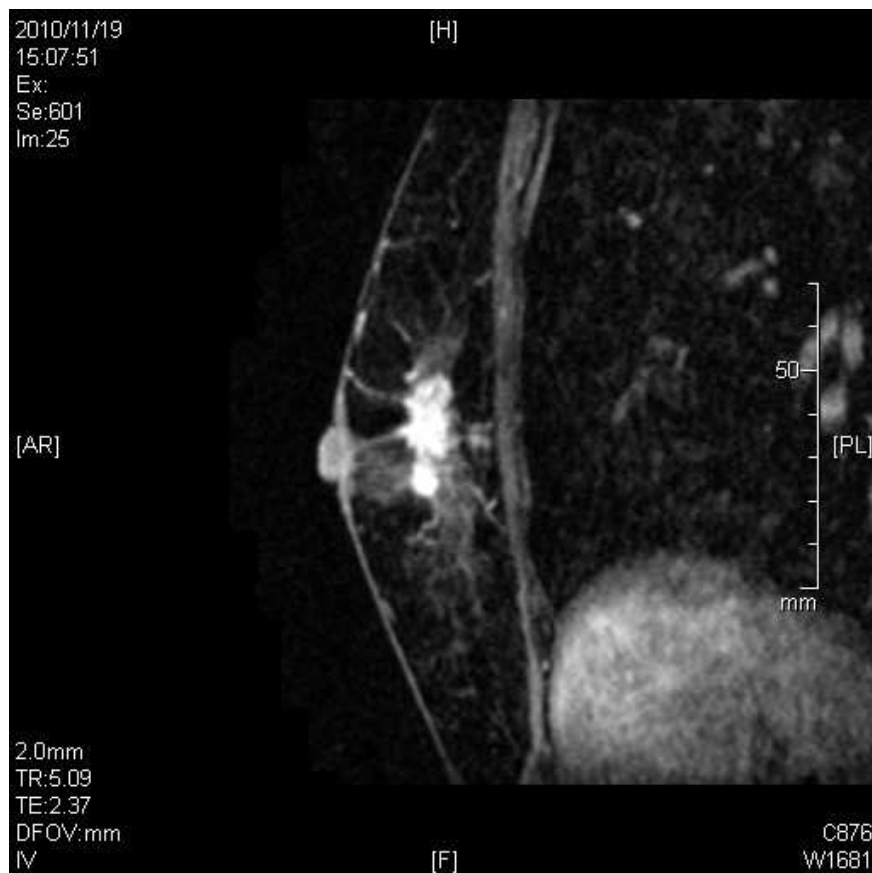

Fig. 2.3. A second representative case of DCIS, MRI.

### 3.2 IDC

Table 4 shows the radiological findings of TN invasive cancer in our study. On mammography, in almost all patients scattered fibroglandular (44/100, 44%) to heterogeneous (46/100, 46%) breast density was noted. Triple-negative breast cancers frequently presented with a mass (63/100, 63%) and were less associated with focal asymmetric density (13/100, 13%), calcifications (10/100, 10%), and distortion (5/100, 5%). Margins of masses were assessed. Masses with microlobulated margins were the most frequent (26/63, 41.3%), indistinct margins (19/63, 30.2%) and circumscribed margins (12/63, 19.0%) were commonly observed, but spiculated margins were rare (6/63, 9.5%).

On ultrasound, cancers were less frequently observed as non-mass lesions (7/97, 7.2%), and were more likely to present as a mass (90/97, 92.8%); these were lobulated (42/90, 46.7%), irregular (17/90, 18.9%), or oval (24/90, 26.7%) in shape, and less likely to show attenuating posterior echoes (8/97, 8.2%). Of the 42 cases obtained via elasticity imaging, 35 (83.3%) lesions were scored as 4 or 5.

Mammography	n=100	Ultrasound	n=97
Density		Findings	
Predominant fatty	6	Mass	90
Scattered fibroglandular	44	Non-mass like	7
Heterogeneously dense	46	Architectural distortion	0
Dense	4	Calcifications	0
Findings		Shape of mass	n=90
No abnormal findings	10	Oval	24
Focal asymmetric density	13	Lobulated	42
Mass	63	Irregular shape	17
Calcifications	10	Indistinct	7
Architectural distortion	5		
		Posterior echoes	
Border of mass	n=63	Accentuating	43
Circumscribed	12	No change	46
Microlobulated	26	Attenuating	8
Indistinct	19		
Spiculated	6	Vascularity	
		Avascular	7
		Spotty signals	32
		Hypovascular	38
		Hypervascular	14
		Elasticity score	n=42
		1~3	7
		4, 5	35

Table 4. Mammography and ultrasound findings for triple negative breast cancer patients

Representative cases are shown in Figs. 3 and 4. On the mammogram of the first case, there were scattered fibroglandular elements in both breasts. There was a 2.3 cm oval high density mass with circumscribed margin in the left breast in the posterior depth of the superior region seen on the mediolateral oblique view which likely represents expansively growing tumor. On the ultrasound, there was an oval mass with circumscribed margin in the inner upper quadrant of the left breast. The tumor size was approximately 2.0 cm, slight spotty vasculature was seen at the edge of the tumor, and poor elasticity via elastography (elasticity score 4). MRI also showed an oval enhanced mass with circumscribed margin. The pathological findings confirmed invasive ductal carcinoma, nuclear grade 3, with fat invasion and lymphovascular invasion.

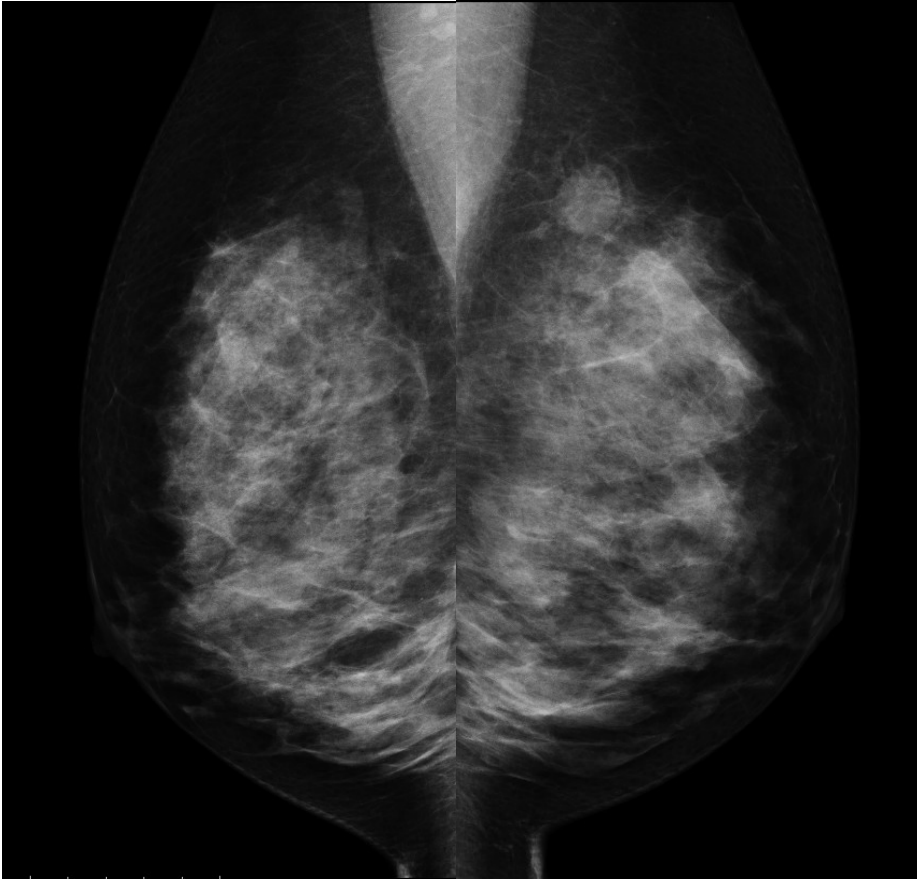


Fig. 3.1. A first representative case of IDC, mammography.

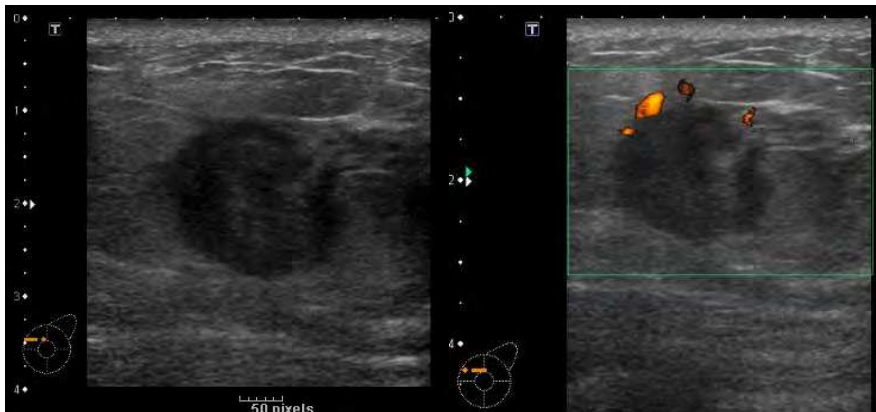


Fig. 3.2. A first representative case of IDC, Ultrasound; B-mode and power Doppler.

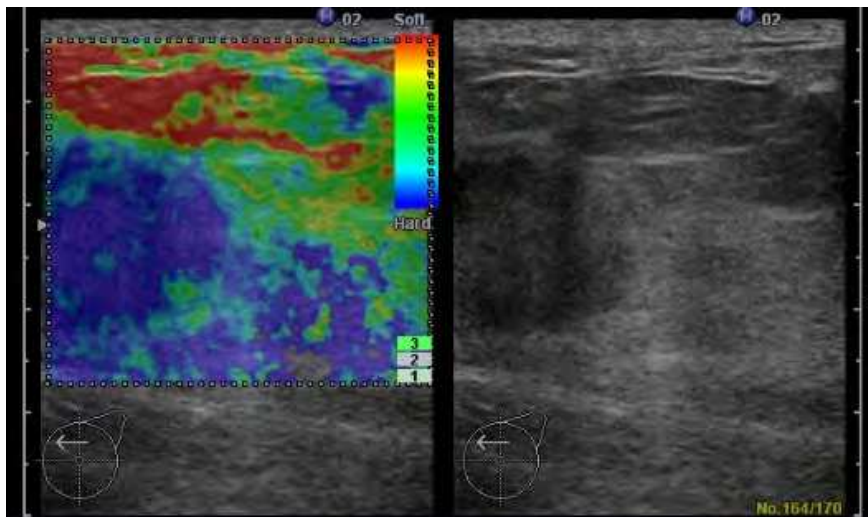


Fig. 3.3. A first representative case of IDC, Ultrasound; elastography.

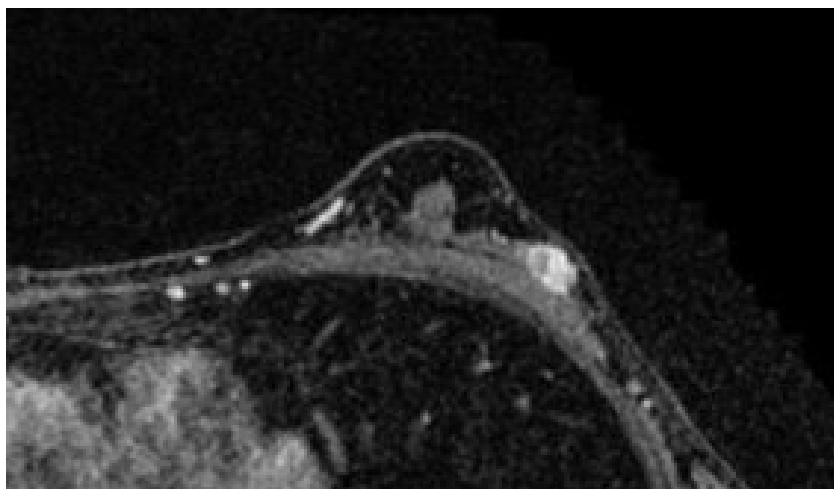


Fig. 3.4. A first representative case of IDC, MRI.

On the second case, mammogram revealed scattered fibroglandular elements in both breasts. There was an oval high density mass with microlobulated margins in the posterior depth of the superior region seen on the mediolateral oblique view of the right breast. The tumor sizes was 1.8 cm in diameter. On the ultrasound, there was a lobulated mass with circumscribed margin in the outer upper quadrant of the right breast. The mass showed mosaic pattern vasculature indicating hypervascularity of the tumor, and poor elasticity via elastography (elasticity score 4). MRI showed a circumscribed enhanced mass in the upper portion of the right breast. Pathological findings revealed invasive ductal cancer, nuclear grade 2.

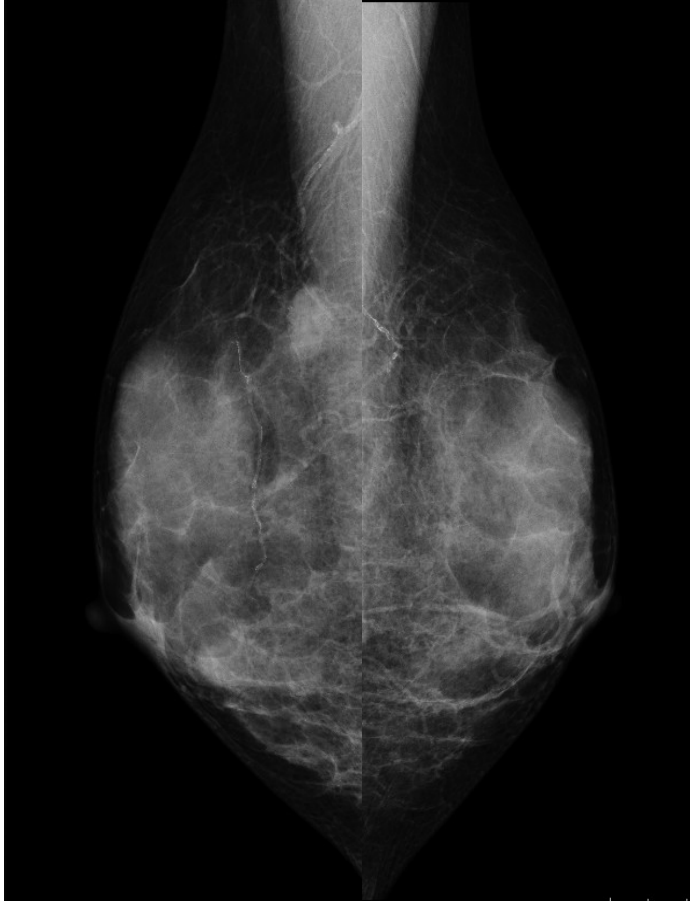

Fig. 4.1. A second representative case of IDC, mammography.

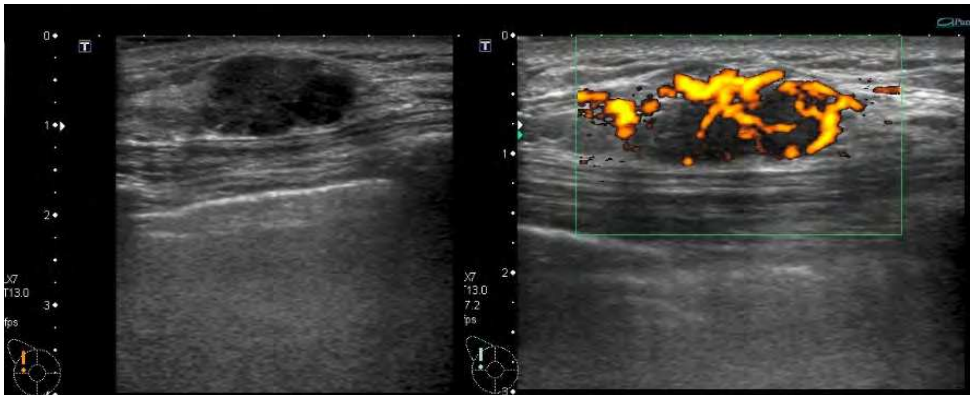


Fig. 4.2. A second representative case of IDC, Ultrasound; B-mode and power Doppler view.

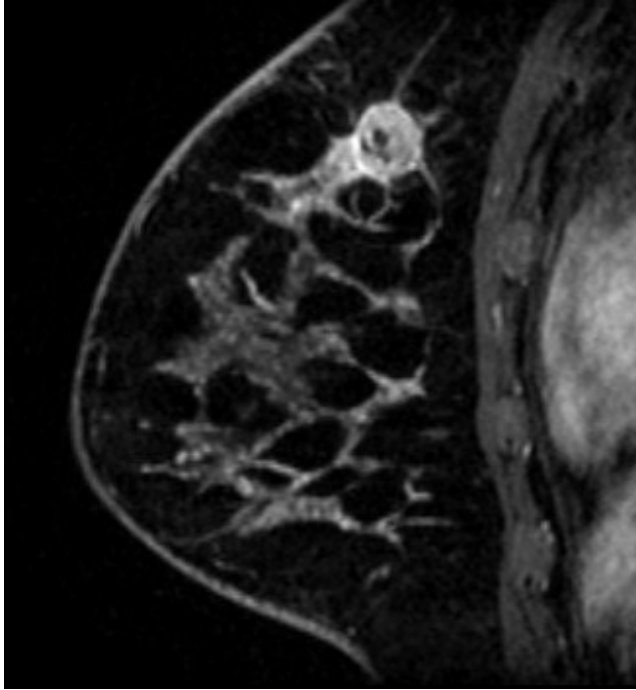


Fig. 4.3. A second representative case of IDC, MRI.

#### 4. Discussion

There are a few reports describing mammography and ultrasound findings of triple-negative breast cancers (Ko ES et al., 2010; Wang Y et al., 2008; Yang WT et al., 2008). In those studies, comparisons were made between the mammography and ultrasound findings of hormone receptor negative, HER2-negative cancers with hormone receptor positive, HER2-negative cancers and hormone receptors negative, HER2-positive cancers. The radiological features of TN breast cancers included in our study were similar to the features described above. According to the Japanese data, hormone receptor positive breast cancer, such as luminal A or B, less likely to be found as a mass with pushing border compared to triple negative type cancers (Iwase H et al., 2010). Additionally, a few researchers have stated that triple-negative cancer is less frequently associated with calcifications, compared to the other subtypes. Collett et al. (Collett K et al., 2005) evaluated interval cancers diagnosed in a screening program between 1996 and 2001 and found that TN breast cancers were more likely than non-TN breast cancers to present in the interval between regular mammograms. The radiological features of TN breast cancer would give an answer to this.

Wang et al. showed that triple-negative cancers are less likely to be associated with spiculated margins on mammography than estrogen receptor-negative human epidermal growth factor receptor-positive cancers are. In their series of 23 TN breast cancers, 9% were mammographically occult and only 23% had associated calcifications. (Wang Y et al., 2008).

Dent et al determined that TN breast cancers had a much lower proportion of breast cancers first detected by mammography or ultrasound than patients with other breast cancers (19.6% versus 36.0%) (Dent R et al., 2007).

Dogan et al reported that TN breast cancer features include; triple negative cancers were mammographically occult in 9% and sonographically occult in 7% of the patients (Dogan BE et al, 2010). When they could be visualized, the TN breast cancers had benign or indeterminate mammographic and sonographic findings, such as focal asymmetry (21%) and circumscribed round or oval masses (15.8%), despite their large size. Only three cases (6.8%) were identified as calcifications alone on mammography. Triple negative breast cancer is less likely to be detected in the routine screening using mammography alone. In contrast, all the cancers were visualized on MRI and showed characteristic findings associated with malignancy, as defined by the BI-RADS criteria. The most frequent MRI finding was a round or oval contrast-enhanced mass with irregular or spiculated margins and rim enhancements, (Schnall MD et al., 2006) and the characteristic shape is a common mammographic and ultrasound finding. Jinguji et al., who previously suggested an association of poor prognostic factors, such as nodal status, blood vessel invasion, and hormone receptor negativity, with rim enhancement on MRI, which are also some of the clinicopathological features of TN breast cancer. (Jinguji M et al., 2006)

Uematsu et al. suggested frequent association of rim enhancements and smooth mass margins on their series of TN breast cancers. (Uematsu T et al., 2009)

There are many reports describing the characteristic findings of MRI, although there are few describing those findings of mammogram or ultrasound.

In our study, we determined the radiological characteristics, which were often observed as a mass (65%) on mammography. In the ultrasound findings, we noted that TN breast cancers were more likely to be seen as mass lesions (71%), with oval or lobulated shapes, and hypo-echoic masses. Posterior echoes were less likely to attenuate, and vascularity was identified to some extent. From a previous report (Itoh A et al., 2006), the sensitivity, specificity, and accuracy of elastography were 83.3, 86.7, and 85.2%, respectively, with a cutoff score of between 3 and 4. Among the patients who were able to have elastography, TN breast cancer appeared as hard masses, with elasticity scores of 4 or 5. These findings represent TN tumor characteristics including high cellularity, less fibrous mass, and an elasticity score as high as ordinary invasive ductal carcinoma.

Our study showed that only 20% (4/20) of TN DCIS were detected because of mammographic abnormal calcifications. To gain a better understanding of the character of this rare type of DCIS, we retrospectively reviewed the charts and reports of each case.

Ordinarily, DCIS was first described a century ago by Dr. Joseph Bloodgood, but its natural history is poorly understood. In a large population-based surveillance, epidemiology, and end results series, Ernster et al. (Ernster VL et al., 2000) reported a 10-year mortality risk of DCIS of only 1.9%. Therefore, early detection is essential for improving the prognosis of breast cancer. The prognosis of TN invasive cancer is considered to be poor. If TN DCIS is a precursor of TN invasive carcinoma, detection of TN DCIS is attributed to appropriate treatment of the cases that may become TN invasive carcinoma.



DCIS was detected because of breast lumps or an abnormal discharge from the nipple. Through wider usage of MMG, and the development of radiological detection technologies capable of identifying breast abnormalities long before they become palpable, the frequency of DCIS detection has increased (Frykberg ER, 1997; Schnitt SJ et al., 1988; Dershaw DD, 1989; Stomper PC, 1989; Ikeda DM & Anderson I, 1989). Historically, most cases of DCIS (72–80%) have been diagnosed by MMG. This is mainly because of abnormal calcifications, such as necrotic calcifications representing dead tumor cells or secretory calcifications in tumor nests. Only 10–12% of DCIS cases have been discovered because of masses without calcifications revealed by MMG.

Abnormal calcifications are seen in approximately 62% (Ikeda DM & Andersson I, 1989) to 72% of common DCIS cases (Kopans DB, 1998). The percentage in TN DCIS cases of abnormal calcifications is considerably lower than in common DCIS cases.

In our cohort, the percentage of TN DCIS was only 3.0% of all DCIS. This percentage is much less than that of TN cancer rate in IDC cases.

When we investigated the reason why TN DCIS is so rare, we were able to identify a few possibilities. TN DCIS may grow rapidly in a short time span, which makes it difficult to detect during its noninvasive term. This is one possibility that TN cancers were reported more likely to present in the interval between regular mammograms. TN invasive carcinoma is known to have rapid growth characteristics and has a poor prognosis. On the basis of pathology and molecular studies, some DCIS represents a precursor to invasive breast cancer; however, the proportion of untreated DCIS that will progress to invasive breast cancer is uncertain (Bradley BB et al., 2006; Livasy CA, 2007; Flora Z, 2007). Ko et al. suggest that triple-negative breast cancer may develop rapidly to an invasive stage with no major *in situ* components or to a precancerous stage; hence, such tumors lack calcifications on mammography (Ko ES et al., 2010). Moriya et al. reported the incidence of TN DCIS among DCIS as being less than 5% (Moriya T et al., 2010). They also think it is possible that TN DCIS transforms to invasive cancer in its early stage, not remaining preinvasive DCIS. However, the presence of precursor lesions of TN breast cancer has not been clarified, and its origin and development remain to be investigated.

In our study, we identified a small number of patients (according to their mammograms) who were diagnosed as being without any abnormalities. If this were to happen in a normal screening process, such patients might slip through undiagnosed. We noted that ultrasound did indeed pick up all abnormalities. As a result, we can conclude that ultrasound used in combination with mammography is advantageous in detecting TN breast cancer.

Among DCIS, subtypes of DCIS correlate to the progression to invasive carcinoma; comedo type DCIS progresses to invasive carcinoma, both more often and more rapidly than low-grade DCIS (Pinder SE & Ellis IO, 2003; Ketcham AS & Moffat FL, 1990). From our findings, comedo components were frequently seen among lesions, and these comedo components are thought to be one reason for the rarity of TN DCIS. These results do not adequately explain the rarity of TN DCIS with its growth speed. The expression of ER, PgR, or HER2 is different between intraductal and invasive components within a patient in fewer cases, and its significance (whether it can be explained by dedifferentiation) has attracted a lot of interest recently. TN DCIS is thought to be a complex of several phenotypes. Not all TN DCIS cases progress rapidly to invasive cancer.

In lesions consistent with noninvasive and invasive components, the expression of HER2 differs between these two components, positive in the noninvasive part, and negative in the invasive part. ER positivity between these two components is almost the same (50–75%), however, HER2 positivity in DCIS is much higher than in invasive cancer, 32–55 and 20–25%, respectively. It is thought that a high proportion of DCIS lesions that progress to invasive lesions do lose overexpression of HER2 (Wiechmann L & Kuerer HM, 2008). Therefore, when hormone-negative and HER2-positive DCIS progresses to an invasive carcinoma, it becomes a TN invasive carcinoma, which might be another reason for the rarity of TN DCIS.

Our findings suggest that TN DCIS cases are less likely to have calcifications in comparison with non-TN DCIS. TN DCIS are also detected mainly as masses or asymmetry. US and MRI findings of TN DCIS are almost the same as those of DCIS as seen in previous studies. From our data, almost all TN DCIS were observed as low echoic masses by US, which leads us to believe that US is a more important diagnostic tool than MMG in detecting TN DCIS. By using US more frequently, the detection rate of TN DCIS should be elevated.

## 5. Conclusion


We diagnosed TN DCIS in 3.0% of all DCIS cases. There were fewer incidences of mammographic abnormal calcifications with TN DCIS than with non-TN DCIS. Mammography and ultrasound imaging together revealed that the morphological features of TN breast cancer include a lobulated mass, with less attenuating posterior echoes, some vascularity, and low elasticity.

## 6. References

- Betsill, WLJ, Rosen, PP., Lieberman, PH. & Robbins, GF. (1987). Intraductal carcinoma. Long-term follow-up after treatment by biopsy alone. *JAMA*, Vol. 239, No.18, (May 1978), pp. 1863–7, ISSN 1538- 3598
- Bradley, BB., Stuart, JS. & Laura, CC. (2006). Ductal carcinoma in situ with basal-like phenotype: a possible precursor to invasive basal-like breast cancer. *Mod Pathol.*, Vol.19, No.5, (May 2006), pp. 617–21, ISSN 1530-0285
- Collett, K., Stefansson, IM., Eide, J., Braaten, A., Wang, H., Eide, GE., Thoresen, SØ., Foulkes, WD. & Akslen, LA. (2005). A basal epithelial phenotype is more frequent in interval breast cancers compared with screen detected tumors. *Cancer Epidemiol Biomarkers Prev.* Vol.14 No.5, (May 2005), pp. 1108-12, ISSN 1538-7755
- Dent, R., Trudeau, M., Pritchard, KI., Hanna, WM., Kahn, HK., Sawka, CA., Lickley, LA., Rawlinson, E., Sun, P. & Narod, SA. (2007). Triple-negative breast cancer: clinical features and patterns of recurrence. *Clin Cancer Res.*, Vol.13, No.15, (Aug 2007), pp. 4429-4434, ISSN 1557-3265
- Dershaw, DD., Abramson, A., Kinne, DW. (1989), Ductal carcinoma in situ: mammographic findings and clinical implications. *Radiology*, Vol. 170, No. 2, (Feb 1989), pp. 411–5, ISSN 1527-1315.
- Dogan, BE., Gonzalez-Angulo, AM., Gilcrease, M., Dryden, MJ., Yang, WT. (2010). Multimodality imaging of triple receptor-negative tumors with mammography, ultrasound, and MRI. *Am J Roentgenol.* Vol.194, No.4, (Apr 2010), pp. 1160-6, ISSN 1546-3141

- Ernster, VL., Barclay, J., Kerlikowske, K., Wilkie, H. & Ballard-Barbash, R. (2000). Mortality among women with ductal carcinoma in situ of the breast in the population-based surveillance, epidemiology and end results program. *Arch Intern Med.*, Vol.160, No.7, (Apr 2000), pp. 953–8, ISSN 1538-3679
- Flora, Z., Theodoros, NS. & George, CZ. (2007). Precursors and preinvasive lesions of the breast: the role of molecular prognostic markers in the diagnostic and therapeutic dilemma. *World J Surg Oncol.*, Vol.5, (May 2007), pp. 57–68.
- Frykberg, ER. (1997). An overview of the history and epidemiology of ductal carcinoma in situ of the breast. *Breast J.*, Vol.3, No.5, (Sep 1997), pp. 227–31, ISSN 1524-4741
- Ikeda, DM., Anderson, I. (1989). Ductal carcinoma in situ: atypical mammographic appearances. *Radiology.* Vol.172, (Sep 1989), pp. 661–6, ISSN 1527-1315.
- Itoh, A., Ueno, E., Tohno, E., Kamma, H., Takahashi, H., Shiina, T., Yamakawa, M., Matsumura, T. (2006). Breast disease: clinical application of US elastography for diagnosis. *Radiology.* Vol.239, No.2, (May 2006), pp. 341–50, ISSN 1527-1315
- Iwase, H., Kurabayashi, J., Tsuda, H., Ohta, T., Kurosumi, M., Miyamoto, K., Yamamoto, Y., Iwase, T. (2010). Clinicopathological analyses of triple negative breast cancer using surveillance data from the Registration Committee of the Japanese Breast Cancer Society. *Breast Cancer*, Vol.17, No.2, (Nov 2010), pp.118–24, ISSN 1880-4233
- Jinguji, M., Kajiya, Y., Kamimura, K., Nakajo, M., Sagara, Y., Takahama, T., Ando, M., Rai, Y., Sagara, Y., Ohi, Y. & Yoshida, H. (2006). Rim enhancement of breast cancers on contrast-enhanced MR imaging: relationship with prognostic factors. *Breast Cancer*, Vol.13, No.1, (Jan 2006), pp. 64–73, ISSN 1880-4233
- Ketcham, AS. & Moffat, FL. (1990). Vexed surgeons, perplexed patients, and breast cancers which may not be cancer. *Cancer.* Vol.65, No.3, (Feb 1990), pp. 387–93, ISSN 1097-0142
- Ko, ES., Lee BH., Kim HA., Noh, WC., Kim, MS. & Lee, SA. (2010). Triplenegative breast cancer: correlation between imaging and pathological findings. *Eur Radiol*, Vol.20, No.5, (May 2010), pp. 1111–7, ISSN 0938-7994
- Kopans, DB. (1998), *Breast imaging*, (2nd ed.), Lippincott-Raven, ISBN 0-397-51302-X, Philadelphia
- Livasy, CA., Perou, CM., Karaca, G., Cowan, DW., Maia, D., Jackson, S., Tse, CK., Nyante, S. & Millikan, RC. (2007). Identification of a basal-like subtype of breast ductal carcinoma in situ. *Hum Pathol.*, Vol.38, No.2, (Feb 2007), pp. 197–204, ISSN 1532-8392
- Moriya T, Kanomata N, Kozuka Y, Hirakawa H, Kimijima I, Kimura M, Watanabe M, Sasano H, Ishida T, Ohuchi N, Kurebayashi J. & Sonoo, H. (2010). Molecular morphological approach to the pathological study of development and advancement of human breast cancer, *Med Mol Morphol.*, Vol.43, No.2, (Jun 2010), pp. 67–73, ISSN 1860-1499
- Page, DL., Dupont, WD., Rogers, LW. & Landenberger, M. (1982). Intraductal carcinoma of the breast: follow up after biopsy alone. *Cancer*, Vol.49, No. 4, (1982), pp. 751–8, ISSN 1097-0142
- Page, DL., Dupont, WD., Rogers, LW., Jensen, RA. & Schuyler, PA. (1995). Continued local recurrence of carcinoma 15–25 years after a diagnosis of low grade ductal carcinoma in situ of the breast treated only by biopsy. *Cancer*, Vol.76, N0.7, (Oct 1995), pp. 1197–200, ISSN 1097-0142

- Pinder, SE. & Ellis, IO. (2005). The diagnosis and management of preinvasive breast disease: ductal carcinoma in situ (DCIS) and atypical ductal hyperplasia (ADH)—current definitions and classification. *Breast Cancer Res.*, Vol.5, No. 5, (Jul 2003), pp. 254–7, ISSN 1465-5411
- Schnall, MD., Blume, J., Bluemke, DA., DeAngelis, GA., DeBruhl, N., Harms, S., Heywang-Köbrunner, SH., Hylton, N., Kuhl, CK., Pisano, ED., Causer, P., Schnitt, SJ., Thickman, D., Stelling, CB., Weatherall, PT., Lehman, C. & Gatsonis, CA. (2006). Diagnostic architectural and dynamic features at breast MR imaging: multicenter study. *Radiology*, Vol.238, No.1, (Jan 2006), pp. 42–53, ISSN 1527-1315
- Schnitt, SJ., Silen, W., Sadowsky, NL., Connolly, JL. & Harris JR. (1988). Ductal carcinoma in situ (intraductal carcinoma) of the breast. *N Engl J Med.*, Vol.318, No.14, (Apr 1988), pp. 898–903, ISSN 1533-4406
- Simpson, JF. (2009). Update on atypical epithelial hyperplasia and ductal carcinoma in situ. *Pathology*, Vol.41, No.1, (Jan 2009), pp. 36–9, ISSN 1465-3931
- Stomper, PC. (1989). Clinically occult ductal carcinoma in situ detected with mammography: analysis of 100 cases with radiologicpathologic correlation. *Radiology*, Vol.172, No.1, (Jul 1989), pp. 235–41, ISSN 1527-1315
- The Committee of Mammography Guideline (Japan Radiological Society, Japanese Society of Radiological Technology). (December 2010). *Mammography guidelines* (3rd ed.), Igaku Syoin, ISBN978-4-260-01204-1, Tokyo, Japan
- Uematsu, T., Kasami, M., Yuen, S. (2007). Triple-negative breast cancer: correlation between MR imaging and pathologic findings. *Radiology*, Vol.250, No.3, (Mar 2009), pp. 638–647, ISSN 1527-1315
- Wang, Y., Ikeda, DM., Narasimhan, B., Longacre, TA., Bleicher, RJ., Pal, S., Jackman, RJ. & Jeffrey, SS. (2008) Estrogen receptor-negative invasive breast cancer: imaging features of tumors with and without human epidermal growth factor receptor type 2 overexpression. *Radiology*, Vol.246, No.2, (Feb 2008), pp. 367–75, ISSN 1527-1315
- Wiechmann, L. & Kuerer, HM. (2008). The molecular journey from ductal carcinoma in situ to invasive breast cancer. *Cancer*. Vol.112, No.10, (May 2008), pp. 2130–42, ISSN 1097-0142
- Yang, WT., Dryden, M., Broglio, K., Gilcrease, M., Dawood, S., Dempsey, PJ., Valero, V., Hortobagyi, G., Atchley, D. & Arun, B. (2008). Mammographic features of triple receptor negative primary breast cancers in young premenopausal women. *Breast Cancer Res Treat*, Vol.111, No.3, (Oct 2008), pp. 405–10, ISSN 0167-6806



## **Mammography - Recent Advances**

Edited by Dr. Nachiko Uchiyama

ISBN 978-953-51-0285-4

Hard cover, 418 pages

**Publisher** InTech

**Published online** 16, March, 2012

**Published in print edition** March, 2012

In this volume, the topics are constructed from a variety of contents: the bases of mammography systems, optimization of screening mammography with reference to evidence-based research, new technologies of image acquisition and its surrounding systems, and case reports with reference to up-to-date multimodality images of breast cancer. Mammography has been lagged in the transition to digital imaging systems because of the necessity of high resolution for diagnosis. However, in the past ten years, technical improvement has resolved the difficulties and boosted new diagnostic systems. We hope that the reader will learn the essentials of mammography and will be forward-looking for the new technologies. We want to express our sincere gratitude and appreciation to all the co-authors who have contributed their work to this volume.

### **How to reference**

In order to correctly reference this scholarly work, feel free to copy and paste the following:

Yasuyuki Kojima, Reika In and Hiroko Tsunoda (2012). Radiologic Features of Triple Negative Breast Cancer, Mammography - Recent Advances, Dr. Nachiko Uchiyama (Ed.), ISBN: 978-953-51-0285-4, InTech, Available from: <http://www.intechopen.com/books/mammography-recent-advances/current-research>

# **INTECH**

open science | open minds

### **InTech Europe**

University Campus STeP Ri  
Slavka Krautzeka 83/A  
51000 Rijeka, Croatia  
Phone: +385 (51) 770 447  
Fax: +385 (51) 686 166  
[www.intechopen.com](http://www.intechopen.com)

### **InTech China**

Unit 405, Office Block, Hotel Equatorial Shanghai  
No.65, Yan An Road (West), Shanghai, 200040, China  
中国上海市延安西路65号上海国际贵都大饭店办公楼405单元  
Phone: +86-21-62489820  
Fax: +86-21-62489821

© 2012 The Author(s). Licensee IntechOpen. This is an open access article distributed under the terms of the [Creative Commons Attribution 3.0 License](#), which permits unrestricted use, distribution, and reproduction in any medium, provided the original work is properly cited.