

Microsurgical Management and Functional Restoration of Patients with Obsolete Spinal Cord Injury

Zhang Shaocheng
*Department of Orthopaedics, Changhai Hospital
The 2nd Military Medical University Shanghai
China*

1. Introduction

Obsolete or chronic traumatic paraplegia is still a difficult medical problem at present time. Many patients with manifestations of post-injury changes in the spinal cord may have similarly normal images when observed with imaging technology like the MRI. These normal imaging results, however, do not indicate that the spinal cord is intact. Indeed, apart from compression and instability, a great difference in the sensory and motor function recovery is always seen among patients though they may have similar MRI imaging changes. So what factors then affect the recovery of the nerves functions? Through anatomical studies and operative observations, we have found that adhesions in the (**endorhachis**), the traction of the fibrous strip, traumatic scars, (**mollescence**), and cysts are among the main reasons. Elimination of most of these factors has been shown to benefit patients by increasing their potentials for functional recovery. Authur Dr.Zhang Shaocheng who as a survival and a member of medical team , his experiences with the treatments of patients who sustained either incomplete or complete spinal cord injury from the Tangshan (Hebei provence, China) earthquake in 1976; as well as numerous patients with spinal cord injuries from various causes in present time, have also led to the concept that additional functional recovery do occur in patients after using specialized microsurgical techniques like dural sheath slitting, nerve segments implantations among others which form the basis for this publication. The author is privileged to disclose that the Tangshan earthquake, herein mentioned, claimed the lives of 250,000 persons, over 240,000 persons sustained various type of traumatic injuries, and about 6,000 persons manifested either paraplegia or quadriplegia and related complications associated with spinal cord injuries.

Some patients received previous non-specific treatments before attending our services, while others were treated by us first hand. Records of patients thus treated with these specialized microsurgical techniques show early nerve function recovery compared with results from their prior non-specific treatment. Prior MRI studies done on these patients showed that the spinal cords had no severe damages. During the operation, any impediments to functional recovery of the spinal cord such as bone compression or unstable canales spinalis stenosis were eliminated.

Patients with chronic high-level complete spinal cord injury suffer from spastic paralysis as well as bowel and bladder dysfunctions, which cannot be improved by drug treatment or physical therapy. It has been reported from the works of doctors in many countries, based on their decades of clinical experiences, that connecting normal peripheral nerve with root-injured brachial plexus could improve some nerve functions. This mature technology inspired the author to help restore some neurological functions in patients with chronic high-level complete spinal cord injury by connecting normal peripheral nerves, from above the paralysis level, with peripheral nerves around paralyzed parts. As limb muscles are spastic and peripheral nerves, their dominating regeneration capacity, after spinal cord injury occurring later and higher than that of brachial plexus injury, so the prognosis of patients with chronic spinal cord injury is better than that of brachial plexus nerve root injury, given the same operation. Furthermore, after the donor nerve grows to the target muscles, nerve impulses causing target muscle contraction can also stimulate the high-tension coordinating muscle that can be trained to improve limb function.

However, the amount of the neurological function that paraplegic and quadriplegic patients need to regain is much more than what brachial plexus injury patients need, and the number of donor nerve is relatively in shortage. Therefore, only a few nerve functions can be regained. How to connect donor nerve with target nerve fiber accurately is the key. Another important issue to consider is how to maintain and take advantage of appropriate muscle tension and pathological contraction, and prevent target muscles from atrophying after surgery until new nerve fibers grow into the receptor nerve. The response to these concerns can be seen in our surgical approach where we wedge cut the outer membrane of donor nerve fiber and some perineurium of receptor nerve, and cut off some nerve fibers selectively in the muscle to maintain appropriate tension. Finally the donor nerve was embedded into the incision on the receptor nerve, and the outer membranes of the two were sutured together. We term this procedure as nerve **insert** grafting surgery (Fig.1 Fig.2) and the clinical results are quite satisfactory.

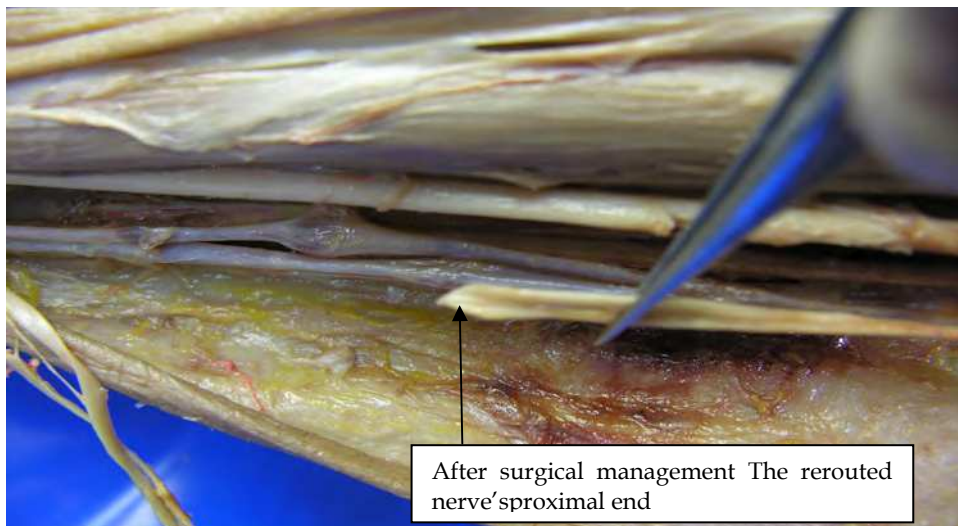


Fig. 1. Simulant procedures of Nerve rerouting ,insert grafting and selected suture interfascicular on cadaver specimen.

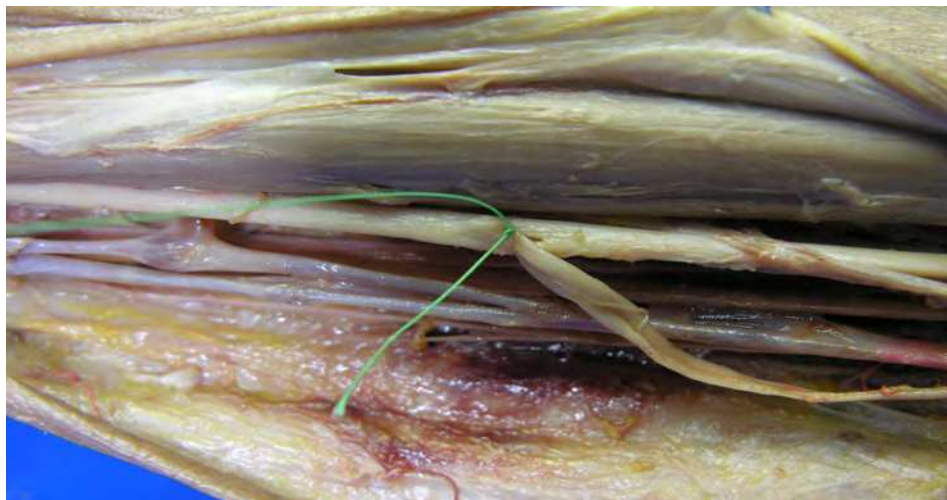

Fig. 2. Simulant procedures of Nerve rerouting ,insert grafting and selected suture interfascicular on cadaver specimen.

2. Patients with late incomplete rupture of spinal cord

2.1 Relief mini- incisions of the dura mater

This procedure was useful in incomplete paraplegic patients who showed early nerve function recovery 3 months after a traumatic injury in whom also there were no observed improvements after three additional months of physical therapy. CT scan and MRI images of these patients showed no severe spinal cord damages. For the procedure, under general anaesthesia, the patient was placed in a lateral or prone position prepped and draped. A midline lumbar skin incision was made and exposure done down to the level of the spinal canal. Impediments to functional recovery of the spinal cord such as bone compression, for some patients or unstable canales spinalis stenosis, in others were eliminated. The *endorhachis* of the involved segment of the spinal cord was exposed and found to be thickened, hardened, and without pulsation. We made about three to six 1cm longitudinal slit-like incisions on this layer with the assistance of a 4-6X forehead microscope in the thickened and hardened areas, leaving the arachnoid and pia mater spinalis intact (Figure 2.1).The pulsation of the dura mater recovered, which is obvious after complete release. We covered the spinal cord with artificial dura mater or sacrospinal muscle flap and closed the wound. We may conclude that the compression in the dural sac is the main obstacle to nerve function recovery, a condition which could not be relieved by the body itself. This microsurgical technique did promote functional nerve recovery in our patients.

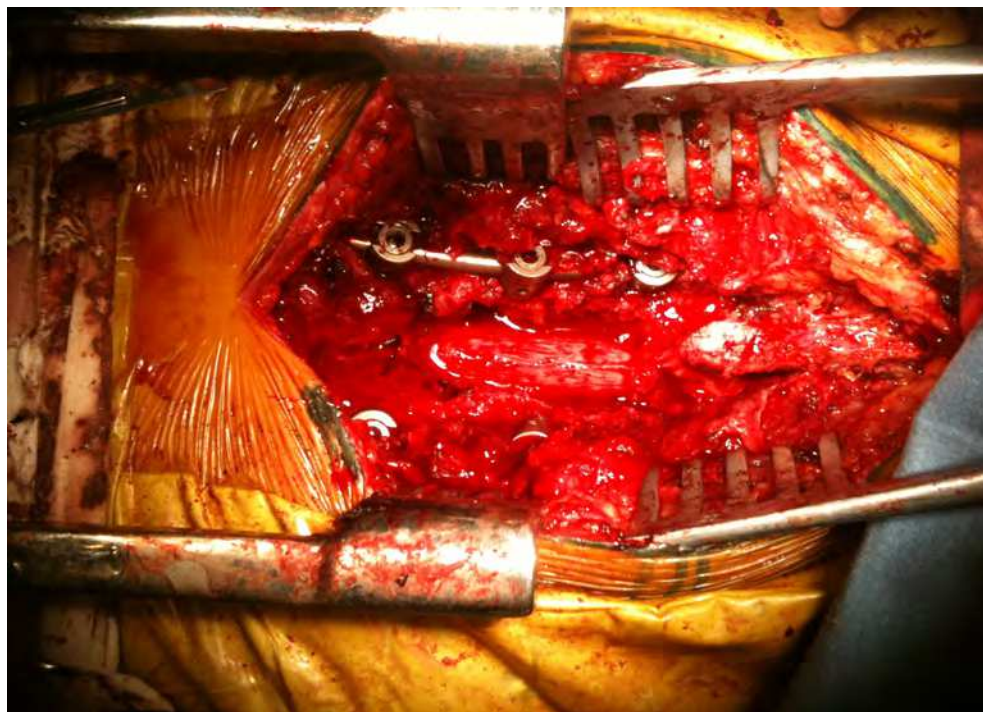


Fig. 3. Intra-op view showing mini incisions on the dura.

2.2 Intra-dural microlysis of the spinal cord and nerve roots

Similar to the procedure described in section 2.1, in some patients with late spinal cord injury, whose MRI pictures show that the injured spinal cord area is very close to the dura, or where the nerve roots are adherent to the dura by scar tissues, or where there are other strange shadows between the spinal cord and the dura, we may still open the *endorachis*. Since the fibrous band, strip, or scar were small and inconspicuous, careful and repeated observation to determine their presence and subsequent removal was necessary, as missing any of these would adversely affect the results (Figure 2.2). It was always observed intra-operatively that the initial parts of the nerve root were adherent to the spinal cord, and that a strip of fibrous tissues were seen between the anterior and posterior branches of the nerve root which dragged or pinched the spinal cord. We noted that the adhesions of the arachnoid and the pulling of the ligamenta denticulatum by these fibrous tissues made that affected segment of the spinal cord to appear structurally changed. The pia mater spinalis became thicker and adherent to the spinal cord, thus compressing it. The adhesion between the spinal cord and the arachnoid, compression by the pia mater spinalis, ligamenta denticulatum, nerve root, as well as the peripheral fibrous tissues were all completely relieved by the same microsurgical technique.

Finally, the *endorachis* and spinal canal were covered by a sacrospinal muscle pedicle flap. All the patients showed descend in their sensory planes and an increase in muscle force above grade one. The major muscle force of both lower extremities recovered above grade three and partial ability of walking was regained. Additional benefits were bowel and bladder functions improvement.

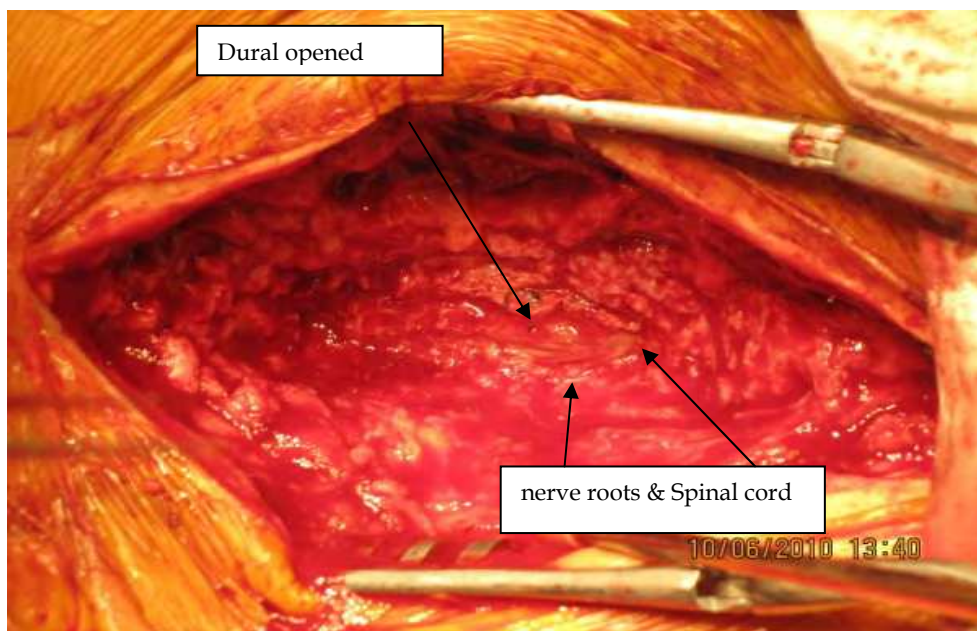


Fig. 4. Intra-op view of intradural microlysis.

2.3 Intradural lysis and peripheral nerve implantation

In some patients with late spinal cord injury, following decompression and lysis of the dura, the abnormal crimped spinal cord was opened by making three to six incisions on its surfaces dorsally and laterally, each about 0.1 mm to 0.2 mm deep and extended beyond the abnormal part. Autogenous sural nerve segments were harvested corresponding to the length of the area of abnormality (Figure 2.3). After these peripheral nerve segments were microsurgically denuded of their epineuriums and perineuriums, making them resemble cauda equina-like tissues, they were aligned longitudinally with severed strips implanted into the spinal cord incisions.

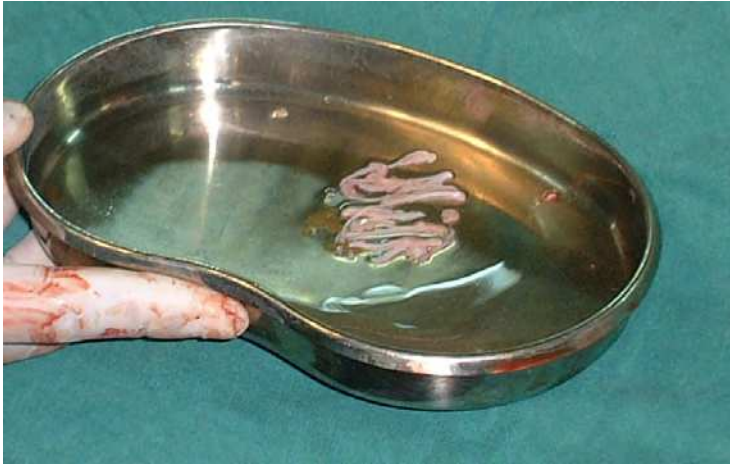

Fig. 5. Harvested autogenous sural-nerve segments.

Finally, the endorachis and spinal canal were covered by a sacrospinal muscle pedicle flap. All patients showed recovery of sensory, motor, as well as bowel and bladder functions.

2.4 Cyst aspiration and peripheral nerve implantation

In clinical practice, if a cyst of 1×1 cm in size or larger, as indicated by the pre-surgical MRI imaging review, or if the cyst could clearly be observed through its dark-colored, fluctuant, and thin-walled nature during surgical procedure, it should be punctured with a fine needle, aspirated a little and incision about < 3mm be made on the injured cord area, and its content drained out. The defect thus created by this technique can be covered with segments of peripheral nerve implants as described in section 2.3. This is done to prevent sudden sac wall collapse which might further complicate the existing spinal cord injury. Finally closure is done in layers. Such method can improve the function of sensory, motor nerves, and bowel and bladder activities.

3. Patients with late complete rupture of the spinal cord

3.1 Microlysis of proximal spinal cord and nerve roots

To present, there is still no convincing method of recovering spinal cord function in paraplegic and quadriplegic patients suffering from spinal cord injury. Meanwhile, it is well known that, due to its anatomic characteristics, there are always different degrees of injury to nerve root 1-3 segments above the ruptured spinal cord level (Figure 3.1). In clinical practice, these functions experienced complete loss in the acute period, and partially restore with regression of the acute traumatic reaction. Unfortunately, 1-3 months post-injury, in the proximal end of the spinal cord, particularly due to the reaction, scars formed and caused nerve roots adhesions such that the recovered function could not be conducted by nerve roots.

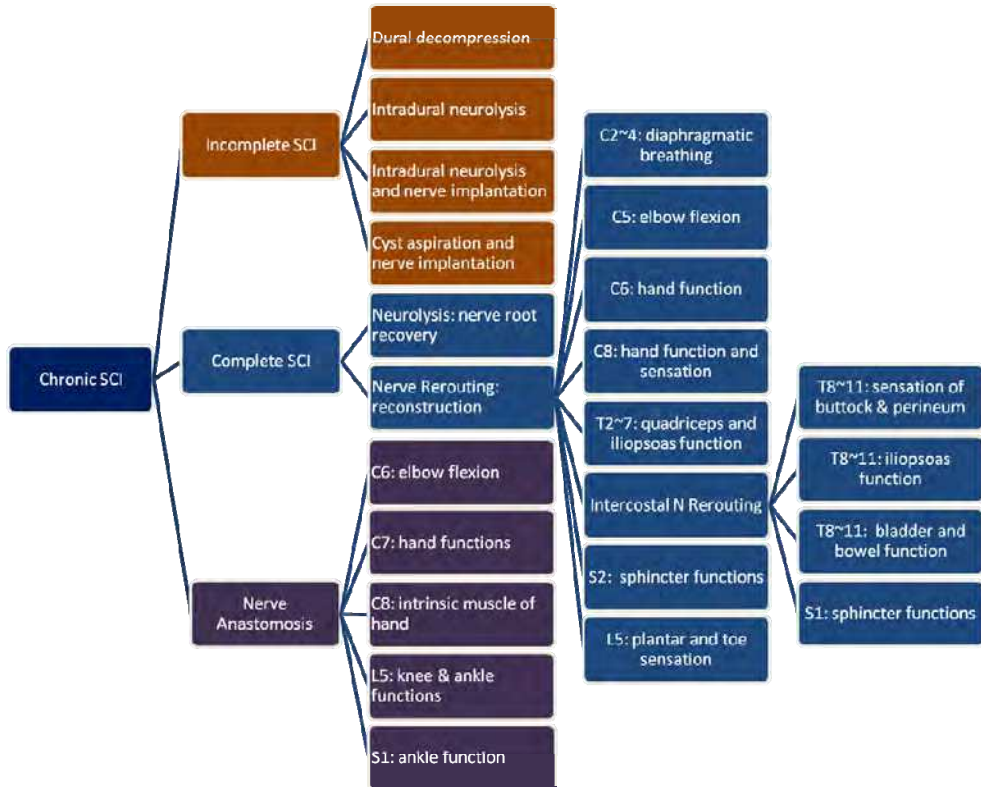


Fig. 6. Anatomy showing nerve roots in their original position.

To save the function of these nerve roots and improve the quality of life for patients with lower cervical and thoraco-lumbar region complete spinal cord injury, we perform another microsurgical technique. Under general anaesthesia, a dorsal midline incision is made on the skin and dissection made down to the spinal canal. After general epidural lysis of scars and decompression, the dura mater of the involved area was exposed and opened with the help of a 4-6X forehead microscope or a 6× to 40× operating microscope, where necessary. The proximal broken end of the spinal cord and corresponding nerve roots were exposed. These nerve roots with their relatively integrated continuity in anatomical morphology were thoroughly and sharply released from their initial parts to the intervertebral foramen area under the microscope. After lysis, the injured spinal cord area was covered with artificial dura mater or sacrospinal muscle flap. All patients who underwent this procedure showed recovery or improved partial sensory and motor functions of 1-2 nerve root segments.

3.2 Function restoration of chronic complete spinal cord injury by peripheral nerve rerouting and nerve insert grafting

Various nerve-rerouting surgeries are described below:



3.2.1 C2~4 Injuries: Connecting nerve branch of accessory nerve with phrenic nerve

Indications: C2~4 injured patients who show no spontaneous breathing and required ventilator support, and the strength of at least one side of the trapezius muscle. Surgical purposes: To restore part of diaphragmatic breathing function, which means breathing through the shrug movement without ventilator support in the awoken state. Anatomy: Accessory nerve is formed by cranial nerve root and spinal cord root (mainly C1 ~ 4), and cervical plexus nerves are composed of anterior branches of C1~4. So accessory nerve function was intact in spinal cord injury below C5 nerve level. Sternocleidomastoid and trapezius muscles were mainly dominated by accessory nerve, but most of the muscular branches were bifurcated in muscles, therefore cutting accessory nerve at supraclavicular level only affect partial strength of the trapezius muscle, with no loss of other important function. Surgical procedures: Accessory nerve was cut off proximally, and then rerouted and “grafted” into phrenic nerve in the relaxed state (Figure 7).

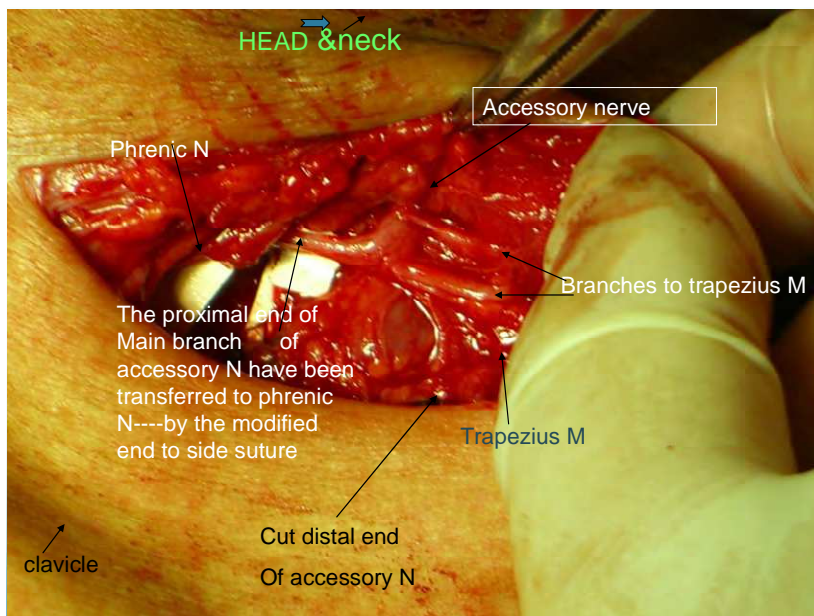


Fig. 7. Surgical procedure where accessory nerve is connected to phrenic nerve in the neck.

3.2.2 C5 Injury: Connecting nerve branches of accessory nerve and cervical plexus nerve with musculocutaneous nerve

Indications: C5 injured patients with quadriplegia for more than one year, no recovery of elbow flexion function, intact trapezius muscle function, and age <50-year-old.

Surgical purposes: To reconstruct elbow flexion.

Surgical procedures: A small transverse incision was made at the supraclavicular level, and then the main branch of accessory nerve was exposed and cut off. Musculocutaneous nerve was exposed below the clavicle and part of nerve fiber was cut off selectively. Get through an under-skin tunnel between the two incisions, then reroute and “graft” accessory nerve with musculocutaneous nerve.

3.2.3 C6 Injury: Connecting nerve branches of accessory nerve and cervical plexus with median nerve

Indications: Patients with no recovery of hand/wrist function.

Surgical purposes: To reconstruct some hand function.

Surgical procedures: Branches of accessory nerve and cervical plexus were cut off distally, then transferred to the supraclavicular level and “grafted” into the internal root or proximal segment of the median nerve (Figure 8).

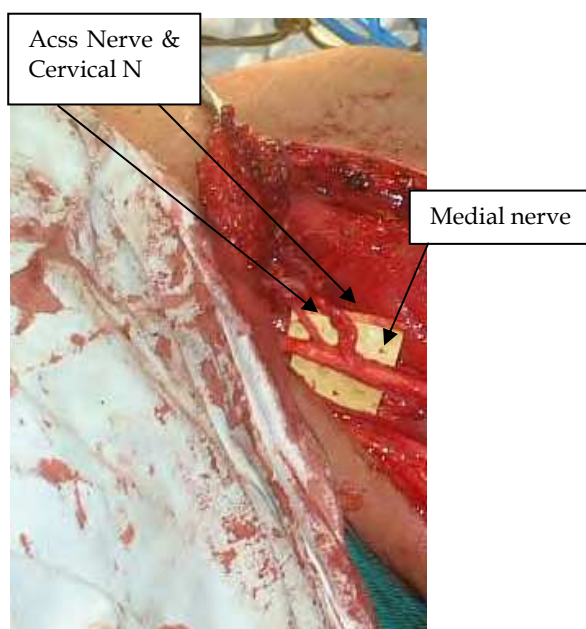


Fig. 8. Intra-op view of connections of accessory, cervical plexus and Median nerves in the supraclavicular region.

3.2.4 C8 Injury: Connecting pronator quadratus muscle branch of anterior interosseous nerve with deep branch of ulnar nerve, and superficial branch of radial nerve with superficial branch of ulnar nerve

Indications: loss of intrinsic muscles function, and sensitivity of little finger and ulnar part of ring finger. The strength of pronator quadratus muscle is of level 3 or more.

Surgical purposes: To rebuild part of motor functions of hand and sensitivity of ulnar part of hand.

Anatomy: Anterior interosseous nerve is composed of nerve fibers from C6 and C7. Thus there is no significant effect by cutting off pronator quadratus muscle branch.

Surgical procedures: Cut off pronator quadratus muscle branch of anterior interosseous nerve in the volar forearm, and then "graft" to the ulnar nerve. Superficial branch of radial nerve is connected to the superficial branch of ulnar nerve using conventional methods (Figure 9).

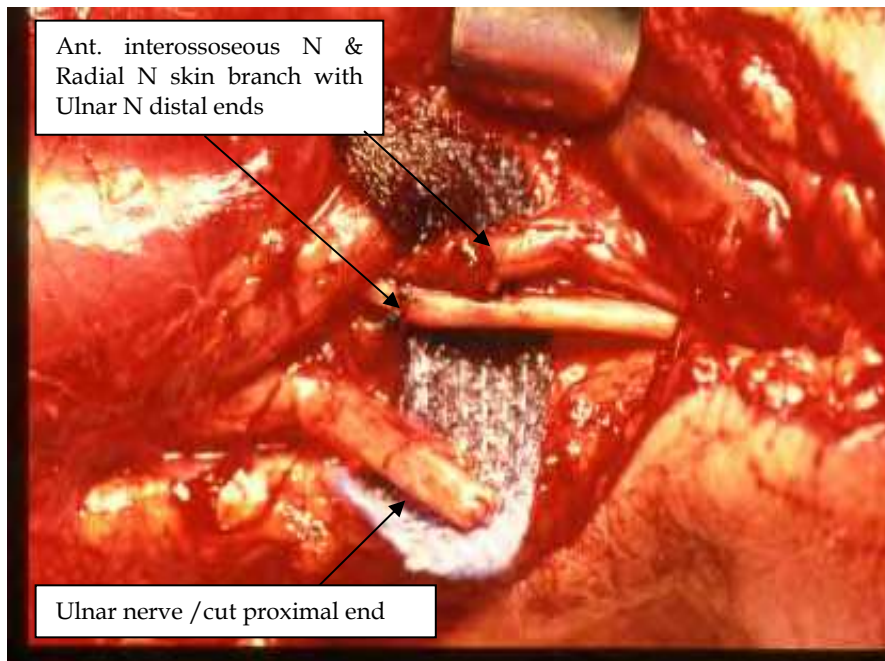


Fig. 9. Segments of Ant. Interosseous, and branches of radial and ulnar nerves.

3.2.5 T2~7 Injuries: Connecting vascularized ulnar nerve with femoral nerve

Indications: Young patients who sustained T2~ 7 injuries want to have the operation; also to fully understand the functional damage in recipient nerve area.

Surgical purposes: To rebuild partial motor function of quadriceps and iliopsoas muscles. This may improve walking ability with brace assistance.

Anatomy: Ulnar nerve is composed of nerve fibers from C7~ T1. Femoral nerve is composed of nerve fibers from L2~4, which dominate quadriceps and iliopsoas muscle innervations.

Surgical procedures: Ulnar nerve is transected from the wrist area. The remaining distal end of ulnar nerve is connected to the median nerve using conventional methods. Alternatively, this distal end may be connected to the anterior interosseous nerve or superficial branch of radial nerve to maintain some function of the ulnar nerve in the arm. The detached ulnar nerve is then separated *non-invasively*, together with the forearm portions of the ulnar artery and vein or superior ulnar collateral vessels, up to its beginning in the brachial plexus. Through subcutaneous tunnel in the trunk, the ulnar nerve is rerouted to the groin region (Figure 10). Separate and connect thoracodorsal artery and vein with the superior ulnar collateral artery and vein in the side of the chest wall, or connect ulnar artery and vein with deep iliac artery and vein or femoral artery and vein. Then the deep or superficial branches of ulnar nerve are connected to the femoral nerve, and the dorsal branch stitched to the ilioinguinal nerve.

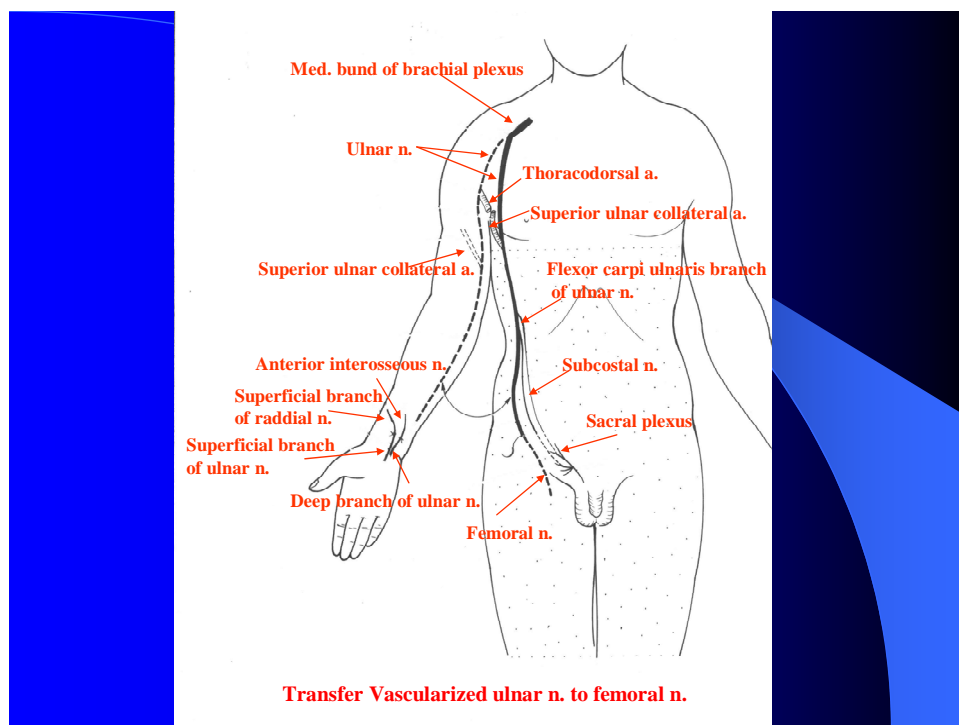


Fig. 10. Diagram of restoration of stepping-forward and ambulatory functions in individuals with paraplegia through rerouting of vascularized ulnar nerve to femoral nerve in the groin.

3.2.6 Vascularized intercostal nerve rerouting

Transferring intercostal nerve to the cauda equina or terminal nerve roots has been carried out for nearly a hundred years, but because of no significant effect comparing with high expectations; recently few doctors are willing to carry out such surgeries with hope of achieving better results. We have made some modifications: 1. Reroute intercostal nerve along with its vessels, to improve blood supply to nerve and decrease adhesion (Figure 11); 2. Only transect particular bundles of receptor nerve fibers, to maintain proper muscle tension and pathological reflex; 3. Stitching nerve in the epidural area is suggested, according to results from animal experiments and clinical trail; 4. Vascularize the nerve to be bridged, for example, arterialize the sural nerve by anastomosis of small saphenous vein with intercostal artery.

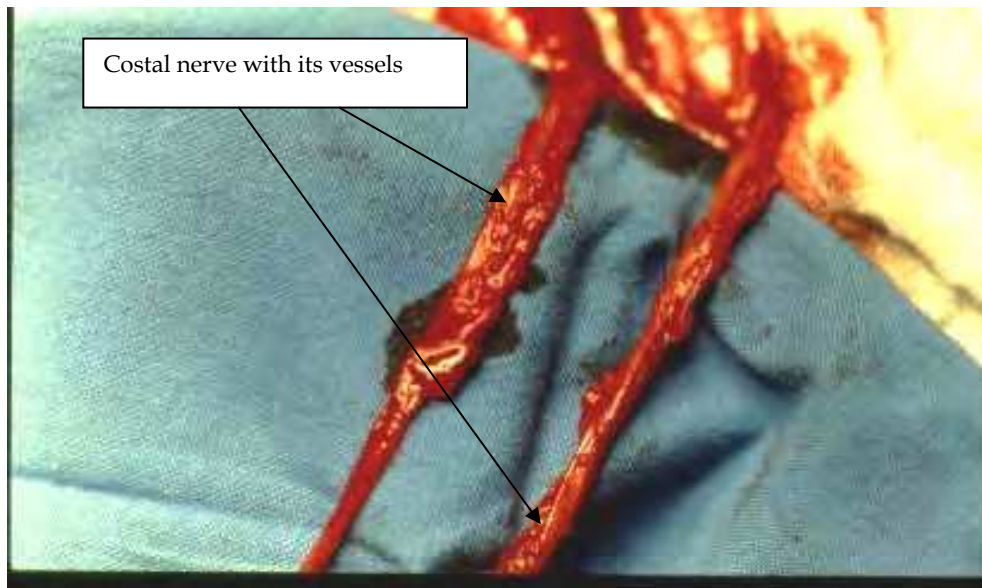


Fig. 11. Costal nerve with its vessels.

3.2.6.1 T8-T11 Injuries: Vascularized intercostal nerve rerouting to connect lateral femoral cutaneous nerve with ilioinguinal nerve to regain sensation of buttocks, lateral femoral and external genitalia regions

Indications: Male patients with complete injury to nerve roots T9~11 and show no recovery of sensory and motor functions, however, they do experience penile erection. It is also indicated for young women with strongly expressed desire to improve genital sensation.

Surgical purposes: To regain sensation of buttocks, the lateral femoral and external genitalia regions.

Anatomy: The intercostal nerve is formed by the anterior branch of the thoracic nerve while the lateral femoral cutaneous nerve is formed by L2~3 nerve fibers, which is divided into anterior and posterior branches in the groin. The anterior branch distributes to the skin of the anterolateral thigh, and the posterior branch distributes to the skin of the lateral thigh. Ilio-inguinal nerve is formed by T12~L2 nerve fibers, which distributes to the skin of upper and medial thigh, the penis and scrotum or labia.

Surgical procedures: Take separately the 8th and 9th intercostal nerves as example: separate intercostal nerves with their vessels, and reroute them to the ilio-inguinal and lateral femoral cutaneous nerves, and then connect them directly or bridge with sural nerve segment.

3.2.6.2 T8-T11 Complete Injuries: Connecting vascularized intercostal nerve with selective bundles of L1/2 nerve roots to reconstruct iliopsoas function (grafting technique)

Indications: Spastic paralysis of both lower extremities.

Surgical purposes: To reconstruct iliopsoas function (mobile with brace)

Anatomy: iliopsoas, quadriceps and vastus medialis are controlled by nerve fibers from L2~4 nerve roots. Patients with improved iliopsoas function could achieve hip flexing, and train quadriceps to contract synchronously to facilitate knee extension.

Surgical procedures: Isolate and transect two intercostal nerves above paraplegic plane with intercostal vessels, and connect them with selective bundles of L2 or L2/3 nerve roots. If the length of the intercostal nerve is not enough, then harvest sural nerve for bridging.(Fig 12)

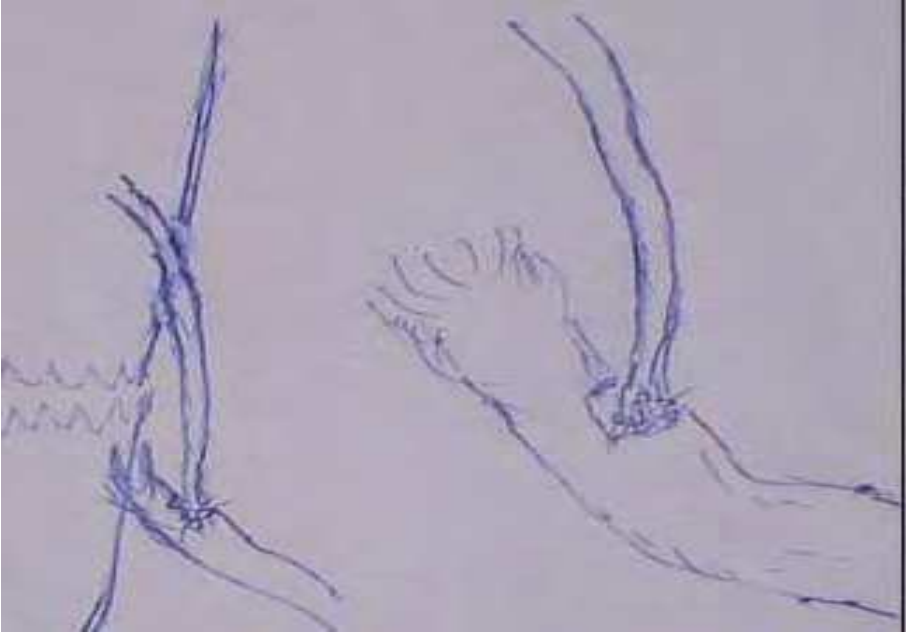

Fig. 12.

3.2.6.3 Connecting vascularized intercostal nerve with sacral nerve root to reconstruct partial bladder and bowel function (grafting technique)

Indications: T8-T11 injuries.

Surgical purposes: To reconstruct partial bladder and bowel functions.

Anatomy: S2~4 nerve roots innervate the anal and urethral sphincters. In patients with spinal cord injury above T12, lower central nervous system functions of defecation and urination are preserved and their low-level reflex arc remains intact, but lost contact with the high-level central nervous system. So, bladder and bowel functions could be improved as long as the establishment of such a neural pathway, which only needs a few nerve fibers to rebuild, exists. This approach allows part of the normal mixed nerve (intercostal nerve) fibers to connect with the sacral nerve roots and pelvic nerve plexus to establish urination reflex, and also rebuild partial sphincter and sensory function at the same time.

Surgical procedures: The procedures are the same as that of connecting L1/2 nerve roots, except that the receptor nerve is the sacral nerve not lumbar nerve. The number of receptor

nerve root fibers to be transected depends on the severity of bladder and sphincter spasm (Figure 13a & Figure13b).

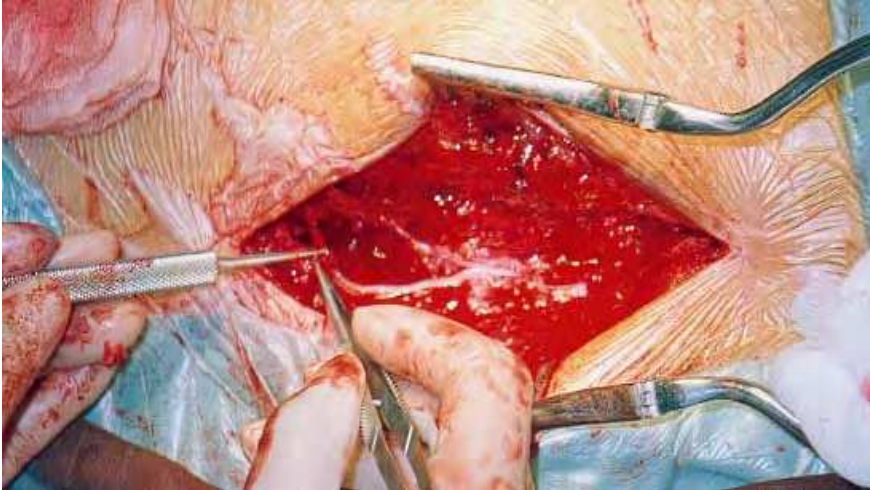


Fig. 13a.

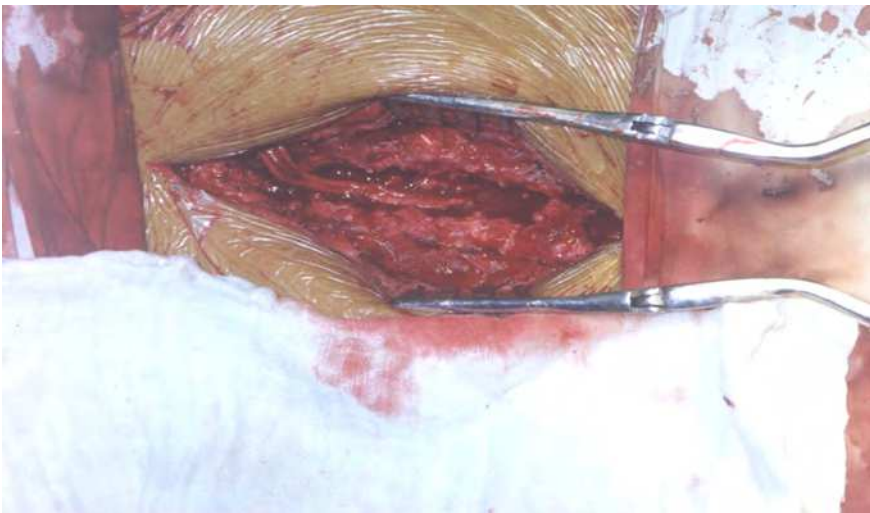


Fig. 13b.

3.2.6.4 Connecting vascularized intercostal nerve with ilio-inguinal nerve for sensation in the perineum

Surgical procedure: One incision about 12cm long laterally on the chest wall along the 8th or 9th rib. Expose the underlying tissues and take the vascularized intercostals nerve. Make

another incision about 8cm long laterally in the costo-iliac region of the abdominal wall; explore and identify the ilio-inguinal nerve. Make a subcutaneous tunnel connecting the two incisions (Figure 3.2.6.4a). Anastomose the intercostal nerve with the ilio-inguinal nerve in this tunnel by bridging sural nerve graft (Figure 14a/b).

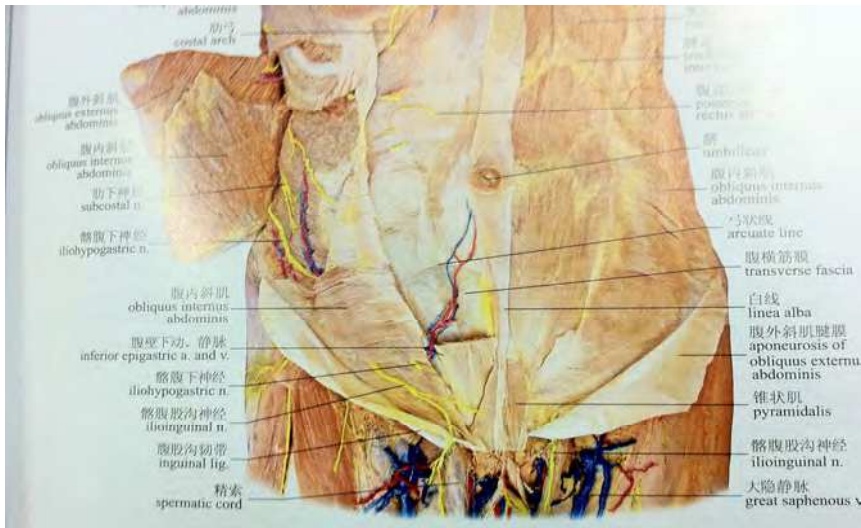

Fig. 14a. Anatomy Atlas illustrating musculo-cutaneous nerves and vessels ilioinguinal nerve.

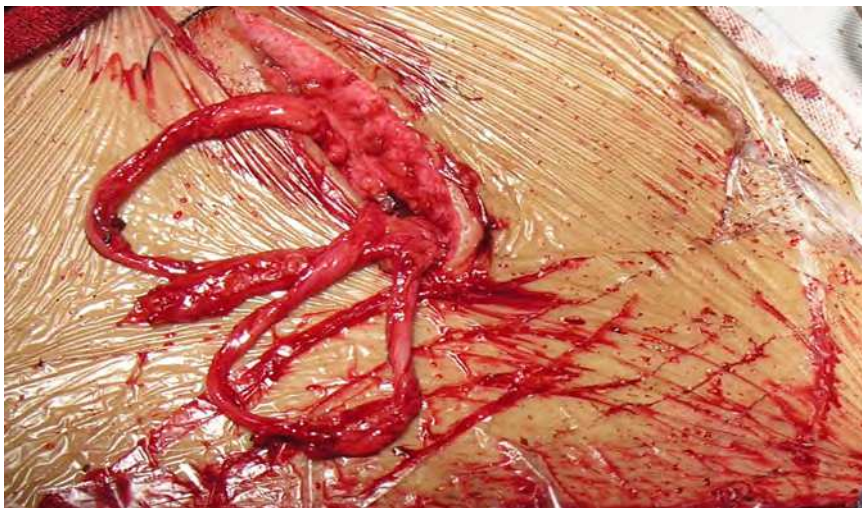


Fig. 14b. Intra-op demonstration of tunneling technique in the subcostal-iliac region.

3.2.6.5 S1 Injury: Connecting vascularized intercostal nerve to pudendal nerve

Indication: Incontinence after the injury with injury time <6 months

Surgical purpose: To restore the urethral anal sphincter functions, and improve stool and incontinence.

Surgical procedure: Locating and transecting the intercostal nerve as described in section 3.2.6. Locating the pudendal nerve, this can be found at the basin of a 1-2cm long incision in the hip, and connect it with intercostal nerve through a subcutaneous tunnel (Figure 15).

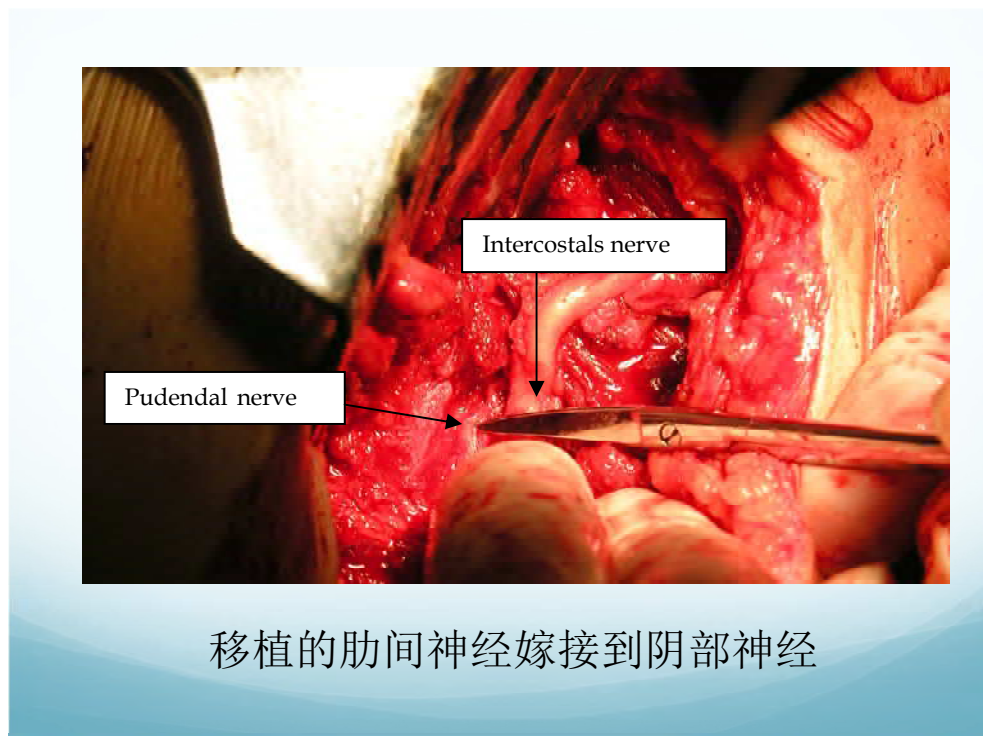


Fig. 15. Intercostal and pudendal nerves anastomosis.

3.2.6.6 S2 and below injuries: Connecting muscle branch of superior/ inferior gluteal nerve with pudendal nerve

Indications: Incontinence for >6 months and the strength of gluteus muscle > level 3.

Surgical purpose: To reconstruct part of the urethral and external anal sphincter function

Anatomy: superior/ inferior gluteal nerve is mainly composed by nerve fibers from L4~S1, with a trunk of about 2cm length, and then divided into multiple muscular branches into the gluteal muscle. Cutting one of these muscular branches would not cause significant gluteal dysfunction. Pudendal nerve is formed by nerve fibers from S2~4. The place where these two nerves go out of pelvis are very close to each other. And the muscular branches of superior/ inferior gluteal nerves are long enough to be connected with pudendal nerve directly.

Surgical procedure: In the incision in the hip, isolate superior/inferior gluteal nerve near piriformis muscle and find the pudendal nerve by the outer edge of the sacrum. Cut off one of the muscular branches of superior/inferior gluteal nerve, and connect it with pudendal nerve.

3.2.6.7 L5 or below injury: Connect sural nerve to tibial nerve to improve sensation of plantar surface and toe

Indications: *Restore the ability of walking and sense of lateral malleolus/ instep, but no sense of plantar and toe.*

Surgical purposes: To improve sensation of plantar surface and toe.

Anatomy: Sural nerve can be cut at the distal lateral malleolus and connected to the tibial nerve.

Surgical procedure: Separate sural nerve in the distal lateral incision on the leg, and connect it to the tibial nerve via a subcutaneous tunnel.

Injury	Method	'Donor'	'Receptor'	Function
C2~4	R	Branch of accessory nerve	Phrenic nerve	Diaphragmatic breathing function
C5	R	Branch of accessory nerve and cervical plexus nerve	Musculocutaneous nerve	Elbow flexion
C6	R	Branch of accessory nerve and cervical plexus	Median nerve	Hand function
C6	A	Axillary nerve	Musculocutaneous nerve	Elbow flexion
C7	A	Lateral root of median nerve	Medial root of median nerve	Hand function
	A	Posterior brachial plexus	Ulnar nerve	
C8	R	Pronator quadratus muscle branch of anterior interosseous nerve	Deep branch of ulnar nerve	Hand function and sensation
		Superficial branch of radial nerve	Superficial branch of ulnar nerve	
C8	A	Median nerve	Ulnar nerve	Hand intrinsic function
T2~7	R	Ulnar nerve	Femoral nerve	Walking
T8-T11	I	Lateral femoral cutaneous nerve	Ilioinguinal nerve	Sexual life
T8-T11	I	Intercostal nerve	Selective bundles of L1/2 nerve roots	Walking
T8-T11	I	Intercostal nerve	Sacral nerve root	Bladder and bowel function
L5	A	L3	L4	Knee and ankle function
L5 or below	R	Sural nerve	Tibial nerve	Plantar and toe sensation
S1	I	Intercostal nerve	Pudendal nerve	Bladder and bowel functions
S1	A	Peroneal nerve	Tibial nerve	Ankle function
S2 and below	R	Muscle branch of superior/ inferior gluteal nerve	Pudendal nerve	Bladder and bowel function

4. Peripheral nerve side- to- side interfascicular anastomosis

This operative technique involves several steps. First, the site of injury is explored and the injured nerve recovered and repaired by standard techniques. Second, a relatively normal nerve root, termed "donor nerve", is identified close to the injured nerve as possible. Third, this "donor" nerve is then drawn toward the injured nerve below the level of its site.

For example, if the L4 and L5 lumbar nerve roots had been injured, the nerve was chosen for side-to-side neurorrhaphy at the lower ventral thigh. If the lower trunk of the brachial plexus had been injured, the ulnar and median nerves were chosen for side-to-side neurorrhaphy which placed two nerves abreast closely at an appropriate segment. 1cm - 2cm longitudinal incision is made on the epineurium and partial perineurium were performed at the neighbor side. Then the incised epineurium and partial perineurium were sutured closely side-to-side with 9 to 11 monofilament nylon and microsurgical instruments. Fourth, the limb with the neurorrhaphy is immobilized with a cast for three to four weeks after surgery to avoid tension on the sutured nerves. Finally, physical therapy is advised, and neurotrophyl medication is administered in appropriate dosage.

The methods for peripheral nerve side-to-side anastomosis are as follows:

The procedure, as described above, involves shifting of a normal peripheral (donor) nerve in the paralyzed region to a receptor nerve to the same site. This is accomplished by transposing the distal end of the donor nerve to the region of the receptor nerve where we wish to establish the anastomosis. The length of side-to-side segments of the two nerves is 1cm-2 cm. The perineurium and epineurium layers of the two nerves are carefully opened and the side of the donor nerve is inserted into the incision made on the side of the receptor nerve. The two nerves are then embedded and stitched to each other and their perineuriums and epineuriums closed in layers.(Fig.16) For instance, if the tibial nerve lacks function due to injury and the lateral popliteal nerve is normal, their neighboring segments, about 5 cm proximal to their bifurcations, would be drawn together and approximated as described above. (Fig.17,18,19)

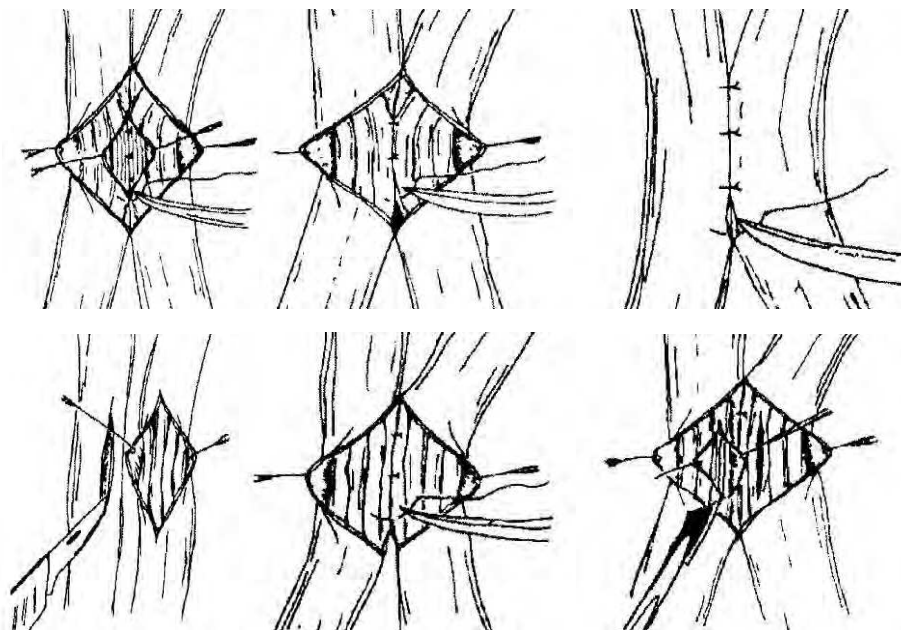


Fig. 16. Schematic Diagram of Side-to-side Neurorrhaphy: (A). Epineurium incision of the two neighboring nerves; (B). Suture on one side of the epineurium ;(C). Incision of the perineurium; (D). Suture one side of the perineurium ;(E). Suture another side of the perineurium ;(F). Suture another side of the epineurium.

Table 4.1 shows different types of donor-receptor nerve fiber anastomosis and their potential resultant benefits.



Fig. 17. Rat's tibia with fibular N side to side suture post operation 3 months ---looked as one nerve trunk).



Fig. 18. Anatomy show.

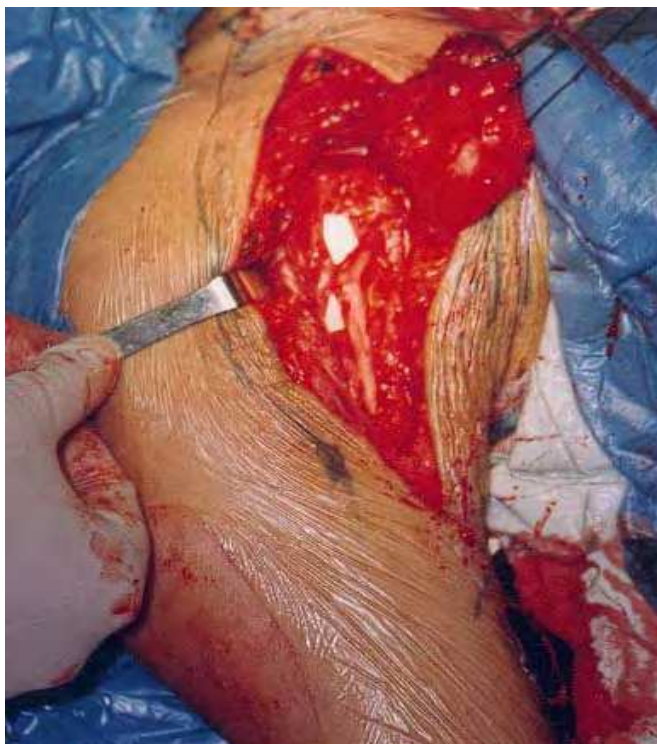


Fig. 19. Intra-op photo showing side-to-side suture of Lateral Cord with medial cord for restoration of hand function for a C7 level Spinal cord injured patient.

The level of spinal cord injury	Donor nerve	Receptor nerve	The anastomosis site	Functional reconstruction
C6	Axillary nerve	Musculocutaneous nerve	The anterior axillary region	The function of elbow flexion
C7	The lateral root of median nerve posterior plexus brachialis	The medial root of median nerve Ulnar nerve	The initial part of median nerve axilla	The function of hand
C8	Median nerve	Ulnar nerve	Upper arm in the lower 1 / 3	The function of Intrinsic muscle of the hand
L5	L3	L4	Pelvis	The functions of knee and ankle
S1	Peroneal nerve	Tibial nerve	The superior popliteal fossa region	The function of ankle

Table 4.1 The donor/receptor sites of side-to-side anastomosis in different levels of spinal cord injury.

5. Conclusion

The main objective of most current operations is to eliminate outside compression of the dural sac and stabilize the spine. Lacking the knowledge that the arrested functional recovery of the spinal cord can be due to scar formation on the inner dural sac, intradural sac lysis is often ignored, which influences the recovery of the spinal cord. Using microsurgical techniques, we completely loosened the scars and adhesions, and as for the scarring or a cystic spinal cord, the spinal cord was opened and autogenous peripheral tissues were implanted, so the functional recovery of a damaged spinal cord segment would be better improved, and the results be satisfactory by the time of initial clinical evaluation.

According to our clinical observation, most patients with chronic complete spinal cord injury received partial functional restoration by peripheral nerve rerouting and nerve grafting procedures. For complete paraplegic patients, even partial sensory, motor with additional bladder and bowel function restorations can bring much convenience, reduce complications and greatly improve their quality of life. As only a few nerves can be used for rerouting techniques, these series of microsurgical procedures can only restore limited and key functions. More training of muscle contraction caused by pathological reflex and

grafted nerve is necessary for effective motor function. In 226 cases follow-up between 3-28 years, effect active movement functions (M3) were restored in 37%, sensation (S2-S3) in 76%, *refelection* in 81%. Therefore, patients who cannot receive standard rehabilitation training would not get a satisfactory result. It can be recommended not to treat older patients in poor general condition, or patients of difficult economic standard with such surgery.

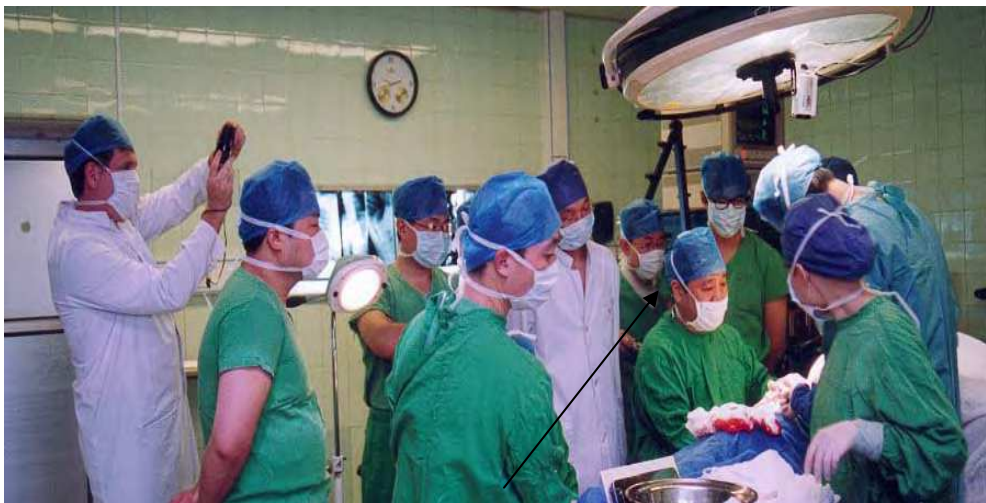


Fig. 20. Dr. Zhang Shaocheng M.D, the operator.

6. References

- [1] Frankel HL. Traumatic paraplegia. *Nurs Mirror Midwives J.* 1975; 141(19); 48-52.
- [2] McCormick PC. Spinal Cord Injury without Radiographic Abnormality. *Neurosurg. Suppl.* 2002; 50; 53:100.

- [3] Dang R, Zhang S, Ji R, et al. Applied anatomy of lumbosacral nerve roots corresponding to the T12-L4 vertebra. *Chinese J Anatomy*. 1996; 19:381-4.
- [4] Cigliano A, Scarano E, De Falco R, et al. The posterolateral approach in the treatment of post traumatic canal stenosis of the thoraco-lumbar spine. *J Neurosurg Sci*. 1997; 41:387-93.
- [5] Horvat JC. Spinal cord reconstruction and neural transplants. New therapeutic vectors. *Bull Acad Natl Med*. 1994; 178(3):455, dis. 464.
- [6] Zompa EA, Cain LD, Everhart AV, et al. Transplant therapy: recovery of function after spinal cord injury. *J Neurotrauma* 1997;14(8):479-506.
- [7] Giovanini MA, Reiter PJ, Eskin TA, et al. Characteristics of human fetal spinal cord grafts in the adult rat spinal cord: influences of lesion and grafting conditions. *Exp Neurol*. 1997; 148(2):523-43.
- [8] Delamarter RB, Sherman J, Carr JB, et al. Pathophysiology of spinal cord injury: recovery after immediate and delayed decompression. *J Bone Joint Surg (Am)*. 1995; 77: 1042-9.
- [9] Zhang SC, Zhao J. Gatism treated with neuroanastomosis. *J Neurol Orthop Med Surg*. 1993; 14:37-8.
- [10] Zhang SC, Ma Yuhai, Liu Hui ren, et al. Intradural Lysis and Peripheral Nerve Implantation for Traumatic Obsolete Incomplete Paralysis. *Orthopaedic Surgery. Surgical Technology International*, 2007; 15:321~24
- [11] Shaocheng Zhang, Xuesong Zhang, Rongming Ji. Functional Reconstruction of Peripheral Nerves in Paraplegia. *J Neurol Orthop Med Surg* 2000 20(3):89~97
- [12] Zhang SC, Zhao J. Gatism treated with neuroanatomosis. *J Neurol Orthop Med Surg*, 1993, 14(1):37~38
- [13] Zhang SC. Ulnar nerve transfer to the sciatic and pudendal nerves in paraplegia. *J Neurol Orthop Med Surg*, 1993, 14(6):3~4
- [14] Zhang SC, Laurence J, Zhang ZW. Restoration of stepping-forward and ambulatory function in patients with paraplegia: rerouting of vascularized intercostals nerves to lumbar nerve roots using selected interfascicular anastomosis. *Surgical Technology International*, 2003; 11:244~248
- [15] Zheng MX, Xu WD, Qiu YQ, Xu JG, Gu YD. Phrenic nerve transfer for elbow flexion and intercostal nerve transfer for elbow extension. *J Hand Surg Am*. 2010 Aug; 35(8):1304-9. Epub 2010 Jul 8.
- [16] Sullivan J, Spinal cord injury research: review and synthesis. *Crit Care Nurs Q*. 1999; 22(2):80-99.
- [17] Prochazka A, Mushahwar VK. Spinal cord function and rehabilitation-an overview. *J Physiol* 2001; 533(Pt 1):3-4
- [18] Pearson KG. Could enhanced reflex function contribute to improving locomotion after spinal cord repair? *J Physiol*. 2001; 533(Pt 1):75-81.
- [19] Zhang SC. Paraplegia treatment by anastomosis of lateral cutaneous nerve of thigh and ilioinguinal nerve with vascularized intercostals nerve for sensation reconstruction. *Acad J Sec Mil Med Univ* 1998; 19(3):264-5.
- [20] Zhang SC, Zang X. Functional reconstruction of peripheral nerves in paraplegia. *J Neurol Orthop. Med Surg* 2000; 20(3):89-97.
- [21] Zhang SC, Xiu XL, Li QH, et al. Nerve degeneration of lower extremity after paraplegia. *Acad J Sec Mil Med Univ*. 1999; 20(9):684-5.

- [22] Zhang Shao-cheng, Ma Yu-hai, Xu Shuo-gui, et al. Autoperipheral nerve implantation for the treatment of obsolete incomplete paralysis. *Chinese Journal of Clinical Rehabilitation*. 2006, 10(5): 161-163
- [23] Zhang Shao-cheng, Ma Yu-hai, Johnson Laurence, et al. Reconstruction of bowel and bladder function in paraplegic patients by vascularized intercostal nerve transfer to sacral nerve roots with selected interfascicular anastomosis. *Chinese Journal of Clinical Rehabilitation*. 2006, 10(17): 190-192
- [24] Zhang Shaocheng, Luo Chaoli, Zhao Yongjing, and YH Ma. The treatment of spastic cerebral palsy with side-to-side peripheral nerves anastomosis. *AANOS*, 2001, 21(3): 84-87.



Orthopedic Surgery

Edited by Dr Zaid Al-Aubaidi

ISBN 978-953-51-0231-1

Hard cover, 220 pages

Publisher InTech

Published online 09, March, 2012

Published in print edition March, 2012

Orthopaedic surgery is the widest and the strongest growing surgical specialty. It is clear, that the process of improving treatments and patients care, requires knowledge, and this requires access to studies, expert opinion and books. Unfortunately, the access to this knowledge is being materialized. As we believe that access to the medical knowledge should be reachable to everyone free of charge, this book was generated to cover the orthopaedic aspect. It will provide the reader with a mix of basic, but as well highly specialized knowledge. In the process of editing this book, my wife Jurgita has been, as usual, the most supportive person. I would like to thank her for being in my life. I would like to thank Mr. Greblo, the Publishing Process Manager, for all his help and last but not least thanks to our readers, as without them this book would have no meaning.

How to reference

In order to correctly reference this scholarly work, feel free to copy and paste the following:

Zhang Shaocheng (2012). Microsurgical Management and Functional Restoration of Patients with Obsolete Spinal Cord Injury, Orthopedic Surgery, Dr Zaid Al-Aubaidi (Ed.), ISBN: 978-953-51-0231-1, InTech, Available from: <http://www.intechopen.com/books/orthopedic-surgery/microsurgical-management-and-functional-restoration-of-patients-with-obsolete-spinal-cord-injury>

INTECH

open science | open minds

InTech Europe

University Campus STeP Ri
Slavka Krautzeka 83/A
51000 Rijeka, Croatia
Phone: +385 (51) 770 447
Fax: +385 (51) 686 166
www.intechopen.com

InTech China

Unit 405, Office Block, Hotel Equatorial Shanghai
No.65, Yan An Road (West), Shanghai, 200040, China
中国上海市延安西路65号上海国际贵都大饭店办公楼405单元
Phone: +86-21-62489820
Fax: +86-21-62489821

© 2012 The Author(s). Licensee IntechOpen. This is an open access article distributed under the terms of the [Creative Commons Attribution 3.0 License](#), which permits unrestricted use, distribution, and reproduction in any medium, provided the original work is properly cited.